

# Laparoscopic lateral suspension (Dubuisson) in the treatment of pelvic organ prolapse

Can Luo , Dongmei Wei, Yueyue Chen, Ling Mei, Xiaoyu Niu

**To cite:** Luo C, Wei D, Chen Y, *et al.* Laparoscopic lateral suspension (Dubuisson) in the treatment of pelvic organ prolapse. *Gynecology and Obstetrics Clinical Medicine* 2024;4:e000010. doi:10.1136/gocm-2024-000010

Received 16 February 2024  
Accepted 26 April 2024

## ABSTRACT

**Background** Currently, the global ageing population is becoming increasingly severe, and the incidence of pelvic organ prolapse (POP) is rising year by year, which seriously impacts the psychosomatic health and the quality of life in female patients. Surgical treatments for POP still face enormous challenges.

**Methods** The aim of this review is to discuss the laparoscopic lateral suspension (LLS) approach to the management of POP. We use MeSH terms for each topic to retrieve relevant literature from the PubMed and Embase databases. Our group reviewed, synthesised and summarised included studies.

**Results** LLS has been widely applied in the treatment of middle pelvic compartment defects. In comparison to sacrocolpopexy (SC), the most significant advantage of LLS is that it avoids dissecting the complex sacral region and possesses simple surgical procedures. But its cure, recurrence, reoperation and complication rates have been widely discussed. Issues regarding its value and its potential equivalence in surgical therapeutic effects compared with SC have gained continuous attention.

**Conclusions** Based on the existing research, LLS demonstrates advantages in the treatment of POP, particularly in cases of middle pelvic compartment defects. However, solely based on current clinical studies, it is premature to establish superiority or inferiority compared with SC. LLS is not yet a substitute for SC.

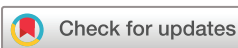fullness as the cardinal symptoms.<sup>2</sup> Wu *et al*<sup>3</sup> projected that by the year 2050, the morbidity rate for individuals experiencing symptomatic POP in the USA would attain 46%. At that juncture, about 9.2 million women will be affected.

Surgery is currently the primary treatment modality for severe POP, and there are various surgical methods and pathways available. The objectives of surgical intervention encompass alleviating symptoms and restoring the anatomical integrity of pelvic floor support.<sup>4</sup> The risk of undergoing surgery for POP or stress urinary incontinence (SUI) in a woman's lifetime in the USA ranges from 11% to 19%.<sup>5</sup> According to the literature, anterior pelvic compartment defects are the most common in POP, often occurring concurrently with middle pelvic compartment defects.<sup>6</sup> As per Delancey's theory of pelvic compartment defect, sacrocolpopexy (SC), as a correction for middle pelvic compartment and level I defect, has admitted to be the gold standard technique for the treatment of apical prolapse.<sup>7</sup> However, the execution of this surgical procedure requires intervention in the comparatively intricate sacral promontory region, situated on the right side adjacent to the ureter and iliac vessels. Intraoperatively, there is a risk of life-threatening haemorrhage, sacral nerve and ureteral injury, intervertebral discitis and even sacral osteomyelitis, particularly in obese women and patients with anatomical variations.<sup>8</sup> Therefore, the operation is technically challenging, demanding a high level of laparoscopic operative skills from the surgeon.

In 1998, laparoscopic lateral suspension (LLS), first introduced by Dubuisson in Switzerland,<sup>9</sup> sparked extensive discussions regarding its cure, recurrence, reoperation and complication rates. The evaluation of its value and its potential equivalence in surgical treatment effects compared with SC has gained continuous attention.<sup>10</sup> Based on

## INTRODUCTION

The pelvic floor anatomy is intricately complex, and the pelvic organs maintain their normal position and function with the support of surrounding compositions such as muscles, ligaments, blood vessels and nerves. With the processes of pregnancy, childbirth and ageing, the histological structure of the pelvic floor debilitates, leading to the occurrence of pelvic organ prolapse (POP).<sup>1</sup> Baerber *et al*<sup>2</sup> reported that the incidence of POP detected during physical examinations reached 50%, with a substantial portion of these cases being asymptomatic patients with POP. Merely 2.9%–8.3% of patients sought medical intervention, presenting with symptoms characterised by vaginal bulge and sensations of lower abdominal heaviness and



© Author(s) (or their employer(s)) 2024. Re-use permitted under CC BY-NC. No commercial re-use. See rights and permissions. Published by BMJ.

Department of Gynecology and Obstetrics, Sichuan University West China Second University Hospital, Chengdu, Sichuan, China

## Correspondence to

Dr Xiaoyu Niu, Department of Gynecology and Obstetrics, Sichuan University West China Second University Hospital, Chengdu, Sichuan, China; niuxy@scu.edu.cn

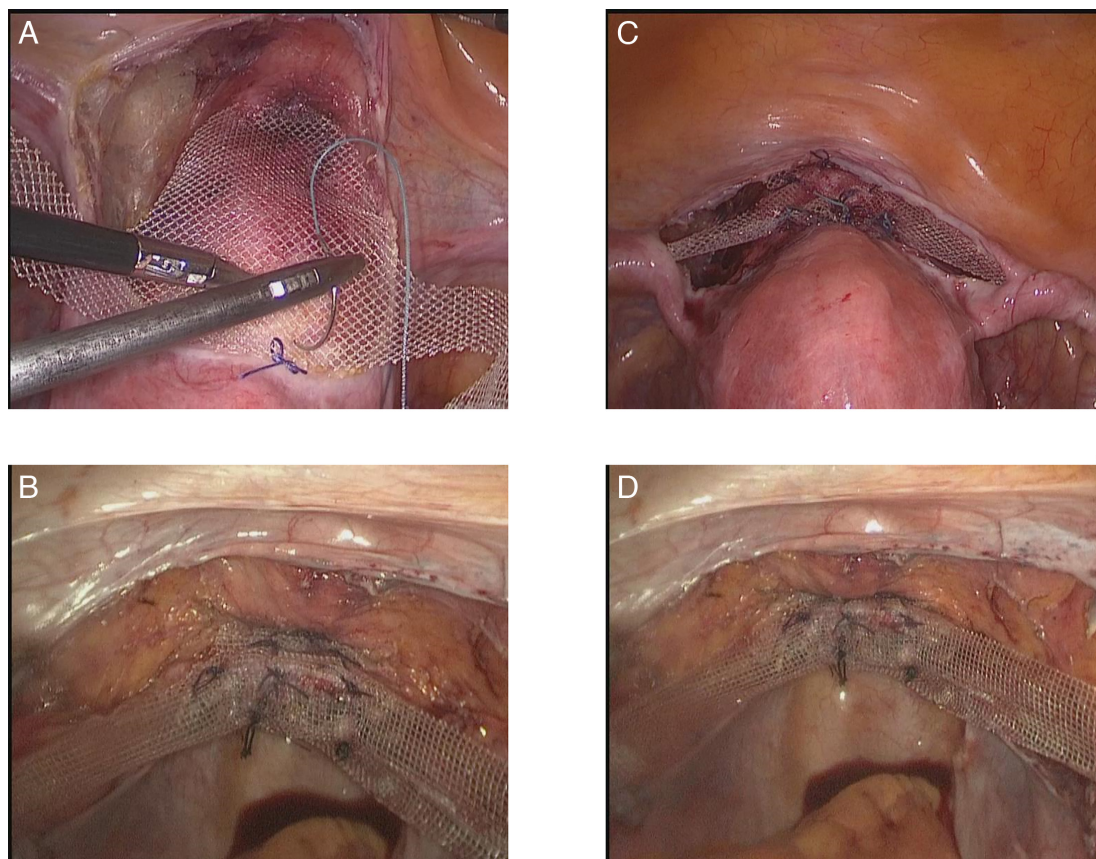
the latest clinical findings on LLS, this review provides an objective analysis and review, with the aim of conducting an in-depth analysis of this surgical technique for the benefit of the readers.

### HISTORICAL BACKGROUND AND OPERATIVE TECHNIQUE OF LLS

Dubuisson *et al* first proposed it in 1998.<sup>9</sup> Initially, LLS required the use of two meshes, positioned separately on the anterior and posterior vaginal walls.<sup>11</sup> However, due to a higher rate of mesh exposure, the approach was modified to employ a single anterior wall mesh combined with posterior colporrhaphy vaginally. To mitigate the morbidity of mesh-related complications, the mesh types have also evolved over the years, from the original use of Vicryl composite meshes or polyester meshes to polypropylene meshes, macroporous lightweight polypropylene meshes or precut titanium-coated polypropylene meshes. Furthermore, the suturing techniques for mesh fixation have also undergone several improvements, incorporating various types of non-absorbable sutures and novel absorbable tacks or fasteners.<sup>12</sup> Presently, Dubuisson *et al* recommend the use of absorbable sutures, as the mesh fibrosis can be firmly secured into the vaginal wall. In contrast, a non-absorbable suture carries a higher risk of postoperative mesh erosion, exposure and infection due to bacterial colonisation and foreign body rejection reactions.

The T-shaped polypropylene meshes used in LLS have side wings approximately 2–3 cm wide and 20–30 cm long. The central part of the mesh is laid flat in the vesicovaginal space, sutured and fixed onto the vaginal fascia. Through bilateral 2–3 mm cutaneous incisions in the lower abdominal wall (about 3 cm above and 4 cm lateral to the anterior superior iliac spines), atraumatic forceps are entered and perforated only the aponeurosis of the external oblique muscle to create tension-free retroperitoneal tunnels. Under the monitoring of the laparoscopic system and avoiding vascular areas, the forceps move towards the lateral abdominal wall through subperitoneal tunnels parallel to the ovarian vessels. Then the lateral arms of the mesh are anchored to the aponeurosis of the external oblique muscle and posterior to the bilateral anterior superior iliac spine (figure 1). Given that the central part of the mesh is anchored to the cervix and the mesh side wings attach within the retroperitoneal tunnels, the uterus forms a symmetrical lateral tension-free suspension. Ultimately, to mitigate mesh-related complications, the pelvic peritoneum is sutured to achieve reperitonealisation of the mesh surface.<sup>13</sup>

Dubuisson *et al* performed LLS on two patients who had POP in 1998,<sup>9</sup> and both achieved satisfactory anatomical cure rates and symptomatic improvement rates after surgery. Subsequently, they summarised the clinical data of 73 patients with apical POP treated by LLS in a



**Figure 1** Intraoperative photograph of LLS. (A) and (B) showed uterus preserved during the LLS procedure. (C) and (D) showed LLS combined with hysterectomy. LLS, laparoscopic lateral suspension.



prospective cohort study,<sup>14</sup> in which seven patients underwent concomitant repair of the posterior vaginal wall and perineal body. After a median follow-up of 17.5 months, the anatomical cure rate for apical prolapse reached 98.6%, with only one patient experiencing a recurrence of apical prolapse. When considering cases of anterior and posterior vaginal wall prolapse, the combined rate of de novo and recurrent prolapse was 17.8%, with a reoperation rate of % within follow-up. It is noteworthy that among the patients who underwent LLS in conjunction with posterior colporrhaphy, there were no observed cases of recurrent posterior wall prolapse.

LLS has been proposed as a potentially easier and safer alternative, particularly for the middle and anterior pelvic compartments.<sup>15</sup> According to Delancey's hammock theory, LLS mainly focuses on strengthening the level I support to address anterior and middle pelvic compartment defects while having a limited impact on level II and level III defects. For patients with evident preoperative rectocele, LLS can be performed along with the placement of a posterior pelvic compartment mesh in the rectovaginal space vaginally or posterior colporrhaphy vaginally.<sup>16</sup> However, it has been suggested that the lateral arms of the T-shaped mesh may not guarantee the closure of the pouch of Douglas, potentially leading to enterocele or Douglas hernia postoperatively.<sup>14</sup> However, the incidence of such complications is low, with a reoperation rate ranging from 2% to 7%.<sup>13 16–18</sup>

In 2020, a prospective double-centre study from Italy analysed the clinical data of 120 patients who were diagnosed with POP and receiving treatment for LLS.<sup>16</sup> Following 2 years after surgery, 89% of the patients indicated the disappearance of POP-related symptoms. The anatomical cure rates for the anterior and apical compartments were 94.2% and 94.9%, respectively, and the incidence of de novo posterior compartment prolapse was 1.7%. It was noted that patients with POP and a body mass index of >25 were more susceptible to developing de novo posterior pelvic compartment prolapse. According to another case series conducted in two medical centres in Italy,<sup>19</sup> 48 patients with POP (apical pelvic compartment ≥stage II with no or mild posterior pelvic compartment defect) underwent LLS; 1 year postoperatively, the anatomical cure rates for the anterior and apical pelvic compartments were 92% and 100%, respectively, and they reported no severe rectocele cases after surgery. Notably, LLS had a significantly shorter surgical time compared with SC (104 min vs 199±46 min,  $p<0.05$ ). If there are no obvious symptoms of rectal prolapse, it may not be necessary to treat the posterior pelvic compartment defect simultaneously. In a study,<sup>15</sup> researchers conducted LLS using a mini-laparoscopic approach, and they observed that only one case (2.8%) experienced de novo posterior pelvic prolapse, which did not necessitate surgical intervention. Some researchers believe that correcting posterior pelvic compartment defects can help reduce the risk of recurrence. A recent Cochrane systematic review<sup>20</sup> indicates that repairing posterior pelvic compartment

defects vaginally is the preferred method. If mesh materials are used, this must be carefully weighed against the risk of mesh-related complications. Several studies have demonstrated that the risk of mesh erosion increases fivefold when posterior pelvic compartment meshes are employed.<sup>21 22</sup> The surgical plan should be individualised, involving comprehensive preoperative communication with the patients and their family.

### COMPARATIVE EFFICACY OF LLS AND SC

The SC, in which the uterine or vaginal apex (after total hysterectomy) is fixed to the anterior longitudinal ligament of the sacrum with pelvic floor repair materials such as a mesh, is now widely recognised as the gold standard technique for the treatment of symptomatic apical stage II and above prolapse (level I defect), and it has been carried out in clinical practice for nearly 30 years.<sup>23</sup> SC included two paths: abdominal SC (ASC) and laparoscopic SC (LSC). Due to the complex anatomy of the anterior longitudinal ligament, which is situated at the sacral promontory, this procedure demands a high level of laparoscopic surgical skills from the operating surgeon. Through the study of the learning curve for SC, Claerhout *et al* reported that surgeons need to perform at least 60 SC procedures to achieve a satisfactory surgical cure rate and minimise the risk of surgical complication.<sup>24</sup> Malanowska *et al*<sup>25</sup> reported that LLS has a shorter learning curve (LSC: maximum operative time: 245 min, minimum operative time: 85 min; LLS: maximum operative time: 280 min, minimum operative time: 90 min), and it is technically less demanding than LSC.

According to reports in the literature, the early anatomical and subjective cure rate of SC was approximately 95%, with long-term rates ranging between 70% and 75%.<sup>26</sup> And a review reported an objective and subjective efficacy rate of around 90% for SC after a mean follow-up of 26 months.<sup>27</sup> Sarlos *et al* followed up with 101 patients who had POP treated with SC, showing an objective cure rate of 98% at 1 year postoperatively, which decreased to 83.8% after 5 years.<sup>28</sup> Literature indicates that the early anatomical and subjective cure rate of LLS is around 90%, with the cure rate remaining above 80% after 3 years of surgery.<sup>12</sup> However, there is currently a lack of long-term follow-up studies on LLS. Compared with SC, LLS offers a lower surgical complexity, a simpler procedure and a shorter learning curve, with 10–15 surgeries typically sufficient for a surgeon to become proficient in this technique.<sup>12</sup> Currently, there have been no reports of severe perioperative complications or cases requiring conversion from laparoscopy to laparotomy during LLS procedures.<sup>12</sup> In contrast, SC has a reported rate of severe complications of approximately 2.7%, including haematoma, peritonitis and sacral nerve injury,<sup>29</sup> and the intraoperative conversion rate to open surgery even reached 4%.<sup>30</sup>

Isenlik *et al*<sup>31</sup> conducted a study involving 80 patients with POP (all with ≥stage II apical/anterior pelvic

compartment defect and mild or no posterior pelvic compartment defect), who were randomly divided into the LLS combined with total laparoscopic hysterectomy (LLS-TLH) group and the SC combined with TLH (LSC-TLH) group. After 1 year of follow-up, the anatomical cure rates for the apical pelvic compartment were 92.5% versus 87.5% ( $p>0.05$ ), and for the anterior wall, the anatomical cure rates were 78.6% versus 74.1% ( $p>0.05$ ). The subjective cure rates in both groups were 87.5% versus 90% ( $p>0.05$ ). In the LLS-TLH group, three patients experienced apical compartment prolapse recurrence, six had anterior vaginal wall prolapse recurrence, and there was a 10% incidence rate of de novo posterior vaginal wall prolapse. Among all recurrent cases, three patients underwent LSC again due to symptomatic stage III recurrence. Nevertheless, in the LSC-TLH group, no apical compartment prolapse recurrence was reported; seven patients had anterior vaginal wall prolapse recurrence, and the de novo incidence of posterior pelvic compartment prolapse was 7.5%. Since the recurrence in this group was milder in degree and symptoms, none of the patients needed a reoperation. Both groups reported no severe adverse events during the perioperative period. In the SC-TLH group, one patient experienced vaginal mesh exposure at 6 months postoperatively and underwent exposed mesh excision under local anaesthesia. To the best of our knowledge, this is the first randomised controlled study comparing LLS and LSC, which suggests that LLS is effective for stage II or higher apical prolapse with or without an anterior pelvic compartment defect. However, due to the relatively short follow-up time, limited sample size and design flaws, the superiority or inferiority of LLS compared with LSC could not be definitively determined. High-quality, large sample, multicentre randomised controlled trials are needed to validate and draw conclusions.

### LLS AS A NOVEL ALTERNATIVE APPROACH FOR PATIENTS WITH APICAL POP

Common native tissue repair methods for correcting middle pelvic compartment defects include uterosacral ligament suspension (USLS) and sacrospinous ligament fixation (SSLF).<sup>32</sup> A meta-analysis<sup>33</sup> revealed that compared with ASC, SSLF had a lower surgical cure rate (88.32% and 91.45%; OR 0.52; 95% CI 0.29 to 0.95;  $p=0.03$ ), a higher recurrence rate (11.58% and 8.32%; OR 1.97; 95% CI 1.04 to 3.46;  $p=0.04$ ) and increased postoperative dyspareunia (14.36% and 4.67%; OR 3.10; 95% CI 1.28 to 7.50;  $p=0.01$ ). Another meta-analysis<sup>34</sup> demonstrated that the anatomical cure rate of laparoscopic USLS was 90% after an average follow-up of 22 months, with a subjective cure rate of 90.5%. In a randomised controlled trial published in 2023, the efficacy of USLS was compared with SSLF. At 1 year postoperative follow-up, the anatomical cure rates were 34.6% and 40% for the anterior pelvic compartment ( $p>0.05$ ), 100% for both groups in the middle pelvic compartment

and 73.1% and 92% for the posterior pelvic compartment ( $p>0.05$ ). However, there are no clinical studies comparing LLS, USLS or SSLF. Despite the remarkable efficacy of transvaginal mesh (TVM), the US Food and Drug Administration has issued repeated warnings regarding the safety of TVM due to the high incidence of mesh-related complications.<sup>35</sup>

As modern science further explores and recognises the pathogenesis of pelvic floor disorders, several basic studies have observed abnormal collagen metabolism and imbalanced mechanisms of oxidative stress within the pelvic floor tissues of patients with POP.<sup>36-37</sup> Some researchers have demonstrated that the 'uterus' is also a 'victim' in POP; unnecessary hysterectomy can further weaken the support of the pelvic floor tissues, exacerbating the clinical presentation of POP.<sup>38-39</sup> Simultaneously, the vagina loses support from surrounding ligaments, making the remaining stump prone to prolapse. Literature has reported a high rate of residual prolapse, up to 43%, following vaginal hysterectomy.<sup>40</sup> The traditional view among women holds that the 'uterus' represents 'identity' and 'dignity'. Most patients with POP believe that hysterectomy will affect their sexual satisfaction and that 'the uterus is a part of their sense of identity', therefore the majority of patients wish to preserve their uterus, especially young and sexually active ones.<sup>40</sup> Compared with total hysterectomy, preserving the uterus results in shorter surgical duration, reduced blood loss,<sup>39</sup> decreased risk of de novo posterior vaginal wall prolapse and a sixfold reduction in mesh-related infection risk.<sup>41-42</sup>

Veit-Rubin *et al*<sup>43</sup> followed up with 417 patients who received LLS, among whom 247 patients preserved their uterus; 74 patients had undergone hysterectomy for various reasons prior to the procedure, and 96 patients had intraoperative hysterectomy. One year after surgery, 78.4% of patients reported no POP-related symptoms. The anatomical cure rate was 91.6% for the anterior vaginal wall, 93.6% for the apical wall and 85.3% for the posterior wall. The overall reoperation rate due to recurrent prolapse was 7.3%. At a mean follow-up of 7.2 years, 214 patients participated in a telephone survey and more than 85% perceived an improvement in their condition, and patient satisfaction was linked to the decision regarding hysterectomy. In comparison to 339 symptomatic patients with uterine prolapse and/or cystocele who underwent LLS combined with total hysterectomy, those who underwent LLS while retaining the uterus exhibited significantly higher rates of anatomical cure and subjective symptom improvement. Yassa *et al*<sup>38</sup> conducted a retrospective analysis of clinical data from 17 patients who had POP treated by LLS with uterine preservation. After a median follow-up of 17.5 months, the anatomical cure rates for the apical and anterior vaginal walls were 100% and 88.2%, respectively. The subjective cure and patient satisfaction rates were 94.12% and 100%, respectively. They also noted a significant improvement in nocturnal urinary frequency. LLS is suitable for patients who are willing to retain their uterus, providing careful

anatomical and functional cure rates while maintaining the normal physiological axis of the vagina to a greater extent.<sup>44</sup> However, if the diagnosis indicates elongation of the uterine cervix, the recommended procedure is trachelectomy.

### PERIOPERATIVE COMPLICATIONS IN LLS

Regarding perioperative complications, most of them are concentrated on mesh complications. Two high-risk factors for mesh erosion<sup>21</sup> are tobacco use and mesh type. According to a recent systematic review<sup>45</sup> about the LLS, the study indicates that the mesh erosion rate ranges from 0% to 13%. This variation is associated with factors such as the type of mesh material, the duration of follow-up, sample size and accompanying surgical methods. None of the studies have reported any serious adverse events. According to the Clavien-Dindo classification system, there have been no complications classified as grade 4 or higher reported. A patient reported experiencing pain at the site of fixation of the abdominal mesh and was later cured by the ablation of the lateral suture fixing mesh days after surgery.<sup>46</sup> Dubuisson *et al*<sup>25</sup> indicated one case of bladder perforation during separation of the vesicovaginal space, who recovered completely within 7 days after promptly intraoperative repair of the bladder and postoperative catheterisation. Martiello *et al*<sup>26</sup> reported a patient who underwent a granulotomy for abdominal wall incision granuloma. The systematic review reports a rate of de novo constipation after LLS ranging from 0% to 5.9%, which is lower compared with SC; researchers speculate that this may be associated with relatively minimal damage to the lower abdominal nerves during LLS. The incidence of de novo SUI after LLS varies from 0% to 8.3%. Most literature did not report postoperative dyspareunia.

The normal axis of the vagina is very important for maintaining normal pelvic floor functions.<sup>47</sup> Under normal circumstances, the axis of the vagina is oriented posteriorly to the S3 and S4 axes,<sup>48</sup> maintaining a relatively horizontal position with the levator ani. Changes in the axis of the vagina following LLS have also been investigated in recent years. In a research study<sup>49</sup> in 2001, patients undergoing SSLF or SC procedures were subjected to MRI evaluation. The study involved measuring and comparing angles between the upper and lower segments of the vagina, the angle between the lower segment of the vagina and the pubic coccygeal line and the angle between the levator ani and the pubic coccygeal line. The researchers observed a deviation in the axis in the SC group, although it remained close to physiological limits. In contrast, the SSLF procedure disrupted the axis by pulling the vagina forward. SC positions the uterus more posteriorly than its normal anatomical location, placing the anterior compartment without the support of intra-abdominal pressure. This may lead to symptoms of urgency and

de novo anterior prolapse.<sup>38</sup> Some experts posit that postoperative LLS may result in anterior displacement of the vaginal axis and a comprehensive evaluation of clinical outcomes related to vaginal function has not been fully undertaken.

In a prospective case-control study conducted by Çiğdem *et al*<sup>44</sup> in 2021, the pelvic organ anatomical correction level following LLS was investigated. Additionally, postoperative changes in the vaginal axis were compared using MRI technology. The study included a total of 21 participants, with 11 patients undergoing LLS with uterine preservation and a control group consisting of 10 non-pregnant women. Preoperatively, the angle (angle A) between the pubic coccygeal line and the lower segment of the vagina in the study group was lower than that in the control group ( $54.90 \pm 3.32$ ,  $p < 0.001$ ). The angles (angle B) measured preoperatively in the study group and the control group between the levator ani and the pubic coccygeal line were  $7.73 \pm 1.85$  and  $12.4 \pm 4.48$ , respectively ( $p = 0.005$ ). The assessment of the angle (angle C) between the lower and upper segments of the vaginal axis in the study group and the control group yielded values of  $132.73 \pm 9.23$  and  $133.50 \pm 12.15$ , respectively ( $p = 0.871$ ). Regarding angle measurement changes in the LLS group preoperatively and postoperatively, angle A measurements were  $44.64 \pm 2.94$  and  $56.55 \pm 4.11$ , respectively ( $p < 0.001$ ). The measurements of the angle B were  $7.73 \pm 1.85$  preoperatively and  $12.55 \pm 1.97$  postoperatively ( $p < 0.001$ ). The measurements of the angle C were  $132.73 \pm 9.23$  and  $131.91 \pm 7.58$ , respectively ( $p = 0.833$ ). The researchers observed that, compared with non-pregnant women, angles A and B were compromised preoperatively but showed recovery postoperatively. However, the angle C in patients from both the control and LLS groups was found to be similar preoperatively. This study represents the inaugural application of MRI technology for the assessment of the vaginal axis following LLS. Nevertheless, the study is characterised by a limited sample size and a short follow-up duration, constituting the principal drawbacks that constrain the generalisability of its conclusions.

### CONCLUSION

The incidence of POP is increasing annually, making prevention and treatment of POP a central focus in the fields of pelvic floor and urogynecology. Based on the existing research, LLS demonstrates advantages in the treatment of POP, particularly in cases of middle pelvic defects. However, solely based on current clinical studies, it is premature to establish superiority or inferiority compared with SC. LLS is not yet a substitute for SC; rather, it represents an alternative surgical option. The benefits can be succinctly summarised as follows: (1) avoiding dissection of the sacral promontory. (2) a short learning curve, simplicity of the



procedure and low incidence of mesh-related complications; (3) providing a novel alternative for patients with POP who wish to preserve their uterus. However, there are ongoing debates regarding the issues of LLS associated with posterior pelvic defects and the vaginal axis. Current literature mostly consists of retrospective analyses or case studies, lacking high-level evidence from large samples and long follow-up prospective randomised controlled trials.

**Contributors** Conception and design: CL, LM, YC and XN. Administrative support: XN and DW. Manuscript writing: all authors. Final approval of the manuscript: all authors.

**Funding** This study was supported by the foundation of Science & Technology Department of Sichuan Province (No. 2019YFS0008, funder: DW) and the National Key Research and Development Program of China (No. 2021YFC2009100, funder: XN).

**Competing interests** None declared.

**Patient and public involvement** Patients and/or the public were not involved in the design, or conduct, or reporting, or dissemination plans of this research.

**Patient consent for publication** Not applicable.

**Ethics approval** Not applicable.

**Provenance and peer review** Not commissioned; externally peer reviewed.

**Open access** This is an open access article distributed in accordance with the Creative Commons Attribution Non Commercial (CC BY-NC 4.0) license, which permits others to distribute, remix, adapt, build upon this work non-commercially, and license their derivative works on different terms, provided the original work is properly cited, appropriate credit is given, any changes made indicated, and the use is non-commercial. See <http://creativecommons.org/licenses/by-nc/4.0/>.

## ORCID iD

Can Luo <http://orcid.org/0000-0003-1047-8473>

## REFERENCES

- Weintraub AY, Gliner H, Marcus-Braun N. Narrative review of the epidemiology, diagnosis and pathophysiology of pelvic organ prolapse. *Int Braz J Urol* 2020;46:5–14.
- Barber MD, Maher C. Epidemiology and outcome assessment of pelvic organ prolapse. *Int Urogynecol J* 2013;24:1783–90.
- Wu JM, Hundley AF, Fulton RG, et al. Forecasting the prevalence of pelvic floor disorders in U.S. *Obstet Gynecol* 2009;114:1278–83.
- McLeod LJ, Lee PE. Pelvic organ prolapse. *CMAJ* 2023;195:E1013.
- Smith FJ, Holman CDJ, Moorin RE, et al. Lifetime risk of undergoing surgery for pelvic organ prolapse. *Obstet Gynecol* 2010;116:1096–100.
- Payebto Zoua E, Boulvain M, Dällenbach P. The distribution of pelvic organ support defects in women undergoing pelvic organ prolapse surgery and compartment specific risk factors. *Int Urogynecol J* 2022;33:405–9.
- Vieillefosse S, Thubert T, Dache A, et al. Satisfaction, quality of life and lumbar pain following laparoscopic sacrocolpopexy: suture vs. tacksers. *Eur J Obstet Gynecol Reprod Biol* 2015;187:51–6.
- Vanlander AV, Muiño Mosquera L, Panzer J, et al. Megaconial muscular dystrophy caused by mitochondrial membrane homeostasis defect, new insights from skeletal and heart muscle analyses. *Mitochondrion* 2016;27:32–8.
- Dubuisson JB, Chapron C. Laparoscopic iliac colpouterine suspension for the treatment of genital prolapse using two meshes: a new operative laparoscopic approach. *J Gynecol Surg* 1998;14:153–9.
- Catanzarite T, Tan-Kim J, Nguyen JN, et al. A novel, structured fellow training pathway for robotic-assisted sacrocolpopexy. *Perm J* 2021;25:20.224.
- Dubuisson JB, Chapron C, Fauconnier A. Laparoscopic lateral colpouterine suspension for treatment of genital prolapse using two meshes. *J Am Assoc Gyn Lap* 1999;6:S12–3.
- Dällenbach P. Laparoscopic lateral suspension (LLS) for the treatment of apical prolapse: a new gold standard *Front Surg* 2022;9:898392.
- Chatziioannidou K, Veit-Rubin N, Dällenbach P. Laparoscopic lateral suspension for anterior and apical prolapse: a prospective cohort with standardized technique. *Int Urogynecol J* 2022;33:319–25.
- Dubuisson J, Eperon I, Dällenbach P, et al. Laparoscopic repair of vaginal vault prolapse by lateral suspension with mesh. *Arch Gynecol Obstet* 2013;287:307–12.
- Mereu L, Dalpra F, Terreno E, et al. Mini-Laparoscopic repair of apical pelvic organ prolapse (POP) by lateral suspension with mesh. *Facts Views Vis Obgyn* 2018;10:139–45.
- Mereu L, Tateo S, D'Alterio MN, et al. Laparoscopic lateral suspension with mesh for apical and anterior pelvic organ prolapse: a prospective double center study. *Eur J Obstet Gynecol Reprod Biol* 2020;244:16–20.
- Dubuisson JB, Eperon I, Jacob S, et al. Laparoscopic repair of pelvic organ prolapse by lateral suspension with mesh: a continuous series of 218 patients. *Gynecol Obstet Fertil* 2011;39:127–31.
- Dällenbach P, Alec M, Boulvain M, et al. Outcomes of robotically assisted laparoscopic lateral suspension (RALLS) with mesh for anterior and apical prolapse. *J Robot Surg* 2022;16:287–94.
- Martinello R, Scutiero G, Stuto A, et al. Correction of pelvic organ prolapse by laparoscopic lateral suspension with mesh: a clinical series. *Eur J Obstet Gynecol Reprod Biol* 2019;240:351–6.
- Mowat A, Maher D, Baessler K, et al. Surgery for women with posterior compartment prolapse. *Cochrane Database Syst Rev* 2018;3:CD012975.
- Dällenbach P, De Oliveira SS, Marras S, et al. Incidence and risk factors for mesh erosion after laparoscopic repair of pelvic organ prolapse by lateral suspension with mesh. *Int Urogynecol J* 2016;27:1347–55.
- Mahrn MA, Herath RP, Sayed AT, et al. Laparoscopic management of genital prolapse. *Arch Gynecol Obstet* 2011;283:1015–20.
- Neymeyer J, Moldovan DE, Miller K, et al. Female urology: review of the development in the past 5 decades. *Aktuelle Urol* 2019;50:39–55.
- Clairhout F, Roovers JP, Lewi P, et al. Implementation of laparoscopic sacrocolpopexy—a single centre's experience. *Int Urogynecol J Pelvic Floor Dysfunct* 2009;20:1119–25.
- Malanowska-Jarema E, Osnytska Y, Starczewski A, et al. A comparative study in learning curves of laparoscopic lateral suspension vs. laparoscopic sacrocolpopexy: preliminary results. *Front Surg* 2023;10:1274178.
- Nygaard I, Brubaker L, Zyczynski HM, et al. Long-term outcomes following abdominal sacrocolpopexy for pelvic organ prolapse. *JAMA* 2013;309:2016–24.
- Lee RK, Mottrie A, Payne CK, et al. A review of the current status of laparoscopic and robot-assisted sacrocolpopexy for pelvic organ prolapse. *Eur Urol* 2014;65:1128–37.
- Sarlos D, Brandner S, Kots L, et al. Laparoscopic sacrocolpopexy for uterine and post-hysterectomy prolapse: anatomical results, quality of life and perioperative outcome—a prospective study with 101 cases. *Int Urogynecol J Pelvic Floor Dysfunct* 2008;19:1415–22.
- Campos S, Billone V, Durão M, et al. Complications of laparoscopic sacrocolpopexy: as harmless as they seem? *Acta Obstétrica e Ginecológica Portuguesa* 2016;10:21–31.
- Vandendriessche D, Sussfeld J, Giraudet G, et al. Complications and reoperations after laparoscopic sacrocolpopexy with a mean follow-up of 4 years. *Int Urogynecol J* 2017;28:231–9.
- Iserlik BS, Aksoy O, Erol O, et al. Comparison of laparoscopic lateral suspension and laparoscopic sacrocolpopexy with concurrent total laparoscopic hysterectomy for the treatment of pelvic organ prolapse: a randomized controlled clinical trial. *Int Urogynecol J* 2023;34:231–8.
- Raju R, Linder BJ. Evaluation and management of pelvic organ prolapse. *Mayo Clin Proc* 2021;96:3122–9.
- Zhang W, Cheon WC, Zhang L, et al. Comparison of the effectiveness of sacrosplenic ligament fixation and sacrocolpopexy: a meta-analysis. *Int Urogynecol J* 2022;33:3–13.
- Vermeulen CKM, Schuurman B, Coolen A-LWM, et al. The effectiveness and safety of laparoscopic uterosacral ligament suspension: a systematic review and meta-analysis. *BJOG* 2023;130:1568–78.
- Kahn B, Varner RE, Murphy M, et al. Transvaginal mesh compared with native tissue repair for pelvic organ prolapse. *Obstet Gynecol* 2022;139:975–85.
- Gong R, Xi Y, Jin X, et al. Effects of the decrease of B-catenin expression on human vaginal fibroblasts of women with pelvic organ prolapse. *J Obstet Gynaecol Res* 2021;47:4014–22.
- Niu K, Chen X, Lu Y. Col3A1 Rs1800255 polymorphism is associated with pelvic organ prolapse susceptibility in Caucasian individuals: evidence from a meta-analysis. *PLoS One* 2021;16:e0250943.
- Yassa M, Tug N. Uterus-preserving laparoscopic lateral suspension with mesh operation in pelvic organ prolapse: initial experience in a

- single tertiary center with a median 24-month follow-up. *Geburtshilfe Frauenheilkd* 2019;79:983–92.
- 39 Meriwether KV, Antosh DD, Olivera CK, *et al.* Uterine preservation vs hysterectomy in pelvic organ prolapse surgery: a systematic review with meta-analysis and clinical practice guidelines. *Am J Obstet Gynecol* 2018;219:129–46.
  - 40 Robinson D, Thiagamoorthy G, Cardozo L. Post-hysterectomy vaginal vault prolapse. *Maturitas* 2018;107:39–43.
  - 41 Gutman R, Maher C. Uterine-preserving POP surgery. *Int Urogynecol J* 2013;24:1803–13.
  - 42 Frick AC, Barber MD, Paraiso MFR, *et al.* Attitudes toward hysterectomy in women undergoing evaluation for uterovaginal prolapse. *Female Pelvic Med Reconstr Surg* 2013;19:103–9.
  - 43 Veit-Rubin N, Dubuisson J-B, Gayet-Ageron A, *et al.* Patient satisfaction after Laparoscopic lateral suspension with mesh for pelvic organ prolapse: outcome report of a continuous series of 417 patients. *Int Urogynecol J* 2017;28:1685–93.
  - 44 Pulatoğlu Ç, Yassa M, Turan G, *et al.* Vaginal axis on MRI after laparoscopic lateral mesh suspension surgery: a controlled study. *Int Urogynecol J* 2021;32:851–8.
  - 45 Campagna G, Vacca L, Panico G, *et al.* Laparoscopic lateral suspension for pelvic organ prolapse: a systematic literature review. *Eur J Obstet Gynecol Reprod Biol* 2021;264:318–29.
  - 46 Dubuisson J-B, Yaron M, Wenger J-M, *et al.* Treatment of genital prolapse by laparoscopic lateral suspension using mesh: a series of 73 patients. *J Minim Invasive Gynecol* 2008;15:49–55.
  - 47 Rane A, Lim YN, Withey G, *et al.* Magnetic resonance imaging findings following three different vaginal vault prolapse repair procedures: a randomised study. *Aust NZ J Obst Gynaeco* 2004;44:135–9.
  - 48 Funt MI, Thompson JD, Birch H. Normal vaginal axis. *South Med J* 1978;71:1534–5.
  - 49 Sze EH, Meranus J, Kohli N, *et al.* Vaginal configuration on MRI after abdominal sacrocolpopexy and sacrospinous ligament suspension. *Int Urogynecol J Pelvic Floor Dysfunct* 2001;12:375–9.