

Multimodal imaging and management of multiple retained corneal bee stingers

Sreeram Jayaraj, Ramanuj Samanta , Ajai Agrawal, Sandhya Shrestha

Ophthalmology, All India
Institute of Medical Sciences
– Rishikesh, Dehradun,
Uttarakhand, India

Correspondence to
Dr Ramanuj Samanta;
ramanuj.samanta@gmail.com

Accepted 8 June 2023

DESCRIPTION

A man in late 20s, presented to our ophthalmology outpatient department with complaints of right eye (RE) diminution of vision, pain, watering and mild periocular swelling following an incidence of bee sting 10 days ago. He was advised some topical medications from a local hospital. Family members also tried to remove the stingers with a piece of cloth. Without any remission, he sought a second opinion at our institute. Examination revealed best-corrected visual acuity of 20/30 and intraocular pressure (IOP) of 14 mm Hg in the RE. Slit-lamp evaluation revealed mild circumcorneal congestion, focal corneal oedema with overlying minimal punctate epithelial keratopathy, three intracorneal stingers, mutton-fat keratic precipitates and 3+ cells in the anterior chamber (AC) (**figure 1A**). Anterior segment optical coherence tomography (AS-OCT) further confirmed the exact location of stingers (**figure 1B**). The RE posterior segment and left eye examination were unremarkable. The patient was started on topical prednisolone acetate 1%, moxifloxacin 0.5%, carboxymethyl cellulose 0.5% and homatropine 2%. A diagnosis of multiple retained corneal bee stingers with secondary intraocular inflammation was made and the need for the removal of stingers was explained. Under topical proparacaine hydrochloride 0.5%, a clear corneal incision was made at 10°o clock with a 15-degree knife (**figure 2A**). With the help of a 23-gauge end-grasping forceps, two stingers were grasped from the endothelial side and removed carefully after injecting a viscoelastic agent in the AC. The remaining intrastromal stinger was removed with a 31-gauge needle from the epithelial side (**figure 2B**). Four weeks postoperatively, visual acuity in the RE improved to 20/20 (partial) with normal IOP, and resolution of corneal oedema and AC inflammation were noted. Corneal endothelial cell density was within the normal range postoperatively.

Ocular bee sting injury can present as penetrating, immunologic, or toxic reaction, or any combination of these. Injury can present in the form of insult to the cornea, conjunctiva, AC, lens, vitreous cavity, extraocular muscles or even the optic nerve.¹ The reaction to a bee sting can be due to the stinger or venom within it. The active components of the venom include apamin, mast cell degranulating peptide, phospholipase-A2 related peptide and melittin.² Melittin and apamin can cause endothelial damage, cataract and zonular dehiscence. Phospholipase-A can degenerate the chromatophores of the iris epithelium manifesting as heterochromia.¹ Secondary bacterial infection is another

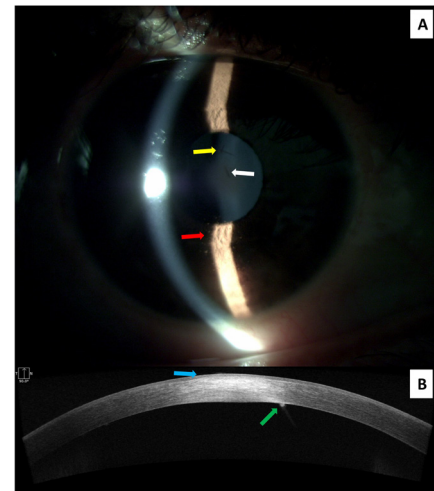


Figure 1 (A) Anterior segment imaging with slit-illumination showing two overlapping corneal stingers (yellow arrow) and a separate stinger (white arrow). Keratic precipitates (red arrow) were also noted in the Ait's triangle. (B) Anterior segment optical coherence tomography showing one of the stingers projecting into the anterior chamber (green arrow) and associated adjacent corneal oedema (blue arrow).

complication of a bee sting.³ Possibly our patient had a toxic reaction and/or superadded immunological reaction leading to secondary uveitis. There is partial disagreement regarding the management

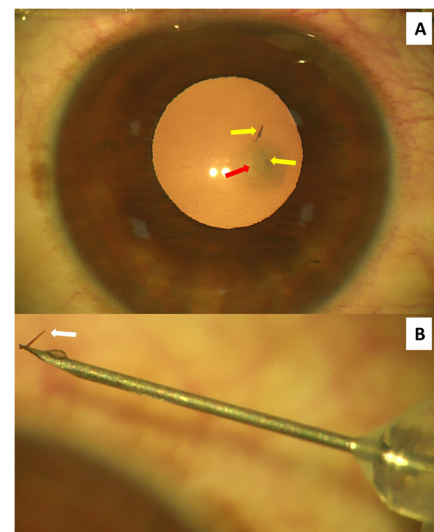
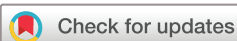

Figure 2 (A) Intraoperative image showing intracorneal stingers in the cornea (yellow arrows) and surrounding corneal oedema (red arrow). (B) Magnified view of one stinger removed using a 31-gauge needle (white arrow).



© BMJ Publishing Group Limited 2023. No commercial re-use. See rights and permissions. Published by BMJ.

To cite: Jayaraj S, Samanta R, Agrawal A, et al. *BMJ Case Rep* 2023;**16**:e255939. doi:10.1136/bcr-2023-255939

Images in...

of retained stingers.^{4 5} While some clinicians preferred early surgical removal of stingers,⁴ others suggested observation as stingers often become inert once the venom is exhausted.⁵ We removed the intracorneal stingers due to persistent symptoms and AC inflammation despite using topical medications. AS-OCT helped us to precisely locate the stingers and decide the approach of removal. The combination of a bidirectional approach from the epithelial and endothelial side, and the use of simple yet appropriate instruments minimised the risk of collateral tissue damage and consequent corneal scarring in the visual axis. Meticulous history, appropriate imaging and a targeted surgical approach with minimal manipulation are keys to management in such patients.

Learning points

- ▶ Retained corneal bee stingers can cause persistent intraocular inflammation.
- ▶ Anterior segment optical coherence tomography may help in precisely locating the stingers and deciding the approach to removal.
- ▶ Targeted surgical approach through epithelial and/or endothelial side may minimise corneal scarring.

Contributors SJ, RS, AA and SS were responsible for drafting of the text, sourcing and editing of clinical images, investigation results, drawing original diagrams and algorithms, and critical revision for important intellectual content. SJ contributed to conceptualisation, design, literature search, data acquisition and analysis, manuscript

preparation, and review. RS contributed to conceptualisation, design, definition of intellectual content, literature search, data analysis, manuscript preparation, editing and review. AA contributed to conceptualisation, design, manuscript editing and review. SS contributed to literature search, data acquisition and analysis, manuscript preparation, editing and review. SJ, RS, AA and SS gave final approval of the manuscript.

Funding The authors have not declared a specific grant for this research from any funding agency in the public, commercial or not-for-profit sectors.

Competing interests None declared.

Patient consent for publication Consent obtained directly from patient(s).

Provenance and peer review Not commissioned; externally peer reviewed.

Case reports provide a valuable learning resource for the scientific community and can indicate areas of interest for future research. They should not be used in isolation to guide treatment choices or public health policy.

ORCID iD

Ramanuj Samanta <http://orcid.org/0000-0002-9737-8346>

REFERENCES

- 1 Gudiseva H, Uddaraju M, Pradhan S, *et al*. Ocular manifestations of isolated corneal bee sting injury, management strategies, and clinical outcomes. *Indian J Ophthalmol* 2018;66:262–8.
- 2 Chen Y-N, Li K-C, Li Z, *et al*. Effects of bee venom peptidergic components on rat pain-related behaviors and inflammation. *Neuroscience* 2006;138:631–40.
- 3 DeBroff BM, Donahue SP, Caputo BJ, *et al*. Clinical characteristics of corneal foreign bodies and their associated culture results. *CLAO J* 1994;20:128–30.
- 4 Lin P-H, Wang N-K, Hwang Y-S, *et al*. Bee sting of the Cornea and conjunctiva: management and outcomes. *Cornea* 2011;30:392–4.
- 5 Razmjoo H, Abtahi M-A, Roomizadeh P, *et al*. Management of corneal bee sting. *Clin Ophthalmol* 2011;5:1697–700.

Copyright 2023 BMJ Publishing Group. All rights reserved. For permission to reuse any of this content visit <https://www.bmj.com/company/products-services/rights-and-licensing/permissions/> BMJ Case Report Fellows may re-use this article for personal use and teaching without any further permission.

Become a Fellow of BMJ Case Reports today and you can:

- ▶ Submit as many cases as you like
- ▶ Enjoy fast sympathetic peer review and rapid publication of accepted articles
- ▶ Access all the published articles
- ▶ Re-use any of the published material for personal use and teaching without further permission

Customer Service

If you have any further queries about your subscription, please contact our customer services team on +44 (0) 207111 1105 or via email at support@bmj.com.

Visit casereports.bmj.com for more articles like this and to become a Fellow