

Successful treatment of refractory crusted scabies

Toshinori Nishizawa ¹, Kazuhiro Ishikawa,² Mizuki Takamizawa,³ Hiroko Arioka¹

¹Department of General Internal Medicine, St Luke's International Hospital, Tokyo, Japan

²Division of Infectious Disease, St. Luke's International Hospital, Tokyo, Japan

³Department of Dermatology, St Luke's International Hospital, Tokyo, Japan

Correspondence to

Dr Toshinori Nishizawa; nishizawa.toshinori@gmail.com

Accepted 28 October 2022

DESCRIPTION

A man in his 70s, with mild cognitive impairment, presented with a 6-month history of a pruritic rash. He had been diagnosed with hyperkeratotic eczema and treated with hydrocortisone butyrate 0.1% (moderate potency) cream 3 months previously. Physical examination revealed dry crusts on his neck, trunk, arms, legs, palms and soles (*figure 1A*). Microscopy of scrapings of palmar papules revealed scabies mites and eggs (*figure 1B*). Laboratory testing revealed marked eosinophilia (3645 cells/ μ L; normal: <500 cells/ μ L). The patient was diagnosed with crusted scabies. He was hospitalised and treated with oral ivermectin 200 μ g/kg on days 1 and 8, crotamiton 10% cream and phenothrin 5% lotion. His eosinophil count normalised after 1 week; however, it increased again 2 weeks later. Microscopy of scrapings from crusted sole papules revealed mites and eggs. Ivermectin was repeated six times. The rash subsided 4 weeks after treatment initiation (*figure 1C*). The patient's family members were treated with oral ivermectin and crotamiton 10% cream; all bedsheets and clothes were cleaned, and he was discharged home.

Crusted scabies is a severe form of scabies and is highly contagious. In classic scabies, patients have approximately 10–15 mites, whereas patients with crusted scabies can have several thousands.¹ The risk of crusted scabies is high in nursing homes and hospitals, and among socially disadvantaged populations and immunocompromised individuals.² The diagnosis might have been missed by the first physician because the patient did not describe his symptoms clearly and an inadequate diagnostic evaluation. Physicians

Learning points

- Cases of crusted scabies may require more than two doses of ivermectin, administered 1 week apart.
- Most recurrences are caused by reinfestation from untreated contacts; therefore, contacts must be treated simultaneously.
- Dermoscopy and skin scrapings are important for determining whether itching is due to residual scabies or an allergic reaction.

should be knowledgeable about the diagnosis and treatment of scabies, to avoid misdiagnosis and inadequate treatment.

Skin scraping of burrows or erythematous papules should be performed. Mites are easily found in patients with crusted scabies, but negative skin scraping results do not rule out classic scabies because the number of mites may be low. Dermoscopy is helpful for visualising mites and burrows.^{3,4} Mites can be identified in grey delta structures at the edge of burrows are collected with a small blade and observed under a microscope.

Postscabetic itch, due to the immune response to mite antigens, may persist for several months.⁵ Dermoscopy and scrapings are important for determining whether the itching is due to residual scabies or an allergic reaction. Postscabetic itch can be treated with oral antihistamines and topical corticosteroids. Persistent infestation may be due to incorrect application and poor penetration of topical treatment through crusted skin, reinfestation or drug-resistant mites.⁶ Most recurrences are caused by reinfestation from untreated contacts,⁷ so family members and close contacts should be treated, regardless of whether they are symptomatic. Ivermectin resistance has been reported in individuals with intensive ivermectin exposure⁸ but is rare in Japan. Oral ivermectin 200 μ g/kg on days 1 and 8 is the first-line treatment for crusted scabies. Ivermectin is not ovicidal; thus, two doses are required to kill hatchlings before they breed. Crusted scabies is refractory to initial treatment because of the large number of mites and heavy skin crusting.⁹ Therefore, repeated ivermectin administration may be necessary if ova are still present after two doses, as in this case.

Acknowledgements The authors wish to thank Satoru Arai, Department of Dermatology, St Luke's International Hospital, Tokyo, Japan, for his professional support. We also wish to thank Iroha Yamamoto, Junior Resident, St Luke's International Hospital, Tokyo,

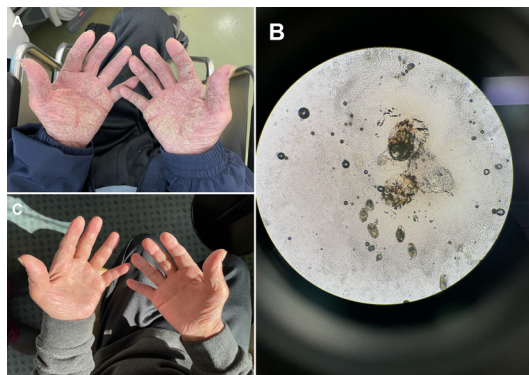
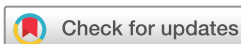

Figure 1 Findings of crusted scabies. (A) Dry crusts on the patient's palms on presentation. (B) Microscopy of skin scrapings of palmar papules showing scabies mites and eggs. (C) The patient's palms 4 weeks after starting treatment showing clearing of the rash.



© BMJ Publishing Group Limited 2022. No commercial re-use. See rights and permissions. Published by BMJ.

To cite: Nishizawa T, Ishikawa K, Takamizawa M, et al. *BMJ Case Rep* 2022;**15**:e251842. doi:10.1136/bcr-2022-251842

Japan, for her kind support. We would like to thank Editage (www.editage.com) for English language editing.

Contributors TN, KI, MT cared the patient and wrote the report. HA read and approved the final version of the report.

Funding The authors have not declared a specific grant for this research from any funding agency in the public, commercial or not-for-profit sectors.

Competing interests None declared.

Patient consent for publication Consent obtained directly from patient(s).

Provenance and peer review Not commissioned; externally peer reviewed.

Case reports provide a valuable learning resource for the scientific community and can indicate areas of interest for future research. They should not be used in isolation to guide treatment choices or public health policy.

ORCID iD

Toshinori Nishizawa <http://orcid.org/0000-0003-2074-646X>

REFERENCES

- 1 Tjioe M, Vissers WHPM. Scabies outbreaks in nursing homes for the elderly: recognition, treatment options and control of reinfestation. *Drugs Aging* 2008;25:299–306.
- 2 Matsuura H, Senoo A, Saito M, *et al.* Norwegian scabies. *Cleve Clin J Med* 2019;86:163–4.
- 3 Prins C, Stucki L, French L, *et al.* Dermoscopy for the in vivo detection of *Sarcoptes scabiei*. *Dermatology* 2004;208:241–3.
- 4 Sunderkötter C, Wohlrab J, Hamm H. Scabies: epidemiology, diagnosis, and treatment. *Dtsch Arztebl Int* 2021;118:695–704.
- 5 Chiu LW, Berger TG, Chang AY. Management of common scabies and postscabetic itch in adults: lessons learned from a single-center retrospective cohort study. *Int J Womens Dermatol* 2021;7:716–20.
- 6 Anderson KL, Strowd LC. Epidemiology, diagnosis, and treatment of scabies in a dermatology office. *J Am Board Fam Med* 2017;30:78–84.
- 7 Hicks MI, Elston DM. Scabies. *Dermatol Ther* 2009;22:279–92.
- 8 Currie BJ, Harumal P, McKinnon M, *et al.* First documentation of in vivo and in vitro ivermectin resistance in *Sarcoptes scabiei*. *Clin Infect Dis* 2004;39:e8–12.
- 9 Bassi A, Arunachalam M, Galeone M, *et al.* Norwegian scabies. *QJM* 2014;107:225.

Copyright 2022 BMJ Publishing Group. All rights reserved. For permission to reuse any of this content visit <https://www.bmj.com/company/products-services/rights-and-licensing/permissions/>
BMJ Case Report Fellows may re-use this article for personal use and teaching without any further permission.

Become a Fellow of BMJ Case Reports today and you can:

- ▶ Submit as many cases as you like
- ▶ Enjoy fast sympathetic peer review and rapid publication of accepted articles
- ▶ Access all the published articles
- ▶ Re-use any of the published material for personal use and teaching without further permission

Customer Service

If you have any further queries about your subscription, please contact our customer services team on +44 (0) 207111 1105 or via email at support@bmj.com.

Visit casereports.bmj.com for more articles like this and to become a Fellow