

Adenovirus type 5 community-acquired pneumonia in an immunocompetent patient

Katsunori Masaki,^{1,2} Takanori Asakura,¹ Kaori Sakurai,^{1,2} Kiyofumi Ohkusu³

¹Division of Pulmonary Medicine, Department of Medicine, Keio University School of Medicine, Tokyo, Japan

²Department of Internal Medicine, Saiseikai Utsunomiya Hospital, Utsunomiya, Tochigi, Japan

³Department of Microbiology, Tokyo Medical University, Tokyo, Japan

Correspondence to
Dr Katsunori Masaki,
masaki@keiomed.com

Accepted 26 March 2019

DESCRIPTION

A previously healthy 55-year-old Japanese woman was admitted to our hospital with a 5-day history of cough, dyspnoea and high fever. She had two budgerigar parrots, a sparrow and a dog. She had been administered levofloxacin (500 mg/day) 2 days before admission. She had a grandson who had a cold 6 days before her admission. Her vital signs included a body temperature of 37.8°C, pulse rate of 72 beats/min, respiratory rate of 20 breaths/min, blood pressure of 120/74 mm Hg and percutaneous oxygen saturation of 92% despite administration of 6 L/min oxygen via a reservoir mask. Chest examination revealed bilateral wheezing and rhonchi but no crackles. Laboratory tests showed an elevated C-reactive protein (3.87 mg/dL; normal range <0.35 mg/dL) with a normal white cell count ($4.76 \times 10^9/L$). Chest CT demonstrated bilateral ground-glass attenuation with peribronchial thickening (figure 1). Sputum Gram-stain and culture were negative for any pathogens. Legionella and pneumococcal urinary antigen tests, a rapid influenza diagnostic test using a nasopharyngeal swab and a serum anti-HIV antibody test were also negative. Ceftriaxone (2000 mg/day) and minocycline (200 mg/day) were administered for typical

and atypical pathogens coverage, respectively. A multiplex, real-time reverse transcriptase PCR (RT-PCR) assay of her sputum was negative for major atypical pathogens known to cause community-acquired pneumonia (CAP). These atypical pathogens included *Chlamydophila* spp, *Mycoplasma pneumoniae*, *Legionella pneumophila* and *Coxiella burnetii*. However, the 1004 bp fragment of the hexon gene was amplified by PCR,¹ and the DNA sequence shared homology with adenovirus type 5, searched by BLAST. This was confirmed using a serum neutralisation test, which was also positive for adenovirus type 5. Therefore, the patient was diagnosed with adenovirus type 5 CAP. Subsequently, we discontinued all antimicrobial treatments and transitioned to careful observation as the patient gradually recovered after 1 week of supportive care.

Viral pathogens such as influenza virus, adenovirus and rhinovirus are common causes of atypical CAP.² Although the risk of adenovirus infections of the lower respiratory tract is the greatest in children,³ adenovirus is a common pathogen causing acute respiratory infections in older adults as well.⁴ We, therefore, postulate that our patient may have been infected from contact with her sick grandson because adenovirus type 5 is mainly associated with respiratory tract infections in children.⁵ The severity and epidemiology of human adenovirus infections are influenced by

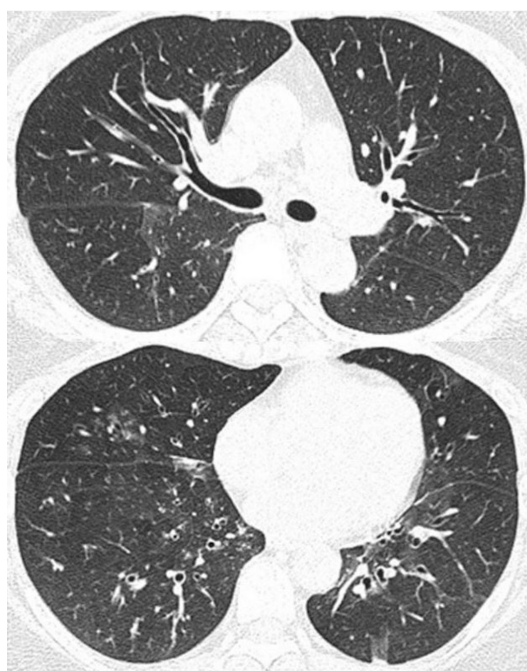


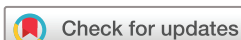Figure 1 Chest CT on admission demonstrated bilateral ground-glass attenuation and small nodular shadows with peribronchial thickening.

Patient's perspective

I thought that my difficulty breathing was caused by bronchitis or pneumonia and my symptoms were very similar to those experienced by my grandson. My doctors suspected that the pathogens causing my pneumonia came from our family's pet birds. Eventually, my hypothesis might be true!

Learning points

- ▶ Physicians should consider viruses as causative pathogens in patients with atypical community-acquired pneumonia.
- ▶ When a physician suspects atypical pneumonia based on patients' reported history or chest imaging, molecular techniques such as real-time reverse transcriptase PCR are useful for diagnosis of atypical pathogens such as adenovirus.



© BMJ Publishing Group Limited 2019. No commercial re-use. See rights and permissions. Published by BMJ.

To cite: Masaki K, Asakura T, Sakurai K, et al. *BMJ Case Rep* 2019;**12**:e228914. doi:10.1136/bcr-2018-228914

Images in...

adenovirus species and type. In children, the most frequent types are human adenovirus types 1, 2 and 5, and the CAP that these cause have better prognosis compared with the possibly fatal CAP caused by the highly virulent types 4, 7 and 55.⁵ Recently, several rapid molecular tests for viral pathogen detection have become available, which may aid in timely diagnosis and treatment.⁶ Early administration of cidofovir could be an important treatment strategy in cases of severe CAP caused by adenovirus; however, in our case, the patient's symptoms improved with supportive care alone.

Acknowledgements We are deeply grateful to Ichiro Nakachi, Tomoki Matsuo, Daisuke Arai, Hidenori Takanashi, Atsushi Chiyotani and Shigehiro Hagiwara for their assistance.

Contributors KM, TA and KS wrote the article. KO examined RT-PCR assay.

Funding The authors have not declared a specific grant for this research from any funding agency in the public, commercial or not-for-profit sectors.

Competing interests None declared.

Patient consent for publication Not required.

Provenance and peer review Not commissioned; externally peer reviewed.

REFERENCES

- 1 Ishiko H, Shimada Y, Konno T, *et al.* Novel human adenovirus causing nosocomial epidemic keratoconjunctivitis. *J Clin Microbiol* 2008;46:2002–8.
- 2 Jain S, Self WH, Wunderink RG, *et al.* Community-acquired pneumonia requiring hospitalization among U.S. Adults. *N Engl J Med* 2015;373:415–27.
- 3 Chau SK, Lee SL, Peiris MJ, *et al.* Adenovirus respiratory infection in hospitalized children in Hong Kong: serotype-clinical syndrome association and risk factors for lower respiratory tract infection. *Eur J Pediatr* 2014;173:291–301.
- 4 Shi T, Arnott A, Semogas I, *et al.* The etiological role of common respiratory viruses in acute respiratory infections in older adults: a systematic review and meta-analysis. *J Infect Dis* 2019;jiy662.
- 5 Scott MK, Chommanard C, Lu X, *et al.* Human adenovirus associated with severe respiratory infection, Oregon, USA, 2013–2014. *Emerg Infect Dis* 2016;22:1044–51.
- 6 Vos LM, Bruning AHL, Reitsma JB, *et al.* Rapid molecular tests for influenza, respiratory syncytial virus, and other respiratory viruses: a systematic review of diagnostic accuracy and clinical impact studies. *Clin Infect Dis* 2019.

Copyright 2019 BMJ Publishing Group. All rights reserved. For permission to reuse any of this content visit <https://www.bmj.com/company/products-services/rights-and-licensing/permissions/>
BMJ Case Report Fellows may re-use this article for personal use and teaching without any further permission.

Become a Fellow of BMJ Case Reports today and you can:

- ▶ Submit as many cases as you like
- ▶ Enjoy fast sympathetic peer review and rapid publication of accepted articles
- ▶ Access all the published articles
- ▶ Re-use any of the published material for personal use and teaching without further permission

For information on Institutional Fellowships contact consortiasales@bmjgroup.com

Visit casereports.bmj.com for more articles like this and to become a Fellow