

PostScript

LETTERS

Efficacy and strategy of pneumatic dilatation in achalasia

We read with interest the article by Eckardt *et al* regarding the long term results of pneumatic dilatation in achalasia (*Gut* 2004;53:629-33). Fifty four patients were followed up for a median of 14 years after a single pneumatic dilatation using the Browne-McHardy dilator. Five and 10 year remission rates were 40% and 36%, respectively, and repeated dilatations only mildly improved the clinical response. Most of the relapses occurred within one year of dilatation. Patients with post-dilatation lower oesophageal sphincter pressures of <10 mm Hg had a significantly better outcome. The authors suggest that failure to respond to the first dilatation should lead to consideration of alternative therapy.

We disagree with this conclusion and we would like to bring to your attention a recent prospective study on the long term effects of pneumatic dilatation in 11 patients with achalasia.¹ A different approach was chosen—that is, treatment consisted of one or more pneumatic dilatations under conscious sedation in order to achieve stable clinical remission, defined as persisting one year after dilatation. To this end, closer follow up was performed in the first year after dilatation (scheduled assessments at three and 12 months). Thereafter, clinical and manometric assessments were performed yearly for six years. The clinical score was according to Eckardt *et al*. Five patients needed one (30 mm diameter Rigiflex dilator) and six needed two (30 and 35 mm diameter) dilatations. No complications occurred. All patients remained in clinical remission and their lower oesophageal sphincter pressure decreased to <10 mm Hg and remained unchanged over time.

There are similarities in the results of the two studies: (1) the outcome of our 11 patients was comparable with that of the eight patients of Eckardt *et al* with a lower oesophageal sphincter pressure of <10 mm Hg who had a remission rate of 75% at six years; and (2) the observation that the six patients in our series who needed a second dilatation all relapsed within one year of the first dilatation agrees with the data by Eckardt *et al*, showing that most relapses occur in the first 12 months. However, our dilatations were more successful and, importantly, a second dilatation led to a sustained remission in all patients. We do not know the reasons for this difference but we believe it may be at least partly related to our use of the non-compliant Rigiflex dilator, which is currently considered the best choice,² although there are no adequately powered comparisons with the Browne-McHardy dilator in the literature.³ Similarly to our result, a recent paper has shown very good efficacy of a second dilatation with the Rigiflex dilator in patients who had relapsed.⁴ Another possible reason is the use of conscious sedation during the procedure which allowed us to complete all dilatations; Eckardt *et al*, who used topical anaesthesia only, had

to prematurely terminate 17% of the procedures.

In conclusion, our published experience and our current clinical practice, involving treatment and follow up of 10-15 new achalasia patients each year, suggest that performance of one or two dilatations until stable clinical remission is a valuable strategy, and that pneumatic dilatation under conscious sedation with the Rigiflex dilator is an effective long term treatment in most patients with achalasia.

R Penagini, P Cantù

Cattedra di Gastroenterologia, Dipartimento di Scienze Mediche, University of Milan, IRCCS Ospedale Maggiore, Milan, Italy

Correspondence to: Professor R Penagini, Cattedra di Gastroenterologia, Dipartimento di Scienze Mediche, University of Milan, IRCCS Ospedale Maggiore, Milan, Italy; roberto.penagini@unimi.it

Conflict of interest: None declared.

References

- 1 Penagini R, Cantù P, Mangano M, *et al*. Long-term effects of pneumatic dilatation on symptoms and lower oesophageal sphincter pressure in achalasia. *Scand J Gastroenterol* 2002;37:380-4.
- 2 Vaezi MF, Richter JE. Current therapies for achalasia: comparison and efficacy. *J Clin Gastroenterol* 1998;27:21-35.
- 3 Stark GA, Castell DO, Richter JE, *et al*. Prospective randomized comparison of Brown-McHardy and Microvasive balloon dilators in treatment of achalasia. *Am J Gastroenterol* 1990;85:1322-6.
- 4 Mikaeli J, Bishehsari F, Montazeri G, *et al*. Pneumatic balloon dilatation in achalasia: a prospective comparison of safety and efficacy with different balloon diameters. *Aliment Pharmacol Ther* 2004;20:431-6.

Authors' reply

Penagini and Cantù should be congratulated for the remarkable results they were able to obtain in 11 patients with achalasia treated by pneumatic dilatation. To my knowledge, not a single study has so far produced similar results. A review of prospective studies in patients undergoing pneumatic dilatation with the Rigiflex dilator¹ indicated that approximately 80% will have a good or excellent short term response. However, if such patients are observed for prolonged periods, the results obtained do not differ significantly from those observed following treatment with the older balloons. In a recent study, in which 56 patients were treated with the Rigiflex dilator and observed for more than 10 years, the long term success rate was 55%.² Thus it is my impression that differences in treatment results are not so much related to differences in technique and operator experience but rather to the number of patients investigated, duration of follow up, and finally the quality of the study design. It is hoped that carefully designed randomised studies, which are now in progress, will tell us whether we should continue to offer pneumatic dilatation to the great majority of patients with achalasia or whether we should advise them to undergo surgery instead.

V F Eckardt

Correspondence to: Dr V F Eckardt, Deutsche Klinik für Diagnostik, Aukammallee 33 Wiesbaden 65191, Germany; eckardt.gastro@dkd-wiesbaden.de

Conflict of interest: None declared.

References

- 1 Kadakia SC, Wong RKH. Pneumatic balloon dilatation for esophageal achalasia. *Gastrointest Endosc Clin N Am* 2001;11:325-45.
- 2 West RL, Hirsch DP, Bartelsman JFW, *et al*. Long term results of pneumatic dilation in achalasia followed for more than 5 years. *Am J Gastroenterol* 2002;97:1346-51.

Probiotics in IBD: mucosal and systemic routes of administration may promote similar effects

We read with considerable interest the paper by Sheil *et al* (*Gut* 2004;53:694-700) who reported the successful application of the subcutaneous route for probiotic attenuation of colitis.

We agree with the corresponding commentary of Ghosh *et al* (*Gut* 2004;53:620-2) regarding the need to study mechanisms underlying probiotic interactions. Recently, we further standardised a method to compare the anti-inflammatory potential of orally administered lactic acid bacteria (LAB) in a murine model of acute 2,4,6, trinitrobenzene sulphonic acid (TNBS) induced colitis.¹ This model allowed us to discriminate "protective" strains, showing between 30% and 70% reduction of inflammatory score, from strains which did not significantly attenuate experimental colitis. We could select highly performing strains of *Lactobacillus salivarius* and *Lactobacillus rhamnosus* that consistently lowered colitis. In comparison, a strain of *Lactobacillus acidophilus*, *Lactococcus lactis*, and *Streptococcus gordonii* never showed any improvement. For all five strains, we investigated the protective effect of a single intraperitoneal injection of 5×10^7 live microorganisms, 24 hours prior to induction of colitis. Surprisingly, protection by the LAB strains via this systemic route closely matched the efficiency of the oral route (fig 1).

When evaluating both routes simultaneously, the anti-inflammatory effect was of comparable magnitude. Moreover, the prophylactic impact of the intraperitoneal *Lactobacillus salivarius* strain was established up to two hours before TNBS administration. It is noteworthy that two delayed injections could lead to protection but caused marked weight loss (23% ($p < 0.05$) v 15% and 11%, respectively, for control and oral route groups) with alleged fever.

Our findings clearly confirm those of Sheil *et al* (*Gut* 2004;53:694-700) showing strain specific in vivo probiotic effects distant from the target tissue, suggesting a relationship between the type of LAB (or LAB components) and peritoneal immunocompetent cells. Pereyra and colleagues² reported transient dose dependant induction of a/b-like interferon in serum of intraperitoneal injected *Lactobacillus bulgaricus* while *Streptococcus thermophilus* did not. Recent

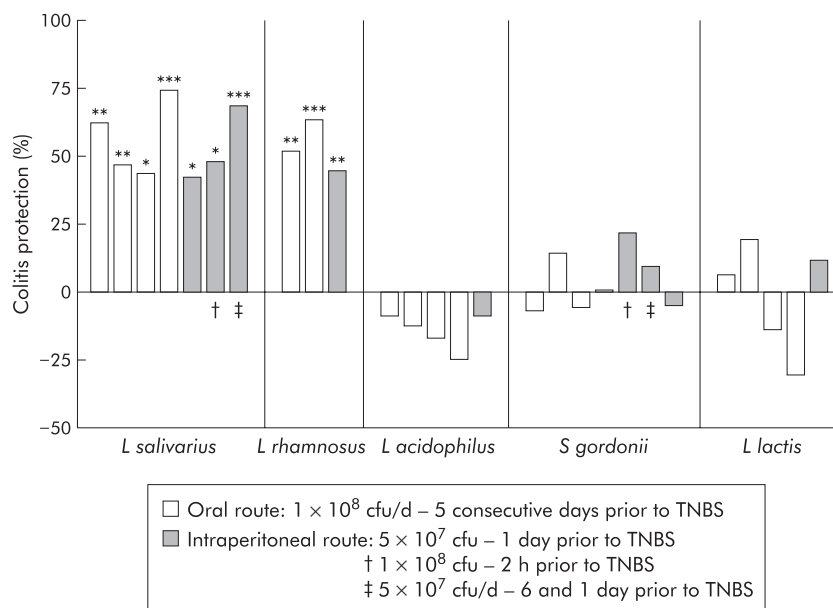


Figure 1 Lactic acid bacteria (LAB) protection on macroscopic damages induced by 2,4,6, trinitrobenzene sulphonic acid (TNBS): the impact of the oral or intraperitoneal route of LAB administration on reduction of TNBS induced colitis in mice. Results are expressed as per cent reduction of mean macroscopic inflammation⁷ of mice treated with LAB, in relation to the mean score of non-treated mice. Colitis index was assessed 48 hours after TNBS administration. Each bar represents an independent experiment of control (n = 10) and LAB treated mice (n = 10). *p < 0.05, **p < 0.01, ***p < 0.001, significantly different from the corresponding TNBS control group (Mann-Whitney U test). CFU, colony forming unit; d; day.

observations showed that heat treatment of an orally administered probiotic cocktail abolished the colitis protection in a DSS model, while irradiation improved it.³ Consequently, cellular integrity appears to be necessary to explain at least some part of the effect, although cell walls and peptidoglycans of killed bacteria cannot be considered as passive. Possibly both “good” and “bad” signals are given out by LAB, and the immune system is integrating all of them. Those “mixed” signals will no doubt be specific for each strain as well as dose dependent. Differences in physicochemical status could explain the mortality seen by Sheil *et al.*, especially when using heat treated bacteria. Pereyra and colleagues² established that the maximal non-lethal quantity of injected live LAB was 5×10^7 but it can be hypothesised that toxicity may also differ with strain and viability status. Both pro- and anti-inflammatory components of probiotics have been reported to interact with systemic immune cells, showing effects comparable with other well known anti-inflammatory or therapeutic molecules.⁴ It is therefore most probable that systemic delivery of specific live or killed probiotics may influence the delicate balance between Th1 and Th2 immunity, and subsequently have an impact on local immunity. Clear relationships, however, are not obvious. A first example is the case of subcutaneous CpG DNA that promoted a Th1 response and was able to alleviate some symptoms of DSS colitis but caused inflammation when administered after the onset of colitis.⁵ Secondly, different experimental models of colitis support a potential benefit of probiotic DNA,⁶ although it seems very premature to restrict this probiotic effect to nucleic acids only.⁶

As emphasised by Gosh and colleagues (*Gut* 2004;**53**:620–2), approaches involving

fractional studies are essential tools to complete the knowledge obtained from *in vitro* and *ex vivo* models and assist in understanding the interactions between LAB and the immune system. These studies may reveal common mechanisms active in inflammation, tolerance, and allergy models. Even if this study confirms the importance of the systemic route for certain probiotic activity, we cannot neglect the possible influence of local and innate immunity, the general status of the gut flora, and the role of epithelial cells in the cross talk between both.

Acknowledgements

We are indebted to Danisco France for financial support.

B Foligné, C Grangette, B Pot

Bactériologie des Ecosystèmes, Institut Pasteur de Lille, Lille, France

Correspondence to: Dr B Pot, Institut Pasteur de Lille, 1 Rue du Prof Calmette, BP 245, F-59019 Lille, France; bruno.pot@ibl.fr

Conflict of interest: None declared.

References

- 1 Foligné B, Nutten S, Steidler L, *et al.* Potentialities of the TNBS-induced colitis model to evaluate the anti-inflammatory properties of lactic acid bacteria. *Dig Dis* (in press).
- 2 Pereyra BS, Falcoff R, Falcoff E, *et al.* Interferon induction by *Lactobacillus bulgaricus* and *Streptococcus thermophilus* in mice. *Eur Cytokine Netw* 1991;**2**:299–303.
- 3 Rachmilewitz D, Katakura K, Karmeli F, *et al.* Toll-like receptor 9 signaling mediates the anti-inflammatory effects of probiotics in murine experimental colitis. *Gastroenterology* 2004;**126**:520–8.
- 4 Mercenier A, Pavan S, Pot B. Probiotics as biotherapeutic agents: present knowledge and future prospects. *Curr Pharm Des* 2003;**9**:175–9.

- 5 Obermeier F, Dunger N, Strauch UG, *et al.* Contrasting activity of cytosin-guanosin dinucleotide oligonucleotides in mice with experimental colitis. *Clin Exp Immunol* 2003;**134**:217–24.
- 6 Reid G, Guarner F, Gibson G, *et al.* Discussion on toll-like receptor 9 signaling mediates the anti-inflammatory effects of probiotics in murine experimental colitis. *Gastroenterology* 2004;**127**:366–7.
- 7 Wallace JL, MacNaughton WK, Morris GP, *et al.* Inhibition of leukotriene synthesis markedly accelerates healing in a rat model of inflammatory bowel disease. *Gastroenterology* 1989;**96**:29–36.

Mutations in anionic trypsinogen gene are not associated with tropical calcific pancreatitis

Pancreatitis is considered to be an autodigestive disease due to premature activation of trypsinogen inside the pancreas. Its genetic basis has recently been established with the identification of causal mutations in cationic trypsinogen gene (*PRSS1*) in patients with hereditary¹ and non-hereditary pancreatitis.² Mutations in other genes such as *SPINK1* (encoding pancreatic secretory trypsin inhibitor)³ and cystic fibrosis transmembrane conductance regulator (*CFTR*)^{4,5} genes have also been associated with the disease. Tropical calcific pancreatitis is a type of idiopathic pancreatitis, reported particularly in the tropics. Recently, we and others demonstrated absence of *PRSS1* mutations but significant prevalence of the N34S mutation in the *SPINK1* gene in these patients.^{6–8} However, our study raised two important questions: firstly, the exact role of *SPINK1* mutations in disease causation as cationic trypsinogen is normal with an intact auto-lysis site; and secondly, the cause of the disease in the remaining patients negative for both *PRSS1* and *SPINK1* mutations.

Of the nine members of the human trypsinogen gene family, only *PRSS1*, *PRSS2*, and *PRSS3* are functional genes coding for cationic, anionic, and meso-trypsinogen isoforms, respectively. The anionic form accounts for about one third of the total trypsin in pancreatic juice. We investigated whether mutations in the anionic trypsinogen gene may contribute to the pathogenesis of tropical calcific pancreatitis. Of 20 mutations reported to date in the *PRSS1* gene, 17 are clustered in exons 2 and 3 only. The remaining three are in the promoter region but reported in isolated patients. Hence we initially screened exons 2 and 3 of the anionic trypsinogen gene in 68 well characterised Indian patients with tropical calcific pancreatitis.⁶ Subsequently, we also sequenced the promoter, complete coding region, and the flanking region in an attempt to look for any novel mutation.

Owing to the extremely high sequence homology between *PRSS1* and *PRSS2*, a nested polymerase chain reaction (PCR) was used to ensure specificity. The primers were selected from the published study of Chen and colleagues⁹ and all of the exons of *PRSS2* were PCR amplified, purified, and sequenced on both alleles using internal sequencing primers and the Big Dye terminator cycle sequencing approach. However, we did not find any of the reported or any novel mutations in the coding region or in the splice site junctions, except a synonymous polymorphism A90A (GCA>GCG) in exon 3 of the anionic trypsinogen gene. This variation was observed in both the heterozygous

and homozygous states with a mutant allele frequency of 0.58 (9 AA, 20 GG, and 39 AG) and was comparable with 0.61 in 50 controls (7 AA, 18 GG and 25 AG) analysed.

Our results thus exclude any association of mutations in the anionic trypsinogen gene in tropical calcific pancreatitis and suggest a role for other genetic or non-genetic factors in the pathogenesis of the disease. Screening of genes such as *CFTR* may explain the disease in the remaining patients. It also affirms the importance of the N34S mutation in *SPINK1* as the major genetic factor for this type of pancreatitis.

M M Idris*, S Bhaskar*

Centre for Cellular and Molecular Biology,
Hyderabad, India

D N Reddy

Asian Institute of Gastroenterology, Hyderabad, India

K R Mani

Centre for Cellular and Molecular Biology,
Hyderabad, India

G V Rao

Asian Institute of Gastroenterology, Hyderabad, India

L Singh, G R Chandak

Centre for Cellular and Molecular Biology,
Hyderabad, India

Correspondence to: Dr G R Chandak, Centre for
Cellular and Molecular Biology, Uppal Rd,
Hyderabad, AP 500 007, India;
chandakgrc@cmb.res.in

doi: 10.1136/gut.2004.055335

*M M Idris and S Bhaskar contributed equally to
this work.

Conflict of interest: None declared.

References

- Whitcomb DC, Gorry MV, Preston RA, *et al*. Hereditary pancreatitis caused by a mutation in the cationic trypsinogen gene. *Nat Genet* 1996;14:141–5.
- Gorry MC, Gabbazeideh D, Furey W, *et al*. Mutations in the cationic trypsinogen gene are associated with recurrent acute and chronic pancreatitis. *Gastroenterology* 1997;113:1063–8.
- Witt H, Luck W, Hennies HC, *et al*. Mutations in the gene encoding the serine protease inhibitor Kazal type I are associated with chronic pancreatitis. *Nat Genet* 2000;25:213–16.
- Shaner N, Schwarz M, Malone G, *et al*. Mutations in the cystic fibrosis gene in patients with chronic pancreatitis. *N Engl J Med* 1998;339:645–52.
- Cohn JA, Friedman KJ, Noone PG, *et al*. Relation between mutations of the cystic fibrosis gene and idiopathic pancreatitis. *N Engl J Med* 1998;339:653–8.
- Chandak GR, Idris MM, Reddy DN, *et al*. Mutations in the pancreatic secretory trypsin inhibitor gene (PSTI/SPINK1) rather than the cationic trypsinogen gene (PRSS1) are significantly associated with tropical calcific pancreatitis. *J Med Genet* 2002;39:347–51.
- Bhatia E, Chowdhuri G, Sikora SS, *et al*. Tropical calcific pancreatitis: strong association with SPINK1 trypsin inhibitor mutations. *Gastroenterology* 2002;123:1020–5.
- Schneider A, Suman A, Rossi L, *et al*. SPINK1/PSTI mutations are associated with tropical pancreatitis and type II diabetes mellitus in Bangladesh. *Gastroenterology* 2002;123:1026–30.
- Chen J, Audrezet M, Mercier B, *et al*. Exclusion of anionic trypsinogen and mesotrypsinogen involvement in hereditary pancreatitis without cationic trypsinogen gene mutations. *Scand J Gastroenterol* 1999;8:831–2.

Elevated plasma protein C levels correlate with the presence of fatty liver (NASH and NAFLD)

The clinical implications of non-alcoholic fatty liver disease (NAFLD) are derived mostly from its common occurrence in the general population and the potential of the condition to progress to fibrosis and cirrhosis.¹ Markers that help in making an early diagnosis and treatment are warranted. Protein C is a vitamin K dependent glycoprotein that functions as a circulating anti-coagulant through proteolytic cleavage and inactivation of the coagulation factors Va and VIIIa.² Whether or not protein C levels increase in patients with NAFLDs has not been assessed.

We measured protein C levels in 44 patients (28 men and 16 women; mean ages 45 (11) and 49 (12) years, respectively); 15 patients with fatty liver (FL), 15 with non-alcoholic steatohepatitis (NASH), and 14 with chronic viral hepatitis B+C (CH). All were diagnosed by histology and liver technetium scan or ultrasound. Ten healthy subjects were used as controls. Obesity, hyperlipidaemia, and diabetes were present in 60%, 73%, and 23% of cases, respectively; 64% of patients had elevated liver enzyme tests (alanine aminotransferase 45 (21) IU/l in FL and 43 (18) IU/l in NASH). Mean protein C levels were significantly increased in patients with NAFLD (n = 30) compared with those with chronic viral hepatitis (140 (36)% v 101 (24)%; p < 0.0009) and healthy individuals (140 (36)% v 120 (12); p < 0.04). No significant difference in protein C levels was noted between simple fatty liver and NASH. (149 (34)% and 130 (37)%, respectively; p = 0.07). A significant correlation was found between protein C and extent of fatty infiltration (r = 0.63; p < 0.001) (fig 1), insulin resistance index (r = 0.3; p < 0.01), and triglyceride levels (r = 0.45; p < 0.001). Protein C could discriminate correctly between NAFLDs and chronic viral hepatitis in 82% of cases. No significant association was found between protein C and aminotransferase levels.

In conclusion, protein C was elevated in patients with NAFLD. The underlying mechanism remains unknown. Agewall *et al* suggested an increase in hepatic synthesis of protein C due to increased hepatic insulin resistance.³ Increased levels have been

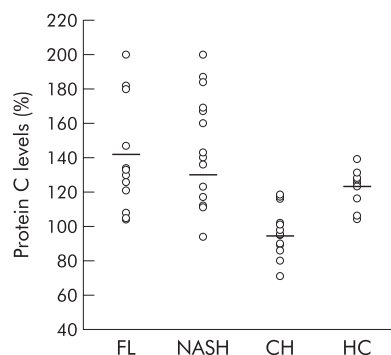


Figure 1 Protein C levels (normal 70–130%) in the study population (fatty liver (FL), non-alcoholic steatohepatitis (NASH), chronic viral hepatitis B+C (CH), and healthy controls (HC)). Horizontal bars indicate median levels.

reported in patients with diabetes, hypertriglyceridaemia, and nephrotic syndrome, with the use of anabolic steroids, oral contraceptives, and alcohol, and with increasing age.⁴ Diabetes and hypertriglyceridaemia are predisposing conditions to fatty liver⁵ and were present in 23% and 73% of cases, respectively. The remaining conditions were excluded by clinical and biochemical findings. Although more studies are needed, these preliminary findings suggest that elevated protein C levels together with elevated liver enzymes may be used as markers for NAFLD and may obviate the need for liver biopsy.

N Assy

Department of Internal Medicine A, and Liver Unit,
Sieff Government Hospital, Safed, Israel, and
Technion Institute, Faculty of Medicine, Haifa, Israel

S Schlesinger

Department of Internal Medicine A, Sieff Government
Hospital, Safed, Israel

O Hussein

Department of Internal Medicine A, Sieff Government
Hospital, Safed, Israel, and Technion Institute, Faculty
of Medicine, Haifa, Israel

Correspondence to: Dr N Assy, Liver Unit, Sieff
Government Hospital, Safed 13100, Israel;
assy.n@ziv.health.gov.il

doi: 10.1136/gut.2004.060251

Conflict of interest: None declared.

References

- Angulo P. Nonalcoholic fatty liver disease. *N Engl J Med* 2002;346:1221–31.
- Bajzar L. Thrombin activatable fibrinolysis inhibitor and an antifibrinolytic pathway. *Arterioscler Thromb Vasc Biol* 2000;20:2511–18.
- Agewall S, Bokemark L, Wiskstrand J, *et al*. Insulin sensitivity and haemostatic factors in clinically healthy 58-year old men. *Thromb Haemost* 2000;84:571–5.
- Bell H, Odegaard OR, Anderson T, *et al*. Protein C in patients with alcoholic cirrhosis and other liver diseases. *J Hepatol* 1992;14:163–7.
- Assy N, Kaita K, Mymin D, *et al*. Fatty infiltration of liver in hyperlipidemic patients. *Dig Dis Sci* 2000;45:1929–34.

Coexistent chronic idiopathic intestinal pseudo obstruction and inflammatory bowel disease

Chronic idiopathic intestinal pseudo obstruction (CIIP) is a severe condition presenting with abdominal pain and dysmotility. Inflammatory or degenerative changes of the autonomic nervous system or of the muscles of the bowel have been observed in CIIP.^{1,2} As patients with inflammatory bowel disease (IBD) may show clinical^{3,4} and histological⁵ signs of autonomic neuropathy and dysmotility,^{6,7} the aim of this study was to examine whether there is an association between CIIP and IBD.

Six patients at our hospital presenting with signs and symptoms of intestinal dysmotility were diagnosed with CIIP based on clinical features, antroduodenojunal manometry, and full thickness biopsies (table 1).^{8,9} Patient No 1 had an acute erosive colitis some years previously with bloody diarrhoea and an enhanced sedimentation rate, which was treated with steroids, and patient No 2 had relapsing proctitis treated with 5-aminosalicylic acid (5-ASA). Patient No 3 was

Table 1 Summary of the findings in our patients

Patient No: age (y)/ sex	Debut age/CIIP diagn age (y)	Main symptoms	Clinical diagnosis	Endoscopic pathology	Histopathology	Antroduodenal manometry
1 23/F	16/22	Pain, bloody diarrhoea	Crohn's disease, CIIP	Small and large bowel	Degenerative neuropathy. Suspected Crohn's disease	
2 26/F	15/25	Pain, vomiting	Proctitis, CIIP	Rectum	Degenerative neuropathy	Abnormal
3 35/F	Teenage/29	Constipation, dyspepsia	Crohn's disease, CIIP	Small and large bowel	Ganglionitis	
4 44/F	35/39	Constipation, pain	Suspected Crohn's disease, CIIP	Small bowel	Normal	Abnormal
5 55/M	39/41	GORD, later pain and diarrhoea	Suspected Crohn's disease, CIIP	Normal	Suspected Crohn's disease	Abnormal
6 67/M	61/64	Pain, weight loss	Crohn's disease, CIIP	Large bowel	Ganglionitis. Crohn's disease	

CIIP, Chronic idiopathic intestinal pseudoobstruction; GORD, gastro-oesophageal reflux disease.

totally and patient No 4 partially colectomised because of slow transit constipation. Patient No 6 was proctocolectomised due to refractory colitis. The patients were further investigated with magnetic resonance (MR) enterography¹⁰ and video capsule enteroscopy to establish whether there were any signs of IBD. If these examinations showed any pathology, push enteroscopy and ileocolonoscopy were also performed. All biopsies collected over the years were re-evaluated.

MR enterography did not reveal any pathological changes in any of the subjects. In three patients (Nos 1, 3, and 4), video capsule enteroscopy revealed Crohn-like ulcerations/erosions in the stomach and small intestine. Further examination of patient No 1 by push enteroscopy confirmed the erosions in the stomach and one third of the proximal small intestine. In patient No 3,

capsule enteroscopy showed aphthous ulcers typical of Crohn's disease throughout the distal jejunum and ileum (fig 1A). Ileocolonoscopy showed the same picture in the ileum and ileorectal anastomosis.

Histopathological examination of the full thickness biopsies from patient Nos 1 and 2 showed visceral degenerative neuropathy, combined with vacuolisation of the interstitial cells of Cajal (ICCs). In patient Nos 3 and 6, lymphocytic ganglioneuritis was found in both neural plexa of the resected colon and ileum (fig 1B), with signs of neurone degeneration, and 50% and 80% reduction of ICCs in the perimenteric ICC-plexus and deep muscular plexus of the circular muscle layer, respectively. Patient No 4 had a normal biopsy, and patient No 5 was not biopsied. Examination of mucosal biopsies from patient No 1 revealed focal active inflammation in the duodenum and caecum, and chronic inflammation in the rectum; patient No 5 had multifocal mild antral cryptitis, and both patients were diagnosed with suspected Crohn's disease. Colon biopsies from patient No 6 revealed epithelioid cell granulomas and multinucleated giant cells, as well as multifocal transmural lymphoid hyperplasia consistent with Crohn's disease.

In three patients (Nos 1, 3, and 4), dysmotility preceded the mucosal changes. In patient Nos 2 and 5, these two entities occurred simultaneously, while in patient No 6, dysmotility developed after proctocolectomy. Ganglionitis in patient No 3 could have been caused by Crohn's disease before other symptoms of the disease developed. Treatment with 5-ASA has reduced her abdominal pain. The normal histology of the sigmoidum in patient No 4 does not exclude the possibility of ganglionitis in other parts of the bowel due to the known patchy involvement of the gut in Crohn's disease.

The present observations indicate that apart from inflammation, even purely degenerative neuronal and ICCs changes seen in CIIP can occur in patients who also have IBD/ an IBD-like condition. At present, it is not known whether the observed abnormalities are part of IBD or independent of each other. This small patient sample prevents us from drawing any definite conclusion regarding this question. Further observations are needed to establish whether or not this connection is causal.

B Ohlsson

Department of Medicine, Malmö University Hospital, University of Lund, Sweden

F-T Fork

Department of Diagnostic Radiology, Malmö University Hospital, University of Lund, Sweden

B Veress

Department of Pathology, Malmö University Hospital, University of Lund, Sweden

E Toth

Department of Medicine, Malmö University Hospital, University of Lund, Sweden

Correspondence to: Dr B Ohlsson, Department of Medicine, Entrance 35, 205 02 Malmö, Sweden; bodil.ohlsson@kir.lu.se

doi: 10.1136/gut.2004.058826

Conflict of interest: None declared.

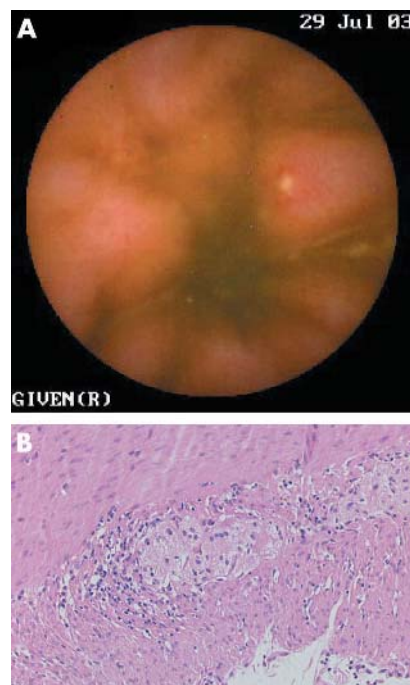


Figure 1 Patient No 3. (A) Capsule endoscopic view of the terminal ileum showing an aphthous ulceration in the ileum. (B) Moderate lymphocytic infiltrate around and within the myenteric ganglia (haematoxylin-eosin $\times 100$).

References

- Patel R, Christensen J. Chronic intestinal pseudo-obstruction: Diagnosis and treatment. *The gastroenterologist*, 1995;3:345–56.
- De Giorgio R, Sarnelli G, Corinaldesi R, et al. Advances in our understanding of the pathology of chronic intestinal pseudo-obstruction. *Gut* 2004;53:1549–52.
- Lindgren S, Lilja B, Rosén I, et al. Disturbed autonomic nerve function in patients with Crohn's disease. *Scand J Gastroenterol* 1991;26:523–8.
- Isgar B, Harman M, Kaye MD, et al. Symptoms of irritable bowel syndrome in ulcerative colitis in remission. *Gut* 1983;24:190–2.
- Dvorak AM, Osage JE, Monahan RA, et al. Crohn's disease: transmission electron microscopic studies. III. Target tissues. Proliferation of and injury to smooth muscle and the autonomic nervous system. *Hum Pathol* 1980;11:620–34.
- Manousos ON, Salem SN. Abnormal motility of the small intestine in ulcerative colitis. *Gastroenterology* 1965;104:249–57.
- Rao SSC, Read NW, Brown C, et al. Studies on the mechanism of bowel disturbance in ulcerative colitis. *Gastroenterology* 1987;93:934–40.
- Stanghellini V, Camilleri M, Malagelada J-R. Chronic idiopathic intestinal pseudo-obstruction: clinical and intestinal manometric findings. *Gut* 1987;28:5–12.
- Mann SD, Debinski HS, Kamm MA. Clinical characteristics of chronic idiopathic intestinal pseudo-obstruction in adults. *Gut* 1997;41:675–81.
- Gourtsoyannis N, Papanikolaou N, Grammatikakis J, et al. MR enteroclysis: technical considerations and clinical applications. *Eur Radiol* 2002;12:2651–8.

Cannabinoid hyperemesis: not just a problem in Adelaide Hills

We read the article by Allen and colleagues (*Gut* 2004;53:1566–70) with interest and would like to report a case of probable cannabinoid hyperemesis seen in a district general hospital in the UK.

A 21 year old chef was admitted to our hospital on seven occasions over a two year period (April 2001 to December 2002) with profuse vomiting. Apart from a history of migraine as a child, he was fit and well. He smoked cannabis. Physical examination was unremarkable. The observation that the patient wanted to take regular baths because he had found that bathing eased the sickness was documented in the nursing notes but its significance was not appreciated. Investigations during attacks disclosed neutrophilia but blood urea, electrolytes, liver biochemistry, and serum amylase were normal. Abdominal x ray was also normal. Upper gastrointestinal endoscopy showed grade I oesophagitis and gastritis. Gastric biopsies were histologically normal. An abdominal ultrasound scan and small bowel barium follow through examination were normal. Additional normal or negative investigations included: autoantibodies and immunoglobulins, C reactive protein, and urinary porphyrin screen. Computed tomography scan of the brain was also normal.

During his last admission, the patient's girlfriend showed us an article published in an Australian newsletter which she had obtained via the internet, in which Dr JH Allen had raised the possibility of a link between recurrent vomiting and cannabis abuse. With the aid of the internet we traced and contacted Dr Allen who shared his experience of this condition with us.

Reviewing the patient's history, he freely admitted to smoking cannabis and experiencing the compulsive desire to bathe during bouts of vomiting. Following his last admission in December 2002, our patient stopped smoking cannabis and has remained free of symptoms. The clinical presentation which is almost identical to the cases described by Allen *et al*, together with the response to cessation of smoking cannabis, supports the view that our patient was suffering from cannabinoid hyperemesis and that this condition is international.

E Roche, P N Foster

Macclesfield District General Hospital, Macclesfield, Cheshire, UK

Correspondence to: Dr E Roche, Macclesfield District General Hospital, Victoria Rd, Macclesfield, Cheshire SK10 3BL, UK; enrico.roche@ntlworld.com

Conflict of interest: None declared.

Inflammatory bowel disease stimulates formation of carcinogenic N-nitroso compounds

In patients with inflammatory bowel disease (IBD), an increased incidence of colorectal cancer is observed.¹ Although severe inflammatory conditions per se represent a risk factor for neoplasia, we would like to draw attention to the possible role of increased activity of inducible nitric oxide synthase (iNOS), as found in IBD patients,² in the endogenous formation of carcinogenic N-nitroso compounds (NOC). In healthy

Table 1 Faecal N-nitrosodimethylamine (NDMA) concentrations in patients with inflammatory bowel disease (IBD) and in healthy controls

	Controls (n = 17)	All IBD cases (n = 17)	Non-hospitalised cases (n = 10)	Hospitalised cases (n = 7)
%NDMA positive	35	41	56	25
NDMA (ng/g)*	1.4	10.9†	14.3††	2.4‡

*Average concentration of NDMA positive samples.

†p<0.05, ††p<0.01: significantly higher compared with the control group (Mann-Whitney U test).

‡p<0.05: significantly lower compared with non hospitalised cases (Mann-Whitney U test).

individuals, relatively small amounts of NOC are formed by the interaction between NOC precursors (NOCP), present in dietary items such as meat and fish, and nitrosating agents derived from dietary nitrate. It has been proposed that endogenous formation of NOC may explain the link between meat consumption and colon cancer risk found in epidemiological studies.³ We hypothesised that as a result of chronic inflammatory conditions in the large intestine, increased colonic iNOS activity may produce an excess of NO, nitrogen oxides, and nitrite, which in turn react with NOCP present in the colon to produce relatively high levels of NOC. Increased formation of NOC in IBD patients may thus contribute to the relatively high incidence of colorectal cancer associated with this disease.

A recent population based case control study showed that in cases with a history of IBD, increased exposure to drinking water nitrate was associated with an increased risk of colon cancer whereas no such association was found in the overall population.⁴ This clearly indicates that the risk of colon cancer in IBD patients is not only determined by the disease itself but dietary factors known to influence the endogenous formation of NOC are also associated with an increased risk in these patients. Although both the increased formation of NOC found in mice with chemically induced colitis⁵ and increased levels of NO and nitrite found in the colonic lumen of patients with ulcerative colitis⁶ support this hypothesis, faecal NOC levels have never been investigated in IBD patients.

Therefore, we collected faecal samples from 17 patients diagnosed with ulcerative colitis and 17 healthy controls, and determined levels of N-nitrosodimethylamine (NDMA), a predominant carcinogenic NOC, using gas chromatography-mass spectrometry, as previously described.⁷ The study was approved by the medical ethics committee of the Maasland Hospital, Sittard, the Netherlands, and all patients gave their consent. In 41% of patients, we found levels of NDMA above the detection limit of 1 ng/g faeces, compared with 35% of controls. Comparison of concentrations in NDMA positive samples showed that the average concentration in patients was significantly higher than that in the control group (table 1). When IBD patients were subdivided into hospitalised and non-hospitalised cases, the difference between the non-hospitalised group and controls was even more pronounced, whereas NDMA concentrations in hospitalised patients and controls were comparable. As all hospitalised patients received only liquid nutrition (Nutrison; Nutricia, UK) without additional intake of NOCP rich dietary foods, these results confirm that the combination of high dietary NOCP intake and inflammation may present a risk factor.

Most research on endogenous NOC exposure has focused predominantly on the

intra-gastric formation of these compounds in relation to the gastric cancer risk. However, we now report that faecal NDMA levels in IBD patients are considerably higher than those we reported previously in gastric juice (0.25 (0.3) ng/g),⁷ which indicates that NOC exposure may be even more relevant in colon carcinogenesis.

Based on these results, we conclude that the colon of IBD patients is exposed to relatively high concentrations of this carcinogenic compound, probably as a direct consequence of continuous NO production by the inflammatory process. As this exposure may strongly contribute to the increased colon cancer risk associated with IBD, dietary recommendations for IBD patients, avoiding high NOCP intake, seem warranted.

T M C M de Kok

Department of Health Risk Analysis and Toxicology, University Maastricht, Maastricht, the Netherlands

L G J B Engels

Department of Gastroenterology, Maasland Hospital, Sittard, the Netherlands

E J Moonen, J C S Kleinjans

Department of Health Risk Analysis and Toxicology, University Maastricht, Maastricht, the Netherlands

Correspondence to: Dr T M C M de Kok, Department of Health Risk Analysis and Toxicology, University Maastricht, PO Box 616, 6200 MD, Maastricht, the Netherlands; t.dekok@grat.unimaas.nl

doi: 10.1136/gut.2004.057471

Conflict of interest: None declared.

References

- 1 Lashner BA, Hanauer SB, Silverstein MD. Optimal timing of colonoscopy to screen cancer in ulcerative colitis. *Ann Intern Med* 1988;108:274–8.
- 2 Kimura H, Hokari R, Miura S, *et al*. Increased expression of an inducible isoform of nitric oxide synthase and the formation of peroxynitrite in colonic mucosa of patients with active ulcerative colitis. *Gut* 1996;42:180–7.
- 3 Bingham SA, Pignatelli B, Pollock JR, *et al*. Does increased endogenous formation of N-nitroso compounds in the human colon explain the association between red meat and colon cancer. *Carcinogenesis* 1996;17:515–23.
- 4 De Roos AJ, Ward MH, Lynch CF, *et al*. Nitrate in public water supplies and the risk of colon and rectum cancers. *Epidemiology* 2003;14:640–9.
- 5 Mirvish SS, Haorah J, Zhou L, *et al*. N-Nitroso compounds in the gastrointestinal tract of rats and in the feces of mice with induced colitis or fed hot dogs or beef. *Carcinogenesis* 2003;24:595–603.
- 6 Roediger WEW, Lawson MJ, Rodcliffe BC. Nitrite from inflammatory cells: A cancer risk factor in ulcerative colitis. *Dis Colon Rectum* 1990;33:1034–6.
- 7 Vermeer ITM, Engels LGJB, Pachen DMFA, *et al*. Intra-gastric volatile N-nitrosamines, nitrite, and pH, and *Helicobacter pylori* during long-term treatment with omeprazole. *Gastroenterology* 2001;121:517–25.

Hepatocellular carcinoma occurring after successful treatment of childhood cancer with high dose chemotherapy and radiation

Hepatocellular carcinoma (HCC) is one of the world's most common malignancies and accounts for more than 90% of all primary liver cancers. A number of different risk factors have been identified for the development of HCC.¹ Hepatitis B carrier state, environmental toxins, chronic hepatitis C virus infection, hereditary haemochromatosis, and liver cirrhosis of almost any cause are well known risk factors for HCC. In addition, environmental toxins such as aflatoxins and contaminated drinking water may contribute to the pathogenesis of HCC, especially in Asia and underdeveloped countries. Finally, a number of HCC cases have occurred after the use of thorotrast for diagnostic procedures, and survivors of the atomic bomb of Hiroshima were also at higher risk for HCC development,² indicating that radiation might also induce the development of HCC. Herein we describe a rare case of HCC occurring in a patient 17 years after successful treatment of peripheral neuroectodermal tumour (PNET)

A 32 year old female presented with pain in the right upper quadrant of her abdomen. Seventeen years prior to presentation in our hospital this patient was treated for a PNET with a combination of high dose chemotherapy (vincristine, adriablastin, ifosfamide, and actinomycin D) and surgical removal of the 10×5 cm tumour from her right chest followed by combined radiation (60 Gy) and chemotherapy. There were no signs of any recurrence of the tumour observed on her last check up 12 month earlier. Physical examination of the patient in our clinic showed typical signs of late radiation damage (erythema of the skin and an underdeveloped right breast) (fig 1). A firm 3–5 cm mass was palpable at the lower edge of the liver. Laboratory tests showed elevated α -fetoprotein (41881 μ g/l). Hepatitis serology was negative and there was no evidence of any other liver disease. Magnetic resonance imaging revealed multiple intrahepatic masses up to 6.5 cm. A biopsy from the hepatic tumour was taken and confirmed the clinical diagnosis of HCC. The patient died three months after the diagnosis was made.

To the best of our knowledge, secondary HCC following high dose chemotherapy has never been described and therefore we searched the German Childhood Cancer

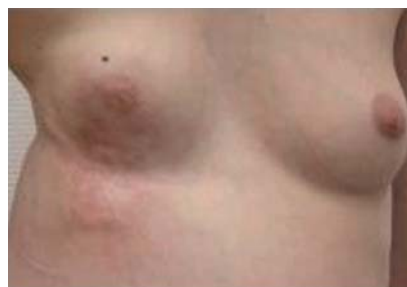

Figure 1 Thorax and upper abdomen of the patient, 17 years after radiation with 60 Gy and removal of the peripheral neuroectodermal tumour.

Table 1 Details of five cases of secondary hepatocellular carcinoma

First malignancy	Age (y)	Treatment	Age when HCC was diagnosed (y)	Time from first to second malignancy (y)
ALL	4	CTx*	20	15
Osteosarcoma	9	CTx, RTx	18	9
ALL	4	na	10	5
PNET	15	CTx, RTx,	33	18
Teratoma	2	na	19	16

ALL, acute lymphocytic leukaemia; PNET, peripheral neuroectodermal tumour; CTx, chemotherapy; RTx, radiation therapy.

*This patient was hepatitis B surface antigen positive.

registry,³ which started to register all cases of malignancies in children (<15 years) in 1980. This database also collects data from secondary malignancies following chemotherapy. In this database we were able to detect a total of four more cases of secondary HCC, which are summarised in table 1. Interestingly one patient was hepatitis B surface antigen positive.

Radiotherapy has been shown to be associated with an increased risk of solid tumours 10–15 years after treatment and later.⁴ There is one report in the literature of a radiation induced hepatoma in a patient with a non-malignant hepatic haemangioma,⁵ which occurred 20 years after radiation of the liver with 28.5 Gy. To date, the molecular mechanism of hepatocarcinogenesis is not completely understood. The main causative agents—hepatitis B virus, hepatitis C virus, and aflatoxin B1—have been identified, which together are responsible for approximately 80% of all HCC in humans. This series of cases clearly supports the notion that secondary HCC can follow not only radiation therapy of children but also high dose chemotherapy, and may prompt careful follow up examinations of the liver in patients with a possible risk for the development of HCC.

T F Greten, M P Manns

Department of Gastroenterology, Hepatology, and Endocrinology, Medizinische Hochschule Hannover, Germany

I Reinisch, P Kaatsch

German Childhood Cancer Registry, Institute for Medical Biometrics, Epidemiology and Informatics, University of Mainz, Germany

Correspondence to: Dr T F Greten, Department of Gastroenterology, Hepatology, and Endocrinology, Medizinische Hochschule Hannover, Carl-Neuberg Str 1, 30625 Hannover, Germany; greten.tim@mh-hannover.de

doi: 10.1136/gut.2004.059352

Conflict of interest: None declared.

References

- Llovet JM, Burroughs A, Bruix J. Hepatocellular carcinoma. *Lancet* 2003;**362**:1907–17.
- Thompson DE, Mabuchi K, Ron E, *et al.* Cancer incidence in atomic bomb survivors. Part II: Solid tumors, 1958–1987. *Radiat Res* 1994;**137**(suppl 2):S17–67.
- Kaatsch P, Haaf G, Michaelis J. Childhood malignancies in Germany—methods and results of a nationwide registry. *Eur J Cancer* 1995;**31**:993–9.
- Klein G, Michaelis J, Spix C, *et al.* Second malignant neoplasms after treatment of childhood cancer. *Eur J Cancer* 2003;**39**:808–17.

5 Moore TA, Ferrante WA, Crowson TD. Hepatoma occurring two decades after hepatic irradiation. *Gastroenterology* 1976;**71**:128–32.

Biologics in inflammatory disease: infliximab associated risk of lymphoma development

In their excellent overview of currently available biologic compounds that are in use or under investigation for Crohn's disease (CD), Sandborn and Faubion (*Gut* 2004;**53**:1366–73) reconfirm the unique standing of infliximab. They also note the ongoing discussion concerning the increased occurrence of lymphoproliferative disorders in patients who received infliximab.

Recently, we followed a 61 year old patient with a 31 year history of relapsing CD. Initial treatment was with steroids but after 10 years a right sided hemicolectomy necessitated discontinuation of steroids. Five years before the present admission, the patient relapsed with multiple rectovesicular fistulas. Non-Hodgkin lymphoma was absent in the histologic material. Because of a poor response to conventional treatment, including azathioprine (100–200 mg/day), infliximab was added 22 months before the current admission. Total infliximab therapy included three doses of 400 mg (5 mg/kg) within two months and resulted in a marked reduction of CD activity (azathioprine was maintained). On admission 10 months after the last infliximab infusion, the patient relapsed again with ulcerations and multiple recto-rectal fistulas. Biopsies showed a polymorphous tumour infiltrate. Tumour cells were positive for CD30 and negative for T and B cell markers as well as the anaplastic large cell lymphoma kinase (ALK) and Epstein-Barr virus (EBV) associated proteins. A multiplex polymerase chain reaction approach revealed a clonal T cell population and an oligoclonal B cell population. Based on these results, the diagnosis was ALK negative anaplastic large cell lymphoma with null/T cell phenotype. Clinical stage was IAE. CHOP-chemotherapy resulted in complete clinical and histological remission, which was evidenced by computer tomography, positron emission tomography, and negative rectal histology. Polymerase chain reaction analysis of the rectal biopsies revealed no T cell receptor rearrangement.

Three months later, the patient presented with postobstructive pneumonia. Trans-bronchial biopsies showed a diffuse large B cell lymphoma. In contrast with the preceding rectal biopsies, bronchial tumour cells were positive for CD20, EBER, EBNA2, and LMP-1, indicating EBV infection of latency type III, were detected in tumour cells.

Table 1 Patients with infliximab therapy and development of lymphoma

Case	Age (y), sex, disease	Dose; No of infusions	Lymphoma	EBV
1 ¹	77, M, NR	NR	Burkitt lymphoma	NR
2 ¹	NR	NR	Hodgkin lymphoma	NR
3 ¹	43, F, NR	NR	Hodgkin lymphoma	NR
4 ¹	34, M, NR	NR	DLBCL	Positive
5 ¹	70, M, NR	NR	DLBCL	NR
6 ¹	29, M, CD	5 mg/kg; 3	Hodgkin lymphoma	NR
7 ¹	68, F, NR	NR	B cell NHL	NR
8 ¹	62, M, NR	NR	DLBCL	NR
9 ¹	73, M, NR	NR, multiple,	Mantle cell lymphoma	NR
10 ²	74, F, RA	10 mg/kg; 8	B cell NHL	NR
11 ²	48, M, RA	10 mg/kg; 2	B cell NHL	NR
12 ²	59, F, RA	3 mg/kg; 5	Multiple myeloma	NR
13 ²	61, M, RA	1 mg/kg; 1	Hodgkin lymphoma	NR
14 ²	36, M, CD, HIV	10 mg/kg; NR	B cell NHL	NR
15 ^{2,3}	62, M, CD	10 mg/kg; 1	Intravascular B-NHL	NR
16 ⁴	48, F, DM	5 mg/kg; 3	DLBCL	NR
17 ⁵	47, M, Psoriasis	6 mg/kg; 3	CD30+ T-cell lymphoma	Negative
18 ⁶	70, M, CD	5 mg/kg; 3	Follicular lymphoma	NR
19 ⁶	51, M, CD	5 mg/kg, 4	Hodgkin lymphoma	NR
20 ⁷	25, M, CD	5 mg/kg, 1	NK cell lymphoma	NR
21 ⁷	79, M, CD	5 mg/kg, 1	B cell NHL	NR
22 ⁷	24, F, CD	5 mg/kg, NR	B cell NHL	NR
23 ⁸	NR, RA	NR	DLBCL	NR
24 ⁸	NR, RA	NR	Mixed cell NHL	NR
25 ⁸	NR, RA	NR	B cell NHL	NR
26 ⁸	NR, RA	NR	B cell NHL	NR
27 ⁸	NR, RA	NR	B cell NHL	NR
28 ⁸	NR, RA	NR	DLBCL	NR
29 ⁸	NR, RA	NR	Lymphocytic NHL	NR
30 ⁸	NR, RA	NR	Low grade NHL	NR
31 ⁸	NR, RA	NR	Mixed cell NHL	NR
33 ⁹	NR, CD	5 mg/kg, 1	NK cell lymphoma	NR
34	61, M, CD	10 mg/kg, 3	Metachronous lymphoma (ALCL, DLBCL)	Positive

ALCL, anaplastic large cell lymphoma, CD, Crohn's disease, DLBCL, diffuse large B cell lymphoma, DM, dermatomyositis, NHL, non-Hodgkin lymphoma, NR, not reported, RA, rheumatoid arthritis.

However, tumour cells were negative for CD30 and ALK protein. Molecular analysis demonstrated a monoclonal immunoglobulin heavy chain rearrangement in the absence of a T cell receptor rearrangement, confirming the diagnosis. The tumour was neither responsive to CHOP-Rituximab nor to the ensuing second and third line chemotherapies. When the patient presented for fourth line chemotherapy, spontaneous partial remission was seen, persisting now for 10 months up to the last clinical follow up in September 2004.

As mentioned by Sandborn and Faubion, the 33 published cases¹⁻⁹ (table 1) of lymphomas following infliximab therapy raise the question of a contributory role of infliximab in the propagation of lymphoproliferative disorders.

We can now add a unique case of a metachronous duplex non-Hodgkin lymphoma of initially T and then B cell phenotype. Imbalanced function of T lymphocytes may have acted as a key feature in this patient as the development of CD and the EBV related B cell non-Hodgkin lymphoma were both closely related to T lymphocytes. This links the case to infliximab as proapoptotic effects on T lymphocytes caused by infliximab have been described. Therefore, the recommendation to routinely give infliximab maintenance therapy and concomitant immunosuppressive treatment to minimise the formation of antichimeric antibodies seems to carry a theoretical risk of elevating the incidence of lymphoma above the background rate. Infliximab was approved by the US Federal Drug Administration five

years ago, and up until April 2004 approximately 500 000 patients have been treated. Based on medwatch data, an incidence of non-Hodgkin lymphoma of 6.6/100 000 treated patients was estimated in 2002, which still seems valid if compared with published cases. However, our current knowledge does not allow definitive conclusions to be drawn about the association of infliximab and lymphoma.

C Bucher

Department of Internal Medicine, University Hospital, Basel, Switzerland

L Degen

Department of Gastroenterology, University Hospital, Basel, Switzerland

S Dirnhofer

Institute of Pathology, University Hospital, Basel, Switzerland

M Pless, R Herrmann

Department of Oncology, University Hospital, Basel, Switzerland

P Schraml, P Went

Institute of Pathology, University Hospital, Basel, Switzerland

Correspondence to: Dr P Went, Institute of Pathology, University of Basel, Schönbeinstrasse 40, CH-4031 Basel, Switzerland; pwent@uhbs.ch

Conflict of interest: None declared.

References

- 1 Brown SL, Greene MH, Gershon SK, *et al.* Tumor necrosis factor antagonist therapy and lymphoma

development: twenty-six cases reported to the Food and Drug Administration. *Arthritis Rheum* 2002;**46**:3151-8.

- 2 Bickston SJ, Lichtenstein GR, Arseneau KO, *et al.* The relationship between infliximab treatment and lymphoma in Crohn's disease. *Gastroenterology* 1999;**117**:1433-7.
- 3 Rutgeerts P, D'Haens G, Targan S, *et al.* Efficacy and safety of retreatment with anti-tumor necrosis factor antibody (infliximab) to maintain remission in Crohn's disease. *Gastroenterology* 1999;**117**:761-9.
- 4 Roddy E, Courtney PA, Morris A. Non-Hodgkin's lymphoma in a patient with refractory dermatomyositis which had been treated with infliximab. *Rheumatology (Oxford)* 2002;**41**:1194-5.
- 5 Mahe E, Descamps V, Grossin M, *et al.* CD30+ T-cell lymphoma in a patient with psoriasis treated with ciclosporin and infliximab. *Br J Dermatol* 2003;**149**:170-3.
- 6 Colombel JF, Loftus EV Jr, Tremaine WJ, *et al.* The safety profile of infliximab in patients with Crohn's disease: the Mayo clinic experience in 500 patients. *Gastroenterology* 2004;**126**:19-31.
- 7 Ljung T, Karlen P, Schmidt D, *et al.* Infliximab in inflammatory bowel disease: clinical outcome in a population based cohort from Stockholm County. *Gut* 2004;**53**:849-53.
- 8 Wolfe F, Michaud K. Lymphoma in rheumatoid arthritis: the effect of methotrexate and anti-tumor necrosis factor therapy in 18,572 patients. *Arthritis Rheum* 2004;**50**:1740-51.
- 9 Hanauer SB, Feagan BG, Lichtenstein GR, *et al.* Maintenance infliximab for Crohn's disease: the ACCENT I randomised trial. *Lancet* 2002;**359**:1541-9.

Genotypes 677TT and 677CT+1298AC of methylenetetrahydrofolate reductase are associated with the severity of ulcerative colitis in central China

Increased blood levels of homocysteine have been found to be associated with inflammatory bowel disease (IBD) in several studies.^{1,2} The main genetic determinant associated with elevated plasma levels of homocysteine (t-Hcys) is the *MTHFR* 677C→T gene polymorphism of methylenetetrahydrofolate reductase, a critical enzyme involved in the remethylation pathway of homocysteine.³ An association of the *MTHFR* 677T allele with IBD has been reported in Northern Europe⁴ but not in three other series from Italy and France.⁵⁻⁷ Double heterozygosity *MTHFR* 677CT+1298AC also produces reduced enzyme activity and increased t-Hcys, but its association with IBD has never been studied. Similarly, the association of IBD with transcobalamin (*TCN1* 776C→G), a genetic determinant that influences transcobalamin levels and t-Hcys, is not known. Transcobalamin is the protein that promotes intestinal transcytosis and cell delivery of vitamin B12, the cofactor of the methionine synthase dependent remethylation pathway.⁸

In this study, we have evaluated the association of ulcerative colitis (UC) with *MTHFR* 677C→T, *MTHFR* 1298A→C, and *TCN1* 776C→G in a series of 72 patients from central China who gave informed consent. This series was compared with 111 age and sex matched controls. The research protocol was approved by the local appointed committee. Extraction of DNA and determination of polymorphisms were performed as described previously by us.^{8,9} A continuity corrected χ^2 test and an ANOVA test were used, respectively, to assess differences in categorical and continuous variables between groups. Odds ratios of independent categorical variables

Table 1 Clinical characteristics and *methylenetetrahydrofolate reductase* (*MTHFR*) and *transcobalamin* (*TCN*) polymorphisms in 72 patients with ulcerative colitis (UC) and 111 controls from central China

	Ulcerative colitis	Controls	p Value
n	72	118	
Sex (F/M)	35/37	58/60	0.9423
Age (y) (mean (SD))	41 (15)	40 (13)	0.4809
Age of onset (y) (mean (SD))	38 (14)		
Current smoker (n (%))	1 (1.4)		
Extent of UC (n (%))			
Rectum	40 (55.6)		
Left colitis	15 (20.8)		
Right colon	1 (1.4)		
Total colon	17 (23.6)		
Treatment (n (%))			
5-ASA/SASP	53 (73.6)		
Steroids	15 (20.8)		
Antibiotics	13 (18.1)		
Intestinal resections (n (%))	1 (1.4)		
Genetic polymorphisms (n (%)) [95% CI]			
<i>MTHFR</i> 667T allele	50 (34.7) [27.3–42.7]	91 (41.0) [34.7–47.5]	0.2286
<i>MTHFR</i> 677T	10 (13.9) [7.2–23.0]	21 (18.9) [12.4–26.8]	0.3707
<i>MTHFR</i> 1298 C allele	18 (14.1) [8.8–20.7]	41 (18.5) [13.7–23.9]	0.2889
<i>MTHFR</i> 677CT+1298AC	4 (6.2) [2.0–14.0]	17 (15.3) [9.5–22.7]	0.0755
<i>MTHFR</i> 677TT/CT+1298AC	14 (21.2) [12.6–32.0]	38 (34.2) [25.9–43.3]	0.0659
<i>TCN</i> 776G allele	62 (63.3) [53.6–72.3]	138 (60.0) [53.6–66.2]	0.5709
<i>TCN</i> 776CG+GG	42 (85.7) [74.3–93.6]	89 (77.4) [69.3–84.3]	0.2236
	Total colon	Less extended UC	
<i>MTHFR</i> 677TT+CT/1298AC	7 (43.7) [22.6–66.6]	7 (14.0) [6.3–25.2]	0.0162

that differed significantly between patients and controls were determined by logistic regression analysis. A *p* value <0.05 was considered to indicate statistical significance.

The main clinical characteristics are summarised in table 1. Most of the cases were recently diagnosed. None had any thrombotic manifestations. *TCN* 776G allele frequency was approximately 1.5-fold higher compared with Caucasians, and we failed to find any association with the risk of UC or severity of disease. *MTHFR* 677T allele frequency in our control group was close to that reported in South Europe and much higher than that of North Europe. There was no significant association of the *MTHFR* 677TT or 677T allele with the risk of UC. By comparison, this association was significant in two UC series of 52 and 91 cases, respectively, from the UK and Denmark, two countries with a lower *MTHFR* 677T allele frequency, but not in other series from Italy and France where allele frequency was comparable with that observed in our population. These discrepant results could therefore be related, at least in part, to ethnic variations in 677T allele frequency, as previously observed with Down syndrome, spina bifida, and cardiovascular diseases.¹⁰ In contrast, we found a significant association with age at onset. Onset in 677T allele carriers occurred later than that of non-carriers, with respective mean ages of 42.4 (15.7) and 35.4 (13.8) (*p* = 0.0487).

Our results were different when the two 677TT and 677CT+1298AC genotypes of *MTHFR* were considered together, that correspond to decreased catalytic activity. Firstly, the difference in frequency between patients and controls was at the limit of significance and this could be related to the limited size of our patient series (table 1). Secondly, these genotypes were associated with an increased risk of extensive UC (whole colon) (table 1), with an odds ratio of 4.92 (95% confidence interval 1.3–18.3; *p* = 0.017), after adjustment for age and sex.

In conclusion, our study showed that the genotypes of *MTHFR*, associated with a decrease in enzyme activity, seemed to be more significantly associated with extension of disease than with the primary risk, at least in central China.

M Chen, B Xia

Department of Internal Medicine and Geriatrics, Zhongnan Hospital and Research Centre of Digestive Diseases, Wuhan University Medical School, Wuhan, RP China

R M Rodriguez-Gueant, M Bigard, J-L Gueant

INSERM-0014 and Department of Hepato-Gastroenterology, Medical Faculty and University Hospital Centre, University of Nancy, Nancy, France

Correspondence to: Dr J-L Gueant, INSERM-0014 and Department of Hepato-Gastroenterology, Medical Faculty and University Hospital Centre, University of Nancy, Nancy, France; jl.gueant@chu-nancy.fr

doi: 10.1136/gut.2004.062539

Conflict of interest: None declared.

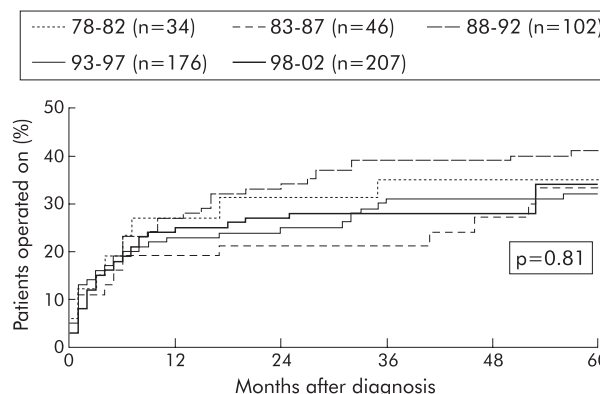


Figure 2

References

- Mahmud N, Molloy A, McPartlin J, *et al*. Increased prevalence of methylenetetrahydrofolate reductase C677T variant in patients with inflammatory bowel disease, and its clinical implications. *Gut* 1999;45:389–94.
- Papa A, Danese S, Grillo A, *et al*. Review article: inherited thrombophilia in inflammatory bowel disease. *Am J Gastroenterol* 2003;98:1247–51.
- Bollander-Gouaille C. *Focus on homocysteine and the vitamins involved in its metabolism*, 2nd edn., Paris: Springer-Verlag 2002.
- Nielsen JN, Larsen TB, Fredholm L, *et al*. Increased prevalence of methylenetetrahydrofolate reductase C677T variant in patients with IBD. *Gut* 2000;47:456–7.
- Vecchi M, Sacchi E, Saibeni S, *et al*. Inflammatory bowel diseases are not associated with major hereditary conditions predisposing to thrombosis. *Dig Dis Sci* 2000;45:1465–9.
- Papa A, De Stefano V, Danese S, *et al*. Hyperhomocysteinemia and prevalence of polymorphisms of homocysteine metabolism-related enzymes in patients with inflammatory bowel disease. *Am J Gastroenterol* 2001;96:2677–82.
- Guedon C, Le Cam-Duchez, Lalaude O, *et al*. Prothrombotic inherited abnormalities other than factor V Leiden mutation do not play a role in venous thrombosis in inflammatory bowel disease. *Am J Gastroenterol* 2001;96:1448–54.
- Namour F, Olivier JL, Abdelmouttaleb I, *et al*. Transcobalamin codon 259 polymorphism in HT-29 and Caco-2 cells and in Caucasians: relation to transcobalamin and homocysteine concentration in blood. *Blood* 2001;97:1092–8.
- Amouzou E, Chabi N, Adjalla C, *et al*. High prevalence of hyperhomocysteinemia related to folate deficiency and mutated 677 C→T/MTHFR, in the coast of West Africa. *Am J Clin Nutr* 2004;79:619–24.
- Guéant JL, Rodriguez-Gueant RM, Anello G, *et al*. Genetic determinants of folates and vitamin B12 metabolisms: a common pathway in neural tube defect and Down syndrome. *Clin Chem Lab Med* 2003;41:1473–7.

CORRECTION

doi: 10.1136/gut.2004.045294corr1

The original article by Cosnes *et al* (Impact of the increasing use of immunosuppressants in Crohn's disease on the need for intestinal surgery. *Gut* 2005;54:237–41), published in the February 2005 issue was incomplete. Figure 2 was missing from the proof. A corrected version of the pdf can be viewed at <http://gut.bmjjournals.com/cgi/data/54/2/237/DC1/1>, and the missing figure can be seen here.