

DOCUMENT RESUME

ED 315 322

SE 051 220

AUTHOR Conrey, Kathleen  
TITLE Lecture Notes on Human Anatomy. Part Two, Fourth Edition.  
PUB DATE Sep 89  
NOTE 105p.; For related documents, see SE 051 218-221. Black and white illustrations will not reproduce clearly.  
AVAILABLE FROM Aramaki Design and Publications, 12077 Jefferson Blvd., Culver City, CA 90506 (\$7.75).  
PUB TYPE Guides - Classroom Use - Materials (For Learner) (051)  
EDRS PRICE MF01 Plus Postage. PC Not Available from EDRS.  
DESCRIPTORS \*Anatomy; \*Biological Sciences; \*College Science; Higher Education; \*Human Body; \*Lecture Method; Science Education; Secondary Education; Secondary School Science; Teaching Guides; Teaching Methods

ABSTRACT

During the process of studying the specific course content of human anatomy, students are being educated to expand their vocabulary, deal successfully with complex tasks, and learn a specific way of thinking. This is the second volume in a set of notes which are designed to accompany a lecture series in human anatomy. This volume includes discussions of tissues, cells, and histology; development and embryology; epithelial, glandular, connective, blood, and muscular tissues; and the internal viscera including the digestive system, the urinary system, the reproductive system, the respiratory system, the circulatory system, and the lymphatic system. (CW)

\*\*\*\*\*  
\* Reproductions supplied by EDRS are the best that can be made \*  
\* from the original document. \*  
\*\*\*\*\*

U.S. DEPARTMENT OF EDUCATION  
Office of Educational Research and Improvement  
EDUCATIONAL RESOURCES INFORMATION  
CENTER (ERIC)

This document has been reproduced as  
received from the person or organization  
originating it.

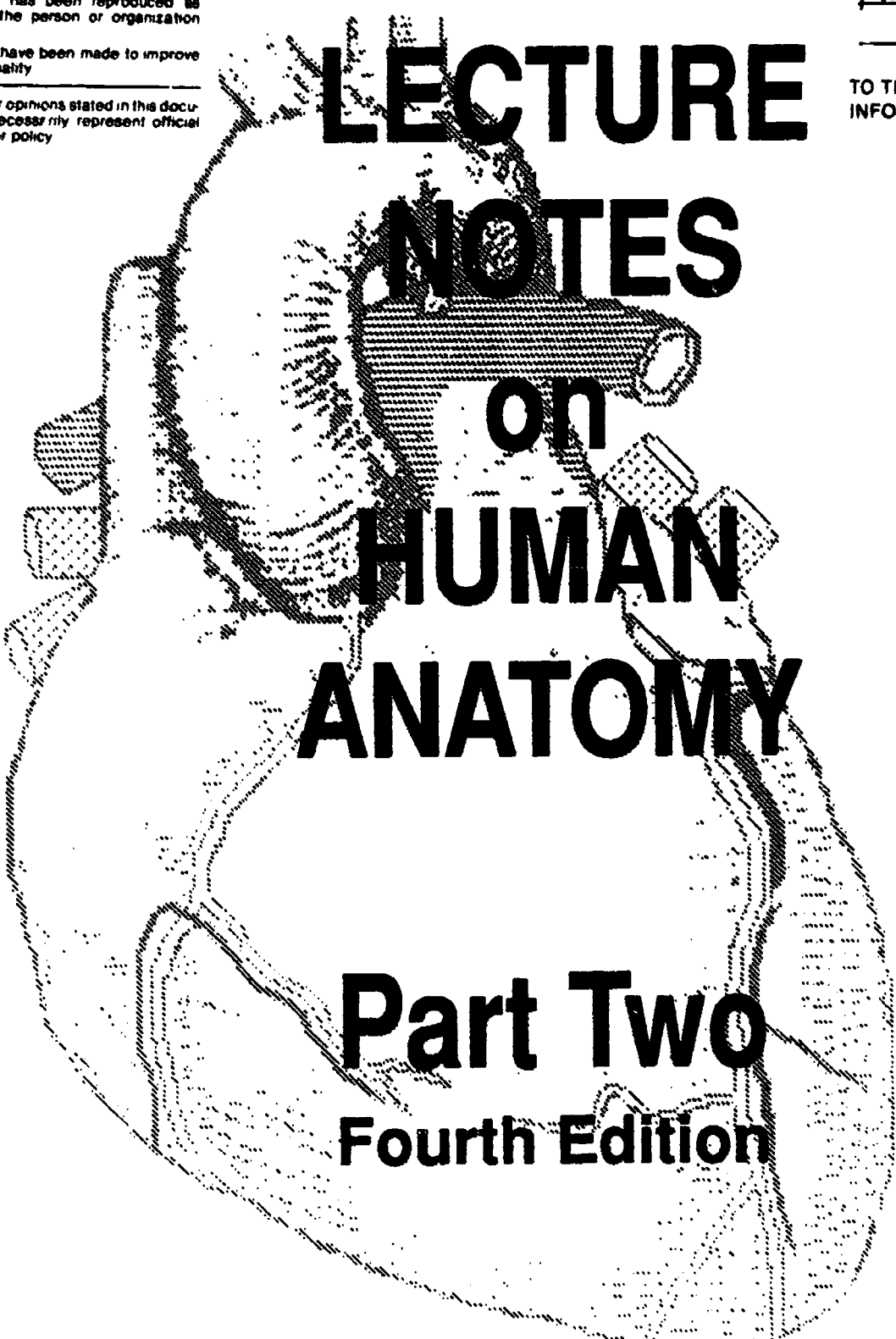
Minor changes have been made to improve  
reproduction quality.

Points of view or opinions stated in this docu-  
ment do not necessarily represent official  
OERI position or policy.

"PERMISSION TO REPRODUCE THIS  
MATERIAL IN MICROFICHE ONLY  
HAS BEEN GRANTED BY

*Kathleen Conrey*

TO THE EDUCATIONAL RESOURCES  
INFORMATION CENTER (ERIC)."



# LECTURE NOTES on HUMAN ANATOMY

## Part Two

### Fourth Edition

by KATHLEEN CONREY

ED315322

0815075

---

# **LECTURE NOTES on HUMAN ANATOMY**

## **Part Two Fourth Edition**

---

The author is a Professor of Natural Sciences at El Camino College. She holds a master's degree from the Department of Human Anatomy, University of California, San Francisco, and has been teaching human anatomy at the community college level since 1967.

**by KATHLEEN CONREY**

The author is a Professor of Natural Sciences at El Camino College. She holds a master's degree from the Department of Human Anatomy, University of California, San Francisco, and has been teaching human anatomy at the community college level since 1967.

**Aramaki Design & Publications**  
**12077 Jefferson Boulevard, Culver City, California**  
**(213) 822-9800**

Fourth Edition, September, 1989  
Copyright ©1988 by Kathleen Conrey

*All rights reserved. No part of this publication may be reproduced, stored in a retrieval system, or transmitted in any form or by any means, electronic, mechanical, photocopying, recording or otherwise, without the prior written permission of the copyright owner.*

First edition and first printing 1982

Printed in the United States of America

---

# TABLE OF CONTENTS

---

<b>HISTOLOGY</b>	
<b>INTRODUCTION</b>	<b>1</b>
<b>THE CELL</b>	<b>2</b>
Cell Membranes and Membrane Transport	2
Cell Organelles	3
<b>EMBRYOLOGY</b>	<b>5</b>
Germ Layer Formation	6
Germ Layer Derivatives	7
<b>EPITHELIUM</b>	<b>9</b>
<b>GLANDS</b>	<b>13</b>
<b>CONNECTIVE TISSUE</b>	<b>17</b>
Fiber Types	17
Matrix Types	18
Cell Types	18
Aging	22
Cartilage and Bone	23
<b>BLOOD</b>	<b>24</b>
Hemopoiesis	24
Hemostasis	24
Erythrocytes	26
Hemoglobin and Anemia	26
Leukocytes	27
<b>MUSCLE TISSUE</b>	<b>30</b>
Sarcomere Anatomy	30
Sliding Filament Contraction	31
Types of Muscle Tissue	31
<b>ARCHITECTURAL PLANS OF SIMPLE ORGANS</b>	<b>33</b>
Blood Vessel Walls	33
Skin	33
Mucous Membranes	34
<b>INTERNAL VISCERA PART I</b>	
<b>DIGESTIVE SYSTEM</b>	<b>36</b>
Peritoneal Membranes	36
Mouth and Pharynx	37
Esophagus and Stomach	38
Intestine	40
<b>ACCESSORY DIGESTIVE GLANDS</b>	<b>43</b>
Liver	43

Gallbladder and Pancreas	
45	
Duct System	45
<b>URINARY SYSTEM</b>	<b>47</b>
<b>GROSS ANATOMY OF THE KIDNEY</b>	<b>47</b>
Kidney Gross Anatomy	47
The Nephron Unit	49
Urine Collection System	51
Summary of Pathways	52
<b>REPRODUCTIVE SYSTEM</b>	<b>53</b>
The Perineum	53
How it Works	55
Reproductive Organ Embryology	56
Male Internal Reproductive Organs	59
Female Internal Reproductive Organs	61
Menstrual Cycle	63
Breast	64
Endocrine Control Mechanisms	64
<b>INTERNAL VISCERA PART II</b>	
<b>RESPIRATORY SYSTEM</b>	<b>66</b>
Functions	66
Pharynx	67
Larynx	68
Lung	70
Respiratory Tree	71
Pleural Anatomy	73
Pathology	74
<b>HEART</b>	<b>75</b>
Location and Walls of the Heart	75
A Pair of Pumps	76
Major Vessels Attached to the Heart	77
Valves	78
Cardiac Cycle	79
Coronary Vessels	79
Conducting System	82
Fetal Heart	83
<b>BLOOD VESSELS</b>	<b>84</b>
Chest Area Arteries	84
Chest Area Veins	85
Head and Neck Arteries	86
Head and Neck Veins	87
Arm Vessels	88
Abdominal Vessels	89

<b>Pelvic Vessels</b>	<b>90</b>
<b>Leg Vessels</b>	<b>91</b>
<b>LYMPHATIC SYSTEM</b>	<b>93</b>
<b>Tissue Fluid Transport</b>	<b>93</b>
<b>Fat Transport</b>	<b>94</b>
<b>Immune Functions</b>	<b>94</b>
<b>Lymphoid Organs</b>	<b>95</b>
<b>ANGIOLOGY</b>	<b>97</b>

---

# ***Introduction to Histology***

---

**Histology is the microscopic study of tissues and also the microscopic study of organ architecture.**

- **Cells are the building blocks of the tissues.**
- **Tissues are groupings of similar or identical cells. There are four basic tissue types: epithelial tissue, connective tissue, muscle tissue, and nerve tissue.**
- **Tissues are organized into organs. Most organs are made of all four tissue types, but the tissues are put together in different proportions and with a different architectural plan for each organ.**
- **Similar organs are grouped together into units which either obviously function together, or are similar in some other way. Such groupings are called systems. Examples: the digestive system, the endocrine system, the reproductive system, etc.**



# The Cell

## CELL MEMBRANES

The cell membrane (unit membrane) is trilayered, totaling 75 angstroms in diameter. The core of the triad is phospholipid material. The outer layers of the triad are globular proteins with which the phospholipid core is studded. Some of these proteins are purely structural, others are interactive enzymes needed for (such things as) membrane transport functions.

There are pores in the membrane which are approximately three angstroms in diameter. The presence of these pores is what makes the membrane semipermeable. Ions and particles smaller than three angstroms diameter are able to pass through the membrane passively. Anything larger is prevented passage except by active transport mechanisms.

## MEMBRANE TRANSPORT

### PASSIVE TRANSPORT

Passive transport through a membrane is a property of the semipermeable nature of the membrane. Several types of passive transport are possible:

#### DIFFUSION

Semipermeable membranes permit diffusion, although a membrane is not necessary for diffusion to occur. Diffusion is the movement of solute particles or ions down a concentration gradient from an area of higher concentration toward an area of lower concentration until equilibrium is established.

#### FILTRATION

Semipermeable membranes permit filtration. Filtration is the passive movement of solute particles or ions through a semipermeable membrane in response to gravity, pressure, or suction.

### OSMOSIS

Osmosis is a special case of diffusion. It requires a semipermeable membrane whose pore size prevents movement of the solute, but permits movement of the solvent. The solvent will obey the laws of diffusion; i.e. it will move down a concentration gradient from an area where there is a greater concentration of solvent towards an area where there is a lesser concentration of solvent.

In biology the solvent is always water, so a good definition of osmosis is: the passage of water through a semipermeable membrane according to the laws of diffusion.

### Tonicity

The terms hypertonic, hypotonic and isotonic relate to osmosis.

- **Hypertonic** refers to a solution of relatively high solute concentration (low concentration of water).
- **Hypotonic** is the opposite of hypertonic.
- **Isotonic** refers to a state of equilibrium in which the total solute concentrations on the two sides of the membrane are equal (even though this state may require very different volumes of solvent to be present on the two sides of the membrane).

### ACTIVE TRANSPORT

Active transport is due to physiological properties of the membrane that make it selectively permeable. Active transport always requires both:

- a specific enzyme
- expenditure of energy

Examples:

- a. Insulin and glucose transport
- b. The Sodium Pump.

# CELL ORGANELLES

## MITOCHONDRIA

Mitochondria are the energy producing factories of the cell. These structures are responsible for cellular respiration, i.e. the stepwise degradation of the cellular fuel glucose. Hydrogen ions are released during this process, and they in turn are combined with oxygen in such a way that energy is released. The by products of this process are carbon dioxide and water. Some of the energy produced is in the form of heat; the rest of the energy is stored in the form of ATP (adenosine triphosphate).

## ENDOPLASMIC RETICULUM

The endoplasmic reticulum is a highly convoluted internal complex of cellular membranes that arise as an invagination of the outer cellular membrane. The ER is contiguous with the outer cell membrane and also with the nuclear membrane.

There are two forms of ER, rough and smooth. Rough endoplasmic reticulum is rough because it is studded with ribosomes. Smooth endoplasmic reticulum is smooth because of the absence of ribosomes.

The function of rough ER, is protein synthesis. RNA copies of the nuclear DNA leave the nucleus and travel to the ribosomes of the ER where they serve as instructional templates for the production of protein.

The function of smooth ER is mucopolysaccharide synthesis. The production process is less well understood than that of the rough ER.

## GOLGI APPARATUS (GOLGI BODY)

The Golgi body is a special area of the smooth endoplasmic reticulum where the layers of membrane are very tightly convoluted and packed closely together.

The Golgi body is the site where protein precursors are converted into active enzymes. It also serves as a packaging plant for enzymes and secretion products that need to be walled off from the cell cyto-

plasm. A good example of this is the lysosome enzymes that are used for cellular digestion of phagocytized particles.

## VACUOLES

A vacuole is any membrane bound inclusion body found inside the cell. It is produced by a pinching off of cellular membranes during such processes as phagocytosis and pinocytosis. Secretion droplets and lysosomes produced by the Golgi apparatus can also be considered as vacuoles.

## CENTROSOME

The centrosome contains two pairs of centrioles for cell division.

## NUCLEAR MEMBRANE:

The trilayered endoplasmic reticulum membrane is doubled back on itself around the nucleus in such a way as to form a double layered nuclear membrane with large pores.

## CHROMATIN

An inclusive name for the DNA material inside the nucleus.

## NUCLEOLUS

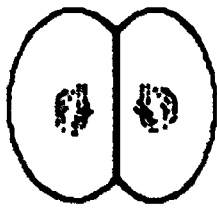
An area inside the nucleus characterized by a concentration of messenger RNA.

## MICROVILLI

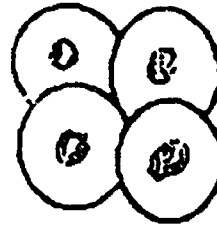
Microvilli are fingerlike evaginations of the outside cell membrane. They serve to increase the surface area of the cell. Increased surface area is an important consideration for cells whose job is absorption, such as those found in the intestine and in the kidney tubules.

## CILIA

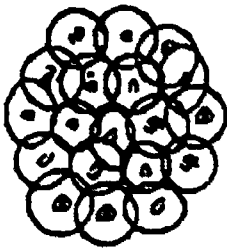
Cilia are special hairlike contractile elements of certain epithelial cells. The cilia are rooted inside the cell and extend outward through the cell membrane on the lumen side of the cell. Coordinated ciliary beating creates ciliary currents in the fluids bathing the epithelium. This is the chief mechanism used in the respiratory system for the movement of mucous, and in the reproductive system for the transport of eggs from fallopian tube to uterus.



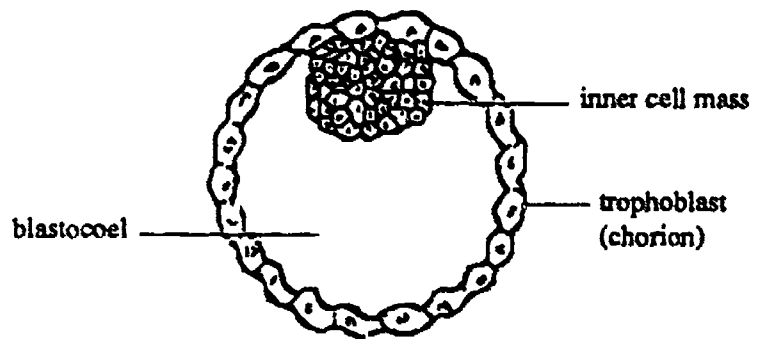
A. Two Cell Stage



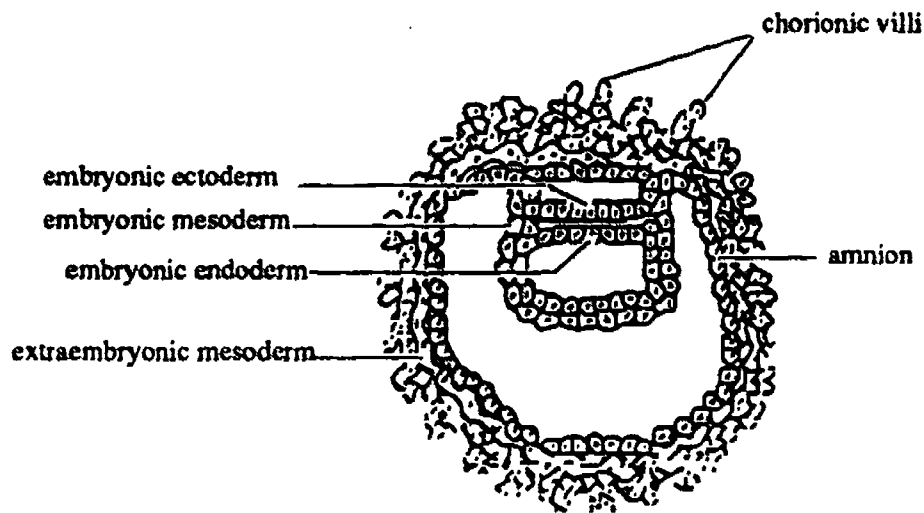
B. Four Cell Stage



C. Morula



D. Blastula With Inner Cell Mass



E The Embryonic Disk Stage of Development

**Fig. 1- Embryonic Germ Layer Formation**

# Early Development of the Embryo

## FERTILIZATION

When the egg is released from the ovary it is surrounded by a group of other cells from the follicle called the *corona radiata*. These cells are held in place around the egg by intercellular glue which is mostly *hyaluronic acid*. Inside the corona radiata, and adhering to the outside of the egg is the *zona pellucida (vitelline membrane)* a thick tough capsule of jellylike material which is almost pure hyaluronic acid. As the egg is swept into the fallopian tube and on toward the uterus, it is met by the sperm cell. Fertilization usually takes place in the upper third of the fallopian tube. A tiny cap on the head of the sperm cell, the *acrosome*, contains *hyaluronidase*, an enzyme which is capable of dissolving away the hyaluronic acid protecting the egg. It probably requires many sperm cells to provide enough enzyme to allow just one of the sperm cells to penetrate the egg. Other sperm cells are prevented from entering by changes that take place in or on the surface of the egg. The nature of these changes is not understood.

When the head of the sperm cell penetrates the egg the tail of the sperm is left outside, and the head of the sperm, containing the haploid number of chromosomes is now called the *male pronucleus*. It fuses with the *female pronucleus* (also containing the *haploid* number of chromosomes). This fusion is called *fertilization*, and the resultant fertilized egg is called a *zygote*. The zygote with its *diploid* number of chromosomes represents the beginning of a new individual that has received half its chromosomes from the male parent and half from the female parent. If the sperm carried an X chromosome the new individual is a genetic female. If the sperm carried a Y chromosome the new individual is a genetic male.

## CLEAVAGE

The first cell division of the zygote produces the "two cell stage"; each of these cells then divides producing the "four cell stage", and so on, until a solid ball of cells called a *morula* is produced. Each of the cells in a morula is *equipotential*, that is, if the mass of cells by chance separates in any way each cell or group of cells can proceed to divide and will eventually produce an entire new individual. See the discussion below on twins.

## DIFFERENTIATION

The term cleavage is only used for the divisions up through the morula stage. With continued division the solid morula becomes a hollow ball of cells called a *blastula*. Cell division has been so rapid up to this point that the daughter cells have not had an opportunity to grow between divisions. As a consequence the cells of each successive division are about half the size of the previous cell, and the early blastula is not much larger than the original egg.

Shortly after formation of the blastula the cells begin to specialize or become different from one another. An *inner cell mass* appears, perhaps explainable as a pile up of more rapidly dividing cells on one side of the blastula. This difference in rate of division may be the first sign of specialization among the cells of the early embryo. Another possible explanation for the appearance of a hollow blastula and its inner cell mass is that the cells on the surface of the morula (the *trophoblast* or *chorion* cells) are somehow different than the cells in the interior, and the surface cells begin to secrete a fluid that collects in the interior of the morula creating a central cavity and pushing the remaining cells (the inner cell mass) against one wall.



In any case, other signs of differentiation rapidly appear as the cells of the inner cell mass begin to stratify into zones which themselves soon show specialization of destiny and function. The body parts of the future individual will develop from only a few of the cells of the inner cell mass, the rest of the cells of the blastula are destined to form the life support system for the embryo, namely the *extra-embryonic* membranes (*chorion*, and *amnion*) and the fetal contributions to the *placenta*.

## IMPLANTATION

The blastula generally arrives in the uterus about 4 days after fertilization, and it apparently remains free in the uterine cavity for a few days, because it generally implants on about day 6 or 7. During this time the outer layer of cells of the blastula (the trophoblast) divide rapidly, forming a second (inner) layer known as *extraembryonic mesoderm*, and also forming finger like projections of the outer surface known as the *chorionic villi*. The cells of the chorionic villi begin to secrete digestive enzymes which enable the blastula to burrow its way into the wall of the uterus. This process takes several days, during which time the chorionic villi and extra-embryonic mesoderm interdigitate with maternal endometrium, forming a complex vascular organ known as the *placenta*, through which exchange of nutrients, blood gasses, and metabolic waste products will take place for the whole term of the pregnancy. In the placenta the embryo's blood circulates within the chorionic villi, and the mother's blood circulates through the spaces around the outside of the villi, however the two blood supplies never come in direct contact with one another.

## GERM LAYER FORMATION

This is the next stage in the process of differentiation, and it takes place simultaneously with implantation. There will eventually be 3 germ layers; two appear first with the third to follow.

The cells of the inner cell mass which are nearest to the trophoblast become the *ectoderm*. A fluid filled cavity (the *amniotic cavity*) appears in the center of the ectoderm cells, and this cavity divides the ectoderm into two parts. The part directly underneath the chorion layer (including a contribution from the extra-embryonic mesoderm) is destined to form the *amnion* layer, a membrane of cells which will eventually completely surround the developing embryo. The other part of the ectoderm group of cells becomes one of the layers of the *embryonic disc*, implying that it is destined to form actual body parts for the future embryo.

Turning our attention to the remainder of the inner cell mass, a second cavity appears, the *yolk sac cavity*. The cells that line this cavity are the *endoderm*, and the layer of endoderm closest to the ectoderm layer also becomes part of the embryonic disc, destined to form parts of the future embryo. The rest of the endoderm forms the *yolk sac*, which in mammals never actually supplies much in the way of nutrient material, and is significant only in that it contributes to the formation of the umbilical artery and vein, and the future gut tube of the embryo.

If you imagine cutting the amniotic cavity open and looking down on the surface of the two cell layered embryonic disc you would see that it is flat and oval shaped at this stage. Its edges will soon start curling under to form a tubular shaped embryo, and simultaneously some of the *ectoderm cells will migrate* between the two existing germ layers to form the third germ layer, the true *mesoderm* of the embryo itself.

The future head end of the tubular shaped embryo now establishes itself by growing more rapidly than the rest of the embryo, and as a result of this rapid growth the head end flexes under.

From the three established germ layers, ectoderm, mesoderm, and endoderm, all the various body parts begin developing. The

brain and spinal cord, the somites, the gut, and the heart, are among the first to appear. The heart is functional quite early (25 days), and it pumps blood to the placenta as well as to the embryo itself. The various organs and tissue of the human body can all be traced back to their germ layer of origin.

## THE FETUS

The embryo is recognizably human at about 8 weeks of development, and at this stage it is called a fetus. At 8 weeks the fetus has most of its future organs, and many are functional. It seems to exercise its muscles with small movements that are as yet too weak to be felt by the mother. This perceptual recognition by the mother of the life within ("quickening") will not occur for several weeks yet.

## TWINNING

### IDENTICAL TWINS

If the cells of the morula do not hang together as they should, the separate cells or cell masses may each develop independently, and the resultant offspring will all have identical genetics and will of course always be of the same sex. Separation of the morula into two or more parts may be partial or complete. If separation is complete the embryos will have separate placentas and chorions; if separation is less complete the embryos may share the same placenta, and perhaps even the same amnion, the same umbilical cord, or even share body parts.

### FRATERNAL TWINS

If two separate eggs are released at the same time they will be fertilized by separate sperm cells, and they will of course develop independently though simultaneously. They may however implant so close together in the uterus that the two chorions and placentas unite. Nevertheless, they do not share the same genetics, may or may not be of the same sex, and are no more closely related than any other pair of siblings.

## GERM LAYER DERIVATIVES

### TISSUES

1. **Epithelial tissue:** may be from ectoderm, endoderm or mesoderm.
2. **Connective tissue:** from mesoderm
3. **Muscle tissue:** from mesoderm.
4. **Nerve tissue:** from ectoderm.

## ORGAN SYSTEMS

### ECTODERM DERIVATIVES

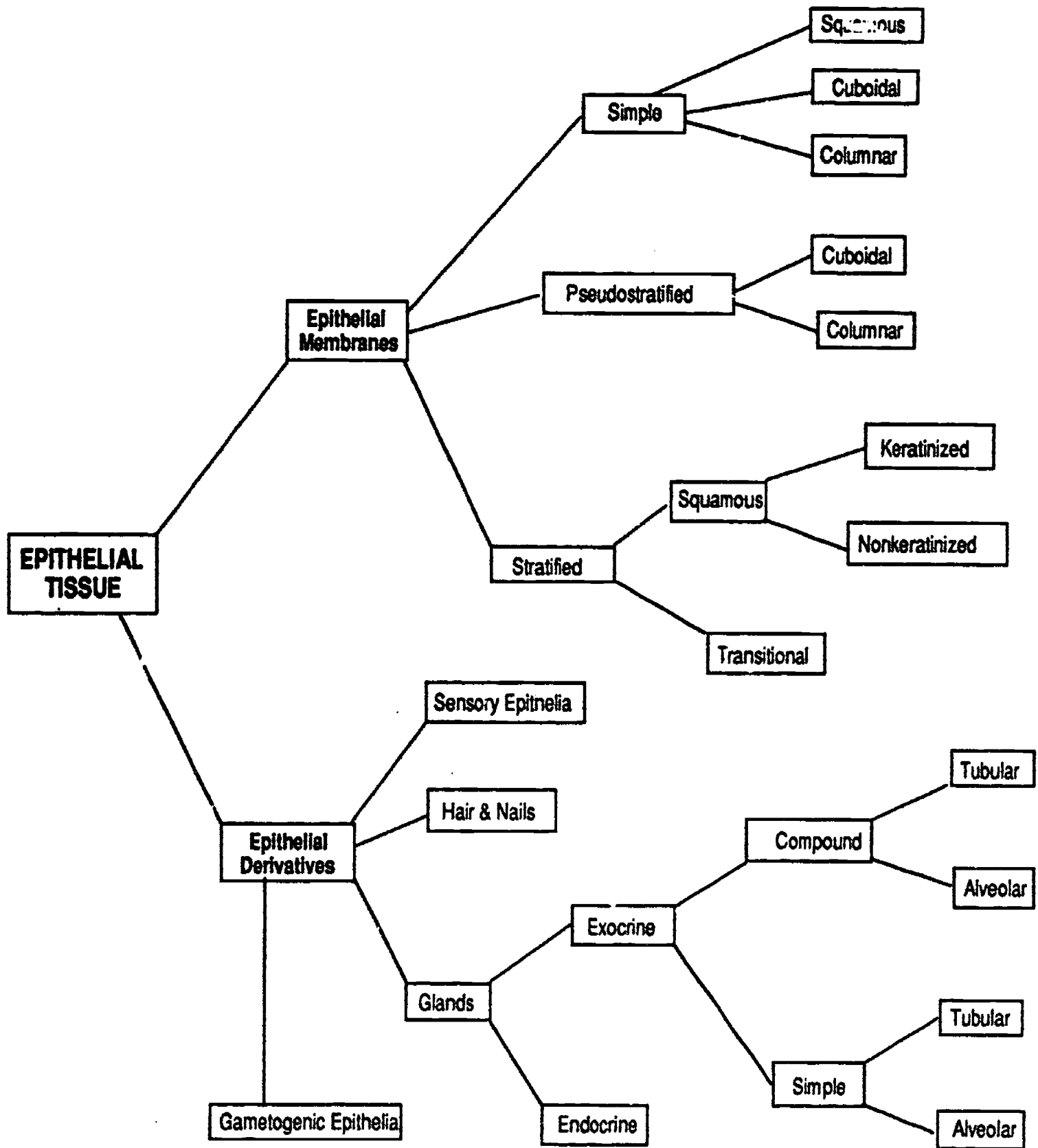
All outside surfaces of the embryo and the infoldings of the same, including all of the nervous system. Examples: epidermis, hair, nails, enamel of teeth, epithelium of mouth, nose, and anus, sweat glands, sebaceous glands, mammary glands, brain, spinal cord, almost all sense organs (inner ear and most of eye), adrenal medulla.

### MESODERM DERIVATIVES

All structures needed to move the body around in order to obtain food: bones, muscles, all connective tissue, circulatory system. Also most of the urinary system and reproductive system. Examples: heart, blood vessels, bone marrow, lymphatics, spleen, lymph nodes, tonsils, gonads, uterus, fallopian tubes, ductus deferens, kidney, and connective tissue and visceral muscle of all organs.

### ENDODERM DERIVATIVES

Epithelium and glands of the digestive system and respiratory system (excluding nose, mouth, and anus). Examples: Epithelium of the gut tube and respiratory tubes, including that of the: tongue, throat, larynx, trachea, lungs, esophagus, stomach, small intestine, large intestine. Examples of glands: liver, pancreas, salivary glands, thymus, thyroid gland, parathyroid glands. Other examples that may be harder to remember: epithelium of urinary bladder, urethra, prostate gland, and lower vagina.



**Fig. 2- Epithelial Tissue Classification**

# Epithelium

## INTRODUCTION

Epithelial membranes are sheets of cells one or more layers in thickness, which line the cavities of the body or cover its surfaces. Most epithelial membranes include scattered cells which have a secretory function.

Epithelial derivatives such as hair, nails, teeth and glands develop as either ingrowths or outgrowths of the basic epithelial sheet.

## EPITHELIAL MEMBRANES

- In an epithelial membrane the cells are fitted together very closely, there is little or no intercellular material between the cells.
- Epithelial membranes by themselves are not mechanically strong. They are always supported by an underlying layer of connective tissue called the *lamina propria*. The epithelium is bound to this connective tissue by a *basement membrane*. This basement membrane is a very thin layer of proteinaceous glue-like material, an extracellular product of the lamina propria.
- An epithelial membrane has two surfaces. One of these, the *basal surface* rests on the lamina propria. The other surface is free, it has nothing on top of it. This surface is called the *free or luminal surface*.
- Epithelial membranes are avascular, i.e. they do not contain blood vessels. Nutrients are delivered by diffusion from the capillaries of the underlying connective tissue.
- All epithelial membranes are subjected to wear and tear; their component cells die and must be replaced by mitotic cell division if the membrane is to remain intact and functional.

## EXAMPLES

The outer layers of the skin are an example of an epithelial tissue. Other external sur-

faces where we find epithelium include all the tubes and passageways leading to the exterior, such as the nose, mouth, anus, vagina, bladder, and urethra. These passages are all lined with mucous membranes, the outer layer of which is epithelium.

Some surfaces of the body do not lead to the outside but instead face internal cavities. Epithelium in these locations is given a special name. For example, the epithelial lining of the inside of blood and lymphatic vessels is called *endothelium*, and the epithelial surface of the pleura and peritoneum is called *mesothelium*.

## SURFACE SPECIALIZATIONS

Some epithelial membranes possess surface specializations such as microvilli and cilia that relate to the function of the epithelium.

### • MICROVILLI

The free surfaces of cells in the intestine and in the kidney possess dense groups of microvilli which increases the active surface area of these cells. The microvilli give the membranes a fuzzy appearance. In the intestine this appearance is often known as a striated border. In the kidney tubules the same structure is often called a *brush border*.

### • CILIA

The free surface of epithelial cells in the respiratory and genito-urinary tracts and parts of the nervous system is ciliated. The coordinated ciliary beating moves mucus or fluids along the surface of the membrane.

## CLASSIFICATION METHOD

Please refer to Figure 2.

Epithelial membranes are classified according to two major microscopic features:

- the number of cell layers
- the shape of the cells

*Determination of these features requires*



*visualization of a tissue sample which has been sectioned perpendicular to the membrane surface.*

## NUMBER OF LAYERS

### • SIMPLE

If there is a single layer of cells, all of which are in contact with the basement membrane, the epithelium is classed as a *simple* epithelium. In such a case the nuclei of the cells typically line up with one another in an even row.

### • STRATIFIED

If more than one layer of cells is superimposed one upon the other, and only the bottom layer of cells rests on the basement membrane, the epithelium is said to be *stratified*. Stratified epithelia are found wherever protection from mechanical abrasion is necessary. The upper cells may be damaged or scraped off without necessarily breaking the integrity of the membrane.

## CELL SHAPE

Three basic cell shapes are recognized:

### SQUAMOUS, CUBOIDAL, COLUMNAR

Squamous cells are flat when viewed from the side. A good analogy is that of a fried egg that has been sliced through the middle of the yolk and viewed from the cut edge. The yolk of the egg represents the nucleus of the cell, the white of the egg represents the cytoplasm of the cell.

Cuboidal cells are about as tall as they are wide.

Columnar cells are taller than they are wide. When considering cell shape in a stratified epithelium it is only the cells of the surface layer that are taken account of since the cells in deeper layers are always cuboidal or irregular in shape.

One particular type of columnar cell which stores and secretes mucous is called a goblet cell. When the cell is swollen with stored mucous it becomes goblet shaped. These cells are characteristic of the epithelium of the gastrointestinal and respiratory tracts.

## DESCRIPTION OF TYPES

### SIMPLE EPITHELIA

#### SIMPLE SQUAMOUS EPITHELIUM

One layer of squamous cells.

Simple squamous epithelial membranes are very delicate and fragile; they present a barrier of minimum thickness and are found in regions where diffusion or filtration rather than protection is the main requirement.

Examples of their occurrence:

- inner surface of blood vessels
- Bowman's capsules of the kidney
- lung alveoli.

#### SIMPLE CUBOIDAL EPITHELIUM

One layer of cuboidal cells.

Simple cuboidal epithelium is found where the membrane must be somewhat stronger than squamous cells or where the cells must work harder and are therefore larger (each cell contains more organelles).

Simple cuboidal epithelial cells specialize in absorption or secretion. When engaged in absorption the cells often have microvilli on their free surface to increase surface area. Kidney tubule cells are an excellent example of simple cuboidal epithelium with a brush border. All gland cells are also simple cuboidal type epithelium. The germinal epithelium covering the outside of the ovary and lining the seminiferous tubules of the testis is also of the simple cuboidal type.

#### SIMPLE COLUMNAR EPITHELIUM

One layer of columnar cells.

This epithelium also specializes in absorption and secretion. It is a stronger epithelium than the simple cuboidal type, and is found where mechanical stress is greater. A good example of this type is the epithelium lining the stomach and intestine.

#### PSEUDOSTRATIFIED COLUMNAR

*Apparantly* more than one layer of cells, but in actuality only one layer exists. The predominant cell shape is columnar.

This epithelium should actually fall in the category of simple, because in fact all of the cells touch the basement membrane. However three unique factors contribute to the false (*pseudo*) impression that the epithelium is stratified:

- the cells are of different heights, not all of them reach the top surface
- the nuclei are at different levels rather than all lined up in a row
- the specimen is rarely cut perpendicular to the surface.

A key point that makes positive identification easy: all pseudostratified columnar epithelium that you will see in the lab also have cilia and goblet cells.

Pseudostratified columnar epithelium with cilia and goblet cells is restricted to the upper respiratory tract and is sometimes called *standard respiratory epithelium*. The goblet cells secrete mucus which serves to entrap particulate matter and the cilia move the stream of mucus toward the oral cavity.

## STRATIFIED EPITHELIA

Both stratified cuboidal and stratified columnar epithelia exist in the human body but they are rare and their distribution is erratic, so they will not be considered in this discussion.

### STRATIFIED SQUAMOUS EPITHELIUM

More than one layer of cells, the cells on the free surface are squamous in shape.

Many layers of cells, the surface cells are squamous. (The cells of deeper layers are usually cuboidal or irregular in shape.) Stratified squamous epithelia are specialized for protection. The stratified arrangement is logical since no one cell is very strong, but layer piled on top of layer will give a strong result.

There are two forms:

- keratinized
- nonkeratinized

Keratinized epithelia are always found on dry surfaces, nonkeratinized epithelia are always found in wet areas.

In stratified squamous keratinized epithelia the cells in the middle strata manufacture the protein *keratin*. Keratin is a sticky horn-like protein material made by certain stratified epithelia. Keratin causes the cells in the upper layers of the epithelium to stick together even after they have lost their nuclei. These flake-like layers on the top surface of an epithelium make it impermeable to water, preventing dehydration and absorption of water.

On a practical level the best way to make the diagnosis between keratinized and nonkeratinized stratified squamous epithelia is to look for nuclei in the top layers of cells. If nuclei are present the cells are living, and the epithelium is nonkeratinized. If nuclei are absent the cells are nonliving and the epithelium is of the keratinized type.

Stratified squamous keratinized epithelium is typical of the epidermis (outer layer of the skin) and is found on the dry surfaces of the body.

Nonkeratinized stratified squamous epithelia are found in areas that are subject to mechanical abrasion but not to dehydration. Such areas include the lining of the mouth, esophagus, anus, and vagina.

### TRANSITIONAL EPITHELIUM

More than one layer of cells. The cells on the free surface are sometimes squamous and sometimes not.

Transitional epithelium is of the stratified type in that it contains many layers of cells. The top layer of cells sometimes appears squamous and sometimes appears cuboidal (with a dome shaped free surface) depending on degree of stretch.

This type of epithelium is found only in the urinary bladder and is specially adapted for stretching.

## SUMMARY OF FUNCTIONS OF EPITHELIA

FUNCTION	EPITHELIAL TYPE
<b>Protection against</b> <ul style="list-style-type: none"> <li>• mechanical/chemical insult</li> <li>• stretching</li> <li>• dehydration (weathering)</li> </ul> <b>stratified squamous keratinized</b>	<b>Stratified Epithelia</b> <i>stratified squamous</i> , both keratinized and nonkeratinized (epidermis, mouth, esophagus, vagina, and anus)  <i>transitional</i> epithelium of bladder  epithelium of the <i>epidermis</i>
<b>Ciliary Transport of mucus and particulate matter along membrane surfaces:</b>	<b>Ciliated Epithelia</b> ciliated pseudostratified columnar (respiratory tract) and ciliated simple columnar (oviducts & ductus deferens).
<b>Secretion, both synthesis and release of products</b>	<b>Simple Cuboidal Epithelia</b> of glands, both exocrine and endocrine
<b>Diffusion and Filtration of gases, nutrients, and waste products.</b>	<b>Simple Squamous Epithelia</b> lining of blood vessels, lung alveoli and renal (Bowman's) capsule of kidney
<b>Absorption of nutrients and Reabsorption of renal filtrates</b>	<b>Simple Columnar of gut</b> <b>Simple Cuboidal of kidney tubules</b>
<b>Lubrication</b> <ul style="list-style-type: none"> <li>• secretion of serous fluid</li> <li>• secretion of mucus lubricant</li> </ul>	<b>Simple Squamous mesothelium</b> <b>Simple Columnar of gut</b> <b>Pseudostratified (goblet Cells) of respiratory tract</b>
<b>Sensory reception</b>	<b>Modified Epithelia of taste buds, olfactory epithelia, and inner ear</b>
<b>Reproduction</b>	<b>Gametogenic epithelia of ovary/testis</b>

# GLANDS

## INTRODUCTION

### SECRETION VS EXCRETION

An epithelial cell may synthesize materials which are not used directly by that same cell, but instead are expelled from the cell into the blood or onto the body surfaces. This process is called glandular activity, or secretion. Secretion differs from excretion by the nature of the expelled product. If the product is useful to the organism the process is called secretion. Excretion implies removal of waste products that are potentially toxic to the organism, or removal of excesses of useful products.

### UNICELLULAR VS MULTICELLULAR

Glands may be either unicellular or multicellular. The most familiar unicellular gland is the *goblet cell*, a columnar epithelial cell specialized for the production of mucus. Goblet cells are an important part of the simple columnar epithelium of the intestinal tract, and also of the pseudostratified columnar epithelium of the respiratory tree. Multicellular glands are an aggregation of cells specialized for secretion. Multicellular glands are always derived embryologically from simple cuboidal epithelial membranes.

## EMBRYOLOGY

Figure 3 shows the embryologic development of a gland. In Fig. 3-A, a simple cuboidal epithelial membrane is resting upon a layer of connective tissue containing an embryonic blood capillary. From the basal surface of the epithelium a cord of cells is pushing down into the connective tissue. The cells of this cord are produced by the mitotic activity of cells in the epithelium.

In Fig. 3-B continued mitotic division has produced a large number of cells organized into a long cord projecting deeply into the connective tissue. At this time the cord is a solid mass of cells. From this point on the

gland precursor may develop in either of two directions, exocrine or endocrine.

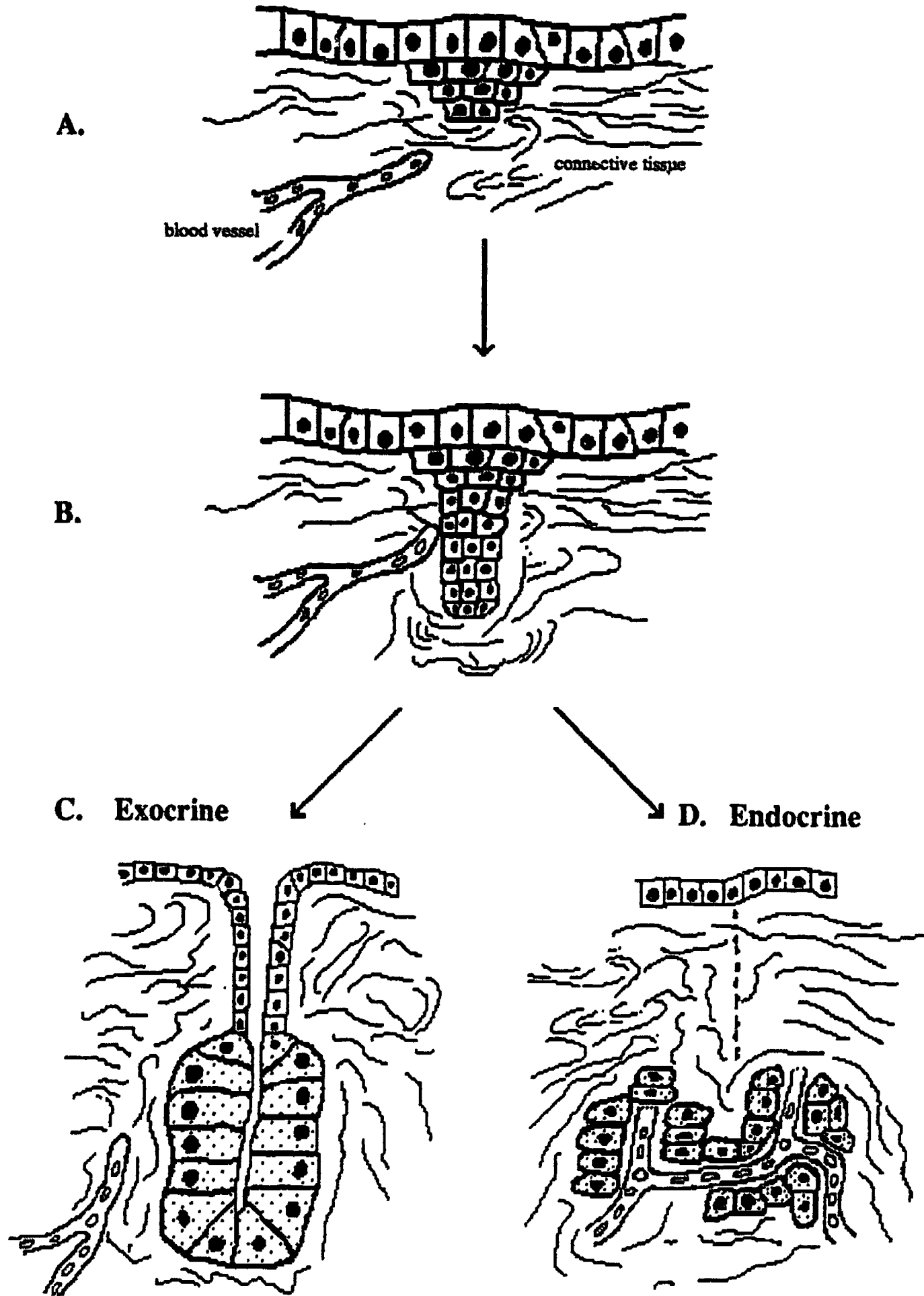
### EXOCRINE GLANDS

Fig. 3-C shows an *exocrine* gland. The superficial end of the cord of cells has hollowed out to form a *duct* connecting to the surface. The deeper end of the cord has formed an aggregate of secretory cells each of which opens on to the duct. This aggregate is called the *secretory unit*. The secretion of an exocrine gland is conveyed to the surface of the epithelium by way of its duct.

### ENDOCRINE GLANDS

Fig. 3-D shows an *endocrine* gland. Endocrine glands are ductless. The developing cord of epithelial cells completely loses its connection with the epithelial membrane from which it arose. This leaves the secretory unit isolated beneath the surface. As a result the cellular secretions are picked up by capillaries and transported throughout the body in the blood stream. The secretory product of an endocrine gland is referred to as a hormone.





**Fig. 3- Embryology of Glands**

## CLASSIFICATION

Glands are basically classified as either exocrine or endocrine. Exocrine glands are then further classified according to the structure of the duct and the shape of the secretory unit. Please refer to Figure 4.

### Duct Structure (See Fig. 4-A, B)

The duct may be either branched or unbranched. If the duct is branched the gland is classified as *compound*. If the duct is unbranched the gland is classified as *simple*.

### Secretory Unit Shape (Fig. 4-C, D)

The secretory unit may be either tube shaped or it may be rounded into a sac or flask shape. If it is tube shaped the gland is classed as *tubular*. If it is sac shaped the gland is classed as *alveolar* (a.k.a. *acinar*).

Some compound glands have secretory units of both shapes in which case it is described as a compound tubulo-alveolar gland. (Fig. 4-E).

In some simple glands the tubular secretory unit may be coiled, in which case it is described as a simple coiled tubular gland.

## SECRETION METHODS

Glands, whether exocrine or endocrine, are sometimes further described according to the method by which they discharge secretory products from the cells.

### HOLOCRINE

In the holocrine method secretion products accumulate throughout the whole cell and are not released until the cell dies and disintegrates. This type of secretion is always accompanied by large amounts of cellular debris. The sebaceous (oil secreting) glands are of this type.

### MEROCRINE

In the merocrine method the secretion droplet is enveloped in membranes which wall it off from the cell cytoplasm. These vacuoles continuously make their way to the surface of the cell where the membrane of

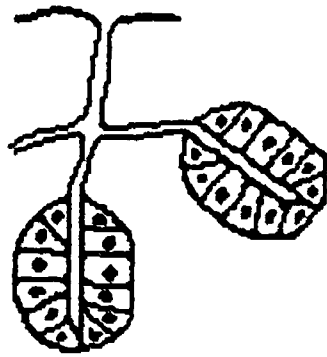
the vacuole fuses with the outer cell membrane and the product is discharged to the outside of the cell with no loss of cytoplasm.

The merocrine method is the most common method of secretion. Almost all glands are of the merocrine type. Some examples include: the ordinary sweat glands of the skin, and all of the glands which produce digestive enzymes, including the salivary glands, and the pancreas.

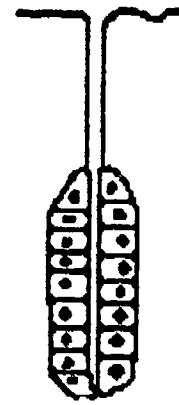
### APOCRINE

The apocrine method is intermediate between the other two methods. The secretion droplets accumulate in the apex of the cell until the membranes in this region pinch the tip off from the main cell. There is a moderate amount of cellular debris accompanying this method.


The mammary glands and the sweat glands of the axilla use this method. Axillary body odor is the result of bacterial action on the resultant cellular debris.



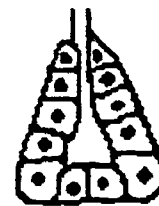
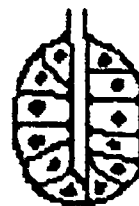**A. Compound Duct**



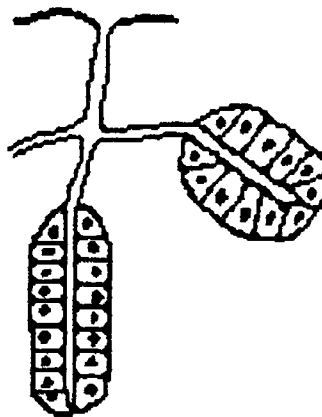
**B. Simple Duct**



**C. Tubular Secretory Unit**



**D. Alveolar (Acinar) Secretory Unit**



**E. Compound Tubulo-alveolar Gland**

**Fig. 4- Classification of Exocrine Glands**

# CONNECTIVE TISSUE

## INTRODUCTION

Connective tissue serves to connect, support, and bind together the body tissues, while at the same time providing flexibility, elasticity, and in some cases lubrication. All the epithelial tissues are supported from underneath by a layer of connective tissue (the *lamina propria*). Every single muscle cell, every peripheral nerve cell, and every blood vessel, is ensheathed with connective tissue.

Embryonic connective tissue is called *mesenchyme*. It has a mushy consistency, and the cells are *multipotential* (a.k.a. *pluripotential*), i.e. capable of developing into many or perhaps all of the more specialized or differentiated cells of connective tissue.

## COMPONENT PARTS

The three basic components of connective tissue are :

- *cells*
- *fibers*
- *matrix* (ground substance)

Fibers and matrix are extracellular products of the living cells. The ratio of cells to fibers, and/or the density of the matrix determines the various connective tissue types. For example, blood has a fluid matrix with many cells and no solid fibers (unless clotted). Bone has a solid matrix, few cells, and many fibers.

There are three different fiber types, two basic types of matrix, and numerous different cell types. The cells and fibers can be easily observed under the light microscope. Matrix on the other hand usually appears to be amorphous (without form or structure).

## FIBER TYPES:

### COLLAGEN FIBERS:

Collagen fibers are also known as "white fibers" because in gross anatomy masses of

these fibers have a white color. Each fiber appears to be quite broad when seen under the compound light microscope, but when examined with the electron microscope each is seen to be composed of small subunits called protofibrils. The protofibrils aggregate in bundles to form fibrils, and the fibrils in turn aggregate into bundles known as fibers. It is these latter that we see with the light microscope. The width of the fiber depends on the number of fibrils in the fiber. If the fiber appears to branch it is because sometimes the fibrils separate from the main mass of fibers.

Collagen fibers are known for their great tensile strength. When the tension exceeds fiber strength the fiber breaks and frays, much like the end of a frayed rope.

Collagen is a protein. One third of the protein of the body is said to be collagen. Collagen can be readily dissolved in dilute acid or by boiling in water. Dissolved collagen can reaggregate spontaneously into fibers when the conditions of temperature and pH are suitable, and presumably this is what happens in vivo. Dissolved collagen is a familiar glue.

### RETICULAR FIBERS:

The protein reticulin is very similar to collagen in all ways except aggregation. Some scientists consider reticular fibers to be immature collagen fibers, and like collagen fibers they are compound fibers, though much smaller. They branch and anastomose to form a delicate network around fat cells, gland cells, and in the basement membrane under epithelia. They are *argyrophilic*, but are difficult to stain with any other method, and thus will not be seen in ordinary slide preparations.

### ELASTIC FIBERS:

Elastin is a stringy protein that has the ability to stretch and recoil back into its



original size and position. Consequently elastic fibers are found where elasticity is needed, such as in the skin. They are also found in the walls of arteries where their ability to stretch is important since arteries dilate or pulse with each heart beat and the elastic recoil of the artery helps to keep the blood moving. Elastic fibers can be stretched to approximately 150% of their resting length before breaking. Masses of elastic fibers are yellow in color when seen in gross anatomy. When seen under the microscope they are not compound. They appear as dark, narrow, thread like strands.

### **MATRIX TYPES:**

The matrix or "ground substance" of all animal cells can also be thought of as intercellular glue. Chemically the matrix is a carbohydrate-protein complex that behaves physically as a sol-gel. A sol-gel exhibits the properties of both a fluid and a solid. Temperature, pH, and water content are the main determinants of the sol-gel state. For example, gelatin mixed with warm water is a sol; when allowed to cool it "sets" or becomes a gel. There are two basic varieties of matrix material:

#### **HYALURONIC ACID**

Hyaluronic acid is a soft jellylike amorphous viscous substance. Chemically it is a high molecular weight polysaccharide combined with protein. While binding cells together it nevertheless permits flexibility. The viscosity of hyaluronic acid varies, partly depending on the amount of calcium present.

A familiar example of almost pure hyaluronic acid is the mass of jelly that frog eggs are imbedded in when you find them in ponds and quiet streams. Mammalian eggs (including human eggs) are also surrounded by a thick coating of this same jelly material. Human sperm cells each carry a small packet of the enzyme hyaluronidase, a multitude of sperm cells being necessary to dissolve away enough of the hyaluronic acid to permit one sperm cell to penetrate and

fertilize the egg. Some particularly virulent bacteria also possess this enzyme, permitting them to dissolve away the intercellular glue and spread rapidly in the tissue of an infected animal.

Hyaluronic acid is also found in the aqueous and the vitreous humor of the eye and in the synovial fluid of joints. In these places it contributes the properties of lubrication, water retention, and shock absorption. Water retention is important in the eye in order to keep the internal pressures of the eye high, which in turn maintains the shape of the cornea, and holds the retina smoothly against the back wall of the eye.

#### **CHONDROITIN SULFATE**

Chondroitin Sulfate is also a polysaccharide-protein combination but differs from hyaluronic acid chiefly in that it contains more sulfur than does hyaluronic acid. Because of its high sulfur content, chondroitin sulfate contains numerous disulfide (sulfur to sulfur) bonds. These very strong chemical bonds produce a firmer gel, providing more shape and form, while still retaining flexibility and elasticity. The most familiar example of chondroitin sulfate is cartilage (gristle). The crystalline lens of the eye is also made of this material.

### **CELL TYPES:**

The cells of connective tissue are generally divisible into two populations, fixed and wandering. Cells of the fixed population are permanent residents of the connective tissue. Those of the wandering population move between the circulatory system and the connective tissue. The wandering cells are probably relatively inactive while circulating, and become active in the connective tissue. All white blood cells belong to the wandering population, and they will be considered in the lecture on blood. Only the fixed population of cells will be considered here.

#### **FIBROBLASTS /FIBROCYTES**

The ending "blast" indicates an active, generative or formative cell. The ending

"cyte" indicates an inactive or resting state of the same cell. Fibroblasts produce the intercellular (extracellular) substances of connective tissue, namely the fibers and matrix material. These products are formed inside the cells and then extruded into the extracellular space. Fibroblasts/fibrocytes are the most numerous cells seen in slides of loose areolar connective tissue, and they are the only cells seen in tendons and ligaments. Seen in side view they are long spindle shaped cells with fuseform (cigar shaped) nuclei; seen from a top view the cytoplasm (if it can be seen at all) will appear star shaped (stellate). However, most often only the small dark compact nucleus is visible.

#### **FAT CELLS (SIGNET RING CELLS):**

Some regions of the body are predominantly fat cells in which case this tissue is called adipose tissue. Young fat cells look much the same as fibroblasts. In intermediate stages the cell cytoplasm contains numerous small droplets of fat. Later these droplets coalesce to form a large central vacuole of liquid fat. The fat vacuole pushes the nucleus and cytoplasm to the periphery of the cell leaving the clear vacuole in the center of the cell; the stained cell thus takes on the appearance of a signet ring. The name arose because in the routine technology of slide preparation the thinly sliced tissue is treated with fat solvents (xylene) before staining, and the solvent effectively empties the storage vacuole. Early anatomists did not immediately guess the function of these strange empty looking cells.

One excellent place to see young healthy looking fat cells under the microscope is on a slide of a cross section of small blood vessels and nerves. Fat cells can always be found serving as packing material around these structures.

#### **MAST CELLS (TISSUE BASOPHILS):**

Mast cells are widely distributed in connective tissue and are found in greatly increased numbers in inflamed tissues. Their cytoplasm is heavily laden with large granules

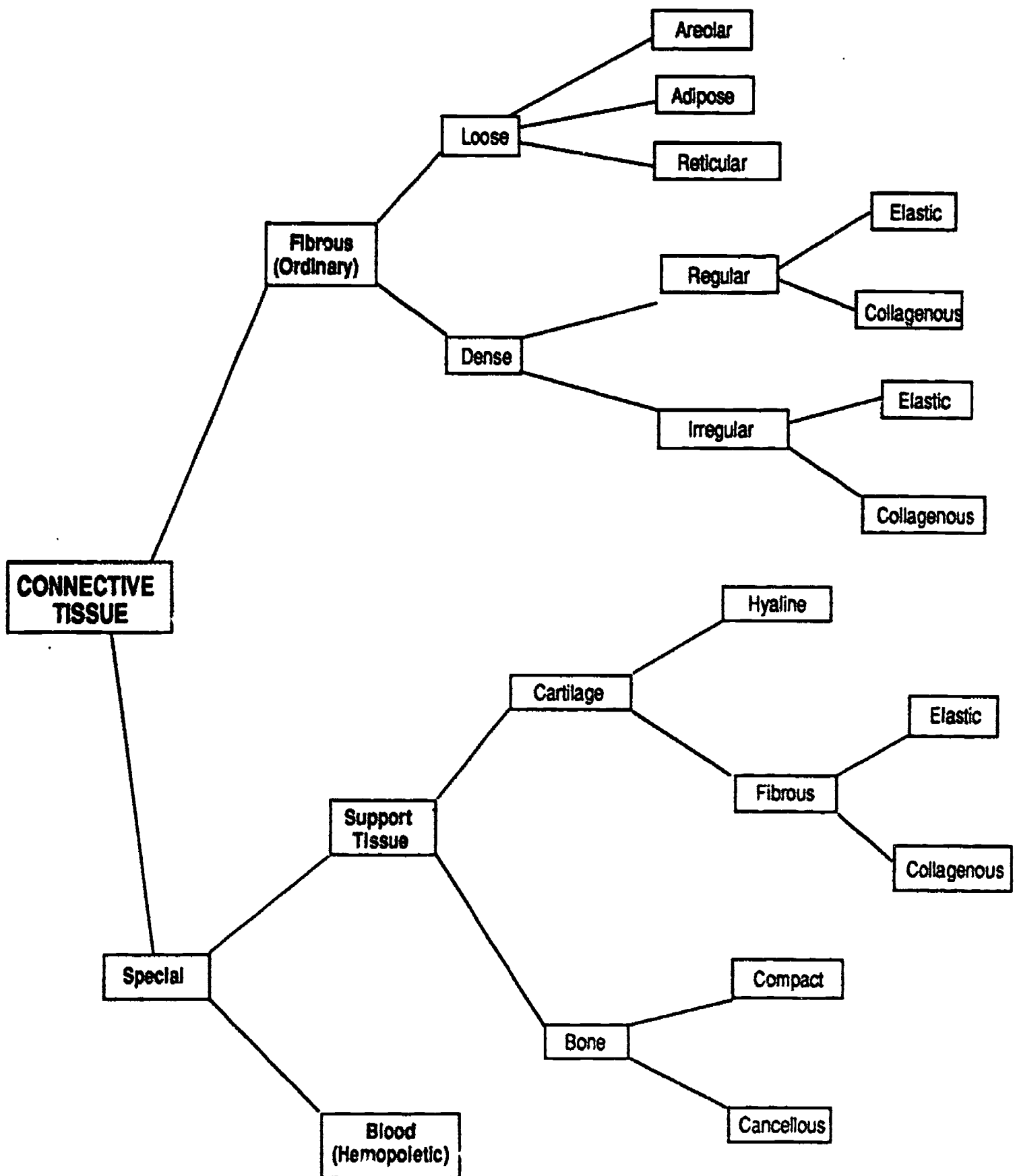
which have an affinity for stains with a basic (alkaline) pH. These granules are known to contain *heparin* and *histamine*. Heparin is an anticoagulant and helps to dissolve small blood clots and prevent new ones from forming in slow moving veins and capillaries. Basophils and mast cells are thought to secrete heparin continuously. Histamine is involved in tissue inflammation and allergic reactions, and is only released when the mast cell is damaged.

#### **FIXED MACROPHAGES (HISTIOCYTES)**

You will not be expected to identify macrophages since to do so would require special tissue preparations that are not available.

These cells belong to a system of cells of similar function scattered throughout the body. This system is technically known as the reticuloendothelial system; you may find it useful to think of the RE system as the immune system.

Macrophages exhibit active ameboid movement and phagocytic activity. *In vivo* they ingest foreign particles such as bacteria and dust particles, and naturally occurring particulate matter such as dead cells. In slide preparations they can be positively identified only if made to ingest particulate matter before fixation and staining.



**Fig. 5- Classification of Connective Tissue**

# CLASSIFICATION

The classification of connective tissue is inconsistent from one author to another. The scheme of classification used in this course is to divide the connective tissues into two main groups, ordinary and special. The special connective tissues include bone, cartilage, and blood, each of which will be considered separately. All connective tissue other than bone, cartilage, and blood is classed as ordinary or fibrous connective tissue. Examples of fibrous connective tissue include: tendons, ligaments, fascia, aponeuroses, dermis and hypodermis of the skin, lamina propria and submucosa of epithelial membranes, adipose tissue, etc.

Classification of the various fibrous connective tissues is based on:

- the density of fibers (loose and dense)
- the physical alignment of the fibers (regular or irregular).
- the predominant fiber type (collagenous, elastic, reticular)
- the cell types

Classification of the special connective tissues is based on:

- the density and type of matrix
- the density and type of fibers.

## LOOSE FIBROUS TYPES

In loose connective tissue the fibers are loosely and randomly scattered through the matrix, and as a consequence, there are large spaces between the fibers, occupied by many different kinds of connective tissue cells, capable of performing a wide variety of functions.

### AREOLAR

Loose connective tissue is best typified by *areolar* connective tissue. Areolar connective tissue is the most widespread form of connective tissue encountered in the human body. In dissection it appears as a whitish cobwebby material.

### ADIPOSE

A second type of loose connective tissue is

known as adipose tissue because of the predominance of fat cells. Adipose tissue is not a typical form of connective tissue because cells rather than fibers are its predominant feature. Large masses of adipose tissue are found around organs such as the kidneys, adrenal glands, and heart. A layer of adipose tissue beneath the skin is responsible for the smooth contours of the body.

### RETICULAR

Reticular connective tissue forms the framework for all glands, for example the liver, spleen, and lymph nodes. It is also found in the bone marrow cavities. Reticular tissue consists of a delicate meshwork of fine branching fibers to which are attached fixed macrophages (cells of the immune system). The open spaces of the network are filled in with cells of the organ which it serves as a framework.

## DENSE FIBROUS TYPES

In dense connective tissue the fibers are closely packed together; there is little space between the fibers, and thus there are few cell types present other than fibrocytes, which are responsible for production of the fibers. The density of the fibers gives great mechanical resistance to these types. Dense connective tissue is further divided into two subcategories, regular and irregular.

### REGULAR AND IRREGULAR:

In this context, *regular* means that the fibers are arranged parallel to one another, and *irregular* means that the fibers cross one another forming a meshwork type. The regular types are generally subjected to forces along one axis, so the fibers are arranged in an orderly parallel manner in the direction of the stress. The irregular types are found in areas where the mechanical forces are likely to come from several directions.

Tendons and ligaments are examples of dense *regular* connective tissue. The aponeuroses and the fascia lata of the thigh are



examples of dense *irregular* connective tissues.

#### **COLLAGENOUS AND ELASTIC:**

The dense regular and irregular connective tissues are further subdivided into collagenous or elastic depending on the predominant fiber type. Tendon, ligaments and aponeuroses are dense *collagenous* connective tissues, because the primary fiber type is collagen. The ligamenta flava (yellow ligaments) of the vertebral column, the vocal cords, and the suspensory ligament of the penis are examples of dense *elastic* connective tissues.

#### **AGING:**

It now seems apparent that the process of aging is in large part related to changes in the connective tissue cells. All of us are familiar with some of these changes: stiffening of the joints, loss of elasticity of the skin, hardening of the arteries. There is much that we don't know, but we at least know that with aging comes an increase in the amount and thickness of the collagen fibers. We also know that the elastic fibers become thicker and less springy. In fact, all of the extracellular substances produced by connective tissue cells, which are so necessary to the organization of living systems, continue to be formed every day of our lives, even after mature growth has been reached.

Acquiring multicellularity through the adhesiveness of cells means that aging is simultaneously introduced into the life history of the organism as an inevitable consequence of embryology. Single celled organisms are potentially immortal.

Thus, aging can be viewed (in part) as an aspect of development that has gone beyond the optimal needs of the organism for proper functioning.

# Support Tissue

## CARTILAGE

Active formation of cartilage is done by *chondroblasts* which secrete matrix material around themselves. Once the cell has "painted itself into a corner" it enters a resting phase and is called a *chondrocyte*.

Chondrocytes reside in small spaces called *lacunae* that they have left for themselves in the matrix. There are no special arrangements for delivery of nutrients or removal of waste products.

Cartilage is *avascular*. No blood vessels can penetrate into cartilage due to a chemical inhibitor in the matrix. Cartilage cells are kept alive by diffusion to and from the blood vessels of the perichondrium. As a result the thickness to which a piece of cartilage can grow is limited.

Cartilage is classified as hyaline if it is without visible fibers, or fibrous if the fibers are conspicuous. Fibrous cartilage is subclassified depending on the type of fibers present.

### HYALINE CARTILAGE

Hyaline cartilage has a glassy smooth texture that gives it its name. Hyaline cartilage is found:

- in embryonic pre-bones
- covering the ends of bones at moveable joints (articular cartilage)
- at the ends of the ribs where they attach to the sternum
- in the nasal cartilage, part of the nasal septum
- in the tracheal rings and plates of cartilage in the larger bronchial tubes.

### ELASTIC CARTILAGE

Elastic cartilage is hyaline cartilage with the addition of many elastic fibers. It is found in the pinna of the external ear, in the epiglottis of the larynx, and in the Eustachian tube of the middle ear.

### WHITE FIBROCARILAGE

White fibrocartilage is hyaline cartilage with the addition of many collagenous fibers. It is effective as a shock absorber and is stronger than hyaline cartilage. It is found in the pubic symphysis, in the intervertebral discs, and in the menisci of the knee joint.

## BONE

Bone differs from cartilage in that it is a *highly vascular* tissue in which no bone cell is more than 0.1 mm away from a blood capillary. The organic matrix of bone tissue is called *osteoid tissue*, and it is produced by osteoblasts. When it is first produced osteoid tissue is rubbery in consistency; later, minerals are added to convert it to the dense rigid material we think of as bone.

### CANCELLOUS / COMPACT BONE

In cancellous bone the matrix is laid down as a meshwork of spicules; the spaces between the spicules are occupied by bone marrow. Cancellous bone is not a weight bearing tissue.

In compact bone the matrix is laid down in *concentric lamellae* (layers) around small blood vessels or capillaries. The microscopic organizational unit of compact bone is called the *haversian system*. In three dimensions the haversian system has a long cylindrical shape with an *haversian canal* at its center. The haversian canal is occupied by a small blood vessel. The *interstices* between the haversian systems are filled in by *interstitial lamellae*. Active *osteoblasts* become resting *osteocytes* once they are surrounded on all sides by matrix material. The space in which an osteocyte resides is called a *lacuna*. The intercellular substance of bone is permeated with *canaliculi* (tiny canals) that connect neighboring lacunae. This arrangement serves as a transport line between capillaries and bone cells, for efficient delivery of nutrients and removal of waste products.

# BLOOD

Blood is a modified connective tissue, and as such is composed of **matrix, fibers, and cells**. The matrix of blood is unique in that it is a liquid. The fibers are unique in that they are usually in the dissolved state. Circulating blood volume can be estimated by taking 8% of the body weight expressed in kilograms. Thus a 70 Kg person (150 pounds) would have about 5.5 Liters of blood. Of this 5.5 L, about 55% or 3L is plasma.

The liquid matrix of blood is called either *plasma* or *serum*. Plasma is the liquid phase of unclotted (whole) blood, and serum is the liquid left over after blood clots. Plasma and serum are largely water containing dissolved proteins, and electrolytes. The important proteins include: Prothrombin, Fibrinogen, Albumin, Gamma Globulin, other Globulins. The important electrolytes include:  $\text{Na}^+$ ,  $\text{Cl}^-$ ,  $\text{Ca}^{++}$ ,  $\text{HCO}_3^-$

## HEMOPOIESIS

There are two types of hemopoietic (blood forming) tissue, myeloid and lymphoid.

In the fetus the liver and spleen are both actively hemopoietic, but after birth the most important myeloid tissue is red bone marrow. In children red bone marrow is found in the cancellous interior of all bones, but in adults it is found only in the sternum, ribs, vertebral bodies, cranial bones, crest of the ilium, and the proximal ends of the humerus and femur. Myeloid tissue produces thrombocytes, erythrocytes, neutrophils, eosinophils, basophils, and monocytes.

Lymphoid tissue is found in the thymus, lymph nodes, tonsils, Peyer's patches, and the spleen. Lymphoid tissue produces the white blood cells known as lymphocytes.

## HEMOSTASIS

The technical term for the various natural mechanisms of the body which help to control bleeding is *hemostasis*. The most important of the hemostasis mechanisms is blood clotting. The *clotting reaction* or *cascade reaction* is a chain of events that can be summarized and simplified into three main steps.

*Platelet factor* a protein contained inside the *thrombocytes*, must mix with the plasma in order to initiate the clotting reaction. This platelet factor is released from the platelets when they are bruised, injured or exposed to connective tissue.

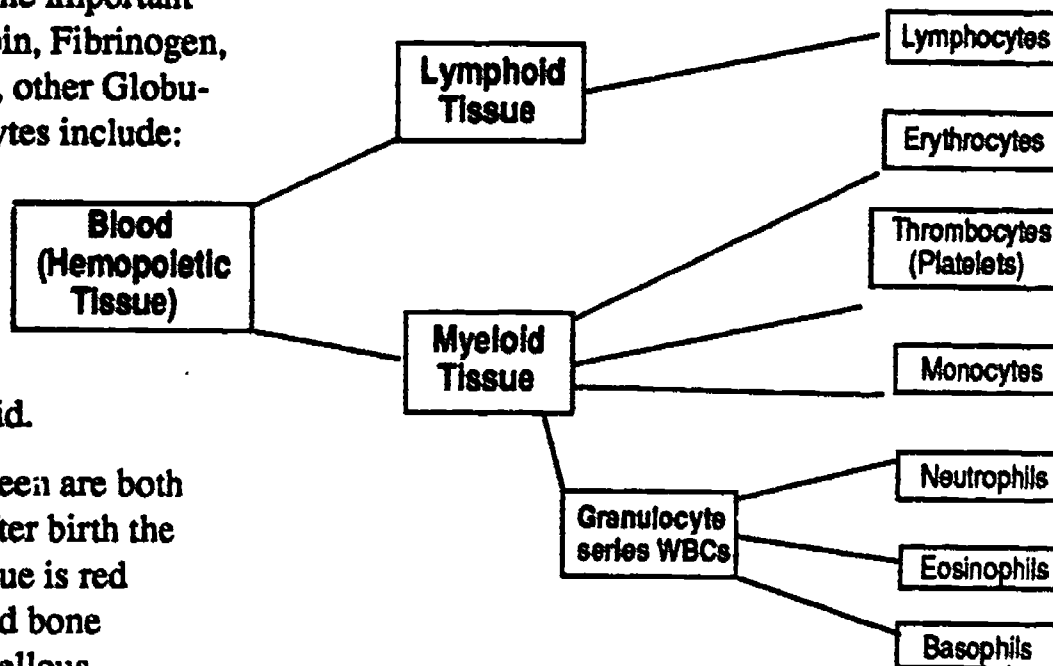
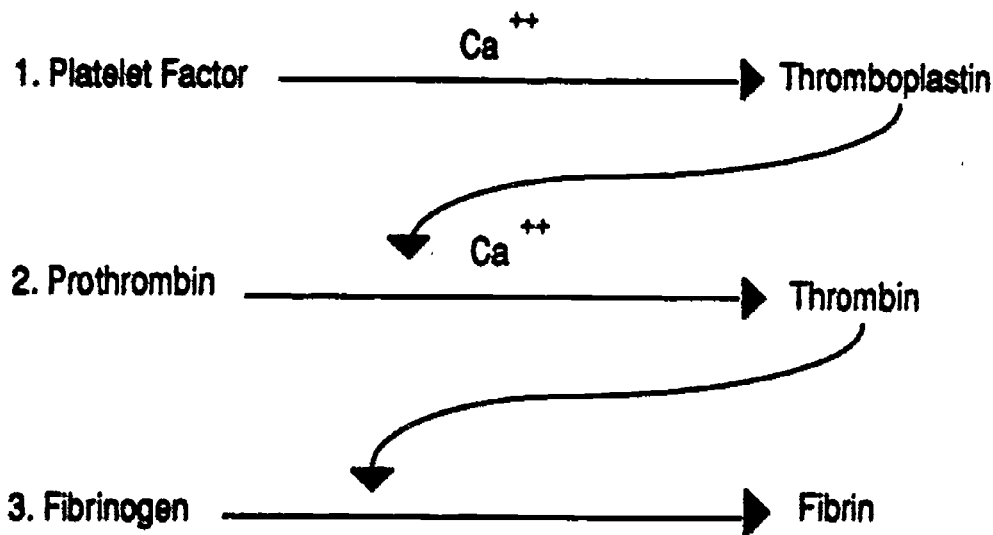


Fig. 6- Embryology & Classification of Blood Cells

*Prothrombin* and *fibrinogen* are both liquid proteins components of blood plasma. *Fibrin* is a solid protein derived from fibrinogen which forms during the clotting reaction. The fibrin precipitates out of solution in the form of long sticky strands which form a meshwork that traps all of the cells and pulls them out of suspension. This is the clot.



**Fig. 7- Three Step Clotting Reaction**

**Calcium ions** ( $Ca^{++}$ ) are also very necessary to the clotting reaction, and in fact clotting can be prevented by chemicals which bind with the calcium ions making them unavailable. Chemicals which prevent blood clotting are called *anticoagulants*. Some common anticoagulants which act by binding calcium are Heparin, Sodium Citrate, and Lithium oxilate.

**Platelets** (*thrombocytes*) are not true cells, rather they are fragments of *megakaryocyte* cells found in the bone marrow. There are about 300,000 per microliter of blood, and their half life is 4 days.

## BLOOD CELL COUNTS

A complete blood count (CBC) includes a red blood cell (RBC) count and a white blood cell (WBC) count. A measured sample of the blood is diluted in a known volume of fluid, and the number of cells is counted either by hand or by machine.

A normal RBC count is in the range of 4.5 to 5.5 million cells per microliter of blood. The number will vary depending on such factors as age, gender, pregnancy, aerobic exercise and altitude. Children have a lower count than adults, women usually have a lower count than men, pregnant women have a lower count than non pregnant women. Regular aerobic exercise will increase the number of RBCs, as will living in a high altitude environment.

A normal WBC count is in the range between 5,000 to 8,000 cells per microliter of blood. It will go up during bacterial infections and down if the bone marrow is damaged.

## HEMATOCRITS

Determination of the hematocrite level (*packed cell volume*), is a quick way to determine the red blood cell *content* of whole blood without doing a blood cell count. Whole

blood is treated with an anticoagulant and a sample is then centrifuged so that all of the cells in the sample are packed into the bottom of the container. Plasma normally occupies 55% of the total blood volume, and the cells packed into the bottom of the tube normally occupy 45% of the volume (normal range 42-47%). The number of white cells is so small compared to the number of red cells that the volume of white cells, seen as a thin buff colored layer on top of the red cells, is virtually non measurable, and is called the *buffy coat*.

## DIFFERENTIALS

A differential is not a blood count, rather it is a morphological study of the blood cells, including a determination of the relative percentages of the five or so different types of white blood cells. A stained blood smear is examined microscopically. As each white blood cell comes into view a decision is made as to what kind of white cell it is. A tally is kept, and after roughly 100 cells have been examined and tallied the results are expressed as percentages.

### NORMAL DIFFERENTIAL:

Neutrophils:	60 - 70 %
Lymphocytes:	20 - 35 %
Monocytes:	3 - 8%
Eosinophils:	1 - 5%
Basophils:	0.3 - 0.5%



White cell morphology and functions will be discussed below.

## ERYTHROCYTES

### MORPHOLOGY & FUNCTION

Circulating red blood cells are not true cells since they do not have a nucleus. In recognition of this they are sometimes called red blood corpuscles. Each RBC is a membrane bound sac that is loosely filled with hemoglobin.

The average diameter of an RBC is 7.5 *microns*, with a thickness of 2 microns. The smallest capillaries are narrower than that. The loose nature of this sac and the fluid nature of the hemoglobin inside allow the cell to deform in order to squeeze through narrow capillaries and around sharp turns inside the circulatory system.

The corpuscle is in the shape of a biconcave disk. The thin center area was probably the area occupied by the nucleus during the time in the cell's life cycle when it had a nucleus.

When the red blood cell is first formed it has a nucleus, but during the maturation phase, while the cell is still in the bone marrow, it gradually loses its nucleus, and the interior of the cell is then fully occupied by hemoglobin. *Erythropoietin*, a hormone made by the kidney, stimulates faster production of RBCs. Erythropoietin is released when *hypoxia* (low blood oxygen) occurs, as it might in a person who lives at high altitude or a person who is doing regular heavy physical activity, or in a person who is anemic or after severe blood loss (hemorrhage).

### PHAGOCYTOSIS OF RBCs

Once the RBC enters the peripheral circulation it has a life span of about 120 days, after which time the membrane begins to break down. The worn out RBCs are phagocytized in the spleen, liver, and red bone marrow.

## HEMOGLOBIN

Hemoglobin is a conjugated protein. It consists of the protein *globin* and four molecules of the pigment *heme*. Each molecule of heme contains an iron molecule at its center. The iron is responsible for the red color of the blood. Oxygenated heme is bright scarlet red, deoxygenated heme is a darker maroon red. Some animals use copper instead of iron in their blood pigments, and in these animals the color of the blood is green.

Hemoglobin has a reversible affinity for oxygen, depending largely on concentration of oxygen in the area. Because of this property hemoglobin is the perfect agent for the transport of oxygen in the body. It takes up oxygen in the lungs and transports it to the tissues where it is released.

When an RBC is phagocytized the hemoglobin is disassembled. The iron is removed and stored and then recycled for making new hemoglobin. The rest of the hemoglobin molecule is converted to bile pigments which are used for fat emulsification in the digestive system.

## ANEMIA

Anemia is any deficiency in hemoglobin, from whatever cause. The correlation with RBC number is not absolute. A person with anemia might have a decreased number of RBCs, but they might also have a normal number of RBCs in which each one is of reduced size, or each RBC may be filled with less than the normal amount of hemoglobin.

### IRON DEFICIENCY ANEMIA

This type of anemia is also called simple anemia. It is due to lack of adequate iron intake in the diet. Iron is required to make the heme molecule. Good sources of iron include meat and fish, and especially liver, and also dark green leafy vegetables such as spinach.

### **PERNICIOUS ANEMIA:**

This type of anemia is due to the inability to make RBCs, usually due to lack of production of **intrinsic factor** by the stomach epithelium. Intrinsic factor is needed for absorption of vitamin B<sub>12</sub>, which in turn is needed to complete the maturation of RBCs.

### **SICKLE CELL ANEMIA:**

Sickle cell anemia is due to an inequitable abnormal gene for hemoglobin production. The genetic trait is recessive and will not be expressed unless the person has inherited two copies of the abnormal gene, one from the father and one from the mother. This state is called the homozygous state in contrast to the heterozygous state in which the person has inherited one abnormal copy and one normal copy.

A person with the heterozygous condition will be a carrier of the abnormal gene but will not usually experience any deleterious medical effects, except under conditions of extremely prolonged and strenuous physical exertion such as one might encounter in the armed services boot camps.

If homozygous, the person is subject to periodic debilitating sickle cell crises triggered by activities which demand high oxygen consumption. The abnormal hemoglobin becomes rigid and distorted, at low oxygen tensions, and the RBC is stretched into the so called sickle shape. The cell membrane of sickled cells is sticky and the cells are fragile. During a sickling crisis small capillaries become clogged due to clumping of cells and inability of cells to turn corners and squeeze thru narrow channels. In addition many of the fragile cells hemolyze (lyse, burst) spilling the hemoglobin into the plasma (where it is non-functional).

## **LEUKOCYTES**

### **MORPHOLOGY & FUNCTION**

Five types of white blood cells can be distinguished from one another under the light microscope. These five are commonly

classified into two groups known as the "granulocytic series" and the "monocytic series". These groupings are based on simple visible morphological differences. The term "monocytic series" can be confusing since it includes both the monocyte cell line and the lymphocyte cell line, one of which comes from myeloid tissue, and the other of which comes from lymphoid tissue.

### **GRANULOCYTIC SERIES**

Granulocytes all have granules in the cytoplasm of the cell. The color, texture, and size of the granules is different for the three subcategories of the granulocyte series, and these differences are important to the correct identification of the cell type. The nucleus of all mature granulocyte cells is multilobed, most typically three lobed.

#### **NEUTROPHILS**

The Neutrophil is also called a *Poly* or *PMN* (short for *polymorphonuclear leukocyte*). Neutrophils have granules which are of a very small size and fine texture. Most of the granules are very pale, and a dusty lavender color.

Neutrophils are the most numerous and short lived (6 hours) of all the white blood cells, and they function as very active phagocytes. 100 billion of them are produced every day. Their granules are lysosomes, containing enzymes which are used to kill and digest phagocytized bacteria. They are very mobile and are chemically attracted to the site of an infection. They are the first cells to arrive at an infection, and hence are the first line of defense. An accumulation of these cells at the infection site is called *pus*.

Mature cells typically have three lobed nuclei. The nucleus stands out very sharply in contrast to the pale dusty looking cytoplasm.

White blood cells normally remain in the bone marrow until they are mature. However, if the body is fighting a heavy infection the production of neutrophils is stepped

up, and immature forms (called *juveniles* and *band* or *stab* cells) may appear in the peripheral blood and be tallied in the differential. This condition is called a "*shift to the left*". The most visible feature of these immature cells is the nucleus. A juvenile cell has a single J shaped nucleus that is indented on one side. A stab or band cell has a narrower band shaped nucleus. As soon as lobulation is seen the cell is considered to be a mature neutrophil.

### **EOSINOPHILS**

The granules in eosinophils are very large, refractile, and rusty brown or red-orange in color. There are so many granules that they obscure the nucleus. The color of the granules is due to an affinity for the dye *eosin* which is present in the mixture of dyes used to stain the blood.

Eosinophils are associated with allergies and some parasitic infections. Eosinophil levels are elevated in both conditions. They apparently inactivate some of the chemicals released from connective tissue mast cells during allergic reactions, and they are known to attack some parasites.

### **BASOPHILS**

The granules in basophils are also very large, but they are nonrefractile, and are dark blue to black looking. The granules are clearly visible as separate from the nucleus. The color of the granules is due to an affinity for the basic *hematoxylin* dye which is present in the mixture of dyes used to stain blood smears.

Basophils are associated with chronic tissue and joint inflammations. The *granules contain histamine and heparin*, and it is suggested that this cell plays some role in the balance between clotting and nonclotting of blood.

### **MONOCYTIC SERIES**

Both of the cells in the monocytic series have single nuclei (not lobed). The cytoplasm of each is generally considered to be agranular (non granular).

### **MONOCYTES**

Monocytes are the largest of all the WBCs, usually about one and a half to two times the diameter of a RBC. The nucleus is large and loose or foamy looking. It is typically folded into a kidney bean shape. The agranular cytoplasm is abundant and has the appearance of frosted glass.

Monocytes are active phagocytes that are mobilized more slowly than neutrophils, and hence act as the so called second line of defense against bacterial infections, however they are able to ingest larger numbers of bacteria than are the neutrophils.

Monocytes probably secrete a factor which stimulates the release of neutrophils from the bone marrow.

Monocytes also have an important role to play in cellular immunity; in order for a dedicated T lymphocyte to proliferate, it must first come into physical contact with a macrophage that has ingested a foreign antigen.

Monocytes remain in the circulating blood for about 24 hours, after which time they migrate from the blood to the tissues where they have a half life of about 200 days. All tissue macrophages come from circulating monocytes.

### **LYMPHOCYTES**

Lymphocytes are the smallest of all of the WBCs, their diameter is usually just slightly larger than that of a RBC. The nucleus is round and very dark and compacted in appearance. The cytoplasm is often so scanty as to be almost non visible. If cytoplasm is visible it is agranular and clear sky blue in color. The so called "large lymphocytes" are probably younger versions of the smaller lymphocytes. These larger cells have more abundant cytoplasm, but the nuclear appearance is the same as for the more mature form.

Lymphocytes are central to the action of the immune system. Functionally they are



classified into two broad categories, T cells and B cells. These cannot be differentiated from one another visually.

Both types arise from multipotential precursor cells (stem cells) in the bone marrow. The precursor cells however lack the surface receptors that allow the B and T cells to recognize specific antigens. The surface receptors will appear as the daughter cells mature. Each maturing lymphocyte becomes programmed to recognize only one particular antigen by virtue of the fact that it develops multiple copies of one particular type of receptor.

The lymphocyte stem cells are constantly generating great numbers of new receptor types by an ongoing process of random genetic recombination.

B cells are responsible for humeral immunity and T cells are responsible for cellular immunity. B cells produce antibodies against foreign antigens such as bacteria and viruses. T cells (there are four subtypes) produce chemical agents (lymphokines) that cause rejection of foreign cells, as well as defense against tumors, fungi, and viruses.

## RELATED VOCABULARY

### **Erythrocytosis:**

increased number of RBCs. Erythrocytosis is a normal response to chronic low oxygen levels.

### **Leukocytosis:**

increased number of WBCs (above 10,000 cells per microliter of blood). Leukocytosis is the normal response to bacterial infection.

### **Leukopenia:**

decreased number of WBCs (below 5000 cell per microliter of blood). Leukopenia is characteristic of typhoid fever, tuberculosis, and radiation sickness.

### **Thrombocytopenia:**

decreased number of platelets

### **Leukemia:**

abnormal and rapid proliferation of WBCs. Cancer of the blood.

**Thrombus:** a stationary clot

**Embolus:** a moving clot

### **Thrombocytopenia purpura:**

insufficient numbers of platelets are being produced. Large numbers of purple bruises are one obvious sign of this condition.

### **Hemophilia:**

A genetic condition in which the patient can't form thromboplastin or some other necessary component of the clotting reaction. Bleeders.

### **Thrombophlebitis:**

inflammation of a vein which causes multiple clots to form. The danger is that the clots will become emboli.

# MUSCLE TISSUE

## DEFINITION OF TERMS

### ROOT WORDS

**myo** - Greek for muscle or meat

**sarco** - Greek for flesh (sarcasm means *to tear the flesh*)

### CONNECTIVE TISSUE WRAPPINGS

**epimysium** - around a muscle

**perimysium** - around a fascicle

**endomysium** - around a cell

### MUSCLE CELLS

**sarcolemma** - cell membrane

**sarcoplasm** - cytoplasm

**fiber** - single muscle cell

**fibrils** - subunits of a fiber

**filaments**

myosin and actin subunits of a fibril

**sarcomere**

functional sections of a fibril

**sarcoplasmic reticulum**

endoplasmic reticulum of a muscle cell.

The sacs of the sarcoplasmic reticulum

reversibly store and release calcium ions.

## SARCOMERE ANATOMY

### MYOFILAMENTS

The myofilaments actin and myosin interdigitate with one another. The myosin filaments occupy the center section of the sarcomere, the actin filaments occupy each end of the sarcomere.

### Actin

Actin filaments are found on the ends of the sarcomere. They are small in diameter and therefore the area they occupy is relatively non dense. Each actin filament is composed of long strands (molecules) of troponin and tropomyosin proteins wrapped around one another in a helix formation.

### Myosin

Myosin filaments are the thicker filaments found in the center of the sarcomere; be-

cause of their diameter the area that they occupy is relatively dense. Each filament of myosin has an enlargement or bulge at its center.

Each myosin filament is made up of many subunits known as myosin molecules. Each myosin molecule has an enlarged head which sticks out at the sides of the filament; these heads form the cross bridges that make contact with adjacent actin filaments during contraction

### Z LINE (OR Z BAND)

This structure is found at each end of the sarcomere; it marks the boundary between adjacent sarcomeres. The actin filaments of the sarcomere are attached to the Z line.

### T TUBULES

Microtubules that lie parallel to the Z line and reach up to the surface of the cell where they are continuous with the sarcolemma. These tubules bring the neurotransmitter chemical into the interior of the muscle cell.

### CROSS STRIATIONS

Actin filaments are smaller in diameter than myosin filaments, hence the end areas of the sarcomere (where only actin filaments are found) are less dense than the center area of the sarcomere where only myosin filaments are found. The less dense areas transmit more light (isotropic bands) than does the denser area (anisotropic band).

### I BANDS

There are two of these bands for each sarcomere, one next to each Z line. Each I band is an area of the sarcomere where only actin filaments are found. I stands for *isotropic* referring to a relative ability to transmit light. These bands are areas of low density where the actin filaments do not overlap with the myosin filaments. They appear as light striations relative to the A band in the center of the sarcomere.

### **A BAND**

A stands for *anisotropic*, referring to a relative inability to transmit light. The A band is the area in the center of each sarcomere corresponding to the actual length of the group of myosin filaments. The area is of high density and therefore anisotropic, so it appears as a dark striation relative to the I bands on either side of it.

### **H BAND**

The H band is part of the A band. It is the lighter region in the center of the A band where there is no overlap between actin and myosin filaments. It is shaped somewhat like a capitol letter H, hence the name "H" band.

### **M LINE**

M stands for middle. These bulges line up with one another and create a region of greater density that looks like a dark line running down the center of the sarcomere. This line is known as the M line.

## **SLIDING FILAMENT THEORY OF MUSCLE CONTRACTION**

### **1. NERVE IMPULSE**

When a nerve impulse arrives at a muscle cell it causes the release of neurotransmitter (acetylcholine) onto the surface of the muscle cell which spreads into the interior of the sarcomere by way of the T tubules. The neurotransmitter causes calcium ions to be released from the sarcoplasmic reticulum. The calcium ions flood into the sarcomere and facilitate contraction by causing them to bind with troponin of the actin filament.

### **2. CALCIUM BONDS**

When calcium ions bind with troponin the troponin molecule physically shifts, exposing a small socket in the troponin/tropomyosin helix into which a myosin cross-bridge fits. Thus actin and myosin make physical connection with one another for the first time.

### **3. CROSS BRIDGE ROTATION**

At the same time that calcium is flowing into the cell, ATP (adenosine triphosphate, the energy currency of the cell) is broken down into ADP + P + free energy. This free energy causes the cross bridges to rotate which causes the actin filaments to slide toward the center of the sarcomere where they overlap the myosin filaments to a greater extent, thus shortening the length of the sarcomere. Neighboring sarcomeres are also shortening, and thus the fibril, the fiber, and the whole motor unit also shorten.

### **4. CROSS BRIDGE RETURN**

ATP expenditure may also be required to break the connections and return the myosin heads (cross bridges) to their original positions, ready to make contact and rotate again. Muscle contraction is thus a sequence of small ratchet-like connections, rotations, and returns.

## **ANATOMIC CHANGES IN THE CONTRACTING SARCOMERE**

- The myosin filaments do not move.
- The actin filaments slide toward the center of the sarcomere.
- The Z lines move closer together.

thus:

- The I bands become narrower.
- The H bands become narrower.
- The A bands don't change.
- The sarcomere shortens.

## **TYPES OF MUSCLE TISSUE**

### **SMOOTH MUSCLE**

The cells are small and delicate and fuseform (cigar shaped). Each has a pale centrally located nucleus; the cytoplasm is not striated. The cells occur in thin sheets, each cell is surrounded by a delicate connective tissue network, and the whole sheet is separated from other sheets of muscle by areolar connective tissue. When contraction

occurs it resembles a slow, smooth, spreading wave. This type of muscle gives the appearance of not fatiguing since it is capable of continuing to contract for hours (as during childbirth). A whole sheet of muscle cells requires only one nerve since the impulse spreads readily from one cell to the next. Other names for this type of muscle are **visceral muscle, involuntary muscle, and autonomic nervous system muscle.** Some of the places it is found are: the walls of hollow internal organs (except the heart), in the walls of ducts and vessels, and attached to the hairs of the skin.

## **SKELETAL MUSCLE**

The cells are boldly striated, and each cell is enormously long and quite wide. There are many nuclei per single cell; the nuclei are peripheral in position and are small, dark, and condensed looking. The muscle cells are grouped into large fascicles or bundles, and each cell requires individual connection to a branch of an axon; there is no spreading of contraction from one cell to another.

The contractions are strong, brief, and powerful, but the muscle fatigues easily. Synonyms for this type of muscle tissue are: **striated muscle, voluntary muscle, somatic muscle, and peripheral nervous system muscle.**

## **CARDIAC MUSCLE**

The cells are small, faintly striated, with central nuclei and blunt ends that anastomose with one another by way of special junctions called intercalated discs. The discs facilitate the spread of contraction from one cell to another. Some cells branch before connecting to another cell, so that the tissue has the appearance of a branched network rather than a group of bundles. Each cell has its own intrinsic pulsating contractility that appears not to fatigue. The pulsations synchronize with one another. There are no synonyms for this type of muscle.

## **MOTOR UNIT CONCEPT**

One motor unit = the total number of skeletal muscle cells supplied by the branches of a single axon (a single nerve cell). When a nerve impulse activates a nerve cell, all branches of that nerve will release ACh simultaneously, and the whole motor unit will respond.

Some motor units are as small as three muscle cells, some are as large as 600 or more muscle cells. Small motor units allow for fine motor control and thus delicate movements; large motor units are associated with power. Increased power will also result from activating more nerves, and thus calling into action more motor units (*recruitment of motor units*).



# ARCHITECTURAL PLANS OF SIMPLE ORGANS

## BLOOD VESSEL WALLS

Arteries and veins both have the following three basic layers, but the layers are thicker in arteries (especially the tunica media), and the elastic tissue is lacking in veins.

## ARCHITECTURAL PLAN

### 1. TUNICA INTERNA

This layer is also known as the *tunica intima*. It has three sub parts:

#### A. ENDOTHELIUM

#### B. BASEMENT MEMBRANE

This layer is invisible unless a special stain is used to prepare the slide.

#### C. INTERNAL ELASTIC MEMBRANE

### 2. TUNICA MEDIA

#### A. SMOOTH MUSCLE

#### B. EXTERNAL ELASTIC ZONE

### 3. TUNICA EXTERNA

This layer is also known as the *tunica adventitia*. It is a layer composed of irregular fibrous connective tissue.

## PATHOLOGY OF ARTERY WALLS

### ARTERIOSCLEROSIS

Arteriosclerosis is a term applied to a number of pathologies in which there is thickening, hardening, and loss of elasticity of the walls of arteries. Changes may occur in the intima, media, or both.

### ATHEROSCLEROSIS

Atherosclerosis is a form of arteriosclerosis. There is an abnormal growth of cells (tumor) (atheroma) in the tunica media. These growths are called atheromas. The atheroma disrupts the internal elastic membrane and occludes the lumen of the artery.

## SKIN

Skin is an organ, not a tissue. It is the largest organ by weight in the human body, and serves an important immune system organ, as well as a mechanical and chemical barrier to the outside world. It has three basic layers, only one of which is epithelial.

### 1. EPIDERMIS

This is the avascular epithelial surface layer of the skin. It has five subsections:

#### A. STRATUM CORNEUM

The cells of this zone have lost their nuclei and are beginning to dehydrate and flake off of the skin. As long as they are present they have a protective function.

#### B. STRATUM LUCIDUM

This zone is translucent. The cells have lost their nuclei but the dead cells remain tightly glued in place. They have a protective function.

#### C. STRATUM GRANULOSUM

The cells of this zone are full of *keratin granules*. Keratin is a protein material that is manufactured by the living cells of the skin. It acts as a type of intercellular glue which keeps the upper layers of dead cells in place for a considerable length of time.

#### D. STRATUM SPINOSUM

This zone is also sometimes called the Malpighian layer. The cells in the bottom part of this zone may contain pigment granules which protect the dividing cells in the stratum basale from damage by sunlight.

#### 5. STRATUM BASALE

Another name for this layer is *Stratum Germinativum*. This single layer of cuboidal cells clings to the basement membrane of the skin. These are the actively dividing cells which give rise to all of the cells in the higher zones.



## 2. DERMIS

The dermis is a layer of dense irregular collagenous connective tissue that is well vascularized. It has several interesting features which are listed below.

### A. DERMAL PAPILLAE

The dermal papillae are raised portions of the dermal layer that help to anchor the epidermis to the dermis.

### B. SWEAT GLANDS

These glands are also called *sudoriferous* glands. They are simple coiled tubular glands which have a long duct that reaches to the free surface of the skin.

### C. SEBACEOUS GLANDS

These oil secreting glands are found only in hairy skin. Their ducts always open into the hair follicle.

## 3. HYPODERMIS

This section of the skin is also known as the *subcutaneous* layer. It is a connective tissue zone beneath the dermis, and characterized by the presence of adipose tissue.

## MUCOUS MEMBRANES

A mucous membrane is also known as a *mucosa*. It has four layers:

### 1. EPITHELIUM

The epithelium of a mucous membrane will vary depending on location and function. For example, in the respiratory system it will be pseudostratified columnar, in the intestine it will be simple columnar, and in the esophagus it will be stratified squamous.

### 2. BASEMENT MEMBRANE

The basement membrane is a delicate layer of glue-like material secreted by the connective tissue cells of the lamina propria. It is usually invisible unless special stains are used. It plays an important roll in keeping the epithelial sheet intact.

### 3. LAMINA PROPRIA

The lamina propria is the connective tissue layer underlying the basement membrane of all mucosae. This layer always includes

small blood vessels, lymphatics, nerves, and sometimes multicellular mucous glands.

## 3. MUSCULARIS MUCOSA

The muscularis mucosa is a thin layer of smooth muscle found beneath the lamina propria.

## RESPIRATORY TUBE WALLS

### 1. MUCOSA

#### A. EPITHELIUM

Pseudostratified columnar epithelium with cilia and goblet cells.

#### B. BASEMENT MEMBRANE

#### C. LAMINA PROPRIA

#### D. MUSCULARIS MUCOSA

### 2. SUBMUCOSA

This is a zone of dense fibrous connective tissue that may contain pieces of hyaline cartilage and multicellular mucous secreting glands.

### 3. ADVENTITIA

This is a zone of irregular loose fibrous connective tissue surrounding the outside of the trachea and bronchi.

## GUT TUBE WALLS

### 1. MUCOSA

#### A. EPITHELIUM

Simple columnar epithelium.

#### B. BASEMENT MEMBRANE

#### C. LAMINA PROPRIA

#### D. MUSCULARIS MUCOSA

### 2. SUBMUCOSA

This is a zone of dense fibrous connective tissue that may contain large numbers of multicellular mucous secreting glands. It also contains larger blood vessels and lymphatics than does the lamina propria.

### 3. MUSCULARIS EXTERNA

The muscularis externa is also called the *Tunica Muscularis*. These layers of smooth muscle are responsible for the churning

action of the stomach and for peristalsis in the rest of the digestive tube. Only the stomach has all three layers. Other parts of the digestive tube have two layers.

#### **A. INNERMOST OBLIQUE LAYER**

This layer is found only in the stomach.

#### **B. INNER CIRCULAR LAYER**

The muscle cells in this layer are oriented in a circular fashion around the circumference of the tube. When these cells contract they constrict the diameter of the tube. In certain locations the inner circular layer is especially thick; such structures are known as *sphincters*.

#### **C. OUTER LONGITUDINAL LAYER**

The muscle cells in this layer are oriented parallel with the longitudinal axis of the tube. When this layer contracts in a coordinated fashion with the inner circular layer of muscle, a bolus of food is moved forward through the gut tube.

### **4. SEROSA OR ADVENTITIA**

A serosa is the same as an adventitia except that it has an additional outer layer of simple squamous epithelium known as *mesothelium*. This mesothelium secretes serous fluid, which is a thin watery fluid that moistens and lubricates the peritoneum.

The esophagus and all retroperitoneal portions of the digestive system are surrounded by an adventitia rather than a serosa.

# Digestive System

## PERITONEAL MEMBRANES

There are three types of membranes associated with the digestive system: *mesentery*, *omentum*, and *suspensory ligaments*. All of these are derived from peritoneum.

### MESENTERY

The term mesentery refers to any double fold of parietal peritoneum that connects an organ to the posterior abdominal wall. In the case of the small intestine, the parietal peritoneum of the posterior abdominal wall projects forward into the abdominal cavity in a double fold shaped like a

pleated fan. The outer edge of this fan shaped fold is approximately 20 feet long. The posterior border (the handle of the fan) is approximately 6-8 inches long. It serves as a highway for the mesenteric arteries and veins which supply the small intestine. It also organizes the intestinal tract, preventing it from getting tangled.

### OMENTUM

The greater and lesser omentum are folds of peritoneum connecting the stomach to some other organ.

#### GREATER OMENTUM:

The greater omentum is the first thing that one sees upon opening the abdominal cavity. It is an apron like double fold of peritoneum

that hangs from the lower edge (greater curvature) of the stomach and doubles under to connect the stomach to the transverse colon. It hangs down loosely over the intestines, and serves as a fat storage organ and as a reserve storehouse for fixed tissue macrophages.

#### LESSER OMENTUM:

The lesser omentum is a double fold of peritoneum stretching between the lesser curvature of the stomach and the liver.

### LIGAMENTS OF THE LIVER

A suspensory ligament is a fold of peritoneum connecting one organ to another, or connecting an organ to the body wall. The coronary and falciform ligaments are suspensory ligaments, the ligamentum teres is not.

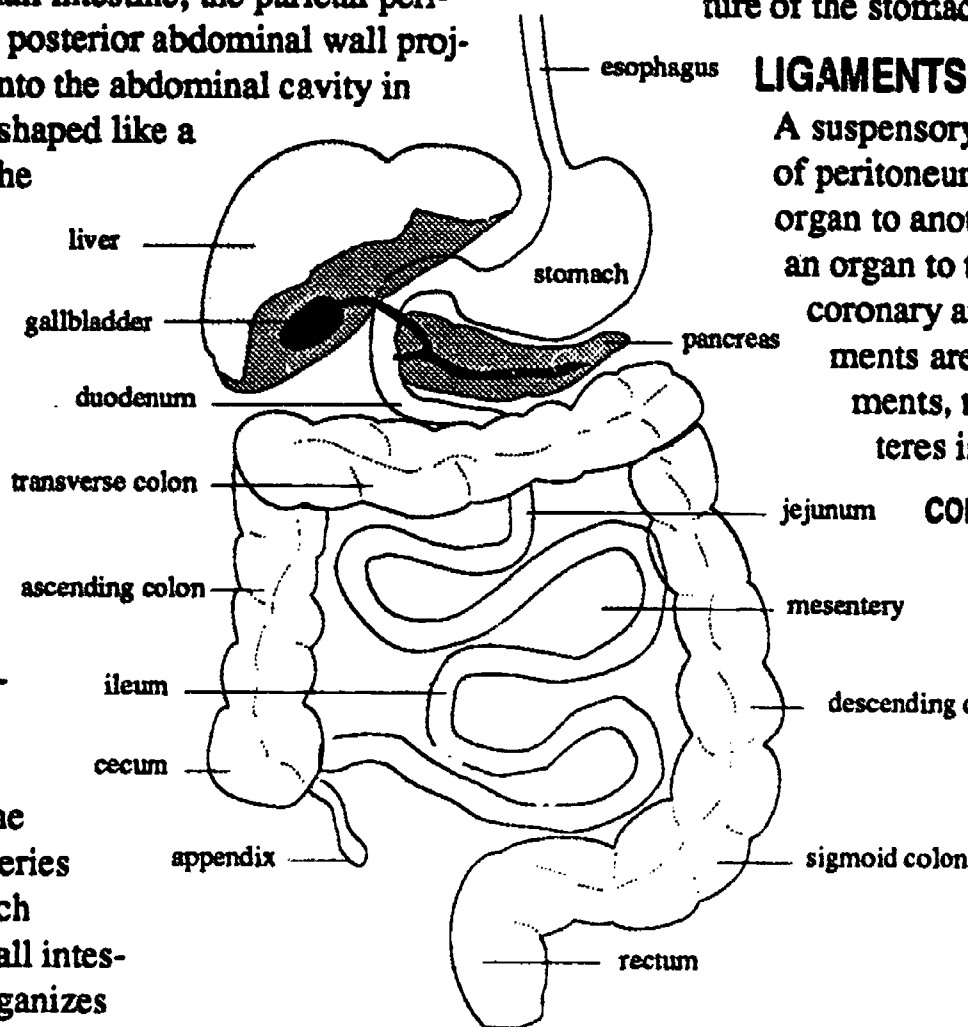
#### CORONARY LIGAMENT

The coronary ligament of the liver is the peritoneal connection between the liver and the diaphragm. The visceral peritoneum on the superior surface of the liver leaves the liver and turns upward to become the parietal peritoneum of the bottom

surface of the diaphragm.

#### FALCIFORM LIGAMENT

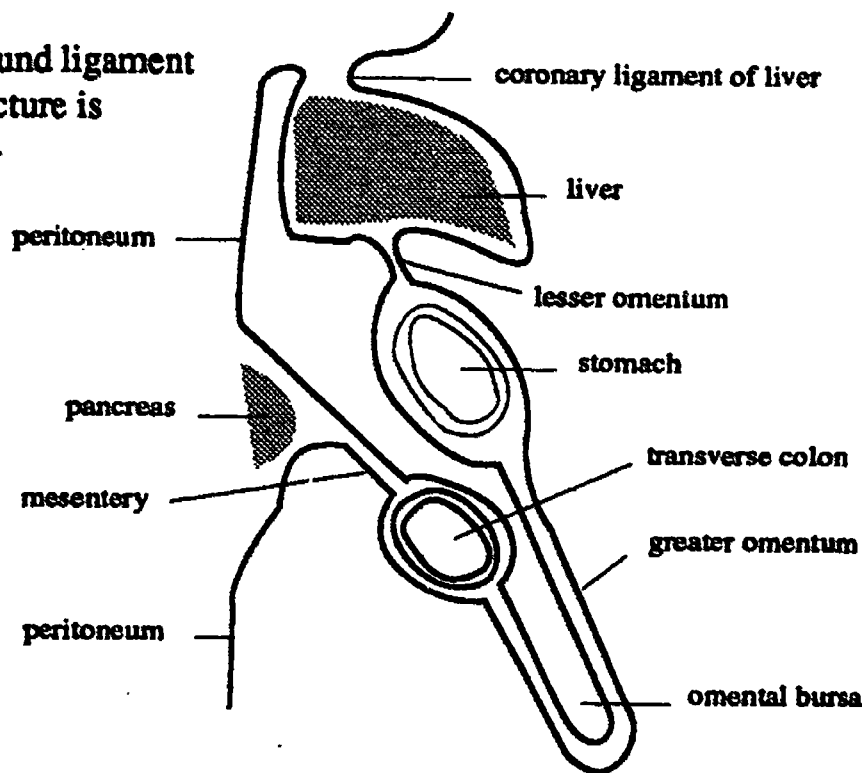
The falciform ligament is a double fold of peritoneum found between the right and left lobes of the liver. It envelops the ligamentum teres (see below).



**Fig. 8- Overview of Digestive System showing the Mesentery of the Intestine**

## LIGAMENTUM TERES

Also known as the round ligament of the liver. This structure is not a suspensory ligament, rather it is a remnant of the umbilical vein, which was the blood vessel carrying nutrient laden blood from the placenta to the fetus. (The definition of a vein is that it carries blood toward the heart. The umbilical vein carries blood to the fetal heart.)



**Fig. 9- Peritoneal Membranes of the Abdomen, Midsagittal View.**

## MOUTH AND PHARYNX

### DIGESTIVE FUNCTIONS

Chemical digestion processes depend upon maximum surface area. Small particles have more surface area than larger particles. Mastication of food is a mechanical process that creates small particles out of larger pieces.

Food must be moistened and lubricated to aid in swallowing. Saliva contains both water and mucous to serve this end. Food must also be moistened in order to be tasted. Taste triggers digestive enzyme secretion, both in the mouth and in the lower parts of the digestive system.

Saliva contains *salivary amylase* that begins the chemical digestion of starch by breaking down the long chain starch molecules into simple sugars.

Saliva also has antibacterial properties. People with compromised saliva secretion have more dental carries.

### DENTITION

A dental formula indicates the pattern of

teeth for only one quadrant of the mouth since the lower jaw pattern is identical to the upper jaw pattern, and the right and left sides are mirror images of one another. The dental formula is unique to each species. The first set of teeth are the 20 deciduous teeth of the child. They begin to erupt at 5-9 months. The second set of

teeth are the permanent teeth of the adult. They begin to erupt at 6 years and eruption is completed by the 15th year except for the wisdom teeth (2nd and 3rd molars) which erupt between 17-25 years of age.

#### ADULT DENTAL FORMULA

2 : 1 : 2 : 3

two incisors,  
one canine,  
two premolars (bicuspid),  
three molars

#### CHILD'S DENTAL FORMULA

2 : 1 : 0 : 2

two incisors,  
one canine,  
two molars

### SALIVARY GLANDS

#### PAROTID

The parotid salivary gland is in front of the ear and behind the ramus of the mandible. Mumps is a viral inflammation of the parotid gland.

The duct from the parotid gland crosses over the masseter muscle and penetrates the mucosa to open inside the mouth at the level of the second molar in the upper jaw.



## **SUBMANDIBULAR**

The submandibular gland (also known as the submaxillary gland) lies below the body of the mandible; its duct opens at the base of the frenulum of the tongue.

## **PAPILLAE OF THE TONGUE**

The papillae of the tongue are projections of the epithelium of the upper surface of the tongue. Two of the three types contain taste buds.

### **VALLATE (CIRCUMVALLATE)**

The vallate papillae are the fewest in number and the largest of the papillae. There are 7-12 of them on each side, located at the back of the tongue in a single V shaped row. Each one is like a castle surrounded by a moat or trench which is kept clear of debris by flooding from glands in the papilla. Each papilla contains several taste buds which send information to the brain via cranial nerve IX.

### **FUNGIFORM**

The fungiform papillae are located on the tip and sides of the tongue. These papillae look like red spots on the tongue because their epithelium is so thin and transparent that it allows blood to show through. They contain taste buds which send information to the brain via cranial nerve VII.

### **FILIFORM**

The filiform papillae are the most numerous of the papillae. They are evenly distributed over the whole surface of the tongue. They do not contain taste buds. Each one is shaped like a tiny hooked file. They serve to roughen the surface of the tongue so that it is not so slick, helping to keep food from sliding off of the tongue during chewing. They are also sense organs for touch. In some animals, like the cat, these papillae are enlarged and rasp like.

## **MISCELLANEOUS**

### **FRENULA OF TONGUE & LIPS**

A frenulum is a thin fold of mucus membrane attaching two parts, one of which is less movable than the other. There is a

frenulum connecting each lip to the adjacent gum (*gingiva*), there is also a frenulum connecting the tongue to the floor of the mouth. If this one is too short (tongue tied) it makes speech difficult.

### **GINGIVAE**

The gingivae are the gums.

### **SOFT PALATE AND UVULA**

The uvula is part of the soft palate, and the soft palate participates in swallowing by helping to close off the opening to the nasopharynx.

## **ESOPHAGUS**

### **HISTOLOGY**

#### **MUCOSA OF THE ESOPHAGUS**

The epithelium of the esophagus is subject to abrasion from nearly solid food particles, and is therefore of the stratified squamous type. A great deal of mucous is needed to facilitate passage of this food through the tube and into the stomach. There are a large number of mucous glands which extend all the way from the lumen down into the submucosa.

#### **MUSCULARIS EXTERNA:**

The upper one third of the esophagus contains voluntary muscle. The middle one third contains a mixture of skeletal and smooth muscle. The lower one third contains smooth muscle. Swallowing begins as a voluntary act but continues as a peristaltic wave of the smooth muscle.

## **STOMACH**

### **REGIONS & CURVATURES:**

#### **CARDIAC REGION**

The cardiac region of the stomach is the area immediately surrounding the junction of stomach and esophagus.

#### **FUNDIC REGION**

The fundus of the stomach is the bubble like area at the top of the stomach.

#### **BODY OF THE STOMACH**

The body of the stomach is the main and largest part of the stomach.



## PYLORIC REGION

The pyloric region is lowest part of the stomach immediately preceding the junction between stomach and duodenum.

## GREATER CURVATURE

The greater curvature is the left hand and inferior border of the stomach.

## LESSER CURVATURE

The lesser curvature is the right hand border of the stomach.

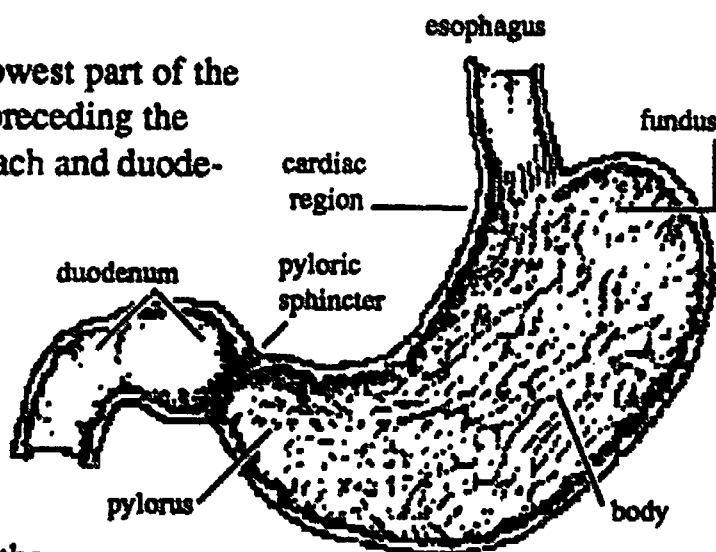


Fig. 10- Stomach

## HISTOLOGY OF THE STOMACH

### RUGAE

When the stomach is empty the mucosa and submucosa are thrown into temporary folds called *rugae* which disappear when the stomach is distended with food.

### GASTRIC GLANDS

The epithelium of the stomach is the simple columnar type with many mucous secreting goblet cells. The surface of the mucosa is marked by closely set *gastric pits* which are openings that lead to the subsurface *gastric glands*. The volume of secretion from these gastric glands has been estimated at approximately 2500 cc per day. There are three types of secretory cells in the glands.

#### Mucous Neck Cells

The necks of the gastric glands are lined with goblet cells called the mucous neck cells. The mucous tends to protect the epithelium of the stomach from harm from the HCl produced by other cells of the gastric glands.

#### Chief Cells

The chief cells secrete *pepsinogen*, the inactive form of *pepsin*, a protease enzyme that begins the process of protein digestion.

#### Parietal Cells

The parietal cells secrete HCl and intrinsic factor. HCl is a strong acid necessary for conversion of pepsinogen (the in-

active protease) to pepsin, the active form. Perhaps it is the presence of this acid that makes the stomach ulcer prone (peptic ulcers). *Intrinsic factor* is needed for absorption of vitamin B<sub>12</sub> which in turn is needed for production of red blood cells.

### MUSCULARIS EXTERNA

The smooth muscle of the stomach is unique in that it has three layers rather than the usual two. The extra layer of muscle is important to the churning action of the stomach. The layers from inside out are:

- Innermost Oblique layer
- Inner Circular layer
- Outer Longitudinal layer

### PYLORIC SPHINCTER

The pyloric sphincter is found at the lower end of the stomach where it joins with the duodenum. It is a thickening of the inner circular layer of the muscularis externa. The sphincter stays tightly constricted until the stomach contents are liquified, then it relaxes, allowing the liquified stomach contents (*chyme*) to enter the duodenum.

## FUNCTIONS OF THE STOMACH

### DIGESTION

The churning action of the stomach is an important mechanical part of digestion. In addition the first phase of protein digestion begins with the pepsin secreted by the stomach.

### ABSORPTION

Only a few things are absorbed through the stomach wall, namely simple sugars such as fructose, alcohol, & some drugs such as aspirin.

# INTESTINE

## FUNCTIONS

The chief function of the small intestine is digestion of food and absorption of nutrients. The chief function of the large intestine is absorption of water and electrolytes.

### DIGESTION:

Most of the digestive activity of the small intestine is due to pancreatic enzymes aided by bile. Pancreatic enzymes are made by the pancreas, bile is made by the liver cells, both are ducted to the duodenum via a system of ducts. More will be said about these subjects below.

### ABSORPTION

The term absorption refers to the uptake of molecules through the mucosa of the intestine and into the blood or lymphatic capillaries. These function requires maximum mucosal surface area.

## MUCOSAL SURFACE AREA

There are about 6 different ways in which to increase mucosal surface area in order to maximize the absorption process.

### LENGTH OF INTESTINE

A longer tube will have more mucosal surface area than a shorter tube. The length of the intestinal tube is related to the diet of the animal in question. Carnivores have relatively short intestinal tracts. Herbivores need very long intestinal tracts. Omnivores like the human (and the pig) have intermediate length intestinal tracts.

### COILS

In order to fit a long tube into the abdominal cavity the tube must be coiled.

### PLEATS

The inside surface (mucosa and submucosa) of the intestine is folded into permanent pleats. In the small intestine each pleat is called a *plica circulares*. In the large intestine these pleats are called the *semilunar folds*.

### VILLI

Villi are fingerlike folds of the mucosa of the small intestine. They are found in the small intestine only, not in the stomach or large intestine. They are just barely visible with the naked eye and cause the inside surface of the small intestine to appear to have a velvety texture.

The main characteristic of the villi is that the lamina propria of each contains a blood capillary and a lymphatic capillary (lacteal). It is into these vessels that the products of digestion are absorbed. The fat goes mainly into the lacteal and the other nutrients are absorbed into the blood capillaries.

### MICROVILLI

Microvilli are fingerlike projections of the membrane of the superior surface of the cell. Many microvilli project from the free border of each simple columnar epithelial cell. They are present in both the small and large intestine (as well as on the cells in the kidney tubules. Under the light microscope they give a fuzzy appearance to the free borders of the columnar epithelial cells. This fuzzy border is sometimes called a "*brush border*".

### INTESTINAL GLANDS

The intestinal glands are somewhat similar to the gastric pits of the stomach in that they are subsurface indentations of the mucosa. The crypts are found between the bases of the villi of the small intestine. The only function they appear to have is that of increasing the surface area. Formerly it was thought that the crypts contained a special kind of cell called a *Paneth cell*, thought to be the source of secretion of special intestinal enzymes. Now it is believed that these intestinal enzymes are secreted by all parts of the intestinal mucosa.

## SMALL INTESTINE

The small intestine is approximately 21 feet long and is divided into three regions.

### DUODENUM

The duodenum is the first 10 inches of the small intestine. It is shaped like a capitol

letter C. The duodenum is retroperitoneal, except for the first section which is called the cap of the duodenum. See Fig. 10.

The duodenum is very ulcer prone (duodenal ulcers), particularly the second part of the duodenum which receive the full impact of the acidic chyme as it squirts out of the stomach. The submucosa in this area of the duodenum possesses large numbers of glands called Brunner's glands which produce copious amounts of mucous.

Another feature of the duodenum is the *duodenal ampulla*, also known as the *duodenal papilla*, *ampulla of Vater* and *papilla of Vater*. This papilla is the common

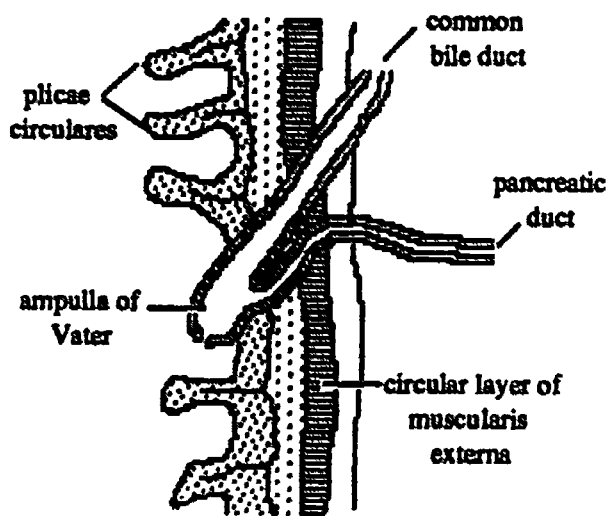


Fig. 11- Duodenal Ampulla

opening of the ducts from the gall bladder and the pancreas into the duodenum.

#### JEJUNUM

The jejunum is approximately 8 feet long. It has no special features.

#### ILEUM

The ileum is approximately 12 feet long. At its terminal end it enters the cecum at an abrupt right angle. This opening of ileum into cecum is guarded by a sphincter called the *ileocecal valve*.

One of the most interesting features of the ileum is the presence of *Peyer's patches*. Peyer's patches are nonencapsulated masses of lymphoid tissue found in the mucosa and submucosa of the wall of the small intestine,

especially in the ileum, and especially near the ileocecal valve. They always occur on the side of the intestinal tube opposite to the attachment of the mesentery.

## LARGE INTESTINE

The large intestine is approximately 3.5 feet long and is divided into six regions.

### CECUM (CAECUM)

The cecum is the first part of the large intestine to receive the contents of the small intestine when the ileocecal valve opens. It is found in the lower right quadrant of the abdomen in humans. The size of the cecum varies among different species; it is particularly large in herbivores and may be nonexistent in carnivores.

### Vermiform appendix

The vermiform (worm shaped) appendix is attached to the cecum in the lower right quadrant of the abdomen. It is thought to be a nonfunctional vestigial structure, probably a remnant of what was once a larger cecum. It is not present in all species.

### ASCENDING COLON

The ascending colon is the direct upward continuation of the cecum on the right side of the abdomen. At the level of the liver it makes a right angle turn to the left. This turn is called the *right colic flexure*, or *hepatic flexure*. The ascending colon is retroperitoneal.

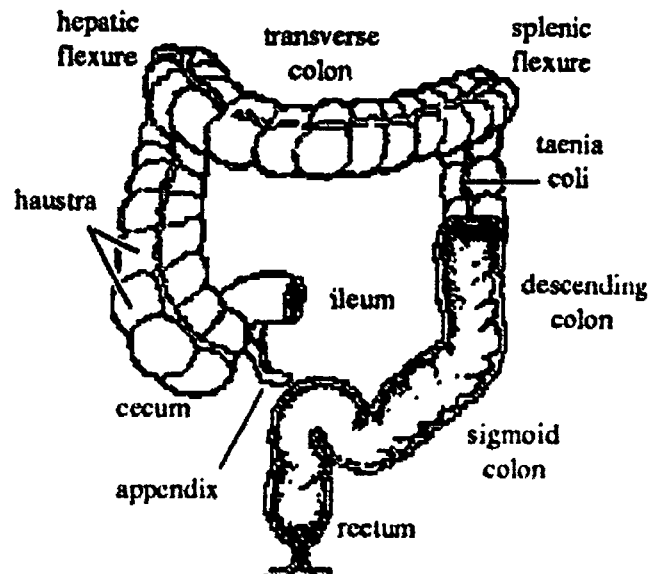


Fig. 12- Large Intestine

## TRANSVERSE COLON

The transverse colon is inferior to the stomach, and stretches from the right side of the abdomen (near the liver) to the left side of the abdomen where it touches the spleen. In pictures of cadavers it is seen as a horizontal section of the colon. In a living person it usually droops to a variable degree. When it reaches the spleen it makes a right angle turn downward. This turn is called the *left colic flexure* or *splenic flexure*.

## DESCENDING COLON

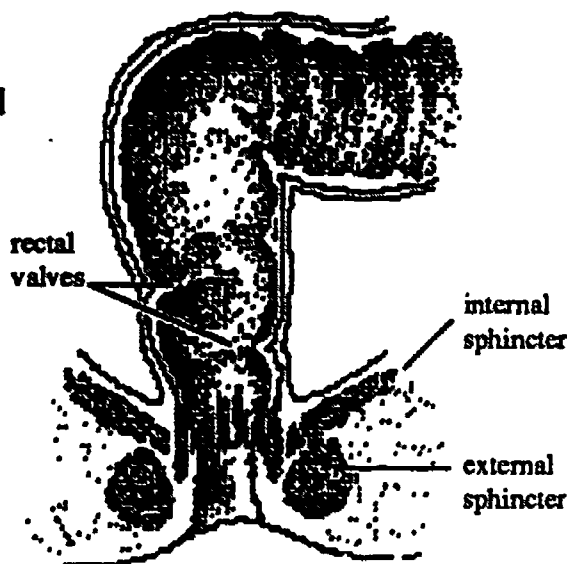
The descending colon is the section of colon on the left side of the abdomen. The descending colon is retroperitoneal.

## SIGMOID COLON

The sigmoid colon is the S shaped section of colon directly continuous with the descending colon. The name refers to the S shape.

## RECTUM

The rectum is retroperitoneal and is directly continuous with the sigmoid colon. It has mucosal folds called *rectal valves* which help to support the weight of the feces, reducing



**Fig. 13- Rectal Canal**

the pressure on the anal sphincter. When taking a rectal temperature it is important not to push against one of the rectal valve since they can tear.

There are two *rectal (anal) sphincters*, the inner one is a thickening of the circular smooth muscle and is involuntary. It opens automatically in response to distention of the rectum. The external anal sphincter is of skeletal muscle and is voluntary. During childhood toilet training the child is taught to recognize the feelings of rectal distension and to take appropriate action.

## DISTINGUISHING FEATURES OF LARGE INTESTINE

The large intestine can be distinguished from the small intestine by the following four features:

- **Diameter.** The large intestine has a larger diameter than the small intestine.
- **Taeniae coli:** The taeniae coli represent the longitudinal muscle layer of the muscularis externa which has been bunched into three strips or bands. The anterior taenia leads to the appendix and is therefore a useful landmark.
- **Haustra:** The taeniae coli are shorter than the length of the large intestine itself so they act to gather the large intestine together into sacculations ( sac-like bulges).
- **Epiploric appendages:** The epiploric appendages are fatty bits of visceral peritoneum hanging from the outer surface of the large intestine. They have no known function but are unique and are therefore useful in identifying the large intestine.



# Accessory Digestive Glands

## THE LIVER

### ANATOMY OF THE LIVER

#### LOBES

Seen from an anterior view, the liver is divided into *right and left lobes* by the falciform ligament. If examined from a posterior inferior view two additional lobes can be seen, the *caudate and quadrate lobes*. The quadrate lobe is shaped like a quadrangle and is closest to the gall bladder. The caudate lobe is the most posterior of the two and partially envelopes the inferior vena cava.

#### PORTA HEPATIS

The term porta hepatis means "gateway to the liver". It lies in the lesser omentum and consists of a triad of vessels which supply blood to and remove bile from the liver.

#### COMMON BILE DUCT

The common bile duct receives bile from the smaller hepatic bile ducts, and carries it to the duodenum.

#### HEPATIC PORTAL VEIN

The hepatic portal vein collects blood from the spleen, stomach and intestines. This blood is rich in absorbed dietary nutrients, and these nutrients are brought to the liver for further processing.

#### HEPATIC ARTERY

The hepatic artery is a branch of the celiac trunk, which in turn is a branch of the aorta. This is the route by which oxygen and dietary fat arrive at the liver.

#### LOBULE ARCHITECTURE

The liver is made up of hexagonal lobules that are just barely visible to the naked eye. At the center of each lobule is a branch of an hepatic vein called the *central vein*.

*Cords* of cuboidal liver cells are arranged like spokes in a wheel radiating out from the

central vein. Between these cords are the *venous sinusoids* of the liver, which are like very large capillaries in that the exchange of nutrients and gasses takes place between the blood in the sinusoids and the cells in the cords. Here and there along the sinusoids are the resident macrophages of the liver, called *Kupffer cells*.

At the perimeter of the lobule, in the corners between neighboring lobules, are groupings called *triads*, which consist of small branches of the hepatic artery, portal vein, and bile duct.

Blood arrives in the lobule by way of the portal vein and hepatic artery, and then enters the liver sinusoids where it gives up the food and oxygen it is carrying to the liver cells. The used blood then drains into the central vein and from there into the hepatic veins and inferior vena cava.

Bile, made by the liver cells, moves in the opposite direction to that of the blood flow. It is initially collected by very fine ducts found between the cells of the liver cords. These ducts are called the *bile canaliculi*. They drain into the bile duct found in the triad. These ducts in turn join together to form the hepatic bile ducts which carry bile to the gall bladder for storage. The larger bile ducts are readily distinguished from blood vessels by their cuboidal epithelial lining.

### FUNCTIONS OF THE LIVER

#### STORAGE

The liver stores certain items, notably *vitamin A, iron, and glycogen*.

#### DETOXIFICATION

The liver removes all kinds of toxic substances from the blood and disposes of them in various ways. Notable among these are *alcohol and esters* of all kinds. Most chem-



icals which are volatile and aromatic are esters.

## SYNTHESIS OF UREA

When amino acids are catabolized they are deaminated i.e. the nitrogen molecule is removed and discarded as a nitrogenous waste product (ammonia). Ammonia is extremely toxic to cells, so the liver immediately converts the ammonia to urea, which is less toxic. The urea is removed from the blood in the kidneys.

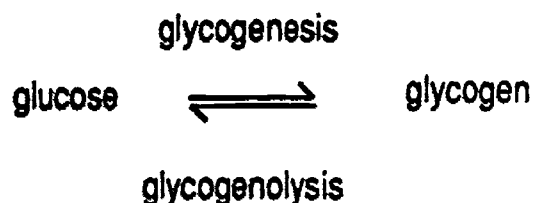
## SYNTHESIS OF BILE

Bile is synthesized by liver cells from bilirubin and cholesterol. (Bilirubin is a breakdown product of hemoglobin). The bile is then ducted to the gall bladder where it is concentrated and stored. Its place of action is the small intestine, where it acts as an emulsifying agent so that lipase enzymes can work efficiently.

## GLUCOSE METABOLISM

### 1. GLYCOGENESIS

The liver removes excess glucose from blood and converts it into the storage form, glycogen, which is a polymer of glucose. It is a reversible process.



### 2. GLYCOGENOLYSIS

The reverse of glycogenesis is called glycogenolysis. The term implies the measured release of glucose.

### 3. GLUCOGENESIS:

This term means the production of glucose from amino acids and or fatty acids. Falling blood sugar stimulates glucogenesis.

## PROTEIN METABOLISM

### 1. SYNTHESIS OF PLASMA PROTEINS

The liver cells have the special job of producing plasma proteins, including albumin and various globulins (except for immunoglobulin).

Albumin, which is essential for osmotic equilibrium, is 70% of the total plasma protein. Lack of sufficient blood albumin is often accompanied by *ascites*, the edematous accumulation of fluids in the peritoneal cavity. Ascites is a symptom of Kwashiorkor (protein starvation).

The globulins are used as carrier molecules for transport of steroid and thyroid hormones and cholesterol. Various globulins are also blood clotting factors (such as fibrinogen and prothrombin).

### 2. CATABOLISM OF AMINO ACIDS

Amino acids can be burned as fuel if sufficient glucose is not available. See number 5 below.

## FAT METABOLISM:

### 1. LIPOGENESIS

Production of fat from glucose and/or amino acids is a function of the liver. When excess calories are consumed the extra glucose can be converted into fat which is then transported to the adipose cells for storage.

### 2. LIPOLYSIS:

On the other hand, fatty acids can be used as a fuel source if glucose is not available.

When fats are being burned for fuel by products known as ketones are produced. A high level of ketones in the blood is called *ketosis*. Ketones are acidic; if the levels are very high they cause *acidosis* which in turn can produce coma and death.

## LIVER PATHOLOGY

*Hepatitis* is any inflammation of the liver. *Cirrhosis* is the destruction of liver cells accompanied by production of scar tissue.

Symptoms of both hepatitis and cirrhosis: decreased plasma albumin, edema, *jaundice*, and increase in circulating ammonia.

Causes: viral, alcohol abuse, drug abuse, toxic compounds. Included among the liver toxins: alcohol, tranquilizers, anesthetics, all volatile compounds such as carbon tetra-

chloride, gasoline fumes, benzene, xylene, acetone, etc.

**Gout:** Liver produces uric acid rather than urea (from cellular nucleic acids). Uric acid accumulates in the cells and can cause inflammation.

## GALLBLADDER

The gall bladder concentrates, stores, and releases bile. Its epithelium, like that of the bile ducts, is simple cuboidal in type, specialized for reabsorption of water.

The release of bile is coordinated with the presence of fat in the duodenum by the hormone *cholecystokinin*.

Cholecystokinin, produced by the duodenum, causes the gall bladder to contract.

**Gallstones:** May follow infection of the gall bladder, or may be due to a hereditary quirk in cholesterol metabolism.

## PANCREAS

The pancreas has two kinds of tissue, the "pancreatic tissue proper" and the "islands of Langerhans".

### PANCREATIC TISSUE PROPER

This tissue produces digestive enzymes which are ducted to the duodenum. The enzymes include a variety of *proteases*, *amylases*, and *lipases*. Proteases are for protein digestion, amylases are for starch digestion, and lipases are for fat digestion.

### ISLANDS OF LANGERHANS

The islands of Langerhans produce two hormones. insulin and glucagone.

#### INSULIN:

The rate of entry of glucose into all body cells is chiefly regulated by insulin. A rise in blood glucose stimulates the secretion of insulin from the pancreas and the subsequent leveling off of blood sugar.

#### GLUCAGON:

A fall in blood glucose level stimulates the pancreas to secrete glucagon. Glucagon stimulates glycogenolysis by the liver, thus

increasing the blood glucose level.

## PANCREATIC PATHOLOGY

### DIABETES MELLITUS

Diabetes mellitus (as opposed to diabetes insipidus) is due to insulin insufficiency and/or decreased tissue sensitivity to insulin.

Type I Diabetes (juvenile onset diabetes) is the most severe form and has the poorest prognosis. It is probably hereditary and is usually due to degeneration of the  $\beta$  cells.

Type II Diabetes (Maturity Onset Diabetes) is due to decreased tissue sensitivity to insulin (insulin resistance).

Tissues vary in their sensitivity (or resistance) to insulin. Obesity increases insulin resistance and therefore aggravates diabetes mellitus. Exercise and weight loss raise tissue sensitivity to insulin. Orinase raises tissue responsiveness and also increases insulin production.

### HYPOGLYCEMIA

Hypoglycemia is thought to be due to overreaction of the pancreas (hypersecretion of insulin) following ingestion of refined carbohydrates. This results in a too rapid drop in blood sugar level. Symptoms of very low blood sugar levels: weakness, fatigue, depression, and "the shakes".

Hypoglycemia is a fad disease, and there is probably much quackery associated with its "diagnosis" and treatment. Be skeptical of any person who says that you or they have hypoglycemia without a thorough physical examination including a three to five hour glucose tolerance test.

## DUCT SYSTEM

The following is a description of the ducts connected to the liver, gall bladder, pancreas and duodenum.

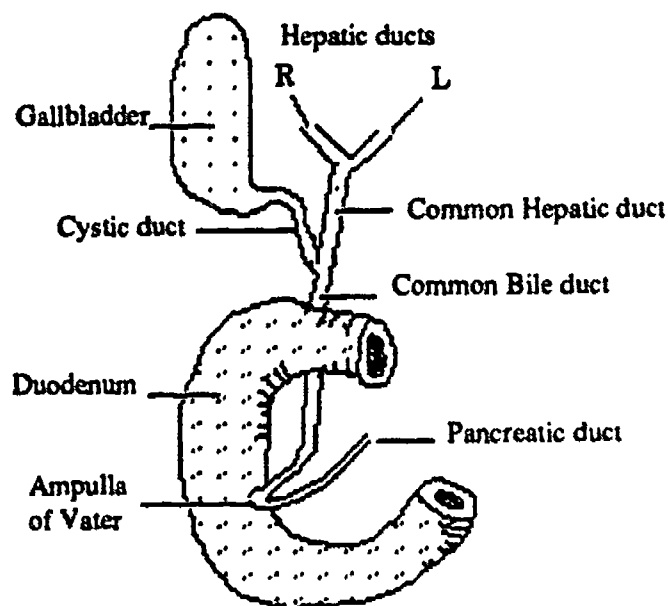
The bile ducts bringing bile out of the lobes of the liver are called the *right and left hepatic bile ducts*. They join to form the *common hepatic bile duct*. The bile duct leading to and from the gall bladder is called

the **cystic bile duct**. The cystic bile duct and the common hepatic bile duct join to form the **common bile duct** which goes to the duodenum.

Embryologically the pancreas begins in two areas, each with its own duct. Later these combine to become the head of the pancreas and the body of the pancreas. Usually only one of the original ducts remains as the **main pancreatic duct** or **duct of Wirsung**. If the second (smaller one) persists it is known as the **accessory pancreatic duct**.

The **ampulla of Vater** or **duodenal ampulla** is formed by the common bile duct joining with the pancreatic duct inside the duodenum.

The **sphincter of Oddi** surrounds the common bile duct only. It is the part of the muscularis externa (of the wall of the intestine) that surrounds the duct as it enters the ampulla of Vater. If the sphincter of Oddi is closed bile backs up into the gall bladder for storage and removal of water.



**Fig. 14- Duct System**

# Urinary System Lecture

## GROSS ANATOMY OF KIDNEY

### GENERAL DESCRIPTION

The kidney is *retroperitoneal* and lies against the posterior abdominal wall in the lumbar region, just below the twelfth rib and at the level of the umbilicus. It is held in place by fat padding.

The **hilum** of the kidney is the indented medial surface of the kidney where the renal artery and renal vein enter the kidney and the *ureter* exits. The hilum invaginates the kidney to form a nonfunctional pocket called the *renal sinus*.

The renal sinus encloses the major branches of the blood vessels, and the *renal pelvis*, which serves as an internal collecting basin for urine. The renal pelvis can be thought of as the expanded upper end of the ureter.

The kidney is surrounded by a *fibrous capsule* of connective tissue which enters the renal sinus at the hilum and is reflected back over the calyces and renal pelvis as their outer coverings.

### KIDNEY TISSUE

A lengthwise section of the kidney shows two general regions, the *medulla* or core tissue and the *cortex* or outer layer of tissue. The medulla is packed with straight tubules of various sizes running parallel to one another. The cortex contains the *renal corpuscles*, (the filtering units of the kidney) and the convoluted tubules.

In some animals, including humans, the medulla region is broken up into discrete units called *pyramids* because of their shape. The spaces between the pyramids are occupied by cortex tissue, and these areas are called the *renal columns*. The base of each pyramid (the broadest part) points toward the periphery of the kidney, and the *papilla* or apex points into a *minor calyx*. The base of the pyramid is not squared off, but instead

has extensions called *medullary rays*, which extend farther out into the cortex.

### MAJOR AND MINOR CALYX

A calyx is a funnel shaped structure that is part of the urine collection system. Each minor calyx surrounds the papilla of one pyramid, and thus receives the urine produced by that lobe of the kidney. Two or more minor calyces may fuse to form a major calyx. The major calyces in turn drain into the renal pelvis.

### LOBES/LOBULES

The kidney of humans is subdivided into 6-18 lobes. Each lobe consists of one medullary pyramid plus the overlying cortex. The lobes in turn are subdivided into lobules. Each lobule consists of one medullary ray plus the overlying cortex.

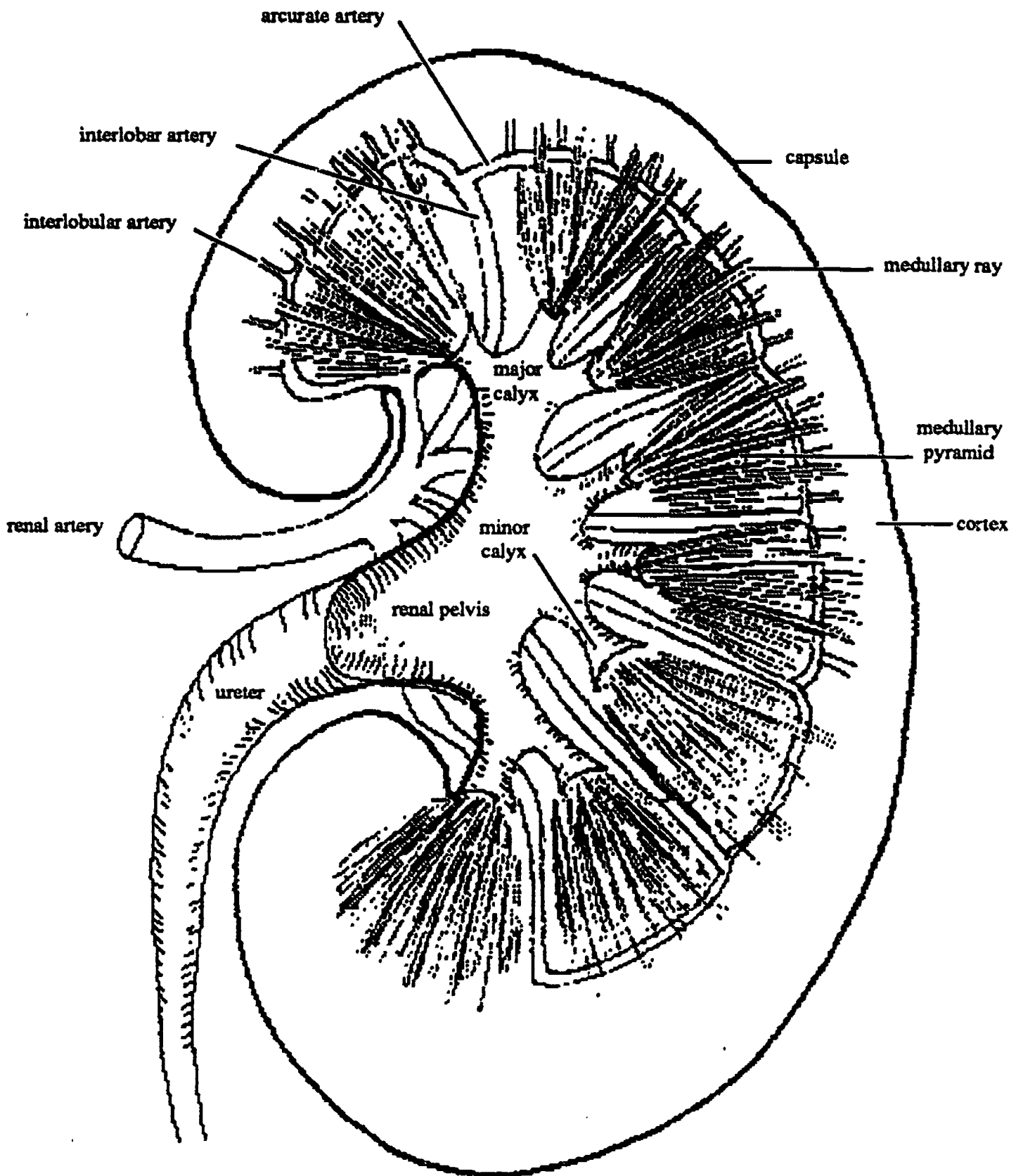
### BLOOD SUPPLY

The complete circulatory pathway listed in correct sequence is as follows:

- renal artery
- interlobar artery
- arcuate artery
- interlobular artery
- afferent arteriole
- glomerulus
- efferent arteriole
- peritubular capillary plexus (includes vasa recta)
- interlobular vein
- arcuate vein
- interlobar vein
- renal vein

Once the renal artery is inside the renal sinus it branches. These branches extend between each pyramid and are therefore called the *interlobar arteries*. Neighboring interlobar arteries anastomose and arch over the base of each pyramid as the *arcuate arteries*. These in turn give off vertical branches into the cortex between the medullary rays,





**Fig. 15- Gross Anatomy of the Kidney**

appropriately called the *interlobular arteries*. Each interlobular artery gives off multiple side branches (*afferent arterioles*), one to each *glomerulus*.

**RENAL PORTAL SYSTEM:**

A *glomerulus* is a capillary bed that looks like a small ball of yarn. Exiting from each

*glomerulus* is an *efferent arteriole* which leads to another capillary network the *peritubular capillary plexus* which surrounds the tubules of the nephron (and also includes some long loops called the *vasa recta*.) The peritubular capillary plexus drains into straight venules which carry the blood into the *interlobular vein*, and then into larger





veins all of which parallel the branches of the arteries, and have the same names: *arcuate vein, interlobar vein, renal vein*. Finally the renal vein drains into the inferior vena cava.

## THE NEPHRON UNIT

The nephron is the functional unit of the kidney. Each kidney contains many thousands of nephrons. A nephron consists of a filtering unit and an attached set of blood vessels and urine tubules.

## KIDNEY FUNCTIONS

The primary function of the kidney is the removal of nitrogenous wastes from the blood. The secondary function of the kidney is to maintain normal composition, volume, and pH of the blood and body fluids, *i.e.* to maintain normal electrolyte balance.

The nitrogenous wastes that need to be removed are the result of protein (specifically amino acid) catabolism, during which toxic ammonia by products are created. These ammonia by products of metabolism are converted to urea in the liver. Urea is also toxic, but less toxic than ammonia, especially if it is kept very dilute. So here is the dilemma: urea must be removed from the blood, but it cannot be selectively removed since that would bring the selecting cells into direct contact with poisonous urea.

The way this problem is solved is to create a very dilute renal filtrate containing urea and large amounts of water and salts and glucose, and then to reabsorb most of the water and salts and all of the glucose and put these reclaimed items back into the blood from whence they were taken when the filtrate was first formed.

Exactly how this is done can best be understood by examining the detailed anatomy of the nephron.

## NEPHRON EMBRYOLOGY

In the embryonic kidney thousands of blind ended immature nephrons and arterioles grow towards one another. These pairs will meet head on, and the arteriole invaginates the blind end of the nephron tubule. This process is analogous to punching your fist into a soft balloon or beach ball. The result is that the tip end of the nephron tubule (*Bowman's capsule*) ensheathes the growing arteriole, which in turn forms a capillary bed (*glomerulus*) inside the Bowman's capsule. (Together the glomerulus and Bowman's capsule are sometimes called the *renal corpuscle*.) Eventually a blood vessel works its way out of the glomerulus and becomes the efferent arteriole.

## ADULT NEPHRON ANATOMY

The parts of the nephron tubule listed in correct sequence are:

- Bowman's capsule (renal capsule)
- proximal convoluted tubule
- loop of Henle (including ascending and descending limbs)
- distal convoluted tubule
- collecting tubule

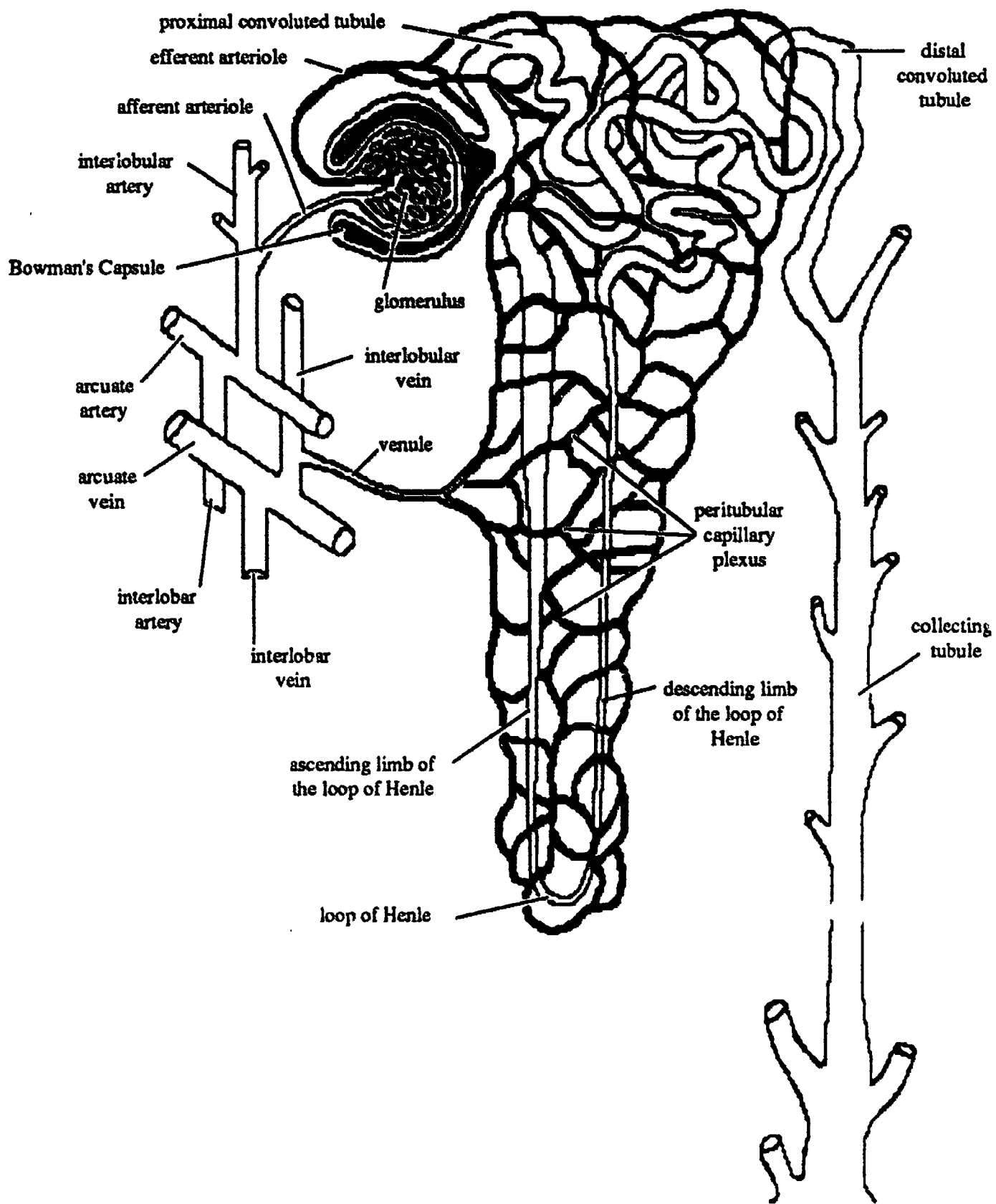
Each collecting tubule drains into a minor calyx.

## NEPHRON FUNCTION

### FORMATION OF CAPSULAR FILTRATE

The beginning stages of urine formation occur at the interface between the glomerulus and Bowman's capsule. These structures are both lined with simple squamous epithelium. The efferent arteriole is half as large as the afferent arteriole, thus the blood pressure in the glomerulus is higher than in most capillary beds. This pressure causes the filtrate to form. The filtrate is called *capsular filtrate*.

Blood cells and most protein molecules are too large to be filtered, but all other elements of the plasma are easily able to leave the capillaries, enter Bowman's capsule, and start down the tubules. Thus, the capsular filtrate contains large amounts of water, and



**Fig. 16- The Adult Nephron Unit**

it also contains urea, glucose, and various dissolved salts (electrolytes).

#### FILTRATE REABSORPTION

Most of the water and salts must be reclaimed, i.e. reabsorbed back into the blood, otherwise the person would rapidly die of dehydration and electrolyte imbalance.

Almost all parts of the kidney tubules are lined with cuboidal epithelium that have microvilli. These are the cells that reabsorb most of the capsular filtrate. The reabsorbed fluids are put back into the blood by way of the peritubular capillary plexus which then drains into the venous system. Only urea and other protein wastes from metabolism are not reabsorbed. These substances remain in the lumen of the tubules, pass into the collecting ducts and thence to the minor calyx, etc. until they are eventually excreted as urine.

#### REABSORPTION THRESHOLD

The reabsorption process involves both active and passive transport mechanisms. Glucose is reabsorbed by active transport from the proximal convoluted tubule. Active transport requires energy expenditure and the presence of highly specific enzymes, thus there may be a threshold (maximum rate limit) beyond which the substance can't be reabsorbed. This is particularly true of glucose (the glucose threshold).

#### FLUID VOLUMES

Approximately 180 liters of filtrate is formed per day (both kidneys). Reabsorption reciaims about 178 liters of fluid for every 180 liters of original filtrate. This is 99% of the filtrate. Only 1.5 to 2 liters is actually excreted as urine. (180 liters is approximately equal to 47 gallons, i.e. 9 five gallon carboys

About 20% of the plasma flowing through the kidney at any time is filtered. This means that the kidney takes about 20% of the urea out of the blood with each passage.

Water balance is mainly regulated by *antidi-*

*uretic hormone (ADH)* from the posterior pituitary gland. More ADH is released when the salt concentration of the blood is high. It acts on the distal convoluted tubules and collecting tubules of the kidney causing more water to be reabsorbed back into the blood from these areas. Conversely, when the salt in the blood is too diluted less ADH is secreted, and more water is excreted in the urine.

Salt reabsorption is regulated by the hormone aldosterone from the adrenal cortex. Aldosterone causes more  $\text{Na}^+$  ions to be reabsorbed, (increased water reabsorption will follow).

#### URINE COLLECTION SYSTEM

The collecting tubules of the medulla all drain into a cuplike subdivision of the renal pelvis called the *minor calyx*. Two or more minor calyces merge to form a *major calyx*, and the major calyces merge to form the *renal pelvis*. The renal pelvis is drained by a ureter which carries urine to the bladder. The two *ureters* are connected to the inferior surface of the bladder, which is also where the urethra exits. The three tubes attached to the bottom of the bladder create a formation called the *trigone* which can be seen from the interior of the bladder.

The bladder has two sphincters, an *internal sphincter* of smooth muscle and an *external sphincter* of voluntary muscle. The internal sphincter is the part of the muscle wall of the bladder which surrounds the beginning of the urethra; the external sphincter is part of the *urogenital diaphragm* which surrounds the urethra below the bladder.

The technical term for urination is *micturition*..

# Summary of Pathways

## CIRCULATORY PATHWAY

1. Renal artery
2. Interlobar artery
3. Arcuate arteries
4. Interlobular arteries
5. Afferent arteriole
6. Glomerulus
7. Efferent arteriole
8. Peritubular capillary plexus
9. Interlobular vein
10. Arcuate vein
11. Interlobar vein
12. Renal vein

## URINE PATHWAY

13. Bowman's Capsule
14. PCT
15. Loop of Henle
16. DCT
17. Collecting Tubule
18. Minor Calyx
19. Major Calyx
20. Pelvis of Kidney
21. Ureter
22. Bladder
23. Urethra

capsular filtrate





# The Reproductive System

## THE PERINEUM

The perineum is the floor of the pelvic cavity. Externally it is the region that the lay person would vulgarly refer to as the crotch. Anatomists divide the region into two triangular areas, the *anal triangle* and the *urogenital triangle*.

The structures in the anal triangle are identical in both male and female and therefore it will be discussed first. The structures in the urogenital triangle of male and female are homologous to one another, but not identical, so the urogenital triangle will be discussed separately for male and female.

## ANAL TRIANGLE

The three bony points of the anal triangle are the two ischial tuberosities and the coccyx. The floor of the pelvic cavity in the anal triangle is formed by a thin and steeply angled layer of skeletal muscle called the *levator ani*. The levator ani muscle layer is penetrated by one opening, the *anus*. The *sphincter ani externus* is voluntary muscle that surrounds the anal opening.

The anterior boarder of the anal triangle doubles as the posterior border of the urogenital triangle. It consists of a pair of narrow transverse muscles, the *superficial transverse perinei muscles*, that originate on the ischial tuberosity and insert on a midline spot of connective tissue called the *perineal body*.

## UROGENITAL TRIANGLE

The three bony points of the urogenital triangle are the two ischial tuberosities and the pubic symphysis. The floor of the pelvic cavity in the urogenital triangle is a thin layer of skeletal muscle known as the *urogenital diaphragm*. The urogenital diaphragm is penetrated by the urethra in both male and female, and by the vagina in the female.

There are three bodies of erectile tissue in the urogenital triangle of both the male and the female. The physical appearance of erectile tissue is best described by the terms *spongy* or *cavernous* because of the sponge like network of large cavernous blood sinuses which are empty most of the time, but fill with blood during sexual excitement. Certain parts of the erectile bodies are covered by thin layers of voluntary muscle which contracts during sexual excitement.

In the male all three bodies of erectile tissue found in the urogenital triangle participate in the formation of the penis. In the female two of the three bodies of erectile tissue form the clitoris and the third body of erectile tissue surrounds part of the vaginal canal and extends into the labia minora.

## PARTS OF THE PENIS

The male urogenital triangle contains the parts of the penis. The only other structure present is the scrotum (skin enclosing the testicle). The testicle will be discussed in another lecture.

### 1. CORPUS SPONGIOSUM

The central body of erectile tissue in the male is called the *corpus spongiosum* (also known as the *corpus cavernosum urethra* because it surrounds the part of the urethra known as the *spongy urethra*). In the male the urethra transmits semen as well as urine.

#### a. distal end

The distal end of the corpus cavernosum urethra is called the *glans penis*.

#### b. intermediate section

The intermediate section of the corpus cavernosum urethra forms part of the shaft of the penis.

#### c. proximal end

The proximal end of the corpus cavernosum urethra is called the *bulb of the penis* because of its bulbous shape. The

bulb of the penis is firmly attached to the perineal body in the urogenital triangle.

#### d. muscle covering

The bulb region is covered by a thin layer of skeletal muscle known as the *bulbo-cavernosus muscle*. Voluntary contraction of this muscle assists with erection by compressing the underlying veins, thereby trapping blood in the spongy erectile tissue. Reflex pulsations of this muscle cause ejaculation of the semen during the male climax.

## 2. CORPORA CAVERNOSA (OF THE PENIS)

On each side of the corpus cavernosum urethra is a pair of erectile bodies called the *corpora cavernosa of the penis*, or *corpora cavernosa* for short. Note the plural endings; when this term is used in the singular form it becomes *corpus cavernosum*.

#### a. distal end

The distal ends of the corpora cavernosa tuck in under the glans penis.

#### b. intermediate section

The intermediate portions of the two corpora cavernosa are the main components of the shaft of the penis (in which the corpus spongiosum also participates). The shaft of the penis is suspended from the pubic symphysis by connective tissue called the suspensory ligaments of the penis.

#### c. proximal end

The proximal end of each of the corpora cavernosa diverges (bends) laterally and is firmly attached to the ramus of the ischium. Because of this lateral bend, each of these sections of the corpus cavernosum is called a *crus* (plural form becomes *crura* of the corpora cavernosa of the penis).

#### d. muscle covering

Each crus is covered with a thin layer of skeletal muscle called the *ischiocavernosus muscle*. Contraction of these muscles assists with erection of the penis

by compressing the venous drainage from the erectile tissue.

## 3. PREPUCE

The prepuce or *foreskin* of the penis is a double fold of skin which is reflected back over the glans penis and connected to the glans penis by a frenulum. *Circumcision* (surgical removal of the prepuce) is customary in some cultures for religious or hygienic reasons. A sebaceous secretion known as *smegma* tends to collect under the foreskin.

## PARTS OF THE VULVA

The two regional terms used in discussing the female urogenital triangle are vulva and vestibule. *Vulva* is the more inclusive term; it refers to all of the female external genitalia, including the *mons veneris*, the *labia majora* and all parts of the *vestibule*. The labia majora are homologous to the scrotum of the male except that they do not contain the gonad.

## PARTS OF THE VESTIBULE

*Vestibule* refers to the *labia minora* and everything inside of them, namely the *clitoris*, the *vagina*, and the *urethral meatus*. The labia minora are folds of skin that contain erectile tissue which is part of the bulb of the vestibule.

### 1. CORPUS SPONGIOSUM

#### a. proximal end

The *bulb of the vestibule* in the female is homologous to the bulb of the penis in the male. It is a centrally placed mass of erectile tissue that surrounds the openings of the vagina and urethra and extends superficially into the labia minora. The main difference between the bulb of the vestibule and the bulb of the penis is that the bulb of the vestibule does not fuse in the midline.

#### b. intermediate section

In the female there is no intermediate section to the corpus spongiosum, i.e. the corpus spongiosum does not extend anteriorly to become part of the clitoris.

### c. distal end

There is no distal portion to the corpus spongiosum in the female, instead the glans of the clitoris migrates during its embryology to become part of the lateral corpora cavernosa of the clitoris.

### d. muscle covering

Just as in the male, the bulb is covered with a thin layer of voluntary muscle known as the *bulbocavernosus* muscle. During sexual excitation this muscle assists with engorgement of the female erectile tissue in much the same way that it does in the male.

## 2. CORPORA CAVERNOSA OF CLITORIS

On each side of the bulb of the vestibule is a pair of erectile bodies called the corpora cavernosa of the clitoris. They are almost exactly homologous to the corpora cavernosa of the penis.

### a. proximal end

The proximal end of each of the corpora cavernosa diverges laterally to become a *crus*, just as it does in the male.

### b. intermediate section

The intermediate portions of the two corpora cavernosa form the main *body of the clitoris*, which is approximately an inch in length.

### c. distal end

The distal ends of the corpora cavernosa of the clitoris are attached to the *glans clitoris*.

### d. muscle covering

Just as in the male, each crus is covered with a thin layer of skeletal muscle called the *ischiocavernosus* muscle. This voluntary muscle assists with erection of the clitoris during sexual excitation just as it does in the male.

## 3. PREPUCE

The prepuce of the female is more commonly known as the *hood* of the clitoris. Its frenulum is continuous with the labia minora.

Female "circumcision" is practiced by a few cultures, but the term is misplace since the surgical procedure actually being performed is *clitoridectomy*.

## HOW IT WORKS

### ERECTION

Sexual excitement (under the influence of the parasympathetic nervous system) causes the arteries supplying the erectile tissue to dilate, and a large quantity of blood under pressure enters the cavernous spaces. As the blood spaces fill they expand and compress the deep veins which drain blood out of these spaces, thus holding blood in the cavernous spaces.

Contraction of the bulbocavernosus and ischiocavernosus muscles assists with erection by compressing superficial veins and thereby restricting venous drainage, with the result that more blood enters the erectile tissue than leaves it, and the spongy tissue becomes turgid, firm and erect.

As sexual excitement subsides the arteries contract and muscular tension is reduced, therefore incoming blood flow is reduced and venous compression is lessened; blood is allowed to drain out and erection subsides.

In the female the clitoris and the bulb of the vestibule both become erect; swelling of the vestibule serves to increase the friction on the penis during coitus.

### ORGASM

The clitoris and penis are supplied with abundant sensory nerve fibers leading to the sacral and lumbar regions of the spinal cord stimulation of which can lead to a general buildup of sexual tension that culminates in a series of spinal reflexes (including sympathetic nervous system reflexes), accompanied by a sense of abrupt physiological and psychological release.

In the male these spinal reflexes includes ejaculation, the sudden propulsion of the semen out of the urethra. This is due to pul-



sating contractions of the bulbocavernosus muscle, and sequential contractions of the bulbourethral glands, then the prostate gland, ejaculatory ducts, and finally the seminal vesicles.

In the female orgasm is accompanied by rhythmic contraction of the perineal muscles, vagina, uterus, and fallopian tubes. These contractions probably aid in the transport of sperm cells.

Following orgasm, still under the direction of the sympathetic nervous system, blood flow to the erectile tissues is decreased and the erection subsides. Also, the muscles of the perineum relax, further aiding detumescence.

## REPRODUCTIVE ORGAN EMBRYOLOGY

The development of the sex of an embryo is determined primarily by genetic inheritance. In the body cells (somatic cells) of humans there are 23 different kinds of chromosomes, each of which can be recognized on sight by a skilled person, and each of which has been named, or rather numbered, from 1 to 23, with the last of the 23 different types being called the sex chromosomes, either x or y.

Our somatic cells all contain 2 copies of each of these 23 different types of chromosomes. Thus each body cell has 46 chromosomes in total. This doubled number is called the *diploid* number. With regard to chromosome number 23, the sex chromosome pair, females have an xx and males have an xy.

### GENETIC DETERMINANT

The physical development of the sex organs of an embryo is determined primarily by the presence or absence of the y chromosome, or to be more exact, by the presence or absence of a specific small section of the y chromosome. It has been known for some time that:

a. an abnormal individual with only a single x but no y chromosome (Turner's syndrome.) will develop as a female; sterile in humans, normal in the mouse.

b. an abnormal xxy individual (Klinefelter's syndrome) will develop as a male but with some female secondary characteristics, and often (but not always) with severe mental retardation.

c. an abnormal xyy will develop as an apparently normal male. There are some arguable studies indicating that such an individual may have "superaggressive" behavioral characteristics.

d. an abnormal embryo with only a single y chromosome is nonviable.

Scientists have long puzzled over how to explain the rare existence of xx males and xy females. Very recently (Dec. 23 1987, *Cell*) this has been shown to be the result of genetic *cross over* during production of the sperm cells. Cross over is a process wherein part of a chromosome winds around its partner during chromosome pairing (metaphase of meiosis), and then breaks away from the original chromosome and re-attaches to the partner. In this way short sections of a chromosome are sometimes exchanged between pairs of chromosomes. If cross over happens between the xy pair, the gene(s) on the y chromosome which determine maleness may cross over and become a part of the x chromosome. Subsequently, when this particular x carrying sperm cell fertilizes an egg the xx embryo will develop into a male because of the abnormal presence of the gene determining maleness on the x sperm cell. Likewise when the abnormal y sperm cell (lacking the male determining section) fertilizes an egg that particular xy embryo will develop into a female.

### HORMONAL DETERMINANT

Every vertebrate embryo of whatever gender, contains the *primordia* (immature



structures) for formation of both male and female reproductive systems. The development of one or the other system is largely controlled by testosterone concentrations during a specific window of time during embryonic development, and also by different sensitivities of the target organ tissues to the hormone. These factors are presumably regulated by the crucial section of the y chromosome discussed above.

The reproductive primordia consist of a double set of internal "plumbing" attached to the gonad, one male set and one female set. Only one of the double set of tubes and ducts develops into the mature reproductive tract, the other set degenerates and disappears. In the adult female the set that remains becomes the fallopian tubes and uterus. In the adult male the set that remains becomes the tubes and ducts that carry the sperm cells from the testicle to the urethra. If the gonads are removed from an early animal embryo both sets of plumbing remain in the undeveloped form.

In addition to the double "plumbing" each early embryo has a single set of structures in an indifferent stage of development, i.e. they could develop into either male or female structures. These structures become the ovary, the labia majora, the bulb of the vestibule, and the clitoris in the female. In the male these same structures become the testes, scrotum, and penis. Each structure has a *homologue* in the opposite sex.

## HOMOLOGUES

testes/ ovary

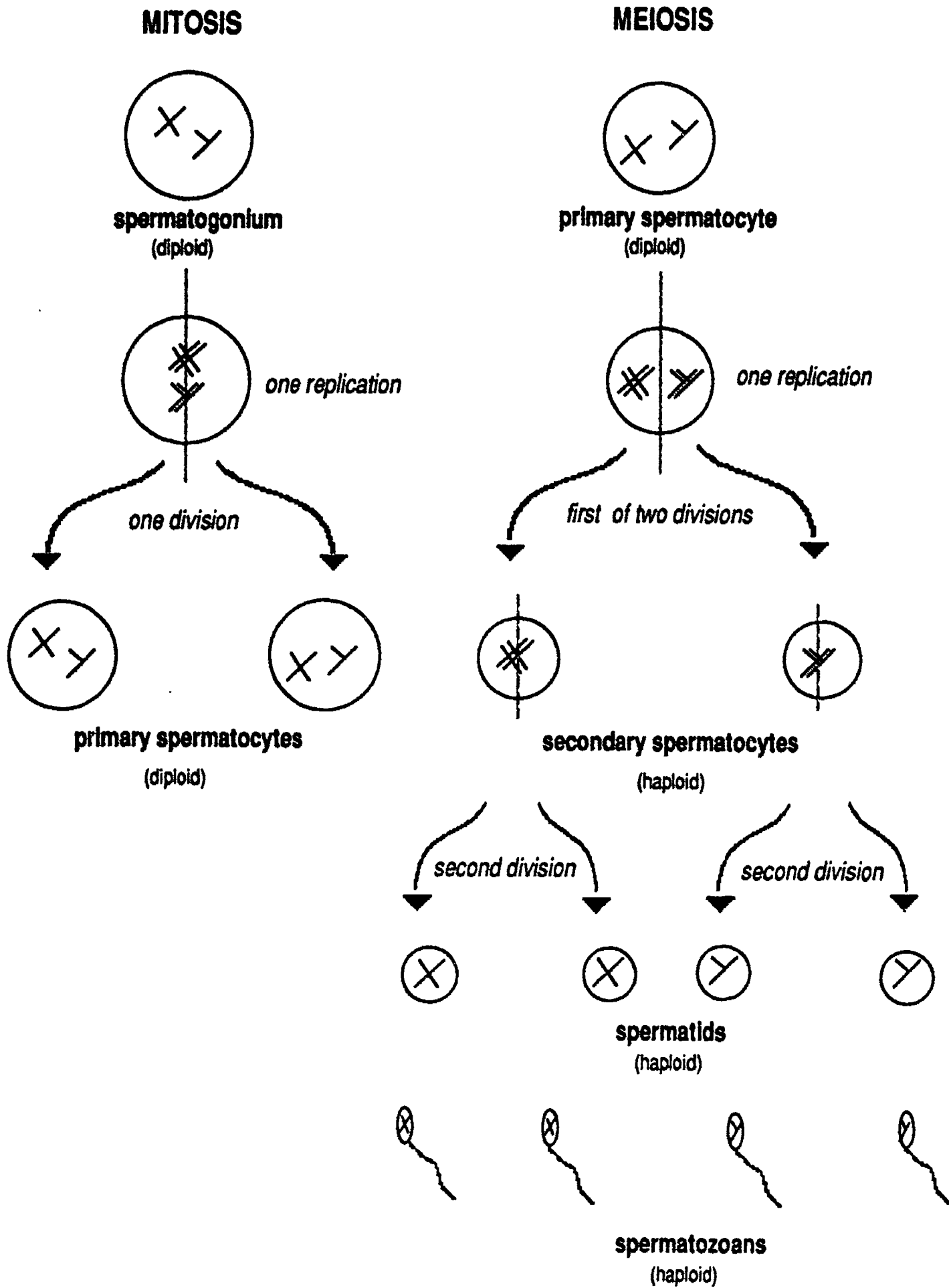
scrotum/ labia majora

bulb of penis/ bulb of vestibule

crura of penis/ crura of clitoris

glans of penis/ glans of clitoris

gubernaculum/gubernaculum



**Fig. 17- Spermatogenesis**

# MALE INTERNAL ORGANS

## THE TESTICLE

The testicle has two functions, namely gametogenesis (spermatogenesis) and male hormone production (testosterone).

### SPERMATOGENESIS

The sperm cells are produced from the inside epithelial lining of the *seminiferous tubules* in the testicles. There are many miles of these highly coiled tubules packed inside each testicle. The tubule epithelium in an immature male is of the simple cuboidal type; at puberty the epithelium starts dividing and becomes stratified cuboidal. With each subsequent division the daughter cells are pushed into the next layer of cell (toward the lumen of the tubules).

The basal layer of the *germinal epithelium* consists of cells called *spermatogonia* that have the usual diploid number of chromosomes (46). They duplicate by ordinary mitosis so that their daughter cells (layer 2, *primary spermatocytes*), also have 46 chromosomes. From the time of puberty on into old age primary spermatocytes are continually being produced by mitosis, so that no sperm cell is ever around for very long.

The primary spermatocytes undergo *meiosis*, a process that includes one replication of chromosomes followed by two divisions, (in contrast to mitosis which consists of one replication followed by one division) so that the chromosome number is reduced from diploid to *haploid*. Thus the daughter cells in layer 3, (*secondary spermatocytes*) and layer 4, (*spermatids*), have 23 chromosomes.

Each spermatid undergoes a maturation phase during which it develops a flagellum and becomes ready for its journey. During this time they bury their heads in and derive nourishment from the supportive *Sertoli cells*. Sertoli cells are large glycogen containing cells that extend from the basement membrane toward the lumen of the seminiferous tubule. A mature spermatid is

called a *spermatozoan*.

Spermatogenesis is *temperature dependent*; it requires a temperature considerably lower than that of the interior of the body. When the testes are in the scrotum they are kept cool enough for spermatogenesis to proceed normally.

### HORMONE PRODUCTION

In the interstices between seminiferous tubules there are cells known as the *interstitial cells* of the testes. These interstitial cells produce the male hormone *testosterone* which is responsible for the male secondary sexual characteristics and for male *libido*.

### MALE "PLUMBING"

The mature sperm cells migrate from the seminiferous tubules into the *straight tubules*, into the *rete testes*, into the *efferent ductules* and on into the *epididymis* for temporary storage. The epididymis is a very highly coiled tubular structure that is wrapped with a heavy layer of connective tissue. From a surface view the coiled tube cannot be seen, and it looks somewhat like a tadpole in that it has a head, body, and tail. The tail is directly continuous with the *ductus deferens* (old name = *vas deferens*). As the ductus deferens leaves the scrotum it passes through the body wall via the inguinal canal. Inside the abdominal cavity it hooks around the ureter, descends into the pelvic cavity, and enters the prostate gland where its name changes. The short section of duct inside the prostate gland is called the *ejaculatory duct*. From the ejaculatory duct the sperm cells next pass into the *prostatic urethra*, *membranous urethra*, and *spongy (penile) urethra*.

### ACCESSORY GLANDS AND SEMEN

The fluid that is ejaculated at the time of male orgasm is called the semen. It contains sperm cells and the alkaline secretions of three accessory glands.

### BULBOURETHRAL GLANDS

The bulbourethral glands are a pair of very small glands embedded in the urogenital

diaphragm layer of muscle. They also go by the older name of "Cowper's glands". The secretion they produce is a crystal clear mucoid material that has an alkaline pH. A drop of this mucoid secretion usually appears at the tip of the glans penis during sexual arousal. It acts as a lubricant to aid in intromission (penetration of the female) and its alkalinity helps to neutralize the natural acidity of the the male urethra preceding ejaculation.

#### PROSTATE

The prostate gland is a single walnut sized structure located immediately below the urinary bladder, and surrounding the urethra. It produces a thin, milky, alkaline secretion that accounts for most of the volume of the semen. The alkalinity of the secretion helps to neutralize the normal acidity of the female reproductive tract.

#### SEMINAL VESICLES

The seminal vesicles are a pair of elongated saclike glands located behind the bladder and connected to the ductus deferens. They produce a clear thick mucoid, alkaline secretion that is rich in the sugar fructose. The fructose probably serves as an energy source for the sperm cells as they make their journey through the female uterus and up into the fallopian tubes.

#### SPEERM CELL MOTILITY

The alkalinity of semen is important in that it helps protect the sperm from acid present in the male urethra and in the female vagina. Acid depresses sperm motility. Motility is greatest in a neutral or slightly alkaline environment.

The seminal fluids also contain **prostaglandins**, chemicals that are found in many tissues and have a wide variety of functions, but in the reproductive tracts they apparently aid in the transport of sperm cells toward the egg by causing **peristaltic waves** in the female reproductive tract.

The speed at which sperm cells can travel by virtue of flagellar action alone has been

clocked at 3 mm per min. That speed is insufficient to account for the fact that sperm cells appear in the upper ends of the female fallopian tubes 45 minutes after ejaculation. The distance involved is greater than can be accounted for by the flagellar movements of the sperm. This emphasizes the important contribution to sperm transport made by contractions of the female vagina and oviducts.

#### SEMINAL VOLUME

The volume of seminal fluid produced will vary depending on such factors as age and frequency of ejaculations, but on the average we can speak of volumes in the approximate range of 2.3 to 3.5 cc per ejaculation.

#### SPEERM NUMBERS

Sperm cells are present in very high numbers, but they do no account for much of the volume of the semen. The average sperm cell count is **100 million per cc** of semen. An individual is considered "sterile" if his sperm cell count drops to 20 million per cc, because his chances of fathering a child are practically zero in such a case. The idea that it only takes one sperm cell to fertilize an egg is misleading. Each sperm cell carries a small amount of the enzyme *hyaluronidase* in the *acrosome* region, and it takes millions of sperm cells, to contribute sufficient hyaluronidase to dissolve the hyaluronic acid (jelly coat) protecting the egg.

#### LIFE SPAN OF GAMETES

Sperm cells generally live for two to three days inside the female reproductive tract. Egg cells generally live for one to two days after ovulation. One consequence of these figures is that conception can result from sexual intercourse occurring both before and after the actual moment of ovulation.



# FEMALE INTERNAL ORGANS

## THE OVARY

The ovary has two functions, namely gametogenesis (oögenesis) and female hormone production (estrogen and progesterone).

### OÖGENESIS

During the third month of fetal life the *germinal epithelium*, which is the epithelium covering the outside of the ovary, produces groups of cells called *primary follicles* that leave the surface of the ovary and descend into the connective tissue stroma of the interior of the ovary. Each follicle consists of one *primary oöcyte* (egg) surrounded by a group of supporting cells called *follicular cells* or *granulosa cells*.

The primary follicles remain in a quiescent state until puberty. From puberty on several follicles each month begin to grow and develop; one of them will continue to develop; the others atrophy, leaving tiny white scars called *atretic follicles*.

Inside the developing follicle the oöcyte matures, and the granulosa cells increase in number and produce *follicular fluid* which collects in the *antrum* of the follicle. As the follicle enlarges and the pressure inside the antrum rises, the ovarian tissue covering the follicle becomes compressed, then ischemic, and finally necrotic. This fully ripe stage is known as the *Grädfian follicle*; when it ruptures (about day 14 of the cycle) the event is known as *ovulation*; The egg is released into the peritoneal cavity but is usually swept up by the fallopian tubes

Ovulation is usually somewhat painful due to the trauma suffered by the ovary, and also due to some minor irritation of the peritoneum (peritonitis) caused by the blood and follicular fluid entering the peritoneal cavity.

After ovulation the ruptured follicle heals and the metabolism of the granulosa cells changes so that they begin to accumulate lipids. The resultant structure is known as the *corpus luteum*. The length of existence

of the corpus luteum is dependent upon the fate of the ovum. If the egg is fertilized the corpus luteum will expand and persist for the first 3 to 4 months of the pregnancy. If pregnancy does not occur the corpus luteum lasts for about two weeks and then it involutes, leaving a large white scar called the *corpus albicans*.

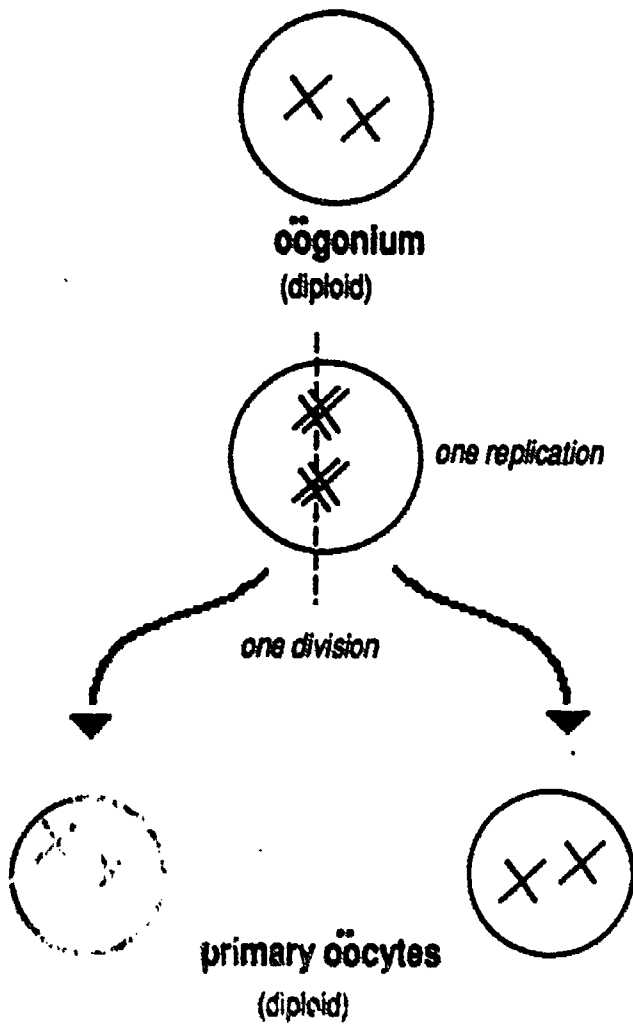
Several hundred thousand primary follicles are produced in the embryonic female; fewer than 500 of them will ever develop fully. The main point however is that all of the future eggs are sitting there waiting for the chance to develop, and while they are waiting they are subject to a variety of environmental insults, many of which (like X-Rays) are cumulative over a life time. For this reason, eggs released late in the life of the female are less likely to be viable than those released early in the childbearing years.

### HORMONE PRODUCTION

The cells of the ovarian stroma which are in immediate contact with the follicle (*theca interna* cells) produce the female hormone estrogen. More and more *estrogen* is produced day after day as the follicle enlarges, ruptures, and becomes a corpus luteum. Estrogen is responsible for the female secondary sexual characteristics and for female libido; it also acts on the uterus and breast preparing them for a possible pregnancy.

After ovulation the corpus luteum produces the hormone *progesterone*. Progesterone is secreted by the cells inside the corpus luteum which were formerly called *granulosa cells*, but which are now called *lutein cells*. In addition the corpus luteum continues to produce estrogen, but the cells which make the estrogen are now called *paralutein cells* (formerly theca interna cells). Progesterone acts on the uterus and breast to continue their preparation for a possible pregnancy.

# MITOSIS



# MEIOSIS

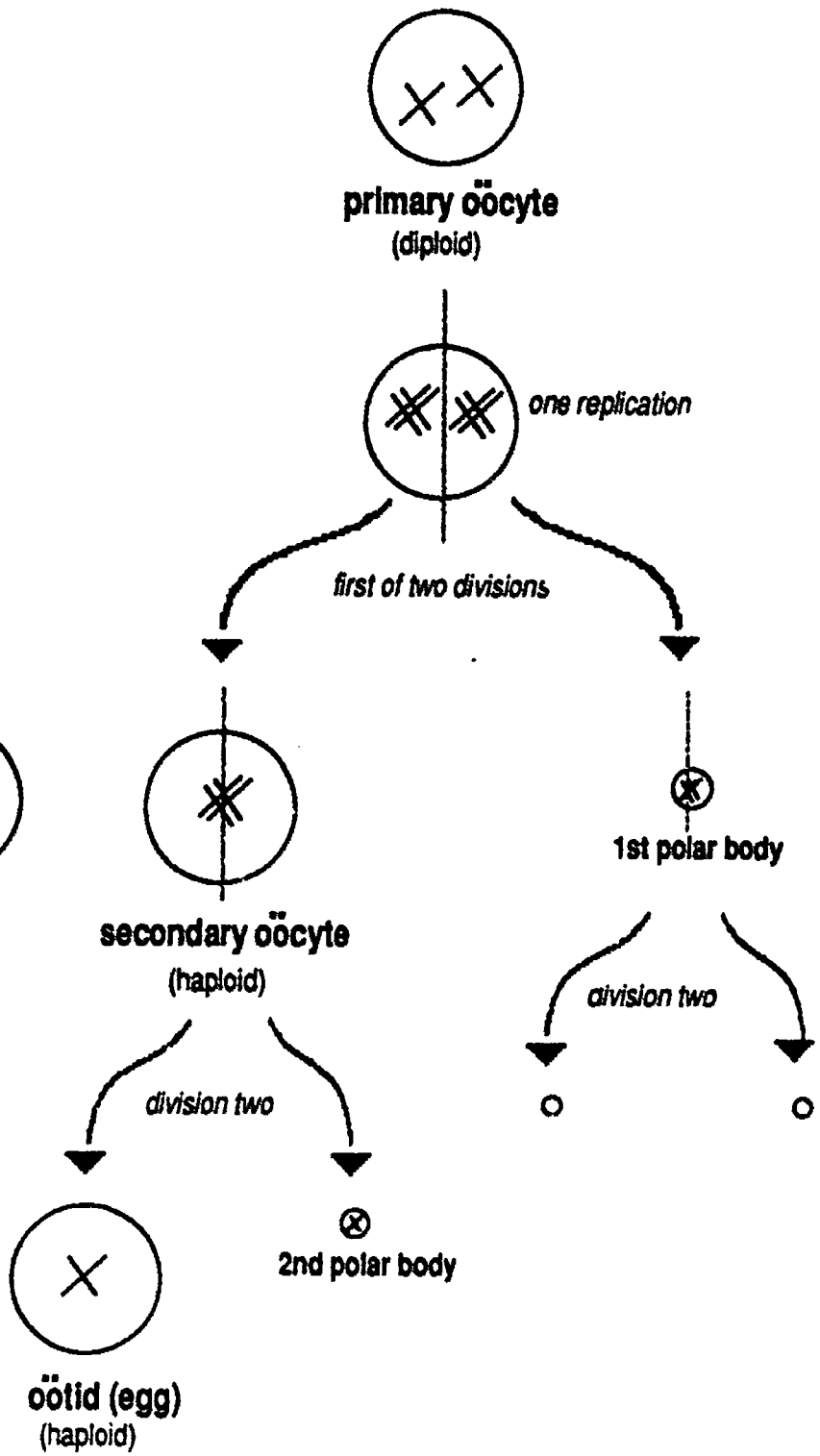


Fig. 18- Oögenesis

## FALLOPIAN TUBES & VAGINA

One end of each of the fallopian tubes ( or uterine tubes) is directly continuous with the uterus. The other end is expanded into a funnel shaped *infundibulum*, the margin of which is fimbriated (fringed). The *fimbria* and the inside surface of the fallopian tubes is lined with *cilia*, all of which beat toward the uterus, creating a ciliary current which transport the egg to the uterus. Fertilization usually occurs in the upper one third of the fallopian tubes. The egg usually lives for one to two days after ovulation.

The vagina is an expandable soft tissue tube leading from the cervix of the uterus to the vestibule. The fact that it attaches high on the sides of the cervix creates a pocket between the cervix and the vaginal wall, called the *fornix* or *fornices*. The *hymen* is a vestigial remnant of mucosal membrane that early in embryonic life covered the vaginal orifice.

## UTERUS

The uterus has three regions, body, fundus and cervix. The *body of the uterus* is the main part of the uterus. The *fundus* of the uterus is the bubble like region at the top, above the level of attachment of the fallopian tubes. The *cervix* is the neck of the uterus, which projects downward into the vagina. The opening in the center of the cervix, leading to the interior of the uterus is called the *os cervix*.

The normal position of the uterus is *anti-flexed*, i.e. bent forward over the bladder. A *retroflexed* uterus is one that is tipped into a straight line with the cervix or bent backward. It was once believed that a tipped uterus caused infertility.

The *vesicouterine* pouch is a peritoneal pocket located between the bladder and the uterus. Similarly, the *rectouterine* pouch is between the rectum and the uterus.

## LIGAMENTS OF THE UTERUS

The *broad ligament of the uterus* is a double fold of peritoneum which connects

the uterus to the body wall. Running through the broad ligament and extending from body wall to uterus to ovary, is a round cord that is a vestige of the gubernaculum. The part that is between body wall and uterus is called the *round ligament of the uterus*. The part that extends from uterus to ovary is called the *ovarian ligament*. The *suspensory ligament of the ovary* is actually just the ovarian artery and vein.

## UTERINE WALL

The smooth muscle in the wall of the uterus is called the *myometrium*. The stratified squamous epithelium lining the interior of the uterus is called the *endometrium*.

The uterine wall is responsive to the hormones produced by the ovary. The myometrium is kept relaxed and quiet by the hormone progesterone. The endometrium responds to both estrogen and progesterone. Estrogen causes the epithelium to proliferate (become thick and spongy), progesterone causes the epithelium to become secretory, and causes the unique spiral arteries to develop.

## THE MENSTRUAL CYCLE

The purpose of the menstrual cycle is to prepare the uterus freshly for each possible pregnancy. The average length of a menstrual cycle is 28 days. Day one is the first day when blood is seen externally. All of the changes in the uterus are correlated with ovarian follicle growth and with changes in blood hormone levels.

Abrupt withdrawal of estrogen and progesterone (when the corpus luteum involutes), causes cramplike waves of contraction in the myometrium, and causes the spiral arteries of the endometrium to undergo alternate constriction, dilation, and then constriction again. The initial constriction of the spiral arteries causes ischemia and then necrosis in the endometrium. When the arteries subsequently dilate the necrotic tips of the arteries will not hold the surge of blood under pressure, and the endometrium sloughs off

is a phenomenon known as menstruation. Bleeding only occurs for a short time; it stops when the spiral arteries constrict for the second time.

## BREAST

Breast tissue is mostly fat, but it also contains *lobules* that with extensive hormonal preparation and support will secrete milk. Each lobule is connected to the nipple by a duct. Each duct has a dilated portion called an *ampulla* immediately beneath the nipple. The *areola* is the deeply pigmented external skin of the breast surrounding the nipple. Each areola contains numerous *sebaceous glands*, the purpose of which is to keep the skin from drying and cracking during suckling. The suspensory ligaments of the breast are short tough strands of connective tissue that extend inward into the breast from the skin and underlying fascia.

In order to manufacture milk the breast tissue must be exposed to massive amounts of estrogen, progesterone, and prolactin (LTH) over a period of many months. The action of these hormones on the breast is called the *priming action*.

When a child suckles the *milk letdown reflex* is initiated. Suckling causes the hormone oxytocin to be released from the posterior pituitary, and oxytocin causes the lobules and ducts of the breast to contract, ejecting milk into the mouth of the child.

## ENDOCRINE MECHANISMS

### INTRODUCTION

In the male, hypothalamic hormones control the anterior pituitary, and pituitary hormones in turn control the testicle. The male is non-cyclic, *i.e.* the hormones and sperm cells are secreted on a steady state basis.

In the female hypothalamic hormones control the anterior pituitary, pituitary hormones control the ovary, and ovarian hormones control the uterus and also shut off the hypothalamic hormones. Thus the female is cyclic; one egg is produced each month, and a fresh uterine lining is prepared for each new egg.

### HYPOTHALAMIC HORMONES

The hormones of the hypothalamus which control the anterior pituitary are called releasing factors or releasing hormones. There are two important ones: *FSH-RH* (follicle stimulating hormone releasing factor) and *LH-RF* (luteinizing hormone releasing factor).

In both male and female FSH-RH causes the pituitary to secrete FSH, and LH-RH causes the pituitary to secrete LH (LH is called ICSH in males).

### ANTERIOR PITUITARY HORMONES

The hormones of the anterior pituitary gland which stimulate the gonads are called by the group name gonadotropic hormones. There are three of them; they were first discovered in female animals and were named according to their functions in the female.

#### FSH

Follicle stimulating hormone in the female stimulates follicle growth with the result that an egg is prepared for ovulation and estrogen is secreted, which in turn prepares the uterus.

Follicle stimulating hormone in the male stimulates the spermatogenic epithelium of the seminiferous tubules to produce sperm cells.



### **LH (ICSH)**

Luteinizing hormone in the female causes ovulation and subsequent corpus luteum formation, with the result that progesterone is secreted, which in turn augments the preparation of the uterus.

Interstitial cell stimulating hormone in the male stimulates the interstitial cells to produce testosterone.

### **LTH**

Luteotropic hormone, also known as *prolactin*, stimulates breast development and milk secretion, and keeps the corpus luteum healthy.

## **NEGATIVE FEEDBACK LOOPS**

Negative feedback loops occur only in the female; they are responsible for the cyclic nature of the female reproductive system.

*A rising estrogen titer* will shut off FSH-RH so that no new follicles are allowed to develop until the fate of the first egg is determined. (Rising progesterone titer may perhaps also stimulate the secretion of LTH (prolactin) by the pituitary)

*A rising progesterone titer* will shut off LH-RH so that no further ovulations are allowed until the fate of the first egg is determined. Rising progesterone may perhaps also stimulate the secretion of LTH (prolactin) by the pituitary).

If a pregnancy occurs the placenta secretes estrogen, progesterone, and also *HCG* (human chorionic gonadotropin. HCG stimulates the further development of the corpus luteum, and therefore reinforces the high levels of estrogen and progesterone, ensuring that the placenta remains in place in the uterus.

If pregnancy does not occur, no HCG is made, and therefore the corpus luteum involutes and progesterone and estrogen levels fall. This decrease causes menstruation, and also allows FSH-RH and LH-RH to be secreted so that the cycle begins all over again.

# Respiratory System

## FUNCTIONS

The respiratory system has two main functions: gas exchange and air conditioning.

### GAS EXCHANGE

#### EPITHELIUM OF ALVEOLI

Diffusion of gasses is maximized by presenting the thinnest possible barrier between the air in the alveoli and the blood capillaries. Thus the epithelium of the alveoli is of the simple squamous type.

#### PROXIMITY OF CAPILLARIES

The capillary network of the lungs is very rich and extensive, and the capillaries are very closely applied to the outside surface of the alveoli. The epithelium of the capillaries is also simple squamous.

#### ELASTIC CONNECTIVE TISSUE

The connective tissue between alveoli and capillaries is kept to a minimum, but what little there is, is elastic connective tissue.

The elastic recoil of this connective tissue is a very important factor in flushing dead air out of the lungs during expiration.

### AIR CONDITIONING

*Standard respiratory epithelium* is responsible for the air conditioning functions of the respiratory system. By definition, standard respiratory epithelium is *pseudostratified columnar with cilia and goblet cells*.

#### WARMING

When air passes over the mucous membranes of the nasal passages, sinuses, and conduit system, the air is warmed by picking up heat from the underlying blood vessels.

#### MOISTENING

Moisture is added to the air from the serous and mucous secretions produced by the mucous membrane.

#### FILTERING

Filtering is accomplished first by the hairs in the nose which screen out the larger dust particles, and second by the combined action

of cilia and mucous. Small particulate matter falls out of the airstream by gravity as air speed decreases in the depths of the respiratory tree. The particles stick to the mucous on the surface of the epithelium. Ciliary beating then clears the mucous by creating currents that stream toward the throat where small quantities are swallowed and larger quantities are coughed up.

## NASAL CAVITY

### NASAL CONCHAE

The superior, middle and inferior conchae or turbinate bones of the nasal cavity create currents and eddies that slow the passage of the air stream and divert some of it into the paranasal sinuses. This slowing of the air stream, along with the increased surface area, aids the air conditioning functions of the epithelium.

### PARANASAL SINUSES

The paranasal sinuses lighten the weight of the skull, provide expanded surface area for the nasal mucosa, and act as resonance chambers for the voice. The paranasal sinuses drain into the nasal cavity.

### NASAL MEATUSES

The word meatus is used slightly out of context in this instance. Usually the word meatus means *opening*, but by definition a nasal meatus is the space beneath a nasal conchae. Thus, the **superior meatus** is the area beneath the superior concha, the **middle meatus** is the area beneath the middle concha, and the **inferior meatus** is the area beneath the inferior concha. In addition, the area above the superior concha is called the **sphenoethmoidal recess**. Each meatus is the receiving area for a small canal connecting one or more of the paranasal sinuses to the nasal cavity. In addition, the **nasolacrimal duct** (tear duct) drains into one of the meatuses, into the inferior meatus to be

precise. All of this drainage pattern information is summarized in the chart that follows:

**Fig. 19- Sinus Drainage Pattern**

NAME OF CAVITY	DRAINAGE SITE
Sphenoid Sinus	Sphenoethmoidal Recess
Ethmoidal Air Cells	Superior Meatus
Frontal Sinuses	Middle Meatus
Maxillary Sinuses	Middle Meatus
Nasolacrimal Duct	Inferior Meatus

## PHARYNX

There are three parts to the pharynx (throat): nasopharynx, oropharynx, and laryngopharynx. Each will be discussed in the following paragraphs.

### NASOPHARYNX

The Nasopharynx is the part of the throat that is above the soft palate. The epithelium of this region is standard respiratory epithelium because it normally comes in contact with air only, not food or water. The structures found in the nasopharynx are the following:

#### EUSTACHIAN TUBE OPENINGS

The eustachian tubes are soft tissue tubes that lead from the throat to the chamber of the middle ear. The purpose of the tube is to allow ambient air to enter the middle ear chamber so that the air pressure on the inside of the tympanic membrane (ear drum) is equal to the air pressure on the outside of the tympanic membrane. The openings of these tubes look like narrow slits in the roof of the nasopharynx.

#### PHARYNGEAL TONSIL (ADENOIDS)

The pharyngeal tonsil is a single patch of friable nonencapsulated lymphoid tissue on the roof of the nasopharynx in the midline between the openings of the two eustachian

tubes. This tonsil, (along with the less important tubal tonsils sometimes seen as a slight swelling around the opening of the eustachian tube), guards the entrance to the eustachian tubes. The purpose of these tonsils is to help prevent throat infections from spreading to the middle ear and mastoid sinuses.

### OROPHARYNX

The oropharynx is the part of the throat directly to the rear of the oral cavity. The epithelium of this region is oral epithelium because it normally comes in contact with food and drink as well as air. Oral epithelium is stratified squamous epithelium. The structures found in the oropharynx are the following:

#### UVULA

This structure is simply part of the soft palate that hangs down from the palate into the oropharynx. During coughing and swallowing, the soft palate contracts against the posterior wall of the throat, closing off the nasopharynx so that food and drink do not travel upwards into the nasopharynx. The uvula participates in this action, but otherwise has no special function.

#### PALATINE ARCHES

The palatine arches are the soft tissue walls of the lateral throat at the posterior end of the soft palate.

#### PALATINE TONSILS

The palatine tonsils are two discrete oval encapsulated nodes of lymphoid tissue found nestled in the palatine arches on each side of the throat at the lower entrance to the nasopharynx. Two thirds of their bulk is hidden beneath the epithelium, one third projects freely upward. A good analogy is an iceberg, only the tip of which shows above the surface of the water. These tonsils try to prevent nasopharynx infections from spreading into the oro- and laryngopharynx.

### LARYNGOPHARYNX

The laryngopharynx is the region of the throat right around the epiglottis, which is the most superior part of the larynx. When



relaxed, the epiglottis projects upward into the laryngopharynx. The epithelium of this region is mostly of the oral type because it comes in contact with food and water during swallowing. The one exception is the inferior surface of the *epiglottis*, which closes down over the glottis during swallowing, and hence does not come in contact with food. This surface is normally covered with standard respiratory epithelium. In smokers the epithelium is transformed to stratified squamous due to the abrasive nature of smoke particles.

## LARYNX

The larynx (voice box) lies below the pharynx, below the hyoid bone, and above the trachea in the anterior neck (see Fig. 20A). It has a skeleton constructed of nine separate pieces of cartilage, is lined with standard respiratory epithelium, and houses the vocal cords. It also serves as the entryway to the trachea and lungs.

Abrasion or vibration cause the standard respiratory epithelium of the larynx to convert to stratified squamous epithelium. Therefore the vocal cords because of their vibration, are covered with stratified squamous epithelium, and in smokers the epithelium of the larynx may be transformed to stratified squamous due to the abrasive action of smoke particles.

The opening (space) between the vocal cords is called the *glottis*. Only air passes through the glottis. Muscles attached to the arytenoid cartilages adjust the size of the glottis and also adjust the amount of tension on the vocal cords. The glottis is wide open

during breathing. It is closed completely in preparation for sneezing and coughing, then opened suddenly so that air explosively exits, the purpose being to dislodge an irritant from the respiratory passages.

## EPIGLOTTIS

The epiglottis is the most superior cartilage of the larynx. It projects upwards and slightly posteriorly into the cavity of the larynx. During swallowing the epiglottis remains relatively stationary and the rest of the larynx is raised up to it so that the epiglottis effectively covers the glottis (opening leading to the larynx and trachea).

## THYROID CARTILAGE

The common name for this cartilage is "Adam's apple". The cartilage is an incomplete ring (horseshoe shaped) with the "open" part of the horseshoe facing posteriorly. The anterior side of the

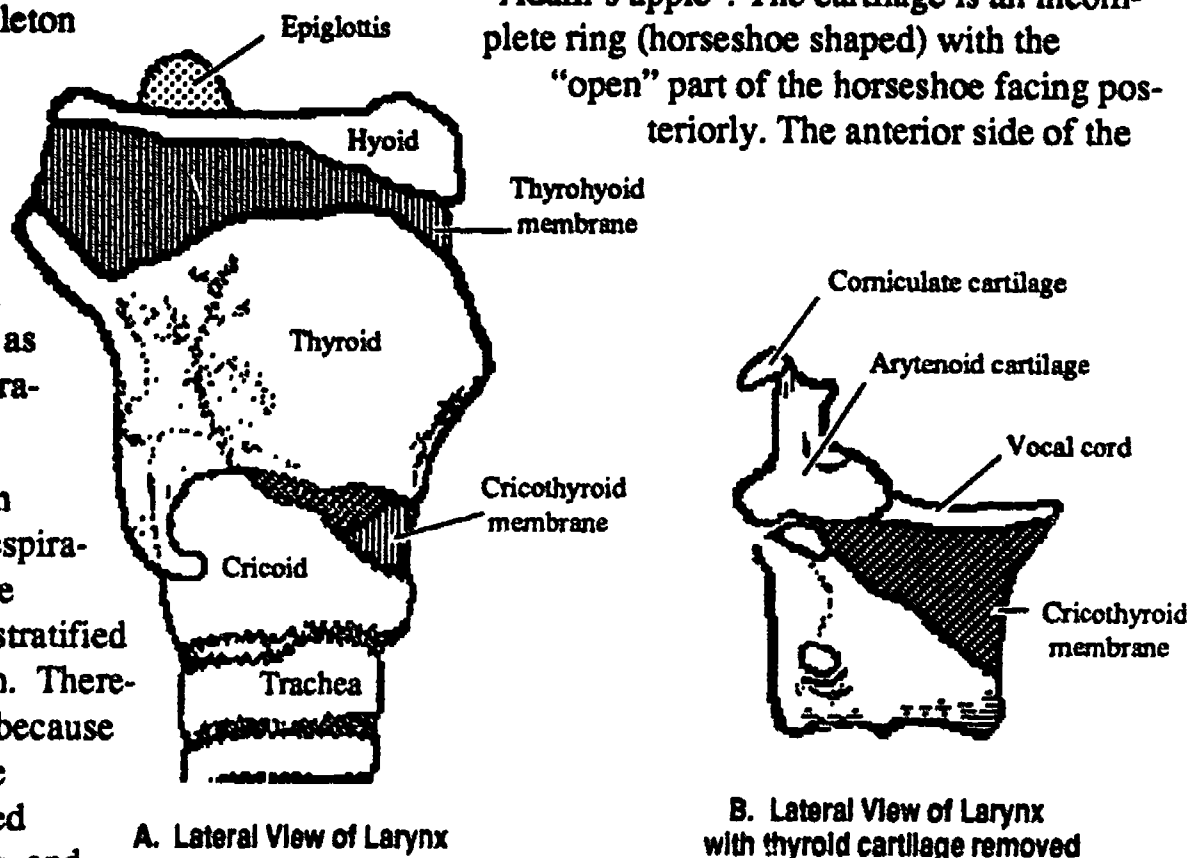


Fig. 20- Cartilage Skeleton of the Larynx

ring is formed by two large flat plates joined in the midline at an angle to one another to form the laryngeal prominence. The angle at which these plates join, and the overall size of the thyroid cartilage is affected by the male hormone testosterone which begins to be secreted in large quantities at the time of puberty. This accounts for the voice changes



in males at puberty. See below under "vocal cords" for more detailed information.

## CRICOID CARTILAGE

The cricoid cartilage is below the thyroid cartilage. It is a complete ring of cartilage shaped like a class ring. The anterior side of the cartilage ring is narrow and the posterior side is enlarged, analogous to the palmar and dorsal surfaces of a class ring.

Connecting the cricoid and thyroid cartilages anteriorly is a thin connective tissue membrane called the cricothyroid membrane. This is the membrane that is punctured during emergency tracheostomy procedures. It is safely below the vocal cords and is not crossed by any important muscle, artery or nerve.

## ARYTENOID CARTILAGES

The two arytenoid cartilages sit on top of the cricoid cartilage on its posterior side. They are small and somewhat triangular in shape. Muscles attached to the arytenoid cartilages cause them to rotate, which in turn changes the tension on the vocal cords and adjusts the size of the glottis.

## CORNICULATE CARTILAGES

The two corniculate cartilages are very small and shaped like pieces of candy corn. They sit on the top of each arytenoid cartilage.

## CUNEIFORM CARTILAGES

The two cuneiform cartilages are extremely small and elongated. They are anterior to the arytenoid and corniculate cartilages in the edge of the aryepiglottic membrane, a mucous membrane which connects the arytenoid cartilage to the epiglottis.

## VOCAL CORDS

Each vocal cord or vocal fold is composed of multiple strands of tough collagenous connective tissue fibers. The cords are covered with stratified squamous epithelium. Each is attached to a corner of an arytenoid cartilage posteriorly, and to the interior surface of the laryngeal prominence anteriorly (see Fig. 21).

The false vocal cords or ventricular folds are simply slack portions of the mucous membrane in the interior of the larynx. They can be made to disappear if stretched and are of no functional importance. They are given their name due to the fact that they are easily mistaken for the actual vocal cords. They lie above the true cords and are the first folds seen when examining a patient's throat.

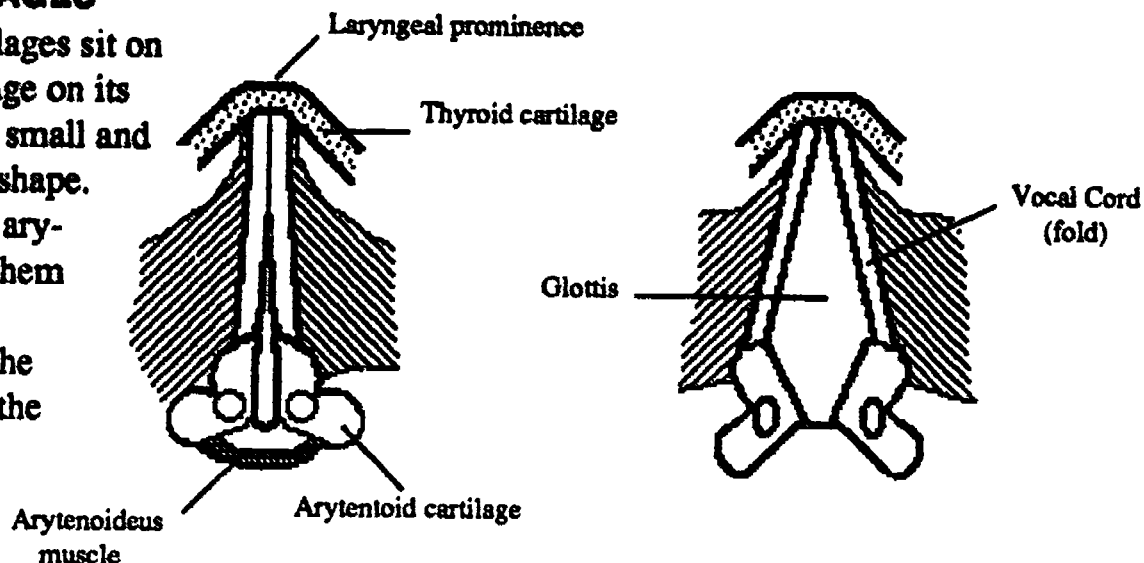


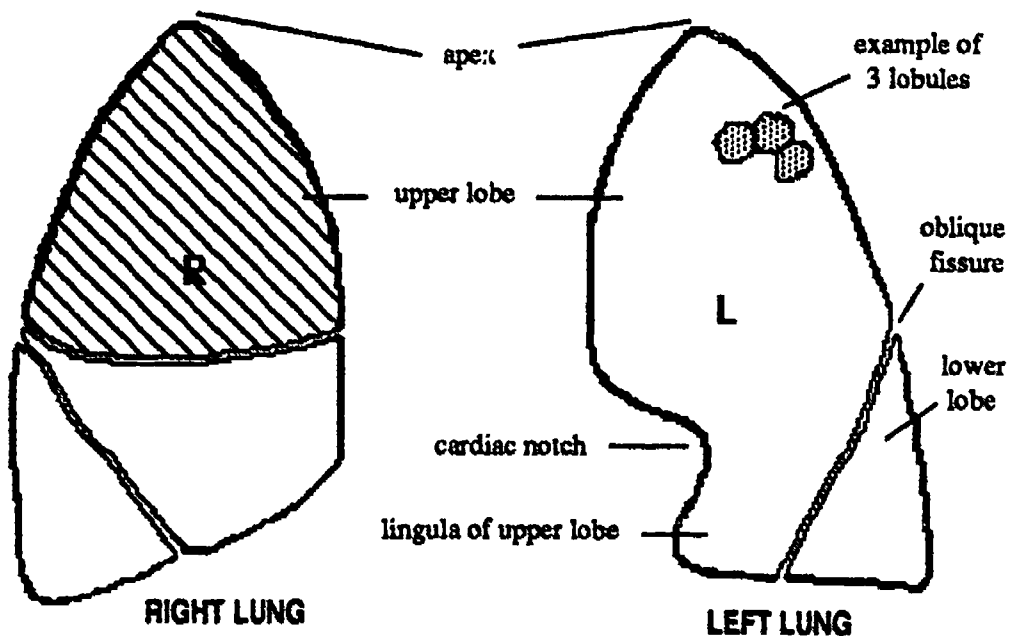
Fig. 21- Vocal Cords and Glottis, Superior View

## VOICE CHANGES

*Testosterone* causes the thyroid cartilage to enlarge overall; it also causes the angle at which the flat plates of the thyroid cartilage meet to become more acute. The effect that this has on the vocal cords is to cause them to lengthen. As with any stringed musical instrument, longer strings vibrate more slowly and thus produce a lower pitch. These physical changes therefore cause the male's voice to deepen.

# LUNG

The lung itself is very light spongy, and highly elastic. The hilum or root of the lung is the area where the bronchi and pulmonary vessels are attached and where the pleural layers reflect back upon one another. The base of the lung refers to the surface which is next to the diaphragm. The apex of the lung is the rounded top portion of the upper lobe. It rises above the clavicle so that surprisingly part of the lung actually extends into the neck.

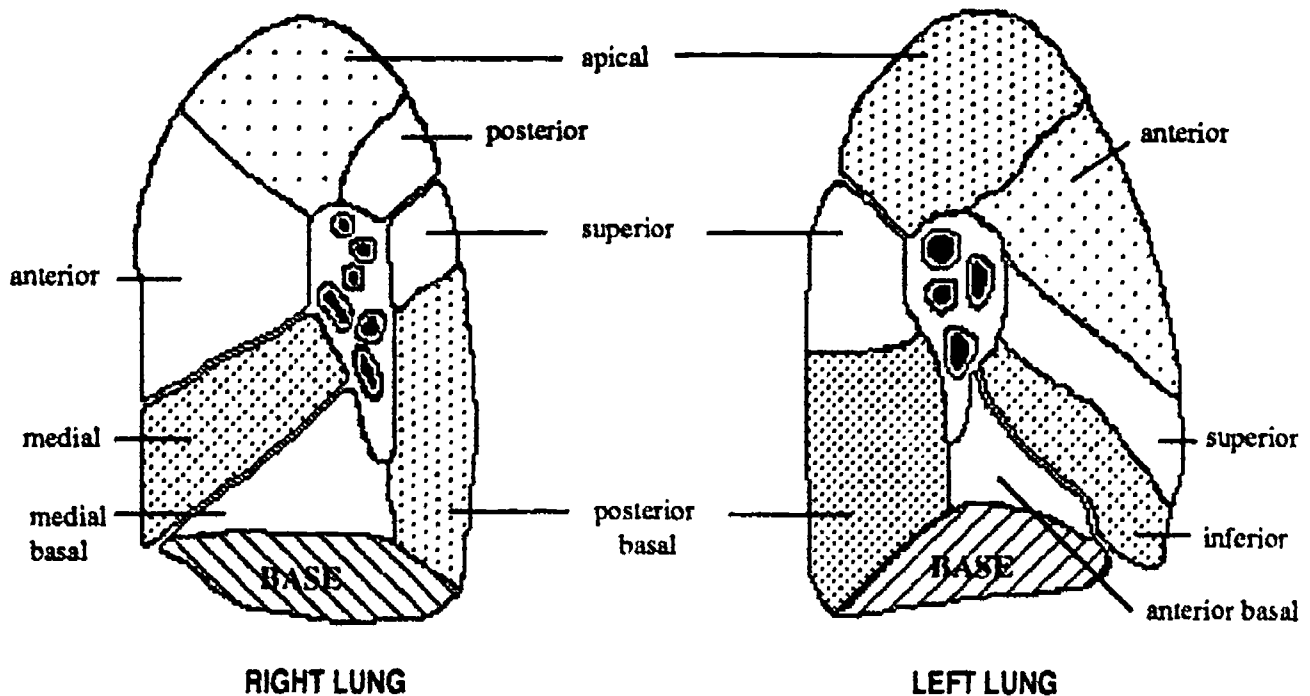


**Fig. 22- Lobes and Lobules of the Lung**

The left lung has 2 lobes, the right lung has 3 lobes. From the lobes on down the subdivisions are the same for both lungs.

- lobes
- bronchopulmonary segments
- lobules
- respiratory units
- alveolar sacs
- alveoli

Bronchopulmonary segments have clinical significance in that they are the smallest subsection of the lung that can be removed surgically; removal of anything smaller creates air leaks that cannot be sealed.



**Fig. 23- Bronchopulmonary Segments as seen from seen from the hilum of the lung**

# RESPIRATORY TREE

The branches of the respiratory tree are intimately connected with the subdivisions of the lung itself, and each branching of the respiratory tubes is accompanied by similar branchings of the pulmonary arteries and veins.

As the respiratory tree branches the walls of the tubules become thinner and thinner until finally at the bottom of the lung there is a minimum barrier to gas exchange between the alveoli and the capillaries.

First the amount of cartilage is decreased until it disappears, then the epithelium is gradually simplified, and finally smooth muscle disappears. At the bottom of the lung, the alveoli are lined with simple squamous epithelium accompanied by a few macrophage cells (dust cells) and reinforced by a small amount of elastic connective tissue. Watch for these changes in the descriptions that follow.

## TRACHEA

The trachea or windpipe lies below the larynx and anterior to the esophagus in the anterior neck. It begins at vertebral level C<sub>6</sub> and ends by bifurcating (forming the two primary bronchi) at level T<sub>4</sub>.

The trachea is kept *patent* (open) by the cartilages in its wall. These horseshoe shaped rings of cartilage are filled in at the back by the trachealis muscle (membrane), which embryologically was part of the wall of the esophagus.

The interior epithelium of the trachea is standard respiratory epithelium. The mucosa contains smooth muscle (muscularis mucosa), and the submucosa contains cartilage.

## PRIMARY BRONCHI

The right primary bronchus leads to the right lung, and the left primary bronchus leads to the left lung. The right primary bronchus is shorter, wider, and more vertical than the left primary bronchus. For this reason aspirated objects usually lodge in the right side of the respiratory tree (see Figs. 24 & 25).

The epithelium of the primary bronchi is standard respiratory epithelium. The mucosa contains smooth muscle and the submucosa contains cartilage. The cartilage in the submucosa of these bronchi is in the form of complete rings.

## SECONDARY (LOBAR) BRONCHI

The secondary bronchi are the branches of the primary bronchi. Each secondary bronchus leads to one of the lobes of the lung. There are three secondary bronchi on the right side and two on the left, corresponding to the fact that the right lung has three lobes and the left lung has two lobes.

The epithelium of the secondary bronchi is standard respiratory epithelium. The mucosa contains smooth muscle and the submucosa contains overlapping plates of cartilage rather than complete rings.

The mucosa contains smooth muscle and the submucosa contains overlapping plates of cartilage rather than complete rings.

## TERTIARY (SEGMENTAL) BRONCHI

Each secondary bronchus divides into two or sometimes three tertiary bronchi. Each tertiary bronchus supplies a subunit of a lobe known as a *bronchopulmonary segment*. (see Fig. 23).

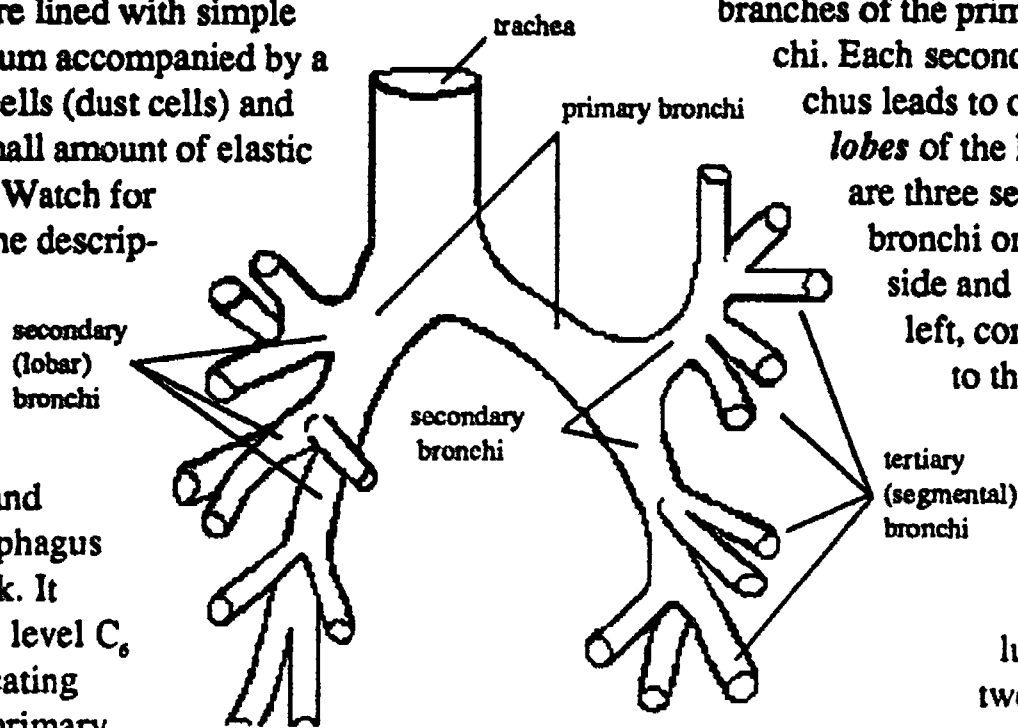


Fig. 24- Major Divisions of the Bronchi, primary, secondary, tertiary

The right lung has 10 bronchopulmonary segments, the left lung has 8 or 10 segments.

The epithelium of the tertiary bronchi is standard respiratory epithelium. The mucosa contains smooth muscle and the submucosa contains *cartilage plates that do not overlap*.

### BRONCHIOLES

Each tertiary bronchus divides into numerous bronchioles which by definition are 1 mm in diameter (see Fig. 25). Each bronchiole supplies a subunit of a bronchopulmonary segment known as a *lobule* (see Figs. 22 & 25).

The epithelium of the bronchiole is standard respiratory epithelium. The mucosa contains smooth muscle but the submucosa *lacks cartilage*.

There is no cartilage in the wall of a bronchiole or in any of the smaller tubes which follow.

### TERMINAL BRONCHIOLES

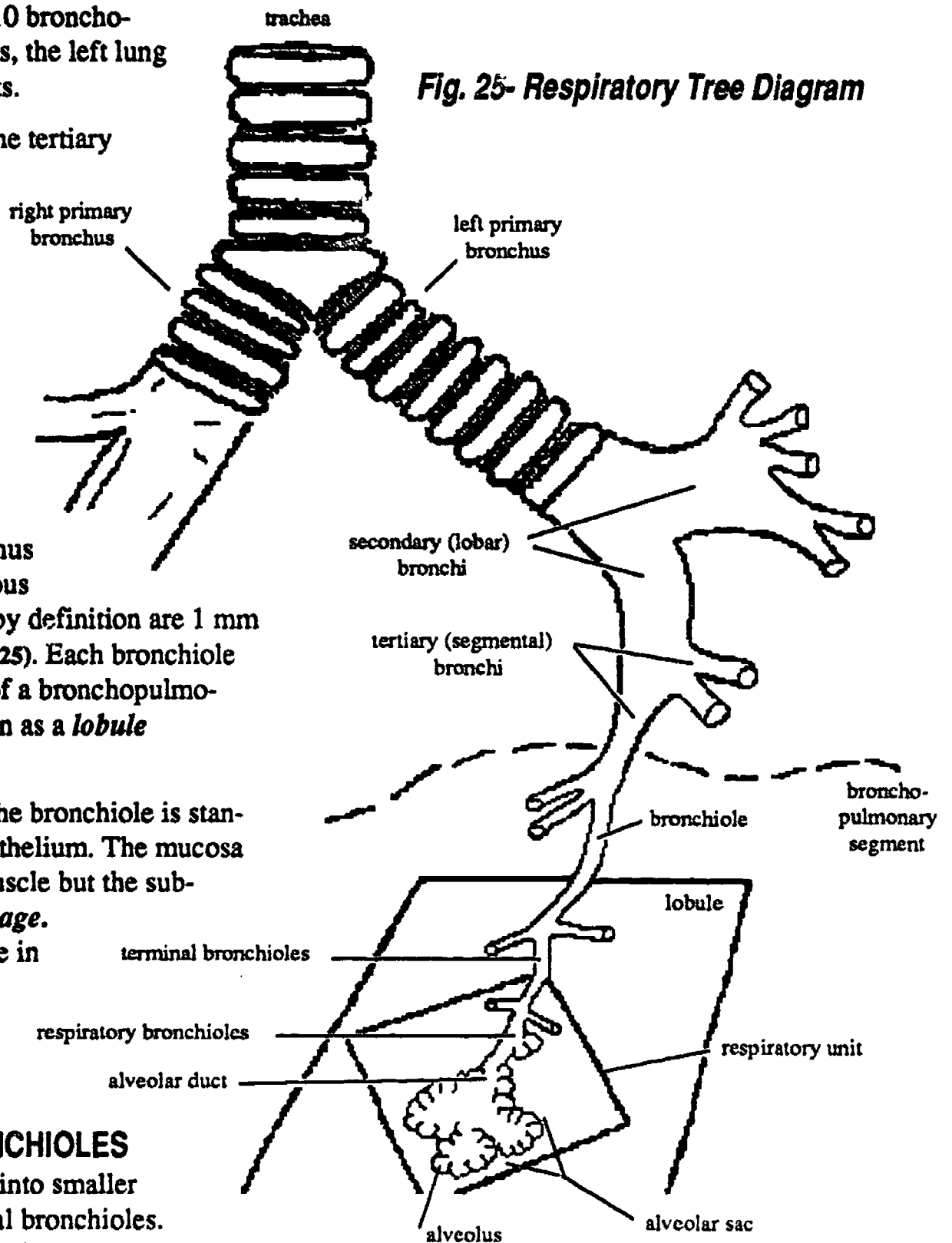
Bronchioles divide into smaller tubes called terminal bronchioles. Each terminal bronchiole supplies a subunit of a lobule known as a *respiratory unit*. (See Fig. 25)

The epithelium of the terminal bronchiole *lacks goblet cells* and is therefore simple columnar rather than pseudostratified columnar. Smooth muscle is still present in the mucosa.

### RESPIRATORY BRONCHIOLES

Terminal bronchioles divide to form respiratory bronchioles, so called because each has a few alveoli attached to its wall, so that

Fig. 25- Respiratory Tree Diagram



some small amount of gas exchange is taking place at this level. (See Fig. 25).

Each respiratory bronchiole leads to a subsection of a respiratory unit known as an alveolar sac. (A useful analogy for the alveolar sac is "a bunch of grapes", whereas each individual grape would be analogous to one alveolus.

The epithelium of the respiratory bronchiole *lacks cilia* as well as goblet cells and is



more cuboidal than columnar. Notice that the cilia persist deeper into the respiratory tree than do the mucous secreting cells. This is an appropriate arrangement, since if the cilia ended before the glands did there would be no way to move the secretions out of the alveolar area.

## ALVEOLAR DUCTS

Each respiratory bronchiole branches to form several alveolar ducts, each of which leads to a subsection of the alveolar sac. (An analogy would be one subsection of a very large bunch of grapes. (See Fig. 25)

The wall of the alveolar duct *lacks smooth muscle* and the epithelium is the cells are a very low cuboidal in shape (perhaps actually more squamous than cuboidal).

## PLEURAL ANATOMY

### PLEURAL MEMBRANES

(See Fig. 26). The pleural membranes are thin layers of connective tissue lined with mesothelium (simple squamous epithelium). A thin watery lubrication fluid called serous fluid is secreted by the pleura.

This lubrication is very important in order to prevent friction and pain with respiration.

#### VISCERAL LAYER

The visceral pleura clings to the outside of the lungs.

#### PARIETAL LAYER

The parietal pleura is the interior lining of the chest wall. It's surfaces have names.

#### Costal Surface

The inside surface of the rib cage.

#### Diaphragmatic Surface

The top surface of the diaphragm.

#### Mediastinal Surface

The surface facing the mediastinum.

## PLEURAL REFLECTIONS

The parietal and visceral layers of the pleura are actually one continuous sheet of membrane which turns back upon itself at the hilum of the lung. This turning back is termed a reflection.

## PLEURAL CAVITY

The pleural cavity is the space between the parietal and visceral layers of the pleura. There is a negative air pressure (i.e. vacuum) in this cavity. It is necessary for there to be a negative pressure in this cavity in order for the lung to inflate.

## PLEURAL RECESSES

The pleural recesses are potential spaces or pockets in the pleural cavity (See Fig. 26) where fluids collect following injury or infection of the thorax. Drains may be put into these areas following thoracic surgery in order to draw off fluids.

#### RIGHT COSTODIAPHRAGMATIC RECESS

This recess is a pocket found on the right side of the chest between the costal and diaphragmatic surfaces of the parietal pleura.

#### LEFT COSTODIAPHRAGMATIC RECESS

This recess is similar to the one above except that it is found on the left side of the chest.

#### COSTOMEDIASTINAL RECESS

This recess is associated with the cardiac notch of the left lung. It is found again at the anterior chest wall between the costal and mediastinal surfaces of the parietal pleura.

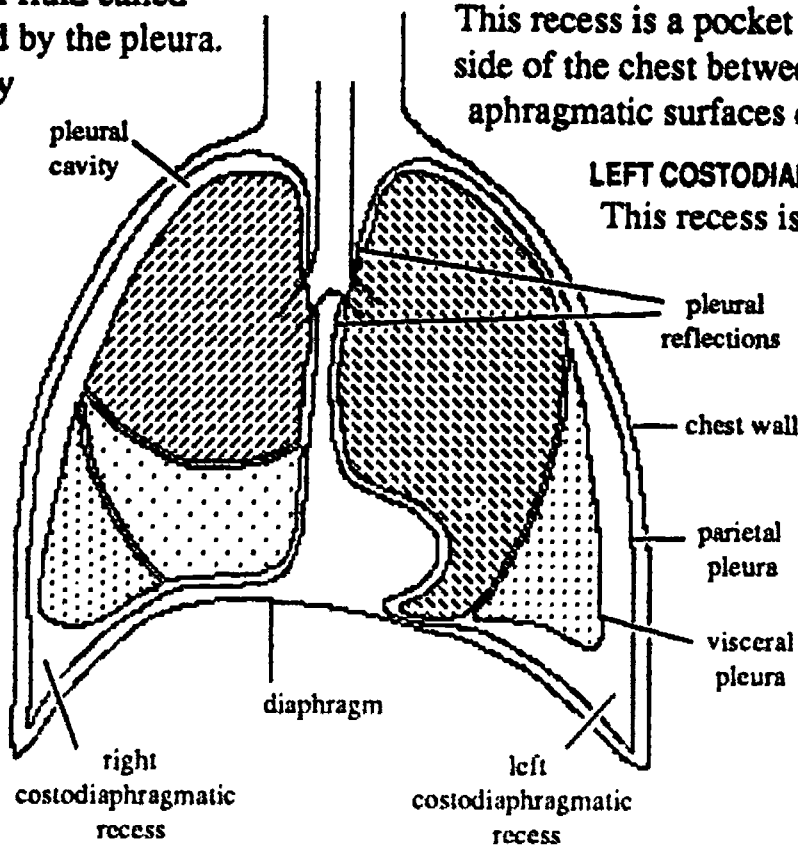


Fig. 26- Pleural Cavity, Pleural Reflections and Pleural Recesses

# **PATHOLOGY**

## **PNEUMOTHORAX**

Pneumothorax means *air in the pleural cavity*. The usual cause is puncture of the chest wall or tearing of the lung. The lung on that side of the thorax will collapse, but if the opening is sealed the air will be reabsorbed gradually over a period of a few weeks. A pneumothorax is sometimes artificially induced in order to collapse the lung to let it rest.

## **PLEURISY**

Inflammation of the lung and pleural membranes with consequent friction and pain upon respiration.

## **EMPHYSEMA**

Emphysema is due to loss of elasticity of the lung alveoli, thus preventing normal passive expiration. The patient has difficulty getting rid of inspired air and this of course makes gas exchange very difficult.

Emphysema is mostly due to the toxic effect of smoke. Cells die and release enzymes which self digest the walls of the alveoli. The elastic tissue breaks into short strands, and the septal walls between the alveoli break down so that the alveoli coalesce into large blebs with much less surface area for gas exchange.

Cigarette smoke also contains other toxins such as nicotine, hydrocarbons, tars, and carbon monoxide. Nicotine constricts the arterioles and CO competitively binds with hemoglobin, both of which contributes to anoxia and cell death. The hydrocarbons and tars are cancer inducing agents.

## **BLACK LUNG DISEASE**

Coal miners disease. As is the case with all lung disease due to breathing of dusty air, there is pulmonary fibrosis and chronic bronchitis. The fibrosis is a collagen scarring and thickening of the septal walls; it yields poor lung expansion and poor gas exchange.

In the case of black lung disease, the dusty air is also toxic as a result of coal tars, and as a result emphysema will also eventually develop.

## **BROWN LUNG DISEASE**

Textile workers disease. Textiles, especially cotton, produce a lot of dust. Breathing the dusty air leads to pulmonary fibrosis and chronic bronchitis.

## **ASBESTOSIS**

Asbestos is a fibrous mineral, the fibers of which are exceedingly light and prone to traveling long distances in the air. Breathing this mineral leads to the usual pulmonary fibrosis and chronic bronchitis. In addition asbestos fibers are carcinogenic. The type of cancer that results is usually a mesothelioma.

## **ASTHMA**

Asthma has many different causes and is accompanied by many different degrees of debilitation of the respiratory system, but the symptoms always include constriction of the bronchioles due to overactive smooth muscle, and excess secretion of mucous from the respiratory epithelium.

# The Heart

## LOCATION

The heart lies obliquely in the mediastinum of the chest with the apex of the heart pointing down. The *apex* of the heart lies in the left fifth intercostal space approximately the width of two fingers to the left of the sternum. This knowledge is useful clinically because the apex is part of the left ventricle of the heart, which is the main pumping chamber, and it is occasionally necessary to inject directly into the left ventricle. The most reliable bony landmark used to locate the apex is the sternal angle which is level with the second rib.

The great vessels of the heart attach to the uppermost part of the heart at the level of the third rib.

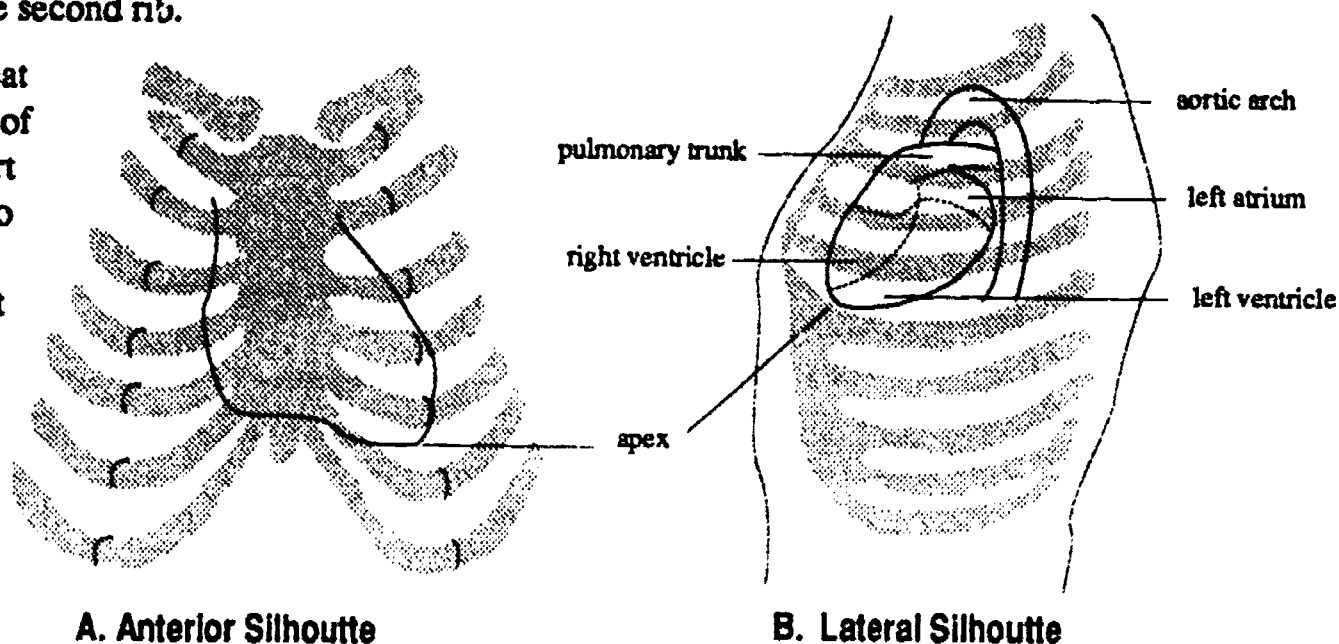


Fig. 27- Position of the Heart in the Chest Cavity

The heart as seen from the front view has been rotated or twisted toward the left, so that the right half of the heart lies more or less in front of the left half of the heart. From the front therefore you can see the right atrium, the right ventricle, a good part of the left ventricle (because it is so large) and only a very small part of the left atrium. Almost none of the left atrium can be seen from the front since it occupies most of the posterior surface of the heart.

mediastinum. It houses the heart. The bottom surface of the fibrous pericardium is fused with the central tendon of the diaphragm. The top of the fibrous pericardium extends upward to surround the beginnings of the great vessels.

## SEROUS PERICARDIUM

The serous pericardium consists of two layers, *parietal pericardium* and *visceral pericardium*

The visceral pericardium (also known as *epicardium*) clings directly to the outside



surface of the heart muscle. The parietal pericardium is attached tightly to the inside surface of the fibrous pericardium.

The serous pericardium is a smooth transparent membrane resembling a balloon blown up inside the boxlike fibrous pericardium. It is invaginated or indented by the fist sized heart. Both layers of serous pericardium secrete a thin film of watery lubricating fluid to reduce friction as the heart beats. The parietal and visceral layers are separated by the *pericardial cavity*.

The *pericardial cavity* is the space between the parietal and visceral layers of the serous pericardium. It is normally empty. If fluid of any kind collects in the pericardial cavity it will put pressure on the heart and inhibit its function. This condition is called *cardiac tamponade*.

## MYOCARDIUM

The myocardium is the actual muscle of the heart. It is thickest in the walls of the left ventricle, thinner in the walls of the right ventricle, and thinnest of all in the walls of the atria.

## ENDOCARDIUM

The endocardium is the simple squamous epithelium which lines the inside cavity of the heart. It is continuous with the endothelium of the blood vessels.

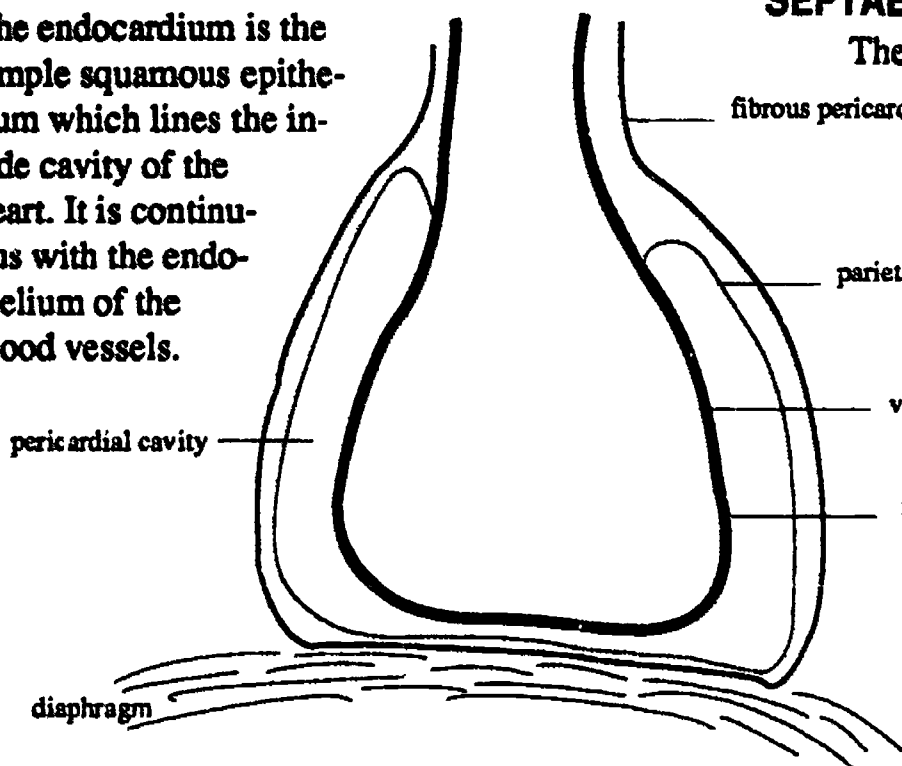


Fig. 28- Layers of the Pericardium

## A PAIR OF PUMPS

Think of the heart as a pair of muscular pumps fused together, side by side.

## CHAMBERS OF THE HEART

Each cardiac pump is composed of an *atrium* and a *ventricle*. The atria are uppermost and the ventricles are below them. The atrium is the receiving chamber of each pump. The ventricle is the propelling chamber of each pump.

Attached to each atrium is a nonfunctional ear shaped appendage called an *auricle*. The inside surface of each auricle is marked by coarse strands of muscle that look like the teeth of a comb, the *pectinate muscles*.

The interior surface of each atrium is very smooth as compared to the ventricles which have an interior surface marked by numerous strands called *trabeculae carneae*. In addition the atria have very thin walls compared to the walls of the ventricles. This is because the atria are required to propel blood only as far as the nearest ventricle whereas the ventricle must pump blood to some part of the body.

## SEPTAE

The right and left heart are separated from one another by a wall called the *median septum*.

In the adult heart there is no communication between the right and left halves of the heart. The part of the median septum which is between the atria is called the *interatrial septum*. The part of the septum which is between the ventricles is called the *interventricular septum*.



Between the atria and the ventricles is the *atrioventricular septum (A-V septum)*. The part of this septum in the right heart is called the *right AV septum*; the part in the left heart is called the *left AV septum*.

## BLOOD FLOW THROUGH THE HEART

The right heart is the pump for the pulmonary circulation. It receives venous blood from the body mass and propels it to the lungs for removal of carbon dioxide and enrichment with oxygen.

The left heart is the pump for the systemic circulation. It receives oxygenated blood from the lungs and propels it out to the rest of the system.

Because of the proportionately greater mass and resistance of the systemic circulation as

compared to the pulmonary circulation the muscular wall of the left ventricle is about three times thicker than that of the right ventricle.

## MAJOR VESSELS ATTACHED TO THE HEART

A *vein* is a vessel that carries blood toward the heart. An *artery* is a vessel that carries blood away from the heart.

### RIGHT HEART VEINS

Three veins bring blood to the right atrium: superior vena cava, inferior vena cava, and coronary sinus.

The *superior vena cava* brings blood from the head, neck, upper limbs, and chest wall.

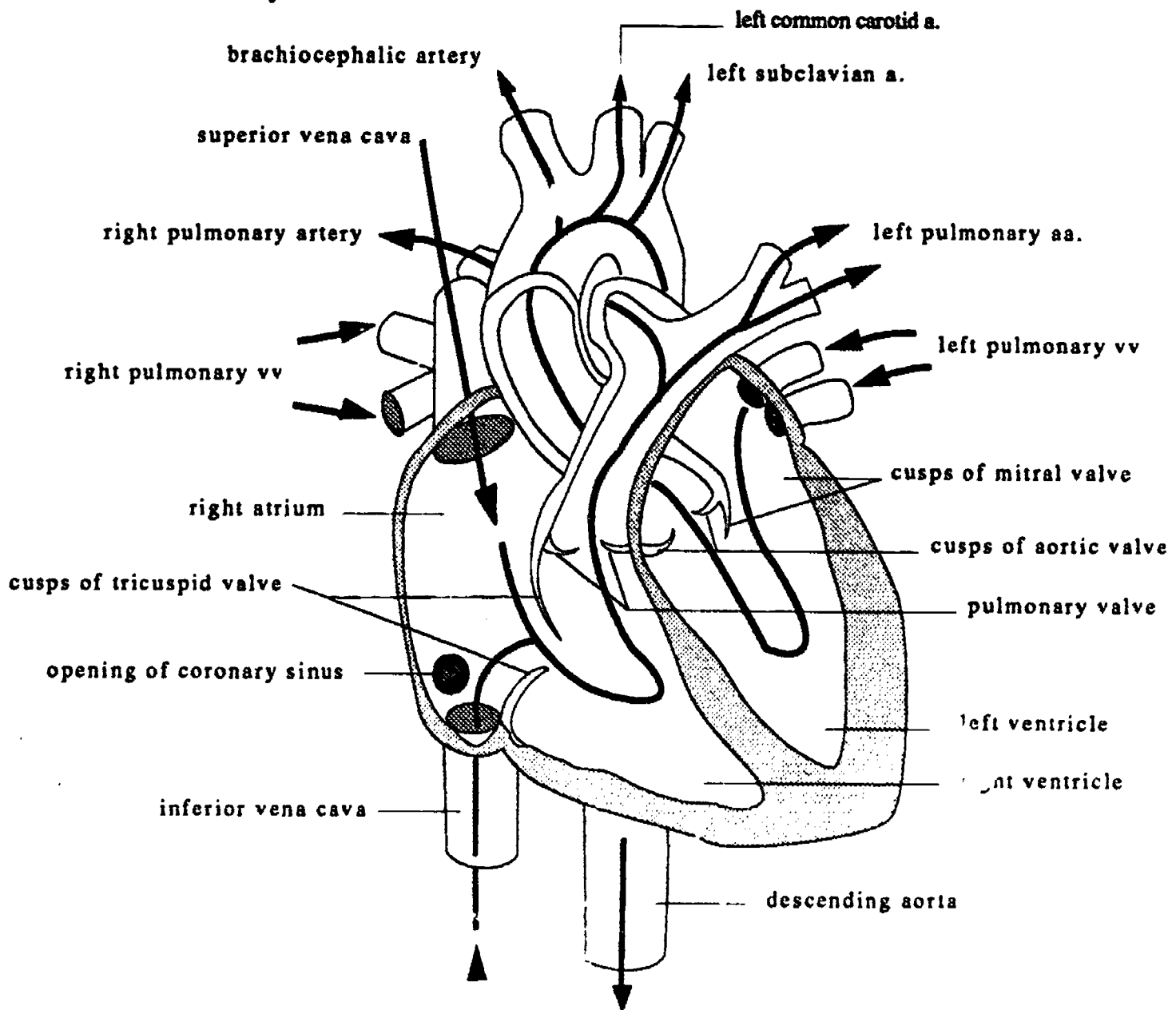


Fig. 29- Blood Flow Through The Heart

The *inferior vena cava* brings blood from the abdomen, pelvis, and lower limbs. The *coronary sinus* brings blood from the muscle of the heart wall.

## RIGHT HEART ARTERIES

The artery carrying blood away from the right ventricle to the lungs is the *pulmonary trunk*. It splits into two branches, the *right and left pulmonary arteries*.

## LEFT HEART VEINS

There are four *pulmonary veins* returning from the lungs to the heart. These four bring oxygenated blood to the left atrium.

## LEFT HEART ARTERIES

The artery carrying blood away from the left ventricle to the systemic circulation is the *aorta*. It ascends a short distance, then arches to the left and descends through the diaphragm and into the abdomen.

## HEART VALVES

The heart has four valves, two atrioventricular valves and two semilunar valves

Valves are one way flow devices designed to keep blood moving in one direction by preventing backflow. They open or close as a simple response to blood pressure changes inside the heart chamber during contraction or relaxation of that chamber.

## ATRIOVENTRICULAR VALVES

Each atrium communicates with its own ventricle through an *atrioventricular orifice*. The orifices are guarded by valves designed to allow blood to flow from the atrium to the ventricle when the ventricle is relaxed, but not in the reverse direction when the ventricle contracts.

The *right atrioventricular valve (Right A-V valve)* has three cusps or flaps and is called the *tricuspid* valve.

The *left atrioventricular valve (Left A-V valve)* has two cusps and is called the *bicuspid* or *mitral* valve.

## SEMILUNAR VALVES

These valves are found in the aorta and pulmonary trunk exactly at the point where the vessel rises out of the top of its respective ventricle. They are designed to prevent blood from falling back into the ventricle during the period of time following contraction, when the ventricle is relaxed and the blood pressure in the ventricles is low.

The *aortic* and *pulmonary semilunar valves* are identical to one another. Each valve has three halfmoon cup shaped cusps. The cups

face upward so that when they fill with blood they bulge into the lumen of the artery and close it off. The full cups are self bracing shapes with no prolapse problems.

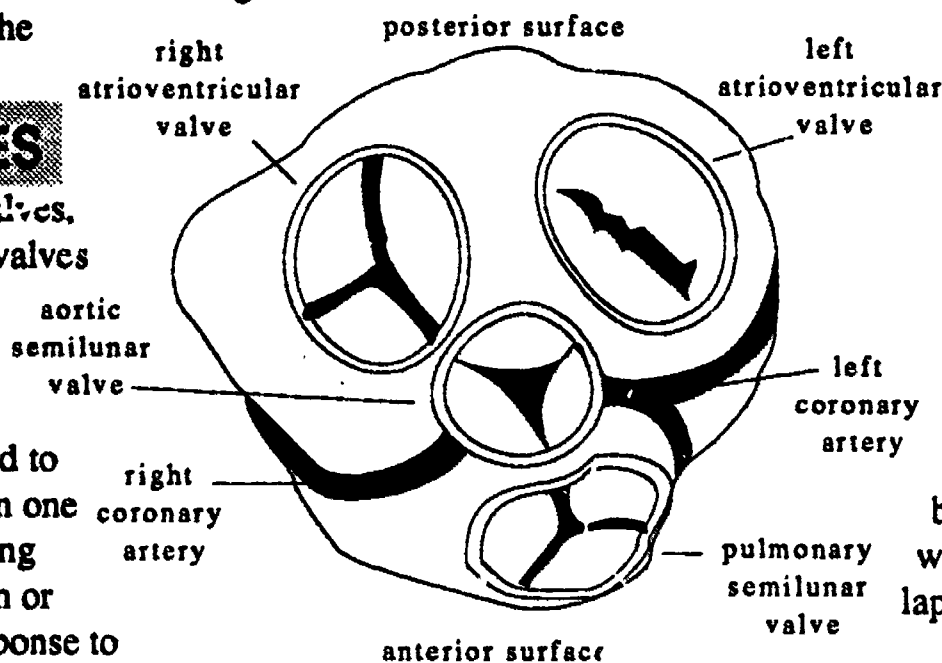


Fig. 30- Heart Valves, Superior View

## PROLAPSE PREVENTION

During ventricular contraction the pressure increases enormously on the underside of the A-V valve cusps, therefore these valves require special structures to prevent them from prolapsing, *i.e.* overclosing or behaving like a swinging door. The structures which prevent prolapse are known as the *papillary muscles* and *chordae tendinae*. They are visible from inside the ventricle only.

## Chordae tendineae

The chordae tendineae are tendinous strings which run from the free end of each papillary muscle to the edges of the valve cusps.

The contraction of the papillary muscles puts just the right amount of tension on the chordae tendineae so that the valve cusps are not allowed to move beyond the fully closed position.

## Papillary Muscles

The papillary muscles are cone shaped mounds of muscle that are attached to the wall of the ventricle on one end. The other end projects freely into the interior of the chamber.

There is one papillary muscle per flap, *i.e.* there are three papillary muscles in the right ventricle, one for each cusp of the tricuspid valve. The left ventricle has two papillary muscles, one for each cusp of the mitral or bicuspid valve.

## CARDIAC CYCLE AND HEART SOUNDS

### SYSTOLE / DIASTOLE

The two pumps are synchronized with one another so that there is an orderly sequence of contractions called the cardiac cycle. The right and left ventricles contract at the same time and they also relax at the same time. Ventricular contraction is called *systole*. Ventricular relaxation is called *diastole*. During diastole the atria contract and the ventricles fill.

### HEART SOUNDS

The atrioventricular and semilunar valves close in pairs. The A-V valves close at the beginning of *systole*; the semilunar valves close at the beginning of *diastole*. The closure of these pairs of valves gives rise to the characteristic "Lub"-"Dub" heart sounds.

## CORONARY VESSELS

The coronary arteries and veins supply and drain the heart muscle itself. The coronary

circulation vessels wind around the surface of the heart in a crown shaped pattern, hence the name coronary. The main arteries lie next to their companion veins in *the coronary sulci* which overlie the median septum and the atrioventricular septum.

## CORONARY ARTERIES

The right and left coronary arteries are the first branches of the aorta. They branch off of the aorta immediately above the semilunar valve.

### RIGHT CORONARY ARTERY

The *right coronary artery* is quite long. It winds around the right margin of the heart in the *A-V sulcus* and then descends in the *posterior interventricular sulcus*. It has only one major branch, the *marginal artery*, which lies at the extreme right hand margin of the heart.

### LEFT CORONARY ARTERY

The *left coronary artery* is quite short. It ends by bifurcating into the circumflex branch and anterior interventricular branch.

The *circumflex artery* winds around the left border of the heart in the *A-V sulcus*. On the posterior surface of the heart it anastomoses with the right coronary artery.

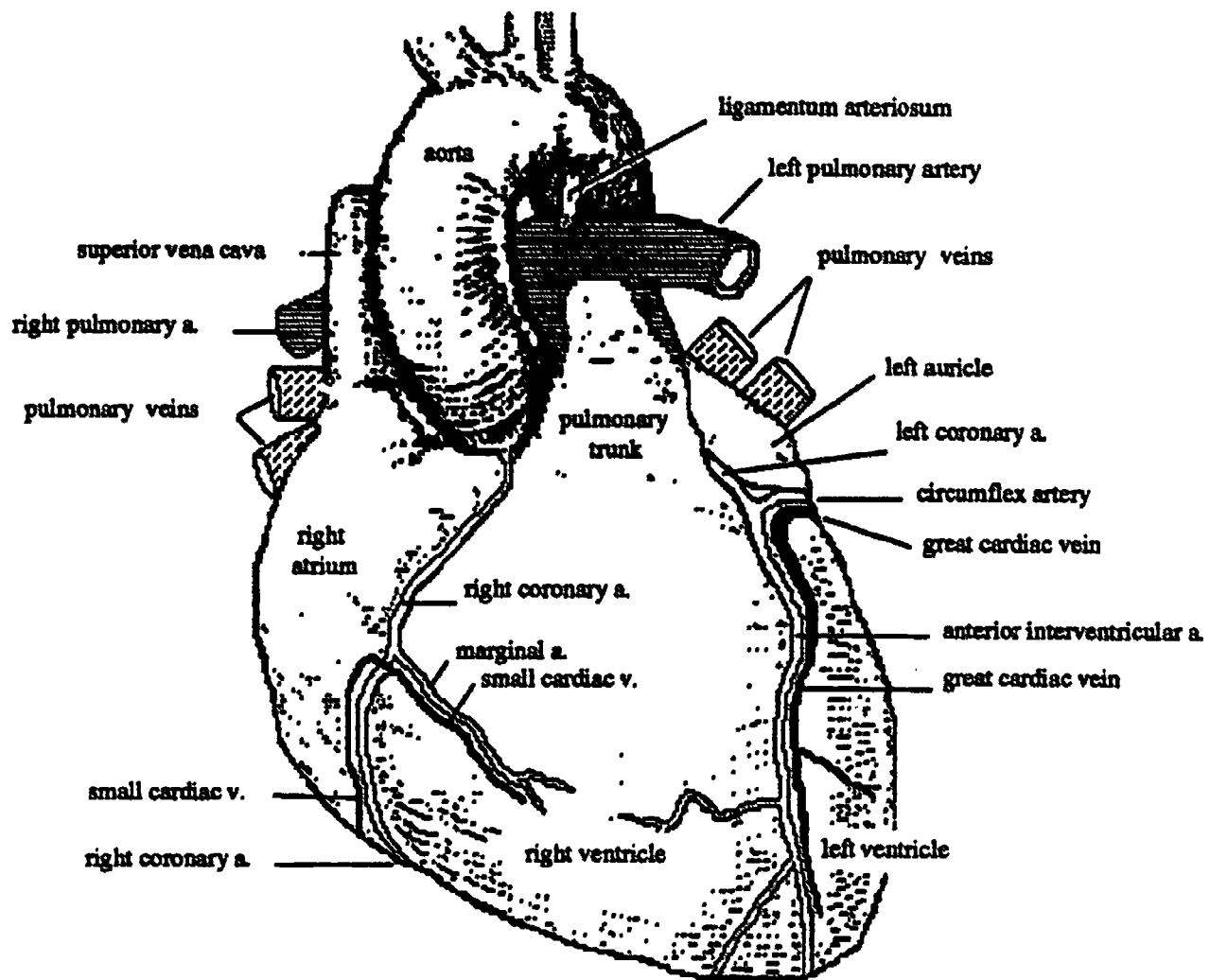
The *anterior interventricular artery* is a straight line continuation of the left coronary artery. It descends in the *anterior interventricular sulcus* and curls around the bottom of the heart to anastomoses with the right coronary artery on the posterior surface of the heart.

## CARDIAC VEINS

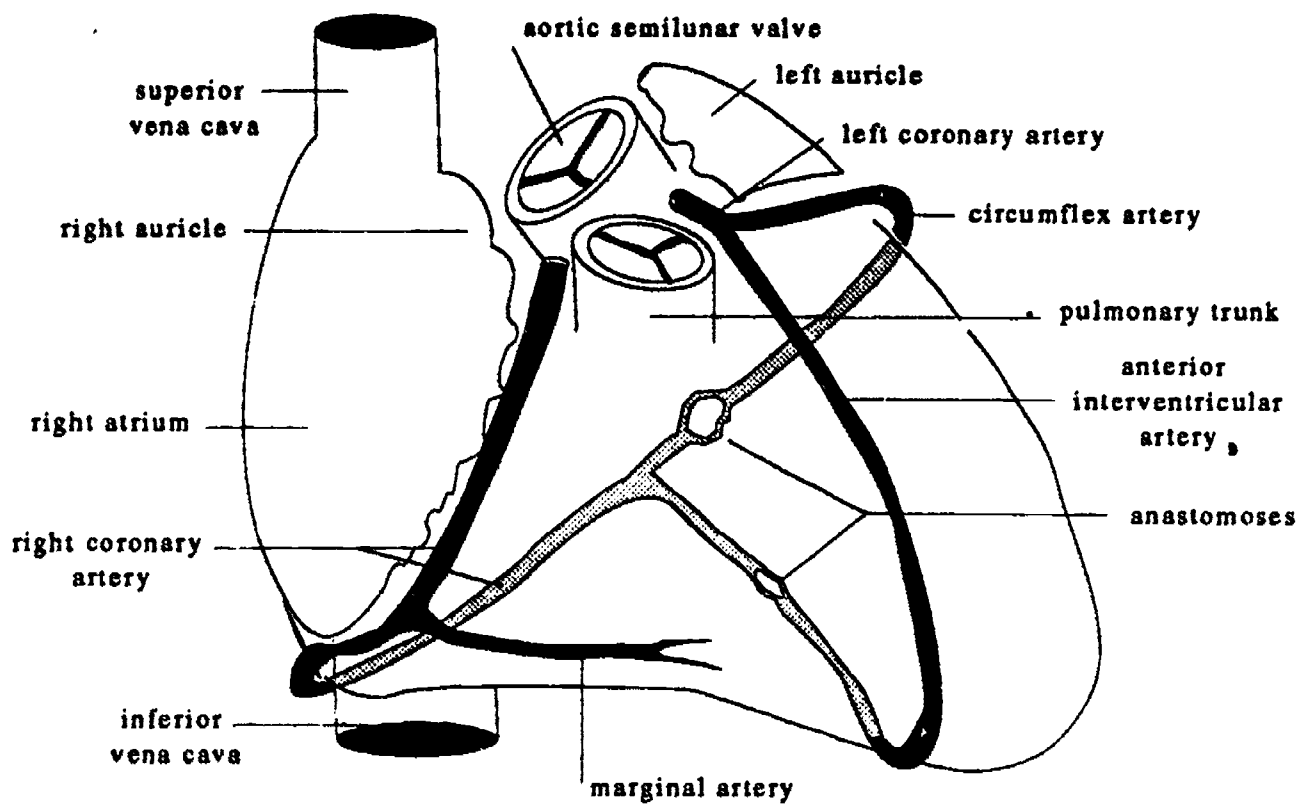
### CORONARY SINUS

The *coronary sinus* is the largest vein of the coronary circulation. It lies in the *A-V sulcus* on the posterior surface of the heart and opens into the right atrium near the inferior vena cava. It receives blood from all the smaller veins (tributaries) which in turn receive blood from the capillary plexus (*subendocardial plexus*) of the heart muscle.

Continued on p. 82.

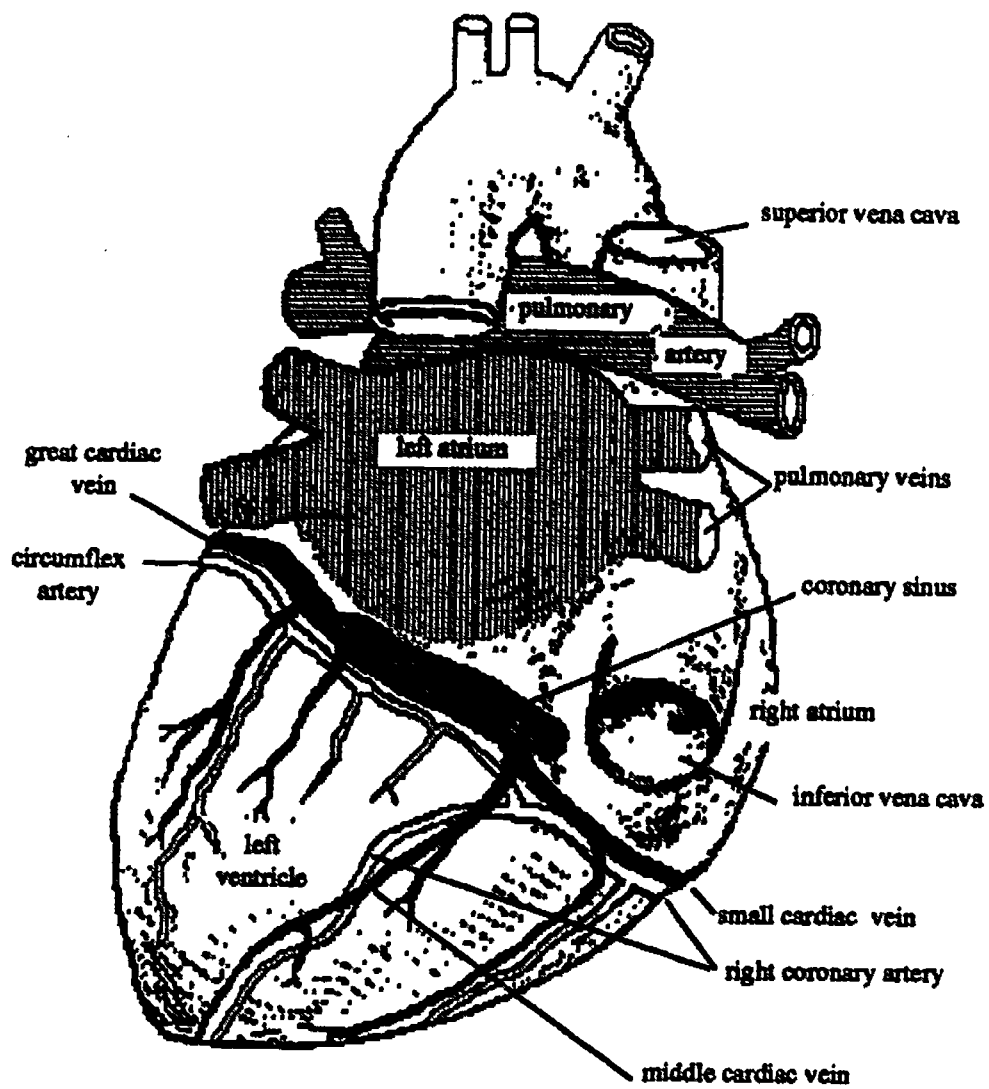


**Fig. 31- Anterior View of Heart**

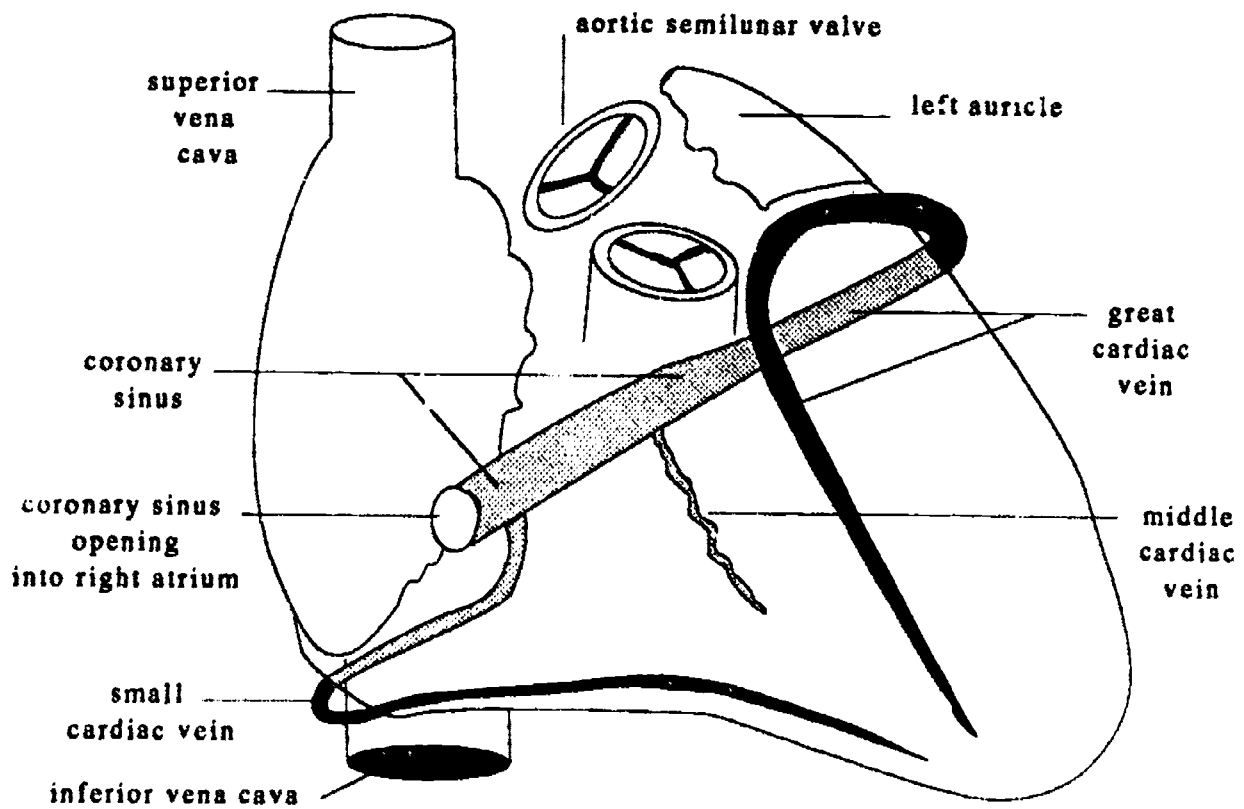


**Fig. 32- Transparent View of Coronary Arteries**





**Fig. 33- Posterior View of Heart**



**Fig. 34- Transparent View of Cardiac Veins**

The tributary veins draining into the coronary sinus correspond in position to the branches of the coronary arteries.

The *great cardiac vein* corresponds to the anterior interventricular and circumflex branches of the left coronary artery.

The *middle cardiac vein* corresponds to the posterior interventricular portion of the right coronary artery.

The *small cardiac vein* corresponds to the marginal branch of the right coronary artery.

## CORONARY ARTERY PATHOLOGY

If any part of the *subendocardial plexus* becomes starved for blood the muscle in that area is described as being ischemic. *Ischemia* is usually accompanied by a characteristic kind of chest pain called *angina pectoris*.

Angina pectoris is a severe cramp like pain in the chest region. It is a referred pain that characteristically radiates down the medial surface of the left arm. The pain is due to spastic contraction of the coronary vessels that occurs when blood flow is reduced.

Ischemia is usually temporary, however, if the coronary arteries are significantly narrowed or occluded, the ischemia may become prolonged causing muscle cells *necrosis*. Death of heart muscle cells is called a *myocardial infarct*. The common term for a myocardial infarct is "heart attack", or sometimes "coronary". The severity of a heart attack will depend on what part of the heart is damaged, and on how large an area is damaged.

## CONDUCTING SYSTEM OF THE HEART

The heart is synchronized by specialized tissue derived from muscle.

### SA NODE

The heart does not need a separate nervous supply in order to beat. The muscle cells of the heart have their own inherent rhythmic

contractility. The individual muscle cell contractions are synchronized into a rhythmic beat by a dominant group of specialized muscle cells which sets the pace for the contractions. This specialized group of muscle cells is called the pacemaker, or more technically, the *sinoatrial node*.

The *SA node* is located in the ceiling of the right atrium next to the superior vena cava. A wave of contraction spreads downward from the SA node, engulfing both atria and pushing the blood from the atria into the ventricles. The SA node normally fires about 72 times per minute. The rate and strength of contractility is adjusted by the autonomic nervous system; the sympathetic nervous system increases and the parasympathetic decreases the frequency and strength of the contractions.

### AV NODE

As the wave reaches the bottom of the right atrium it is diminished in strength until it triggers contraction in a second node of specialized heart muscle cells called the atrioventricular node. The AV node acts like an amplifier which will start a wave of contraction in the ventricles. However, the ventricles cannot be allowed to contract from the top down because the arteries of the heart are attached to the upper side of the ventricles; there is no exit for blood from the bottom of the heart. If the ventricles were to contract from the top down the blood would blow a hole out of the bottom of the heart.

### AV BUNDLE

The solution for this situation is a bundle of specialized heart muscle cells called the *atrioventricular bundle (bundle of His)*. The AV bundle is located in the interatrial wall, extending from the AV node to the interventricular septum. It conducts the contraction impulse from the AV node to the *right and left bundle branches* which run down the interventricular septum to the bottom of the ventricles where they spread out into the musculature of the ventricle

walls. Thus the wave of actual muscle contraction starts at the bottom of the ventricles and spreads toward the top, propelling blood upwards into the aorta and pulmonary trunk.

The terminal fibers of the bundle branches were discovered before the existence of the conduction system was known, and these fibers were called the *Purkinje fibers*. The name now applies to the specialized tissue of the AV bundle as seen microscopically.

## FETAL HEART ANATOMY

The fetus does not use its lungs, and therefore blood is diverted away from the pulmonary circulation vessels.

There are two short circuit devices in the fetal heart which effectively route blood away from the pulmonary arteries. The first of these is the foramen ovale, the second is the ductus arteriosus.

### FORAMEN OVALE

The foramen ovale is an oval hole in the interatrial septum near the junction of the superior vena cava and right auricle. A thin loose flap of tissue hangs down from the top of the foramen like a curtain. This flap is pushed out of the way by the pressure of blood flowing through the foramen (in the fetus only) from the right atrium directly into the left atrium, bypassing the right ventricle and pulmonary vessels.

### DUCTUS ARTERIOSUS

The ductus arteriosus is a short open vessel leading from the top of the pulmonary trunk to the bottom of the aortic arch. Whatever amount of blood does fall from right atrium into right ventricle will be propelled upward from the ventricle and into the pulmonary trunk. When it hits the top of the pulmonary trunk it will keep on going straight into the aortic arch, bypassing the right and left pulmonary arteries.

## CHANGES AT BIRTH

### FOSSA OVALIS

At birth, when the child starts breathing, the pressure in the left atrium rises and equalizes with the pressure in the right atrium, holding the curtain of tissue in the midline between the two atria. This closes the foramen ovale functionally, and within a short time the edges of the flap fuse closing the foramen anatomically.

When the foramen ovale closes it leaves behind a depression in the interatrial septum where the wall is thin. This thin depression is called the *fossa ovalis*. If for whatever reason the foramen remains open the defect is referred to as *patent foramen ovale*.

### LIGAMENTUM ARTERIOSUM

At birth blood flow thru the ductus ceases due to pressure changes in the thorax and heart, and shortly thereafter the ductus constricts and begins to fill in with connective tissue.

The filled in duct resembles a ligament and is therefore called the *ligamentum arteriosum*. If for some reason it remains open the defect is referred to as *patent ductus arteriosus*.

# Blood Vessels: Chest Area Arteries

## AORTIC ARCH

The arch of the aorta in humans has three branches: *brachiocephalic*, *left common carotid*, and *left subclavian*. In the cat there are only two branches off the arch: *brachiocephalic* and *left subclavian*.

### ❖ BRACHIOCEPHALIC A.

An older name for this artery is "Innominate Artery". In humans it has two branches, one heading for the brachium and one heading for the cephalic region. In cats the left common carotid is also attached to the brachiocephalic artery.

#### 1. RIGHT COMMON CAROTID A.

The word *common* in the name of a vessel indicates that it will soon split into two other vessels. The common carotid travels up the neck to the level of the thyroid cartilage (Adam's apple) where it splits into internal and external carotids. It comes closest to the skin just below its bifurcation point (a pulse/pressure point used when taking a patient's heart rate).

#### 2. RIGHT SUBCLAVIAN A.

The word subclavian means under the clavicle. This vessel passes under the clavicle on its way to the arm where it will become the *axillary artery* of the arm. Along the way it gives off three branches which distribute to the brain, chest, and shoulder.

##### a. Vertebral a.

This artery is one of the main sources of blood for the brain. It will be discussed with the head and neck arteries.

##### b. Internal Thoracic A.

(Internal Mammary)

This artery clings to the internal surface of the chest wall, giving off branches to the rib cage as it descends. These branches supply the breast as well as the ribs.

#### 1. Anterior Intercostal aa.

The anterior intercostals will anastomose

with the posterior intercostals (which are direct branches of the descending thoracic aorta).

#### 2. Thyrocervical (and Costocervical) aa.

The branches of these arteries supply the neck and shoulder muscles.

### ❖ LEFT COMMON CAROTID A.

The anatomy of the left common carotid is identical to that of the right common carotid described above.

### ❖ LEFT SUBCLAVIAN A.

The anatomy of the left subclavian is identical to that of the right subclavian described above.

## DESCENDING THORACIC AORTA

#### 1. Posterior Intercostal aa.

The descending aorta in the thorax gives off many small branches to the intercostal areas. These anastomose with the anterior intercostals which are branches of the internal thoracic artery (see above).

#### 2. Esophageal, Bronchial, and Diaphragm aa.

The veins of the chest that empty into the heart include the pulmonary veins, the coronary sinus, inferior vena cava, and



# Blood Vessels: Chest Area Veins

the superior vena cava. Of these the pulmonary veins and the coronary sinus were covered in the heart lecture. The inferior vena cava does not receive any significant tributaries in the chest, therefore it will be discussed under the heading of Abdominal Veins. This leaves the superior vena cava for present discussion.

## SUPERIOR VENA CAVA

The superior vena cava brings blood to the heart from the upper part of the body (head, arms, shoulders). It is formed by the joining together of the the right and left brachiocephalic veins, and it also receives two other small tributaries, the azygos vein and the joined internal mammary veins.

### ◆ BRACHIOCEPHALIC VEINS

There are two brachiocephalic (innominate) veins. Each is formed by the junction of a *subclavian vein* from the arm and an *internal jugular vein* from the head and neck region.

The tributaries of the brachiocephalic veins on the right and left sides of the chest are mirror images of one another, so the words "right" and "left" are not used in the list below.

#### 1. SUBCLAVIAN VEIN

The subclavian vein is the direct continuation of the axillary vein of the arm. Close to the junction where it empties into the brachiocephalic vein it receives the *external jugular vein*, which is a major tributary from the head and neck.

#### 2. INTERNAL JUGULAR VEIN

This vein will be discussed with the "Head and Neck Veins".

### ◆ AZYGOS VEIN

The azygos vein collects blood from the chest wall. It receives blood from the following tributaries.

a. Posterior intercostal veins

b. veins from : Esophagus , Bronchii , Diaphragm

c. Hemiazygos vein

This vein may or may not be present. If it is present it receives the posterior intercostals from the left side of the chest. If it is not present those same intercostals simply cross the midline and empty directly into the azygos vein.

### ◆ INTERNAL THORACIC VEIN

The two internal mammary (internal thoracic) veins are companions to the arteries of the same name; they receive the anterior intercostal veins. The two internal mammary veins fuse just before draining into the superior vena cava.

# Blood Vessels: Head and Neck Arteries

## EXTERNAL CAROTID A.

Most of the branches of the external carotid stay outside of the skull. The exception is the meningeal branch of the maxillary artery.

### ◆ FACIAL ARTERY

The facial artery wanders around over the face and finally ends up in the orbit where it anastomoses with the ophthalmic branch of the internal carotid artery

### ◆ OCCIPITAL ARTERY

This branch supplies the scalp in the occipital region.

### ◆ SUPERFICIAL TEMPORAL A.

This is the direct upward continuation of the external carotid artery. It supplies the scalp in the temporal and parietal regions.

### ◆ MAXILLARY ARTERY

This supplies blood to the teeth in the upper jaw, and also to the nose. One interesting branch enters the skull to supply the meninges.

### MIDDLE MENINGEAL ARTERY

This artery is the exception to the rule in that it goes inside the skull, but even this branch stays external to the brain. It supplies the meninges.

## INTERNAL CAROTID ARTERY

The internal carotid enters the skull through the carotid foramen and carotid canal. The two carotid arteries are the most important source of blood for the brain. Each internal carotid has two branches, both of which are part of the *Circle of Willis* of the brain.

### ANTERIOR CEREBRAL ARTERY

The anterior cerebral artery is a small branch of the internal carotid that turns toward the frontal pole of the brain.

### Anterior Communicating Artery

This artery joins the two anterior cerebral

arteries to one another.

### Ophthalmic Artery

Supplies blood to the orbit. Anastomoses with the facial branch of the external carotid.

### MIDDLE CEREBRAL ARTERY

The middle cerebral artery is a large branch of the internal carotid artery that follows the lateral fissure and supplies the parietal and temporal lobe areas of the brain.

### Posterior Communicating Artery

The posterior communicating artery is a small branch that joins the middle cerebral artery to the posterior cerebral artery.

## VERTEBRAL ARTERY

These arteries are also an important source of blood for the *Circle of Willis* of the brain. On their way up the neck toward the head, each vertebral artery threads its way through the transverse foramina of the cervical vertebrae. They enter the skull through the foramen magnum.

### ◆ BASILAR ARTERY

As soon as the two vertebral arteries enter the skull they join together to form the single basilar artery which is located on the base of the brain stem. The basilar artery soon splits again to form the two posterior cerebral arteries, which are part of the *Circle of Willis*.

### POSTERIOR CEREBRAL ARTERIES

The posterior cerebral arteries supply the occipital pole of the brain.

### Posterior Communicating Artery

See the description above under "middle cerebral artery."

### CEREBELLAR ARTERIES

The cerebellar arteries branch off of the basilar artery and head for the cerebellum.

# Blood Vessels: Head and Neck Veins

## EXTERNAL JUGULAR

This vein drains blood from the exterior of the skull. Its branches are identical to those of its companion, the external carotid artery.

## INTERNAL JUGULAR

This vein is the companion to the internal carotid artery in the neck. It is a direct continuation of the venous sinuses of the skull whose tributaries drain blood from the brain.

These venous sinuses were first discussed in the unit on bones where you were asked to observe the grooves made by these veins on the interior of the skull. The venous sinuses were discussed a second time in the nervous system unit under the topic "cerebral spinal fluid circulation".

The points to emphasize here is a clinical one. There are two possible routes by which infections may spread into the cranial cavity and cause meningitis. These potential entry routes involve the cavernous sinus and the sigmoid sinus.

### ◆ SUPERIOR SAGITTAL SINUS

The superior sagittal sinus receives blood from adjacent cerebral veins.

Remember that it also receives cerebral spinal fluid which is reabsorbed by way of the arachnoid villi.

### ◆ TRANSVERSE & SIGMOID SINUSES

These sinuses drain blood from adjacent areas of the brain. Note the following points of clinical interest :

#### AURICULAR VEINS

These small tributaries from the middle and inner ear drain into the transverse and sigmoid sinuses. This constitutes a potential entry route for bacteria from ear infections.

#### CAVERNOUS SINUS

There are 1 cavernous sinuses, each is

located next to the sella turcica in the center of the skull. They receive blood from neighboring brain areas and drain that blood into the transverse sinuses. Of clinical importance is the fact that they receive some blood from the facial veins via the orbital veins. This constitutes a potential entry route for bacteria from facial and orbital infections.

### ◆ STRAIGHT SINUS

The straight sinus is a continuation of the inferior sagittal sinus.

#### INFERIOR SAGITTAL SINUS

The inferior sagittal sinus is located in the inferior border of the falx cerebri. It receives blood from adjacent cerebral veins.

# Blood Vessels: Arteries and Veins of the Arm

## DEEP VESSELS

These arteries all have companion veins of the same name. The vessels on the right side of the body are identical to those on the left side.

### ◆ AXILLARY ARTERY & VEIN

The axillary vessels are a direct continuation of the subclavian vessels of the chest. They are distributed to the breast as well as to the shoulder and chest muscles.

#### BRACHIAL ARTERY AND VEIN

The brachial vessels are a direct continuation of the axillary vessels; the name change occurs at the level of the teres major muscle. This brachial artery travels with the median nerve. It comes closest to the skin just above the elbow on the medial side (a pulse/pressure point used when taking a patient's blood pressure). The brachial artery and vein distribute to the upper arm before bifurcating into radial and ulnar vessels, which divide up the territory of the forearm.

#### a. Radial artery and vein

The radial artery and vein distribute to the thumb side of the forearm. The radial artery comes closer to the surface at the wrist than does the ulnar artery. For this reason the pulse/pressure point at the wrist is over the radial artery.

##### Deep Palmar Arch

The radial artery and vein form the deeper of two palmar arches. The arch distributes branches to the fingers.

#### b. Ulnar artery and vein

The ulnar artery and vein distribute to the little finger side of the forearm.

##### Superficial Palmar Arch

This arch is the more superficial of the two palmar arches formed by the radial and ulnar vessels; it also distributes branches to the fingers.

## SUPERFICIAL VESSELS

Superficial veins have no companion arteries; in fact most of these veins are not significant enough to have names. The exception is those veins that are clinically relevant, as is the case with the superficial veins of the arm and the leg.

#### 1. CEPHALIC VEIN

This vein runs under the skin on the radial side of the arm and forearm. It drains into Axillary vein.

#### 2. BASILIC VEIN

This vein runs under the skin on the ulnar side of the arm and forearm. It drains into the Brachial vein.

#### 3. MEDIAN CUBITAL VEIN

This vein is the one most commonly used when taking a blood sample from a patient. The name *cubital* refers to the cubital fossa at the crease of the elbow joint. There are two common patterns by which this vein can anastomose with the basilic vein and cephalic veins; one pattern forms a straight line between the basilic and the cephalic, the other pattern is a "Y" shaped junction between basilic and cephalic.



# Blood Vessels: Abdominal Arteries and Veins

## SINGLE ABDOMINAL AA.

These single branches of the abdominal aorta supply all the viscera that are part of the digestive system.

### ❖ CELIAC TRUNK ARTERY

The celiac trunk in humans is only about a quarter of an inch long. It divides into three arteries.

#### SPLenic ARTERY

The splenic artery runs along the upper edge of the pancreas. It supplies the spleen, with multiple small branches to the pancreas and a gastroepiploic branch which follows the greater curvature of the stomach and anastomoses with a similar branch from the hepatic artery.

Pancreatic branches  
Left gastroepiploic artery

#### COMMON HEPATIC ARTERY

The common hepatic artery carries oxygenated blood to the liver, with important secondary branches to the stomach, pancreas, upper half of the duodenum, and gall bladder.

Right Gastric artery  
Gastrooduodenal artery  
Cholecystic artery

#### LEFT GASTRIC ARTERY

The left gastric artery follows the lesser curvature of the stomach and ends by anastomosing with the right gastric artery (a branch of the common hepatic artery)

### ❖ SUPERIOR MESENTERIC A.

The superior mesenteric artery travels in the mesentery of the intestine, and supplies all of the small intestine, including the lower half of the duodenum. It also supplies the upper parts of the large intestine, namely the cecum, ascending colon, and transverse colon.

### ❖ INFERIOR MESENTERIC A.

The inferior mesenteric artery travels in the

mesentery of the intestine, and supplies the descending and sigmoid colons, and also gives off the superior rectal artery (superior hemorrhoidal) to the rectum.

## PAIRED ABDOMINAL AA.

These branches supply the organs that are not part of the digestive system.

### ❖ RENAL ARTERIES

These are the very large arteries that supply blood to the two kidneys.

### ❖ GONADAL ARTERIES

The gonadal arteries are also known as ovarian or testicular or spermatic arteries, depending on gender.

### ❖ COMMON ILIAC ARTERIES

The abdominal aorta ends by bifurcating into the two common iliac arteries which supply the pelvis and lower limbs with blood.

## PAIRED ABDOMINAL VEINS

The veins that drain directly into the inferior vena cava are the counterparts of the paired abdominal arteries. The exception to the rule is the blood draining into the inferior vena cava from the multiple hepatic veins.

### ❖ RENAL VEINS

These are the veins that drain blood from the kidneys into the inferior vena cava.

### ❖ GONADAL VEINS

The left gonadal vein often drains into the left renal rather than directly into the inferior vena cava.

### ❖ COMMON ILIAC VEINS

These veins return blood from the lower limbs and pelvis.

### ❖ HEPATIC VEINS

The hepatic veins are the veins that are exiting from the liver. They collect blood

from the hepatic sinusoids (capillaries) of the liver lobules. The blood in these veins is blood that the liver has already finished processing. The raw nutrients received from the digestive tract have been metabolized or stored by the liver, and the usable nutrients are now ready to be sent on to the heart for general distribution.

### **SINGLE ABDOMINAL VEINS**

These are the veins that constitute the hepatic portal system. All of these veins drain into the *hepatic portal vein*, which collects blood from the digestive tract and carries it to the liver for processing. These veins are the counterparts to the single branches of the abdominal aorta. (There is no veins corresponding to the celiac trunk *per se*, but rather the veins correspond to the branches that the celiac trunk gives rise to.

### ◆ **SPLenic VEIN**

This vein receives blood from the spleen and also from the stomach and pancreas. It is the companion vein to the splenic artery.

### ◆ **SUPERIOR MESENTERIC VEIN**

The superior mesenteric vein receives blood from the small intestine and from the upper parts of the large intestine. It is the companion vein to the superior mesenteric artery.

### ◆ **INFERIOR MESENTERIC VEIN**

The inferior mesenteric vein drains into either the splenic vein or equally often into the superior mesenteric vein. It receives blood from the lower half of the large intestine. It is the companion vein to the inferior mesenteric artery

### ◆ **LEFT GASTRIC VEIN**

This vessel is a minor contributor to the portal vein. It is the companion vein to the left gastric artery.

---

## **Blood Vessels: Pelvic Arteries & Veins**

---

The arteries and veins of the pelvis are identical to one another, and the vessels on the right side are identical to those on the left side.

The descending aorta and its companion vein the inferior vena cava, end at approximately the level of the pelvic brim, just slightly below the level of the umbilicus. They end by bifurcating into two common iliac vessels which distribute to the pelvis and legs.

### ◆ **COMMON ILIAC ARTERY & VEIN**

Use of the term "common" indicates that these vessels will branch into two other iliac vessels, one for the pelvis and one for the leg.

Cats have a common iliac vein, just as do humans, however cats do not have a common iliac artery. In cats the internal iliac artery comes off of the *middle sacral artery*

The middle sacral artery is attached to the center of the inverted Y of the bifurcation of aorta. It supplies the tail.

### **INTERNAL ILIAC ARTERY AND VEIN**

The internal iliac vessels distribute to the pelvic and perineal organs and the buttocks. The organs supplied include the: rectum, bladder, prostate, seminal vesicle, penis, scrotum, uterus, vagina, and vulva, (but not the ovary and testicle which are supplied by the gonadal artery, a branch of the aorta). It is more important to remember the structures supplied than to remember the names of the branches.

### **EXTERNAL ILIAC ARTERY AND VEIN**

The external iliac vessels become the femoral vessels of the thigh. The name change occurs as the artery passes under the inguinal ligament.

# Blood Vessels: Arteries and Veins of the Leg

The deep veins of the leg are identical to the companion arteries, and the vessels on the right side are identical to those on the left side.

## MAIN FEMORAL VESSELS

The main femoral artery and vein are direct continuations of the external iliac vessels; they distribute to the thigh and are the equivalent of the brachial artery and vein in the arm. The main femoral has many small branches, but only two large ones: the deep femoral and the popliteal. One of these (the popliteal) is really just a name change for the continuation of the femoral vessel into the popliteal fossa.

### ❖ DEEP FEMORAL ARTERY & VEIN

These vessels are also known as the *profunda femoris* artery and vein. They run parallel to the main femoral vessel and distribute to the muscles of the thigh. They are the most important collateral circulation vessel of the leg, *i.e.* if the main femoral vessel is occluded the deep femoral vessel can often take over the job of supplying blood to the rest of the limb.

### LATERAL FEMORAL CIRCUMFLEX A. & V.

This is the largest branch of the profunda femoris. It winds around the thigh laterally and distributes to the hip joint. One long descending branch winds around the knee and anastomoses with branches of the popliteal vessel.

### ❖ POPLITEAL ARTERY & VEIN

The popliteal vessels are the direct continuation of the main femoral vessels. The name comes from the popliteal fossa at the back of the knee. They have small branches to the knee and end below the knee by bifurcating into the anterior and posterior tibial vessels.

### ANTERIOR TIBIAL ARTERY AND VEIN

This branch of the popliteal vessel immedi-

ately heads for the front of the lower leg. It passes between the fibula and tibia and descends with the tibialis anterior muscle. At its lower end its name changes to dorsis pedis artery or vein.

### Dorsis Pedis artery and vein

As its name indicates, the dorsis pedis vessel is on the top of the foot.

#### Arcuate Artery

This vessel is the direct continuation of the dorsis pedis. The term "arcuate" refers to the arch that this vessel forms on the top of the foot. It distributes to the toes by way of the *digital branches*.

### POSTERIOR TIBIAL ARTERY AND VEIN

The posterior tibial vessel is the main branch of the popliteal vessel. It heads in the direction of the big toe, gives off one main branch up high on the calf (the peroneal artery and vein), passes behind the medial malleolus, and ends by bifurcating into the medial and lateral plantar vessels on the bottom of the foot. It is the source of distribution to the calf muscles.

The posterior tibial artery is equivalent to the radial artery of the lower arm; a pulse and pressure point are available behind the medial malleolus.

### Peroneal artery and vein

This branch of the posterior tibial vessel distributes to the lateral calf (peroneal muscles).

### Medial and Lateral Plantar a & v

These two vessels are the direct continuation of the posterior tibial vessel. They anastomose to form an arch on the bottom of the foot.

#### a. Plantar arch

The plantar arch distributes to the toes by way of the *digital branches*.

## **SUPERFICIAL LEG VEINS**

These veins are prone to becoming varicose because of the fact that being under the skin they do not benefit from the massaging action of the muscles.

### **◆ LESSER SAPHENOUS VEIN**

This vein is found under the skin in the area of the calf (posterior surface of lower leg). It drains blood into the deep veins by joining the popliteal vein behind the knee.

### **◆ GREATER SAPHENOUS**

This vein drains all of the skin of the leg except for the area covered by the lesser saphenous vein. It drains into the femoral vein at the groin.



# Lymphatic System

The lymphatic system of vessels and lymphoid organs have three main functions:

1. transport of tissue fluid
2. transport of dietary fats
3. immune system functions

## TISSUE FLUID TRANSPORT

### WHAT IS TISSUE FLUID

Tissue fluid (also known as lymph or intercellular fluid or interstitial fluid) is derived from blood plasma by capillary diffusion and filtration. Two systems of vessels collect this fluid from the intercellular spaces and return it to the circulatory system. These two systems are:

1. the venous system
2. the lymphatic system

### FLUID VOLUMES

It is important that the amount of tissue fluid being returned to the circulatory system exactly equal the amount being created. The amount of fluid leaving the arterial ends of the capillaries is large because of the arterial pressures. There are four times as many veins as there are arteries in order to equalize the pickup and delivery aspects of tissue fluid flow, but even these are not sufficient to keep the fluids balanced. The deficit is handled by the lymphatic capillaries.

### LYMPHATIC VESSELS

There are thousands of miles of lymphatic vessels in the body. They begin as transparent microscopic blind ended capillaries in all the tissues of the body except for the central nervous system. If these capillaries are blocked by pathological processes (such as *filariasis (elephantiasis)*) or disrupted by surgery, that part of the body will swell due to the accumulation of intercellular fluids. This situation is called *edema*, or in the case of fluid accumulation in the peritoneal cavity, *ascites*. Usually the swelling is temporary because new capillaries are easily

added.

### VALVES

All lymphatic vessels that drain in the upward direction have valves to prevent the fluid from falling back down from whence it came. These vessels usually have a beaded appearance due to dilation of the vessel above the valve.

### METASTASIS

Cancer spreads by way of the lymphatic vessels. Cancers are a type of tumor that are not recognized as foreign, so the body does not throw up a protective encapsulation around the tumor. As the tumor grows larger cells break off from the edges of the mass and travel by way of the lymphatic vessels.

The lymph fluid percolates through the lymph nodes and other lymphoid organs on its way toward the collecting ducts. Often cancer cells get hung up in these filtering stations and secondary tumors start growing. This spreading process is called *metastasis*.

### COLLECTION DUCTS

#### THORACIC DUCT

The thoracic duct is the major collecting duct of the lymphatic system. It is found on the left side of the thorax hugging the anterior surface of the vertebral bodies. Most of the lymphatic capillaries of the body drain toward the thoracic duct; it collects all the lymph from below the waist, from the left side of the head neck and chest, and from the left arm.

The thoracic duct drains into the subclavian vein just lateral to the point where the internal jugular vein joins with the subclavian. Thus the tissue fluid, which came from the circulatory system is returned to the circulatory system.

#### Cisterna Chyli

The *cisterna chyli* is the expanded lower end of the thoracic duct. It is found at the T<sub>12</sub>,

level close to the diaphragm. This cistern or pool is the main collecting depot for lymph fluid collected from the lower half of the body.

#### RIGHT LYMPHATIC DUCT

The right lymphatic duct is a small version of the thoracic duct. It collects lymph fluid from the right upper quadrant of the body (head, neck, arm, chest) and returns it the circulation in the same way, by draining into the right subclavian vein next to the internal jugular vein.

### TRANSPORT OF FAT

The digestion of carbohydrates, proteins and fats in the small intestine produces smaller molecules called glucose, amino acids, and fatty acids respectively. By comparison with glucose and amino acids, the fatty acids are still fairly large molecules. Perhaps it is this size difference that causes them to travel a different route than the other two molecules. Whereas glucose and amino acids are picked up by the venous capillaries in the walls of the intestine, 60% of the absorbed fatty acids are picked up by the lymphatic capillaries.

#### LACTEALS

Each intestinal villus contains a lymphatic capillary called a lacteal. Lymphatic vessels are normally transparent, but these vessels of the intestine look white after a meal due to the presence of emulsified microdroplets of fat dispersed in the lymph fluid. Because of the superficial resemblance to milk, these vessels are called *lacteals*.

#### CHYLE

The white fluid inside of a lacteal is called *chyle*. After leaving the intestinal wall this fluid travels in the mesentery of the gut toward the cisterna chili, the main collection point for the abdomen, pelvis, and lower limbs.

### IMMUNE FUNCTIONS

The main job of the immune system is to recognize the difference between "self" and "non-self", and to destroy that which is "non-self". *i.e.* foreign.

Any molecule recognized as foreign to the body is called an **antigen**. Recognition of antigens is accomplished by matching the shape of an antigen molecule with a mirror image receptor site on the surface of an immune system cell. Immune system stem cells continuously generate new receptors by a process of random genetic recombination.

The immune system has two basic families of cells that react to antigens.

These are:

1. the macrophage family of cells (the reticuloendothelial system), and
2. the lymphocyte family of cells.

Macrophages are produced by mitotic activity in the red bone marrow. They then are distributed to all parts of the body where they protect against infection by attacking and eating (phagocytizing) antigens.

Lymphocytes are produced by mitotic activity in the *germinal centers* of the lymphoid organs. Most of these cells enter the circulating blood where they do surveillance work, looking for particular antigens.

The lymphocyte family of cells consists of two functional groups, the *B lymphocytes*, and the *T lymphocytes*, both of which have circulating stem cells on surveillance duty.

Recognition of an antigen by a lymphocyte stem cell causes that lymphocyte to rapidly divide, so that a clone of identical lymphocytes dedicated to that one particular antigen is produced. The members of the clone then have the further capacity to differentiate into two specialized subfamilies.

*B stem cells may differentiate into plasma cells or into memory cells:*

Plasma cells produce antibodies, molecules

which attach to the surface of an antigen and physically mask its disease causing sites. Plasma cells are present only so long as an antigen is present.

Memory cells persist after the antigen is defeated, and give the body the capacity to respond very rapidly if it is exposed to that same antigen again at some future time.

*T stem cells differentiate into two subgroups called  $T_H$  and  $T_C$ .*

The  $T_H$  and  $T_C$  subgroup names refer to surface markers found on the cell membrane of the cell. Each subgroup contains cells that act directly (*effectors*) or by influencing other immune system cells (*regulators*).

*$T_H$  effectors* activate other white blood cells.

*$T_H$  regulators* are called *helper* cells; they facilitate both B and T cell functions.

*$T_C$  effector* cells are called *cytotoxic* cells; they attach to an antigen and attack it by secreting a toxin that is lethal to the antigen.

*$T_C$  regulators* are *suppressors* of other T or B cells.

## LYMPHOID ORGANS

Macrophage cells and lymphocyte cells are found in all parts of the body; they are especially concentrated in the lymphoid organs.

### ◆ THYMUS

The thymus is the primary lymphoid organ. It has a cortex and a medulla, and it is known to produce a number of different hormones.

#### EARLY SEEDING ACTION

Before the age of 12 the thymus produces many thousands of committed T lymphocytes that then migrate to and take up residence in all of the secondary lymphatic organs.

#### INVOLUTION

After the age of 12 the thymus involutes (gets smaller and turns fatty) as its seeding function is completed.

#### THYMIC HORMONE

Thymic hormones stimulate the function of the outlying lymphatic organs in some way. The thymus continues to produce these hormones, but the quantity of hormone produced declines with age. This may be one of the reasons for increased susceptibility to viral infections and cancer with advancing age.

### ◆ LYMPH NODES

The lymph nodes are small nodules that vary in size from that of a pin head to an olive. They are surrounded by a capsule of connective tissue, and they often become swollen and tender during infectious diseases.

The lymph stream enters the node via the *afferent vessels* around the periphery, filters through the *lymph sinuses* of the nodule, and exits at the *hilum* via the *efferent vessel*. Fixed macrophages are found in the *medulla* in the center of the node. B cells occupy the *germinal centers* and T cells occupy the *cortex* areas.

Lymph nodes are generally found in small groups near veins. Especially large concentrations of them are found in the *cervical, axillary and inguinal regions*.

### ◆ PEYER'S PATCHES

Peyer's patches are nonencapsulated patches of lymphoid tissue found in the submucosa of the intestinal wall. They play a vital role in defending the body against mass invasion by bacteria from the gut.

### ◆ SPLEEN

The spleen differs from other lymphatic tissue in that it filters blood; worn out RBCs are phagocytized here. It is also interesting to note that the spleen has the highest concentration of B cells and plasma cells.

### ◆ TONSILS

A tonsil is a mass of lymphatic tissue located in the oro or nasopharynx (throat). There are three tonsils by name, two of them occurring as paired organs. They act as guard stations which help to prevent the spread of bacteria to other parts of the respiratory system. They often swell when they are actively fighting an infection, sometimes they themselves become infected and become part of the problem rather than part of the solution. When this happens they may be surgically removed. They are known to regrow if any portion of the tonsil is left behind during the "T & A" (tonsillectomy and adenoidectomy).

The most widely known pair of tonsils, the *palatine tonsils* (often known simply as "*the tonsils*"), are located on each side of the throat, nestled between the glossopalatine and pharyngopalatine arch. These tonsils are encapsulated with connective tissue. Most of the tonsil is out of sight beneath the epithelium of the throat, only the tip of the tonsil projects above the surface and can be seen from inside the throat.

The second most well known tonsil is commonly known as the *adenoids*, but more accurately described by its technical name,

*pharyngeal tonsil*, so called because of its location in the roof of the nasopharynx. This is a single patch of lymphoid tissue located in the midline of the nasopharynx between the openings of the two eustachian tubes. It is not encapsulated by connective tissue and is very friable.

The last pair of tonsils, the "tubal tonsils" are found as a ring of lymphoid tissue around the mouth of each eustachian tube. These tonsils are difficult to see unless swollen, and are not included in the usual "T & A" operation.



# Angiology

## ARTERIES VS VEINS

- Arteries are smaller in diameter than veins.
- Arteries have thicker walls than veins.
- There are usually three- four veins for every artery.

These differences between the vessels can be accounted for by the fact that the arterial system is a high pressure system in comparison to the low pressure venous system, and yet both systems must move equal volumes of blood per unit time.

## CIRCULATORY SHUNTS

A shunt is an *anastomosis*, i.e. a direct communication between two vessels larger than a capillary.

### A-V SHUNTS

(Arterio-Venous Anastomosis)

An A-V shunt is a direct communication between an artery and its companion vein. When the *precapillary sphincters* are tightened arterial blood will bypass the capillary bed and flow directly into the vein via the shunt, thus blood is returned to the heart much more quickly than it would be if it had to go through the capillary bed. This is the arrangement used by the autonomic nervous system to *reroute blood flow* to the parts of the body that have the most need of it at any given time.

#### Sympathetic

The sympathetic nervous system dilates the precapillary sphincters leading to the skin, lungs, and muscle. It constricts those leading to the digestive system.

#### Parasympathetic

The parasympathetic nervous system dilates the precapillary sphincters leading to the digestive system. It constricts those leading to the muscles and skin.

### A-A OR V-V SHUNTS

An anastomosis between a main vessel and a secondary vessel provides *collateral circulation*, i.e. an alternate route to and from each area of the body. These shunts between vessels may be especially important if normal routes are interrupted by trauma, surgery, etc.

## VENOUS BLOOD FLOW

Blood in veins is not pushed by a pump as it is in the arteries. How is blood flow maintained in the venous system?

Development of sufficient pressure inside the veins to maintain flow can be accounted for by the following mechanisms.

### OSMOSIS

Osmotic pressure is created by the fact that blood proteins do not leave the capillaries. Their presence inside the venous end of the capillary bed is the chief reason why tissue fluids move from the intercellular spaces into the veins.

### MUSCULAR MASSAGE

Veins are generally surrounded by muscle masses. During muscular activity the venous blood is moved forward through the veins by the massaging action of the surrounding muscles.

### VENOUS VALVES

Veins that carry blood upward against the force of gravity have simple valves that act as one way flow devices. These valves are inward folds of the *tunica intima* of the vein. The pulmonary veins, the portal system veins and the vena cavae do not have valves.

### SUCTION (THORACIC PUMP)

The negative thoracic pressure and the bellows like action of breathing creates a suction in the thoracic cavity known as the thoracic pump. In addition blood moving

rapidly through the larger diameter veins creates venturi type forces that suck blood from smaller veins into the larger vein at their junction points.

## **HYDROSTATIC PRESSURE**

Hydrostatic pressure is simply the pressure created by the weight of a column of fluid. Hydrostatic pressure increases as the volume of fluid accumulates inside a vessel.