

DOCUMENT RESUME

ED 268 335

CE 044 217

**AUTHOR** Sobczak, James  
**TITLE** Radiology Technician (AFSC 90370).  
**INSTITUTION** Air Univ., Gunter AFS, Ala. Extension Course Inst.  
**PUB DATE** 20 Apr 84  
**NOTE** 59lp.; Supersedes ED 226 207.  
**PUB TYPE** Guides - Classroom Use - Materials (For Learner) (051)

**EDRS PRICE** MF03/PC24 Plus Postage.  
**DESCRIPTORS** \*Allied Health Occupations Education; Behavioral Objectives; Biomedical Equipment; Correspondence Study; Distance Education; Equipment Utilization; Learning Activities; \*Medical Evaluation; Medical Services; Military Personnel; \*Military Training; \*Nuclear Technology; Postsecondary Education; \*Radiologic Technologists; \*Radiology

**IDENTIFIERS** Air Force

**ABSTRACT**

This five-volume student text is designed for use by Air Force personnel enrolled in a self-study extension course for radiology technicians. Covered in the individual volumes are radiographic fundamentals (x-ray production; primary beams; exposure devices; film, film holders, and darkrooms; control of film quality; and environmental safety); osteology and positioning (osteology positioning of the extremities, vertebral column, ribs, sternum, skull, facial bones, and paranasal sinuses and positioning of the upper and lower extremities, chest and abdomen, vertebral column, and skull); special techniques (mamography and zeroradiography, obstetrical radiography, ultrasonography, tomography, computer tomography, scanography and arthrography, bedside and surgical radiography, and film duplication and subtraction) special procedures (contrast studies of the digestive, urogenital, respiratory, cardiovascular, lymphatic, nervous, integumentary, and endocrine systems); and general information and radiation therapy (radiation therapy and management of department functions). Each volume in the set contains a series of lessons, exercises at the end of each lesson, a bibliography, and answers to the exercises. Supplementary volume review exercises and a change supplement are also provided.  
(MN)

\*\*\*\*\*  
\* Reproductions supplied by EDRS are the best that can be made \*  
\* from the original document. \*  
\*\*\*\*\*

ED268335

RADIOLOGY TECHNICIAN

(AFSC 90370)

EXTENSION COURSE INSTITUTE

AIR UNIVERSITY

U.S. DEPARTMENT OF EDUCATION  
NATIONAL INSTITUTE OF EDUCATION  
EDUCATIONAL RESOURCES INFORMATION  
CENTER (ERIC)

This document has been reproduced as  
received from the person or organization  
originating it

Minor changes have been made to improve  
reproduction quality

• Points of view or opinions stated in this docu-  
ment do not necessarily represent official NIE  
position or policy

CE044217

## ECI COURSE MATERIALS SHIPPING LIST

COURSE NO  90370	COURSE TITLE  RADIOLOGY TECHNICIAN (AFSC 90370)	EFFECTIVE DATE OF SHIPPING LIST  20 Apr 84
------------------------	--	--

**INSTRUCTIONS** The following materials are needed to complete this course. Check this list immediately upon receiving your course package, and if any materials are missing or incorrect (numbers don't match) notify ECI immediately. Use the ECI Form 17 for this purpose, and be sure to include your identification number, address, course and volume number, and VRE form designation (if a VRE is involved). Send all correspondence separately from your answer sheet.

ITEM	TYPE	DESIGNATION OR TITLE	INVENTORY CONTROL NUMBER	VRE ANSWER SHEET IDENTIFICATION
1	E.V	ECI RETURN ENVELOPES (6 EACH)		
2		YOUR KEY TO A SUCCESSFUL COURSE	M-140	
3	VOL	VOL 1, Radiographic Fundamentals	90370 01 7809	
4	VRE	VOLUME REVIEW EXERCISE (VOL 1)	90370 01 22	90370 01 22
5	VOL	VOL 2, Osteology and Positioning	90370 02 8310	
6	VRE	VOLUME REVIEW EXERCISE (VOL 2)	90370 02 23	90370 02 23
7	VOL	VOL 3, Special Techniques	90370 03 8311	
8	VRE	VOLUME REVIEW EXERCISE (VOL 3)	90370 03 23	90370 03 23
9	VOL	VOL 4, Special Procedures	90370 04 8401	
10	VRE	VOLUME REVIEW EXERCISE (VOL 4)	90370 04 23	90370 04 23
11	VOL	VOL 5, General Information and Radiation Therapy	90370 05 8402	
12	VRE	VOLUME REVIEW EXERCISE (VOL 5)	90370 05 23	90370 05 23
13		ECI SURVEY	99-01	99-01
		NOTE: DIRECT ANY QUESTIONS OR COMMENTS RELATING TO ACCURACY OR CURRENCY OF TEXTUAL MATERIALS TO AUTOVON 736-2647.		
		YOU ARE NOT REQUIRED TO POST ANY CHANGES LISTED ON THIS SHIPPING LIST WHICH CORRECT TYPOGRAPHICAL ERRORS, UNLESS SUCH ERRORS CHANGE OR OTHERWISE AFFECT THE MEANING OF THE MATERIAL.		

## LIST OF CHANGES

COURSE  
NO.

90370

EFFECTIVE DATE  
OF SHIPPING LIST  
20 Apr 84

CAREER FIELDS, POLICIES, PROCEDURES AND EQUIPMENT CHANGE. ALSO ERRORS OCCASIONALLY GET INTO PRINT. THE FOLLOWING ITEMS UPDATE AND CORRECT YOUR COURSE MATERIALS. PLEASE MAKE THE INDICATED CHANGES.

### 1. CHANGES FOR THE TEXT: VOLUME 1

- a. Page 3, col 1, line 3: Change " $2n^2A$ " to " $2n^2$ ." Line 10 from bottom Change "8keV" to ".8 keV."
- b. Page 9, col 2, line 5: Change "big" to "high."
- c. Page 12, col 2, line 5: Change "10 volts" to "110 volts."
- d. Page 43, Exercises (040)-5: Delete.
- e. Page 52, col 2, line 8: Change "pneumonia" to "pneumonia."
- f. Page 86, col 2, line 12: Change "Both" to "But."
- g. Page 101, col 1, line 2 from bottom: Change " $2/5$  amperes" to "2.5 amperes."
- h. Page 109, col 2, line 16: Change "AM" to "AFM."
- i. Page 119, answer 040-5: Delete.

### 2. CHANGES FOR THE TEXT: VOLUME 2

- a. Page 2, col 1, line 6: After "portions." add "The horizontal plane or transverse plane is any plane that divides the body into superior and inferior portions."
- b. Page 16, col 2, line 3 from bottom: Change "*trapexium*" to "*trapezium*."
- c. Page 29, col 2, line 20: Change "Bifib" to "Bifid."
- d. Page 43, col 1, line 17: Change "Medical" to "Medial."
- e. Page 46, col 2, line 8 from bottom: Change "veritcal" to "vertical."
- f. Page 53, col 1, line 1: Change "necessry" to "necessary." Line 4 from bottom: Change "contract" to "contrast."
- g. Page 55, col 1, line 21 from bottom: Delete "body." Line 3 from bottom: Change "of" to "to."
- h. Page 66, col 1, line 19: Change "side" to "knee."
- i. Page 70, Exercises (245)-4: Change "do" to "should."
- j. Page 73, col 2, line 10: Before "Which" insert "4." Line 12: Before "What" insert "5." Line 14: Before "Which" insert "6." Line 16: Before "How" insert "7."

## LIST OF CHANGES

COURSE  
NO.

90370

CAREER FIELDS, POLICIES, PROCEDURES AND EQUIPMENT CHANGE. ALSO ERRORS OCCASIONALLY GET INTO PRINT. THE FOLLOWING ITEMS UPDATE AND CORRECT YOUR COURSE MATERIALS. PLEASE MAKE THE INDICATED CHANGES.

EFFECTIVE DATE  
OF SHIPPING LIST

20 Apr 84

### 2. CHANGES FOR THE TEXT: VOLUME 2 (Continued)

- j. Page 81, col 1, line 9: Change "609de" to "60°."
- k. Page 88, Figure 7-3: The top of the figure needs to be rotated 1/4 turn clockwise to view this figure correctly.
- l. Page 89, col 1, last line: Change "lower" to "upper."
- m. Page 98, Exercises (266)-4: Change "CR-orbitcmeatal" to "CR-infraorbitomeatal."

### 3. CHANGES FOR THE TEXT: VOLUME 3

- a. Page 14, col 1, line 14 from bottom: Change "make" to "made."
- b. Page 16, col 2, line 8: Change "partmotion" to "part-motion."
- c. Page 17, col 1, line 16 from bottom: Change "Colcher-sussman" to "Colcher-Sussman." Col 2, line 6: Change "prupose" to "purpose."
- d. Page 26, col 1, line 13: Change "here" to "hear." Exercises (418)-3: Change "wat" to "what."
- e. Page 28, col 1, line 1: After "stimulated," add "the crystal."
- f. Page 30, col 2, line 25 from bottom: Change "originate, s" to "originates." Line 24 from bottom: Change "result;" to "result."
- g. Page 32, col 2, line 3: Change "whiel" to "while." Line 17: Change "flscan" to "scan."
- h. Page 34, col 2, line 3: After "wave" add "is."
- i. Page 35, col 2, line 20 from bottom: Change "ares" to "area."
- j. Page 37, col 2, line 2 from bottom: Change "should" to "shows."
- k. Page 39, col 2, line 29: Change "bladder" to "bladder)."
- l. Page 41, col 2, line 24 from bottom: Change "application" to "applications."
- m. Page 43, col 2, line 1: Change "turmors" to "tumors." Line 5: Change "her" to "one's."

## LIST OF CHANGES

COURSE  
NO.

90370

EFFECTIVE DATE  
OF SHIPPING LIST

20 Apr 84

CAREER FIELDS, POLICIES, PROCEDURES AND EQUIPMENT CHANGE. ALSO ERRORS OCCASIONALLY GET INTO PRINT. THE FOLLOWING ITEMS UPDATE AND CORRECT YOUR COURSE MATERIALS. PLEASE MAKE THE INDICATED CHANGES.

### 3. CHANGES FOR THE TEXT: VOLUME 3 (Continued)

- n. Page 44, col 1, line 10 from bottom: After "examination," add "it may be advisable." Col 2, line 3: Delete "cephaly."
- o. Page 51, Exercises (439)-2: Delete.
- p. Page 54, col 1, line 6: Change "4-4" to "4-2."
- q. Page 62, col 1, line 21 from bottom: Delete "ments." Line 12 from bottom: Change "the" to "The."
- r. Page 63, col 1, line 16 from bottom: After "slice" add "to assign a mathematical value for each picture volume element. This information is changed into a video form so that a reconstructed image is visualized." Col 2, line 5: Change "ism ade" to "is made."
- s. Page 65, col 1, line 25 from bottom: Delete "with." Line 20 from bottom: Delete "to" and after "controls" add "for proper mechanical movement of."
- t. Page 67, col 1, line 13 from bottom: Change "wad" to "was."
- u. Page 68, col 1, line 6: Change "fig. 5-12" to "(fig. 5-12)."
- v. Page 69, col 1, line 2 from bottom: After "according" delete "ing."
- w. Page 71, col 1, line 1: Change "scane" to "scans."
- x. Page 77, Exercises (459)-3a: After "many" add "cubic." Exercises (459)-3b: After "many" add "cubic."
- y. Page 83, col 1, line 14: Change "dicussion" to "discussion." Line 20: Change "under stand" to "understand."
- z. Page 84, col 1, line 25: After "possible," add "before."
- aa. Page 85, col 1, line 16: Change "applied" to "applies."
- bb. Page 87, col 1, line 8: After "of" add "the."
- cc. Page 90, col 1, line 6 from bottom: Change "gives" to "results." Exercises (472)-4: Change "do" to "should."
- cd. Page 94, answer 439-2: Delete.

## LIST OF CHANGES

COURSE  
NO.

90370

EFFECTIVE DATE  
OF SHIPPING LIST  
20 Apr 84

CAREER FIELDS, POLICIES, PROCEDURES AND EQUIPMENT CHANGE. ALSO ERRORS OCCASIONALLY GET INTO PRINT. THE FOLLOWING ITEMS UPDATE AND CORRECT YOUR COURSE MATERIALS. PLEASE MAKE THE INDICATED CHANGES.

### 4. CHANGES FOR THE TEXT: VOLUME 4

- a. Page 7, col 2, line 7 from bottom: Delete "3."
- b. Page 17, Figure 1-14: Change "Hepatic Radicals" to "Right and Left Hepatic Ducts."
- c. Page 23, col 1, line 31: Change "done" to "do."
- d. Page 36, col 1, line 15: Delete "bled."
- e. Page 37, col 1, line 6: Change "AMBY" to "AMBU."
- f. Page 39, col 1, line 3 from bottom: Change "axes" to "axis."
- g. Page 67, col 2, lines 5-7 from bottom: Delete "In this section . . . to form catheters."
- h. Page 89, col 1, line 4 from bottom: Change "are" to "is."
- i. Page 90, col 1, line 4: Change "discuss" to "cover."

### 5. CHANGES FOR THE TEXT: VOLUME 5

- a. Page 4, col 2, line 6: Change "n" to "an."
- b. Page 15, col 2, line 6: After "physician" add a comma. Line 7: After "dentist" add a comma.

### 6. CHANGES FOR THE VOLUME REVIEW EXERCISE: VOLUME 1

- a. Page 3, question 9: In the stem of the question, after the first "10" add "A."
- b. Page 11, question 58, choice c: Change "ration" to "ratio."
- c. Page 16, question 91: At the end of the question, add a question mark.
- d. Page 17, question 97: In the stem of the question, after "using" add "high."
- e. The following questions are no longer scored and need not be answered: 50 and 85.

90370 01 7809


CDC 90370

# RADIOLOGY TECHNICIAN

(AFSC 90370)

Volume 1

*Radiographic Fundamentals*



Extension Course Institute  
Air University



Prepared by  
MSgt James Sobczak  
School of Health Care Sciences, USAF (ATC)  
Sheppard AFB, Texas 76311

Reviewed by  
Janice M. Beck, Education Specialist  
Extension Course Institute (ATC/AU)  
Gunter AFS, Alabama 36118



PREPARED BY  
SCHOOL OF HEALTH CARE SCIENCES, USAF (ATC)  
SHEPPARD AIR FORCE BASE, TEXAS

---

EXTENSION COURSE INSTITUTE, GUNTER AIR FORCE STATION, ALABAMA

THIS PUBLICATION HAS BEEN REVIEWED AND APPROVED BY COMPETENT PERSONNEL OF THE PREPARING COMMAND  
IN ACCORDANCE WITH CURRENT DIRECTIVES ON DOCTRINE, POLICY, ESSENTIALITY, PROPRIETY, AND QUALITY.

## Preface

IN THE VERY EARLY days of radiology, all of the mechanical work was done by the physician who owned the equipment. He positioned the patient, operated the X-ray generator, made the exposures, and processed the photographic plates. Naturally, this operation restricted the number of patients he could examine in a day's time. One enterprising physician reasoned that if he could train a layman to do the mechanical work, he would be free to handle the purely professional work of the science. He hired a man—the first technician—and taught him how to operate the generator and process the films. However, because of a lack of information on the subject, he neglected to train the man in the basic fundamentals of the science. Such primary concepts as the theory of X-ray production, beam restriction, and protection against ionizing radiation were not included in the "technician's" training. This exclusion of vital fundamental information had very unfortunate results. Both technician and physician, ignorant of the consequences, worked in the primary beam, and, consequently, were overexposed—to the point that the radiation crippled them.

Radiology today has evolved in to a highly technical science, and knowledge of the fundamentals of this field has become increasingly important. Without a good fundamental background, you, the radiology technician, cannot understand the rationale behind current practices, will be unable to apply new concepts, and are not likely to provide the best patient care.

This volume of the CDC covers basic fundamentals of radiology. Some of the information may seem familiar to you, since we have included material from the Phase I and Phase II Air Force training programs. Throughout this volume and the complete CDC, you will also discover many references to quality control, with which you will become more and more involved throughout your career.

Volume 2 will cover osteology and positioning. The osteology will be fairly detailed, while positioning will be discussed mainly from a problematic point of view. In Volume 3, special techniques from a quality control aspect will be discussed. Volume 4 will deal mainly with special procedures and equipment. Volume 5 will discuss radiology in a disaster situation, therapy, ultrasound, and general administrative requirements for radiology.

If you have questions on the accuracy or currency of the subject matter of this text, or recommendations for its improvement, send them to School of Health Care Sciences/MST, Sheppard AFB TX 76311. NOTE: Do not use the suggestion program to submit corrections for typographical or other errors.

If you have questions on course enrollment or administration, or on any of ECI's instructional aids (Your Key to Career Development, Behavioral Objective Exercises, Volume Review Exercise, and Course Examination), consult your education officer, training officer, or NCO, as appropriate. If this agent can't answer your questions, send them to ECI, Gunter AFS AL 36118, preferably on ECI Form 17, Student Request for Assistance.

This volume is valued at 36 hours (12 points).

Material in this volume is technically accurate, adequate, and current as of May 1978.

## Contents

	<i>Page</i>
<i>Preface</i> .....	iii
<i>Chapter</i>	
1 Fundamentals of X-Ray Production .....	1
2 The Primary Beam .....	44
3 Exposure Devices .....	54
4 Film, Film Holders, and Darkroom .....	68
5 Control of Film Quality .....	86
6 Environmental Safety .....	100
<i>Answers for Exercises</i> .....	117

**NOTE:** In this volume, the subject matter is developed by a series of Learning Objectives. Each of these carries a 3-digit number and is in boldface type. Each sets a learning goal for you. The text that follows the objective gives you the information you need to reach that goal. The exercises following the information give you a check on your achievement. When you complete them, see if your answers match those in the back of this volume. If your response to an exercise is incorrect, review the objective and its text.

## Fundamentals of X-Ray Production

AS A RADIOLOGIC technologist, you should understand the equipment with which you are working. True, you can produce a radiograph, perhaps an excellent one, without understanding the how's and why's in the operation of an X-ray machine, but what action would you take in answering a radiation protection question posed by a patient? Would you simply say that radiation protection is required by regulations (which it is), or would you try to enlighten the person? What if you have occasion to make several high load exposures in rapid succession? Could you determine whether the exposures exceed the maximum limits of your X-ray tube? The ability to answer these questions, along with many others, are items that separate the radiologic technologist from someone referred to as a "button pusher."

You are not expected to learn all the complexities of X-ray production or of machine operation. On the contrary, most of this chapter is limited to factors that affect either the speed or the number of electrons that interact within the tube target to produce X-radiation. As you study this chapter, keep in mind that factors which affect the electron ultimately affect either the quality or the quantity (photon energy and number of photons per unit area) of the X-radiation.

### 1-1. Fundamentals of Atomic Theory

When you are using various types of radiation and therapy, you should understand certain fundamental concepts regarding matter and energy. Knowledge of the functional relationships between matter and energy helps you understand how X-rays are produced, how they behave, and how they affect the human body.

**001. Identify the basic structure of an atom according to Bohr's model.**

**Matter.** Matter is defined as any substance that has mass and occupies space. There are three forms of matter: solid, liquid, and gas. Depending on the

substance, matter can exist in any one or a combination of forms. On the basis of their composition, substances may be classified as elements, compounds, or mixtures.

**Element.** An element is a simple substance that cannot be decomposed by chemical means. The smallest unit of an element that still retains the characteristic properties of that element is an atom. For example, if you break gold to its smallest part, you would end up with one atom of gold.

**Compound.** A compound is a complex substance formed by a chemical union of two or more elements in definite proportions. It exhibits properties different from the elements of which it is composed. Water is a combination of hydrogen and oxygen atoms.

**Mixture.** A mixture is made up of two or more substances, each retaining its own physical and chemical properties. For example, salt and sand may be combined to form a mixture. Generally, these components are unchanged and can be separated by physical means. Water added to a salt and sand mixture will dissolve the salt. By filtering the mixture, the sand can be removed and heat will evaporate the water, leaving the salt.

**Atom.** As mentioned before, the smallest unit of an element that still retains the characteristic properties of that element is an atom. What then comprises an atom? Different theories have been advanced and improved upon over the years to explain the structure of the atom.

Bohr's theory proposed in 1913 likens the atom to a miniature solar system. According to this theory, an atom (fig. 1-1) consists of a central nucleus containing a positive electrical charge; orbiting around the nucleus are negatively charged particles called electrons. These electrons revolve around the nucleus in fixed orbits in much the same way that planets revolve around the sun.

As a matter of note, a newer accepted theory based upon wave mechanics treats the orbiting electrons as a kind of three-dimensional cloud spread around the nucleus as electron waves. Though this theory explains

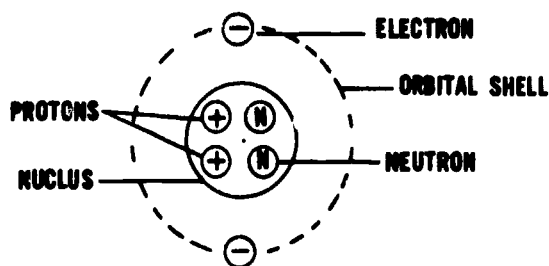


Figure 1-1. Atomic model.

all known phenomena more satisfactorily, it is difficult to form a mental picture of what an atom might look like. Therefore, for our purposes, Bohr's concept will be used.

As mentioned before, an atom contains a nucleus and electrons. The nucleus accounts for almost all the weight and mass of an atom. It furnishes the force causing other particles to spin around the nucleus. The nucleus contains protons and neutrons.

**Protons.** Protons are positively charged particles in the nuclei of atoms. Different elements have their own number of protons. The number of protons contained in the atomic nucleus is indicated by the element's atomic number, represented by the symbol  $Z$ .

**Neutrons.** Neutrons are electrically neutral particles. The number of neutrons in the atomic nucleus of a given element varies. Nuclear stability depends on the number of neutrons in proportion to the protons in the nucleus. The total number of protons and neutrons make up the mass number of an element, which is represented by the letter  $A$ .

**Electron.** The third type of particle in an atom is the electron, which has a negative electrical charge. Electrons whirl around the nucleus in continual motion and are arranged in shells or energy levels. When the atom is in the stable or neutral state, these negative charges are balanced against the positive charges in the nucleus. Once this balance in atomic charge is disrupted (by the loss or gain of an electron), the atom is said to be ionized.

**Exercise (001):**

1. Identify the different parts of the illustrated atom (fig. 1-2), using the five terms listed below.

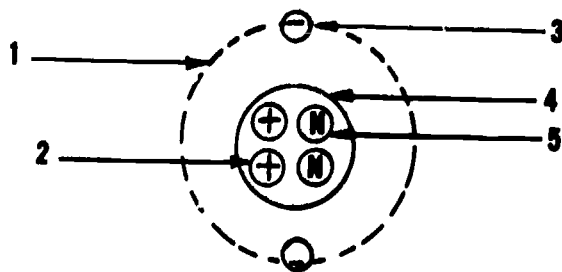


Figure 1-2. Objective 001, exercise 1.

- Nucleus
- Proton
- Electron
- Orbital shell
- Neutron

002. State the law of conservation of energy, and name the forms that energy and matter may take.

The use of orbits to describe electron position indicates the relationship of different electron energy levels. Before we discuss orbital electrons themselves further, let us briefly discuss a few aspects of energy.

**Energy.** Energy is a property common to all forms of matter. Unlike matter, however, energy is not a substance and does not occupy space. Energy is defined as the capacity to perform work. Two of the recognized types of energy are potential and kinetic.

**Potential.** Potential energy is the energy of position or stored energy waiting to be released under the right circumstances.

**Kinetic.** Kinetic energy is the energy inherent in a moving body. When potential energy is released, it becomes kinetic energy. Energy is constantly being changed from one form to another.

**Transformation of Energy.** All changes in the universe involve the transformation of energy. The law of conservation of energy states that matter and energy can be neither created nor destroyed. However, they can be changed from one form to another; that is, matter can be converted to other matter, energy to energy, matter to energy, or energy to matter (or there can be a partial change of each). In other words, mass and energy are mutually convertible. An atomic explosion illustrates how a tiny amount of matter is converted into a relatively large quantity of energy. The matter that seems to be destroyed is actually converted to energy.

**Exercises (002):**

1. List four ways that energy and matter can be converted.
2. State the law of conservation of energy.

003. Define "ionization" and state why ionization is an important consideration in radiology.

**Orbital Electrons.** The orbital electrons that whirl around the nucleus in continual motion are arranged in shells or energy levels. Each shell is given a letter

designation. (See fig. 1-3.) Each shell can hold only a limited number of electrons, which is represented by  $2n^2A$ , where  $n$  designates the number of the shell. The actual number in any give shell depends on whether the element is natural or manmade and on whether its state is neutral or ionized.

**Neutral state.** In the neutral state, the number of orbital electrons is equal to the number of positive charges or the number of protons in the nucleus. However, when X-rays or fast-moving electrons strike an atom, orbital electrons can be removed from their shell. These atoms are no longer electrically neutral and are said to be ionized.

**Ionized state.** Ions have different properties from those of the atoms from which they are derived. As a technologist, you are concerned with ionization. The process of ionization is integrally related to how radiation is produced within the X-ray tube, how X-ray film is exposed, and how biological damage due to radiation occurs within the human body.

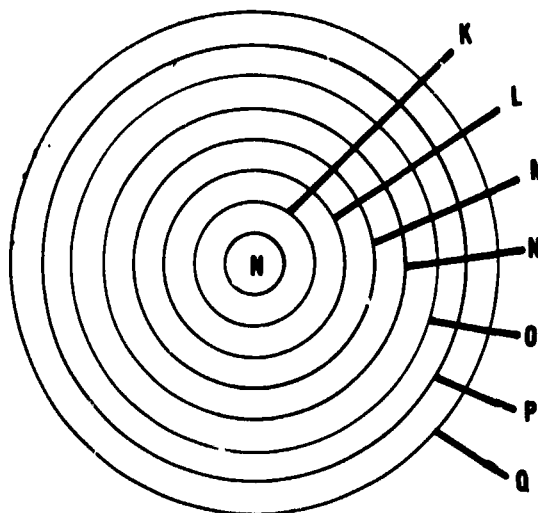


Figure 1-3. Shell designation.

**Exercises (003):**

1. Define "ionization."
  
2. Why is ionization an important consideration in radiology?

**004. Define and describe various types of radiation.**

**Electrons.** Electrons are maintained in their shells by a combination of centrifugal force, which tends to propel them away from the nucleus and an electrostatic force, which attracts the negative electrons toward the positive nucleus. Since electrons are bound by electrostatic force, a certain amount of energy is required to remove an electron from its shell to a point completely outside the atom. This is called the binding energy of that shell.

**Binding Energy.** The binding energy of the shell of an atom is greatest in the K-shell and decreases as the distance of the shell from the nucleus increases. For example, the binding energies for tungsten shells are: K electron, 69.5 kiloelectronvolt (keV); L electron, 12keV; M electron, 2keV; and N electron, 8keV. In other words, in an atom of tungsten, it would require at least 69.5KeV of energy to remove a K electron from its shell and at least 12keV to remove an L electron from its shell, etc. This binding energy is important in the production of characteristic radiation.

**X-Radiation and Gamma Rays.** X-radiation (X-rays) and gamma radiation are identical to each other except for their origin and method of production. X-radiation is the result of the conversion of

either the kinetic or potential energy of electrons into another form of energy, while gamma radiation is emitted from radioactive nuclei. X-radiation is produced by radiative interactions of electrons with matter and collisional interactions of electrons with matter.

**Radiative interactions.** When an electron (which is negatively charged) approaches the nucleus (positively charged), it may be deflected from its original direction by the attractive force of the nucleus. The change of direction causes deceleration of the electron or a loss of some of its kinetic energy. The energy lost by the electron may be given off as an X-ray photon. The radiation produced by this type of interaction is called *Bremsstrahlung* (German for "braking radiation"), general radiation, or white radiation. The energy of the resultant photon depends upon (1) the original kinetic energy of the electron, (2) how close the electron comes to the nucleus, and (3) the charge of the nucleus.

Figure 1-4 shows two separate radiative interactions. The two electrons A and B have been deflected from their original direction by the attractive force of the nucleus. The wavy lines represent the emitted X-ray photons. NOTE: Electron A, which passes closer to the nucleus, had its original direction deflected more than electron B. If the original kinetic energy of both electrons had been equal, the photon A' would have more energy than the photon B', because of greater deceleration.

Since in this type of interaction the electron loses only a portion of its kinetic energy, it may have one or more interactions with other atoms before expending all its energy. In this manner, it would produce several photons with various energies. Figure 1-5 shows how an electron might interact with more than one atom to produce photons with a wide range of energies.

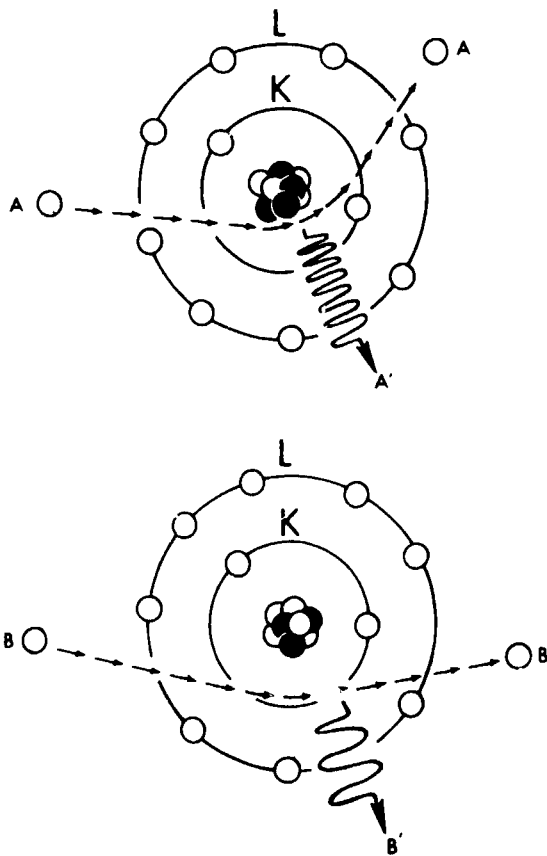


Figure 1-4. Radiative interaction (Bremsstrahlung).

An electron, as well as being decelerated near the nucleus, may occasionally collide with the nucleus. In this case, the electron loses all its energy in the collision, and that energy is given off as a photon. The energy of the photon would be equal to that of the electron. Figure 1-6 shows an interaction of this type.

A beam of Bremsstrahlung radiation has a continuous energy range from a very low energy to the maximum energy possessed by the impinging electrons. The energy spectrum produced by 100keV electrons in tungsten is illustrated in figure 1-7.

**Characteristic radiation.** The discussion up to this point has dealt with how X-rays are generated when electrons interact with the nucleus of an atom. X-rays are also generated when electrons interact with tightly bound orbital electrons. This situation, called collisional interaction of an electron with matter, produces characteristic or line radiation.

In this type of interaction, an electron collides with a tightly bound orbital electron such as an electron in the K shell of an atom of tungsten as in figure 1-8. As a result of the collision, the K electron is ejected from its shell, and energy is absorbed by the atom equal to the binding energy of the shell. The atom is left in an excited state with an excess of energy and an electron vacancy in the shell. Immediately after excitation, the atom returns to a normal state by emitting, in the form of X-ray photons, the energy it has absorbed.

The production of the X-ray photons actually involves several steps. First, another electron, such as from the L shell, fills the vacancy in the K shell. Since the potential energy of an electron in the L shell is higher than that of an electron in the K shell, the L electron loses energy in the transition. The energy lost is equal to the difference in the binding energies of the K and L shell and is given off as an X-ray photon.

Although a photon has been emitted, the process is not yet completed because there is now a vacancy in the L shell, and the atom still has an excess of energy. This vacancy is almost immediately filled by another electron, such as one from the M shell, and another photon is emitted equal to the energy of the difference of the transition. This chain reaction continues with a photon given off for each electron transition until the atom has no shell vacancies and again is in a normal

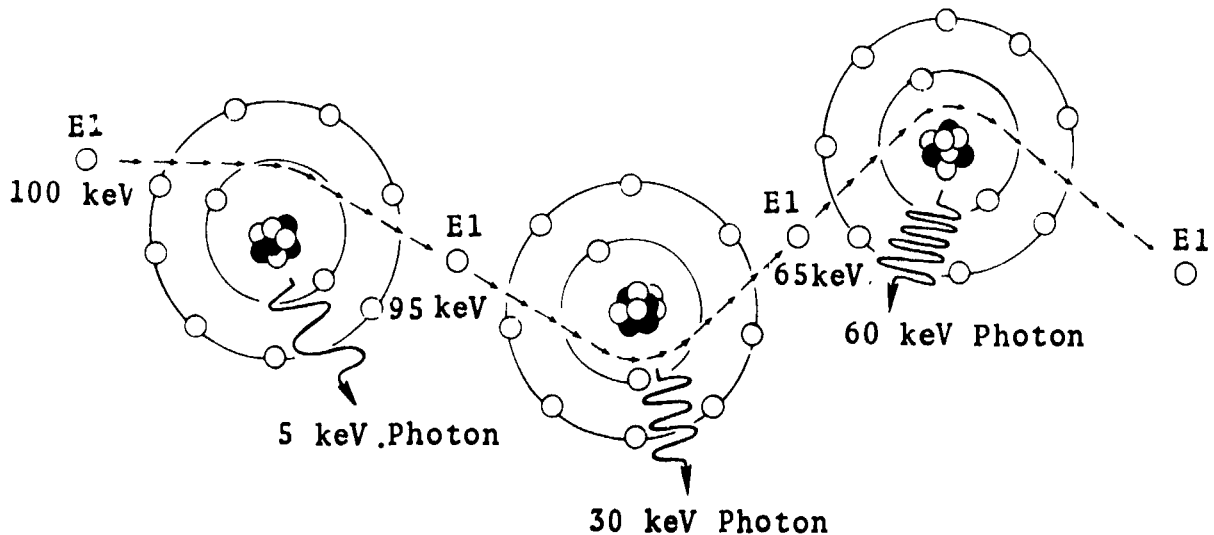


Figure 1-5. Multiple radiative interactions.

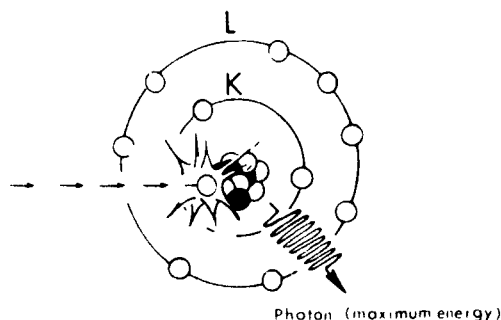


Figure 1-6. Collision of electron with nucleus.

state. (The vacancy in the last shell is filled by a free electron.)

Figure 1-9 shows an atom of tungsten with only the K, L, and M shells demonstrated. The binding energy of tungsten's K, L, and M shells are 69.5, 12, and 2 keV, respectively. In the top illustration, the impinging electron has collided with and ejected a K electron from its shell, and both electrons are seen leaving the vicinity of the atom. In the bottom illustration, as the electron transitions take place, two photons are emitted with energies of 57.5 keV (the difference in binding energies of the K and L shells) and 10 keV (the difference in binding energies of the L and M shells).

The radiation produced in the manner described is called characteristic radiation because its energy is characteristic of the shell of the atom from which it came. The amount of such radiation produced, of course, varies with the type of material. For example, the binding energy of the K shell in copper is 9 keV; therefore, the maximum energy of characteristic radiation that could be generated in copper would be 9 keV, an amount not usable in radiology. Tungsten, however, can generate characteristic radiation with a maximum energy level of 69.5 keV, some of which is usable in diagnostic radiology.

If characteristic radiation is to be generated, an electron must be ejected from its shell. The energy

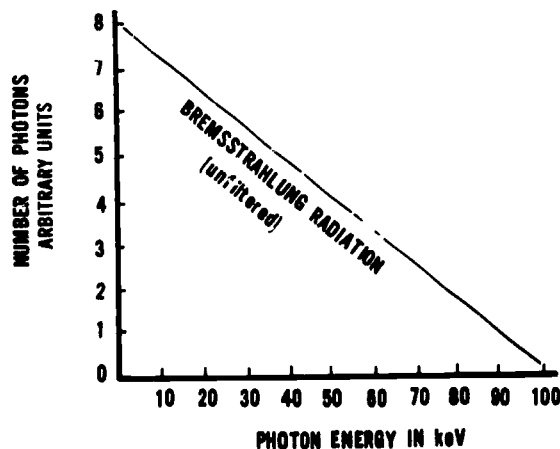


Figure 1-7. Bremsstrahlung radiation energy spectrum.

required to remove an electron from its shell must be equal to or greater than the binding energy of the shell. Since the binding energy of tungsten's K shell is 69.5 keV, it would require an electron with at least 69.5 keV of energy to eject the K electron and thus generate useful characteristic radiation from tungsten. It should be noted that 12 keV of electron energy can eject an L electron (12 keV binding energy) from tungsten, thereby producing characteristic radiation. However, this radiation's maximum energy would be 12 keV, which is not considered useful in radiology and would have to be filtered out.

Throughout the discussion, we have dealt with one electron and its interaction. When millions of electrons interact with millions of atoms in both manners (Bremsstrahlung and characteristic) as described, obviously a wide range of photon energies is generated.

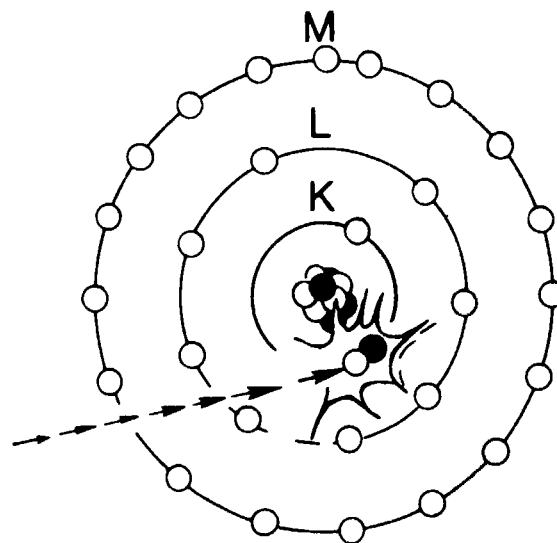


Figure 1-8. Collision of an electron with a K-shell orbital electron.

#### Exercises (004):

Match the types of radiation in column B with their appropriate descriptions or definitions in column A.

- | Column A  | Column B                     |
|---|------------------------------|
| — 1. Electron direction deflected by nucleus.                             | a. X-radiation.              |
| — 2. Electron interaction with orbital electron.                          | b. Gamma radiation.          |
| — 3. Result of converting kinetic or potential energy.                    | c. Bremsstrahlung radiation. |
| — 4. Electron loses only a portion of its kinetic energy.                 | d. Characteristic radiation. |
| — 5. Emitted from radioactive nuclei.                                     |                              |
| — 6. Energy emitted is equal to binding energy of orbit.                  |                              |
| — 7. Energy emitted ranges from very low to energy of impinging electron. |                              |



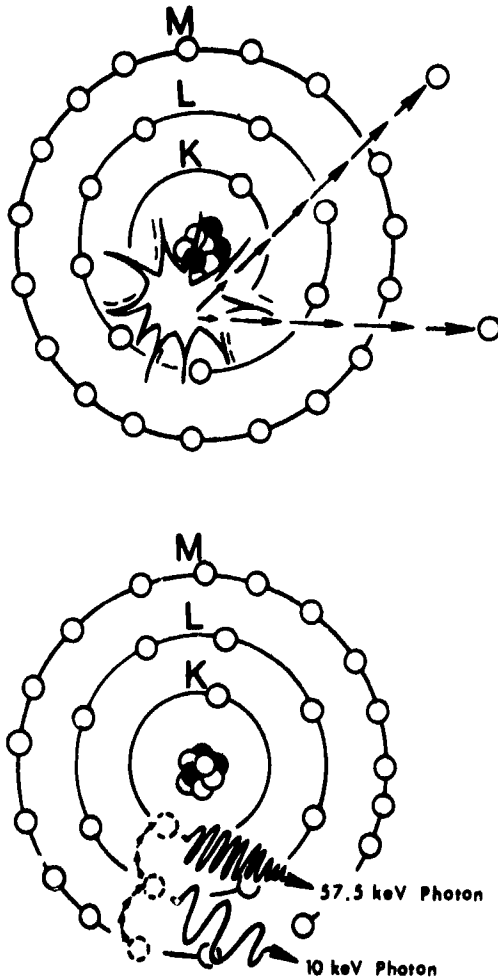


Figure 1-9. Production of characteristic radiation.

### 1-2. Fundamentals of Electricity

The characteristics and effects of electricity can probably be explained best by examining electron theory. Using electron theory, scientists have been able to make discoveries and predications that seemed impossible years ago. The electron not only is the basis of design for electrical equipment but, as mentioned previously, also is directly connected to the production of X-radiation. We shall begin this section with a review of electrical current.

**005. Define "electrical current" and list three factors that influence electron movement in a conductor.**

**Basic Theory of Electrical Current.** The flow or movement of electrons through a conductor constitutes an electrical current. What causes electrons to flow through a conductor? Refer to figure 1-10, which shows two containers of water connected by a pipe. Obviously, the water will flow from left to right until the same amount of water is in both containers. If we compare the drops of water with electrons, then we

could say that the container on the left has a surplus of electrons, and the container on the right has a shortage of electrons. Since electrons have a negative charge, we could also say that the container on the left is negative and the one on the right is positive. This difference between charges is an important factor that affects the movement of electrons in a conductor.

Whenever we have opposite charges, we also have a *difference in potential*, and it is this difference in potential that is required to produce electron flow in a conductor. Similarly, referring to figure 1-10 again, once there is the same water level in both containers, water will stop flowing because there is no longer a difference in potential. In the case of electrons, we could say we have *like charges* when there is no difference in potential.

The flow of water from one container to the other in figure 1-10 is also influenced by the characteristics of the pipe connecting the two. This influence is easy to understand if you imagine how replacing the pipe with one having a smaller diameter would slow the movement of water from one container to another. In case of an electrical current, electron flow is likewise affected by the amount of resistance of the conductor or of other devices present in the circuit.

#### Exercises (005):

1. Define "electrical current."
2. What are three factors that influence the movement of electrons in a conductor?

**006. Differentiate between a conductor, semiconductor, and insulator; given a list of six materials and their valence electrons, classify each according to its conductive properties.**

**Valence Electrons and Conductive Properties.** The electron theory states that all matter is composed of atoms, which in turn are composed of subatomic




Figure 1-10. Demonstrating the effects of difference in potential.

particles called electrons, protons, and neutrons. The electrons orbit the nucleus, and the electrons in the outer orbit are called valence electrons. Now let's concentrate on these valence electrons. The number of valence electrons in an atom determines its electrical characteristics. An atom containing eight electrons in its outer orbit is a stable atom; therefore, it will not readily give up any of its valence electrons. Since a stable atom will not readily give up any of its electrons, any material made up of these atoms would be considered an electrical *insulator* or a poor conductor of electricity. Atoms with three or less valence electrons are unstable, and the electrons can be easily dislodged from the parent atom. Therefore, we would call a material made up of atoms with three or less valence electrons in its outer orbit a *conductor* (a good conductor of electricity). Copper (one valence electron) and iron (two valence electrons) are good conductors of electricity. An atom having four electrons in its outer orbit is neither a good conductor nor a good insulator. We call material made up of atoms having four valence electrons a *semiconductor* material. Note that all metals are conductors of electricity to some extent, but some are better conductors than others. However, there is *no* perfect conductor or insulator.

**Exercises (006):**

1. What is the difference between the conductive properties of a conductor, a semiconductor, and an insulator?
  
2. Classify the following materials as conductors, insulators, or semiconductors.
  - \_\_\_\_\_ a. Silver (one valence electron).
  - \_\_\_\_\_ b. Germanium (four valence electrons).
  - \_\_\_\_\_ c. Krypton (eight valence electrons).
  - \_\_\_\_\_ d. Silicon (four valence electrons).
  - \_\_\_\_\_ e. Copper (one valence electron).
  - \_\_\_\_\_ f. Aluminum (three valence electrons).

**007.** Indicate whether statements correctly reflect relationships between current and voltage.

**Direct Current Characteristics.** Now that we have reviewed some basic facts about electrical current and conductive properties of certain materials, let's look at some characteristics of direct current (dc). Basically our discussion is centered around three terms: *current*, *voltage*, and *resistance*.

**Current.** Current refers to the electrons flowing in a circuit. The unit of measure for a specific number of

electrons is a *coulomb*. By counting the number of coulombs that pass a given point in 1 second of time, we can measure the rate of current flow. The unit of measurement for current flow is the *ampere* (A). There is 1 ampere of current flowing when 1 coulomb of electrons passes a point in a conductor in 1 second, 2 amperes when 2 coulombs pass a point in 1 second, etc.

Since the term "ampere" means coulombs per second, the ampere is a measure of the *rate* at which electrons are moving through a material. We can go back to figure 1-10 and compare amperes to the rate at which the drops of water flow through the pipe. The coulomb, or number of electrons in a charge, is a measure of quantity, as stated before, and can be compared to the number of water droplets present in the container on the left of figure 1-10. When we speak of so many coulombs per second, or amperes, we are referring to the intensity of the current. Since amperes refers to how *intense* the current is, the standard symbol for current is *I*.

**Voltage.** As previously mentioned, a difference between electrostatic charges, also known as a difference in potential, is necessary to move electrons through a conductor. We can also say this difference in potential represents an electrical charge, which in turn represents a certain amount of potential energy. The unit of measurement for this charge is the *volt*. Its symbol is *E*. Voltage is also known as *electromotive force* (EMF).

Since an electrical charge is expressed in volts, the difference in potential is also expressed in volts. Also, since voltage represents the *difference* between charges or *difference* in potential, voltage can exist between two different points even though there is no charge present at one of the points. For example, if one point in a conductor has no charge, it is positive with respect to a negative charge and negative with respect to a positive charge. Voltage also exists between two unequal positive charges and two unequal negative charges. Thus, voltage is purely relative and does not represent a specific charge but rather the difference between one charge and another.

When two points of unequal charges are connected, current flows from the negative to the positive charge, from the less positive to the more positive charge, or from the more negative to the less negative charge. The greater the voltage between the two points, the greater the amount of current moving between the two points.

**Exercises (007):**

Indicate whether the following statements are true or false. If you indicate false, explain your answer.

- T F 1. A coulomb is a measure of a number of electrons.
- 
- T F 2. An ampere is a unit of measure for the rate of electron flow.

T F 3. If 1 coulomb of electrons flows past a given point in a conductor in 3 seconds, 3 amperes of current are flowing in that conductor.

T F 4. The symbol  $Q$  means the same as the number of coulombs present in a charge.

T F 5. The volt is the unit of measure for the difference between two electrostatic charges.

T F 6. EMF is the same as difference in potential.

T F 7. Voltage and difference in potential are two different factors.

T F 8. Voltage cannot exist between two positive charges.

T F 9. Current flows from positive to negative.

T F 10. The voltage value between two unequal negative charges can equal the voltage between two unequal positive charges.

**008. Define "electrical resistance" and state how and in what unit electrical resistance is measured.**

**Resistance.** Under objective 005 of this chapter, we mentioned that electron flow is affected by the amount of resistance present in the conductor or in the electrical devices. We can describe electrical resistance as the opposition to current flow. The greater the resistance present in a circuit, the more limited will be the flow of electrons.

The unit of measurement for resistance is the *ohm*. It is that amount of resistance which allows exactly 1 ampere of current to flow when 1 volt is applied across the resistance. An ohmic value is designated by the symbol  $\Omega$  and we use the letter  $R$  to designate resistance.  $R$  then might equal  $2\Omega$ ,  $5\Omega$ , or  $100\Omega$ .

**Exercises (008):**

1. What is electrical resistance?

2. What is the unit of measurement for resistance?

3. How much resistance is equal to a single measurement unit?

4. Using the appropriate symbol and abbreviation, how would you write "resistance = 4 ohms"?

**009. Relate four conductor characteristics (material, length, cross-sectional area, and temperature) to conductor resistance.**

The resistance of a wire conductor or any object for that matter depends upon four factors: (1) the material, (2) length, (3) cross-sectional area, and (4) temperature.

The *material* of which a conductor is made affects its resistance. We previously discussed materials in general terms, classifying them as conductors, semi-conductors, or insulators. More specifically, one conductor may offer less resistance to current flow than another conductor. Copper, iron, and aluminum are all classified as conductors, yet copper is a better conductor than the other two because it offers the least resistance. Iron offers less resistance than aluminum.

The next factor greatly affecting the resistance of a conductor is its *length*. The longer a conductor, the greater its resistance; and the shorter the conductor, the lower its resistance. The resistance to moving electrons depends upon the number of collisions with other electrons and atoms in a linear path. If the resistances of two different conductors, one twice as long as the other, are compared, the long conductor offers twice as much resistance as the short one, assuming the two conductors are otherwise equal. In other words, the resistance of a conductor is proportional to its length.

Another factor affecting conductor resistance is its *cross-sectional* area. The greater the cross-sectional area, the lower the resistance; the smaller the cross-sectional area, the greater the resistance. A large cross-sectional area provides a larger space through which the electrons move; consequently, fewer electron collisions result. If we compare the resistance of two conductors, one with twice the cross-sectional area of the other, the larger conductor offers only one-fourth as much resistance as does the small one.

The final factor affecting the resistance of a conductor is its *temperature*. For *most* materials, the hotter the material, the more resistance it offers to an electrical current; and the colder the material, the less resistance it offers to the electrical current. This effect comes about because a change in the temperature of a material changes its molecular activity. The effect of temperature upon resistance is the least important of the four factors—material, length, cross-sectional area, and temperature—that control resistance.

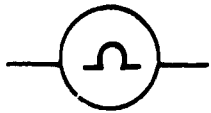
**Exercises (009):**

1. Assuming all other factors are equal, do two current-carrying wires made of different materials offer the same resistance to current flow?
2. Assuming all other factors are equal, does copper offer more or less resistance than iron? Does aluminum offer more or less resistance than copper?
3. If a 3-foot conductor offers  $6\Omega$  resistance, how much resistance does a 1-foot conductor offer if all other factors are equal?
4. Why is the resistance of a conductor influenced by conductor length?

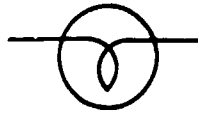
5. If a conductor's resistance is  $2\Omega$ , how much resistance is present in a conductor with twice the cross-sectional area if all other factors are equal?
6. Does conductor temperature affect its resistance? If so, does a big temperature increase or decrease resistance?
7. Of the factors discussed that affect conductor resistance, which one is least important?

**010. Given a schematic of a circuit showing various component symbols, identify the symbols shown.**

**Symbols of Circuit Components.** For simplicity and to save space, symbols of circuit components are used rather than pictures. While it is not necessary for you to identify all component symbols, you will need to identify some of the most common symbols used throughout this chapter. In addition, this knowledge will aid you considerably in interpreting other technical literature. Figure 1-11 shows the common circuit symbols you should know. (NOTE: When a battery symbol is used, the battery voltage is sometimes written alongside the symbol.)



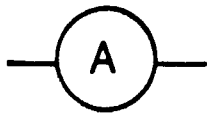OHM METER



LAMP



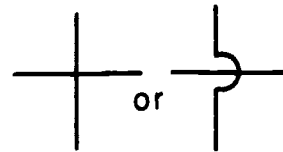
FUSE



AMMETER



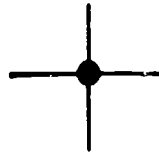FIXED RESISTOR



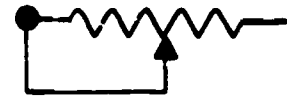CROSSED OVER WIRES



VOLTMETER



CONNECTED WIRES



VARIABLE RESISTOR



SWITCH



BATTERY



GROUND

Figure 1-11. Some common circuit component symbols.

**Exercises (010):**

1. Figure 1-12 is a circuit schematic showing 11 commonly used component symbols. Opposite the appropriate numbers below, write the name of each component symbolized in figure 1-12.

- 1.
- 2.
- 3.
- 4.
- 5.
- 6.
- 7.
- 8.
- 9.
- 10.
- 11.

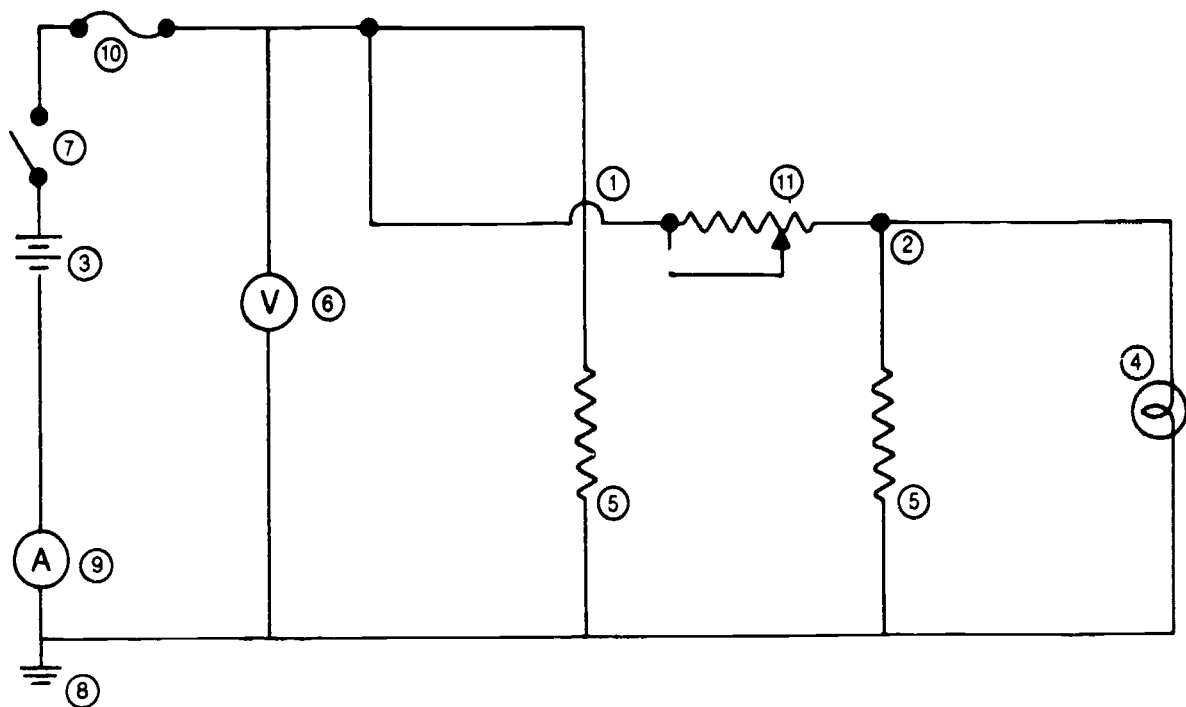


Figure 1-12. Objective 010, exercise 1.

**011. Using the formulas derived from Ohm's law, find the following circuit values: (1) current if voltage and resistance are given, (2) resistance if voltage and current are given, and (3) voltage if current and resistance are given.**

**Ohm's Law.** So far, our discussions of current, voltage, and resistance have dealt mostly with the relative values of those elements. Now, let's see how we can determine the specific value of any one of the three elements when we know what the other two values are.

The relationships between current, voltage, and resistance are expressed in Ohm's law. The law states: "In a dc circuit, current varies directly with the voltage and inversely with the resistance." If we know two of the three values, we can, by using the formulas derived from Ohm's law, determine the other value. The formulas are as follows:

$$\text{Current: } I = \frac{E}{R}$$

$$\text{Resistance: } R = \frac{E}{I}$$

$$\text{Voltage: } E = I \times R$$

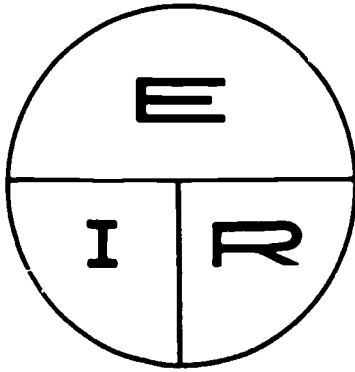


Figure 1-13. The Ohm's law chart.

An easy way to remember these formulas is to use the chart shown in figure 1-13. To use these formulas, cover the letter symbol for the value you are trying to determine. For instance, if you cover up the  $E$ , all you have left is  $I \times R$ . Therefore, in order to find the voltage, your formula is  $E = I \times R$ . Now, if you want to solve for current, you cover up  $I$ . This will leave you with  $\frac{E}{R}$ . Therefore, if you want to calculate the current, your formula would be  $I = \frac{E}{R}$ . If you need the formula for resistance, just cover up the  $R$  and you will get the formula  $R = \frac{E}{I}$ . Now let's see how Ohm's law is applied to a simple dc circuit.

If you look at the circuit in figure 1-14, you will see that it has a battery which is providing 6 volts. The lamp has a resistance of 2 ohms when the switch is closed, and the problem is to find the current. Since you are looking for current, you use the formula  $I = \frac{E}{R}$ . When you substitute the two known values for  $E$  and  $R$ , you have  $\frac{6}{2}$ . Therefore,  $I = \frac{6}{2}$  or  $I = 3$  amps. Even though you now know all the values in this circuit, let's use the formula for practice to prove each value. First, let's solve the  $R$ , the formula for which is  $R = \frac{E}{I}$ . Substituting values, we have  $= \frac{6}{3}$ , or  $R = 2$

ohms. To solve for  $E$ , the formula is  $E = I \times R$ . Therefore,  $E = 3 \times 2$ , or  $E = 6$  volts.

**Exercises (011):**

1. What is the resistance in a circuit if the voltage is 110 volts and the current is 5 amperes?
2. What is the voltage in a circuit if the current is 2 amperes and the resistance is 55 ohms?
3. What is the current in a circuit if the voltage is 12 volts and the resistance is 4 ohms?

**012. Given a schematic of a series circuit, including total voltage and individual resistor values, find the current at various points in the circuit, the total resistance of the circuit, and the voltage drop across each resistor.**

Electrical circuits are classified according to the way their components are arranged or connected. The three types of circuits are *series*, *parallel*, and *series-parallel*. (See fig. 1-15.)

**Series Circuit.** A series circuit is one in which the components are connected end to end and there is only one path for the current. See figure 1-16,A, which shows three electrical devices connected in series.

Now let's discuss the behavior of current, resistance, and voltage in a dc series circuit. Current is the simplest, so let's consider it first, with the aid of figure 1-16,B. If we close the switch, completing the circuit, the three ammeters should show the amount of current

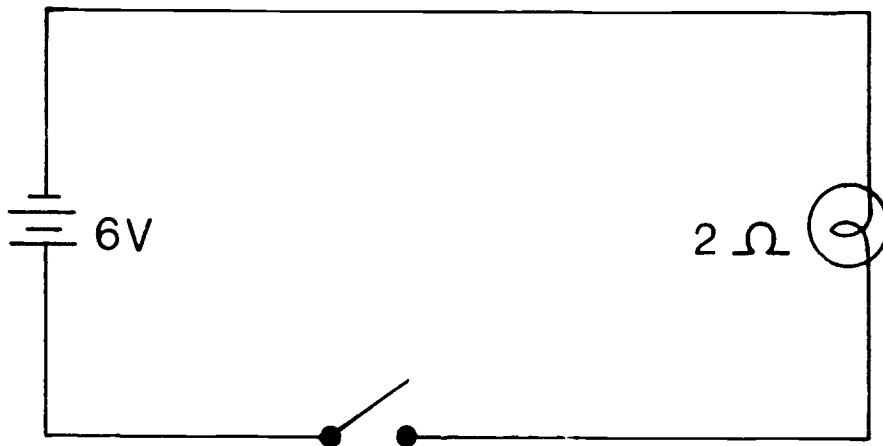


Figure 1-14. A simple dc circuit.

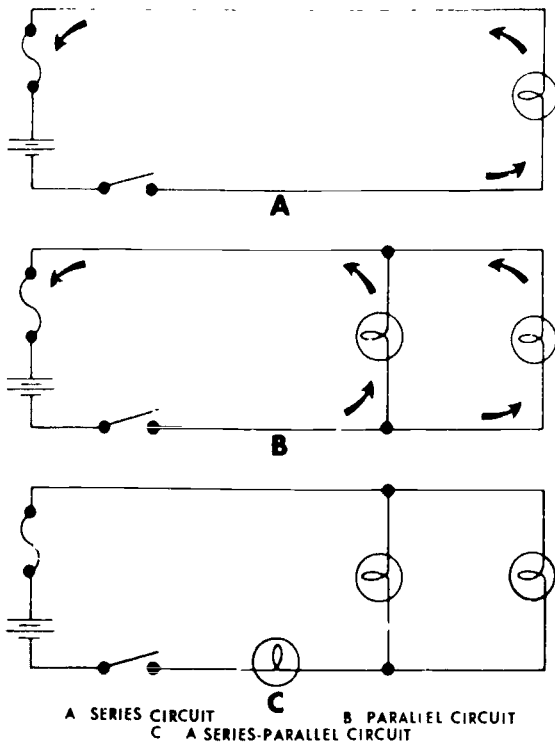


Figure 1-15 Representative simple circuits.

at various points in the circuit. All the ammeters should read the same amount of current. This is the first important thing to remember about a series circuit: *current is the same at all points in a series circuit.* This fact is sometimes expressed in formula form as:

$$I_1 = I_2 = I_3 \dots$$

Total Current equals Current through  $R_1$  equals Current through  $R_2$

It doesn't matter how many resistors you have. If there were five resistors in the circuit, the formula would be:

$$I_1 = I_2 = I_3 = I_4 = I_5$$

Notice that we haven't said how much current there is. We have said merely that whatever the current is, it's the same everywhere in the circuit.

The total resistance in a series circuit is equal to the total of the separate resistors. No matter how many resistors are in a series circuit, they all have to be added to find the total resistance. This rule can be expressed as the following formula:

$$R_t = R_1 + R_2 + R_3 + R_4$$

In a circuit, the voltage drop across a resistor is the voltage required to force the current through the resistor. The total of the voltage drops across all the resistors in a series circuit equals the voltage applied to the circuit. To determine the voltage drop across each resistor, use Ohm's law ( $E = I \times R$ ). For example, if there are two resistors in a 12-volt circuit with values of  $2\Omega$  and  $4\Omega$ , the voltage drop across each resistor is 4 volts and 8 volts respectively. Of course, you must first determine the current in the circuit by using Ohm's law before you can determine the voltage drop. In our example cited above, the current in the circuit is 2A, since  $I = \frac{E}{R}$  ( $E = 12V$  and  $R_t = 6\Omega$ ). Then to find the voltage drop across the  $2\Omega$  resistor, use the formula  $E = I \times R$ . Since  $I = 2A$  and  $R = 2\Omega$ , the voltage drop is 4 volts. The voltage drop across the  $4\Omega$  resistor is 8 volts, since  $I = 2A$  and  $R = 4\Omega$ .

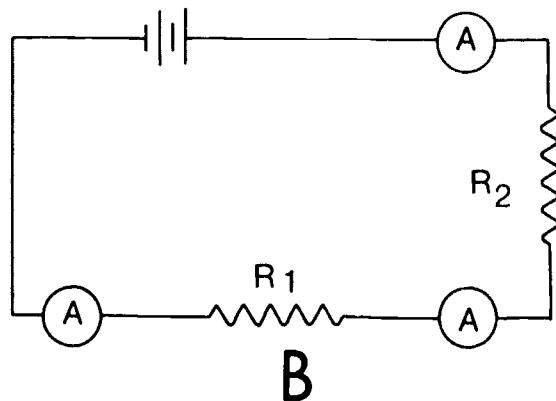
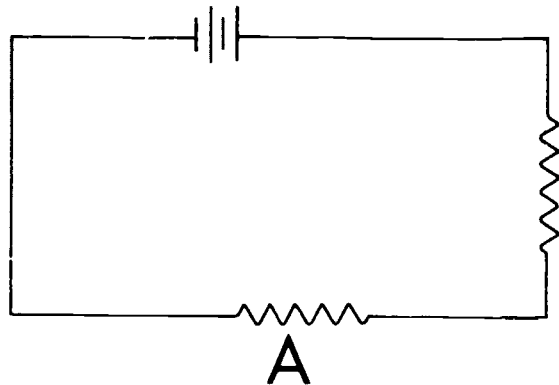


Figure 1-16. Representative series circuits



**Exercises (012):**

Using figure 1-17, answer the following questions.

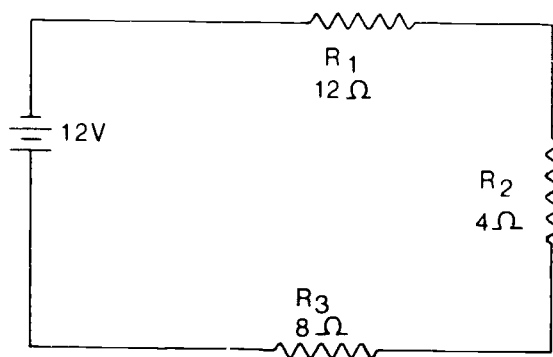


Figure 1-17 Objective 012, exercises 1 through 3.

1. What is the current between  $R_3$  and  $R_2$ ? Between  $R_2$  and  $R_1$ ? Between  $R_1$  and the battery?
2. What is the total resistance in the circuit?
3. What is the voltage drop across  $R_1$ ? Across  $R_2$ ? Across  $R_3$ ?

**013. Given a schematic of a parallel circuit, including the total voltage and individual resistance values, find the voltage at various points within the circuit, the current through each resistor, and the total resistance of the circuit.**

**Parallel Circuit.** It is often necessary to connect electrical devices in a circuit so that the total voltage is applied across each device. A circuit in which two or more devices are connected across a common power source is called a parallel circuit. Let's examine the behavior of voltage, current, and resistance in a parallel circuit.

Note in figure 1-18 that points a, b, c, and d are connected and are one point electrically. Similarly, points e, f, g, and h comprise another electrical point. Since the applied voltage appears between points a and e, the same voltage appears between points b and f and between points c and g, as well as between points d and h. So it can be said that *when resistors are connected in parallel across a voltage source, each resistor has the same voltage applied to it, although the currents may differ, depending upon the values of resistance.* The voltage in a parallel circuit may, therefore, be expressed mathematically as follows:

$$E_t = E_1 = E_2 = E_3$$

where  $E_t$  is the applied voltage,  $E_1$  is the voltage across  $R_1$ ,  $E_2$  across  $R_2$ , and  $E_3$  across  $R_3$ .

The current, on the other hand, divides among the various branches in a parallel circuit in a manner depending upon the resistance of each branch. In a parallel circuit, branches with low resistance draw more current than branches with high resistance. Therefore, the current in the circuit may be expressed mathematically as follows:

$$I_t = I_1 + I_2 + I_3$$

where  $I_t$  is the total current and  $I_1$ ,  $I_2$ , and  $I_3$  are the current through  $R_1$ ,  $R_2$ , and  $R_3$  respectively.

The total resistance in a parallel circuit is always less than the lowest resistance in the circuit. There are several methods to compute the total resistance. However, the reciprocal method will be the only one discussed here. As a rule, we can say that the effective resistance of parallel resistors is equal to the reciprocal of the sum of the reciprocals. Although this idea may sound complicated, it is not. Let's look at the formula:

$$\frac{1}{R_t} = \frac{1}{R_1} + \frac{1}{R_2} + \frac{1}{R_3}$$

Suppose the values of the resistors above are  $R_1$ , 1 ohm;  $R_2$ , 2 ohms; and  $R_3$ , 2 ohms. Substituting the resistance values in the formula, we find:

$$\begin{aligned} \frac{1}{R_t} &= \frac{1}{1} + \frac{1}{2} + \frac{1}{2} \\ \frac{1}{R_t} &= \frac{2}{2} + \frac{1}{2} + \frac{1}{2} \\ \frac{1}{R_t} &= \frac{4}{2} \\ \frac{1}{R_t} &= 2 \\ \frac{1}{R_t} &= \frac{2}{1} \\ 2 R_t &= 1, \text{ or } R_t = 0.5 \end{aligned}$$

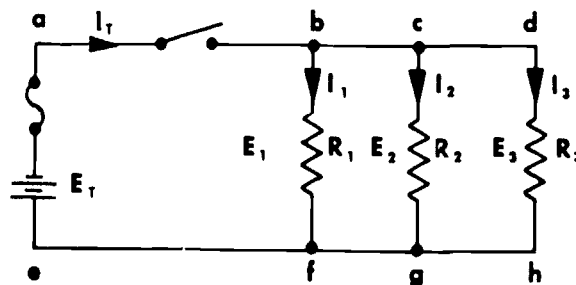


Figure 1-18. A parallel dc circuit.

Therefore, the total resistance in the parallel circuit would be 0.5 ohm.

**Exercises (013):**

Using figure 1-19, complete the following exercises.

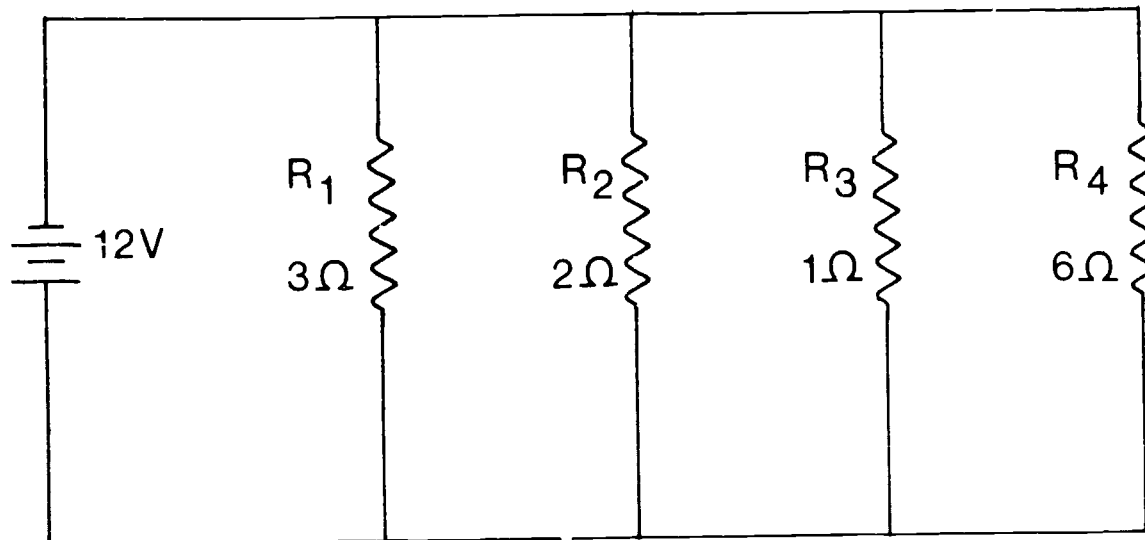


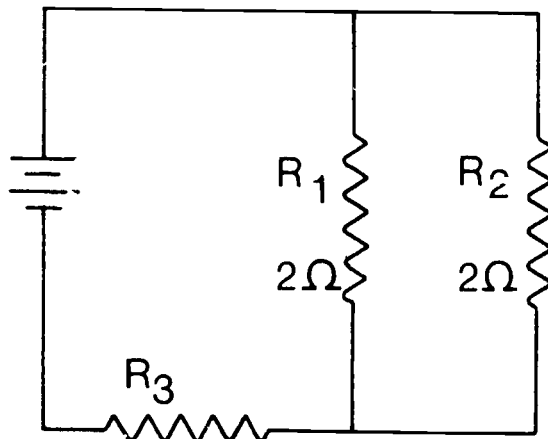
Figure 1-19 Objective 013, exercises 1 through 4

1. What is the voltage across  $R_1$ ? Across  $R_4$ ?
2. What is the current through  $R_1$ ? Through  $R_2$ ? Through  $R_3$ ? Through  $R_4$ ?
3. What is the total current in the circuit?
4. What is the total resistance in the circuit?

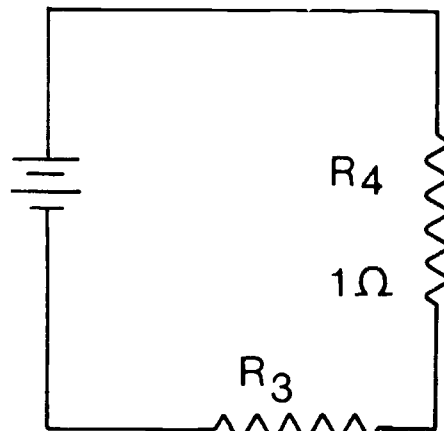
**014. Given a schematic of a series-parallel circuit, find the total resistance in the circuit.**

**Series-Parallel (Compound) Circuit.** A series-parallel circuit consists of two or more parallel resistors connected in a series with one or more resistors. Let's look at such a circuit and see the relationships between current, voltage, and resistance.

The easiest way to find the different values is to redraw the circuit into a series circuit and find the values just as you would any other series circuit. Figure 1-20,A, shows a dc series-parallel circuit with three resistors. The first thing you should do is to find the equivalent resistance of the parallel resistors ( $R_1$  and  $R_2$ ) by using the reciprocal method. Then redraw the circuit into a series circuit (fig. 1-20,B) to include  $R_3$  and another resistor  $R_4$ , which represent the equivalent resistance of  $R_1$  and  $R_2$ . In this case, the resistance of  $R_4$  is  $1\Omega$ .



A



B

Figure 1-20 Direct-current series-parallel circuit redrawn into a series circuit to find the total resistance

**Exercise (014):**

- Figure 1-21 shows a dc series-parallel circuit. What is the total resistance of the circuit?

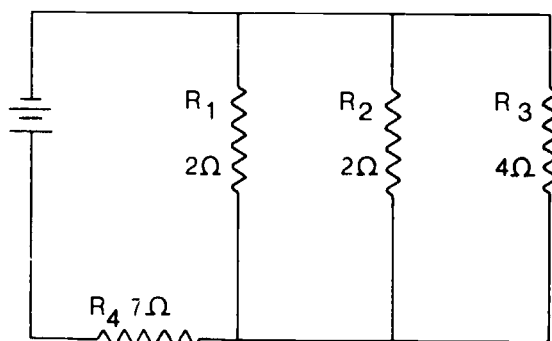


Figure 1-21 Objective 014, exercise 1

shown in figure 1-22. Also shown is an invisible magnetic field, which is present around and inside a magnet. This magnetic field can be demonstrated by placing a piece of paper over a bar magnet and sprinkling iron filings on the paper. Tap the paper gently, and the iron filings will arrange themselves to coincide with the magnetic field (as shown in fig. 1-23). The magnetic field is made of *lines of force*, also called *flux lines*. These lines of force travel from the north pole to the south pole outside the magnet and from the south pole to the north pole within the magnet. The strength of a magnetic field depends upon the number of lines of force per unit area: the more concentrated the lines, the stronger the field. These lines are more concentrated at the poles.

*Laws of attraction and repulsion.* There are two laws that describe the attraction and repulsion of magnetic poles: (1) like magnetic poles repel each other, and (2) unlike magnetic poles attract each other.

**015. Define "magnetism," explain basic aspects of a magnetic field, and state the laws of magnetic attraction and repulsion.**

**Magnetism.** Since there is a definite relationship between electricity and magnetism, a study of electricity must include a discussion of magnetism. It is of special importance to you because magnetism is used in many aspects of X-ray machine and other related equipment operation. Magnetism can be defined as a force that attracts iron, steel, or other magnetic substances.

*Magnetic field.* A magnet, regardless of shape or size, has a north pole (N) and a south pole (S), as

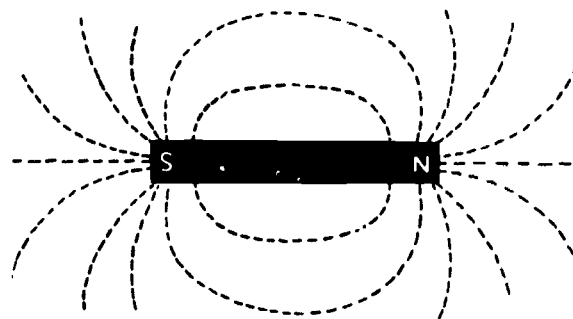


Figure 1-22. Magnetic poles and magnetic field

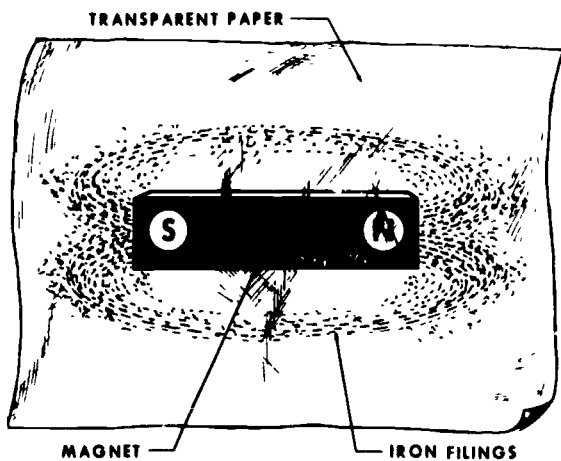


Figure 1-23 Demonstration of the magnetic field

**Exercises (015):**

1. Define "magnetism."
2. Where, in relation to the magnet itself, is the magnetic field located?
3. In what directions do the lines of force travel?
4. What determines the strength of a magnetic field?
5. State the laws of magnetic attraction and repulsion.

**016. Differentiate between magnetic and nonmagnetic substances; and indicate whether statements pertaining to magnetic dipoles and their relationships to a magnetic field are correct.**

*Magnetic and nonmagnetic substances.* All matter is affected to some extent by a magnetic field. Substances strongly attracted by a magnetic field are called magnetic substances, and substances not noticeably affected by a magnetic field are generally classified as nonmagnetic substances. Iron and steel are examples of strongly magnetic materials, while wood, copper, and glass are nonmagnetic.

Magnetic materials consist of millions of tiny elementary magnets, called *magnetic dipoles* or *magnetic domains*, which are molecular or atomic in

size. When these dipoles are arranged at random in an unmagnetized bar of iron or steel (fig. 1-24,A), the cumulative magnetic strength of the dipoles is neutralized. If a magnetizing force is applied to the iron bar, the dipoles become aligned so that all their north poles point in one direction (fig. 1-24,B). With the dipoles aligned in this manner, their magnetic strengths are combined, and lines of force, or a magnetic field, result. The bar is then magnetized. The direction of travel of the lines of force in and around this magnet is established, based upon the alignment of the poles of the magnetic dipoles. See figure 1-24,C.

**Exercises (016):**

1. What is the difference between magnetic and non-magnetic substances?
2. Give two examples of a magnetic material and three examples of a nonmagnetic material.
3. Indicate whether the following statements are true or false.  
T F a. In an unmagnetized magnetic material, the magnetic dipoles are arranged in a random pattern.

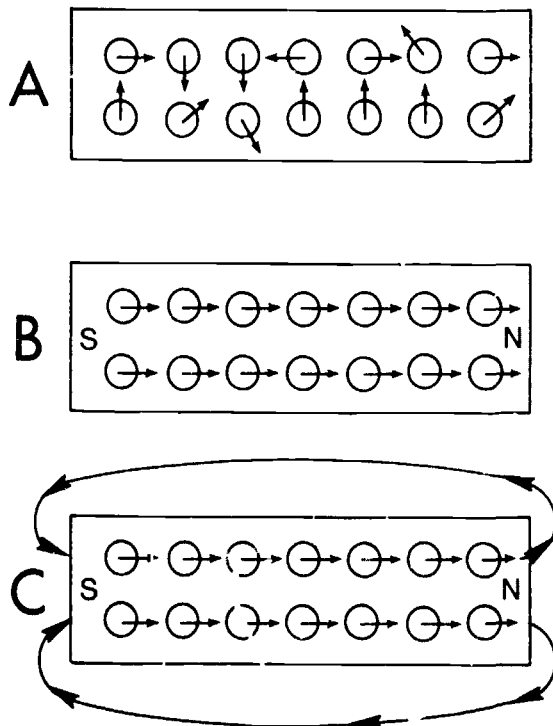


Figure 1-24. Iron bar showing arrangement of magnetic dipoles before and after application of a magnetizing force. (Also shown is the relationship between dipole alignment and direction of lines of force.)

- T F b. Uniform alignment of magnetic dipoles results in an external magnetic field.
- T F c. Direction of travel of lines of force is determined by the direction of alignment of the magnetic dipoles.

017. Explain the relationship between a current-carrying conductor and the electromagnetic field around the conductor.

**Electromagnetism.** When a current is passed through a wire conductor, a magnetic field similar to the magnetic field of a bar magnet is created around the conductor. This magnetic field is sometimes called an electromagnetic field.

*Relationships between conductors and magnetic fields.* The lines of force around a straight, current-carrying conductor are circular and at right angles to the direction of current flow (see fig. 1-25). The magnetic field in this case does not have a north or south pole.

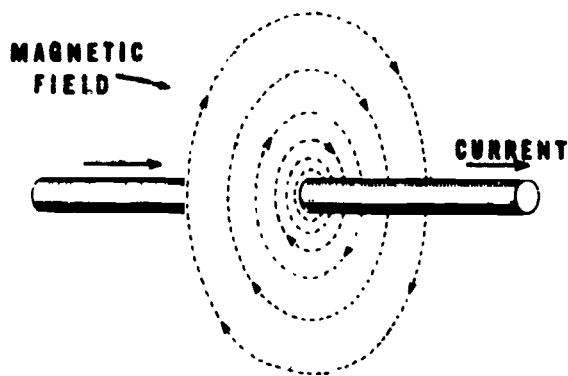


Figure 1-25 Electromagnetic field around a straight current-carrying conductor

If a current-carrying conductor is formed into a loop or coil, as illustrated in figure 1-26, the lines of force pass through the inside of the coil, as shown. As a result, a north pole is created on one side of the loop and a south pole on the other. The direction of the lines of force is the same as that of a bar magnet, with the inside of the coil representing the magnetic bar.

If the wire conductor is formed into many loops, as shown in figure 1-27, the lines of force around the individual loops combine to form a larger and stronger magnetic field. A north and a south pole are then established at opposite ends of the coil.

**Exercises (017):**

1. What condition must exist for a magnetic field to be created around a wire conductor?

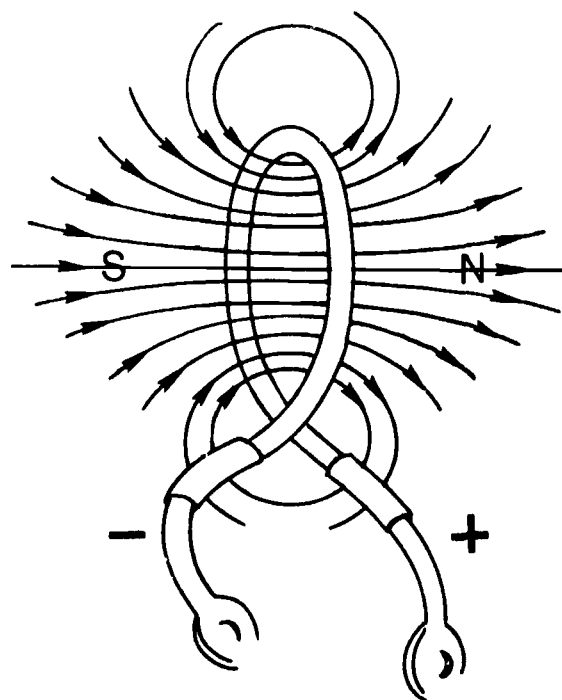


Figure 1-26 Electromagnetic field around a single wire conductor loop.

2. Does polarity exist in the magnetic field of a straight conductor? If not, what can a person do to create a north and a south pole within the magnetic field?
3. Where are the north and south poles located with respect to a current-carrying coil?

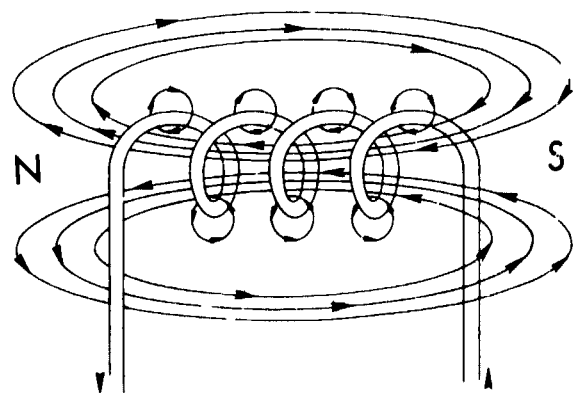


Figure 1-27. Electromagnetic field around a wire conductor formed into several loops

018. List three factors influencing the magnetic strength of a coil, and in each case, explain the relationship between the influential factor and the magnetic strength.

*Factors influencing the magnetic strength of a coil.* When a conductor is wound into a coil, the lines of force around each loop combine with those from other loops to form one magnetic field. It follows that the more loops or turns per unit area—or we can say *the more turns per inch*—the stronger the field.

As the current through the conductor increases, so does the number of lines of force around the conductor; consequently, a higher current also produces a stronger magnetic field.

Another factor that influences the magnetic strength of a coil is the insertion of an iron core in the center of the coil. The iron core affects the magnetic strength for two reasons: (1) the core itself becomes magnetized and its magnetic strength is added to that of the coil, and (2) the core provides an easier pathway for the lines of force to travel; thus the lines of force concentrate themselves within the core. Soft iron is usually used as core material because it has a high permeability, which determines the ability of a material to conduct or concentrate lines of force. (NOTE: Soft iron also has low retentivity. Retentivity is the ability of a substance to remain magnetized after the current is turned off. Low retentivity is necessary for precise control of an electromagnetic field.)

#### Exercises (018):

In exercises 1 through 3 below, list three factors influencing the magnetic strength of a coil. After each factor, explain how it affects the magnetic strength.

- 1.
- 2.
- 3.

019. Indicate whether statements concerning the centering effect of an iron core are correct.

*Iron core centering effect.* The iron core we have discussed is useful in the construction of various electrical devices. Its usefulness is attributed partly to a phenomenon known as the centering effect. Due to this phenomenon, an iron core, when inserted into a current-carrying coil, automatically centers itself to the length of the coil. Also, if the core is suspended off

center inside a coil without current, the core will center itself if current is applied to the coil. The centering effect is used in several electrical applications, such as solenoids, magnetic locks, and circuit breakers.

#### Exercises (019):

Indicate whether the following statements are true or false. If you indicate false, explain your answer.

- T F 1. Due to the centering effect, if an iron core is suspended within a coil with current, the core automatically centers itself to the length of the coil.
- T F 2. The centering effect is used in the construction of magnetic locks, circuit breakers, and solenoids.

020. State the principle underlying relay operation, and explain the effects of an electromagnet in operating a relay.

*Electromagnets and relays.* If an iron core is installed in a fixed position within a coil, the device is known as an *electromagnet*. A frequent use of an electromagnet is in a relay. While relays are of many different sizes and shapes, they all operate on the principle that an electromagnet attracts magnetic substances (usually iron). Let's examine the parts of a simple relay and a simple relay-controlled circuit.

Figure 1-28 shows the parts of a relay: (1) an insulated coil of wire wrapped around an iron core and (2) a pivoting iron bar. When current is introduced into the coil, a magnetic field is created, represented by the broken lines. This attracts the pivoting bar. The iron bar can be used to close or open a circuit; consequently, a relay can be normally open or normally closed. Remember, in a closed circuit, current is flowing; in an open circuit, current flow has stopped.

A relay can also be used to remotely control a neighboring circuit, such as the one seen in figure 1-29. When the switch is closed in the relay circuit, a magnetic field is created, which is represented by the broken lines. The iron bar in the adjacent circuit is attracted to the iron core and closes the adjacent circuit. If the switch is then opened in the relay circuit, the magnetic field around the coil collapses, allowing the spring to open the adjacent circuit.

#### Exercises (020):

Complete the following statements by writing one word in each blank space.

1. The iron core in an electromagnet is in a \_\_\_\_\_ position within the coil.

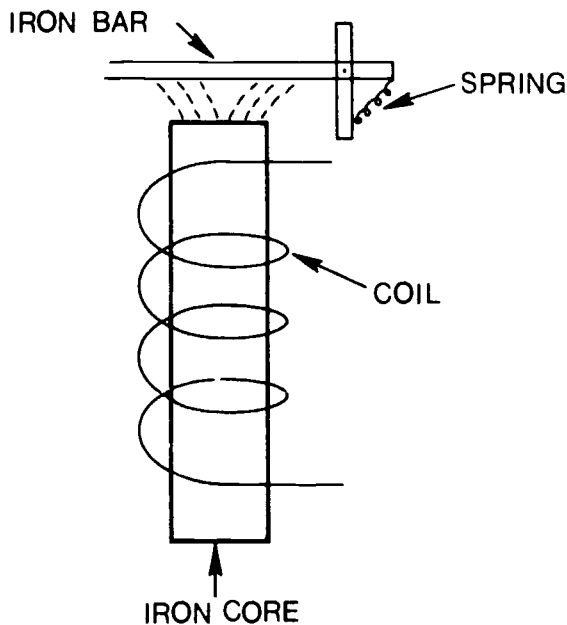


Figure 1-28. The parts of a relay.

2. A major use of an electromagnet is in a \_\_\_\_\_.
3. The principle of operation for a relay is that an electromagnet attracts \_\_\_\_\_ substances.
4. In a relay, the contacts are closed or opened due to the attraction between the \_\_\_\_\_ and the \_\_\_\_\_ iron bar.
5. If a relay-controlled adjacent circuit is closed when current is flowing in the coil of the electromagnet,

the adjacent circuit is \_\_\_\_\_ by \_\_\_\_\_ action when the switch is opened in the relay circuit.

021. Describe the operation of moving coil meters.

*Moving coil meters.* We now turn our attention to meters and meter movements. Electromagnetism is the effect of current flow upon which most meter operations are based. (NOTE: Other effects of electricity are used to detect the presence or amount of electricity; however, our discussion is limited to meter operation based upon the electromagnetic effect.) The most common type of meter movement is the permanent-magnet, moving-coil movement, used in the d'Arsonval meter (fig. 1-30).

Basically, the operation of the meter is quite simple. Direct current is introduced into several turns of copper wire wound around the moving coil. The current produces a magnetic field around the coil, which reacts with the magnetic field formed by the permanent magnet in which the coil is suspended. The coil, which has become an electromagnet, turns on its axis as its poles attempt to repel the like poles of the permanent magnet. An indicating needle mounted on the coil reads the degrees of rotation on the scale. The more current that passes through the coil, the greater is the repulsion or needle deflection, and thus the higher the reading on the scale.

Meters with permanent-magnet, moving-coil movement are used in X-ray machines to measure such values as line voltage, kVp, mA, and mAs.

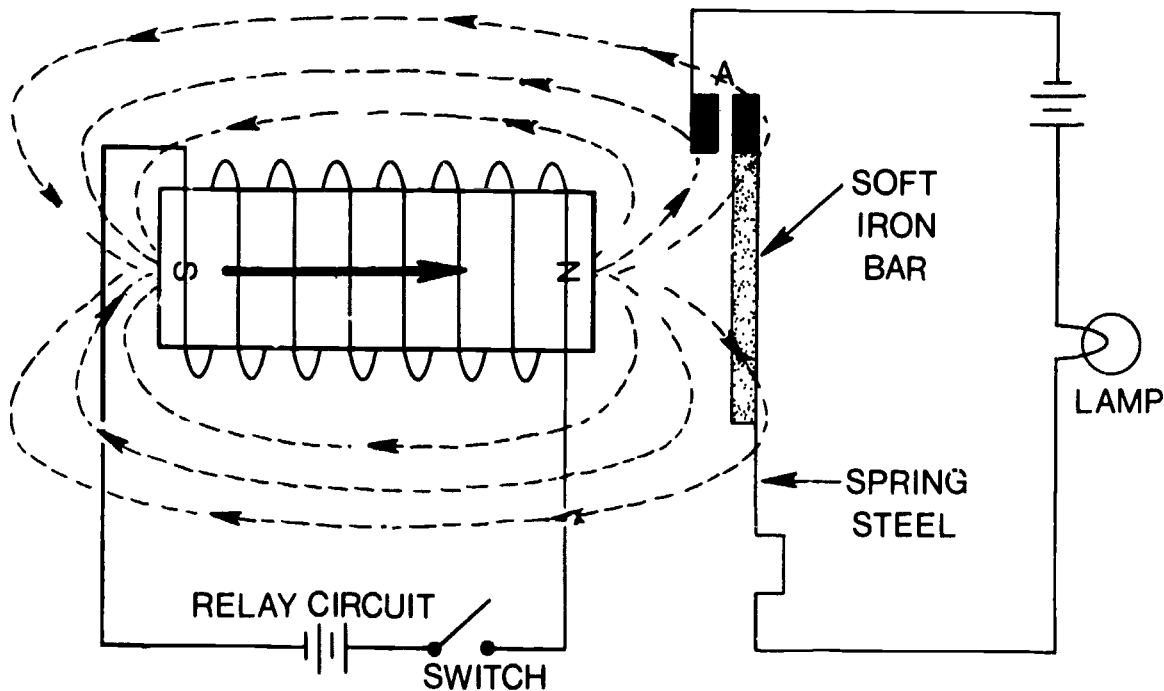


Figure 1-29. A simple relay-controlled circuit

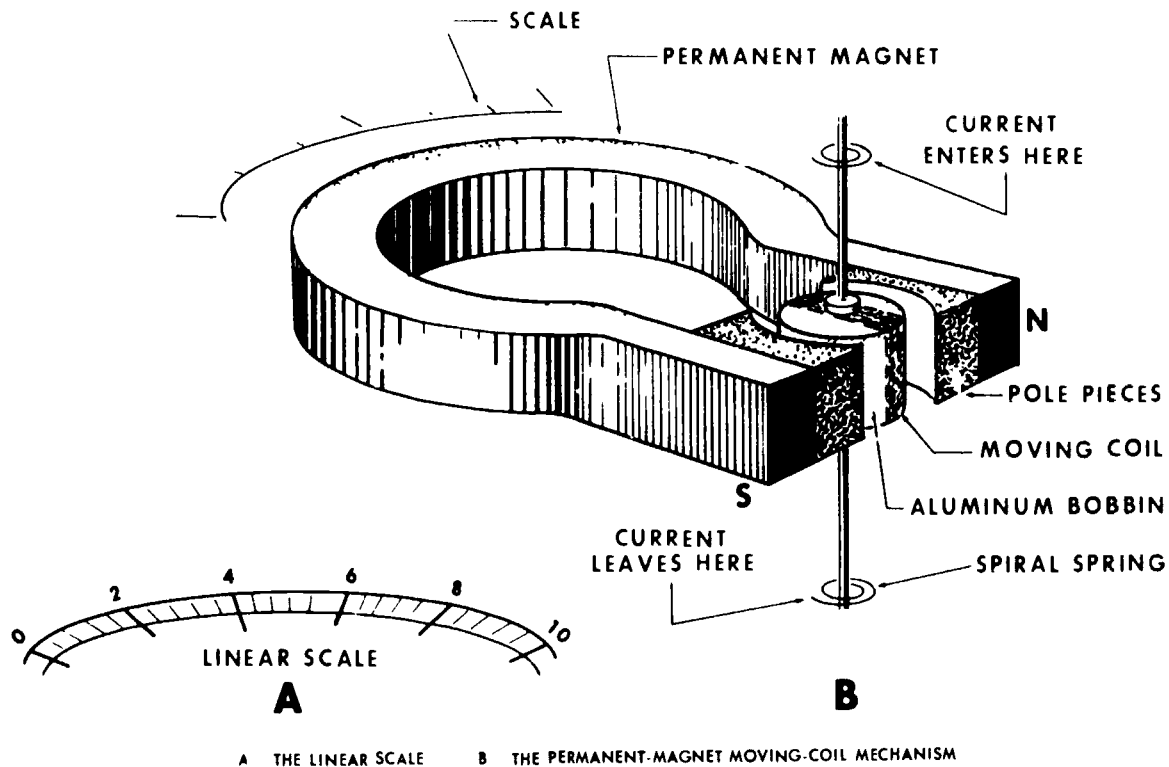


Figure 1-30. A d'Arsonval meter.

**Exercises (021):**

1. On what electrical current effect are most meter operations based?
2. What is the most common type of meter movement?
3. List the types of magnets in the d'Arsonval meter.
4. What causes the moving coil to rotate in a d'Arsonval meter?

**022. Compare electron movement in alternating current to electron movement in direct current.**

**Alternating Current Characteristics.** Up to this point in this chapter, our discussions of current flow have been related to direct current, where electrons continuously flow in one direction through a circuit. Electron movement in alternating current (ac), on the other hand, is bidirectional; that is, electrons move

first in one direction and then reverse themselves and move in the opposite direction. Keep in mind as you study ac that the electrons still move from negative to positive just as they do in DC, since polarity also constantly changes.

**Exercises (022):**

Match the type of current in column B with the description of electron movement in column A. Each column B item may be used once or more than once. Also, both column B items may match a single column A item.

<i>Column A</i>	<i>Column B</i>
_____ 1. Electrons move only from negative to positive.	a. Alternating current (ac).
_____ 2. Electron movement constantly changes directions.	b. Direct current (dc).
_____ 3. In a given circuit, electrons move through the wire conductor in the same direction.	

**023. Describe the major characteristics of 60-cycle alternating current.**

The characteristics of ac can best be understood by referring to a sine wave, as shown in figure 1-31. A sine wave shows the relative values of voltage and current



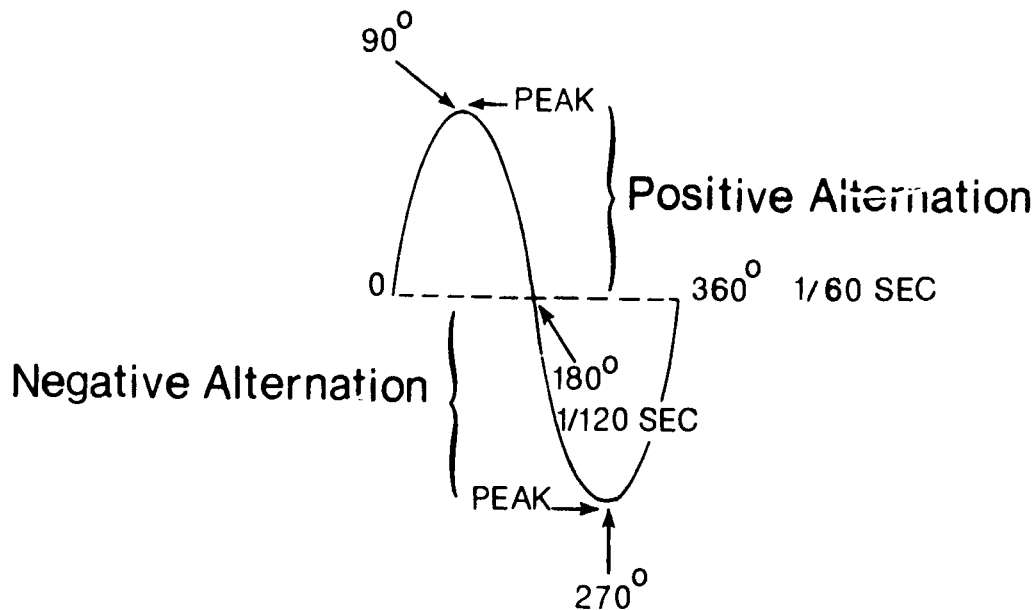


Figure 1-31 An ac sine wave

plotted against time through  $360^\circ$ . Beginning with the horizontal line representing zero or no current flow, ac gradually increases in magnitude (voltage and current values) until a peak is reached. The peak values represent the maximum amplitude of the sine wave and are the maximum voltage and current in the circuit. For example, in a 110-volt circuit drawing 5 amps, those values are reached at that particular point in time that is also at  $90^\circ$  on a  $360^\circ$  scale. Before these "peak" values are reached, the voltage and current values gradually increase, beginning with zero. Once the peak values are reached, ac gradually decreases in value until zero on the sine wave, or no current flow, is reached. This second zero value is reached at  $180^\circ$  on a  $360^\circ$  scale. From this point, ac again increases in magnitude, but below the zero reference line, until a peak or maximum amplitude is reached, and then once again decreases to zero, as shown in figure 1-31. This swing of the sine wave, however, represents a reverse in polarity (i.e., current flowing in the opposite direction from that above the zero reference line).

That portion of the sine wave above the zero reference line is known as the *positive alternation* or positive amplitude, and that portion below the reference line is known as the *negative alternation* or negative amplitude. These alternations are also referred to as impulses or *pulses*. Two consecutive alternations are known as a *cycle*. As stated before, the sine wave represents ac values plotted against time. In the case of 110-volt household current, there are 60 cycles per second. This means that 60 cycles or 120 alternations occur in 1 second. The number of cycles occurring in a second is referred to as the *ac frequency*. For our purposes in this CDC, we shall be concerned mostly with 60-cycle ac, although higher frequencies are used in other fields.

#### Exercises (023):

1. At what point in time during a cycle does the polarity of 60-cycle ac change?
2. During an ac cycle, is current continuously flowing in one direction or another? Explain.
3. How long does it take for 60-cycle ac to build from zero to the maximum current and voltage values?
4. How many alternations occur in one cycle?
5. How many pulses occur in one-half cycle?
6. What is ac frequency?

**024. Define "electromagnetic induction," and analyze the requirements for electromagnetic induction and their effect on the magnitude of induced electromotive force (EMF).**

**Electromagnetic Induction.** If a conductor is moved through a magnetic field and cuts the lines of force or

flux, as illustrated in figure 1-32,A, an electromotive force (EMF) is induced in the conductor. Similarly, if the conductor is stationary and the magnet moves, as illustrated in figure 1-32,B, an EMF is also induced in the conductor. This process of producing an EMF from the relative motion between a conductor and magnetic field is called *electromagnetic induction*. Accordingly, there are three requirements for electromagnetic induction: (1) a conductor, (2) a magnetic field, and (3) relative motion.

The magnitude of the induced EMF depends upon the number of lines of force cut per unit time; the greater this number, the higher the induced EMF. Two ways of increasing the induced EMF are: (1) to increase the relative motion or speed at which the lines of force are cut and (2) to increase the strength of the magnetic field. The magnitude of the induced EMF also depends upon the number of conductors in which the EMF is induced; the more conductors—or as we shall see when we discuss transformers, the more turns in a coil—the higher the induced EMF.

#### Exercises (024):

1. Define "electromagnetic induction."
2. What are the three requirements for electromagnetic induction?
3. Explain the relationship between the magnitude of the induced EMF and the relative motion and strength of the magnetic field.

4. Explain the relationship between the magnitude of induced EMF and the number of conductors in which the EMF is induced.

025. Indicate whether statements pertaining to self-induction and mutual induction are correct.

*Self-induction.* Now that we have reviewed some basic information about electromagnetic induction, let's see how we can induce an EMF or current in a conductor without moving the conductor or the magnet. Refer to figure 1-33. Detail A shows a conductor formed into a coil, and detail B shows an ac sine wave. When the current in the coil corresponds to zero in detail B, there is actually no current present in the coil. From zero to 1, the current is increasing in the direction indicated by the arrows on the coil. You will recall that when there is current in a conductor, there is a magnetic field around the conductor. We have shown the field at only two points in the coil, although it is actually present all along the conductor. We now have two of the three requirements for induction: (1) a conductor and (2) a magnetic field.

Now let's see where the relative motion comes from. As the current increases during the interval from zero to 1, the magnetic field increases in strength and expands to a point where it cuts the conductor in other loops, as shown in detail C of the figure. As the ac decreases from maximum to zero during the interval of 1 to 2 in detail B, the magnetic field decreases in strength. As the field decreases, it cuts the loops in

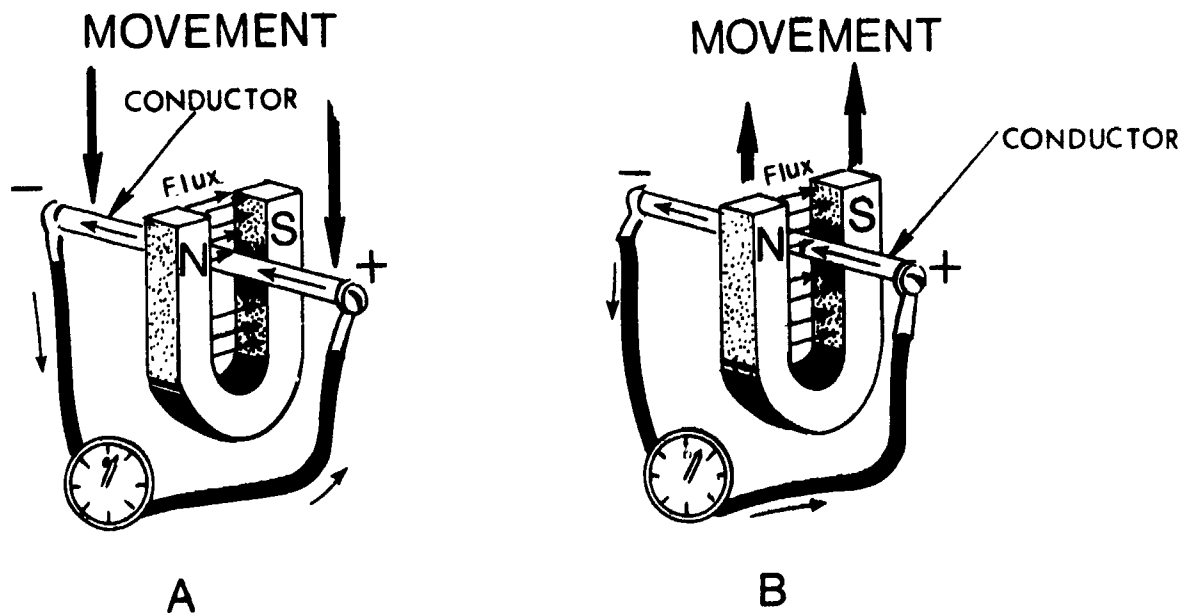


Figure 1-32. Electromagnetic induction

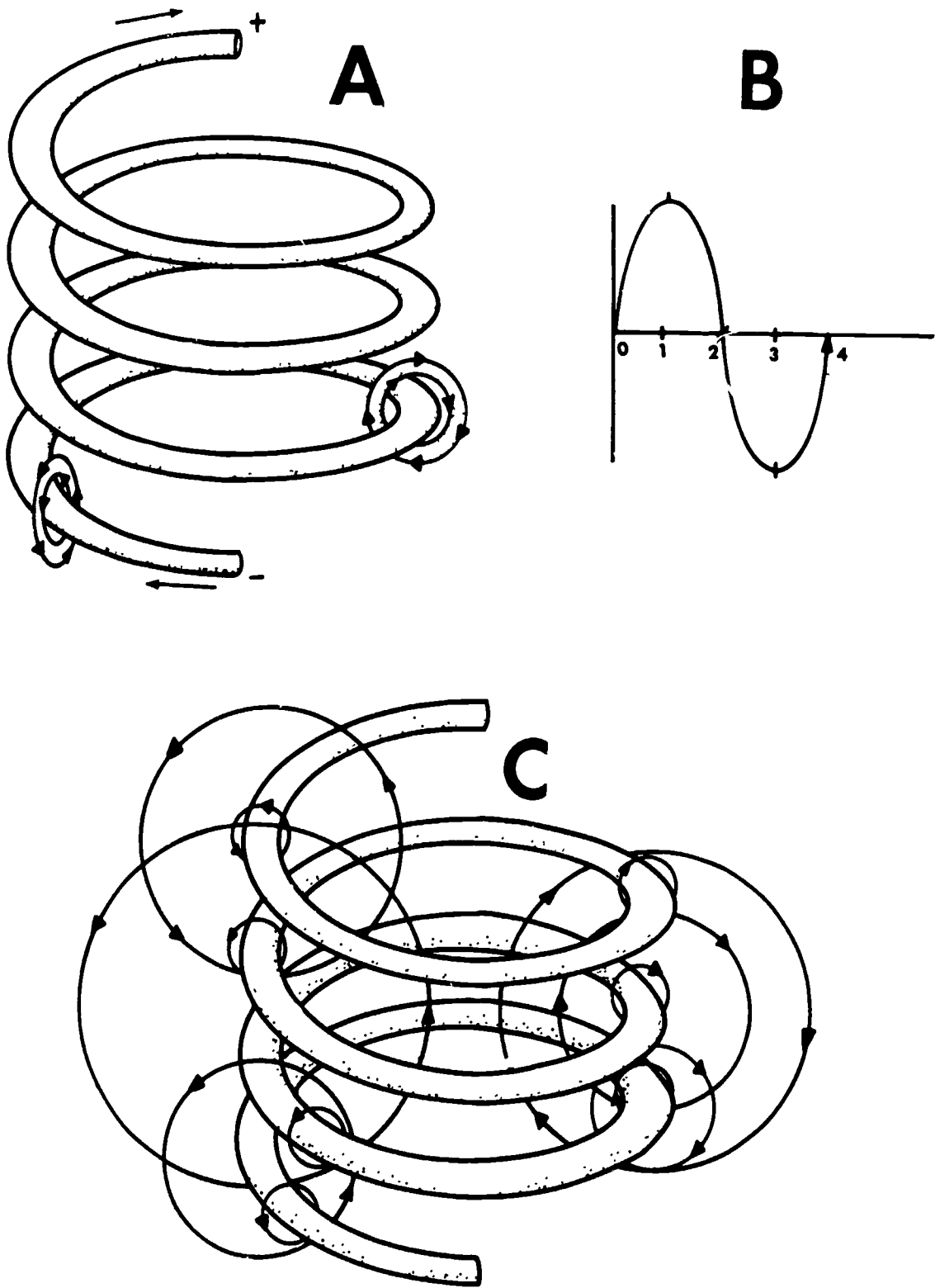


Figure 1-33 Self-induction

the opposite direction. This expansion and collapse of the magnetic field, which is a result of the increasing and decreasing ac values, in part provides the relative motion necessary to induce EMF or current into the other loops of the conductor. The change in direction of ac current flow also changes the directions of the magnetic field, providing additional relative motion. When the magnetic field of a coil induces current into the coil itself, the process is known as *self-induction*.

**Mutual induction.** Mutual induction is the process of introducing current or voltage in a circuit by varying the current or voltage in a neighboring circuit. Figure 1-34 shows an ac generator furnishing power to coil a. Coil a is not electrically connected to coil b. As the expanding and collapsing magnetic field around coil a cuts the loops of coil b, current and voltage are introduced into coil b. Again notice the three requirements for induction, with the relative motion resulting from the expanding and collapsing magnetic field.

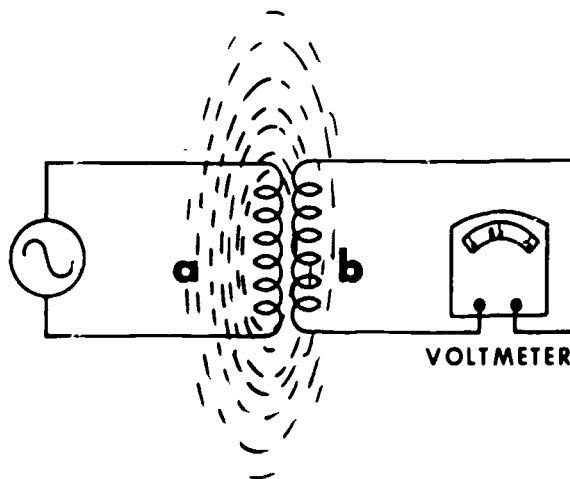


Figure 1-34. Mutual induction.

**Exercises (025):**

Indicate whether the following statements are true or false. If you indicate false, explain your answer.

- T F 1. During self-induction, relative motion results in part from increasing and decreasing ac values.
- T F 2. Only self-induction makes use of an expanding and collapsing magnetic field.
- T F 3. Mutual induction occurs only if one coil is located within the magnetic field of another coil.

**026.** Define "transformer action"; and given data pertaining to two transformers (turns ratio, input voltage, and input current), determine the output values of each transformer.

**Transformers.** In describing transformers, we are actually continuing our discussion of electromagnetic induction. A transformer is an electrical device that operates on the principle of electromagnetic induction. "Transformer action" is the process of transferring electrical energy from one circuit to another by electromagnetic induction.

**Step-up and step-down transformers.** A transformer that increases the voltage is called a *step-up transformer*; whereas, one that decreases the voltage is called a *step-down transformer*. The factor that determines whether a transformer steps up or steps down the voltage is the turns ratio. "Turns ratio" is

defined as the ratio of the number of turns in the primary winding (first coil) to the number of turns in the secondary winding (secondary coil). For example, the turns ratio of the transformer shown in figure 1-35, detail A, is 5 to 1, and that of the transformer in figure 1-35, detail B, is 1 to 4.

Now let's consider transformer actions. What effect does the turns ratio have on the transformer output? The ratio of the transformer input to the output is the same as the turns ratio, provided the transformer is 100 percent efficient. (NOTE: Transformers are not 100 percent efficient, but for ease of calculation we shall consider them to be so.) In other words, an input of 10 volts applied to the primary of the transformer in detail A will induce 2 volts in the secondary. This is an example of a step-down transformer. On the other hand, an input of 10 volts applied to the primary of the transformer shown in detail B will result in an output of 40 volts from the secondary. Thus, detail B is an example of a step-up transformer. No matter what voltage we apply to the primary of the transformer in detail A, the output is one-fifth of the input (assuming we stay within the voltage limits of the transformer). With the transformer shown in detail B, the output is four times the input.

We have explained how the turns ratio determines the step-up or step-down ratio of a transformer. Now let's see what happens to the current. Basically, a transformer that increases the voltage by a given ratio decreases the current by the same ratio. In other words, if we apply 10 volts at 10 amps to the primary of a 1-to-10 step-up transformer, as shown in figure 1-36, detail A, the voltage in the secondary will be 100 volts and the current will be 1 amp. If the transformer is a step-down transformer, as shown in figure 1-36, detail B, the current in the secondary will be increased by the same ratio that the voltage is decreased. Thus, to determine the effect that a transformer has on voltage or on amperage, simply use the following formulas:

$$\begin{aligned} \text{Voltage: } & T_1 : T_2 :: V_1 : V_2 \\ \text{Amperage: } & T_1 : T_2 :: I_2 : I_1 \end{aligned}$$

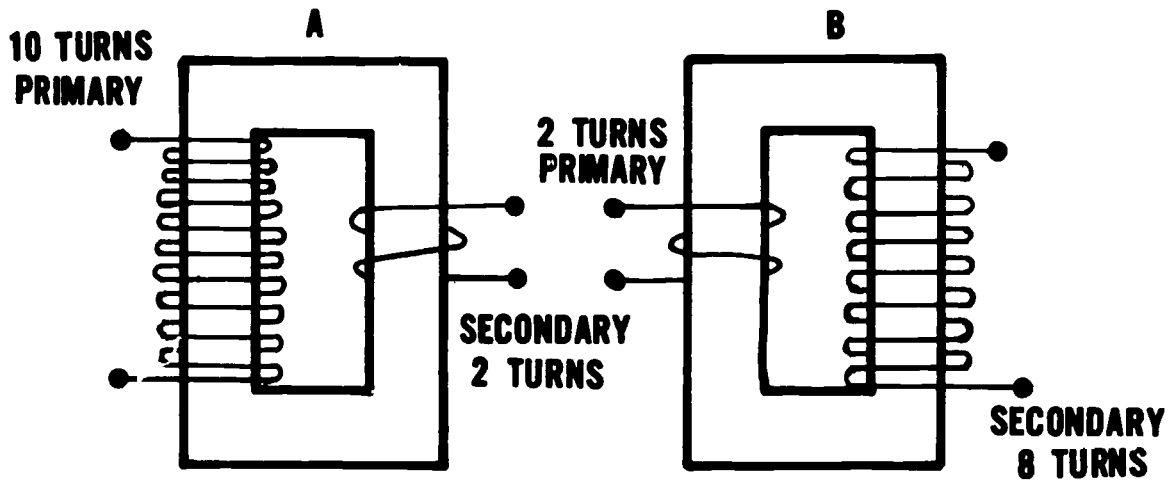


Figure 1-35 Transformer turns ratios

**Exercises (026):**

1. Define "transformer action."
2. What is the output voltage and amperage from a transformer using the following information: input voltage—110 volts; input amperage—5 amps; transformer ratio—10 to 1?
3. What is the output voltage and amperage from a transformer using the following information: input voltage—220 volts; input amperage—3 amps; transformer ratio—1 to 3?

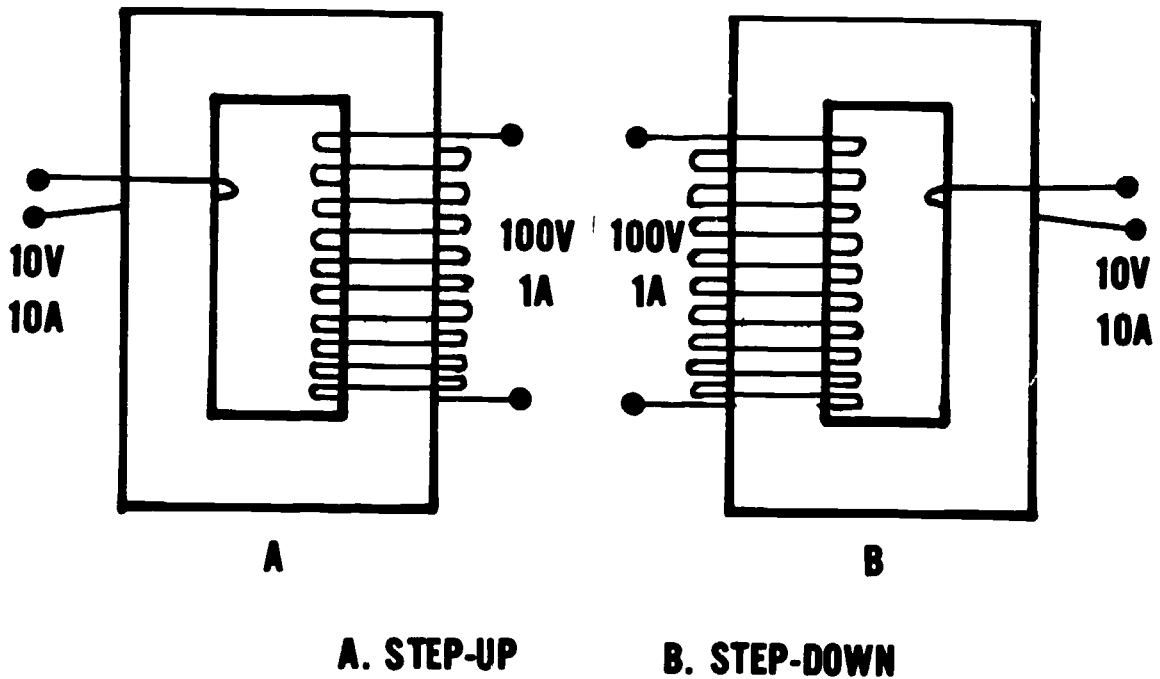


Figure 1-36 Transformer turns ratios

**027. State the purpose and basic operation of an auto-transformer, and explain "redlining."**

**Autotransformers.** As a radiologic technologist, you are concerned with three types of transformers. By now you are familiar with the step-up and step-down transformers. The third type, and probably the most important one to you, is the autotransformer. The autotransformer controls the voltage that enters the primary coil of the high-tension transformer in the X-ray machine. It is generally the kilovolt peak (kVp) selector of the unit. Consider for a moment a transformer consisting of one continuous winding on a long, laminated iron core. When voltage is applied across only one section of it, voltage will be induced in the turns that are not connected directly to the line in the same way that voltage is induced in the secondary coil of a conventional transformer. In fact, the section across which the line voltage is applied is called the primary, and the balance of the winding is called the secondary.

If the voltage is measured across various sections of a typical autotransformer, a situation like that in figure 1-37 may be present. A series of taps or connections to the different turns provides a convenient method of getting a wide variety of voltages to apply to the primary of the high-tension transformer. In the circuit shown in figure 1-37 (this circuit has a constant number of volts per turn), the following voltages could be acquired by setting the selector switch on the various taps:

- Tap #1—50 volts
- Tap #2—100 volts
- Tap #3—150 volts
- Tap #4—200 volts

The same results can be obtained by connecting the line to a number of selected taps and leaving the output connected to a given pair of taps, as in figure

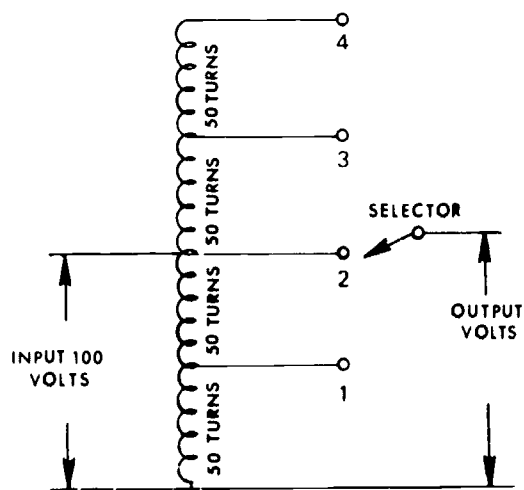


Figure 1-37 Auto transformer circuit-constant volts per turn.

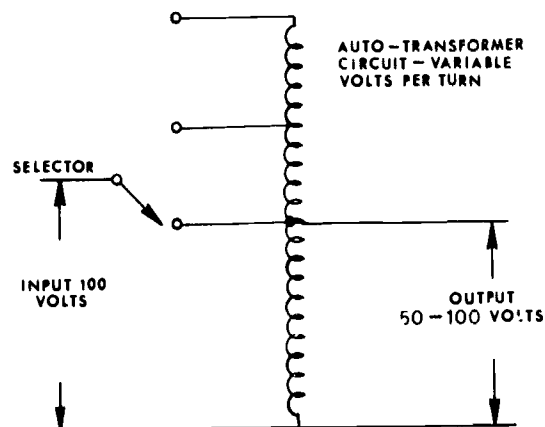


Figure 1-38. Autotransformer circuit—variable volts per turn.

1-38. In actuality, autotransformers are usually provided with many taps in the primary as well as the secondary circuit, with the result that you have an almost unlimited choice of voltage outputs. The autotransformer becomes in this way the basic regulatory source of all the supply voltages needed for operating the many components of the X-ray generator.

Look at figure 1-39; notice that one side of the supply line is connected through a line voltage compensator. Incoming line voltage is not stable, varying from day to day, hour to hour. This instability is caused by other consumers using equipment connected to the same power supply as the X-ray machine.

The voltage compensator does not step up or step down the incoming voltage. It simply shares the available incoming voltage with more or less turns on the autotransformer. For example, normal supply is 230 volts; however, the incoming line voltage is 220 volts. An autotransformer adjusted to step down 230 volts would step the 220 volts down too far, resulting in less kilovoltage than selected. Consequently, the result is an underexposed radiograph. To compensate for this, you adjust the voltage compensator. The voltage compensator increases or decreases the number of turns used in the primary of the autotransformer. Thus, the same volts per turn ratio is maintained and the output remains stable. This process has been called "redlining" a machine.

This compensated voltage is picked off by the major and minor kVp selectors (which you adjust on the X-ray machine control panel) and supplied to the primary of the high-tension transformer. In figure 1-39, the selector marked "MAJOR" is connected to a series of taps, between which there are relatively large differences in voltage. The selector marked "MINOR" gives you small voltage changes. Usually there are 10 steps on the minor selector that give you the same change in voltage as going from one step to the next on the major selector. With a combination of 10 major and 10 minor steps, you can get 100 different output voltages.

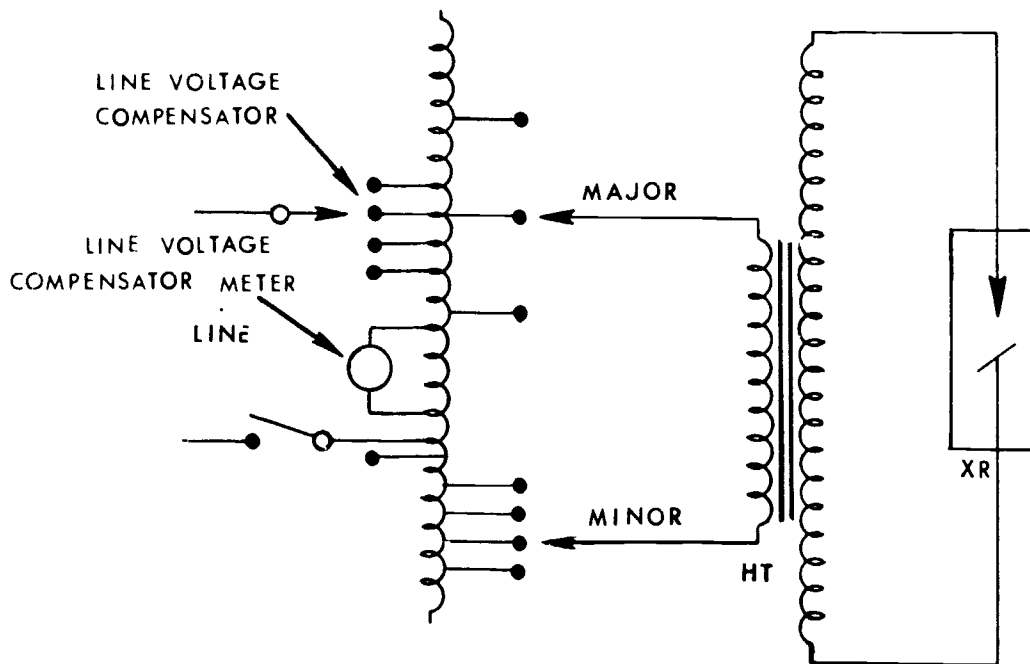


Figure 1-39 Autotransformer circuit—dual selectors

**Exercises (027):**

1. Why is an autotransformer used in an X-ray machine?
2. What is meant by “redlining” a machine?
3. If an X-ray machine is not redlined, how and why is the film exposure affected?
4. What parts of the autotransformer should be adjusted to control the voltage supplied to the high-tension transformer, and on which side of the autotransformer are they located?

**028. Given a list of waveforms across various X-ray tubes, match each with related factors, such as ac power, type of rectification, X-ray production, and use of negative alternations.**

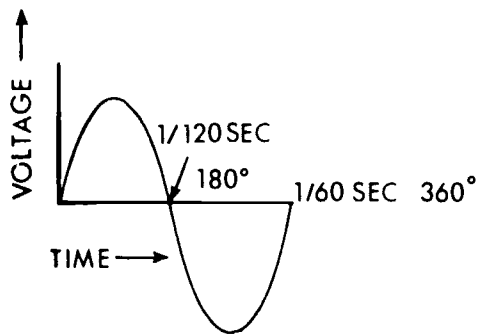
**Rectification.** Rectification is the process of converting ac power to pulsating dc. This conversion is necessary in the X-ray machine because X-ray tubes

are designed to operate on pulsating dc. Our discussion of rectification is based on the resulting waveforms across the X-ray tube. We shall consider the waveforms from two aspects—single-phase and three-phase X-ray generators.

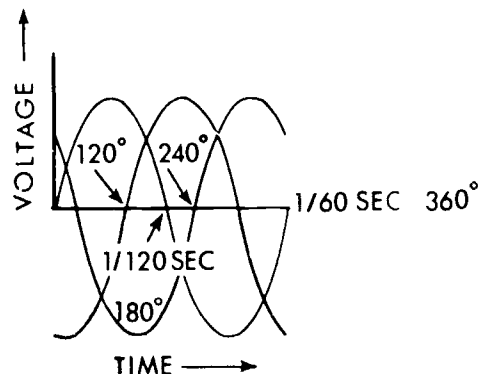
First, let's briefly review single-phase and three-phase ac. You will recall our discussion of the ac sine wave when we discussed the wave representing the ac voltage and current values. The sine wave of 60-cycle ac consists of a single wave that occurs during 1/60 second or one cycle. That type of ac is called single-phase ac, and an X-ray machine operating from single-phase ac is called a single-phase generator. Three-phase ac, on the other hand, consists of three sine waves per cycle separated by 120°, as shown in figure 1-40, which also shows a comparison with single-phase ac. An X-ray machine designed to operate on three-phase ac is called a three-phase generator.

You will also recall that the sine waves below the zero reference line (negative alternations) represent current flowing in the opposite direction from those above the line. Rectification consists of rerouting these negative alternations so that they travel in the same direction as the positive alternations (or in the case of older, small-capacity, single-phase generators, the negative alternation is eliminated altogether).

*Single-phase waveforms.* As previously mentioned, rectification in some of the older X-ray machines, mostly portable units operating on single-phase ac, consists of eliminating the negative alternation. These are either self-rectified or half-wave rectified units. The resulting waveform across the X-ray tube, referred to as one-pulse, is shown in figure 1-41. You can see from the figure that voltage is only applied across



### SINGLE - PHASE AC



### THREE - PHASE AC

Figure 1-40 Single-phase and three phase ac

the X-ray tube for half of a given time period. For example, during a period of 1/60 second, voltage occurs for 1/120 second. During the other 1/120 second, there is no voltage and no X-ray production.

A two-pulse waveform, also shown in figure 1-41, is produced in a single-phase generator, using full-wave bridge rectification. Many old, as well as new, X-ray

machines use full-wave rectification. With this type of rectification, the negative alternation is rerouted in the same direction as the positive alternation, producing two pulses per cycle across the X-ray tube. In comparison with a one-pulse waveform, the two-pulse produces twice as much radiation in a given time period if all other factors are equal.

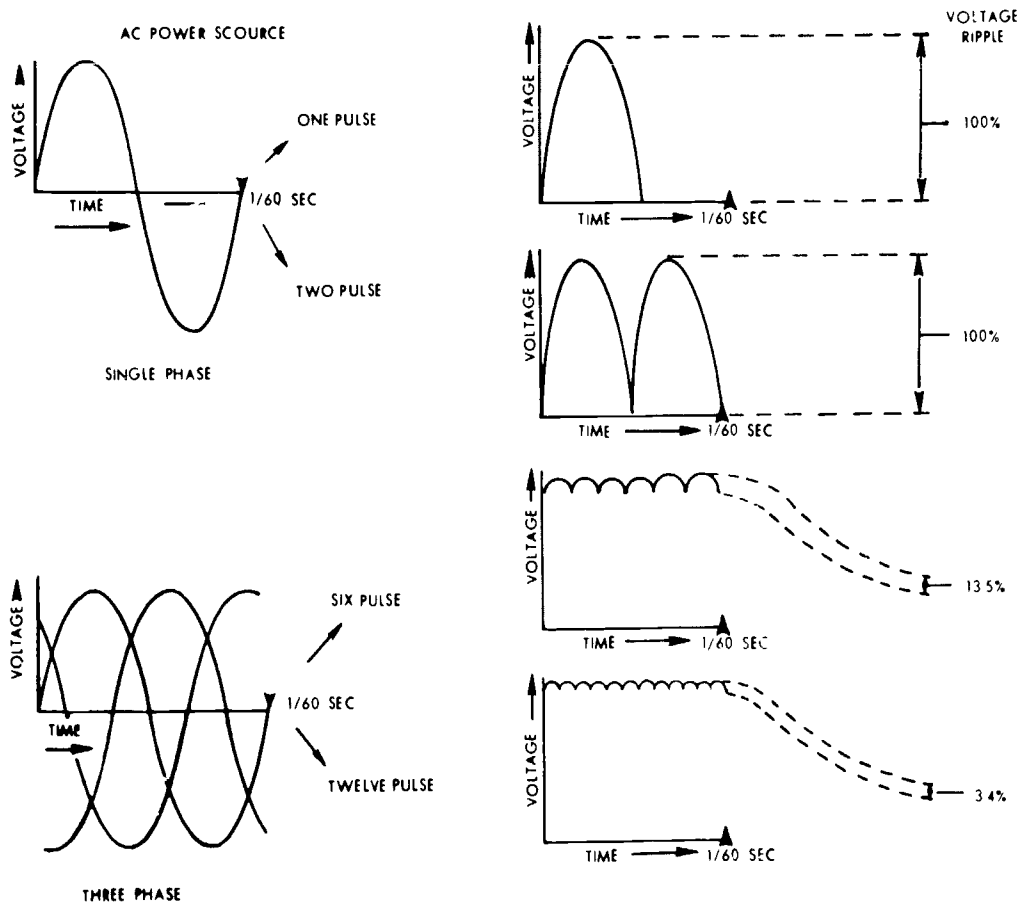


Figure 1-41. Comparison of waveforms produced by different types of rectification.



**Three-phase waveforms.** A three-phase X-ray generator produces either six pulses or 12 pulses per cycle across the X-ray tube, depending upon the type of transformer. Both of these are illustrated in figure 1-41. If a three-phase generator produces a six-pulse waveform, the negative alternations are redirected in the same direction as the positive alternations. In the case of a six-pulse waveform, the negative alternations are redirected, and in case of 12-pulses, the six-pulses are doubled by means of a special transformer that produces a phase shift in the secondary winding. This latter action results in an additional six pulses of current when rectified—three more positive and three more negative pulses across the X-ray tube, all in the same direction.

**Exercises (028):**

Match the waveforms in column B with the appropriate responses in column A. Each column B item may be used once or more than once. In addition, two or more column B items may match a single column A entry.

- |   |  |
|---|--|
| <p><i>Column A</i></p> <ul style="list-style-type: none"> <li>_____ 1. Single-phase ac.</li> <li>_____ 2. Self-rectification.</li> <li>_____ 3. Three-phase ac.</li> <li>_____ 4. Produces X-rays only half of a given time period.</li> <li>_____ 5. Three negative alternations per cycle are directed across the X-ray tube.</li> <li>_____ 6. X-ray production is twice that of one-pulse for a given time period.</li> <li>_____ 7. Negative alternation is eliminated.</li> <li>_____ 8. Six negative alternations per cycle are directed across the X-ray tube.</li> </ul> | <p><i>Column B</i></p> <ul style="list-style-type: none"> <li>a. One-pulse.</li> <li>b. Two-pulse.</li> <li>c. Six-pulse.</li> <li>d. 12-pulse.</li> </ul> |
|---|--|

**029. Relate average electron energies to X-ray tube waveforms.**

*Effect of waveform on average electron energy.* Look again at figure 1-41 and notice the *voltage ripple* for the four voltage patterns. As you can see, it is 100 percent for one- and two-pulse, 13.5 percent for six-pulse, and only 3.4 percent for 12-pulse. Voltage ripple, as you have probably already determined from the figure, is the difference between the peak voltage and the minimum voltage of each pulse. To put this idea in perspective, refer to figure 1-42, which shows a wave pattern produced in a single-phase, two-pulse generator and another produced in a three-phase, 12-pulse generator. With the two-pulse wave, the voltage rises to a peak and then falls to zero (100 percent ripple). This rise and fall of the voltage causes the speed of the electrons across the X-ray tube, an important factor in X-ray production, to vary accordingly. Consequently, if 100 kVp is applied to the X-ray tube, the kinetic energy of the electrons theoretically ranges from zero when the voltage is at zero to

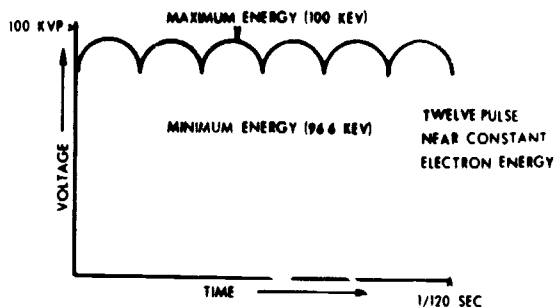
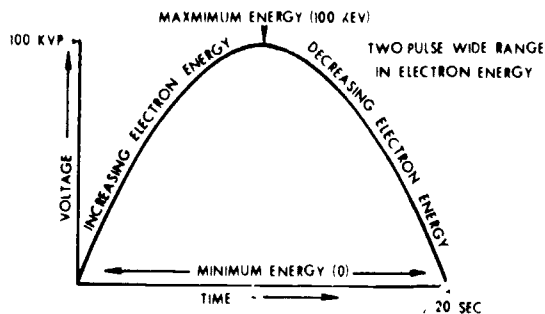


Figure 1-42. Comparison between electron energies of two-pulse and 12-pulse waveforms.

100 keV when the voltage value is at its peak. As you know, keV stands for kiloelectron volts and is a unit of energy. The 12-pulse wave from a three-phase generator does not drop to zero. As stated earlier, it drops only 3.4 percent below peak value. As a result, the kinetic energy of the electrons drops only 3.4 percent below the peak kV value. In other words, the kinetic energy of the electrons (at 100 kVp) in a 12-pulse system theoretically ranges from 96.6 keV to 100 keV. This means that the average kinetic energy imparted to the electrons is much higher in the 12-pulse system than in the two-pulse system. Following this same line of reasoning, you can see that the average electron energies of one-pulse and six-pulse waveforms also vary according to the voltage ripple.

**Exercises (029):**

1. Explain voltage ripple.
2. What important factor in the production of X-rays does voltage ripple affect?
3. What type of generator produces the highest average electron energies?

4. Compare the average electron kinetic energies of six-pulse and 12-pulse waveforms.
5. Compare the average electron kinetic energies of one-pulse and six-pulse waveforms.

**030. Relate electron energy to photon energy, and compare the average photon energies and the beam-penetrating power of single- and three-phase generators.**

*Effect of average electron energy on photon energy.* We can determine the significance of the higher average kinetic energy of the electrons by examining the effect of electron energy on photon energy. When low-speed (low-energy) electrons strike the target in an X-ray tube, their energies are converted either into heat or into low-energy photons. Consequently, since a single-phase generator produces comparatively more low-energy electrons, it also produces a greater proportion of low-energy photons than does a three-phase generator. The greater proportion means that the average photon energy is less in a single-phase generator. Low-energy photons from the target of an X-ray tube are absorbed either by filtration or by the patient. In either case, they usually serve no useful purpose in diagnostic radiology since they do not reach the film and contribute to the exposure.

The penetrating power or quality of a beam of X-rays is governed by average photon energy; in a three-phase beam the average photon energy is greater than in single-phase, assuming that both systems are operated at equal peak kilovoltages. Notice that the qualitative difference in the two beams is in *average* photon energy. Both systems do, in fact, produce low-energy photons. The difference is in the proportion.

**Exercises (030):**

1. What is the relationship between electron energy and photon energy?
2. How do the average photon energies of single-phase and three-phase X-ray beams compare?
3. What type of X-ray generator produces a more penetrating beam of X-rays (assuming both are operated at equal peak kilovoltages)?

**031. Compare the beam intensities of a single-phase and a three-phase generator, and explain the reason for the difference.**

*Comparison of beam intensities between single-phase and three-phase generators.* The intensity of an X-ray beam is greater with a three-phase generator than with a single-phase system for a given tube current. Therefore, the 12-pulse system produces a given amount of radiation in a much shorter period of time than does the two-pulse system. Figure 1-43 shows two-pulse and 12-pulse waveforms. Notice that image-forming radiation is produced only at certain times with two-pulse. At other times, either no radiation at all is produced (when the sine wave is at zero value) or radiation is produced that has insufficient energy to reach the film. The 12-pulse wave continuously produces image-forming radiation because of its near constant voltage level.

**Exercises (031):**

1. How does the intensity of an X-ray beam from a single-phase generator compare to that of a three-phase generator if both are operated at equal tube current?
2. Why is there a difference between the beam intensities as described in exercise 1 above?

**032. Convert the kVp used on a three-phase unit for use on a single-phase unit, and explain why the conversion is made with the kVp.**

*Technique conversion factor between single- and three-phase generators.* The average energy level of the beam of radiation produced by a three-phase unit is higher than that produced by a single-phase unit when both are adjusted for the same peak kV. Therefore, to produce radiographs with the same general scale of contrast, it is necessary to use higher kVp with the single-phase unit. For a given mA station, it requires approximately twice as much exposure time for a single-phase unit as for a three-phase (12-pulse) unit. Therefore, it is more logical to make the technique compensation with kVp rather than with mAs. Increasing the (single-phase) kVp by 15 percent increases the average energy of the beam to a point where the single-phase unit produces radiographs of approximately the same scale of contrast (and density) as those produced by the three-phase unit, using the same mA and time (mAs) factors. In addition, the increase in kVp tends to keep the absorbed dose of the patient to a minimum.

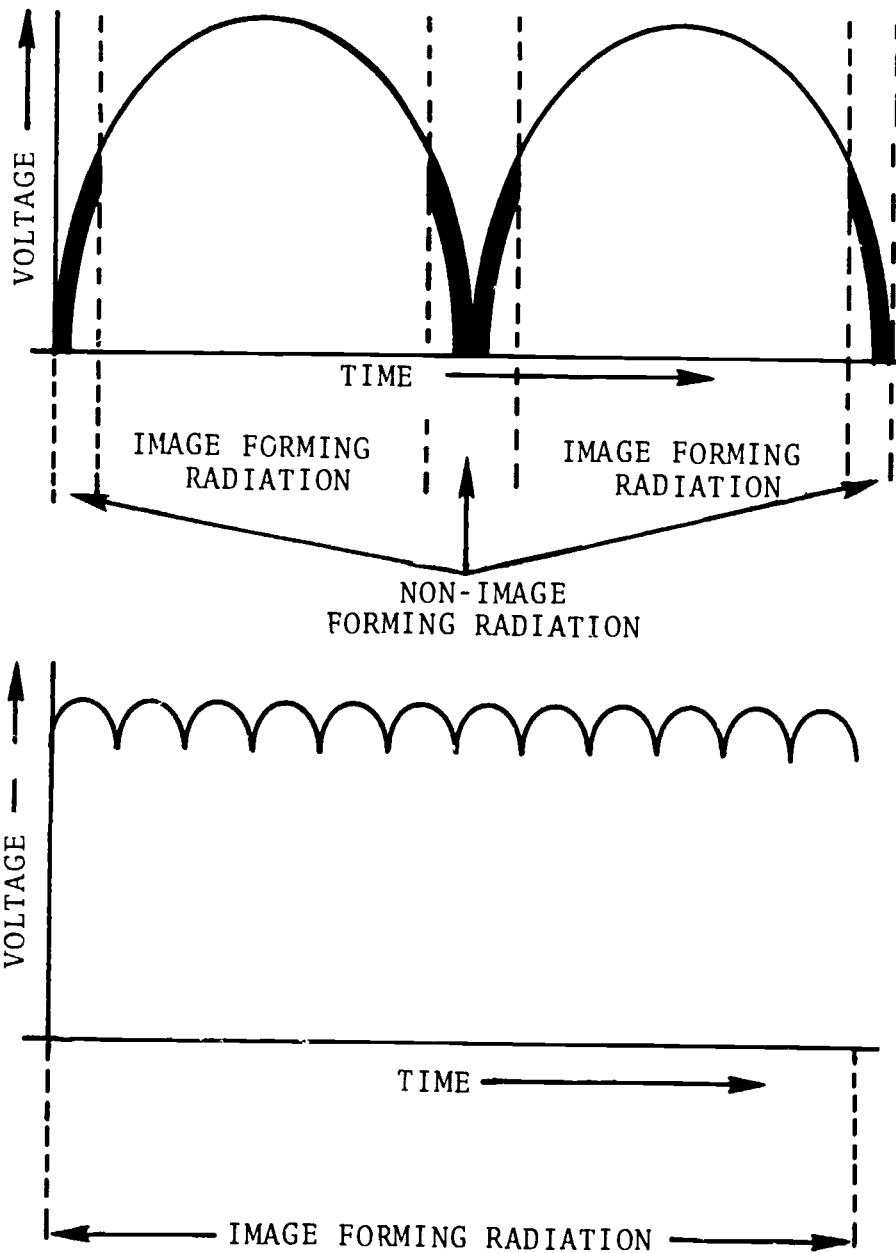


Figure 1-43. Comparison of time periods of single-phase and three-phase when image-forming radiation is produced.

**Exercises (032):**

1. If 92 kVp is used for an exposure on a three-phase unit, what kVp should be used for the same exposure on a single-phase unit (assuming all other factors are equal)?
2. Why is the exposure conversion in exercise 1 above made with the kVp rather than with some other exposure factor?

**033. Compare the X-ray tube capacity for a single-phase and a three-phase generator.**

*Comparison of X-ray tube capacities between single- and three-phase generators. X-ray tube capacity is greater in a three-phase system for short exposures. One reason for the increased tube capacity is that the heat is spread over a larger area on the target. Figure 1-44 shows two rotating targets. Assume that each is subjected to an exposure of 1/60 second. Target A is exposed by a single-phase, two-pulse system, while target B is exposed by a three-phase,*

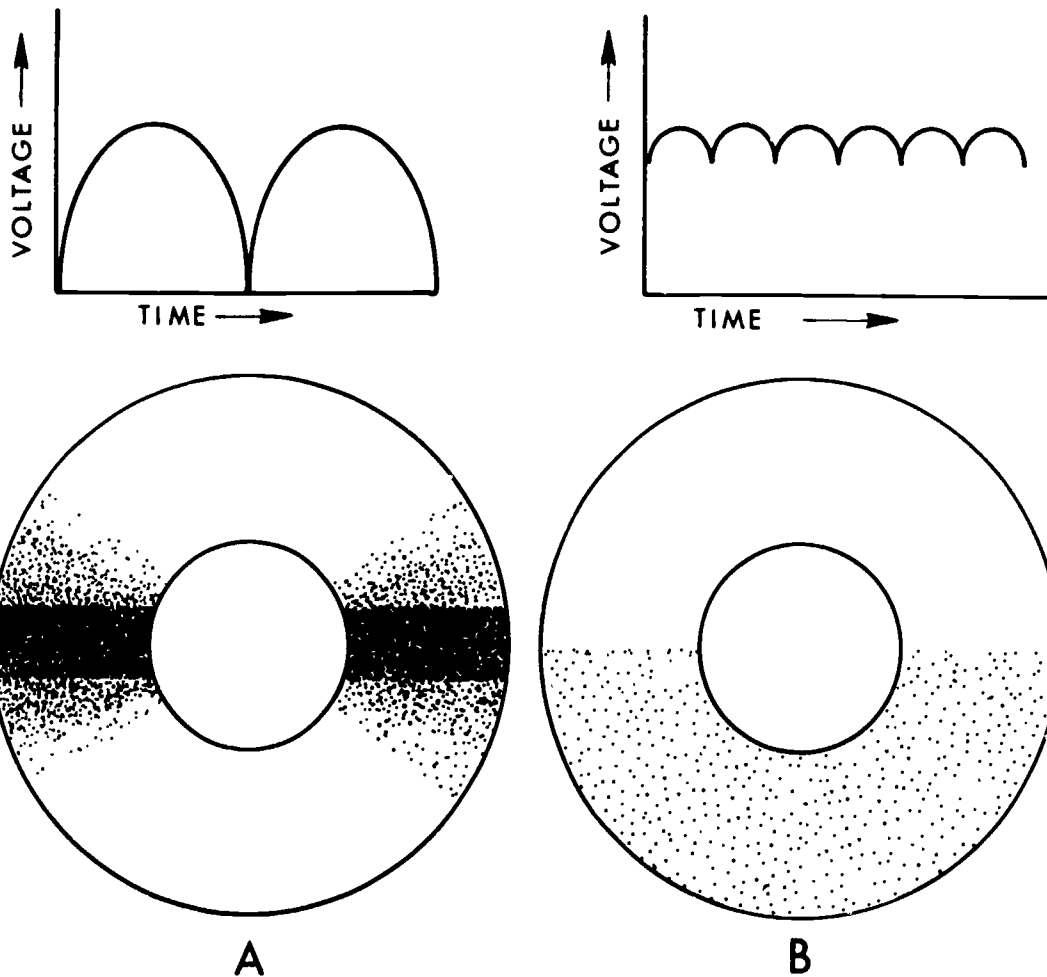


Figure 1-44. Comparison of point heat buildup between single- and three-phase generators

12-pulse system. Target A shows two "hot spots" which correspond to the peak of the two pulses produced at  $1/60$  second. The point heat buildup at these hot spots determines the maximum capacity of the tube on a short exposure. Target B, on the other hand, shows no hot spots due to point heat buildup. The absence of the hot spots results in a more even thermal load. In this manner, the anode disk is fully exploited for X-ray production. The increased thermal capacity for X-ray tubes operated on three-phase is increased only for exposures less than one-half second. From one-half to 1 second, the ratings are approximately the same as for single-phase. Above 1 second, the ratings are usually higher for X-ray tubes operated on single-phase.

**Exercises (033):**

1. For exposures less than one-half second, an X-ray tube operated with what type of generator will have greater capacity? Why?

2. How do single- and three-phase tube capacities compare for exposures of one-half to 1 second?
3. How do single- and three-phase tube capacities compare for exposures greater than 1 second?

**1-3. X-Ray Tubes**

X-ray tubes have undergone considerable change in the past few years. Some of the changes include smaller focal spots, higher capacity, and shorter exposure times. In this section, we shall discuss these and other aspects of X-ray tubes, as well as tube-rating charts. We shall also provide a brief review of the parts of an X-ray tube.

034. Indicate the influence of the X-ray tube cathode on overall tube operation.

**Tube Considerations.** Our discussion of the X-ray tube itself begins with the cathode. With newer X-ray tubes, the cathode is becoming more and more important in overall tube operation.

*The cathode.* The cathode consists of the filament enclosed in a molybdenum or nickel alloy focusing cup. The purpose of the focusing cup is to "aim" the electrons at a specific area on the anode. The filament, when heated to incandescence, is the source of free electrons that interact with the tube target to produce X-radiation. As the filament becomes heated, freed electrons form a cloud around the filament (this is known as thermionic emission). The length of the filament, along with the size and shape of the focusing cup, influences the size of the focal spot. Most X-ray tubes have two filaments and two focal spots. One filament and focal spot is larger than the other. This arrangement increases the capabilities of the X-ray tube. The small focal spot is designed to give maximum detail, but its operating time is limited because of the great amount of heat generated in the small area of the target when high techniques are used. Therefore, to spread the heat over a larger area, a large filament and focal spot are included. Thus you can increase the techniques within certain limits yet not damage the target through overheating. When the large focal spot is used, the heat spreads over a larger surface area of the target and is dissipated at a faster rate than when the small focal spot is used.

An X-ray tube filament is made of tungsten, and the life of the filament is determined in part by the length of time it is maintained in a "boost" condition. By boost time, we mean the short period of time before exposure when the filament is heated to the required emission temperature. The boost condition begins when you depress the STANDBY or ROTOR button of your exposure switch. The condition also automatically begins when you depress the EXPOSURE button. The tendency of tungsten to vaporize at high temperatures, with the resultant deposit of the vaporized tungsten on the glass wall of the tube, causes erratic tube operation and eventual permanent damage. For this reason, you should not use the STANDBY button unless absolutely necessary and then only for a short time.

#### Exercises (034):

1. What is the purpose of the focusing cup in an X-ray tube?
2. From what part of the cathode are the free electrons emitted?
3. What filament characteristic affects the size of the focal spot?
4. If your exposure for a particular radiograph is relatively high, which tube filament should you probably be using?
5. Explain what the "boost" condition is.
6. What precaution should you take to prevent vaporization of the filament?

**035. Indicate characteristics of the X-ray tube anode and state factors that affect focal spot size, film coverage, and detail.**

*The anode.* The X-ray tube anode contains the target in which the electrons interact with the target material to produce X-radiation. The anode is positively charged with respect to the cathode and thereby provides the difference in potential necessary to set the free electrons in rapid motion. The target itself is usually made of tungsten, although some of the newer targets are constructed of a rhenium-tungsten alloy that makes them more resistant to surface etching at high temperatures. Tungsten is used because of its high melting point and high atomic number.

The *actual focal spot* is that area of the target bombarded by the electrons (see fig. 1-45). Its size significantly affects the heat-loading capacity—the larger it is, the greater the heat-loading capacity. Its size is determined in part by a combination of three factors: (1) the size and shape of the filament, (2) the size and shape of the focusing cup, and (3) the angle of the target surface. The *effective focal spot* is the focal spot as it appears from directly beneath the tube at right angles to the electron stream (see fig. 1-45). Its size is very important because it significantly affects the detail on a radiograph. (Focal spot size and detail will be discussed in Chapter 2.) The size of the effective focal spot is determined in part by the size of the actual focal spot and the angle of the target surface.

As you can see from the previous paragraph, for maximum effectiveness, we need an X-ray tube with an actual focal spot large enough to permit the necessary heat loading and an effective focal spot small enough to produce optimum detail. These criteria are fulfilled in part by the application of the *line focus principle*. For the purpose of line focus, the X-ray tube is designed so that the electrons bombard a rectangular area on the target surface. A specific target angle then produces an effective focal spot that is approximately square and much smaller than the actual focal spot. Figure 1-46 shows two different targets, with angles of 20° and 40°. As you can see,

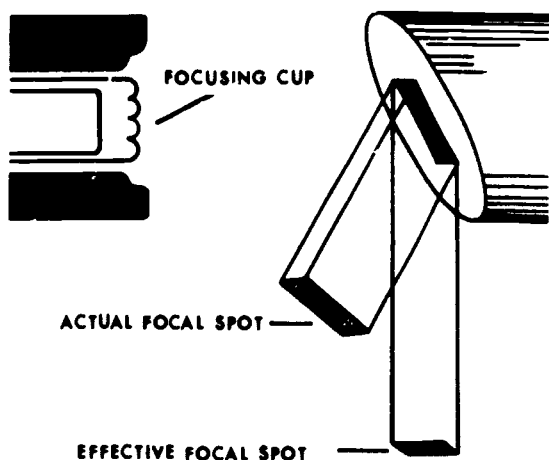


Figure 1-45. Actual and effective focal spots.

both targets produce effective focal spots of equal size, but the actual focal spot at  $20^\circ$  is larger. Consequently, the  $20^\circ$  target produces a relatively large actual and a relatively small effective focal spot.

In actual practice, targets are usually angled less than  $20^\circ$  (some as little as  $7^\circ$ ), thereby aiding in obtaining high heat loading and optimum detail. However, targets with small angles may create a problem that is not significant with larger angles. The problem is in the area of X-ray coverage, or, put another way, the area that the X-ray beam will cover. For example, a target with a  $10^\circ$  angle at a 40-inch focal film distance (FFD) covers only a 14-inch-square area and a  $7^\circ$  angle covers only a 9.5-inch-square field. Obviously these tubes cannot be used to radiograph an anterior posterior (AP) abdomen at 40 inches, since the beam will not cover the entire abdomen. (Tubes of this type can be used effectively, however, where X-ray coverage is not as critical as the requirement for good detail—for example, in an angiographic room, where the beam will cover the smaller films used in automatic film changers.) A  $12^\circ$  target is the smallest angle that adequately covers a 14- by 17-inch film at a 40-inch FFD.

One recent development in tube focal spots is a biased focal spot. Due to the inherent design of X-ray tubes, electrons striking the target have a tendency to concentrate on the outer sides, resulting in more X-ray photons being produced at those locations. In effect, this situation produces two sources of X-ray photons, which may produce double images on the film. The double image is particularly a problem if small vessel magnification radiographs are desired. To overcome the problem, a negative bias voltage is applied to the cathode, which concentrates the electrons more in one spot on the target, thus providing a single source of X-ray photons.

#### Exercises (035):

1. What anode condition causes the free electrons to be set in motion?

2. In what part of the X-ray tube are X-ray photons produced?
  3. Why is tungsten used as target material?
  4. Of what significance is the actual focal spot?
  5. Name two factors that affect the size of the effective focal spot.
  6. Explain what is meant by the "line-focus principle."
  7. Explain the relationship between target angle and film coverage.
  8. What is the smallest target angle that covers a 14- by 17-inch film at a 40-inch FFD?
  9. What type of focal spot is advantageous for small vessel magnification radiographs, and why?
036. State two advantages of a grid-controlled X-ray tube, and explain the factors that produce these advantages.

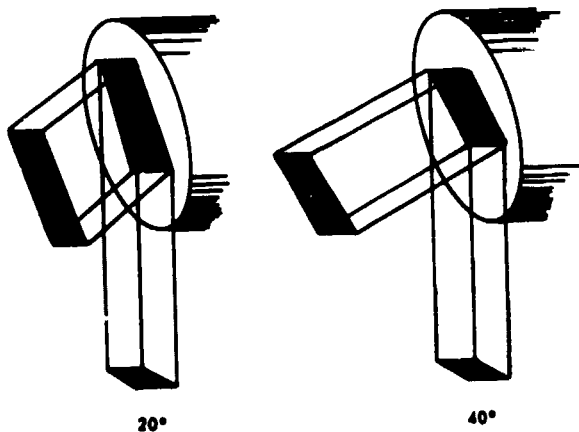


Figure 1-46. Comparison of focal spots of different target angles.

**Grid-controlled tube.** To prevent relay damage due to arcing, an X-ray exposure is normally synchronized to the line voltage so that it begins and ends when the sine wave is at zero value. Using this system in a single-phase generator, the shortest exposure possible is 1/120 second, since the sine wave reaches zero value every 1/120 second. With a grid-controlled tube, the exposure is also synchronized with the line voltage, but it does not necessarily begin and end at zero value. It can be synchronized to a particular portion of the sine wave. Figure 1-47 shows two waveforms with exposures of 1/120 second on a conventionally timed tube and 1/360 second on a grid-controlled tube. Since the conventional exposure should begin and end at zero value, it must encompass one complete pulse. On the other hand, the grid-controlled exposure indicated here includes only the middle third of the pulse. Even shorter exposures are possible with grid-controlled tubes, and this feature makes them desirable for examinations requiring very short exposures. When a grid-controlled, short exposure is used, as in figure 1-47, the radiation dose to the patient is reduced. The reduction occurs because the exposure can be short enough so that it does not include portions of the wave producing low-energy photons. The patient's dose is also reduced when a grid-controlled tube is used with cinefluorography, because X-ray production can be synchronized with the camera shutter. Such synchronization reduces patient exposure because X-rays are produced only when the shutter is open.

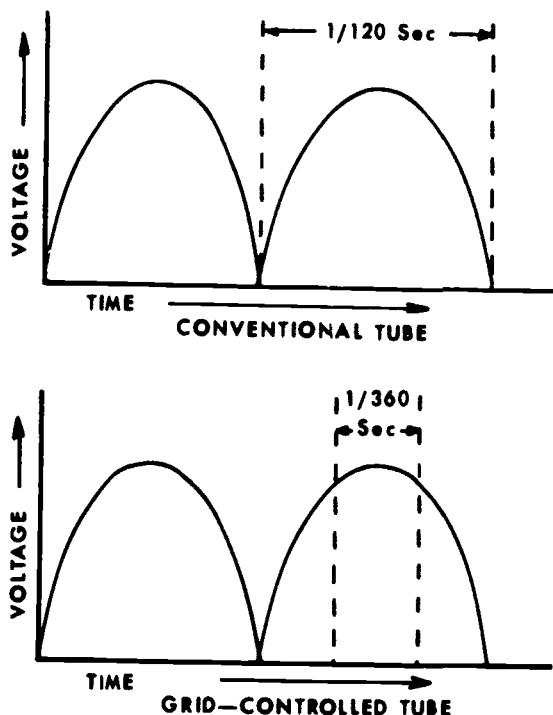


Figure 1-47. Comparison of exposure times between a conventional and grid-controlled tube.

**Exercises (036):**

In the spaces below, name two advantages of using a grid-controlled X-ray tube. After each, explain how the advantage is realized.

- 1.
- 2.

037. Given selected exposure factors (mA, kVp, and sec), calculate the number of heat units per exposure.

**Tube Rating Charts.** How long will an X-ray tube last? Primarily, this depends on how well you take care of it. X-ray tubes are well constructed and provide years of useful service if properly used. When we say "properly used," we mean operated within the exposure limits that are established by the manufacturer and expressed in tube-rating charts. We shall discuss several types of tube-rating charts and how to use them after we have reviewed the calculation of heat units.

**Heat units.** The maximum exposure limits for a particular tube are based on the amount of heat generated in the tube. This heat buildup is expressed in heat units (H.U.). H.U. are the product of kVp × mA × sec in single-phase generators. The formula is written:

$$\text{H.U.} = \text{kVp} \times \text{mA} \times \text{sec}$$

For example, the number of H.U. generated by an exposure of 75 kVp, 100 mA, and 1/2 sec is 3,750 since:

$$\begin{aligned} \text{H.U.} &= \text{kVp} \times \text{mA} \times \text{sec} \\ &= 75 \times 100 \times 1/2 \\ &= 7,500 \times 1/2 \\ &= 3,750 \end{aligned}$$

From previous discussions, you will probably recall that the electron beam in three-phase equipment has a higher average energy level. This, in turn, generates more heat when radiation is produced. To correct the H.U. formula for three-phase equipment, the previously mentioned exposure factors are multiplied by 1.35. For example, to find the H.U. using 75 kVp, 100 mA, and 1/2 second in a three-phase generator, proceed as:

$$\begin{aligned} \text{H.U.} &= \text{kVp} \times \text{mA} \times \text{sec} \times 1.35 \\ &= 75 \times 100 \times 1/2 \times 1.35 \\ &= 3750 \times 1.35 \\ &= 5062 \end{aligned}$$

**Exercises (037):**

1. How many H.U. are generated by a single-phase generator, using 200 mA, 80 kVp, and 1/10 sec?
2. How many H.U. are generated by a three-phase generator, using 300 mA, 1/20 sec, and 74 kVp?

038. Given two different types of single-exposure tube-rating charts, determine: (1) the maximum mA if the kVp and sec are given; (2) the maximum kVp if mA and sec are given; (3) the maximum sec if mA and kVp are given; and (4) whether or not three exposures are safe.

*Single-exposure rating chart.* One type of single-exposure tube-rating chart is shown in figure 1-48. It is used to prevent damage to the tube from a single exposure. Suppose, for example, that you wish to use 100 kVp and 1/5 sec for an exposure and you want to find the maximum mA that can safely be used with those factors. Find where the 100 PKV line (100 PKV on the chart) crosses the 1/5 sec line on the chart. From that point, move horizontally to the left and check the mA scale. In this case, it falls between 150 and 175 mA, which means the 150 mA station is the highest that can be used with 100 kVp and 1/5 sec. You can find either highest kVp or sec for a given exposure by using basically the same procedure.

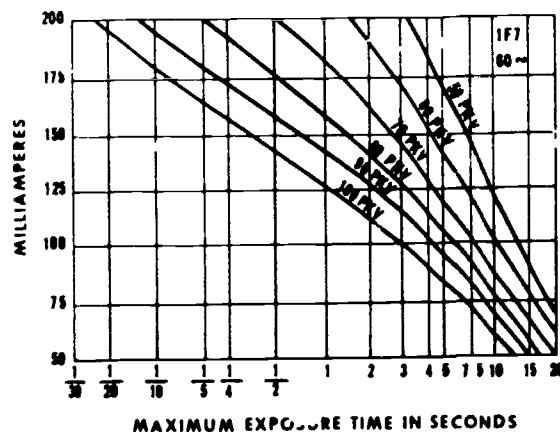


Figure 1-48. Single-exposure tube-rating chart.

You can also check an exposure against the chart to determine whether or not the exposure is safe. For example, suppose you wish to use 125 mA, 1 sec, and 100 kVp. Notice in figure 1-48 that 125 mA intersects the 100 kVp line slightly to the right of 1 sec (between 1 and 2 sec). This tells you that using these factors, an exposure time of a little more than 1 sec is permitted; therefore, the exposure is safe.

Another type of single-exposure tube-rating chart is shown in figure 1-49. To find the maximum mA that you can use, for example, 110 kVp (PKV on the chart) and 0.1 sec, simply find 110 kVp on the left margin. Move horizontally to the 0.1 sec column, and read the maximum mA, which in this case is 190. Use a similar procedure to determine the maximum kVp or exposure time and to determine whether or not an exposure is safe.

PKV	EXPOSURE TIME IN SECONDS										
	UP TO 0.01	0.02	0.05	0.1	0.2	0.5	1	2	5	10	20
50	220	220	220	220	220	220	220	220	220	220	170
60	270	270	270	270	270	270	270	270	230	190	150
70	320	320	300	290	290	270	250	230	190	160	130
80	270	270	260	260	250	240	220	200	170	145	110
90	240	240	230	230	220	210	200	180	150	130	100
100	210	210	210	200	200	190	180	160	140	115	90
110	190	190	190	190	180	170	160	150	125	105	80
125	170	170	170	160	160	150	145	130	110	90	72
150	145	145	140	140	135	130	120	110	95	75	60

Figure 1-49. Single-exposure tube-rating chart



**Exercises (038):**

Complete exercises 1 through 4, which are based on the tube-rating chart in figure 1-50. (PKV on the chart is the same as kVp.)

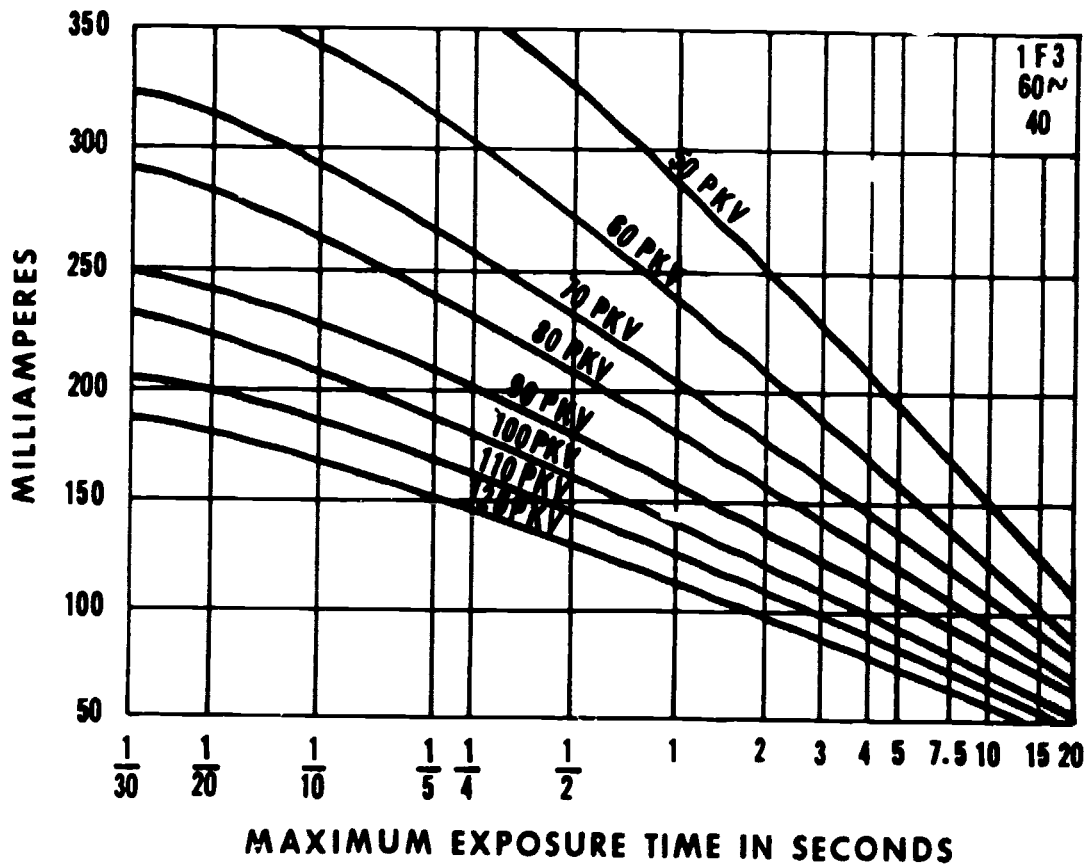


Figure 1-50. Objective 038, exercises 1 through 4.

1. What maximum mA station can safely be used with 1/4 sec and 90 kVp?
2. What maximum kVp can safely be used with 2 sec and 250 mA?
3. What maximum exposure time can safely be used with 200 mA and 110 kVp?
4. Are the following exposures safe?
  - a. 200 mA, 70 kVp, 1 sec.
  - b. 300 mA, 80 kVp, 1/30 sec.
  - c. 100 mA, 100 kVp, 3 sec.

Complete exercises 5 through 8, based on the tube-rating chart in figure 1-51. (PKV on the chart is the same as kVp.)

PKV	EXPOSURE TIME IN SECONDS											
	UP TO	0.01	0.02	0.05	0.1	0.2	0.5	1	2	5	10	20
	MAXIMUM CURRENT IN MA											
50	220	220	220	220	220	220	220	220	210	190	160	140
60	210	210	210	200	200	190	190	180	180	160	140	115
70	180	180	180	170	170	170	160	150	135	120	100	100
80	160	160	150	150	150	150	145	135	120	105	85	85
90	140	140	140	140	135	130	125	120	105	95	75	75
100	130	130	125	125	125	120	115	110	95	85	70	70
110	115	115	115	115	110	110	105	100	85	75	64	64
125	100	100	100	100	100	95	90	85	75	68	56	56
150	85	85	85	85	80	80	75	72	64	56	46	46

Figure 1-51 Objective 038, exercises 5 through 8.

5. What maximum mA can safely be used with 100 kVp and 2 sec?

c. 100 kVp, 0.01 sec, 160 mA.

6. What maximum kVp can safely be used with 0.01 sec and 100 mA?

039. Given an angiographic rating chart and various applicable exposure data, determine whether or not the exposures are safe.

7. What maximum exposure time can safely be used with 70 kVp and 180 mA?

*Angiographic rating chart.* Figure 1-52 is an example of an angiographic rating chart designed to enable you to determine whether or not the total number of exposures for an angiographic examination exceeds the maximum limits of the tube. Suppose your radiologist desires to perform an angiogram and wants two exposures per second for 2 seconds, a total of four exposures. The exposure factors are 1,000 mA, 1/10 sec, and 90 kVp. First, find the heat units per exposure, which in this case is 9,000. Find two exposures per second on the left margin of the chart; move across that column to 9,000 (the maximum load per exposure). Then move up to the total number of exposures, which in this case is two. This means that only two exposures can be made safely—so the examination cannot be performed under the described conditions.

8. Are the following exposures safe?

a. 150 kVp, 0.2 sec, 100 mA.

b. 60 kVp, 5 sec, 160 mA.

EXPOS. PER SEC	TOTAL NUMBER OF EXPOSURES							
	2	5	10	20	30	40	50	60
	MAXIMUM LOAD IN			PKV X MA X SEC		PER EXPOSURE (*)		
1	16500	13800	11400	9000	7400	6400	5700	5000
2	9000	8000	7000	5700	5000	4400	4000	3700
3	6200	5600	5000	4300	3800	3400	3200	3000
4	4800	4400	3900	3400	3100	2850	2650	2500
5	3900	3600	3300	2900	2650	2450	2300	2150
6	3200	3000	2800	2500	2300	2150	2000	1900
8	2500	2350	2200	2000	1850	1750	1650	1550
10	2050	1900	1800	1650	1550	1460	1380	1320
12	1700	1600	1550	1420	1320	1260	1200	1160

Figure 1-52. Angiographic rating chart

**Exercises (039):**

Using the angiographic rating chart in figure 1-53, determine whether or not each of the following groups of exposure data can be safely used for an angiogram.

EXPOS. PER SEC	TOTAL NUMBER OF EXPOSURES							
	2	5	10	20	30	40	50	60
	MAXIMUM LOAD IN			PKV X MA X SEC		PER EXPOSURE (*)		
1	10800	9600	8400	7000	6000	5300	4800	4400
2	5700	5200	4700	4100	3700	3400	3200	3000
3	3800	3600	3300	3000	2800	2600	2450	2300
4	2950	2800	2650	2400	2200	2100	2000	1900
5	2400	2300	2150	2000	1850	1750	1650	1600
6	2000	1900	1800	1700	1600	1500	1460	1400
8	500	1460	1400	1320	1260	1200	1160	1120
10	220	1180	1140	1080	1040	1000	960	940
12	1020	1000	960	920	880	840	820	800

Figure 1-53 Objective 039, exercises 1 through 3

- 300 mA, 1/30 sec, 120 kVp, eight exposures per second for 5 seconds.
- 500 mA, 1/20 sec, 80 kVp, four exposures per second for 13 seconds.
- 1000 mA, 1/10 sec, 96 kVp, one exposure per second for 6 seconds.

**040.** Given two cooling charts (anode and housing) and selected exposure data, answer key questions pertaining to (1) the correlation between the charts and data and (2) the heat dissipation rate indicated by the charts.

*Cooling charts.* There are two types of cooling charts: the anode-cooling chart and the housing-cooling chart. The anode chart shows the maximum number of H.U. that the anode can store, and the housing chart shows the maximum number of H.U. that the tube housing can store. Both charts also show the heat dissipation rate. Let's see how to use the charts, beginning with the anode-cooling chart.

Figure 1-54 shows an anode-cooling chart that can store a maximum of 300,000 H.U. (a relatively high capacity anode). Suppose that during an angiogram or a cine examination the total H.U. applied to the anode is 200,000, and it is necessary to repeat the examination without significant delay. If the examination were repeated immediately, there would be a total of 400,000 H.U. generated by the two examinations—100,000 H.U. more than the anode can store. In this case, to prevent damage to the tube, you would have to allow the anode to cool to 100,000 H.U. before the examination could be repeated. Find the cooling time between examinations by following the cooling curve from 200,000 H.U. to 100,000 H.U., which in

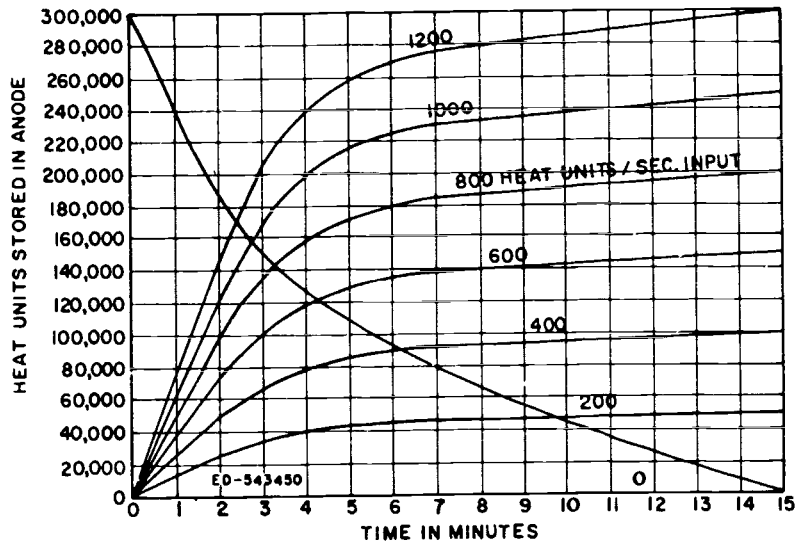


Figure 1-54. Anode-cooling chart.

figure 1-54 is about 4 minutes. So, this examination can be repeated every 4 minutes.

The anode-cooling chart also tells you the relationship between fluoroscopic time and anode H.U. storage. For example, if the fluoroscopic kVp is 100 and the mA is 2, the H.U./sec input is 200. According to figure 1-54, 200 H.U./sec subjects the anode to only about 50,000 H.U. at the end of 15 minutes of continuous fluoroscopic time, allowing for the cooling that occurs during the 15 minutes. In figure 1-54, all of the H.U./sec inputs except 1,200 are safe for indefinite fluoroscopy because they do not subject the anode to the 300,000 H.U. maximum. The input of 1,200 H.U./sec, however, can be used only for 15

minutes because at that time 300,000 H.U. are stored in the anode. Additional fluoroscopy can then be performed after an appropriate cooling time according to the cooling curve, as described earlier.

The housing-cooling chart, shown in figure 1-55, shows the maximum H.U. that can be stored in the tube housing. Notice that the tube housing stores more H.U. than the anode in figure 1-54 (both of these charts are for the same tube). Also, notice that the heat dissipation rate without the air circulator is considerably less than that of the anode in figure 1-54. To see the difference in the heat dissipation rate, notice that the anode in figure 1-54 dissipates 300,000 H.U. in 15 minutes, while the tube housing dissipated only

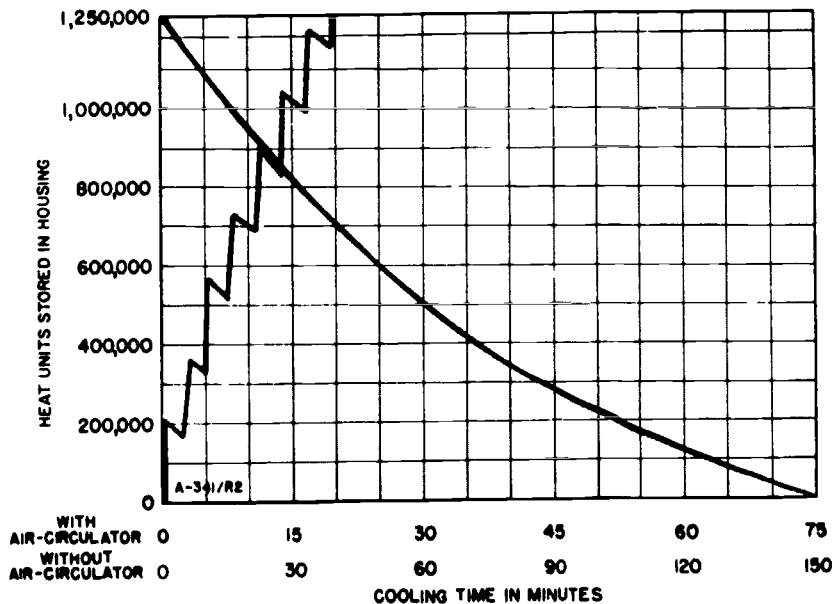


Figure 1-55. Housing-cooling chart.

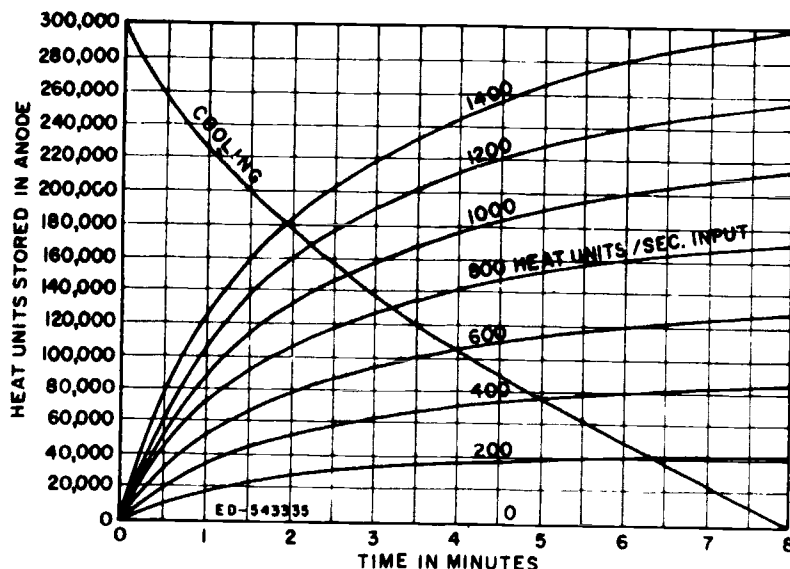
about 200,000 H.U. in 15 minutes without the air circulator. This tells you that even though you can operate your tube safely within the limits of the anode-cooling chart, you may exceed the maximum housing storage capacity.

Consider the 200,000 H.U. of the examination discussed earlier. We decided that the examination could be repeated every 4 minutes without damage to the anode. If the examination were repeated several times, you would eventually reach the housing storage limit. Notice the zigzag line in figure 1-55. Beginning in the lower left corner, the line goes vertically to 200,000 H.U. (the first examination). After 4 minutes

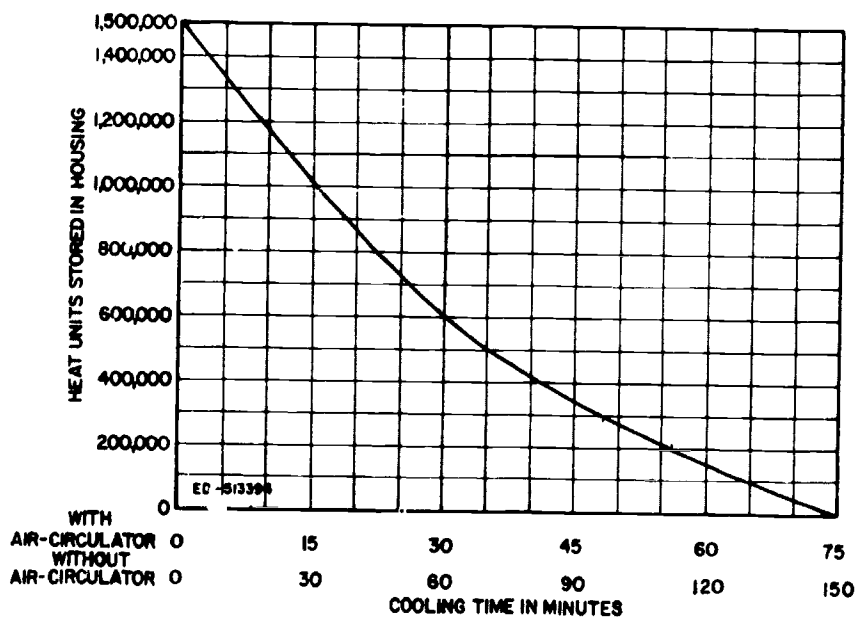
of cooling, based on the cooling curve, the stored H.U. drops to approximately 185,000 H.U. The next exam raises the stored H.U. to 375,000, and so on. Eventually, the stored H.U. in the tube housing reaches the maximum permissible. In this case, only about seven examinations could be performed consecutively.

**Exercises (040):**

Complete the following exercises based on the cooling charts in figure 1-56. Chart A is the anode-cooling chart; chart B is the housing-cooling chart. Both charts are for the same X-ray tube.



A



B

Figure 1-56. Objective 040, exercises 1 through 5

1. If you perform an examination that generates 140,000 H.U., how many minutes of cooling, if any, must you allow before repeating the examination once?
2. If you perform an examination that generates 220,000 H.U., how many minutes of cooling, if any, must you allow before repeating the examination?
3. How long can fluoroscopy be continuously performed, using 5 mA at 120 kVp?
4. How long can fluoroscopy be continuously performed, using an input of 1,400 H.U./sec?
5. If an examination generates 400,000 H.U., how many such examinations can be performed, if the minimum cooling time is allowed between examinations, before exceeding the housing storage capacity? The X-ray tube has no air circulator. For this exercise, disregard figure 1-56,A, and assume that 400,000 H.U. is dissipated from the anode every 10 minutes.

## The Primary Beam

QUALITY CONTROL is one of the most important aspects of a well-coordinated, efficient radiology department. In this chapter, we shall concentrate on a review of the primary beam and how it affects the radiographic image. Understanding the primary beam will greatly assist you in your control of image quality. To achieve this objective, we shall begin by discussing the characteristics of the primary beam. Principally important here are the elements called quality and quantity. Following the discussion of primary beam characteristics, you can apply your knowledge to the study of projection factors. These explanations will enable you to better understand how to formulate techniques and further improve quality control on the job.

### 2-1. Inherent Characteristics of the Primary Beam

The nature of the primary beam is evaluated by two factors, quality and quantity. These are the terms by which you denote both penetrating ability and intensity of the X-ray beam. Let's begin our discussion with beam quality.

#### 041. Indicate whether statements correctly reflect factors that affect the quality of the primary beam.

**Quality.** When we speak of the quality of the primary beam, we actually mean the ability of the beam to penetrate matter or, more specifically, human tissue. A high-quality beam is one with relatively high penetrating power, and a low-quality beam is one with low penetrating power. You should understand the penetrating power of the primary beam because a certain amount of X-ray photons must penetrate the part and reach the film to provide sufficient density and the desired degree of contrast. Consequently, we can say that for all practical purposes there is a minimum degree of penetration required for each body part. We cannot tell you precisely what the requirements are for each body part. They depend on several factors, including part size and pathology.

Wavelength is another term associated with beam quality. The shorter the wavelengths of the X-ray photons, the greater the penetrating power. A beam of X-radiation is composed of many photons with

varying wavelengths; hence it is a *heterogeneous* beam.

Since the *energy* of a photon is directly related to its wavelength, energy is yet another term closely associated with beam quality. The higher the energy of a photon, the shorter its wavelength. Keep in mind that although we may speak of the energy or wavelength of a single X-ray photon, there are millions of photons in a beam of X-radiation with different wavelengths or energies. Therefore, the *average* or *mean* energy, or wavelength, is the important factor.

How do you alter the quality of the primary beam? Obviously, by changing the kVp setting on your control panel. How does the kVp affect beam quality? If you increase the kVp on your control panel, you increase the energies of the electrons across the X-ray tube. Suppose you apply 80 kVp across the X-ray tube. Theoretically, the energies of the electrons range from 1 to 80 keV. (This range would be in a single-phase generator only. In a three-phase generator, the maximum electron energy would be the same, but the minimum energy would be higher, as discussed in Chapter 1.) The energies of the photons produced as the electrons interact with the target also range from 1 to 80 keV. Now suppose you apply 100 kVp across the X-ray tube. The electron energy range and the photon energy range increase proportionately. Consequently, the average energy of a beam of X-radiation is determined by the average energy of the electrons striking the target.

#### Exercises (041):

Indicate whether the following statements are true or false. If you indicate false, explain your answer.

T F 1. Quality of the primary beam denotes penetrative ability.

T F 2. Good visualization of a body part occurs if the part absorbs all photons that strike it.

T F 3. Practically speaking, penetration of a part must meet a definite minimum.

- T F 4. A highly energetic beam of X-radiation has relatively high quality.
- T F 5. Photons with long wavelengths have relatively low energy.
- T F 6. The average energy of a beam of X-radiation depends upon the number of photons present.
- T F 7. You can regulate the penetrating ability of the primary beam by adjusting the kVp selector.
- T F 8. An increase in kVp increases the minimum electron energy across the X-ray tube.
- T F 9. If the average electron energy is lowered, the average photon energy is also lowered.

**042. Define "beam quantity," and given a list of three factors affecting beam quantity, match the factors with appropriate definitive statements or phrases.**

**Quantity.** The quantity, or (as it is usually called) intensity, of a beam of X-radiation at a given FFD can be defined as "the characteristic that affects the density on a radiograph." Intensity of the primary beam is a measure of the number of photons per unit area in combination with the mean energy of the photons.

How do you control the intensity of the primary beam? To understand this, let's go back once again to the electrons that travel from the filament in the X-ray tube to the target. An increase in mA results in a higher filament temperature and more electrons available to traverse the tube for interaction. The more electrons interacting with the target, the more photons produced. Further, the increase in the number of photons is proportionate to the increase in the number of electrons. For example, if the number of electrons is doubled, the number of photons, and consequently the intensity, is doubled. Since mA regulates the amount of electrons, you can see how adjusting the mA regulates the intensity of the primary beam.

Varying the exposure time is another way to regulate the number of electrons interacting with the target. Suppose 100 mA is applied to the X-ray tube for 1/10 sec. If the exposure time is increased to 1/5 sec,

electrons are emitted from the filament at the same rate, but the period of time during which they are emitted is twice as long ( $1/10 \times 2 = 1/5$ ). In effect, this change in the exposure time doubles the number of electrons interacting with the target and consequently doubles the number of photons produced.

Another way to affect the intensity is with the kVp. While mA and exposure time control intensity by regulating the *number* of photons produced, kVp controls intensity by affecting the *number* of photons produced *and* by regulating the *mean energy* of the photons. As discussed earlier, if the kVp is increased, the energy of the electrons is increased. This increase in electron energy also increases the number of photons emitted from the target. A change of plus or minus 15 percent of the kVp amounts to approximately the same as doubling or halving the mA or exposure time.

As with the penetrating power of the beam, we are not now concerned with the energy of a particular electron or with the specific number of photons. The relative intensity is the important issue.

**Exercises (042):**

- In your own words, explain what is meant by "beam quantity."
- Match the quantity factor in column B with the appropriate statement or phrase in column A. Each column B factor may be used once, more than once, or not at all. In addition, more than one column B factor may match a single entry in column A.

<i>Column A</i>	<i>Column B</i>
_____ 1. If doubled, this factor doubles the beam intensity.	a mA
_____ 2. Affects both the number and energy level of the photons.	b FFD.
_____ 3. A 15 percent increase in this factor approximately doubles the intensity.	c. Exposure time.
_____ 4. Decreases intensity by decreasing the number of electrons available for interaction.	d kVp.
_____ 5. Affects intensity by affecting duration of electron emission	
_____ 6. Affects the number of electrons or photons per unit time.	
_____ 7. Regulates beam quantity of a specific distance from the X-ray tube	
_____ 8. If halved, this factor halves the intensity.	

**043. State the inverse square law and indicate its effect on the intensity of the X-ray beam.**

**Inverse square law.** In the preceding discussion we considered beam intensity at a specific distance from the target. According to the *inverse square law*, the intensity of the primary beam is not the same at



various distances from the target of the X-ray tube. The inverse square law states that the *intensity of radiation in the primary beam is inversely proportional to the square of the distance from the target*. Thus, as the distance from the tube increases, the intensity of the beam decreases. If the distance is doubled, the intensity decreases to one-fourth. Similarly, if the distance is halved, the intensity increases four times. This variation in intensity is a result of the divergence of the beam. Figure 2-1 illustrates this relationship. Notice that the primary beam at 72 inches covers an area 4 times as great as at 36 inches because of its divergence. For comparative purposes, let's assume that the blocks in the figure measure 1 square inch and the intensity at 36 inches is 20 X-ray photons per square inch, or 80 photons, for blocks 1, 2, 3, and 4. At 72 inches, because of the divergence of the beam, the 80 photons are now spread over 16 square inches, or 5 photons per square inch. Thus, the intensity is reduced to one-fourth at twice the distance. Note that when we discuss variations in intensity according to the inverse square law, we are speaking only of the number of photons per unit area. Photon energy does not enter into the picture.

**Exercises (043):**

1. State the inverse square law.
2. The intensity of the primary beam at 36 inches from the target is 200 photons per square inch. What is the intensity at 18 inches from the target? At 72 inches from the target?
3. Does the inverse square law affect beam intensity by affecting the number of photons emitted from the target? Explain your answer.
4. What is the connection, if any, between the inverse square law and photon energy?

**044.** Explain the variation of intensity of the primary X-ray beam along the axis of the X-ray tube, indicating both the cause of this variation and the relationship between intensity and the distance from the central ray (CR).

**Anode Heel Effect.** The *anode heel effect* identifies the phenomenon that produces a variation in intensity of the radiation within the primary beam along

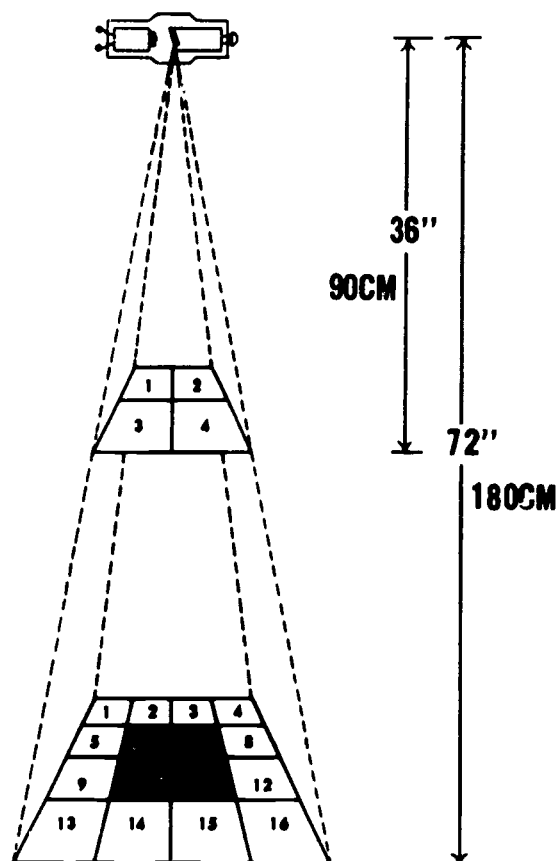


Figure 2-1. The primary beam and the inverse square law.

the longitudinal axis of the X-ray tube. Using the central ray (CR) as our starting point, let's see how the intensity varies.

When we move away from the CR on the anode side, we find that the intensity becomes less and less the farther we go. Also, when we move away from the CR on the cathode side, we find that the beam becomes more intense than it was in the CR area, or on the anode side. The area of increased intensity is limited, however, and, as we continue to move in the direction of the cathode, we find that the intensity again decreases. The intensity percentages at different angles of emission of a 20° anode are illustrated in figure 2-2. Keep in mind that the variation in intensity is mainly along the longitudinal axis of the X-ray tube.

The variation in intensity is due to the angle of the anode. Some photons are emitted from within the target material, rather than from the target surface. As you can see in figure 2-3, photons emitted from within the target toward the anode side of the tube travel through more target material, and therefore, more of these photons are absorbed. On the other hand, since photons emitted toward the cathode side of the tube travel through less target material, fewer are absorbed by the target. Consequently, when we

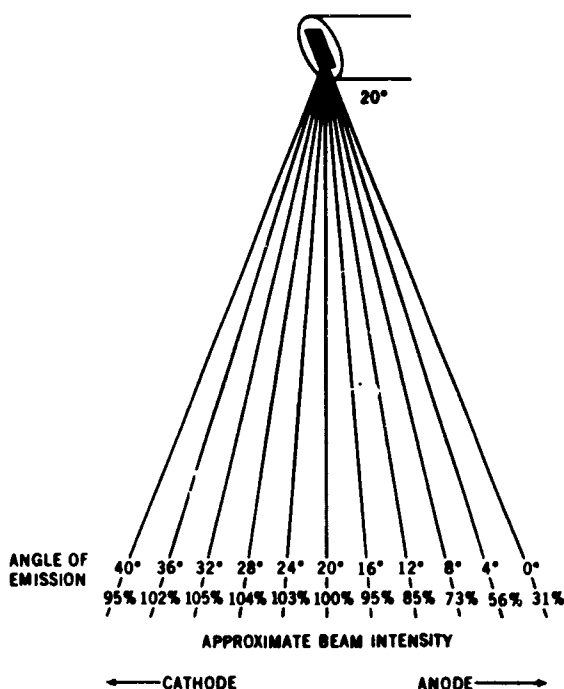


Figure 2-2. The anode heel effect, showing how the intensity of the primary beam depends upon the angle of emission from the target

When we speak of the anode heel effect, we actually mean the number of photons per unit area as opposed to the energies of the photons.

**Exercises (044):**

Fill in the blank spaces by selecting the appropriate words or phrases from the list. The statements pertain to an anode angle of 20°.

- 32°
- Anode
- Cathode
- Farthest
- Absorption; target material
- Increases; decrease
- Longitudinal; anode heel effect

1. The variation in the intensity of the X-ray beam along the \_\_\_\_\_ axis of the X-ray tube is known as the \_\_\_\_\_.
2. The greatest variation in intensity occurs \_\_\_\_\_ from the CR.
3. The intensity of the primary beam gradually decreases toward the \_\_\_\_\_ side of the X-ray tube.
4. The intensity of the primary beam \_\_\_\_\_ toward the cathode side of the X-ray tube for a substantial distance and then begins to \_\_\_\_\_.
5. The greatest concentration of X-ray photons is at a \_\_\_\_\_ angle off the surface of a 20° target.
6. More photons reach the film on the \_\_\_\_\_ side of the X-ray tube.

7. The anode heel effect is caused by \_\_\_\_\_ of X-ray photons by \_\_\_\_\_.

045. Given the hypothetical radiographic situations, apply the anode heel effect to each situation.

**Effect of Tube Angle.** The intensity percentages of the primary beam vary with tubes having different target angles. Refer again to figure 2-2 and note that the percentage range for a 20° target is 95 percent to 31 percent. With a smaller target angle, of 10°, for example, there is a greater difference in the intensity; consequently, the anode heel effect is more pronounced.

**Effect of FFD.** Regardless of the target angle of your tube, one factor that you must consider along with the anode heel effect is the FFD (focal film distance). Consider figure 2-4. If part 1 is radiographed, the intensity range is 85 percent to 104 percent. If part 2 is radiographed, the intensity range is 31 percent to 95 percent. The former range is not sufficient to cause objectionable density variation on a radiograph, while the latter most certainly is. You can see the reason for the difference in the intensity percentage range if you will compare the total area of the primary beam required to radiograph each part in figure 2-4.

**Effect of film size.** Another factor to consider pertaining to the anode heel effect is the film size. Notice in figure 2-5 that if two different sized films are used at a specific distance, the heel effect is more pronounced with the largest film. Thus, in general, we can conclude that radiographs of body parts requiring smaller films are less affected by the heel effect than radiographs of parts requiring larger films.

**Taking advantage of the anode heel effect.** Although the anode heel effect at times can cause unbalanced density on a radiograph, it can be used to your advantage when you X-ray certain parts of the body. Consider, for example, an AP thoracic spine.

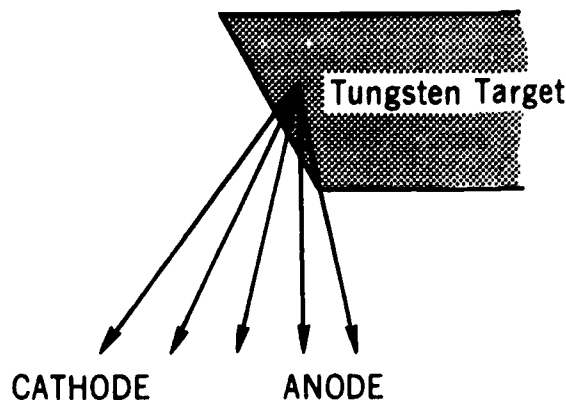


Figure 2-3. Illustration of a target, showing how some photons travel through more target material than others.

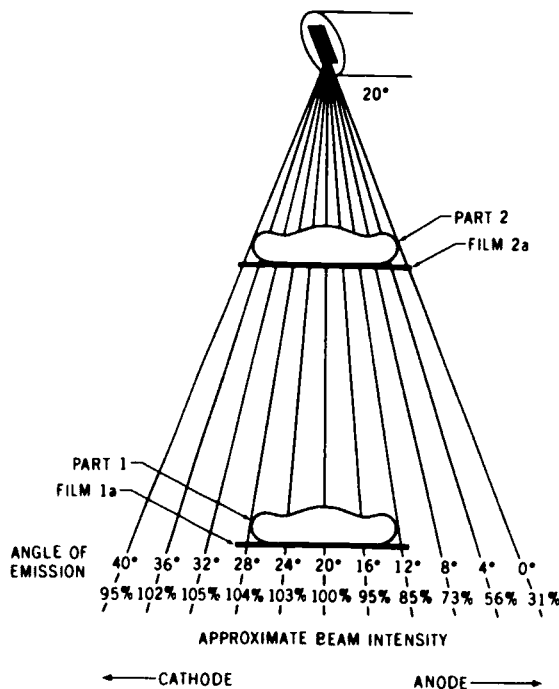


Figure 2-4. The anode heel effect, showing how FFD affects intensity distribution.

The thickness of the chest over the upper part of the spine is not as great as over the lower part. If you position the patient so that the anode side of the tube is over the upper spine and the cathode side over the lower spine, the anode heel effect can help maintain density due to uneven body thicknesses. The leg and femur are two other parts where the anode heel effect should be considered.

#### Exercises (045):

- You have three exposure rooms in your department. Room #1 has a target of 12° anode, room #2 has a 15° anode, and room #3 has a 17° anode. You must radiograph an AP thoracic spine on a patient whose lower chest is considerably thicker than average and whose upper chest is thinner than average. Using information presented in the text, answer the following questions.
  - Which exposure room should you use to take maximum advantage of the anode heel effect?
  - Why should you select that particular room? Be specific.
  - If the room you selected was tied up with a special procedure, which room should be your second choice?
- Your department has eight exposure rooms with anode angles ranging from 10° to 20°. You are establishing a room in which to perform all gall-bladder examinations. A single examination consists of four spot-films (5" by 5" field). Remembering the anode heel effect considerations presented in the text, provide answers to the following exercises.
  - Considering only the anode heel effect, which room should you select?
  - Explain the reason for your answer to exercise a.
- A portable AP radiograph is made of a leg, using a 30-inch FFD and a 17° target. Later the same day another AP radiograph is made in the radiology department, using a 40-inch FFD and also a 17° target. Using information presented in the text, answer the following questions.
  - How should the leg have been positioned to compensate for the difference between the size of the upper and lower portions?

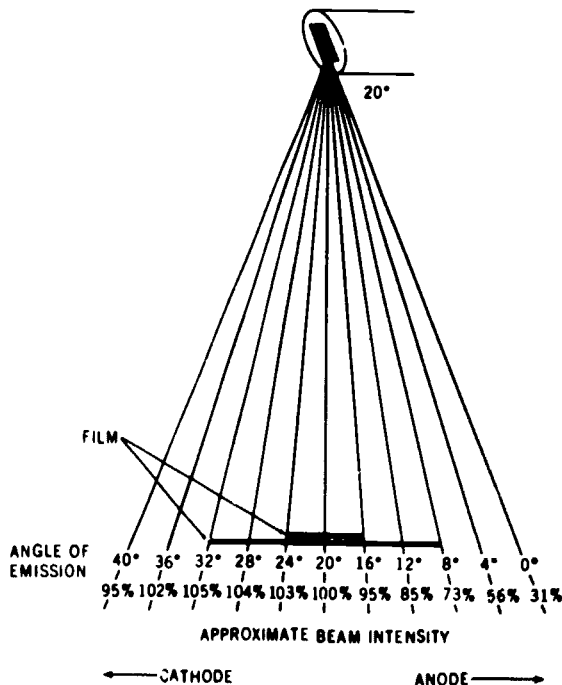


Figure 2-5. The anode heel effect, showing how the intensity varies according to film size.

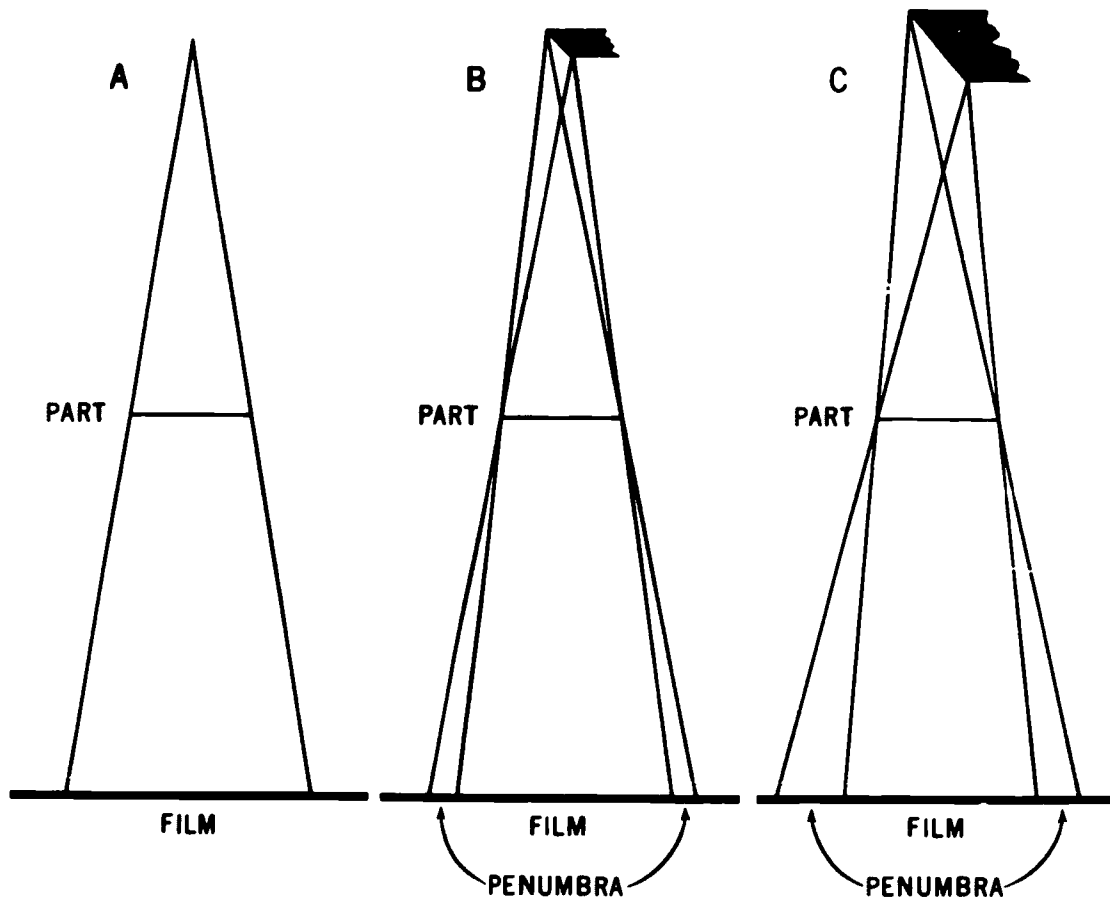


Figure 2-6. Projection of penumbra as a result of focal spot size.

- b. Assuming the radiographs were made using the same relative exposure, which radiograph would show the greater difference between the densities of the upper and lower portions of the leg? Why?

## 2-2. The Primary Beam and Its Projection of the Radiographic Image

We shall continue our study of the primary beam by discussing the geometric factors that affect the quality of a radiographic image. Specifically, the factors are focal spot size and the relationships between the tube, part, and film. We shall study these factors under the headings of focal spot size, magnification, and distortion.

**046. Identify true and false statements pertaining to the relationship between focal spot size and detail, and correct or explain the false statements.**

**Focal Spot Size.** No doubt you have been told many times to use the smallest focal spot possible. Note the use of the word "possible." As long as the exposure does not exceed the heat loading capacity of the tube,

a small focal spot should be used. We shall deal with the heat capacity a little later. For now, let's look a little closer at the detail.

**Focal spot size and detail.** Why does a small focal spot produce better detail than a larger one? To answer that question, refer to figure 2-6. Notice we have drawings of three focal spots projecting an image. Illustration A shows the focal spot as a point source of the X-ray photons. Illustration B represents a small focal spot, and illustration C represents a large focal spot. Notice that we did not refer to the point source as a small focal spot because we have no focal spots that small in radiology. They usually range from 0.3 to 2.0 mm. We show the point source merely to illustrate the difference in the projection of the image.

Notice that all edges of the part in drawing A, figure 2-6, are projected to one spot on the film, while in drawings B and C each edge is projected to a different spot. The reason that each edge is projected to a different spot is that the edge is projected by photons from many points within the target. For simplicity, we have shown in figure 2-6 only the photons from each side of the target, which determine the maximum area of penumbra. When the border of a part is projected in this manner, it is called penumbra and has a "fuzzy" or "unsharp" appearance.

As you can see, there is less penumbra present on

the image of the part projected by the smaller focal spot. A smaller focal spot causes less penumbra because the edges are projected by photons from fewer point sources.

Refer to figure 2-6, B and C, once again and notice the difference between the amount of penumbra from the anode side of the tube to the cathode side. As you can see, the amount is greater on the cathode side. What does this difference mean? First of all, it means that the edge of the part on the anode side is being radiographed with a smaller focal spot than the edge on the cathode side. Of course, the important aspect to note is that radiographs have better (focal spot) detail on the anode side. The farther toward the anode side, the better the detail; and the farther toward the cathode side, the worse the detail. Figure 2-7 gives you an idea of the relative focal spot sizes in the center and at both edges of the beam. The one in the center represents the size listed on your tube-rating chart.

#### Exercises (046):

Indicate whether the following statements are true or false. If you indicate false, explain your answer or correct the statement.

T F 1. Better detail is obtained by using a large focal spot.

T F 2. A large focal spot produces less penumbra.

T F 3. The more penumbra, the better the detail.

T F 4. Penumbra is greatest on the anode side of the tube.

T F 5. Radiographs have better detail on the anode side of the tube, due to the distance from the target.

**047.** Given hypothetical tube capacity data and situations requiring application of the data, apply the correct data to each situation and explain the reasons for your actions.

**Focal spot size and heat-loading capacity.** It would seem from the preceding discussion that you should always use the small focal spot on your X-ray machine. After all, it produces better detail, and detail on a radiograph is very important. However, there is a considerable difference between the heat-loading capacity of different sized focal spots. A small focal spot

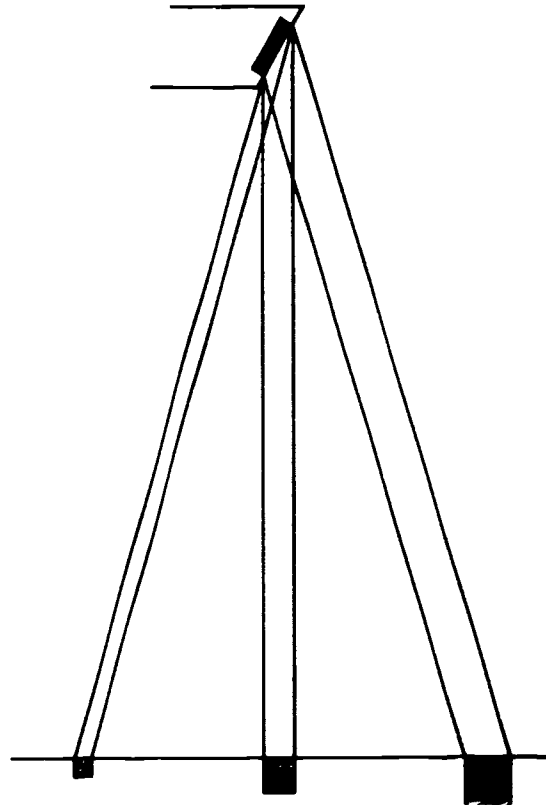


Figure 2-7 Focal spot sizes as seen from different parts of the X-ray field.

will not tolerate high exposures. Therefore, check the exposure factors against the tube-rating chart. If the rating chart shows the exposure to be within the maximum rating of the small focal spot and if some other limiting factor, such as part motion, does not preclude use of the small focal spot, then go ahead and use the small focal spot.

#### Exercises (047):

Suppose that the X-ray tubes in your two exposure rooms have the following focal spots. Further suppose that the *maximum* single exposure capacity is as stated below.

Exposure room #1:

0.2 mm - 100 mA, 78 kVp, 1/4 sec

1.5 mm - 300 mA, 110 kVp, 1 1/2 sec

Exposure room #2:

0.5 mm - 200 mA, 80 kVp, 1/2 sec

2.0 mm - 500 mA, 120 kVp, 2 sec

1. Which exposure room could provide the least penumbra on a radiograph? The most?

2. Which focal spot(s) should you use to radiograph a lateral lumbar spine, using 100 mAs at 110 kVp?

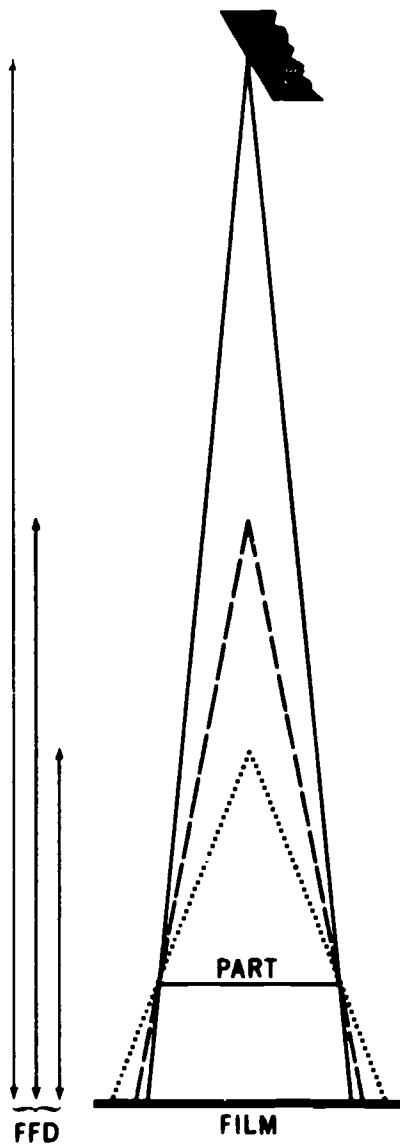


Figure 2-8. How a variation in FFD affects magnification on a radiograph.

- Suppose you are asked to establish procedures to perform magnification radiographs of all wrists with a possible fractured navicular. What action should you take, and why, concerning the exposure room and focal spot size to use for the examination?

**048.** Given selected descriptions of clinical radiographic situations, answer specific questions concerning the effects of FFD and part-film distance upon the situations.

**Magnification.** Magnification should normally be kept to minimum so that the part is projected as

near as possible to its actual size. This aspect is important to the radiologist's interpretation because increased magnification increases the penumbra on a radiograph, causing less clarity of the image. In addition, enlargement of some body parts is a sign of disease. If the part is magnified because of the projection, the radiologist may have difficulty making a diagnosis.

**Factors affecting magnification.** Basically two factors affect magnification: FFD and part-film distance. If you make two radiographs of a particular body part using the same part-film distance and different FFDs, the radiograph with the longer FFD will show less magnification. To illustrate how FFD affects magnification, refer to figure 2-8, where we have illustrated the same size part projected by three different FFDs. Notice that a more divergent beam projects the part on the film at the short FFD. It is this greater divergence which increases the magnification.

Part-film distance also has a pronounced effect on magnification if the FFD remains constant. Notice in figure 2-9 that three parts of equal size are projected by the same FFD. The only difference is in the part-film distance. Part A, which is farthest from the film, is magnified most, while parts B and C, which are nearer the film, are magnified progressively less. Magnification due to an increase in part-film distance occurs for the same basic reason as magnification from decreased FFD—that is, the part is projected by a more divergent beam.

**Practical applications of FFD and part-film distance.** The FFDs and part-film distance used in your department produce radiographs with an optimum scale of contrast, density, and detail. So why should you even be concerned with the FFD and part-film distance? Let's examine some conditions other than routine ones.

Suppose you are the quality control technician and see a skull series performed on a patient with a possible fracture of the superior portion of the right temporal bone. The only lateral radiograph included is a left lateral. From our previous discussion, you should realize that the left lateral does not show the right side as well as does a right lateral. The reason? There is more part-film distance, resulting in less detail of the right temporal bone. Of course, there may be a good reason why the right lateral was omitted—such as an uncooperative patient, for example. However, you won't know that until you investigate, will you?

Let's look at another condition. A patient has some sort of traction device on his leg X-rayed. The device adds 2 inches to the part-film distance for the AP projection. There is an obvious fracture of the midshafts of the tibia and fibula and a questionable fracture involving the ankle joint. The radiologist requests another AP projection so that he can re-evaluate the suspected joint fracture. What do you recommend?

In both of these cases, there are a number of factors that you might consider: a smaller focal spot, slower

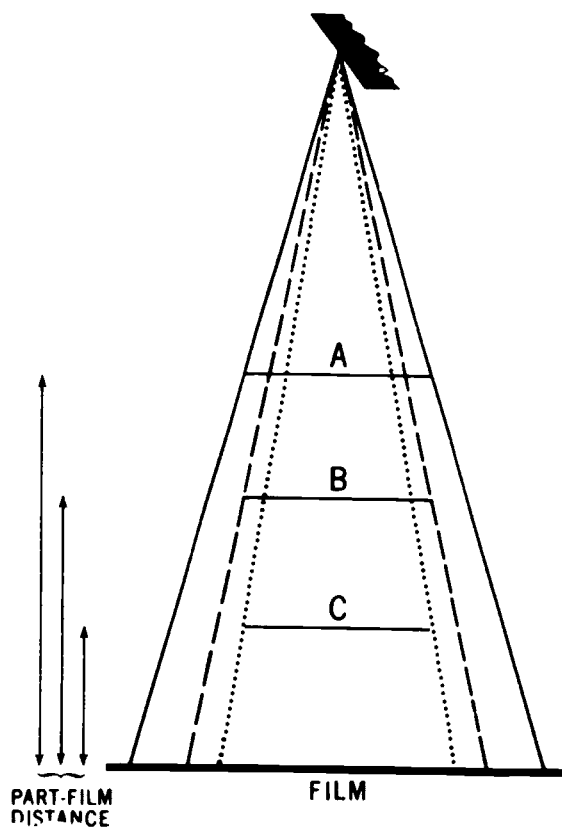


Figure 2-9. The effect of part-film distance on magnification if the FFD remains constant.

screens, direct exposure, and/or patient centering. Also, you shouldn't overlook the FFD.

#### Exercises (048):

1. If a patient is suspected of having a linear fracture of the right parietal bone, which lateral of the skull would best demonstrate the fracture? Why?
2. Two PA radiographs of the chest are made of the same patient: radiograph A using a 60-inch FFD and radiograph B using a 72-inch FFD. Both are diagnostic. Using the information in the text, answer the questions below.
  - a. If the radiographs were made for suspected heart enlargement, which one is best?
  - b. Which ribs (anterior or posterior), on which radiograph, will have greater magnification?
  - c. Which radiograph will have better overall detail?

3. If a properly positioned lateral projection of the right temporomandibular joint shows that the detail of the left side of the skull is interfering with visualization of the joint under study, how could you alter the FFD to decrease the detail of the left side?
4. The clinical history on a patient's X-ray request states "pneumonia, right lower lobe." A chest X-ray is ordered. A student specialist asks you what lateral projection to take. What should you tell him and why?
5. Due to conditions beyond his control, a student specialist performs a portable radiograph of a femur with more than normal part-film distance. There is too much penumbra on the radiograph. What FFD change could you recommend to decrease the penumbra? Why?

049. Identify what distortion is, state whether it's ever acceptable, and explain how to keep it to a minimum.




Figure 2-10. Radiographs of a radiopaque 2-by-2-inch square showing how tube angle and nonparallel part and film cause distortion on a radiograph.

**Distortion.** A part is said to be distorted when it is not projected on the film in its true shape. As a general rule, you should try to keep distortion to a minimum on your radiographs so that the part will appear in its normal shape. Thus, the radiologist can more easily recognize an abnormality. However, at times, deliberate distortion is necessary to project a part away from superimposed structures.

**CR-part-film relationships.** The relationships between the CR, the plane of the part, and the plane of the film affect distortion. Specifically, the plane of the part and the plane of the film must be parallel, and the CR should be perpendicular to this plane to minimize distortion. Notice in figure 2-10 the radiographs of a 2- by 2-inch square. Radiograph A was made under the above conditions. Radiograph B was made with the CR angled  $40^\circ$ . The plane of the square and film were parallel. Radiograph C was made with the square angled  $40^\circ$ . The CR was perpendicular to the film. Radiograph D was made with the film angled  $40^\circ$ . The CR was perpendicular to the square. As you can see, the shape of the square varies. The variation shown should indicate to you the importance of the CR-part-film relationship. Incidentally, the square has a "fracture." Can you see it on all of the projections?

**Acceptable distortion.** There are times when distortion is permissible, even necessary. An example is the

inferosuperior or axial projection of the clavicle. Distortion is necessary in this case to demonstrate the clavicle free from superimposition of the ribs.

**Exercises (049):**

1. What is the general rule regarding distortion on a radiograph?
2. Is distortion ever acceptable? Explain your answer.
3. How should the CR be directed with respect to the part and film to prevent distortion?
4. If the long axis of the femur is placed at a  $35^\circ$  angle to the plane of the film and the CR is perpendicular to the film, would the femur be distorted on the radiograph?
5. What relationship must exist between the part and film to prevent distortion?



## Exposure Devices

EARLY IN THE history of radiography, the pioneers in the field became aware of a serious problem affecting film exposures. The problem was film fog due to scatter radiation. To overcome this condition, certain devices were developed, which are referred to as exposure devices. Initially and until a few years ago, cones, cylinders, and diaphragms were used extensively to restrict the beam of X-radiation and thereby reduce film fog. However, these devices have given way to collimators—the topic of the first section of this chapter.

Another important exposure device used to reduce film fog is the grid. Many refinements have been made in grids since they were introduced. For example, it is no longer sufficient for a technician to merely know that a grid reduces scatter radiation. Some grids reduce scatter radiation better than others. We shall discuss grids in the latter part of this chapter.

### 3-1. Collimators

**050.** Indicate whether statements pertaining to the functions of a collimator are correct.

**Functions of a Collimator.** A collimator is used to restrict the size of the primary beam. As you know, you should *always* restrict the size of the primary beam to the smallest size possible and still include the part under study in the X-ray field. If you think you have heard that last statement before, no doubt you have, and you will hear it again and again. Using a small X-ray field is important for two reasons: (1) it reduces the exposure to the patient and (2) it reduces film fog due to scatter radiation. (We shall discuss beam size and patient exposure in Chapter 6.)

One of the major causes of film fog is scatter radiation that reaches the film. The amount of scatter radiation produced by an X-ray beam is related to the size of the X-ray field. Refer to figure 3-1, where we have illustrated the same body part projected by both a large and a small X-ray field. For a part of this size, only a relatively small film area is needed. If the primary beam is restricted to only that portion of the X-ray film needed, as in drawing A, there is a relatively small amount of scatter radiation reaching the film.

However, if the beam is enlarged so that it covers a larger area, as in drawing B, there is an increase in the scatter radiation reaching the film. Notice that the increase in scatter reaching the film not only occurs on the parts of the film that do not record the image, but also occurs directly over the image itself. The reason for this latter effect is that some scatter radiation is emitted at acute angles with respect to the film.

There are many applications of a small cone field. Let's look at one examination and see how a small cone field may affect the outcome. Suppose the part shown in figure 3-1 is a gallbladder. Further suppose that the concentration of contrast medium in the gallbladder is less than it should be for one reason or another. Because of the minimal concentration of the contrast medium, there is little contrast between the gallbladder and the surrounding structures. If you use a large cone field, you further reduce the contrast by increasing the film fog. But if you use a small cone field, contrast is increased—perhaps enough to adequately demonstrate the gallbladder.

#### Exercises (050):

Indicate whether the following statements are true or false. If you indicate false, explain your answer.

T F 1. A beam-restricting device reduces the intensity of the primary beam.

T F 2. You should use the smallest size X-ray field consistent with the requirements of the examination.

T F 3. A small X-ray field reduces patient radiation exposure.

T F 4. A small X-ray field increases contrast.

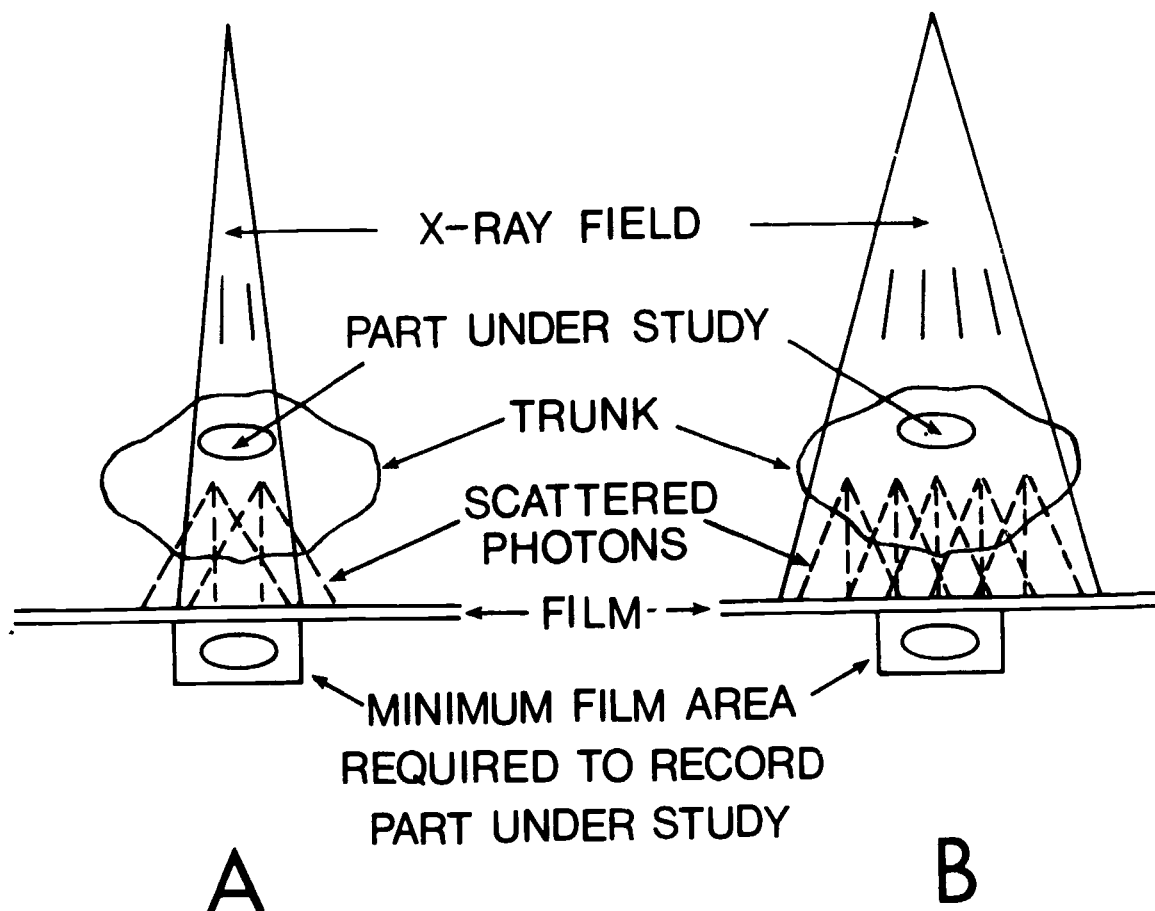


Figure 3-1. Effects of small and large X-ray fields on scattered radiation.

- T F 5. You can reduce scatter radiation by using a larger X-ray field.
- T F 6. A small X-ray field produces less film fog than does a large one.
- T F 7. Scatter radiation from a specific area within the body can fog the film in more than one spot.

**051. Describe the procedure for checking the accuracy of the numerical collimator scale; and given appropriate data, determine whether four collimator scales meet prescribed standards.**

**Collimator Requirements.** AFM 161-38, *Diagnostic X-Ray, Therapeutic X-Ray, and Gamma-Beam Protection for Energies Up To 10 Million Electron*

*Volts*, requires that multipurpose X-ray units be equipped with an adjustable rectangular collimator containing a light localizer that defines the entire X-ray field. Thus, all of your X-ray machines, except for special-purpose units such as those used for mammography, must have such a collimator. The manual also describes several specific collimator requirements.

*Numerical scale.* According to the manual, a numerical scale must indicate the size of the X-ray field at specific distances from the target. The scale must be accurate within 2 percent of the FFD when the CR is directed perpendicularly to the plane of the film. This means that if, for example, you set the collimator scale for a 10-inch X-ray field at a 40-inch FFD, the actual X-ray field must be within 2 percent of 40. The 2 percent refers to the sides of the X-ray field. In the case cited above, each border of the X-ray field must measure from 9.2 inches to 10.8 inches (2 percent of 40 is 0.8).

It is a simple matter to check the accuracy of the numerical scale. All that you have to do is to set the scale for a certain size field at a specific FFD and make an exposure on a film at that FFD. Then measure the sides of the X-ray field. Adjustments to the collimator are made by a medical equipment repairman.

**Exercises (051):**

1. In your own words, describe the procedure for checking the accuracy of a collimator numerical scale.
2. Figure 3-2 shows drawings of four X-ray fields made to check the accuracy of four collimator scales. The scale setting for each drawing is indicated opposite the exercises below. Indicate whether or not the collimator meets the prescribed standards in each case.

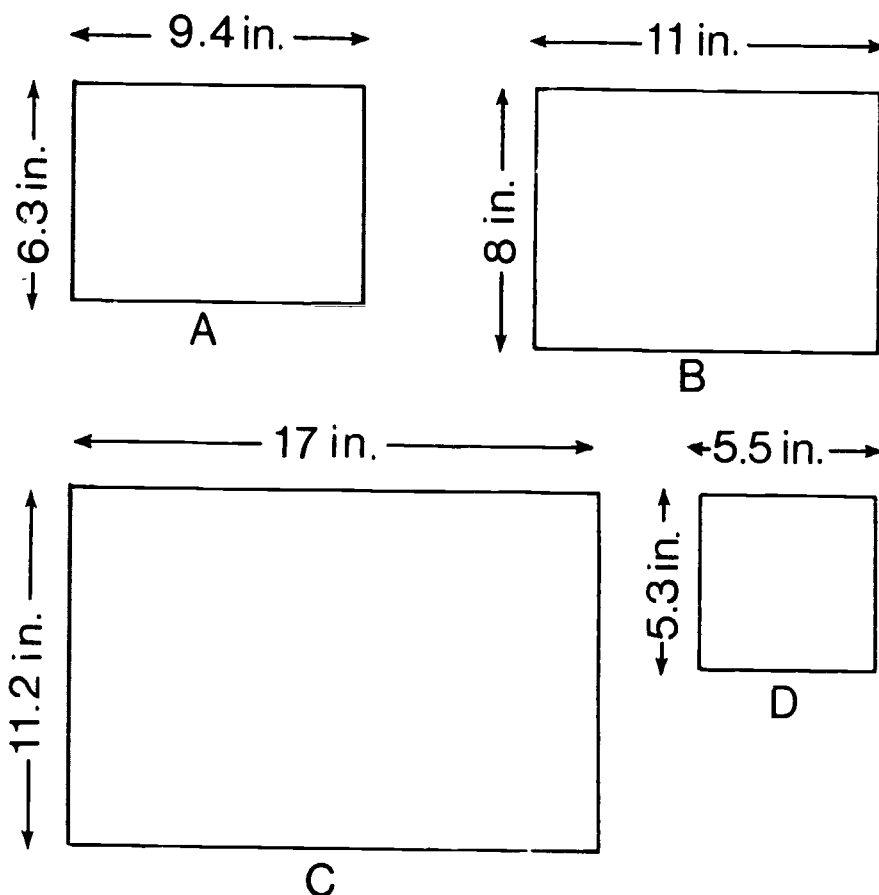


Figure 3-2 Objective 051, exercise 2

- a. Figure 3-2, A—scale set for a 7- by 9-inch field at a 40-inch FFD.
- b. Figure 3-2, B—scale set for a 9- by 11-inch field at a 40-inch FFD.
- c. Figure 3-2, C—scale set for a 13- by 16-inch field at a 72-inch FFD.
- d. Figure 3-2, D—scale set for a 6- by 6-inch field at a 30-inch FFD.

**052. Explain the performance of the beam-defining light and X-ray field compatibility test in terms of wire placement, exposures, collimator adjustment, and compatibility measurements; and evaluate specific test data.**

*Beam-defining light versus X-ray field.* The previously mentioned manual also requires that the "lighted" X-ray field be aligned with the "actual"

X-ray field within 2 percent of the FFD. This requirement is based upon a CR perpendicular to the plane of the film. For example, if the lighted field measures 8 by 10 inches, the short side of the X-ray field must measure between 7.2 and 8.8 inches, and the long side must measure between 9.2 and 10.8 inches.

To check the X-ray field against the lighted field, place a cassette on the table and turn on the collimator light. Adjust the collimator until the lighted field is at least 2 or 3 inches smaller than the film. Place four small pieces of wire, each bent to form a 90° angle, so that the angles correspond to the corners of the lighted field. Measure the borders of the lighted field and record the information. Place some sort of orientation marker on the film so that you can identify the side(s) of the collimator out of adjustment. Make one exposure; then open the collimator to cover the entire film and make another exposure. After processing, measure the sides of the X-ray field and compare them to the measurements of the lighted field. If any side of the X-ray field deviates by more than 2 percent of the FFD, the collimator must be adjusted.

Figure 3-3 is a drawing of a test radiograph. This drawing shows one side of the collimator, AB, to be

out of adjustment. Sides AC and BD of the X-ray field are shorter than the corresponding lighted sides. Whether the collimator meets the required standards depends upon whether sides AC and BD are off more than 2 percent of the FFD. Also notice that the "wires" near corners A and B would not have been seen on the radiograph if the second exposure had not been made. This same test should be made periodically with automatic collimators.

**Exercises (052):**

1. Answer the following questions based on the collimator light, X-ray field compatibility test.
  - a. How should you place the wire pieces on the cassette?
  - b. How many exposures should you make?

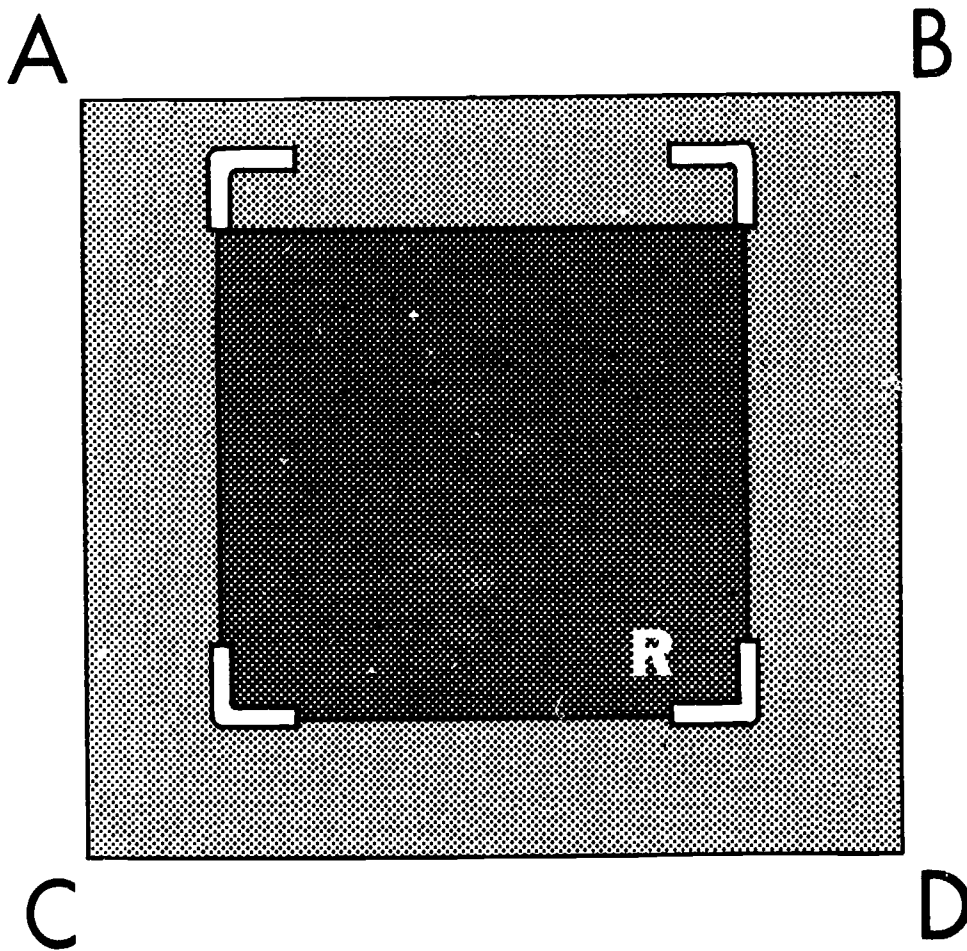


Figure 3-3. Drawing of a radiograph made to check the X-ray field against the lighted field of a collimator.

- c. Why is the second exposure made?
- d. When making the test radiograph, how can you be assured of identifying the sides of the collimator requiring adjustment?
- e. What measurements of the test radiograph should you make to determine the compatibility?
2. In the exercises below, evaluate the test data and determine whether the collimator meets prescribed standards.
- a. Lighted field size—8 by 10 inches at 40 inches FFD; X-ray field size—7 by 10 inches.
  - b. Lighted field size—10 by 10 inches at 40 inches FFD; X-ray field—10 by 10.4 inches.
  - c. Lighted field size—4 by 5 inches at 25 inches FFD; X-ray field size—3.6 by 5.4 inches.
  - d. Lighted field size—14 by 17 inches at 72 inches FFD; X-ray field size—12.2 by 17 inches.

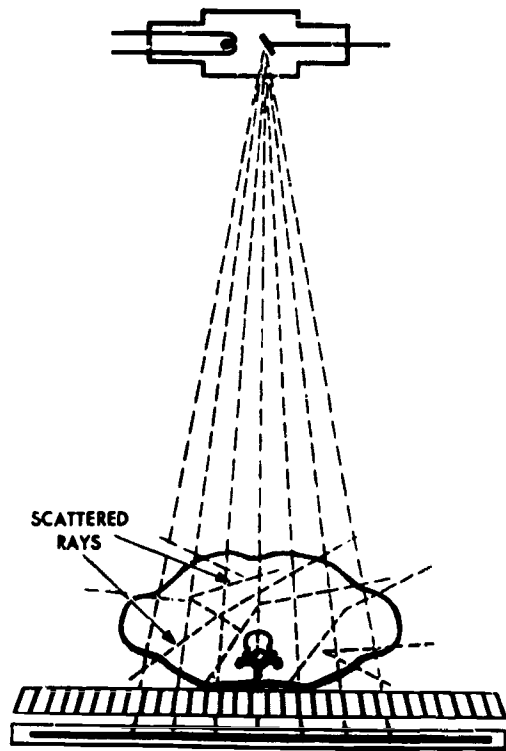


Figure 3-4. Relationships between primary radiation, scattered radiation, and grid strips.

### 3-2. Grids

While the use of a collimator contributes substantially to the reduction of film fog, it by no means solves the problem completely. Considerable film fog still occurs unless an additional device is used.

**053. State the purpose, operation, and application of a grid; and indicate whether or not a grid should be used with specific body parts.**

**Function and Operation of a Grid.** The purpose of a grid is to reduce film fog by absorbing some of the scatter radiation reaching the film. As you know, the grid is placed between the part and the film. Scatter radiation is emitted from many points and in many directions from the patient. Because the greatest portion of the scattered rays strike the lead strips at an angle, most of them are absorbed. Most of the primary radiation, on the other hand, is transmitted by the grid because the individual photons approach the grid from angles corresponding to the angles of the lead strips. Figure 3-4 shows the relationships between the angles of the lead strips and the direction from which primary and scattered radiation approach the lead strips. Since some body parts do not emit enough scattered radiation to significantly fog a radiograph, they do not have to be radiographed with a grid. As a general rule, parts that measure 11-12 centimeters and larger should be taken with a grid. The one exception

is the chest radiograph; it may be taken with or without a grid.

#### Exercises (053):

1. How does a grid reduce film fog?
2. Does a grid absorb all of the scattered radiation?
3. Are all the primary X-ray photons transmitted through the grid?
4. Why is absorption of scattered radiation by a grid greater than its absorption of primary radiation?
5. Match the normal grid application in column B with the appropriate body part in column A. Each application may be used once or more than once.

- Column A**
- \_\_\_\_\_ 1. Skull.
  - \_\_\_\_\_ 2. Wrist.
  - \_\_\_\_\_ 3. Lumbar spine.
  - \_\_\_\_\_ 4. Pelvis.
  - \_\_\_\_\_ 5. Elbow.
  - \_\_\_\_\_ 6. Os calcis.
  - \_\_\_\_\_ 7. Chest.

- Column B**
- a. Grid.
  - b. Nongrid
  - c. Either grid or nong.
  - d.

**054. Differentiate between grid ratio and grid radius.**

**Grid Design.** There are many different grids on the market today. Some are designed to be used under specific conditions. In order for you to use the grid that best fits your particular needs, you need to be aware of the elements of grid design.

**Grid ratio.** The height of a lead strip in relation to the width of the space between two strips is called the grid ratio (see fig. 3-5). Ratio is not directly related to the thickness of the grid or to the number of lines (lead strips) per inch. Consequently, a thin and a thick grid can have the same ratio, and an 80-line grid can have the same ratio as a 100-line grid.

Each grid has a specified ratio, and it can usually be found on the tube side of the grid. Common grid ratios are 4:1, 5:1, 8:1, 12:1, and 16:1. Grid ratio is




Figure 3-5. Examples of grid ratios.

important to you because it affects not only the efficiency of the grid but also the tube alignment.

**Grid radius.** In some grids, the lead strips are parallel to each other; such a grid is called a parallel or unfocused grid. In others, the lead strips are angled, these grids are said to be focused:

a. In an unfocused grid, if imaginary lines parallel to the lateral surfaces of the strips were extended, they would not meet. Figure 3-6 represents an unfocused grid. Note that the strips are perpendicular to the plane of the grid and are parallel with one another

b. When the lead strips in the grid are inclined at progressively larger angles farther from the center strip, the grid is said to be focused. A focused grid has a grid radius, which is the distance from the center of the grid to a point where the planes of the lead strips would meet. Figure 3-7 shows a cross-section of a focused grid, and figure 3-8 shows the grid radius.

The grid radius is important to you because it affects your FFD. A grid usually has a radius specified on its tube side—although on some grids the ratio is specified instead of the FFD range.

**Exercise (054):**

- Match the grid design characteristic in column B with the appropriate statement in column A. Each column B item may be used once or more than once. In addition, both column B items may match a single column A statement.

- Column A**
- \_\_\_\_\_ 1. Affects grid efficiency.
  - \_\_\_\_\_ 2. A focused grid has one
  - \_\_\_\_\_ 3. An unfocused grid has one
  - \_\_\_\_\_ 4. A specified distance.
  - \_\_\_\_\_ 5. Affects FFD.
  - \_\_\_\_\_ 6. Affects tube alignment.
  - \_\_\_\_\_ 7. Pertains to height of a lead strip and interspace.
  - \_\_\_\_\_ 8. Lead strips are not parallel.

- Column B**
- a. Grid ratio.
  - b. Grid radius.

**055. Explain how the number of lines per inch in a grid affects the appearance of a radiograph.**

**Lines per inch.** Grids are available with various numbers of lines per inch. For example, a 12:1 grid is made with either 80 or 100 lines per inch. One difference between them is that the 100-line grid is thinner than the 80-line. The greatest advantage of a grid with many lines per inch is that the lead strips are less visible on the radiograph and therefore interfere less with interpretation. (This, of course, is based on the assumption that the grid is not moved during exposure.) The strips are less visible with more lines per inch for a given ratio because the lead strips are thinner and are not as high. This change in the size of the lead strips reduces the total lead content of the grid. Consequently, at high kV ranges for a given ratio, a grid with many lines per inch (100 vs. 80) improves contrast

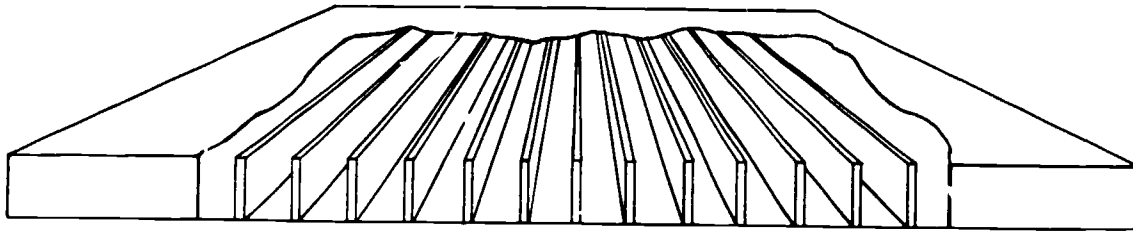


Figure 3-6. Cutaway of an unfocused grid

less than one with fewer lines per inch. When the grid with many lines per inch is used, the energy level of the scattered radiation is high enough to penetrate the lead strips and fog the film.

**Exercises (055):**

1. If two radiographs of the same part are made, one using 8:1, 80-line and the other using 8:1, 100-line stationary grids, on which radiograph would the lead strips be more visible? Why?
2. How does the number of lines per inch of a grid affect radiograph contrast? Why?

**056. Differentiate between the construction and the uses of a linear and a crossed grid.**

*Arrangement of lead strips.* Grids are made with the lead strips in either a linear or a crossed pattern:

a. A linear grid is one with all the lead strips running parallel with each other. Most grids in X-ray tables are linear, and the strips run longitudinally. Linear grids are also available in grid cassettes and as regular portable grids. The directions of the lead strips with respect to the longitudinal axis of the X-ray table, grid cassette, and portable grid are shown in figure 3-9.

b. A crossed grid is made with two sets of lead strips arranged as shown in figure 3-10. Crossed grids are usually not found in X-ray tables used for general radiographic work.

There are certain advantages and disadvantages to using both linear and crossed grids. A linear grid permits virtually unlimited tube angles—if the angle is in a direction parallel to the length of the strips. The tube can be tilted in a direction across the lead strips, but if it is, the angle must be small to prevent loss of density due to absorption of primary radiation. Figure 3-11 shows how two different tube angles, one approximately parallel with the lead strips and the other approximately at right angles to the strips, affect the transmission of photons through a grid.

Crossed grids are generally used in special procedures using biplane techniques. Since a crossed grid is actually made up of two superimposed linear grids, its effective ratio is about twice its nominal ratio. For example, an 8:1 crossed grid has an effective ratio of about 16:1.

**Exercise (056):**

1. Match the grid in column B with the appropriate statement or phrase in column A. Each column B item may be used once or more than once. In addition, both column B items may match a single column A item.

Column A	Column B
— 1. In X-ray tables.	a. Linear.
— 2. In grid cassettes.	b. Crossed.
— 3. Could be used with an angled tube	
— 4. Has higher effective ratio.	
— 5. Use is more limited.	
— 6. Portable grid.	

057. Identify true and false statements pertaining to the purpose, operation, and exposure requirements of Bucks; and correct or explain the false statements.

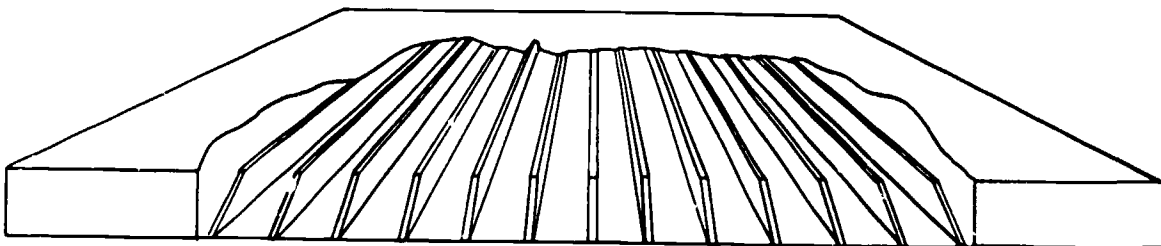


Figure 3-7. Cutaway of a focused grid.

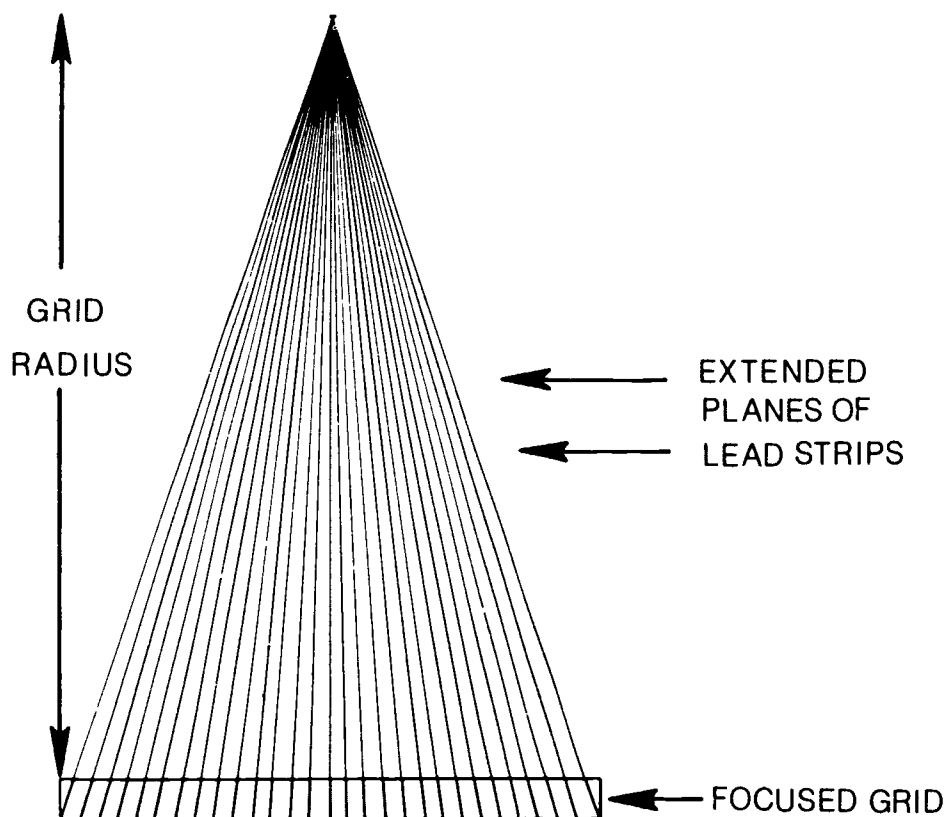


Figure 3-8. Grid radius.

**Grid Movement.** As you know, if the patient moves during an exposure, the part being radiographed is blurred. If movement is considerable and the part is small enough, the part is completely obliterated. Such is the case when a grid is used in a Potter-Bucky diaphragm, a device named after its inventors, which moves the grid during exposure. Movement of the grid blurs out the lead strips that would otherwise appear on the film with a stationary grid. Grid lines, as you know, can interfere with interpretation of a radiograph.

**Bucky operation.** In order for a Potter-Bucky diaphragm (hereafter called a Bucky) to prevent grid lines on a radiograph, movement of the device or grid must satisfy the following three requirements: (1) motion must be smooth and even, (2) movement must start before the exposure, and (3) movement must continue until after the exposure stops.

**Types of Bucky.** Bucky's can be classified as *moving*, *reciprocating*, or *recipromatic*.

A moving Bucky is one in which the grid moves only in one direction during a single exposure. It is then manually reset for the next exposure. The speed of movement is determined by a timer, which also is manually set. When using this type of Bucky, be sure to reset the device before each exposure. Also, set the Bucky timer slightly longer than the actual exposure in order to insure that grid movement occurs for the duration of the exposure. Some portable

Bucky's are of this type and may be found in field-type hospitals or some cystograph units. Minimum exposure time is about 1/10 second.

A reciprocating Bucky continually moves across the table and back for the duration of the exposure. Movement in one direction is slower than in the other. This type of Bucky does not have to be manually set. Minimum exposure time is also about 1/10 second.

A recipromatic Bucky moves at the same rate of speed in both directions across the X-ray table. This type permits exposures in the microsecond range and is the one you probably have in your unit.

**Exposure compensation.** When you are changing from one grid ratio to another, techniques are compensated due to the increased absorption of both primary and scatter radiation. Although a constant factor cannot be given, a change of 5 percent of the applied kVp per ratio change is an acceptable starting point. (See fig. 5-8, later in this book, which can be used as a guide.) The exact change will depend on the kVp range, the number of lines per inch, and the type of interspace material.

**Exercises (057):**

Indicate whether the following statements are true or false. If you indicate false, explain your answer.

T F 1. The purpose of a Bucky is to prevent unwanted grid lines on a radiograph.



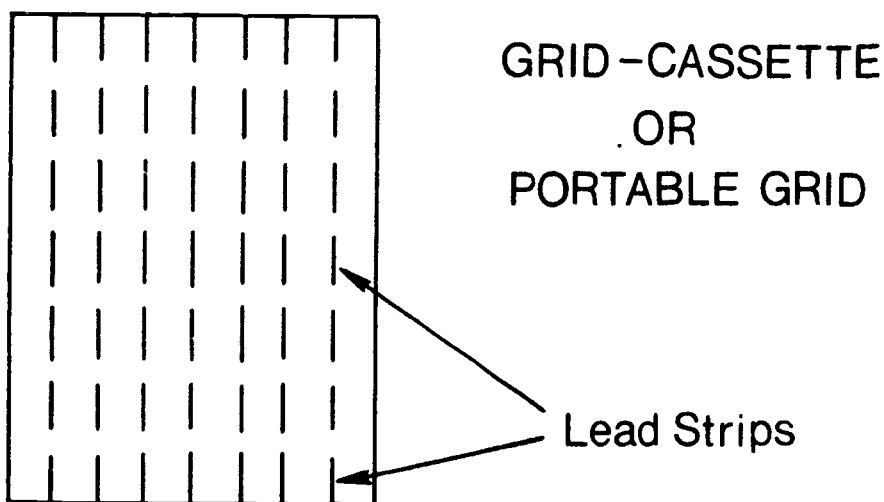
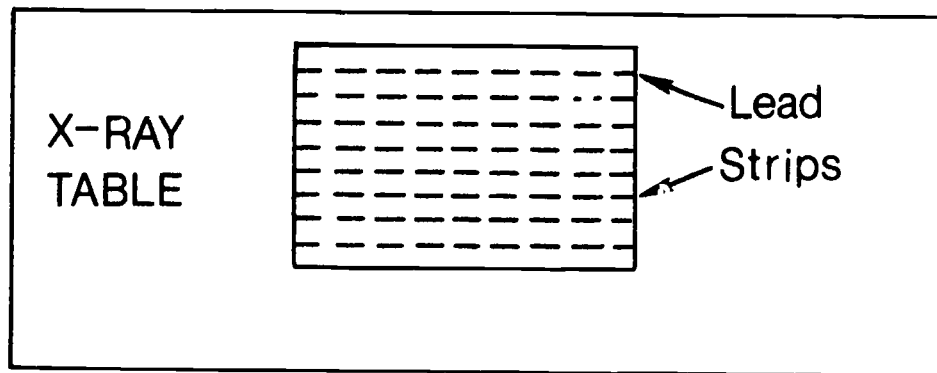


Figure 3-9. Direction of the lead strips in a linear grid.

- T F 2. Duration of movement is an important factor in the operation of a Bucky.
- T F 3. A reciprocating Bucky permits the shortest exposure time.
- T F 4. A reciprocating Bucky must be manually reset before each exposure.
- T F 5. The timer is manually set on a recipromatic Bucky.
- T F 6. All Bucky's must begin movement before the exposure in order to prevent grid lines.
- T F 7. With Bucky exposures, the X-ray tube is not always aligned to the center of the grid.
- T F 8. A 5-percent change in kVp is an acceptable starting point when you are changing from one grid ratio to another.

058. Given particulars pertaining to four pairs of grids, select the most efficient grid from each pair and explain why the selected grid is more efficient.

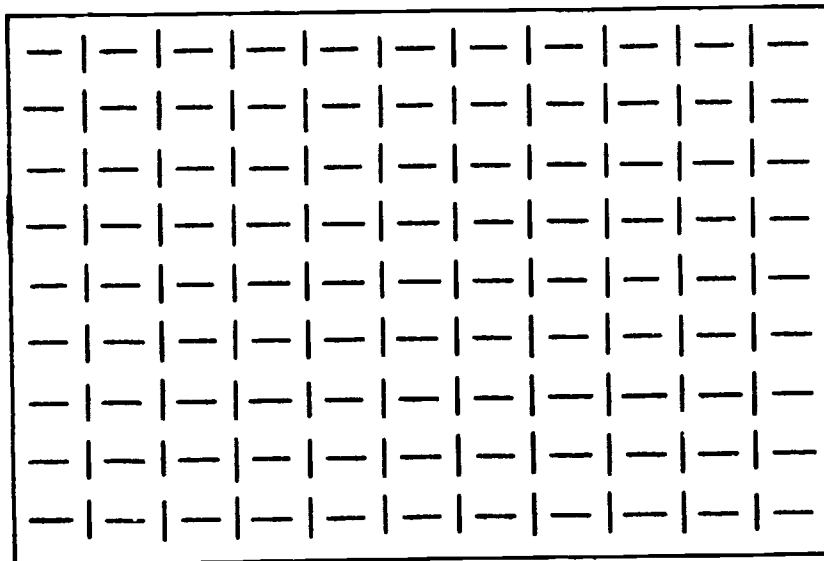


Figure 3-10. Direction of the lead strips in a crossed grid.

**Grid Efficiency.** Grid efficiency refers to the amount of scatter radiation absorbed compared to the amount of primary radiation absorbed. Ideally, a grid would absorb all of the scatter and no primary photons. But due to the lead content in a grid, a portion of the primary beam is also absorbed. Consequently, grids are not 100 percent efficient.

*Effect of grid ratio on grid efficiency.* As a general rule, the higher the effective ratio of a grid, the better the absorption of scatter radiation. This increase in scatter absorption is shown in figure 3-12, which shows lead strips from two grids with different ratios. Notice that the angle of emission, by which scattered photons can reach the film between the lead strips, is larger with the low ratio grid. Consequently, the smaller ratio grid absorbs fewer photons. Also, notice

a scattered photon must penetrate more lead strips to reach the film through the high ratio grid; consequently, the photon has a better chance of being absorbed.

*Effect of lines per inch on grid efficiency.* Earlier in this section, we briefly discussed how the number of lines per inch affects the contrast on a radiograph. We said that the higher the lines per inch for a given ratio, the lower the contrast (long scale), because less scatter is absorbed due to the decrease in lead content. Therefore, the number of lines per inch itself affects grid efficiency. Another factor that affects the efficiency of a grid with many lines per inch (microline grid) is the kVp. If you use high kVp with a microline grid, the efficiency is reduced even more because some scattered photons produced by high kVp have

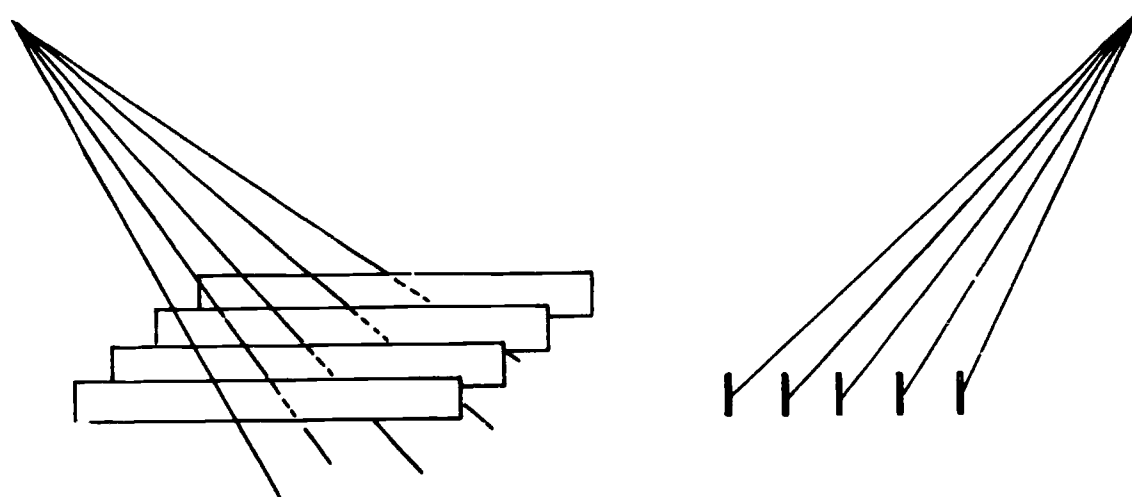


Figure 3-11. Relationship between direction of tube angle and direction of lead strips, showing the difference between the absorptions of primary radiation.

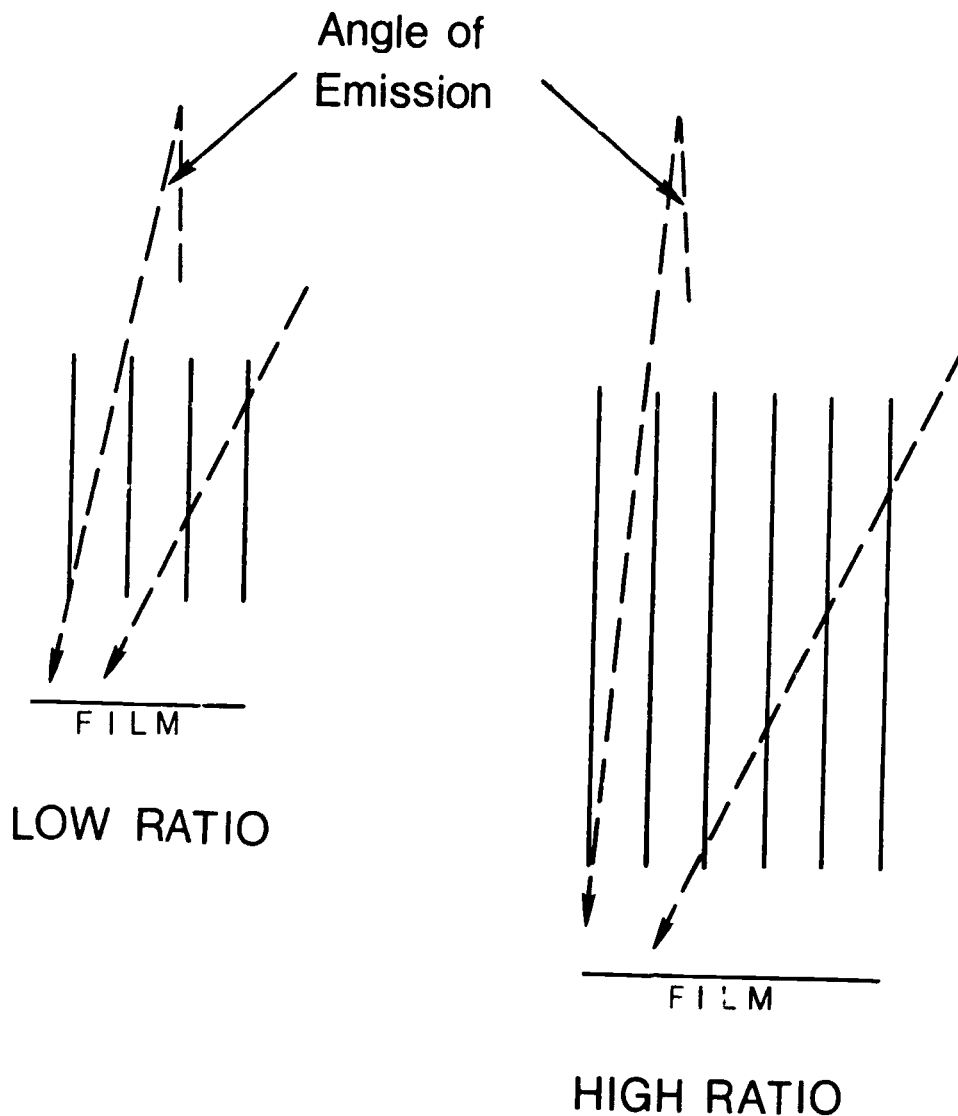


Figure 3-12. Effect of grid ratio on absorption of scattered X-ray photons

high energies. Since the lead strips in a microline grid are thinner, they are more likely to be penetrated by the higher energy, scattered photons. Thus, the grid absorbs fewer scattered photons and is less efficient.

**Exercises (059):**

In the exercises below, select the more efficient grid of the two described, if all other factors are equal. Explain why the grid you select is more efficient.

1. Grid A—nominal ratio 5:1; linear.  
Grid B—nominal ratio 5:1; crossed.
2. Grid A—8:1.  
Grid B—12:1.

3. Grid A—microline; used at 70 kVp.  
Grid B—microline; used at 120 kVp.

4. Grid A—100-line.  
Grid B—133-line.

**059. Indicate the effect and basic concepts of lateral decentering of the X-ray tube, and specify the maximum decentering allowable for specific grids.**

**Problems of Grid Exposure.** Four major problems that technicians experience when using grids are:

(1) lateral decentering—the X-ray tube is not aligned directly in the center of the transverse axis of the grid; (2) distance decentering—the tube is not positioned at the proper distance from the grid; (3) a combination of (1) and (2) above; and (4) off-angle alignment—the tube is improperly angled with respect to the direction of the lead strips. In all of these, there is a reduction in transmission of primary radiation due to increased absorption by the lead strips.

*Lateral decentering.* Lateral decentering is a problem frequently encountered in using a portable grid, basically because there is no mechanical means of centering the tube to the film. Lateral decentering causes an even loss of density over the entire film. Transmission of primary radiation begins to decrease with any amount of lateral decentering. The specific degree of reduction depends upon the grid ratio, the grid radius, and the amount of decentering.

The higher the grid ratio, the more critical is the tube alignment. With all 16:1 grids, tube centering is so critical that 1 inch of lateral decentering is enough to reduce primary transmission to the point that the radiograph is too light for interpretation. Consequently, a 16:1 grid should be used only in places where lateral decentering is not a problem, such as in the X-ray table.

The shorter the grid radius, the more critical is the tube alignment. For example, a grid with a radius of 40 inches absorbs approximately twice as much primary radiation as does a grid with a radius of 72 inches (assuming that the two grids have equal ratios and equal amounts of decentering).

As the amount of decentering increases, so does the absorption of primary radiation. Table 3-1 shows the maximum amount of decentering that still transmits about 80 percent of the primary radiation—enough to produce a diagnostic radiograph in most cases.

**Exercises (059):**

1. An X-ray tube is laterally decentered over a grid. How does this condition affect the appearance of the radiograph?
2. Two radiographs are made, using 8:1 and 5:1 grids, with 1 inch of lateral decentering in each radiograph. Which radiograph shows less loss of radiographic density if all other factors are equal?
3. How does the grid radius affect radiographic density in the presence of lateral decentering?
4. How much lateral decentering is permitted when you are using an 8:1, 40-inch focused grid?
5. How much lateral decentering is permitted when you are using a 16:1, 72-inch focused grid?
6. Which of these two grids permits the most lateral decentering without significant loss of density—8:1, 40-inch focused, or 5:1, 72-inch focused?

GRID RATIO	GRID RADIUS	MAXIMUM DECENTERING (IN INCHES)
5:1	40 (100 cm)	2 (5 cm)
	72 (180 cm)	3 (8 cm)
8:1	40 (100 cm)	1 (2.5 cm)
	72 (180 cm)	2 (5 cm)
12:1	40 (100 cm)	0
	72 (180 cm)	1 (2.5 cm)
16:1	40 (100 cm)	0
	72 (180 cm)	0

**TABLE 3-1**  
**MAXIMUM LATERAL DECENTERING WITHOUT SIGNIFICANT LOSS OF PRIMARY RADIATION**

**060. Relate focus-grid distance to grid radius and radiographic density.**

*Distance decentering.* Distance decentering refers to the use of a focus-grid distance that is more or less than the grid radius. The result on the radiograph is a reduction in the primary radiation toward the lateral edges of the beam, with little or no effect on the central portion of the primary beam. The specific loss of primary radiation depends upon the amount of decentering, the grid ratio, and the direction (near or far) of the decentered tube.

The loss of primary radiation increases as the distance between the grid radius and the X-ray tube increases. There is a certain amount of tolerance for this type of decentering. The tolerance depends partly upon the grid ratio. A grid with a high ratio will not tolerate as much distance decentering as will a grid with a low ratio. Also, there is more tolerance if the distance from the X-ray tube to the grid is greater than the grid radius; less tolerance, if the distance from the X-ray tube to the grid is less than the grid radius.

When we speak of "tolerance," we mean the maximum amount of decentering that still produces sufficient density to produce a diagnostic radiograph. Some grids have a specified focal range, such as 30 inches to 40 inches. You can use any focus-grid distance in that range without experiencing significant loss of primary radiation.

Some grids do not come with a specified focal range. Only the grid ratio is specified. In cases such as this, you should get in touch with the manufacturer and obtain his recommendations. However, you can determine the relative tolerance of various grids by making experimental exposures and determining at what focused grid distances significant loss of primary radiation (density) occurs.

**Exercises (060):**

1. If in making a radiograph, you used a 35-inch focus-grid distance and a grid with a focal range of 36 to 44 inches, how would the appearance of the radiograph be affected?
2. A 40-inch focused grid was used when two radiographs were made. A 48-inch focus-grid distance was used with one radiograph, and a 32-inch focus-grid distance was used with the other. Which radiograph shows the greater change in appearance if all other factors were equal? Explain.

3. How does grid ratio affect the loss of primary radiation due to distance decentering?

4. How can you determine the focal range of a grid if it is not specified?

**061. Given descriptions of the density distribution of two radiographs, specify the cause of the difference in distribution.**

*Lateral decentering plus distance decentering.* When lateral and distance decentering occur together, they are unique in that they produce a radiograph with a loss of density on only one lateral margin of the film. If the X-ray tube is misaligned in both directions and the focus-grid distance is greater than the grid radius, the lateral margin of the film beneath the tube is underexposed. If the focus-grid distance is less than the grid radius, the lateral margin of the film remote from the tube is underexposed. See figure 3-13.

**Exercises (061):**

1. A radiograph shows uneven density. The density on side A of the radiograph is greater than the density on side B. What decentering probably caused the variation?
2. A radiograph shows uneven density. The density on side A of the radiograph is less than the density on side B. What decentering probably caused the variation?

**062. Specify the maximum tube angle allowed across the grid strips for various grids, and describe the appearance of the radiograph if the maximum angles are exceeded.**

*Off-angle alignment.* If the X-ray tube is excessively angled across the lead strips, there is an even, noticeable loss of density over the entire film. The amount of loss depends upon the degree of the angle and grid ratio. The maximum (approximate) angles that still produce adequate film exposure for specific grids are as follows: 5:1, 8°; 8:1, 6°; 12:1, 3°; and 16:1, 1°.

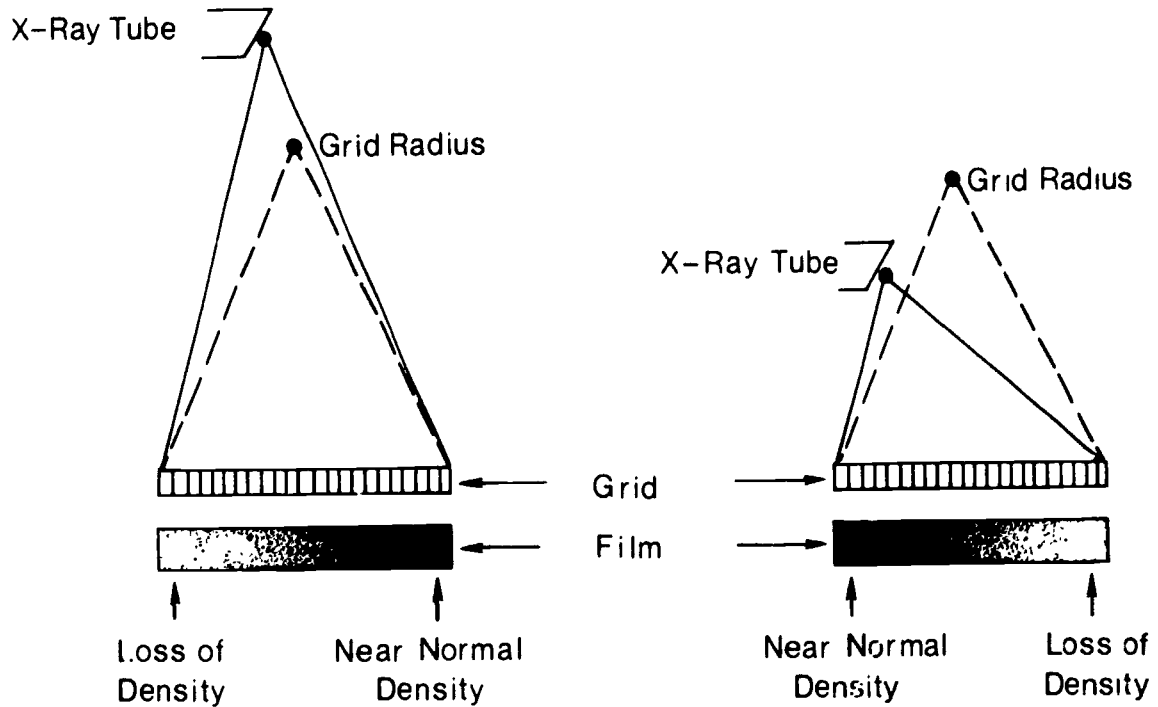


Figure 3-13. Effect of lateral decentering plus distance decentering or film density.

**Exercises (062):**

1. What maximum tube angles are permitted across the grid strips for the following grids?
  - a. 5:1.
  - b. 8:1
  - c. 12:1.
  - d. 16:1.

2. If the angles indicated in exercise 1 above are exceeded, what is the result on the radiographs?

## Film, Film Holders, and Darkroom

AS YOU GAIN experience and advance in grade, you become more involved in the selection of film and film holders used in your department. In this chapter we shall present some general information about these two items to assist you in your selections, as well as other information to help you use them effectively.

Our discussion of darkrooms will also cover the chemistry, evaluation, and the standardization of processing systems.

### 4-1. X-Ray Film

In this section we shall discuss the composition of an X-ray film, the types of film, and film characteristics.

**063.** Given a list of statements pertaining to the composition of an X-ray film, match each with the appropriate film layer.

**Composition of an X-ray Film.** An X-ray film consists of a base, subcoating, an emulsion, and a protective coating on both sides of the film. (See fig. 4-1.)

**The base.** In the past, the base of X-ray film consisted of cellulose acetate. Today, film manufacturers use polyester. Polyester as base material provides more strength in thinner form, has less tendency to curl, and is compatible with the temperatures used in 90-second processors.

**The subcoating.** The subcoating is a thin layer of adhesive material used to attach the emulsion to the film base.

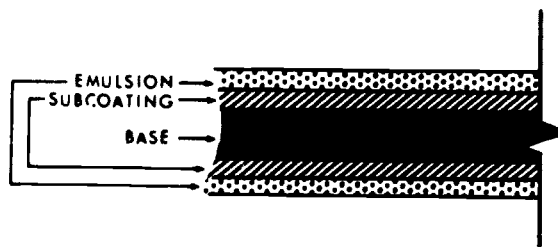


Figure 4-1. Cross section of an X-ray film.

**The emulsion.** Basically, the emulsion is composed of gelatin and silver bromide crystals. The latent and visible images are formed in the film emulsion.

**The protective coating.** A thin, transparent material is coated over the emulsion for protection during handling and storage.

### Exercise (063):

1. Match the X-ray film layer in column B with the appropriate statement in column A. Each column B item may be used once or not at all.

<i>Column A</i>	<i>Column B</i>
_____ 1. Located between the emulsion and base.	a. Base (polyester)
_____ 2. Helps prevent damage to the emulsion	b. Subcoating.
_____ 3. Can withstand high-temperature processing	c. Emulsion
_____ 4. Gelatin and silver bromide	d. Gelatin.
	e. Protective coating

**064.** Given a list of statements pertaining to the three types of X-ray films, match each with the appropriate film.

**Types of X-ray Film.** Many different types of film are used in radiology, but they can be combined into two major groups: screen and nonscreen. These two groupings include every film type except dental, which has a few peculiarities of its own. We shall include dental films in our discussion, for there will be times when you will use them.

**Screen film.** There are basically two types of screen film manufactured today: (1) film sensitive to the blue-violet light emitted from calcium tungstate intensifying screens and (2) film sensitive to the greenish light emitted by rare earth intensifying screens.

The purpose in using either system is to amplify the effect of X-radiation. Screen film contains a smaller amount of silver than does nonscreen film; this factor permits screen film to be processed faster than nonscreen film.

a. Blue-sensitive film. This film has been in use for many years. The primary photographic response is to

the ultraviolet and blue-violet light emitted by the calcium tungstate crystals or lead barium sulphate used in intensifying screens. The film can be processed manually or in an automatic film processor. The Wratten 6B, or an equivalent, is the recommended safelight filter. This film may be used with some of the rare earth intensifying screens. However, the full benefit of the rare earth system—namely, reduced exposure—is not realized.

b. Green-sensitive film. The green-sensitive film is specifically designed to be used with rare earth intensifying screens. Its photographic response is in the green portion of the visible spectrum. It should be processed only in an automatic processor using standard rapid-processing chemicals. Since the photographic response is different, safe lighting must be modified. A GS-1 or equivalent filter is recommended.

*Nonscreen film.* Nonscreen film is designed to be especially sensitive to the direct action of X-rays. When used in this manner, it provides excellent radiographic detail. Generally speaking, it is intended for use only on smaller body parts, such as the extremities and breasts. In actual practice, nonscreen films are usually used in mammography, and screen films are used on extremities. Since a nonscreen film has a larger amount of silver, it will have a higher degree of contrast in the lower exposure ranges. Since the emulsion is thicker in nonscreen films, they require a longer developing and fixing time. Also, because of the thick emulsion, nonscreen films should not be used with intensifying screens because the visible light emitted by the screens cannot penetrate and completely expose the entire emulsion layer.

*Dental film.* This brings us to dental film, which—as we mentioned earlier—has some peculiarities. Dental films are simply modifications of medical X-ray film. They are wrapped in moistureproof, lightproof packets; have emulsion on one side only; and are classified as periapical (used for examining the roots of the teeth), interproximal (for locating cavities between teeth), and occlusal (for examining larger areas). Specifically, dental film has a thinner base and emulsion than does medical X-ray film, and it is supplied in a packet with a lead-foil backing. The amount of exposure required is similar to that of nonscreen film.

#### Exercise (064):

- Match the type of film in column B with the information in column A. Each column B item may be used once or more than once.

<i>Column A</i>	<i>Column B</i>
— 1. Used in mammography.	a. Blue-sensitive film.
— 2. Should not be processed manually.	b. Green-sensitive film.
— 3. Provides greater detail for smaller parts.	c. Nonscreen film.
— 4. Can be used with or without intensifying screens.	d. Dental film.

- 5. Has a thicker emulsion
- 6. Requires longer exposure.
- 7. Wratten 6B safelight filter recommended.
- 8. Used for a lateral lumbar spine
- 9. GS-1 safelight filter recommended.
- 10. Has emulsion on one side only and has a lead-foil backing.

**065. Define "film density"; and given three percentages of light transmitted through a radiograph, specify the numerical density values.**

**Film Characteristics.** All X-ray films are not the same—that is, they differ in such properties as speed and contrast. The best way to compare these properties is to refer to the characteristic curve, which can be obtained from the manufacturer. We shall discuss some characteristic curves, but first let's review film density.

*Density.* Density, as you know, is the ratio of the light transmitted through an X-ray film to the light incident to the film. The less the light transmission, the higher the density.

When we look at an X-ray film we usually think of density in relative terms. We may think of doubling the density or halving the density with little thought of what the specific density measurement is. By using a densitometer, we can measure the actual density on a radiograph.

Density is usually expressed in logarithmic values. While you do not need to understand logarithms, you should be familiar with the specific density values. If a densitometer shows that the density of a particular portion of a radiograph is 1.0, 10 percent of the incident light is transmitted through the film. A density of 2.0 means that 1 percent of the light is transmitted. A density of 3.0 shows that 0.1 percent of the light is transmitted.

#### Exercises (065):

- What is "film density"?
  - 10 percent.
  - 1 percent.
  - 0.1 percent.
- What specific density is present if each of the following percentages of incident light is transmitted through a radiograph?
  - 10 percent.
  - 1 percent.
  - 0.1 percent.



066. Given a characteristic curve of an X-ray film, determine what mAs changes are required to produce specific changes in the density of a radiograph.

Now let's examine a typical characteristic curve and see how you can determine mAs changes. Figure 4-2 show a characteristic curve. As you can see, density is plotted on the vertical axis and the log relative exposure on the horizontal axis. Log relative exposure represents the mAs required to produce a specific change in the density. An increase of 0.3 on the exposure scale represents an approximate doubling of the mAs, and a decrease of 0.3 represents an approximate halving of the mAs. For example, if 10 mAs (0.3 on exposure scale) produces a density of 0.3, 20 mAs

(0.6 on exposure scale) produces a density of 0.8. As you've probably noticed, the mAs was doubled; however, the film density almost tripled. Whether the density change is proportional to the change in mAs depends on where you are on the curve. In the preceding example, the original density fell at the "toe" end of the curve. However, if the original density falls in the relatively straight-line portion of the curve, then changes become more proportional. For example, a relative exposure of 0.6 produces a density of 0.8; by doubling the mAs, raising log relative exposure to 0.9, the density is 1.6. Keep in mind that the log relative exposure scale is relative. You can apply any mAs value to the scale. If 100 mAs produces a density of 0.8, then 200 mAs is required to produce a density of 1.6, according to the curve in figure 4-2.

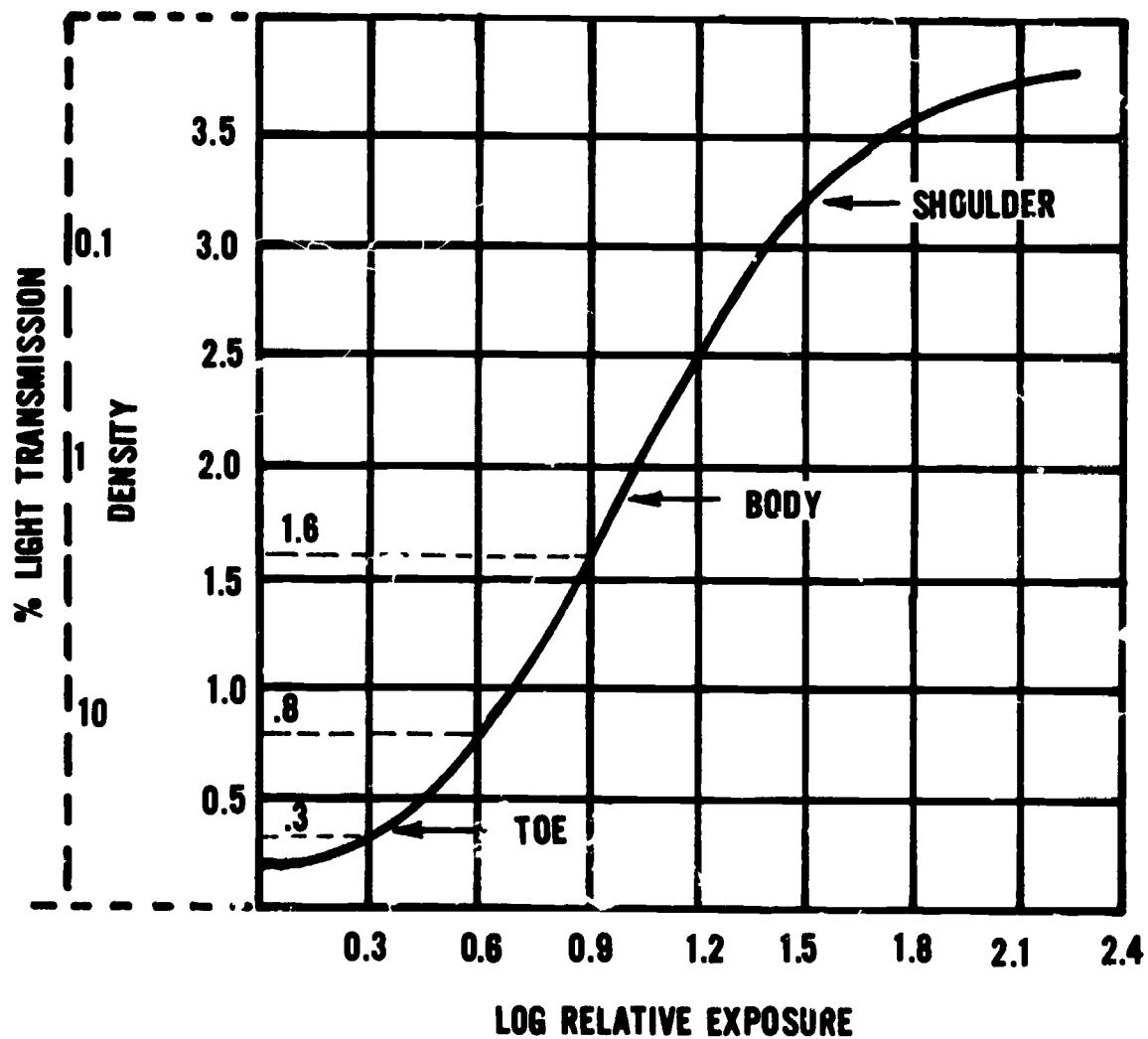


Figure 4-2. A characteristic curve.

**Exercises (066):**

Using the characteristic curve in figure 4-3, complete the following exercises.

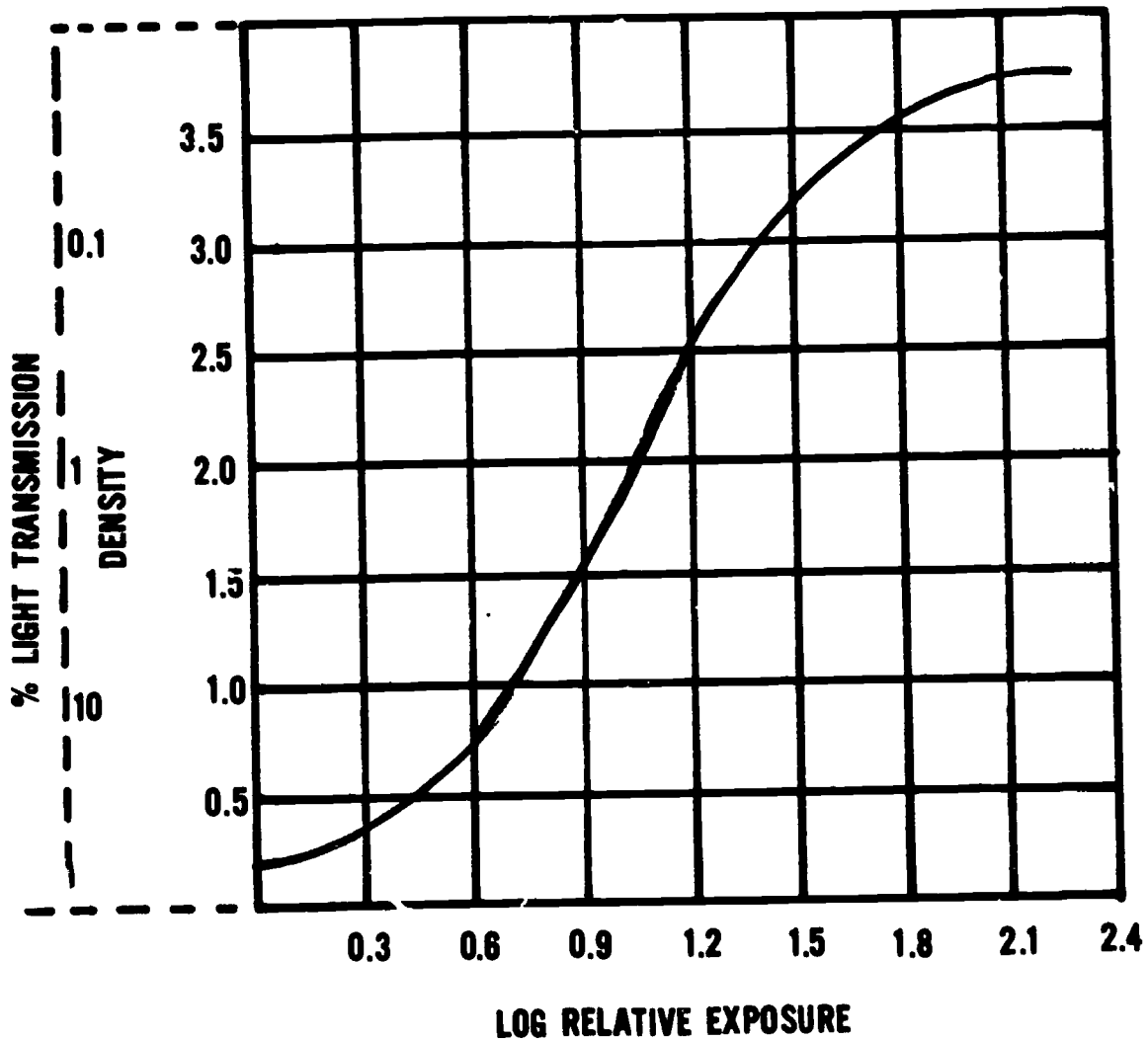


Figure 4-3. Objective 066, exercises 1 and 2.

1. 0 mAs produces a film density of 1.0, how much mAs is required to produce a density of 2.0?
2. If 30 mAs produces a film density of 1.0, how much mAs is required to produce a density of 0.5?

**Background density.** All X-ray films have a certain amount of background density, also called inherent film fog. This density is present after processing even if the film is unexposed. To determine the background density of a film, refer to the toe of the characteristic curve and note the density at zero exposure. The film represented in figure 4-2 shows a background density of approximately 0.2. As a rule, a background density of over 0.2 is excessive.

**Film speed.** The response of a radiographic film to exposure is called film sensitivity or film speed. A "fast" film requires less exposure to produce a specific density than does a "slow" film. Since a fast film requires less exposure, it permits shorter exposure times, subjects the X-ray tube to fewer heat units per exposure, and reduces the radiation dose to the

067. Given characteristic curves of three different X-ray films, evaluate them in terms of background density, film speed, contrast, and exposure latitude.

patient. Fast films, however, usually sacrifice some detail, due to the increased size of the silver bromide crystals in the emulsion, which causes a "grainy" appearance on the radiographs.

Film speeds are not expressed in numerical values; therefore, you must compare the relative speeds of different films by referring to the characteristic curves. The relative speed of a film is indicated by the left-to-right position of the characteristic curve on the graph. The farther to the left the curve is located, the faster the speed; the farther to the right, the slower the speed.

*Contrast and exposure latitude.* You can determine the relative film contrast and exposure latitude also by evaluating the characteristic curves. Both are indicated by the slope of the curve. A more vertical slope indicates higher contrast and less exposure latitude, and a more gradual slope indicates lower contrast and more exposure latitude.

**Exercises (067):**

Complete the following exercises based on the three characteristic curves shown in figure 4-4.

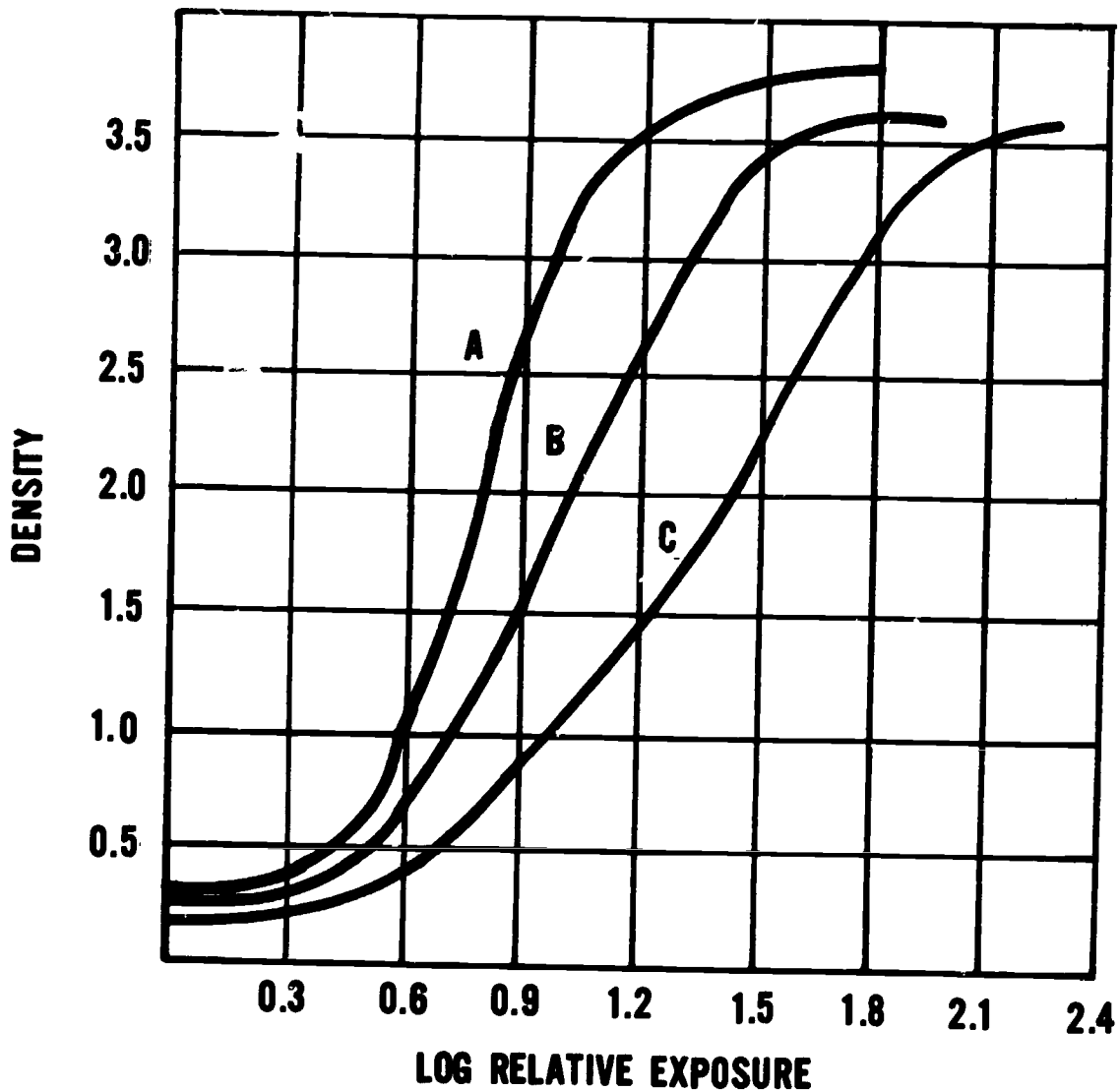


Figure 4-4. Objective 067, exercises 1 through 8.

1. Which film has the highest background density?
2. Which films, if any, have too much background density?

3. Which film is the slowest?
4. Which film would expose your patients to the least radiation?
5. Which film would cause the most strain on your X-ray tube?
6. Which film exhibits the highest contrast?
7. Which film provides the most exposure latitude?
8. Which film sacrifices the most detail?

#### 4-2. Intensifying Screens

Our discussion of intensifying screens includes their purpose, construction, significance of the phosphor, and finally the procedures for performing screen-film contact and screen lag tests.

**068. State the purpose of intensifying screens, list the four layers of an intensifying screen, and give the purpose of each.**

**Purpose of Intensifying Screens.** As you know, intensifying screens reduce the exposure necessary to produce a desired density on a radiograph. They reduce the exposure by converting the radiant energy (X-ray photons) to visible light, which then exposes the X-ray film.

**Construction of Screens.** An intensifying screen consists of four layers of material—the base, the reflecting material, phosphor, and the protective coating.

**Base.** The base is a sheet of cardboard or similar material that supports the rest of the screen.

**Reflecting material.** The reflecting material is a thin layer of substance that reflects the light photons emitted away from the film back toward the film.

**Phosphor.** The phosphor is a material that emits visible light when exposed to X-rays.

**Protective coating.** The protective coating is a thin layer of plastic that prevents the buildup of static, protects the phosphor, and permits the screen to be cleaned without damage to the phosphor.

#### Exercises (068):

1. What is the purpose of intensifying screens?
2. List the four layers of an intensifying screen and state the purpose of each layer.

**069. State the significance of the phosphor layer, and explain factors that determine screen speed and detail in regular intensifying screens.**

**Phosphor Significance.** The layer of phosphor in a regular intensifying screen can be made from crystals of calcium tungstate, barium lead sulfate, or barium strontium sulfate. When X-ray photons strike these crystals, the crystals emit visible light in the blue-violet range of the spectrum. X-ray films designed for use with regular intensifying screens are sensitive to this blue-violet light.

**Screen speed.** Depending upon the size and the thickness of the layer of the crystals, intensifying screens are classified according to their speeds. The speed reflects the sensitivity of the phosphor layer to X-radiation. Slow, medium, and fast are common screen speeds, although different manufacturers apply other terms to their screens. The faster the screens, obviously the less exposure needed to produce a given density on a radiograph. As a rule, large crystals and a thick layer provide a fast screen, while small crystals and a thin layer reduce the speed of the screen.

**Detail.** On the surface it would seem that high-speed screens are best, since they permit shorter exposure times, less strain on the X-ray tube per exposure, and less radiation to the patient. However, these advantages are realized only by sacrificing detail on the radiographs. All intensifying screens reduce the detail on a radiograph below that obtained from direct film exposure, and this reduction in detail is increased as the speed of the screens increases.

Notice in figure 4-5 that we have shown illustrations of two layers of crystals of different thicknesses. Notice that the visible light from some of the phosphor crystals from the thick layer is more diffused because the crystals are farther from the film. The greater diffusion results in more overlapping of the areas under exposure and, consequently, less image clarity.

Figure 4-6 also compares the diffusion of the light, but between large and small crystals. There is more overlapping of the light from the large crystals because they emit more light than the small crystals.

#### Exercises (069):

1. Describe the connection between screen spectral emission and film sensitivity.

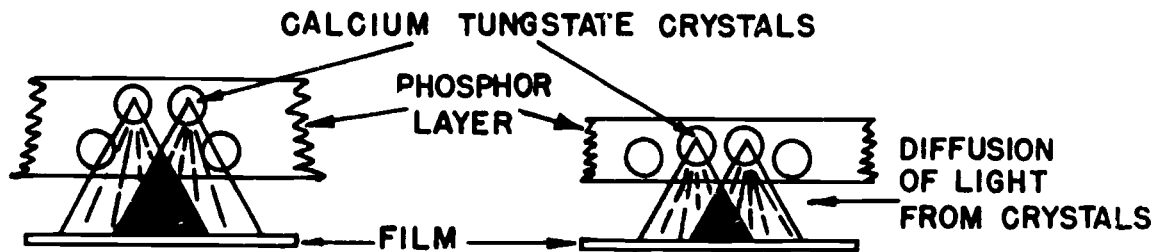


Figure 4-5. Comparison of light diffusion between thick and thin layers of screen phosphor.

2. Of the three screen speeds listed in the text, which one requires the least exposure for a specific examination? The highest exposure?
3. Of the three screens listed in the text, which one provides the best detail? The least?
4. Explain the relationship between crystal size, layer thickness, and detail.
5. Why do crystal size and layer thickness affect detail?

obtain maximum benefit, specially designed X-ray film sensitive to this green light should be used. NOTE: Gadolinium and lanthanum belong to a group of oxides that are termed "rare earth metals"; hence, the term "rare earth."

The crystals used absorb more of the incident radiation and have a higher conversion factor to light than calcium tungstate. Generally speaking, the rare earth system is twice as fast as a comparable calcium tungstate system. Figure 4-7 shows the relative speed response of a rare earth (RE) system vs. a high-speed calcium tungstate (CT) system as a function of kV. The difference in the speed vs. kilovoltage response is a result of the differences in the absorption of the X-ray beam by the rare earth phosphors. In other words, they have a lower absorption factor at kV levels below 70-75 kV and are not as fast.

Since the rare earth system is faster, mAs values can be reduced, allowing for less exposure time to reduce motion, a smaller focal spot to increase detail, or a decrease in kVp to increase subject contrast.

070. Indicate whether statements correctly reflect the major differences between regular and rare earth imaging systems.

The phosphor layer in rare earth intensifying screens is a blend of gadolinium and lanthanum. When X-ray photons strike these crystals, the crystals emit visible light in the green range of the spectrum. To

#### Exercises (070):

Indicate whether each of the following statements is true or false. If you indicate false, correct the statement.  
T F 1. The rare earth system is approximately twice that of a regular high-speed system.

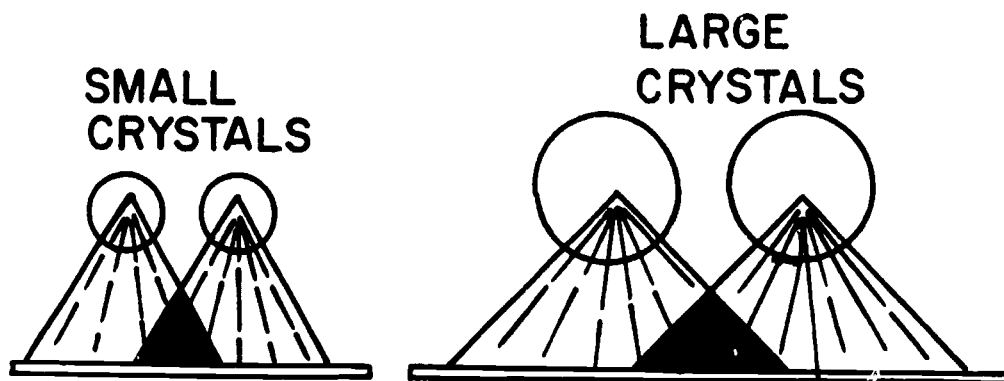


Figure 4-6. Comparison of light diffusion between large and small phosphor crystal.

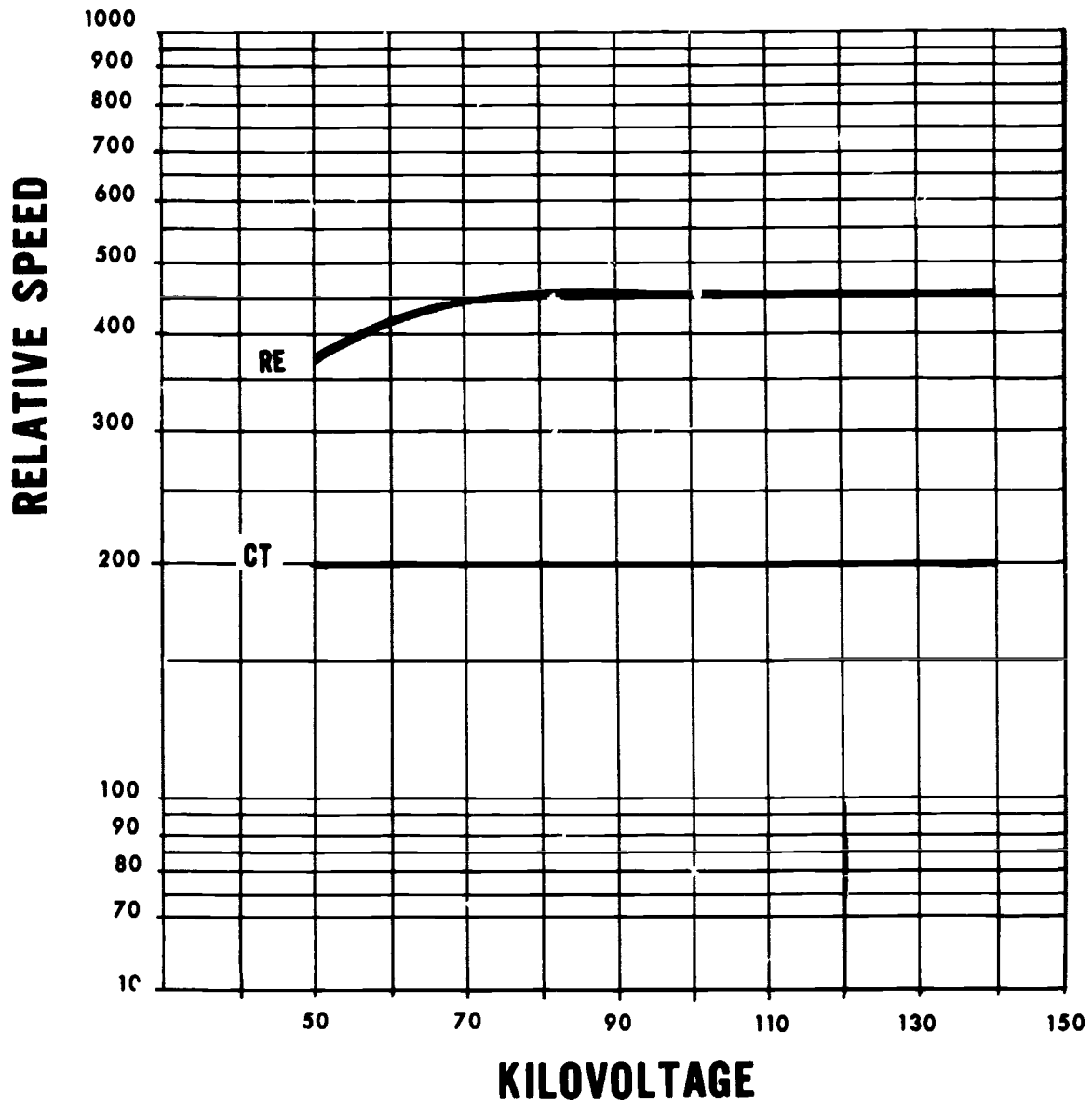


Figure 4-7. Relative speed of calcium tungstate and rare earth intensifying screens.

- T F 2. The safelight requirements for either system is the same.
- T F 3. The rare earth system works best with green-sensitive film.
- T F 4. Gadolinium and lanthanum are the crystals used in rare earth intensifying screens.
- T F 5. The speed response of the rare earth intensifying system is the same, regardless of the kV used.
- T F 6. Calcium tungstate may be used as the phosphor in regular intensifying screens.
- T F 7. The efficiency of a department can be increased by permitting the use of lower power units for a wider range of studies using the rare earth system.

071. Identify true and false statements pertaining to a screen-film contact test, and correct or explain those that you indicate as "false."

**Screen-Film Contact.** Screens must be in close, even contact with the film; otherwise, the film will have a fuzzy appearance, and there will be a definite loss of detail. The detail loss is due to the increased light diffusion from the crystals because they are farther from the film. (See fig. 4-8.) Poor screen-film contact is generally caused by screen warpage resulting from moisture, loose fitting due to broken hinges, improper spring tension in the latches, uneven surfaces caused by a foreign object under the screen, or defective cassette frames.

You can test the screen-film contact quickly and easily in this way: Place a piece of wire mesh on the outside of a loaded cassette and make a flash exposure at about 5 mAs and 40 kVp. After developing, inspect the image of the wire mesh. If the contact is good, the image will be sharp and clearly defined throughout the surface of the film. If it is poor, the outline will be fuzzy, with varying degrees of unsharpness. Figure 4-9 shows two wire mesh images. The one on the left exhibits good contact; the one on the right, poor contact. Although the poor contact in the figure is throughout the film, this may not necessarily be the case always. Poor screen contact can occur in only a small area in the cassette, such as the center. Regardless of the size of the area involved, the cassette must be repaired or replaced.

**Exercises (071):**

Indicate whether each of the following statements is true or false. If you indicate false, correct the statement.

- T F 1. A screen-film contact test is made to determine whether there is an increase in detail.
- T F 2. Poor screen-film contact results in less light diffusion from the phosphor crystals.
- T F 3. To perform a screen-film contact test, make a radiograph of a piece of wire mesh.

T F 4 Unsharp areas on a test radiograph indicate good screen-film contact.

072. Given descriptions of the results of three screen lag tests, evaluate the results and determine whether screen lag is present.

**Screen Lag.** One requirement of good screens is that fluorescence stops at the same time as does the exposure. When screens continue to fluoresce after the exposure has stopped, they are said to have lag or phosphorescence, and the image from one exposure could be carried over to the next film loaded into the cassette. Test for screen lag in these ways:

- a. Make an exposure and take the cassette into the darkroom immediately. Remove the exposed film and reload the cassette. Take the second film from the cassette a few minutes later and develop it. If a density appears, there is a screen lag, and the screens should be replaced.
- b. Expose an unloaded cassette and take it into the darkroom immediately. Take a film from the bin, cover half of it with paper, and load it into the cassette. Leave the film in the cassette for a few minutes; then process it. The half of the film covered with paper will show no exposure. If the half that was not covered by the paper shows an exposure, there is screen lag. Again replace the screens.

**Exercises (072):**

In the exercises below, evaluate the descriptions of the radiographs and indicate whether or not screen lag is present.

- 1. The film is not exposed.
- 2. An even exposure covers the entire film.
- 3. Half the film is exposed; the other half is not.

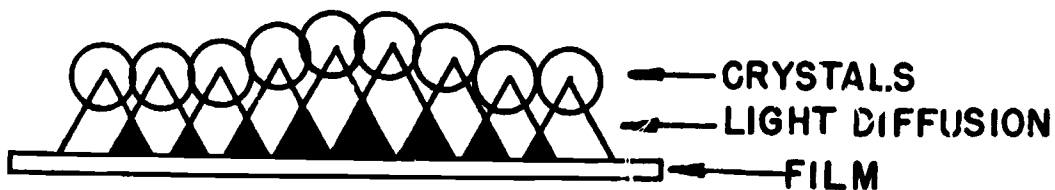


Figure 4-8. Poor screen contact showing increased light diffusion over the area of poor contact.





Figure 4-9. Screen-film contact test.

#### 4-3. Film Processing

We assume that you know by now the procedures for processing radiographs; therefore, we shall not spend a great deal of time on the procedures. Most of this section will be concerned with evaluation and standardization of film processing. We shall explain how to spot some processing problems even before the problems affect the appearance of the radiograph. In addition, we shall discuss ways to standardize all the processors in your department so that you can process a particular radiograph in any processor and obtain the same results. Our discussion will begin with a review of the chemistry of film processing.

**073. Given a list of the chemicals used in processing radiographs, match each with selected statements pertaining to their functions.**

**Processing Chemistry.** Although several chemicals perform various functions in the developer and the fixer, we can say the general functions of the two are as follows: the developer reduces the exposed silver bromide crystals to black metallic silver; the fixer removes the unexposed silver bromide crystals from the film.

**Manual developer.** Basically, manual developer consists of four agents: (1) activator, (2) reducers, (3) restrainer, and (4) preservative.

**a. Sodium carbonate**, also called the activator or accelerator, provides the alkaline base needed to activate the other chemicals. It also causes the film emulsion to swell and soften, permitting access to the exposed silver bromide by other chemicals.

**b. Metol and hydroquinone** are known as the reducing agents. Together they reduce the exposed silver bromide crystals to black metallic silver. Metol acts quickly on the crystals and builds the gray tones of the image. Its action is unpredictable above 75° F. Hydroquinone is slower acting than metol. It builds up the black tones of the image and therefore brings out the film contrast. Hydroquinone does not function effectively below 60° F. Manual developer should be maintained at 68° F because of the sensitivity of these chemicals.

**c. Potassium bromide** is the restrainer in the developer. It limits the action of the reducing agents to prevent development of the unexposed silver bromide crystals. If a film is left in the developer too long, the reducers will override the restrainer and develop the unexposed crystals, resulting in chemical fog. An important point to remember is that bromine, which is a byproduct of the development process, also acts as a reducing agent. It continues to build up throughout the life of the developer; consequently, there is no need to add potassium bromide to the replenisher.

**d. Sodium sulfite** is the preservative in the developer. Its purpose is to prevent rapid oxidation of the chemistry and thereby prolong the life of the developer.

**Automatic developer.** Basically, the automatic developer chemistry is the same as manual developer. Two chemicals, sodium carbonate and sodium sulfite, serve the same functions. Potassium bromide also serves the same function, but it is called the starter solution. The starter is obtained separately from the automatic developer; whereas, the potassium bromide is included as part of the manual developer pack. As with manual developer, potassium bromide is not included in automatic developer replenisher. Two



other differences between the developers are as follows:

a. Metol cannot be used in automatic processors, since the developer temperature is higher than 75° F, usually 80° to 100° F. Phenidone in automatic developer performs the same function as metol in manual developer. Hydroquinone is present in automatic developer and serves the same function as in manual developer.

b. Automatic developer contains a "hardener"—gluteraidehyde. The purpose of this chemical is to control the swelling of the emulsion and thereby help prevent transport problems and damage to the emulsion by the transport rollers.

*Fixer.* The fixer in both manual and automatic chemistry contains four basic agents: (1) acidifier, (2) clearing agent, (3) hardener, and (4) preservative. The preservative is the same chemical, sodium sulfite, and serves the same function as in the developer.

a. Acetic acid, the acidifier, serves two functions: (1) It stops development by neutralizing the alkaline developer solution, and (2) it provides the acidity required for the other chemicals to function.

b. The clearing agent in the fixer is either ammonium thiosulfate or sodium thiosulfate. It removes the unexposed silver bromide crystals from the film emulsion by dissolving them into solution as silver salts. Once the film is cleared, it can be safely exposed to light.

c. The hardener in the fixer is either aluminum chloride, potassium alum, or chrome alum. It shrinks and hardens the emulsion so that it can be handled without damage.

#### Exercise (073):

1. Match the processing chemical in column B with the appropriate statement in column A. Each column B item may be used once, more than once, or not at all. In addition, more than one column B item may match a single column A statement.

<i>Column A</i>	<i>Column B</i>
— 1. Turns the exposed silver bromide crystals to black metallic silver.	a. Potassium alum.
— 2. Prevents chemical fog by limiting the action of the reducing agents.	b. Metol.
— 3. Hardening agent in the automatic developer solution.	c. Sodium thiosulfate.
— 4. Starter solution.	d. Gluteraidehyde.
— 5. Removes unexposed crystals from film emulsion.	e. Sodium carbonate.
— 6. Manual developing temperature is based on these.	f. Hydroquinone.
— 7. Permits reducing agents' entry to the exposed silver bromide crystals.	g. Potassium bromide.
— 8. Hardens the film emulsion in the fixer.	h. Sodium sulfite.
— 9. Prevents oxidation of the chemistry.	i. Phenidone.
	j. Acetic acid.
	k. Ammonium thiosulfate.
	l. Aluminum chloride.

- 10 Developer agent not added to replenisher.
- 11 Doesn't work properly below 60° F.
- 12 Reducing agent that is dependable when temperature is above (24° C).

074. State a common cause of inconsistent quality in radiographs, and briefly explain the procedure for making a film strip.

**Evaluation of Film Processing.** The production of diagnostic radiographs is important. Equally important is the *consistent* production of diagnostic radiographs. Several factors affect the consistency of radiographs: for example, the manipulation of technical factors, screens, grids, and other factors that are mentioned elsewhere in this volume. One of the most common causes of inconsistent film quality is that film processing varies from day to day and from one processor to another. To identify the variations before they affect the radiographs or to prevent the variation altogether, you should check each processor daily, using a sensitometric filmstrip. Basically, the procedure is as follows: the filmstrip is exposed to a predetermined amount of light so that a series of densities is recorded on the film. After processing, the densities of certain density steps are determined with a densitometer and recorded on a chart.

#### Exercises (074):

1. What is a common cause of inconsistent quality radiographs?
2. Briefly explain the procedure for producing a filmstrip.

075. State why a sensitometer should be used to evaluate automatic processors, and indicate certain precautions that you should take in conducting a check of these processors.

**Sensitometer.** The first requirement for evaluating processors is to expose the filmstrips with a device capable of producing repeated equal exposures from one day to the next. Such a device is called a sensitometer. Using a sensitometer, you can be assured that the filmstrips receive equal exposure; consequently, a variation in film density can be accurately traced to the processor. You shouldn't expose the filmstrips

with a radiographic unit because there are usually minor, day-to-day variations in machine output.

Commercial sensitometers are available, but one can be made at a relatively small cost. One "home-made" sensitometer is described in an article written by Trout, Kelly, and Anderson in *Radiologic Technology*, Volume 43, No. 1, 1971, pp. 15-19.

The procedure for exposing the radiographic film in the sensitometer is relatively simple and depends upon the device employed. Keep in mind that you should eliminate as many variable factors as possible in order to accurately evaluate your processing systems. Reserve one box of radiographic film for the evaluation in order to prevent minor variations from one box of film to another from affecting the film densities. Also, after exposure, process the film immediately, since prolonged periods between exposure and processing may also affect the resulting film densities. If you have more than one processor, cut the film into strips after exposure and process a filmstrip in each processor. Be sure to identify the processor on the film strip.

**Exercises (075):**

1. When you are exposing radiographic films to evaluate processors, why is it better to use a sensitometer rather than a radiographic unit?
2. Why is it important to take your films from the same box?

3. How long after exposure should you process the filmstrips? Why?

076. Given a chart showing densities obtained from filmstrips processed in three different processors, evaluate the chart and answer specific questions pertaining to the test data and results.

*Evaluating filmstrips.* Evaluation of the filmstrips is, of course, the most important aspect of the processor checking operation. We shall discuss this aspect from two standpoints: (1) using a densitometer and (2) without using a densitometer.

A filmstrip exposed in a sensitometer, after having been processed, appears similar to a radiograph of a step wedge; that is, there is a series of density steps. With a densitometer, you measure specific density steps of the filmstrip to determine film density contrast and base fog. Let's look at a typical filmstrip and see how to determine these factors.

First of all, to measure the density, select a density step between 0.9 and 1.2. These densities are located on the portion of the characteristic curve that is most sensitive to changes in processing. Let's assume that the density step that suits our needs is 1.0. This means that every day you measure the density of that same step. The next step is to record the information on a chart like the one illustrated in figure 4-10. Notice on

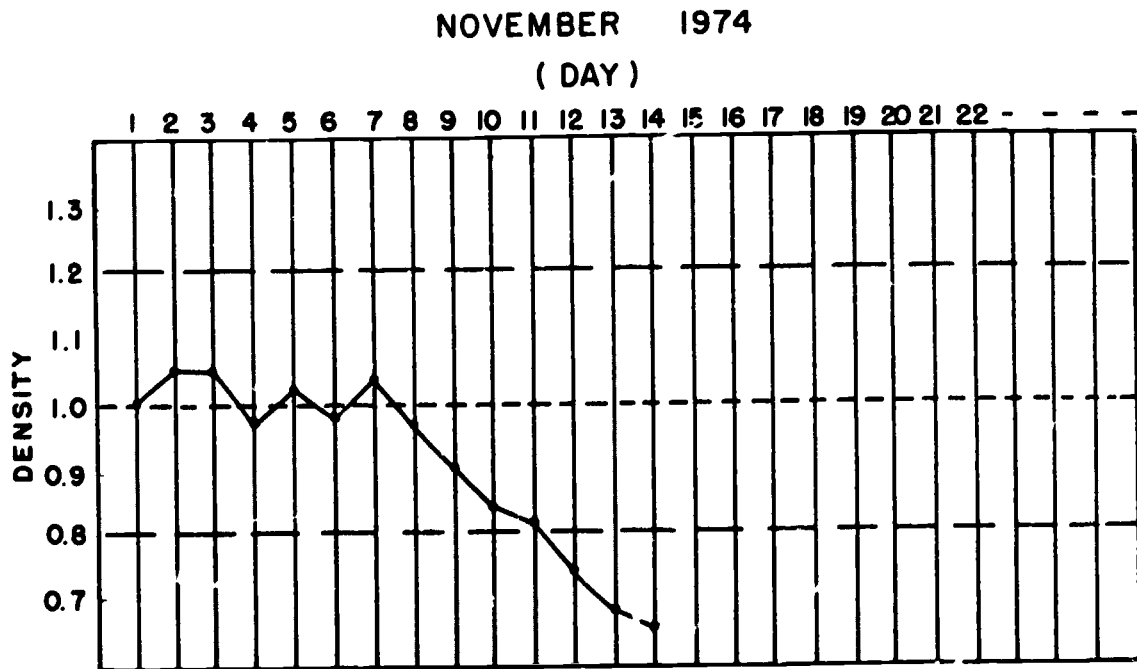


Figure 4-10. Sample chart for recording processor density (single processor)

the chart that the density remains near 1.0 and relatively stable until the seventh day, when it begins to drop steadily. Notice also the broken lines at densities of 0.8 and 1.2. These lines represent the density variation tolerance, which in most cases should be about 0.2 above and below the normal density. As you can see from the figure, the density has dropped below the tolerance limit, has remained below, and continues to drop. This pattern usually indicates processor problems. Although you are actually alerted to the existence of a problem on the ninth day, when the density began to drop, keep in mind that, on a chart such as this, the trend is the important factor. If a density moves outside the tolerable limit but immediately returns, it probably doesn't indicate a significant problem. A major benefit from using a chart like this is that it alerts you to possible processing problems early. Thus you can take the necessary corrective action before a group of radiographs is ruined by the processor. In the case of the processor plotted in figure 4-11 the problem is obviously due to incomplete development, which could be caused by such factors as insufficient replenishment, low developer temperature, or inoperative or insufficient circulation. An increase in density above the tolerance limit indicates such factors as high developer temperature or excessive development caused by strong solutions. (NOTE: The best way to determine the specific problem with your processor is to refer to the troubleshooting chart supplied by the manufacturer. Possible causes mentioned in this section represent only a portion of the most common ones.) You can also plot densities from filmstrips of more than one processor on the same chart, as indicated in figure 4-11.

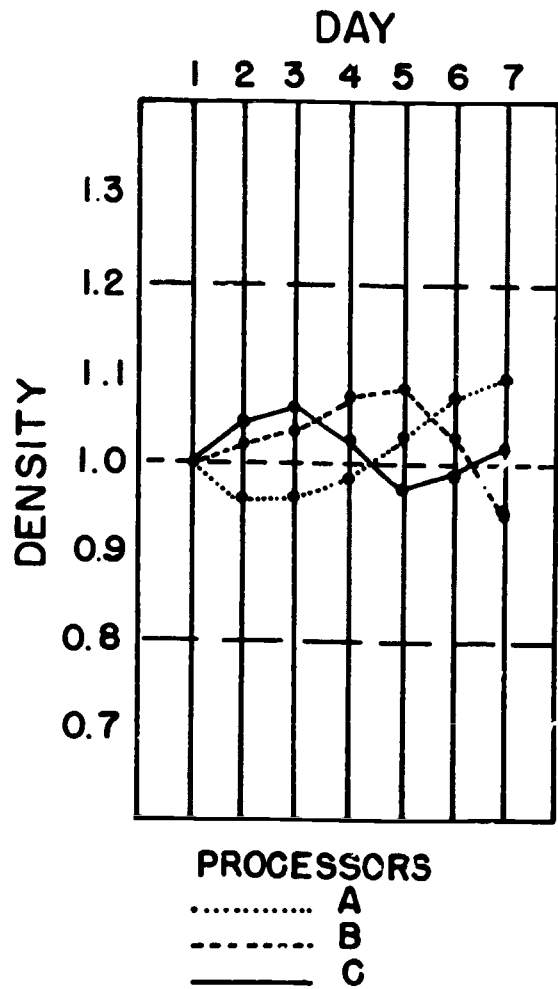


Figure 4-11. Sample chart for recording processor density (three processors)

**Exercises (076):**

Complete the following exercises, using the chart shown in figure 4-12.

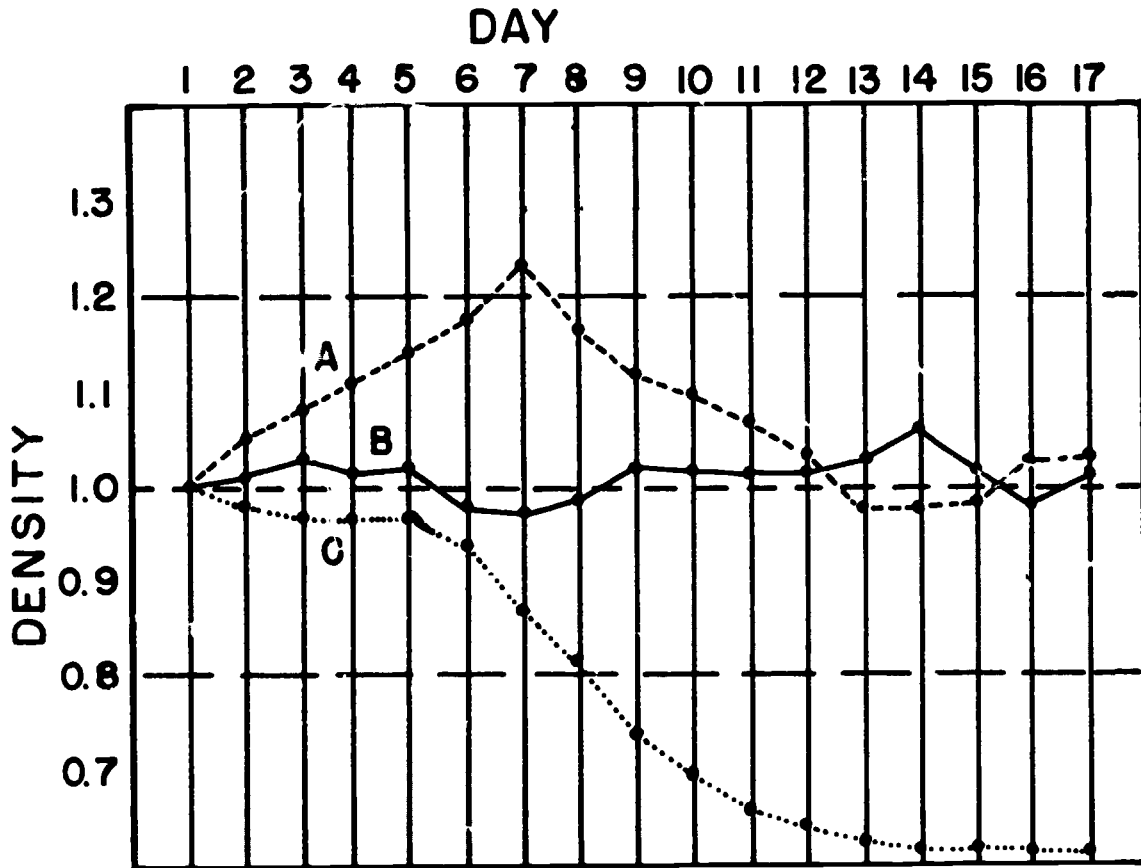


Figure 4-12. Objective 076, exercises 1 through 3.

1. Which processor is the most consistent?
2. Which processor has a significant problem causing underdevelopment? On approximately what day are you alerted to the problem? On approximately what day would you look for a problem with this processor?
3. What would be your thoughts about processor A on days 3 and 4? On day 7? On day 10? On day 17?

Contrast can be evaluated on a day-to-day basis much the same as the density. To evaluate contrast, measure two density steps on the filmstrip. One of the measured steps should be the same step you used to determine the density, as previously described. The other should be a step with greater density, which falls on the upper portion of the slope of the characteristic curve. All that you do is subtract the difference between these two densities and plot the results on a chart, as shown in figure 4-13. A tolerance density of about 0.1 should be established. High contrast, shown by greater difference between the two densities measured, can be caused by high developer temperature. After the temperature reaches a certain high point, a further increase in temperature reduces the contrast. Low developer temperature and improper safelighting also reduce the contrast. The effect of developer temperature on contrast is shown in figure 4-14, where the normal developer temperature is 92° F.

077. Given two charts showing contrast and base fog from filmstrips processed in a single processor, interpret the test data and results.

The base fog of a filmstrip is easily determined by measuring the density of the unexposed density step on the filmstrip. Fog also should be plotted on a chart,

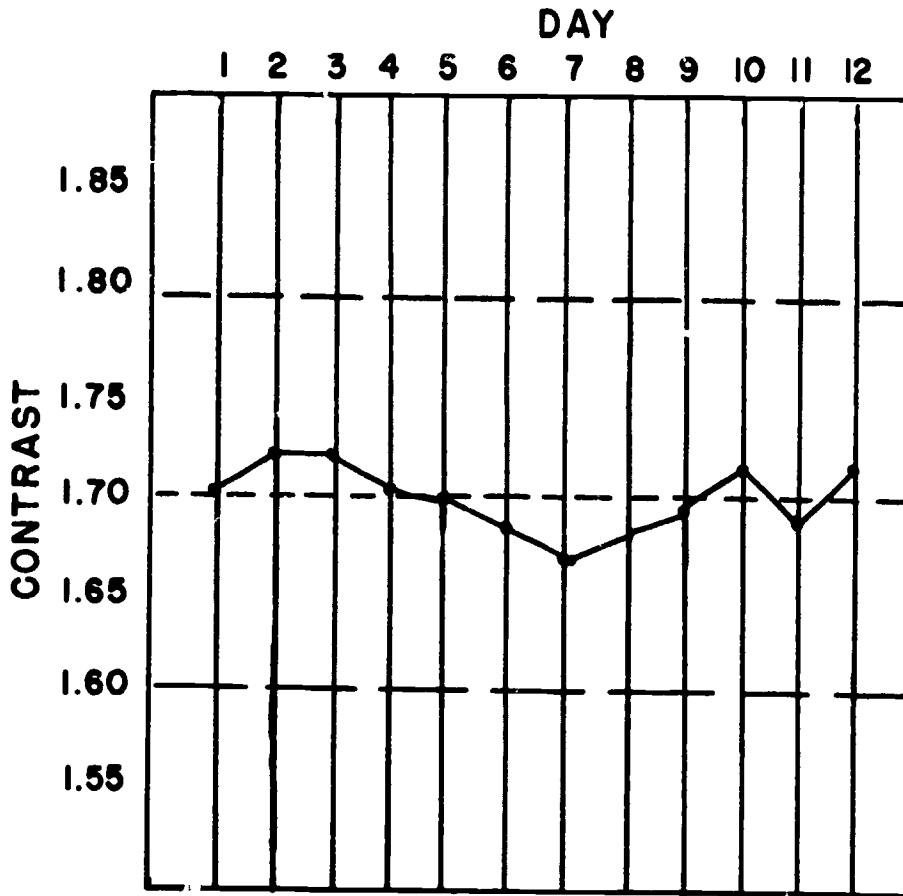


Figure 4-13. Sample contrast chart.

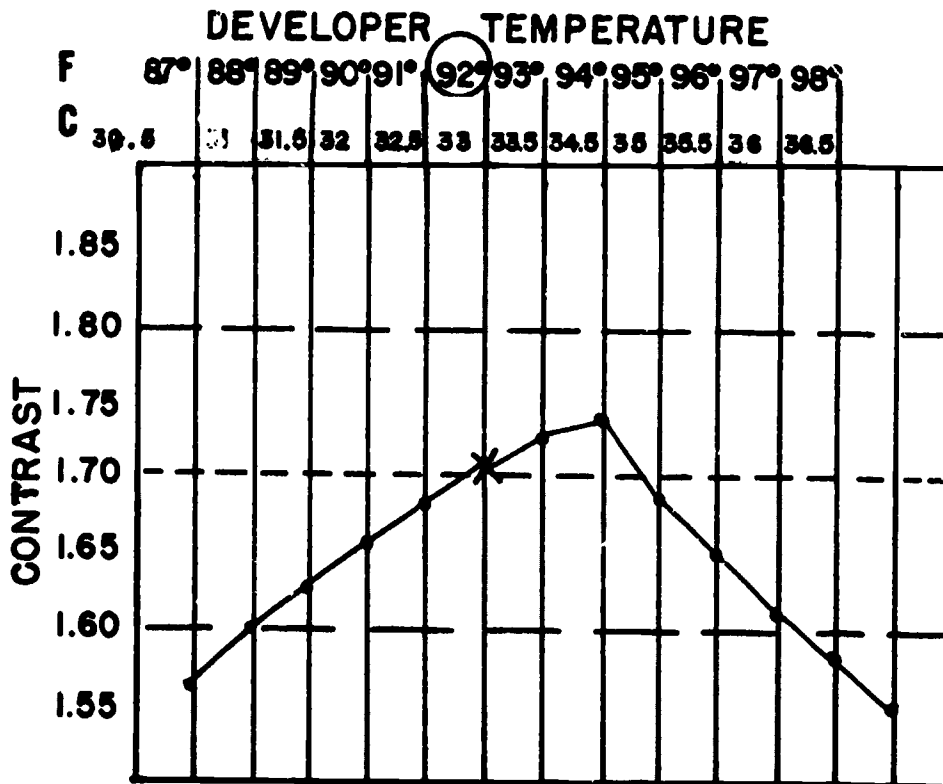


Figure 4-14. Chart showing the effect of developer temperature on contrast.

as shown in figure 4-15. Base fog should remain consistent. Any appreciable increase should be investigated. (Base fog is never lower than the amount specified by the manufacturer.) High developer temperature increases the base fog. Safelighting conditions also affect fog. Increased exposure to safelight increases the base fog level.

**Exercises (077):**

1. Refer to the two charts shown in figure 4-16. Both charts are of filmstrips processed in a single processor. What is the probable cause of the change in contrast and base fog?

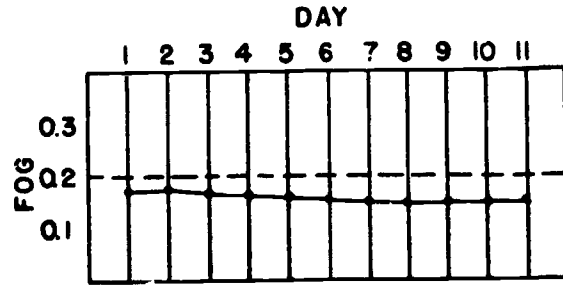


Figure 4-15. Sample chart showing base fog of 0.18.

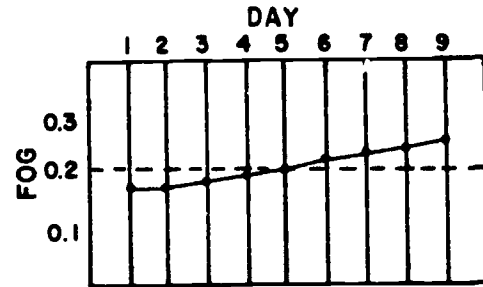
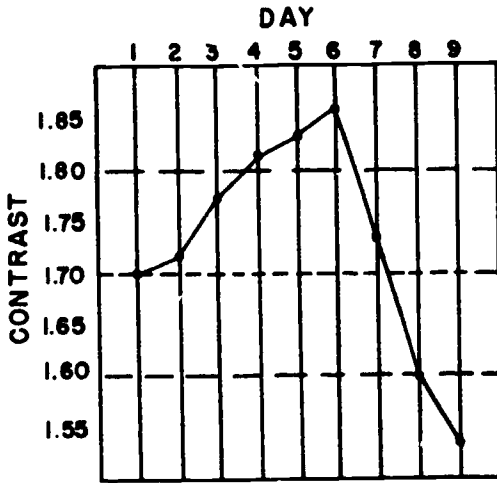


Figure 4-16 Objective 077, exercise 1

2. Refer to the charts in figure 4-17. Both charts are of filmstrips processed in a single processor. What is the cause of the change in contrast and base fog?

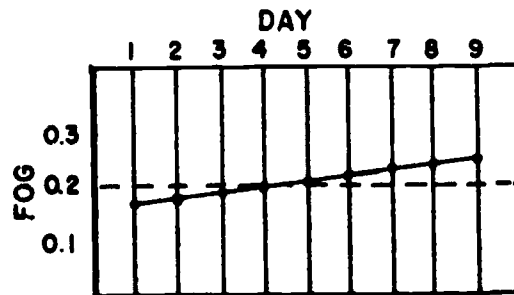
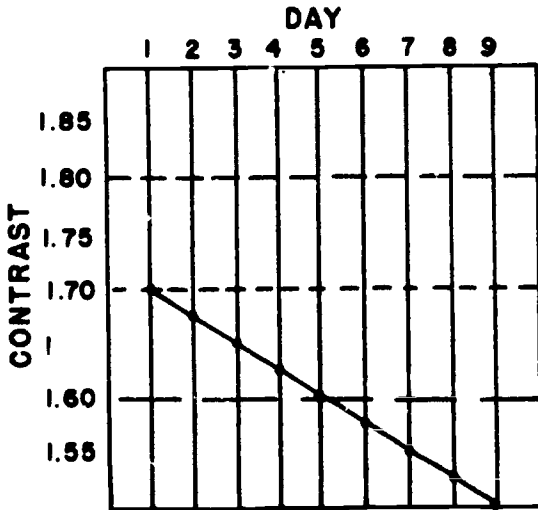


Figure 4-17. Objective 077, exercise 2.

078. Indicate the disadvantages and procedures involved in the evaluation of processors without using a densitometer.

Up to this point, we have discussed evaluation of processing by using a densitometer. You can evaluate your processing without a densitometer also. However, you are not likely to spot potential problems as quickly as you would with charted densitometer results. Without a densitometer, simply visually compare the filmstrips with a base strip. Several of the film manufacturers will provide you with a base strip with which to compare your daily strips. By placing the base strip and daily strips side by side on a view-box, you can make a fairly accurate comparison of the different steps. The most difficult comparison to make is of the contrast, since you must compare the difference between two density steps to the difference between two other density steps. Density and base fog steps are relatively easy to compare, since you have only to compare one density step to another.

**Exercises (078):**

1. What disadvantage results from evaluating processing without a densitometer?
2. Explain how to compare filmstrips without using a densitometer.
3. What specific factor is most difficult to evaluate without a densitometer? Why?

079. Interpret a given standardization chart showing the densities of three processors plotted over a 30-day period.

**Standardization of Film Processing.** Initial standardization of all the processors in your department is as important as daily evaluation of the processing systems. You should be able to process your films (except possibly for special films, such as mammography) in any processor and obtain approximately the same density. If you have a processor breakdown and must process those radiographs in another processor, you will quickly realize the importance of standardized processors.

The best way to standardize your processors is to use the density filmstrip test much the same as we describe previously for daily processor evaluation. Use the strips and plot the data on charts for approximately 1 month before making any decisions about differences between processors.

To standardize processor density, measure a density step that falls between densities 0.9 and 1.2, as explained before. Plot the results on a chart for 30 days. The average density for the time period should vary no more than 0.2 of the density step, as previously explained. For example, if the density step used is 1.0, the plotted density line should remain between densities of 0.8 and 1.2. In addition, the average densities of different processors should be within a density of 0.2 of one another. Figure 4-18 shows a sample 30-day chart on three processors. Processor B is good. Processors A and B are separated by a density of about 0.5, which is too much variation; consequently, A and B are above and below the 0.2 tolerance respectively; both of these processors should be aligned so that their density is closer to that of processor A and a density of 1.0.

When you have variations between your processors, such as those shown in figure 4-18, there are several things that you should check. The first possible cause

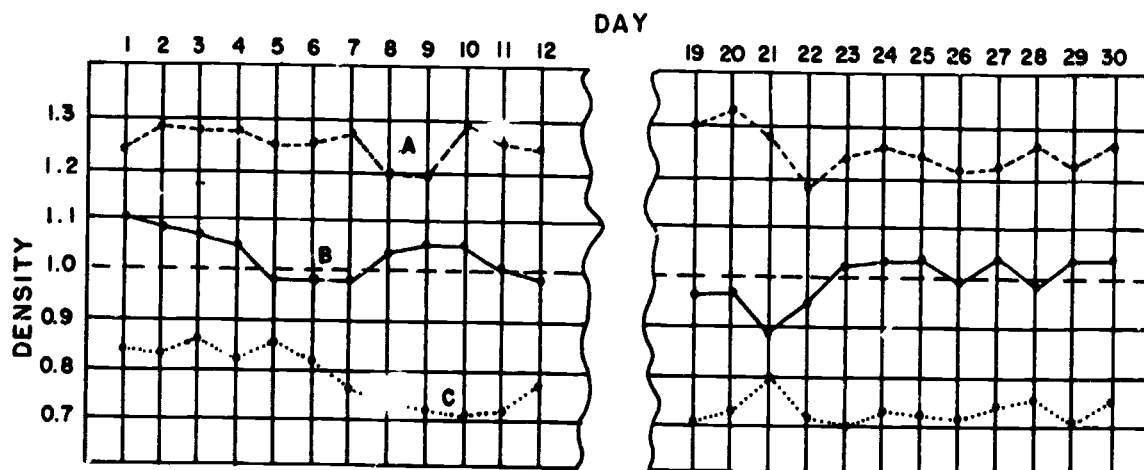


Figure 4-18. 30-day processor standardization chart.

of the variations is that the processor is not being operated according to the manufacturer's recommendations. Underdevelopment can be caused by such factors as low replenishment rates and low developer temperature. Such factors as high developer temperature and replenishment rates are common causes of overdevelopment. Another possible cause of overdevelopment, with resulting increased density, is high developer immersion time. Immersion time can increase in an automatic processor if the transport gears, rollers, or motor are not operating smoothly. Find out from the manufacturer's brochure what the immersion time should be for your processor. Check the actual immersion time, using a timing device, and note when the leading edge of a film enters and exits the developer solution.

If, after checking all of the possible causes of processor variation indicated in the manufacturer's brochure, you can find no reason for the variation, increase the developer time slightly to increase the density, or decrease the time to decrease the density. Do not make major changes in the developing time without first consulting a processor and chemistry manufacturer's representative for advice.

**Exercises (079):**

Figure 4-19 is an example of a processor standardization chart, showing the 30-day densities of three processors (A, B, and C). A density step of 1.0 was measured. Using this chart, complete the following exercises.

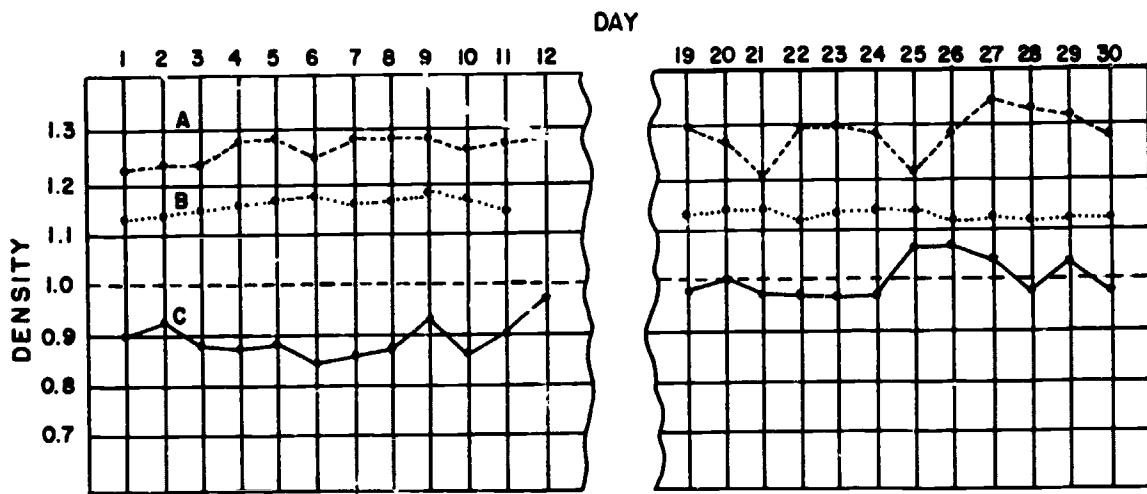


Figure 4-19. Objective 079, exercises 1 through 5.

1. Which processor is likely to produce consistent radiographs?
2. Which processor, if any, shows excessive variation from the measured density step?
3. Are the densities of any two processors separated by more than the maximum allowable amount? If so, which ones?
4. Which processor(s) should be checked for possible problem(s)?
5. When you are troubleshooting the processor(s) you indicated in exercise 4 above, what are three possible causes of the problem(s) that you should consider?



## Control of Film Quality

IN PREVIOUS chapters of this volume, we discussed some of the factors that affect the quality of a radiograph. We discussed such things as the geometrical factors, beam restrictors, grids, and film processing. Now it is time to turn our attention to the exposure factors. Basically, we shall be discussing two factors—mAs and kVp. Although we shall review some material that you are familiar with, we shall concentrate on problems you will face as a quality control technician. We shall begin this chapter with a close look at density and contrast. Next we shall discuss the mathematical concepts of exposure and finally exposure systems.

### 5-1. Density

We have already discussed several factors that control film density, such as intensifying screens, FFD, and film processing. As a general rule, however, these factors, once established, remain constant. We make most of the changes in film density by altering the kVp or mAs simply because it is more convenient to change them than to change the other factors. Keep in mind that this discussion on film density pertains to correcting the initial exposure of a radiograph. In other words, we shall deal with things you need to know as a quality control technician.

**080.** Given a list of statements pertaining to the recognition of radiographs with correct density, indicate which are true and which are false. If you indicate "false," explain your answer.

**Acceptable Radiographic Density.** Before you can determine whether a radiograph has too little or too much density, obviously you must first be able to recognize the correct density of the radiograph. How do you do this? One way would be to measure the average density on each radiograph with a densitometer. Since an average density of 1.5 is about right for most radiographs, you could easily determine whether it is correct by using a densitometer. Of course, we know that this procedure is not practical, so we must look for another way.

**Density of specific structures.** Unfortunately, there is no quick and easy way to learn what a correctly

exposed radiograph looks like because there are no clear-cut guidelines. Experience is perhaps the best teacher of all. One important factor is for you to know and recognize the specific structures that should be demonstrated on the radiograph. It is obvious that you cannot evaluate the density of a structure if you cannot first locate it. Let's take an example. An AP radiograph of the lumbar spine and an AP abdomen are taken to demonstrate different structures. Since the spine radiograph is taken to demonstrate the lumbar vertebrae, the density of those vertebrae would be important. Both other structures are more important on the abdominal radiograph, such as the renal and psoas shadows, bowel pattern, etc. What all of this means is that evaluation of radiographic density begins with recognition of the structures involved.

**Radiologists and density.** Another important factor (perhaps we should say "an important person") that must be considered when evaluating film density is your radiologist. Some radiologists like radiographs with more density than do others. In fact, the same radiologist may want different radiographic densities from one examination to another. We strongly advise you to sit with your radiologist as he interprets radiographs to learn what he likes and dislikes in terms of density and contrast.

### Exercises (080):

Indicate whether the following statements are true or false. If you indicate "false," explain your answer.

T F 1. The average density on most radiographs should be about 1.5.

T F 2. Experience is not advantageous in recognizing correct radiographic density.

T F 3. Knowing and recognizing specific structures can help you to recognize correct radiographic density.

T F 4. Two identical projections of the same body part may require different densities.

T F 5. Density requirements vary from radiologist to radiologist.

**081. State significant features of the procedures for changing the density on a radiograph.**

**How To Change the Density on a Radiograph.** We base our discussion of changing the film density on the assumption that minimum amounts of mAs and kVp are necessary to produce a diagnostic radiograph of a particular part. In other words, if too little mAs is used for a skull radiograph, no increase in kVp can compensate. If too little kVp is used, no increase in mAs can compensate.

Let's assume that you have a radiograph with incorrect image density. How do you change the density? As previously mentioned, the most logical factors to change are the kVp and mAs. As a general rule, for most density corrections you should change only one of the factors when possible. This practice will reduce the possibility of error, and you will learn through experience how the factors separately affect the radiograph.

Most improperly exposed radiographs in a department that has good technique charts have sufficient kVp or mAs to be diagnostic. In cases such as this, you can change either the kVp or the mAs to correct the density. One thing you should always keep in mind is that the way radiographic contrast is affected depends upon what you change. We shall discuss contrast later in this chapter.

When you are evaluating a radiograph to determine how to correct the density, it is a good idea to also consider the kVp and mAs used. Let's look at an example. Suppose that a radiograph of the skull shows good background density. Good background density can be an indication of sufficient mAs. Further suppose that there is not sufficient image density, which means that the structures are too light for clear demonstration. This result could be an indication of insufficient kVp. If, after evaluating the exposure factors used, you find that the kVp used was below normal, you can almost be certain that more kVp is required. Suppose that in another skull radiograph the structures are demonstrated but are not dark enough, and the background density is insufficient. If a review of the exposure factors shows low mAs, the mAs probably should be increased.

If a radiograph is overexposed, it is usually more difficult to determine the cause. A careful evaluation of the exposure used is often the best course of action.

As you no doubt have assumed by now, there are few clear-cut rules to follow with regard to changing the kVp or mAs or both when you wish to alter film density. The best advice that we can give you is to take advantage of every opportunity to learn how kVp and mAs affect a radiograph. If you make a change to improve a radiograph, *check the results*. This habitual practice will help you considerably. You may even want to keep a log of some of the cases so that you can review them collectively.

#### Exercises (081):

Answer the following questions or fill in the blank spaces as appropriate.

1. To produce a \_\_\_\_\_ radiograph, you must use a \_\_\_\_\_ amount of mAs and kVp.
2. To change the density of a particular radiograph, you normally should change either \_\_\_\_\_ or \_\_\_\_\_, but not \_\_\_\_\_.
3. Why should you change only one factor to change density?
4. Do good technique charts provide more flexibility in changing density? Explain.
5. Name three factors that you should consider when deciding whether to change density with mAs or kVp.
6. Background density can be an indication of sufficient or too little \_\_\_\_\_.
7. It is easier to determine the cause of an \_\_\_\_\_ radiograph than the cause of one that is \_\_\_\_\_.
8. A good way to learn how the changes you make to a technique affect radiographic density is to \_\_\_\_\_ the \_\_\_\_\_ of your work.

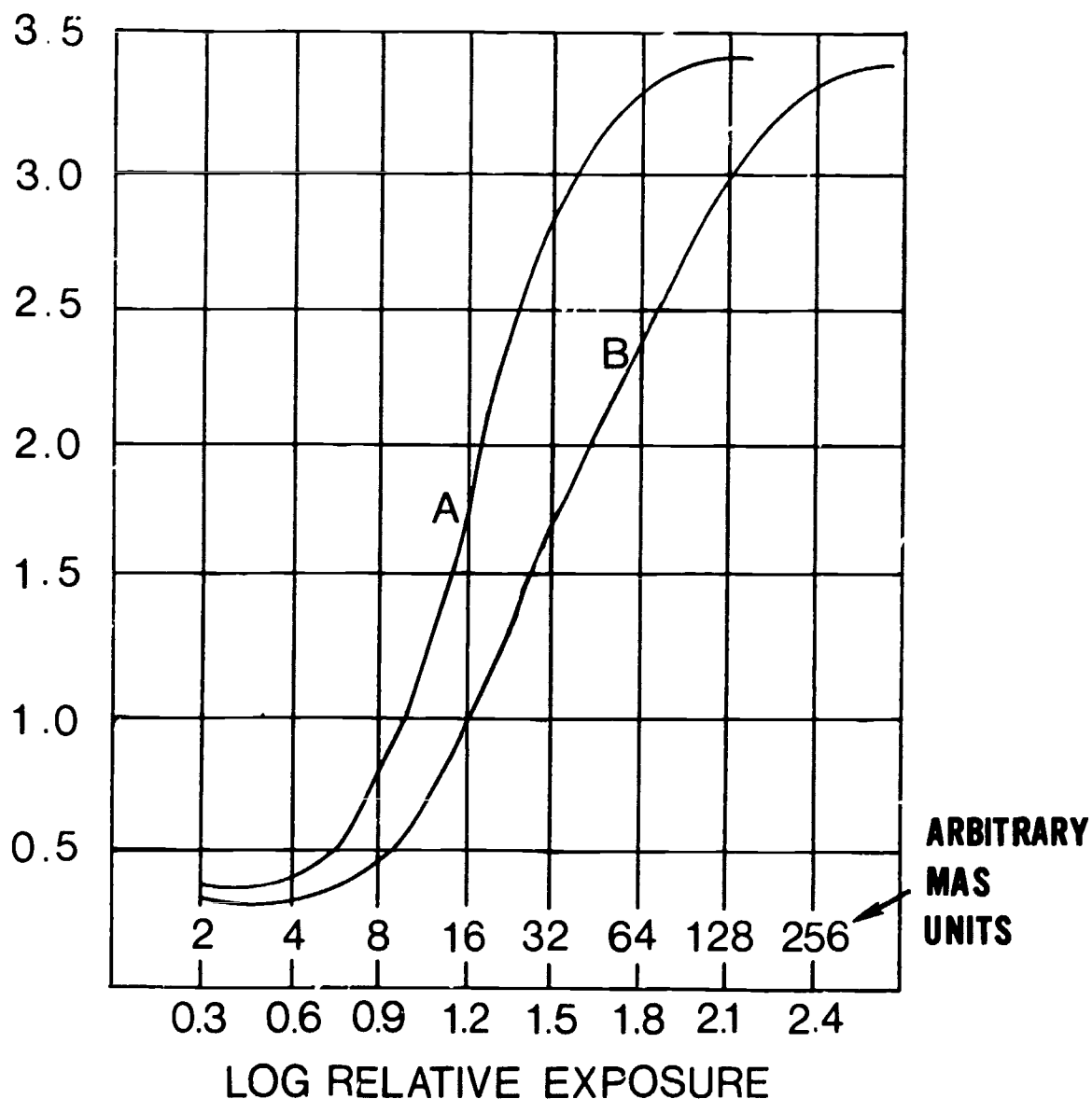


Figure 5-1. Characteristic curves of two different brands of X-ray film.

082. State the basic relationships between mAs, kVp, and radiographic density.

**mAs-density relationship.** You have no doubt heard many times that you should double the mAs to double the radiographic density and halve the mAs to halve the density. Let's see whether this is true. Figure 5-1 shows the characteristic curves of two different X-ray films. Notice in curve A that a change from 1.0 to 2.0 in the density requires a change of from 10 to 18 mAs. In curve B, an increase in mAs from 15 to 48 is required to increase the density from 1.0 to 2.0. As you can see from these two characteristic curves, the rule previously mentioned is not completely accurate. The best way for you to determine what change in mAs will double or halve the density is to refer to the characteristic curve of your particular brand of film.

For most X-ray films, the mAs-density relationship is near enough to the previously mentioned rule to use it. Such is the case with curve A in figure 5-1. As a rule, in this CDC we shall base the discussions of technique compensations on such films.

You should also note that around the shoulder and toe of the characteristic curve the changes in relative exposure are considerably different from the changes along the slope of the curve. Notice in curve A, figure 5-1, that when a film is very dark, with an average density, for example, of 3.4, halving the mAs (from 128 to 64) reduces the density only by approximately 0.1.

**kVp-density relationship.** As you know, the characteristic curve of an X-ray film shows the relationship between the mAs and density. Unfortunately it does not reveal the relationship between kVp and density. Therefore, we are left with a rule-of-thumb to follow when we alter the kVp to correct the density on a

radiograph. The rule is actually based on the relationship between kVp and mAs. Since we know from our characteristic curve the relationship between mAs and density, we can predict the relationship between kVp and density.

The rule is to add 15 percent of the kVp to double the density and subtract 15 percent of the kVp to halve the density. Subtraction of 15 percent of the kVp represents a decrease of 50 percent in the mAs, and addition of 15 percent of the kVp is the same as doubling the mAs. This rule-of-thumb is based on the assumption that the characteristic curve of your X-ray film is similar to curve A in figure 5-1—that is, doubling or halving the mAs approximately doubles or halves the density.

#### Exercises (082):

1. How can you determine the *exact* mAs change required to make a specific change in the film density?
2. If the average density on a radiograph is very low (around 0.3), what relative mAs change, compared to a density of 1.5, is required to significantly increase the density?
3. For most X-ray films, how should you alter the mAs to double and halve the average density on a radiograph?
4. For most X-ray films, how should you alter the kVp to double and halve the average density on a radiograph?

#### 5-2. Contrast

Our discussion of contrast includes a definition of contrast, a description of the types of contrast, a listing of the factors affecting it, and finally, an explanation of how it is controlled.

**083. Define contrast, and given descriptions of three radiographs, compare their contrast properties.**

**Definition and Types of Contrast.** Contrast is defined as "the visible difference in density between the areas or structures on a radiograph." A good example of the absence of contrast is a film that has been exposed to room light and processed. Only one density is present; consequently, there is no contrast.




Figure 5-2. Short-scale or high contrast.

Contrast is classified as either short-scale or long-scale.

**Short-scale contrast.** If the number of useful densities on a radiograph is small and the change from one density to another is abrupt, the radiograph is said to have short-scale contrast. This type of contrast is also referred to as high contrast. See figure 5-2.

**Long-scale contrast.** If the number of useful densities on a radiograph is large and there is little change from one density to another, the radiograph is said to have long-scale contrast. This type of contrast is also referred to as low contrast. See figure 5-3.

**Relative properties of contrast.** You should realize by now that there is no definite line separating the two types of contrast. Contrast is a relative measure of the difference between densities on a radiograph. A particular radiograph may exhibit short-scale contrast when compared to another, but its scale of contrast may be long when compared to a third radiograph.

#### Exercises (083):

1. Define "radiographic contrast."
2. Suppose there are three radiographs of the same part with different scales of contrast. Eleven different densities can be seen on radiograph A with




Figure 5-3 Long-scale or low contrast.

little change from one density to the next. Only five different densities can be visualized on radiograph B with considerable change from one density to the next. Radiograph C shows eight different densities

with proportional changes between densities. Applying the information presented in the text, answer the following questions:

- a. Which of the three radiographs has the lowest contrast?
- b. Which of the radiographs has the highest contrast?
- c. In comparison of radiographs B and C, which exhibits long-scale contrast?
- d. In comparison of radiographs A and C, which exhibits long-scale contrast?
- e. In comparison of radiographs A and C, which exhibits short-scale contrast?

**084. Correlate structure thickness, atomic number, and density with radiographic contrast.**

**Factors Affecting Contrast.** There are three major factors that affect radiographic contrast—film contrast, subject contrast, and film fog. Film contrast is a photographic property of the X-ray film itself and is evaluated by referring to the characteristic curve, as discussed in Chapter 4. Here we shall begin our discussion with subject contrast and conclude with film fog.

*Subject contrast.* Subject contrast depends upon the selective absorption of X-ray photons. When a beam of X-radiation is directed toward a body region, such as the chest, some parts of the region absorb more X-ray photons than do others. For example, the heart absorbs more photons than does the lung tissue. Consequently, the parts of the film beneath the lung tissue receive more photons and when processed appear darker than the heart. This difference in absorption by various body parts is called selective absorption and results in different densities, or contrast, on a radiograph. Several factors affect the selective absorption of photons and consequently the type of radiographic contrast. The first factor we shall discuss is the difference between thickness of structures:

- a. If three structures, identical except for thickness, are interposed between an X-ray tube and film, the thicker structure absorbs more X-ray photons, as

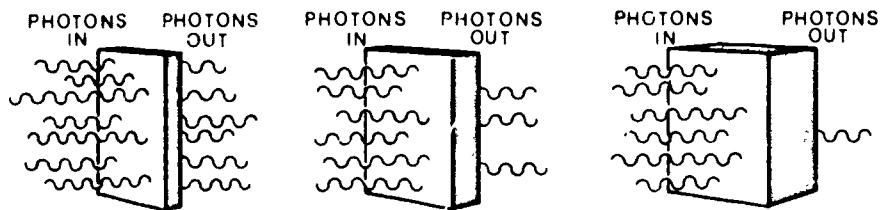


Figure 5-4. Comparison of the difference between absorption of photons by structures with different thicknesses

shown in figure 5-4. An example of this is an AP radiograph of the leg. The fibula, which is thinner than the tibia, absorbs fewer photons than does the tibia. Consequently, the fibula appears a little darker on the radiograph. The greater the difference in part thickness, the greater the difference in the densities appearing on the radiograph—or the higher the contrast.

*b.* The atomic numbers of the various structures also affect the selective absorption of photons. The greater the difference between the atomic numbers, the greater the absorption difference—consequently, the higher the contrast on the radiograph. The reason for the difference in absorption is that the higher the atomic number, the greater is the absorption because of the photoelectric effect. The atomic numbers for bone, muscle, and fat are approximately 12, 7.5, and 6 respectively. You can see why there is relatively high contrast between bone and muscle or between bone and fat, while there is relatively low contrast between muscle and fatty tissue.

*c.* The difference between the densities of structures is another factor that affects the selective absorption of photons. By “density” we mean the number of atoms per unit area. The greater the difference between the densities, the greater the difference in absorption—consequently, the higher the radiographic contrast.

#### Exercises (084):

1. Generally speaking, how do these three factors—structure thickness, atomic number, and density—affect the contrast on a radiograph?
2. Suppose you take two AP radiographs of the leg (tibia and fibula)—one of the proximal leg and one of the distal leg. With all other factors remaining the same, on which radiograph would there be less contrast between the tibia and fibula? Why?
3. If you take a radiograph of a part containing muscle, fat and bone, which of the three structures absorbs the most photons? The least? Why?

Three radiographs are made. Radiograph A shows bone and muscle, radiograph B shows bone and fatty tissue, and radiograph C shows muscle and fatty tissue. All other factors, kVp, and thickness of structures are equal. Based on the information in the text, answer exercises 4, 5, and 6 below.

4. Which radiograph exhibits the highest contrast?

5. Which radiograph exhibits the lowest contrast?

6. The less the difference between structure density, the \_\_\_\_\_ the contrast on the radiograph.

085. Given descriptions of three radiographs, determine the relative kVp used for each and select the one exhibiting the highest contrast.

The most important factor to you—most important because you have direct control—that affects the selective absorptions of photons is the penetrative ability of the primary beam. Whether we say “penetrative ability” or “wavelength” or “energy,” it all boils down to the kVp selected on the control panel.

Let’s see how kVp affects the contrast on a radiograph. Figure 5-5 (A and B) shows equal parts exposed to different beams of radiation. In detail A, 70 kVp was used to expose the steps. Under step 1, we get a density reading of .40; under step 2, 1.94; or there is a difference in density between the two steps of 1.54. For detail B, the kVp was increased 15 percent (mAs was cut 50 percent; the 50/15 rule, to be reviewed later, was used to maintain proper density). Now under step 1, we get a density reading of .44; and step 2, 1.84. The difference now is 1.40. As the density readings between two structures on a radiograph come closer together, the less contrast there is. You might argue “the total difference between the density readings of A and B is only .14; that can’t be significant.” On a densitometer, this .14 difference equates to approximately a 20 percent change in density. Whether this

percentage is significant depends on what is being radiographed. How many times have you taken coned-down views of structures and were instructed to reduce kVp and increase the mAs? The reason: maintain original film density but increase subject contrast.

As a general rule, low kVp gives short-scale (high subject) contrast or few shades of gray between structures. Conversely, higher kVp gives long-scale (low subject) contrast where there are many shades of gray between the lightest and darkest portions of the structure(s) under study.

#### Exercises (085):

Three radiographs are made of a chest, using 50, 80, and 100 kVp. The mAs is varied to compensate for the kVp difference, and all other factors remain the same. The densities of the ribs and the lung tissue are as follows:

Radiograph A: rib density, 1.0; lung density, 2.7.

Radiograph B: rib density, 1.2; lung density, 2.3.

Radiograph C: rib density, 1.5; lung density, 1.8.

Using the information presented in the text and the above data, complete the following exercises.

1. With which radiograph was the 100 kVp used?
2. With which radiograph was 80 kVp used?
3. With which radiograph was 50 kVp used?
4. Which radiograph exhibits the highest contrast between the ribs and lungs?

#### 086. Define "film fog," and indicate the effect of film fog on radiographic contrast.

**Fog.** Film fog—whether caused by scatter radiation, by improper processing, or by exposure of the film to either light or radiation leaks—reduces contrast on a radiograph. Since we have previously discussed ways to reduce film fog in other chapters of this volume, our discussion here will be limited to an explanation of what fog is and how it affects contrast and demonstration of certain structures.

Film fog is a density on a radiograph that is not caused by deliberate film exposure. Ideally, image density and the variations in image density (contrast)

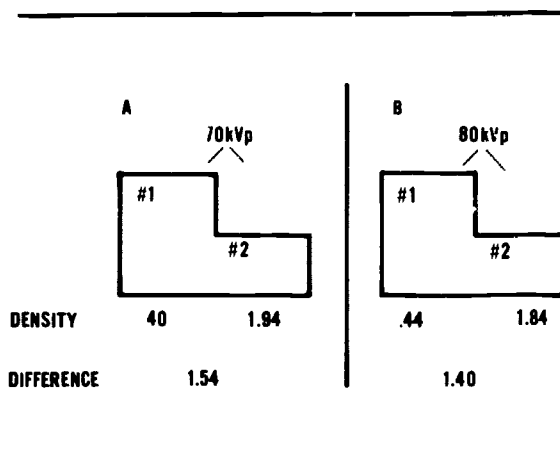


Figure 5-5 How kVp affects contrast

are caused by selective absorption of X-ray photons. Fog density, on the other hand, is not selective in nature. It usually appears evenly distributed over the entire film.

Because of its even distribution, the fog on a radiograph completely obscures some structures and makes others difficult to see. To illustrate how fog affects a radiograph, figure 5-6 shows three drawings representing radiographs of a step wedge. Drawing A shows no appreciable fog. Drawing B represents the addition of a layer of density. Drawing C shows yet another layer of density. If you compare the three drawings, you can see how the contrast has been lowered. Notice also that some steps that were easily distinguished in drawing A begin to disappear as fog is added. A good example is the loss of contrast between steps 4 and 5 in drawing C. You can no longer see any contrast between the two. The reason the structures are obscured is that once a certain density is reached, our eyes can no longer pick up differences between densities.

#### Exercises (086):

1. What is film fog?
2. Specifically, how does the addition of fog affect the contrast on a radiograph?
3. How can the addition of fog to a radiograph cause some structures to be obscure?

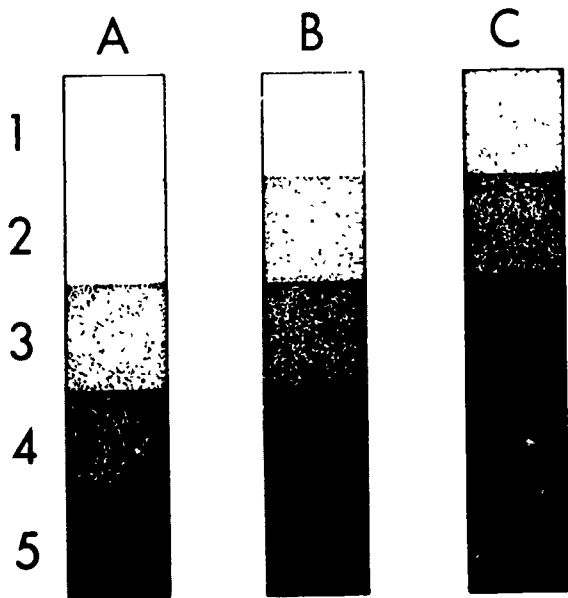


Figure 5-6 The effect of fog upon contrast and visualization of structures.

**087. Given the kVp and mAs values used on a radiograph, change the factors to both raise and lower the contrast of the radiograph.**

**How to Change Contrast on a Radiograph.** There are times when your radiologist wants a properly exposed radiograph repeated with more, or with less, contrast. By "properly exposed," we mean that the radiograph has the correct average density. You should realize by now that to change the contrast, you should change the kVp: increase the kVp to lower the contrast, and lower the kVp to increase the contrast. In addition, you must make a compensatory change in the mAs to maintain the correct density.

You may have heard in the past that you can increase the kVp by 10, halve the mAs, and end up with two radiographs equal in overall density. This "rule" is based on the assumption that density changes on a linear scale if changes are made in the kVp. This assumption is inaccurate. Changes in density resulting from changes in kVp are nonlinear. Therefore, to make a specific change in film density by changing the kVp, you must use a percentage of the kVp.

A good rule of thumb to follow is to increase the kVp by 15 percent and halve the mAs, or lower the kVp by 15 percent and double the mAs. For most brands of radiographic film, these changes will maintain the same approximate density on a radiograph while changing the contrast.

**Exercises (087):**

A radiograph is made, using 80 kVp and 40 mAs. Use this data and the information presented in the text to complete the following exercises.

1. What would be the new mAs and kVp if the contrast needs to be lowered?
2. What would be the new mAs and kVp if the contrast needs to be raised?

**5-3. Mathematical Concepts of Radiographic Exposure**

It would be convenient if we could use the same exposure factors for each examination. For example, if all skull radiographs were performed on patients who could cooperate and maintain the positions with ease, we would have few problems. But we know that it doesn't happen that way. We often radiograph skulls on patients who are seriously injured, on patients intoxicated to the point where they cannot cooperate, or even on small children. For some of these patients, we must change from our routine exposure factors to prevent part motion. The information that you find in this section should enable you to make compensations to your exposure (mA, mAs, sec, or FFD) by calculation, rather than by guesswork.

**088. Apply the mA-sec formula to two sets of exposure factors and calculate (1) the new mA if the exposure time is changed and (2) the new exposure time if the mA is changed.**

**mA and Exposure Time.** As you know, mA and exposure time directly influence radiographic density. The time of exposure, however, has additional significance when patient motion, either voluntary or involuntary, must be controlled to obtain optimum detail. Motion is one of the greatest deterrents to good radiographic detail. Whether the motion is voluntary (as in pediatric cases), controlled (as in respiration), or involuntary (as in peristalsis of the organs—ureters or bowel, beating of the heart, or muscle spasms, you might consider motion when you select the exposure factors to use. The correct combination of sec and mA is one of your most effective means of controlling undesirable motion and thus enhancing image detail.

Expressed mathematically, the mA-sec relationship is  $mA_1:sec_1::mA_2:sec_2$ . To maintain a given film density, the mA required is inversely proportional to the time of exposure when all other factors are kept constant.

Now let's apply this to a working situation. Suppose your standard technique for a lateral skull is 100 mA at 1/10 sec. Further, suppose that there is a change from the normal working situation; for example, that as a result of trauma received in an automobile accident, the patient is semiconscious and unable to



cooperate fully. Motion due to respiration and possibly to muscle spasm has become a factor to consider. In an effort to reduce this motion, you can reduce the normal exposure time. Let's say you want to reduce the exposure time to 1/20 sec. By applying the mathematical formula for mA and sec, you are able to derive the new mA required. Consider the following:

$$mA_1 \cdot mA_2 \cdot sec_2 = sec_1$$

$$100 \cdot x \cdot 1/20 = 1/10$$

$$1/20x = 10$$

$$x = 200$$

Consequently, your new mA is 200.

You can also find your new exposure time if you want to change the mA station. Use the same formula stated above.

**Exercises (088):**

1. Suppose your technique chart calls for 50 mA and 1/10 sec for a particular radiograph. Your patient is uncooperative and you wish to use 1/30 sec. What is your new mA?
2. Suppose your technique chart calls for 600 mA and 1/40 sec and you wish to use the small focal spot that has a 150 mA output. What is your new exposure time?

**089. Applying the appropriate formula to five sets of exposure factors, determine the new mAs, mA, exposure time, or FFD.**

**FFD and Density.** As we have discussed before, X-rays diverge from the focal spot, traveling in straight lines. Thus, the X-ray beam covers an increasingly larger area as the FFD increases, and vice versa. This change in field size, however, results in a change in the number of photons per unit area if all other factors remain constant. When FFD increases, radiographic density decreases; and as the FFD decreases, film density increases. In order to maintain the desired density, then, the quantity of radiation produced can be manipulated to compensate for changes in FFD. Since mAs controls the total quantity of X-rays produced, appropriate changes in this factor can be made to maintain film density and compensate for changes in FFD.

This proportional relationship between mAs and

FFD can be best expressed in a mathematical formula, which is referred to as the *mAs-distance formula*. A verbal reading of the formula would be: The original mAs ( $mAs_1$ ) is to the new mAs ( $mAs_2$ ) as the original FFD squared ( $FFD_1^2$ ) is to the new FFD squared ( $FFD_2^2$ ). You can determine any one of the four factors by using this formula.

A practical application of this formula might be helpful. Suppose that the technique chart normally specifies a technique of 10 mAs using a 72-inch FFD; however, because of equipment limitations and the patient's condition, you are unable to obtain the recommended FFD, but instead must use a 36-inch FFD. What new mAs factor will be required to maintain the original film density? Let's substitute the known technique values into the formula:

$$mAs_1 \cdot mAs_2 :: FFD_1^2 \cdot FFD_2^2$$

$$10 \cdot x :: 72^2 : 36^2$$

$$10 \cdot x :: 5184 : 1296$$

$$5184x = 12960$$

$$x = 2.5$$

Therefore, your new mAs would be 2.5.

Since mAs is the product of mA times exposure time, this same formula represents the mA-distance or time-distance relationships. All you have to do is to substitute mA or seconds for the mAs and proceed as usual with the formula. Although you will have to use the mAs-distance formula to determine certain technique changes, you can make a few changes without using the formula. Just keep in mind that twice the distance requires four times the exposure, and that half the distance requires one-fourth the exposure.

**Exercises (089):**

1. What will your new mAs be if your original mAs was 12.5 at a 40-inch FFD and you wish to change the FFD to 48 inches?
2. If your technique chart calls for 10 mAs at a 40-inch FFD and you wish to reduce the mAs to 2.0, what is your new FFD?
3. Suppose your technique chart calls for 1/60 sec at a 36-inch FFD and you wish to change your time to 1/40 sec. What is your new FFD?

4. What will your new mA be at a 36-inch FFD if your old mA was 100 at a 72-inch FFD?
5. What is your exposure time at a 36-inch FFD if at 72 inches it is 1/5 sec?

#### 5-4. The Standardization of Exposure Techniques

In order to insure consistent film quality and to provide accurate guides for the selection of all exposure techniques, each radiology section should have a standard system of exposure factors. The establishment of such a system is one of the greatest challenges confronting technicians, although it is a problem that could be solved easily if a universally correct exposure technique for each part could be prescribed. But, unfortunately, a universal technique is not possible because of several variables, including the output and the capacity of X-ray machines, the types of exposure devices, the speeds of films and screens, and the preferences of radiologists. Because of these variables, you must be able to prepare and correct your own standard system of exposure factors. This section is intended to help you do so.

**090. Name four requirements of an exposure system and explain how each is met.**

**Requirements of a Standard Exposure System.** A standard system of exposure techniques must meet these four basic requirements: (1) it must produce consistent results; (2) it must provide adequate exposure of the film; (3) it must possess a certain degree of flexibility; and (4) it must provide for the desired range of contrast.

**Consistent results.** By consistent results we mean, for example, that two chest radiographs taken of the same patient 2 months apart will appear the same—the same contrast and density. This is very important in cases where followup radiographs are performed to check progression or regression of pathological conditions.

To produce consistent radiographs from day to day, technique charts are used. As a supervisor, you should enforce the rule that *all* technicians in the department *must* use the charts. The purpose of technique charts is defeated if some technicians are allowed to use "their own" techniques. In addition, your processor must be monitored, as mentioned previously.

**Sufficient exposure of film.** In order to produce satisfactory density, a technique must provide for adequate exposure of the film. This requires proper selections of both mAs and kVp. First, there must be enough radiation in the primary beam to create

silver deposits on the film. Therefore, a minimum mAs value must be established for each part. Secondly, if the primary radiation is to reach the film, the part must be adequately penetrated. Even though the quantity of the beam is sufficient, the image cannot be projected on the film if the part absorbs too much or all of the primary beam. It follows that a minimum kVp value must also be established for each part.

**Flexibility.** Because exposure techniques must be frequently changed to compensate for the conditions of patients, for differences in accessory devices, and for other factors, a system of exposure techniques should be reasonably flexible. For example, a basic technique selected at the highest kVp on your control panel would not permit an increase; and on the other hand, a technique selected at the minimum kVp would not permit a reduction. This means that the mAs and the kVp must be kept within a range from which either may be increased or decreased.

**Desired contrast range.** Any system of techniques must be able to produce the preferred range of contrast within the capabilities and limitations of the machines and other equipment. Of course, the kVp range is the basic determining factor here.

#### Exercises (090):

In exercises 1 through 4 below, name four requirements of an exposure system and tell how you can help insure that each requirement is met.

1

2.

3.

4.

**091. State specific facts about variable kVp techniques.**

**Types of Exposure Systems.** In modern radiography three basic types of exposure systems are in general use: variable kVp techniques, fixed kVp techniques, and high kVp techniques, which can be classified as variable or fixed kVp.

**Variable kVp techniques.** Under the variable kVp techniques system, the mAs remains constant for each part, and the kVp is varied according to part thickness in centimeters. For this reason, it is sometimes referred to as a tissue-thickness technique. One disadvantage of this exposure system is that the contrast varies

Part	Projection	Grid	Screens	FFD	MAS	CMS/kVp										Remarks	
Skull	AP	12 1	Hi-Speed	40"	20	3	14	15	16	17	18	19	20	21	22	23	Measure CR
						70	72	74	76	78	80	82	84	86	88	90	

Figure 5-7 An example of technique chart format

slightly because the kVp changes from one examination to another. However, it is a popular system and relatively easy to apply.

Let's see how to build a variable kVp technique chart. Suppose you decide that for an average-sized adult 20 mAs is sufficient to produce adequate exposure of a PA skull film, and in combination with the necessary kVp, produces the desired scale of contrast. All you need do is to determine the kVp for each centimeter thickness of the skull. For example, suppose you determine by trial and error that the exposure factors of 20 mAs and 80 kVp produce the desired density and contrast for a PA skull that measures 18 cm along the CR. Chart all the information on a working chart. From this starting point, you can perhaps establish the kVp/centimeter relationship for other measurements of the skull. You may have to add or subtract 2 kVp for each centimeter change. If so, you would use 82 kVp for 19 cm, 78 kVp for 17 cm, and so on. Keep in mind that the centimeter measurement is through the path of the CR for each projection of the skull.

The 2-kVp change for each centimeter of part thickness given in the example above may or may not work for some body parts. Usually, kVp changes of from 1 to 4 are made, depending upon the part and the kVp range. The greatest change per centimeter is required when high kVp is used and for denser parts.

Once you determine the correct exposure factors for each part, construct a technique chart, post it near the control panel, and insist that everyone use it. Any type of chart can be constructed as long as it provides the necessary information. Figure 5-7 shows how the example we discussed might look on a technique chart.

You can also construct a *plus factor* technique chart that permits you to determine the correct kVp without referring to the chart for every measurement. Let's take our example of the skull again. Eighty kVp is used for 18 cm. Multiply the cm thickness by 2—which gives you 36. Subtract 36 from 80 (your kVp at 18 cm). This gives you a plus factor of 44 for all projections of the skull. Now when you measure the CR for a projection of the skull, all you have to do is double the cm thickness, add the plus factor, and you have your kVp. Expressed as a formula, the plus factor-kVp relationship for this example looks like this:

$$\begin{aligned}
 kVp &= 2 \times \text{cm} + 44 \\
 &= 2 \times 18 + 44 \\
 &= 36 + 44 \\
 &= 80
 \end{aligned}$$

Keep in mind that the plus factor is determined from a good working exposure and may vary from part to part.

#### Exercises (091):

Complete the following exercises pertaining to variable kVp techniques by filling in the blank spaces with one word or by answering the questions, as appropriate.

1. The same \_\_\_\_\_ is used for each part.
2. What determines the kVp for each radiograph?
3. What is a disadvantage of this type of exposure system?
4. State one advantage of this exposure system.
5. How do you determine the starting technique for a given measurement of a part?
6. When you vary the kVp for parts larger or smaller than average, a kVp change from \_\_\_\_\_ to \_\_\_\_\_ per centimeter is usually necessary.
7. What is the advantage of using the plus factor to determine kVp?
8. What is the kVp for a projection if the part measures 20 cm and the plus factor is 38?
9. What is the plus factor for an examination if 64 kVp is used for 12 cm?

**092. Identify true and false statements pertaining to fixed kVp techniques, and explain those that you indicate as false.**

*Fixed kVp techniques.* An exposure system that is rapidly becoming more popular involves fixed kVp techniques. Under this system, the kVp remains constant for a particular part, while the mAs is varied. The kVp is established on the basis of its satisfactory penetration of that part. The mAs is selected to provide satisfactory density for each part according to its average thickness in centimeters. For parts smaller or larger than the average, the mAs is varied. Generally, it is raised or reduced in increments of 25 percent. Fixed kVp techniques, when properly corrected and worked out to the desired mAs refinements, have one outstanding advantage: they provide consistent contrast for all examinations of a particular part because the kVp is constant. The one major disadvantage is the amount of time and effort that it takes to prepare these techniques. In order to establish the mAs selections, it is necessary to keep accurate records of all radiographs; the record of each should indicate the exposure factors used, the part thickness, and the results of the exposure. Only in this way can techniques be corrected and finalized. Weeks, perhaps months, are required to do this.

**Exercises (092):**

Indicate whether the following statements pertaining to fixed kVp techniques are true or false. If you indicate "false," explain your answer.

T F 1. The kVp is constant for each part.

T F 2. The mAs varied, depending upon the size of the part.

T F 3. A change from 40 to 50 mAs for a larger part is appropriate.

T F 4. Contrast is consistent for all body parts.

T F 5. These techniques are easy to prepare.

**093. Explain what is meant by high kVp techniques, and list three advantages of their use.**

*High kVp techniques.* High kVp techniques are basically high kVp-low mAs exposures and can be applied to either variable kVp or fixed kVp exposure systems. How high is high kVp? Actually it depends upon whom you ask. The best explanation of the matter is that high kVp is the highest kVp you can use and still produce good diagnostic radiographs. It could be 80 kVp for one examination and 120 for another.

High kVp is used in many radiology departments for the following reasons: (1) there is less absorption of photons by the patient, (2) the target of the X-ray tube is subjected to fewer heat units per exposure, and (3) there is greater exposure latitude.

**Exercises (093):**

1. What are high kVp techniques?

2. List three advantages of high kVp techniques.

**094. Given various specific situations in which it is necessary to make changes in the exposure to compensate for factors such as use of a different grid, use of an extension cylinder, the presence of a cast, or patient's age, specify the change in exposure factor to be made.**

**Compensating Factors.** No exposure system is complete without a list of compensating factors to apply when you must alter the exposure because of a different grid, the presence of a cast, close collimation, or the patient's age. Figure 5-8 shows factors that can be used as a starting point. Alter the factors as necessary and use it in the exposure room.

**Exercises (094):**

Complete the following exercises, stating the compensation factor to be used in each specific situation.

1. If your kVp is 75 with a 8:1 grid and you wish to change to a 5:1 grid, what is your new kVp?

2. If your kVp is 92 with a 5:1 grid and you wish to change to a 12:1 grid, what is your new kVp?

3. If your kVp is 120 with a 16:1 grid and you wish to change to a 5:1 grid, what is your new kVp?

## COMPENSATION FACTORS FOR GRID CHANGES

GRID CHANGE	CONVERSION
Nongrid to 5:1 -----	Increase kVp by 5%
Nongrid to 8:1 -----	Increase kVp by 10%
Nongrid to 12:1 -----	Increase kVp by 15%
Nongrid to 16:1 -----	Increase kVp by 20%
5:1 to 8:1 -----	Increase kVp by 5%
5:1 to 12:1 -----	Increase kVp by 10%
5:1 to 16:1 -----	Increase kVp by 15%
8:1 to 5:1 -----	Decrease kVp by 5%
8:1 to 12:1 -----	Increase kVp by 5%
8:1 to 16:1 -----	Increase kVp by 10%
12:1 to 5:1 -----	Decrease kVp by 10%
12:1 to 8:1 -----	Decrease kVp by 5%
12:1 to 16:1 -----	Increase kVp by 5%
16:1 to 5:1 -----	Decrease kVp by 15%
16:1 to 8:1 -----	Decrease kVp by 10%
16:1 to 12:1 -----	Decrease kVp by 5%

### COMPENSATING FACTORS FOR CASTS

Wet cast (cast applied up to 12 hr.) -----	3.5 times mAs or 16 to 20 kVp
Dry cast (anything over 12 hr.) -----	2.0 times mAs or 10 to 14 kVp

### COMPENSATING FACTORS FOR AN EXTENSION CYLINDER OR CLOSE COLLIMATION

Adding a cylinder/close collimation --- Increase mAs by 20%

### COMPENSATING FACTORS FOR AGE DIFFERENCE

Birth to 1 yr. -----	Use 30% of the adult mAs
2 to 5 yr. -----	Use 60% of the adult mAs
6 to 9 yr. -----	Use 70% of the adult mAs
10 to 12 yr. -----	Use 90% of the adult mAs
55 yr. and older -----	Use 75% of the adult mAs

Figure 5-8. Compensating factors.

4. If a cast was applied to a patient's leg 18 hours ago, how much mAs should you use on the leg if the mAs without the cast is 10?
5. By what percentage should you increase the mAs when using an extension cylinder?
6. What percentage of the adult mAs should you use for the following patients?
  - a. Birth to 1 year.
  - b. Six to 9 years.
  - c. Over 55 years.

## Environmental Safety

AS A RADIOLOGIC technologist you operate elaborate electrical as well as radiation-producing equipment. This equipment, if not operated properly, can be extremely dangerous to you and to your patients. In this chapter, we shall define some of the specific problem areas associated with electrical and radiation hazards. We shall also provide solutions, where possible, to help you prevent electrical shock and overexposure to ionizing radiation to you and your patients.

This chapter consists of four sections. The first section pertains to electrical hazards and protection. In the second section we shall discuss radiation hazards and protection for the patient. After that, ways to protect you, the technician, will be covered. Finally, we shall discuss the USAF Film Badge Program.

### 6-1. Electrical Hazards and Protection

As you know, radiology departments are full of electrical devices—from the viewing room to the darkroom to the exposure room. Where electrical devices are present, so is the possibility of an electrical fire or electrical shock. You can help reduce electrical hazards by using commonsense and following recommended safety precautions. Let's begin our study of electrical hazards and protection with a discussion of four factors affecting the severity of an electrical shock.

**095. Name and explain briefly four factors affecting the severity of electrical shock.**

**Factors Affecting Severity of Electrical Shock.** What is the minimum amount of current required to cause electrocution? The amount varies considerably because there are at least four factors involved:

*a.* The person involved and his state of health. An elderly person or one in poor health is more apt to experience the effects of electrical current.

*b.* The part of the body involved. Vital organs, in particular the heart or brain, are more susceptible to electrical current than are, for example, the legs and arms.

*c.* The time of exposure. The length of time the person is exposed is an important aspect. Obviously, the longer the exposure, the greater the effect.

*d.* The type of current. Direct current (dc) is more dangerous than alternating current (ac). As a general rule, we are concerned with AC in our radiology departments, although dc is present in some instances.

### Exercises (095):

In exercises 1 through 4 below, name and briefly describe four factors affecting the amount of current that can cause electrocution.

1.

2.

3.

4.

**096. Identify true and false statements pertaining to the use of a fuse, and explain the false statements.**

**Fuses.** As you know, a fuse is a protective device. What does it protect? Not you. Not your patient. It protects the circuit. It is simply a device that will "burn out" and stop the flow of current when the maximum rating of the fuse is exceeded. Because of this, we can also say that a fuse protects the equipment or structure from damage due to high current or fire. The size of a particular fuse is based upon the amount of current in amperes that the circuit is designed to handle; for this reason, it should not be replaced with a fuse of higher rating.

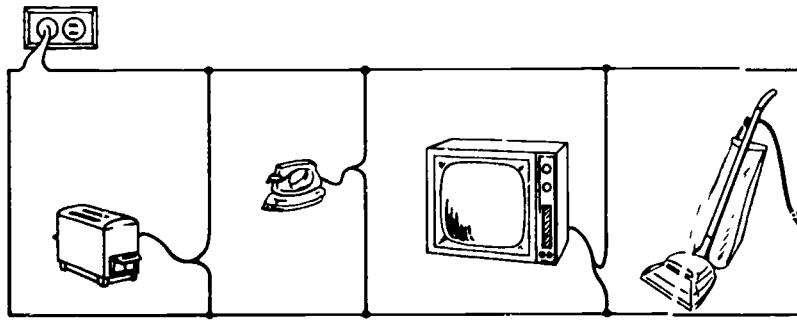


Figure 6-1. Pictorial drawing of an electrical circuit

*A typical experience.* Let's look at a situation that perhaps occurs all too often. A 15-ampere fuse blows in your home. You replace it—and it blows again. This time you replace it with one rated at 25 amperes. Good—the 25-ampere fuse doesn't blow, and all is well, at least for the time being.

A few weeks later, it's a rainy weekend and a good time to get some work done around the house. Your wife is ironing, one child is watching TV, another is using the toaster, and you are using the vacuum cleaner. Suddenly the house is on fire. You barely manage to get everyone out of the burning house. As you watch your home go up in flames, you ask, "What happened?"

Let's investigate. Figure 6-1 is a picture of the electrical circuit at the time the fire started. Figure 6-2 is a schematic of that circuit. Since we have a parallel circuit, the source voltage is applied across each device. Therefore, we can use Ohm's law to calculate the current through each leg and then add the individual currents to get the total current:

$$I_1 = \frac{E}{R_1} = \frac{110}{11} = 10 \text{ amperes}$$

$$I_2 = \frac{E}{R_2} = \frac{110}{11} = 10 \text{ amperes}$$

$$I_3 = \frac{E}{R_3} = \frac{110}{55} = 2 \text{ amperes}$$

$$I_4 = \frac{E}{R_4} = \frac{110}{44} = 2.5 \text{ amperes}$$

$$I_t = I_1 + I_2 + I_3 + I_4 = 10 + 10 + 2 + 2.5 = 24.5 \text{ amperes}$$

Do you see what happened? The 15-ampere fuse that was supposed to protect the circuit would have burned out when the current exceeded 15 amperes. The 25-ampere fuse did not burn out when the safe current value was exceeded. This fuse allowed the wires inside the wall, which are designed to safely conduct only 15 amperes, to get red hot and set the house on fire.

Perhaps you think that this example was overdramatized. Not at all. Fires caused by current overload happen every day, and all too frequently the cause is a "do-it-yourself" type of person who knows just enough to get himself into trouble.

A similar situation can occur in your radiology department. There are various fuses in your electrical equipment that can "blow" out. While it is a simple matter to replace a burned-out fuse with one of equal rating, that is not the proper course of action in all cases. Usually when a fuse blows, there is a reason, and the reason should be determined. There may be a short in the wiring or some other defect causing the increased current in the circuit. The circuit should be checked to determine the cause of the blown fuse before the fuse is replaced. Therefore, we recommend that you have the fuse replaced by a medical equipment repairman so that he can determine the cause and make the necessary repairs.

*The personnel hazard.* Now let's find out why a fuse that is capable of protecting the wiring or the equipment cannot protect you. Figure 6-3 illustrates a parallel circuit protected by a 15-ampere fuse. The total current in this circuit is  $I_1 + I_2 + I_3 = 14.5$  amperes. As you can see, we are within the safe limit

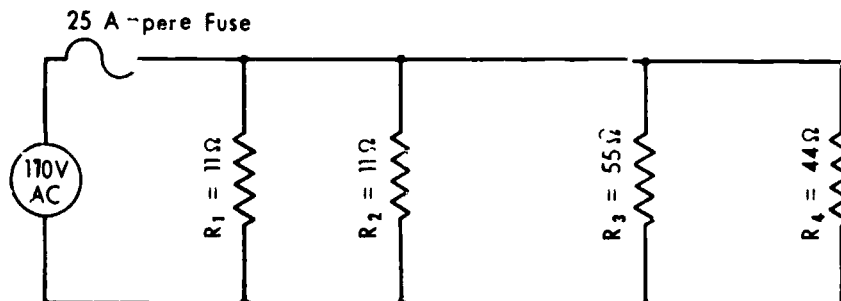


Figure 6-2. Schematic of an electrical circuit.



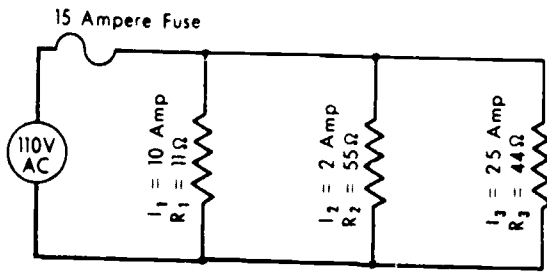


Figure 6-3. Representative parallel circuit.

for the circuit. Figure 6-4 demonstrates the identical circuit, but with your body forming an additional parallel connection. The electrical resistance of your body, measured from hand to hand, varies from less than 5,000 to over 20,000 ohms. This resistance depends upon whether your hands are dry or wet. If you are sweaty, the resistance goes down considerably, because salt is a good conductor. For example, let's assume that your body has a resistance of 11,000 ohms, so the circuit formed would look like that in figure 6-5, with the resistance of your body represented by  $R_4$ . By adding  $I_1 + I_2 + I_3 + I_4$ , we find the total current to be 14.51 amperes. You can see that this is still within the limits of the fuse. Therefore, the fuse would not burn out, *but the 0.01 ampere of current through your body could electrocute you!*

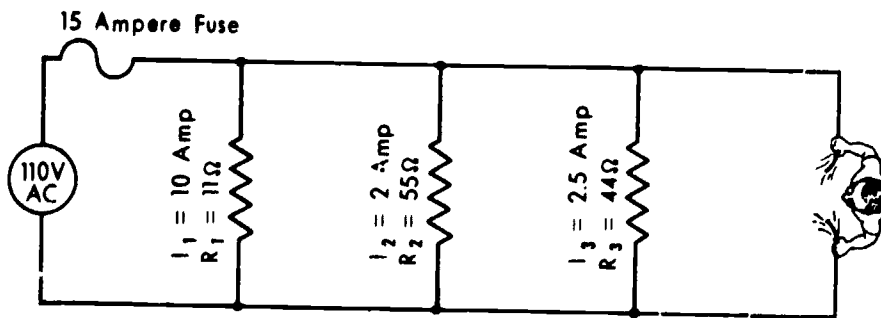


Figure 6-4. Representative parallel circuit with human body added as one element

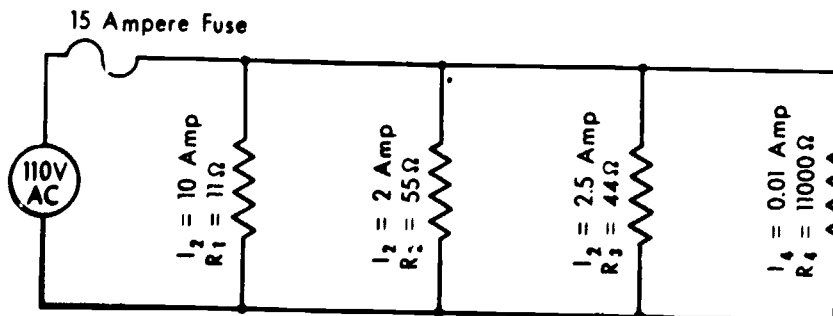


Figure 6-5. Representative parallel circuit with ohmic value of human body computed.

### Exercises (096):

Indicate whether the following statements are true or false. If you indicate false, explain your answer.

T F 1. A fuse is designed to stop the flow of electrical current if the fuse rating is exceeded.

T F 2. Fuses protect machine operators from electrical shock.

T F 3. Fire can result from incompatibility of the fuse and circuit wiring.

T F 4. A fuse protects a patient from electrical shock.

T F 5. Replacing a fuse with one of a higher rating is permitted as a temporary measure on an overloaded circuit.

T F 6. If a fuse burns out in your X-ray machine, you should replace it with one of equal rating and report the incident to your medical equipment repairman. You may continue to use the machine.

T F 7. Contact with an electrical circuit can be fatal even if the circuit is properly fused.

097. State the purpose, value, and effect of grounding an electrical appliance in given situations, and explain related safety practices.

**Grounding.** One of the most important considerations in providing protection for both you and your patient from electrical shock is proper grounding of the equipment. How does grounding protect you and the patient? Let's see.

*A typical electrical appliance.* Figure 6-6, A, shows the relationships between the power wires, ground wire, and the exposed housing of an electrical machine. Notice that the housing is isolated from the wiring.

The obvious reason for this is so that the machine operator will not be shocked when he touches the housing. In figure 6-5, B, we have shown an electrical connection between the hot wire and the housing. This connection could be due to worn insulation of the hot wire or to various other reasons. Now there is a possibility of current in the housing of the machine (even though it is not turned "on")—the part that you come in contact with when you operate the machine. However, chances are you still would not be "shocked" when touching the machine because the current, which divides at the "defect," is routed through the ground wire and to "earth" ground. The current flows to earth because the ground wire offers less resistance than your body, and the current takes the path of least resistance.

So far we don't have much of a problem. Even though there is a defect in the machine wiring, our ground is working properly, so the machine is relatively safe. But, suppose the machine is *not* grounded. Maybe there was no three-prong outlet available, and the ground prong of the power cord was removed so that the plug would fit into the two-prong outlet. Now there is no ground wire—no easy pathway to route the current away from the machine housing and operator (see fig. 6-6, C). However, you still probably would not receive a significant electrical shock because you still do not offer an easy path for the current. Your

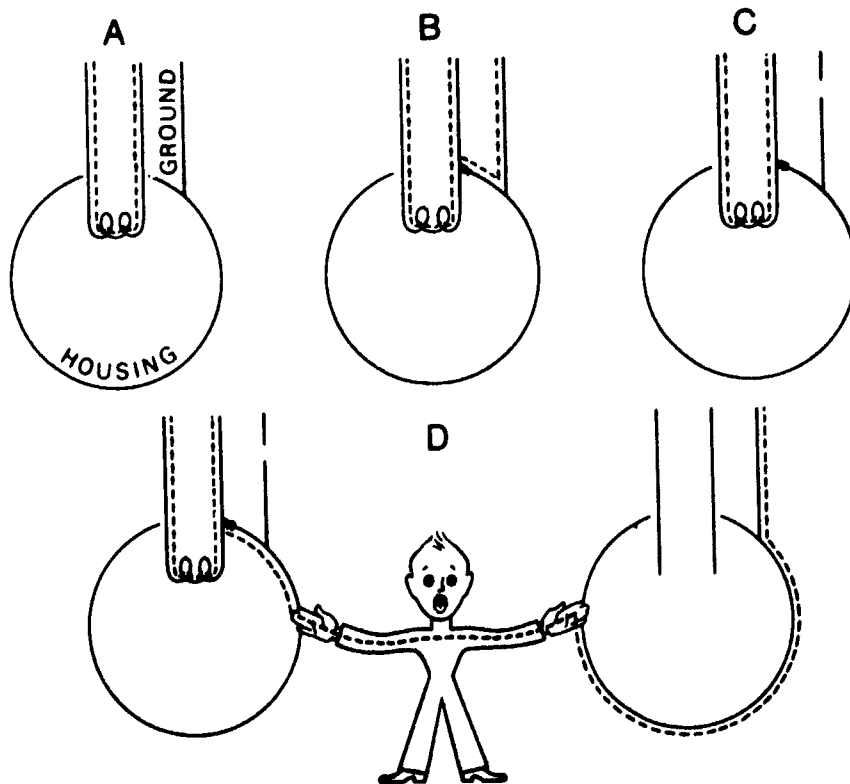


Figure 6-6. Schematics of an electrical appliance showing the relationship between live wiring, ground wire, and housing. The dotted line represents current flow.

body is most likely at the same potential as the machine.

The next variable that we shall add to this hypothetical situation is for you, the operator, to come in contact with another piece of electrical equipment while touching the housing of the initial machine (see fig. 6-6,D). Now the picture has changed considerably. You have connected your body to ground potential. A circuit is formed from the housing of the initial machine, through your body, through the housing of the second machine, and out the ground wire. You definitely are going to receive an electrical shock—the severity of which depends upon the factors previously discussed. Electrocutation is, of course, always possible if the conditions are right. (NOTE: If the initial appliance had been properly grounded, the current would actually “have a choice” of flowing through you to earth or through its own ground wire to earth. The easiest pathway would still be through its own ground wire because of your skin resistance.)

From the above discussion it is obvious that electrical equipment must be grounded, and it usually is—at least at the time of purchase. However, power plugs become old and defective (loose or bent), and power cords and other outside wires become frayed or cracked. Some people use “cheater plugs” to adapt a three-prong plug to a two-prong outlet; and some even cut the ground prong off the power plug.

Do not use electrical equipment if defects are present as we have described. In addition, do not alter power plugs, use “cheater adapters,” or do anything else that would interfere with the grounding of your machine.

Make a habit of checking the power plugs, power cords, or any other outside wiring about your equipment *often*. Such checking is especially important if appliances are often moved, thereby increasing the possibility of damage. If you find any defects in a piece of equipment, do not use it. Call your medical equipment repairman.

#### Exercises (097):

1. According to the text, what is one of the most important safeguards to protect you and your patients from electrical shock?
2. What electrical relationship exists between the circuitry and housing of an electrical appliance in good repair? Why?
3. If an electrical connection exists between a line circuit and the housing is properly grounded, would you be shocked if you touched the housing? Explain your answer.
4. If the situation in exercise 3 above exists with the exception that there is no good ground, would you receive an electrical shock from the housing?
5. Suppose you touch the housing of an electrical appliance that is not grounded. The housing is not isolated from a live circuit. At the same time, you touch a grounded X-ray machine that is not turned on. What would happen, if anything? Why?
6. List four things that you should look for to help prevent an electrical shock from your piece of electrical equipment.
7. What action should you take if you find any of the discrepancies in exercise 6 above?

098. Given a simulated situation of a patient undergoing an angiogram, evaluate the patient's susceptibility to electrocution.

*Grounding of equipment during angiography.* So far we have discussed electrical shocks from appliances through contact with the skin. There are cases in our radiology departments where the resistance of the skin is bypassed, such as during an angiogram. During such an examination, in which a catheter is inserted into the blood stream, it only takes approximately 1/1000 of the lethal skin current to produce ventricular fibrillation in the patient. During ventricular fibrillation, the heart flutters with a series of uncoordinated, rapid, weak pulsations—a condition that can be fatal.

If an angiogram is performed by using a commercial automatic injector, there is an almost perfect electrical conductor from the injector to the patient's heart—the contrast medium in the catheter. In fact, this patient is so susceptible to electrocution that we do not even need a defect in the wiring to introduce a fatal current into his blood stream. He can even be electrocuted by leakage current from an injector in good repair. Leakage current is an undesirable flow of current through or over the surface of an insulating material.

Let's look at a simulated situation and see where the danger comes from. Assume that the electrical machine we discussed in objective number 097 is an automatic injector and we are performing an angiogram. The patient is naturally lying on the X-ray table and film changer, which are grounded. Already he is a prime candidate for an electrical shock because he is grounded. Let's also assume that the injector is grounded. By grounded we mean, of course, that it is properly plugged into a grounded outlet and that there are no wiring defects or other defects.

From our previous discussion in objective 097, it would seem that the patient is still safe from electrical shock—even though he is grounded. Now we shall create the problem. The X-ray machine and the outlet supplying the injector are not grounded to the same ground potential. Because they are not grounded to a common ground, they may not be at the same potential. The difference in potential between the X-ray table or film changer and injector may be only a few volts. If the leakage from the injector to the contrast medium is, for example, 100 microamps, enough current can flow from the injector through the contrast medium in the catheter to the patient's heart to be fatal because the X-ray table and injector are not at the same potential. One hundred microamps is not very much current, but it is enough to cause ventricular fibrillation in this patient.

#### Exercises (098):

A patient who is about to have an angiogram is lying on the X-ray table and film changer. An automatic injector is in position and connected to a catheter that is inserted into the patient's arm and filled with a contrast medium. Using the information presented in the text, answer the following questions.

1. How much relative resistance does the patient's body offer to current flow? Why?
2. What fraction of the lethal skin current can electrocute this patient?
3. Is there any danger to the patient if the injector does not contain any wiring defects? Explain.
4. What electrical conductor exists between the injector and patient? Is the conductor a good one?

5. Comment on the ground status of the patient. Does this ground increase the possibility of current flow through the patient?
6. If the injector and film changer are not at the same ground potential, is this dangerous to the patient? Explain.

#### 099. List ways you can help create an electrically safe atmosphere for an angiographic patient.

How can you help protect your patient from electrical shock and possible electrocution? The first thing to do is to make sure that all the electrical equipment in the room is grounded to the same ground potential. This must be done by the medical equipment repairman. He may need to rewire the entire room so as to create an equipotential grounding system. Once the system is established, never ground a piece of equipment to anything else. This includes things like water pipes, which may not even be a good ground under normal conditions because nonconductive conduit is sometimes used below the ground.

Because of its importance we shall repeat here what we discussed earlier. Do not alter the power plugs, wiring, or anything else affecting the equipment ground. In addition, check *all* support equipment items in which the skin resistance is bypassed. Make sure that such items (examining lamps, film changers, etc.) are grounded through the use of three-prong, heavy-duty line plugs. And finally, *before each examination*, inspect the equipment for frayed line cords, broken plugs, deteriorated insulation, or other equipment defects.

#### Exercises (099):

In exercises 1 through 4 below, list four ways you can help create an electrically safe atmosphere for an angiographic patient.

- 1.
- 2.
- 3.

4.

**100. Cite typical electrical hazards present in the darkroom, and state safety precautions that you should take to avoid hazards.**

*Self-protection in the darkroom.* The darkroom is a likely place for you to receive an electrical shock. One reason for this is that when you process films manually your hands are often wet, and since water is a good conductor of electricity, your natural skin resistance is lowered. Water is also occasionally present on the floor, and this increases the possibility of your being at ground potential—especially if the floor is made of cement. Another factor involved is the manual processor itself. It is mostly likely grounded through the water pipes. Let's look at a couple of darkroom situations.

Suppose that with wet hands you are transferring films from the wash tank to the dryer. The dryer has a defective ground, and the dryer housing is not isolated from the powerline (another defect). As you transfer the films, you are in contact with both the processing tank and the dryer—perhaps by way of the film hangers in both cases. The dryer switch is turned on. You are now at ground potential, and chances are that, under these circumstances, you actually accidentally placed yourself "into" a circuit. Current would travel from the dryer housing, through a hanger to your body, through another hanger to the processor, and on to earth through the water pipes. See figure 6-7.

Let's assume instead that you are not in contact with the processing tank, but that you are standing in some water spilled on the floor. The same situation as that above occurs if the water also is in contact with the tank. See figure 6-8.

You can take several precautions to help prevent an electrical shock in the darkroom.

(1) Apply the "one-hand" rule. According to this rule, you should touch only one electrical appliance at a time to help prevent your body from being at ground potential. The processor is considered an electrical appliance (even if it contains no electrical devices, such as safelights) because it is probably grounded through the water pipes.

(2) Turn off the film dryer when loading and unloading.

(3) Turn off the power supply when changing safelights, etc.

(4) Dry your hands often and keep water off the floor. If the floor accidentally becomes wet, mop it immediately.

(5) Finally, report any electrical shocks, no matter how minor, to the medical equipment repairman so that appropriate repairs can be made.

#### Exercises (100):

1. Why may contact with the manual processor be dangerous to you?
2. Suppose you are transferring films from the wash tank to the dryer and are in contact with both units. Is this condition potentially dangerous? Explain.
3. What is the "one-hand rule," and how can using the rule help protect you from electrical shock?

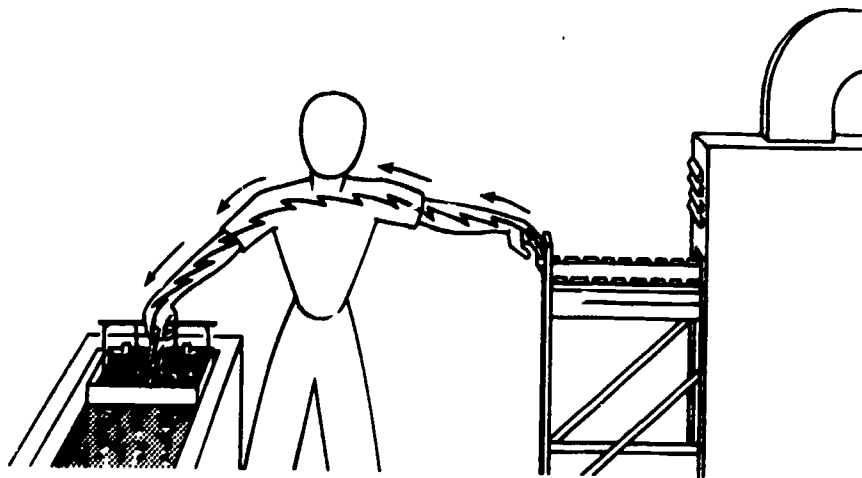


Figure 6-7. A dangerous situation that could exist in the darkroom. Use of the one-hand rule can prevent this from occurring.

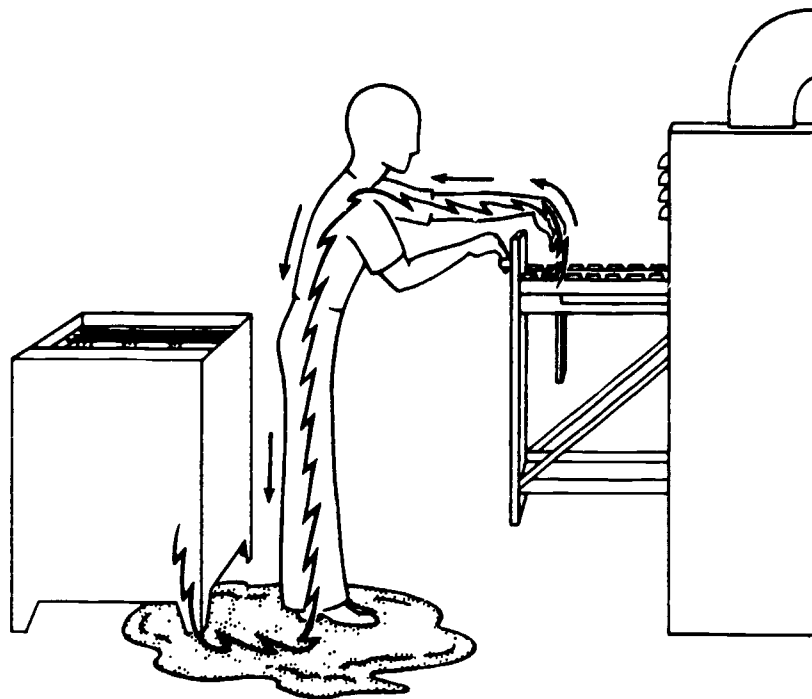


Figure 6-8 A dangerous situation that could exist in the darkroom. This can be avoided by keeping the darkroom floor dry.

4. Select the answer in column B that best fills in the blanks of each sentence in column A.

Column A	Column B
___ 1 The presence of water in the _____ increases your chances of receiving an electrical _____.	a Hangers, water; floor.
___ 2 To be potentially dangerous, contact between you and the processor need not be direct but can be through the processing _____ or _____ on the _____.	b. Darkroom, shock
___ 3 The darkroom floor should be kept _____ and _____.	c. Grounded, wet.
___ 4 The medical equipment repairman should be notified immediately if you experience a _____ or are _____ while using electrical equipment.	d Dry; clean.
	e Tingling sensation; shocked

101. Indicate whether statements pertaining to first aid procedures for a patient suffering from severe electrical shock are correct, and explain the statements that you indicate as "false."

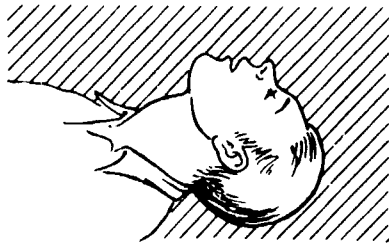
**First Aid for Electrical Shock Victims.** When a person comes into contact with a wire carrying electricity, many things can happen. The victim may be "frozen" to the circuit, or he may be knocked off his

feet. If both voltage and current are high and the victim is in position to provide a good path to ground, the results can be fatal.

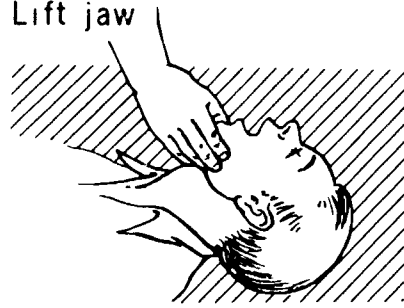
**Eliminating the source.** If someone does come into contact with a hot wire and is either frozen to the circuit or knocked unconscious, *turn the power off as quickly as possible.* If the switch is not close at hand or you cannot immediately find it, don't waste time looking. Remove the victim from the electrical source with a dry wooden pole, dry clothing, rope, parachute cord, or any other material that does not conduct electricity. If you use clothing, rope, or a cord, make it into a loop and put it over a foot, leg, or arm to drag the victim off the electrical source. Be careful not to make contact between the victim and any part of your body, or you, also, will become a victim. Severe electrical shock usually causes the victim to stop breathing, so artificial respiration must be initiated as soon as the victim is free from the electrical source.

**Artificial (mouth-to-mouth) respiration.** The success of mouth-to-mouth respiration often depends upon how soon it is started. Don't waste time moving the victim to an ideal location, and don't wait for mechanical equipment. To begin, place the victim on his back, use your fingers to clear his mouth and throat of any foreign matter, and make certain that he hasn't swallowed his tongue. Next, tilt his head backward so that he is more or less in a "sword-swallowing" position. (See fig. 6-9.) This will insure that his neck is not kinked and that there is a clear passage into his lungs. Then, approach the victim from his side and

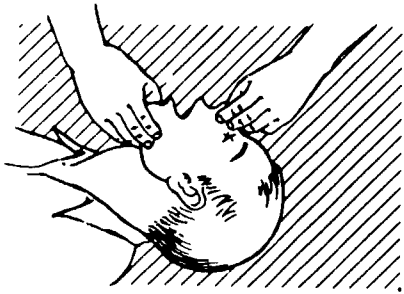
1. Thrust head backward



2. Lift jaw



3. Pinch nostrils



4. Blow into patient's mouth

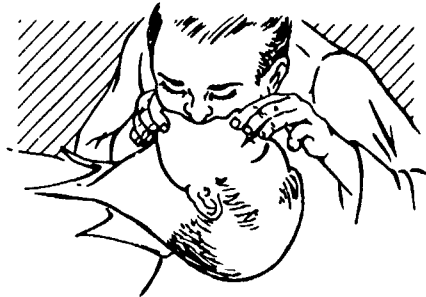

Figure 6-9 Mouth-to-mouth: respiration

hold his lower jaw up by putting your fingers under his chin and your thumb on his lower teeth. Finally, use your hand to close the air passages in the victim's nose. Take a deep breath and cover his open mouth with your own until there is an airtight seal. Blow forcefully into his mouth until his chest expands. This expiration should be done quite forcibly with adults but rather gently with children. Watch his chest as you expire. After the victim's chest rises, remove your mouth from his and allow him to exhale by himself. Repeat this action 12 to 20 times a minute. You may find that you are breathing faster than normal in order to get enough air for yourself. Actually, humans use only about 25 percent of the oxygen they inhale, so the victim is getting all he needs. Continue in a rhythmic manner and without interruption until the victim either starts breathing or is pronounced dead by a physician.

**Closed-chest heart compression.** If the patient's heart has also stopped beating, you must perform closed-chest heart compression in addition to mouth-to-mouth respiration, and again it must be started immediately after the power supply has been turned off or after the patient is removed from the source of electricity.

To perform closed-chest heart compression, kneel beside the patient, place the heel of one hand on the lower end of his sternum and your other hand on top. (See fig. 6-10.) Press downward with both hands at the

rate of one compression per second, as this rate approximates the normal heart rate. The sternum should depress  $1\frac{1}{2}$  or 2 inches. Lift your hands after each compression to permit the sternum to return to its normal position.

If two persons are available, one should perform mouth-to-mouth respiration, and the other should perform closed-chest heart compression. If you are alone, repeat 2 good breaths for every 15 compressions of the sternum.

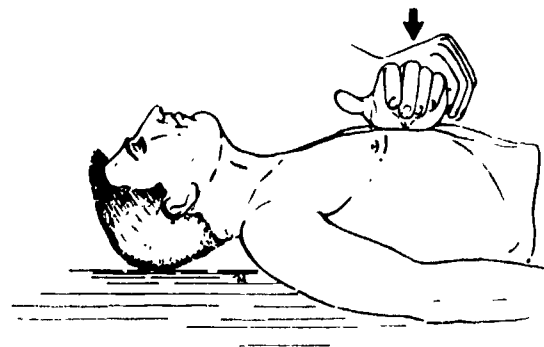


Figure 6-10 Closed-chest heart compression

### Exercises (101):

Indicate whether the following statements are true or false. If you indicate false, explain your answer.

- T F 1. When confronted with an unconscious electrical shock victim, the first thing you should consider is turning off the power supply.
- T F 2. You can be electrocuted yourself by touching someone who is in contact with a live wire.
- T F 3. You should separate an unconscious person from a live wire with the first thing you can get your hands on.
- T F 4. If they are needed, mouth-to-mouth respiration and closed-chest heart compression should be started immediately as soon as the victim is separated from the electrical current.
- T F 5. The position of the victim's head is not important for closed-chest heart compression or mouth-to-mouth respiration.
- T F 6. Your mouth should form an airtight seal over the victim's mouth during mouth-to-mouth respiration.
- T F 7. When performing mouth-to-mouth respiration, you should normally force air into the patient's lungs about 12 to 20 times a minute.
- T F 8. The sternum should be depressed 2 to 2½ inches during closed-chest heart compression.
- T F 9. The sternum should normally be depressed 60 times a minute during closed-chest compression.

- T F 10. If you are performing mouth-to-mouth respiration and closed-chest heart compression simultaneously on a patient, you should repeat cycles of 2 breaths followed by 15 compressions of the sternum.

### 6-2. Radiation Hazards and Protection for Patients

Responsibility for protecting yourself and your patients from needless exposure to radiation rests with you. Granted, health physicists, radiologists, supervisors, and others establish and maintain protective programs in the radiology department. As a 7 level, however, you will have considerably increased responsibilities in this area. You must not only use the appropriate safety precautions, but also insure that personnel under your supervision do likewise.

A good portion of this section is taken from AM 161-38, *Diagnostic X-Ray, Therapeutic X-Ray, and Gamma-Beam Protection for Energies Up To 10 Million Electron Volts*. For further information concerning radiation hazards and protection, refer to this manual.

#### 102. Indicate the purpose, types, and use of filtration of an X-ray beam.

**Protective Filtration.** We shall begin our discussion about patient protection with protective filtration. As you know, adequate filtration of the primary beam is one of the best ways to reduce the patient's exposure to radiation. Let's see how it works.

*Reduction of low-energy photons.* A beam of X-radiation is made up of photons with energies ranging from the kVp setting used to near zero. Many of these photons in the low-energy range are absorbed by the patient's skin and other body tissues. These "soft" photons contribute nothing whatsoever to the film exposure. All they do is increase the patient's exposure, which we obviously do not want. We cannot prevent the low-energy photons from being produced in the target of the X-ray tube, but we can remove most of them before they reach the patient. We do this by filtering the primary beam.

*Types of filtration.* The filters placed between the target and patient are broken down into two types, inherent and added. The first, *inherent* filtration, is that filtration provided by the tube housing. You actually have no control over this filter, since it is a permanent part of the X-ray tube. However, you should be aware of the aluminum equivalency of the inherent filtration for each of your X-ray machines. It is usually 0.5 mm unless the tube has a beryllium window. When the latter is the case, it is normally 0.3 mm. If you are not sure of the amount, check with the



tube manufacturer. The second, *added* filtration, makes up the remainder of the total filtration in the X-ray beam. This type of filtration is simply what we would add to the port of the X-ray tube. Inherent filtration plus added filtration equals *total* filtration.

*Minimum filtration requirements.* You must have a minimum amount of total filtration in the X-ray beam. The minimum aluminum equivalency depends upon the operating kVp and is shown below:

kVp	Minimum Total Filtration
Below 50	0.5 mm aluminum
50 to 70	1.5 mm aluminum
Above 70	2.5 mm aluminum

For example, when you use 80 kVp, you must have a total of 2.5 mm aluminum filtration.

*How filtration increases the mean energy of the beam.* In figure 6-11 we have shown the energy distribution of four beams of X-radiation plotted against the intensity of the beams. Progressively more filtration is added, beginning with the top added filtration curve. Notice that the more filtration added, the fewer the number of low-energy photons, and the less the minimum photon energy of the beam. Consequently, by adding filtration, we are increasing the mean energy of the X-ray beam.

#### Exercises (102):

1. What happens to the low-energy photons that do not reach the X-ray film?
2. How does filtration lower the patient's exposure?
3. What is inherent filtration? How much is normally provided in an X-ray tube?
4. If an X-ray tube has 0.3 mm aluminum equivalency of inherent filtration, how many millimeters of aluminum should be added to operate the tube at 26 kVp?
5. How much total filtration should be in the X-ray beam if 65 kVp is used?
6. If the inherent filtration of an X-ray tube is 0.5 mm, how many millimeters of aluminum should be added to operate the tube at 120 kVp?
7. How does filtration of the beam of X-ray photons increase the beam's mean energy?

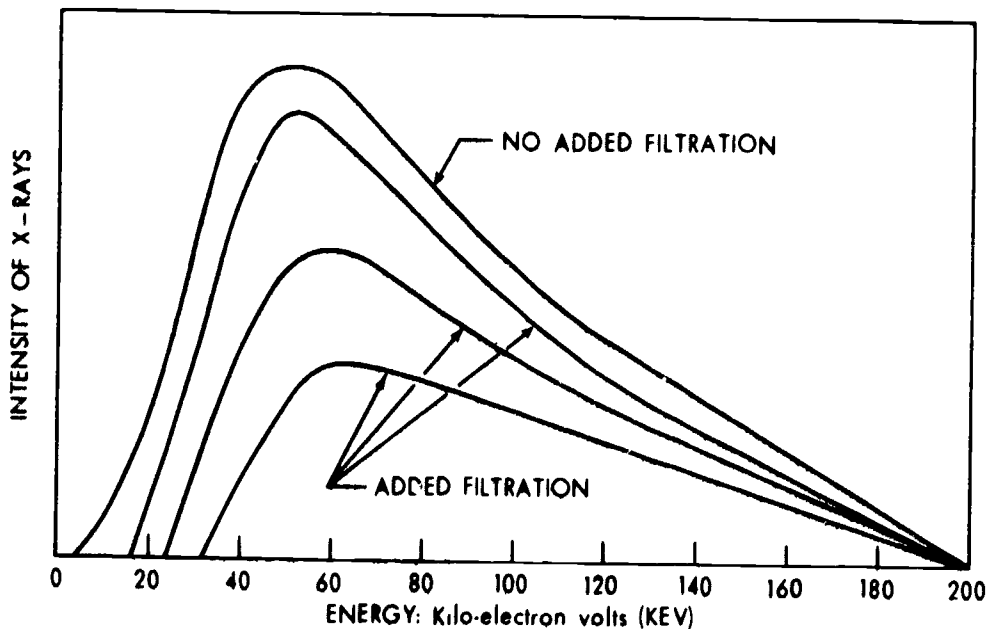


Figure 6-11. Filtration of X-ray photons.

**103. State three ways in which high kVp techniques reduce patient exposure.**

**High kVp Techniques.** We have just discussed how filtration reduces patient exposure by increasing the mean energy of the primary beam. It is not practical, however, to increase the filtration very much beyond the minimum requirements to further reduce patient exposure. The reason for this is that filters work well up to a certain point, but then reduction in patient exposure with more filtration diminishes rapidly.

There is another way to reduce patient exposure by increasing the mean energy of the beam—simply by using high kVp techniques. By high kVp we do not mean 100 kVp or 150 kVp. We mean the highest kVp that produces a radiograph with sufficient density and contrast to adequately demonstrate the anatomical structure under study.

Let's look at a typical examination of the knee. If you presently use 60 to 70 kVp, you may very well be able to increase the kVp to 80 to 90 and still maintain satisfactory contrast. Eighty to 90 kVp is not considered high, but it is higher than you previously had used, and you have taken a positive step in reducing exposure to your patient.

Aside from reducing patient exposure by increasing the mean energy of the beam, high kVp works in two other ways to reduce patient exposure: (1) it permits shorter exposure times—which helps prevent repeat examination due to part motion, and (2) it also provides more exposure latitude, which also helps to prevent repeat examinations due to incorrect exposure factors. Of course, any action that reduces the repeat radiographs also helps to keep patient exposure to a minimum.

**Exercises (103):**

In the exercises below, write down three ways in which high kVp techniques reduce patient exposure.

- 1.
- 2.
- 3.

**104. List two ways that proper collimation reduces patient exposure, and indicate the basic procedure for checking the collimation of a radiograph.**

**Collimation.** One of the best ways to keep patient exposure to a minimum is by restricting the primary

beam to the smallest area consistent with clinical requirements. Exposure of the patient to radiation in areas beyond the part under study is in most cases inexcusable. We emphasize "in most cases." For example, consider a vertebral examination. Ideally, you should collimate to the vertebrae; however, on occasion it may be necessary to include peripheral visceral structures as well.

Checking for collimation is an important part of your quality control duties. You should see the limits of the radiographic field on the film. The size or condition of the patient has no bearing on collimation. For example, consider an abdominal examination on an extremely large patient. If you collimate larger than the inside of the 14 x 17 film, diagnostic information is not added to the film; in fact, it is degraded. The larger field not only increases radiation exposure to the patient but also scatters radiation to the film, thereby increasing film fog. This increase in film fog degrades the image, which could necessitate a repeat. Another example: skull radiographs on a child. Some technicians will collimate to 10 x 12 or a little larger. The reason that if the child moves, the skull will still be on the film and not cut off by collimation. While this is probably true, the radiograph will still have to be repeated due to motion. Restraint devices should be used, not excessive collimation. These are only two examples. Surely you can think of others. The important thing is that you should see the limits of the field on the film. If you can't, you cannot be sure whether the field extends 1 inch or 10 inches beyond the film.

**Exercises (104):**

1. State two ways in which proper collimation reduces patient exposure?
2. As a general rule, what should you look for on a radiograph to insure proper collimation?
3. If you do not see any indications of collimation on a radiograph, what can you assume about the size of the X-ray field?

**105. Name several examinations in which gonadal shielding can be used, and specify two precautions to take when using the shielding.**

**Gonadal Shielding.** To prevent needless exposure of the patients' gonads, you should cover them with pieces of lead-rubber shielding material. For example,

gonadal shielding can be used for hip examinations if you are careful with the placement of the shield. You can also shield the gonads of femur and lumbar spine examinations of male and female patients and abdomen, intravenous pyelogram, sacrum, and coccyx studies of male patients.

The most important consideration when using gonadal shielding is to make sure that the shield is not superimposed over the part under study. In addition, do not use gonadal shielding as a substitute for adequate beam collimation. Use the shield *in addition to* collimation.

**Exercises (105):**

1. Name three examinations in which gonadal shielding can be used on male and female patients.
2. Name four examinations in which gonadal shielding can be used on male patients only.
3. What two precautions should you observe when using gonadal shielding?

**106. Describe the effect and use of high-speed screens and films to reduce patient exposure.**

**High-Speed Screens and Films.** Using high-speed intensifying screens and X-ray films can also reduce patient exposure to radiation by lowering the exposure necessary to produce the radiograph. Keep in mind that there is a loss of detail when high-speed films and screens are used.

At times it may be advantageous to use high-speed screens for most examinations and to use the medium- or slow-speed for radiographs of parts requiring maximum detail, such as the mastoids. In cases such as this, make sure that the cassettes are plainly identified so that, for example, high-speed exposure factors are not used with slow-speed screens.

**Exercises (106):**

1. Why is patient exposure reduced if high-speed intensifying screens and films are used?
2. What must be sacrificed if you use high-speed intensifying screens and films?

3. How can you maintain good screen detail for some examinations and keep patient exposure to a minimum for others?

**107. Given characteristic curves of three identical X-ray films, relate developing time to patient exposure.**

**Film Processing.** A common cause of excessive patient exposure is improper film development. To illustrate how film development affects patient exposure, we have shown in figure 6-12 the characteristic curves of three identical films processed under different conditions. Film A was developed as recommended by the film manufacturer for a period of 5 minutes at 68° F. Film B was developed under the same conditions but for only 3 minutes. Film C also was developed under the same conditions but for only 1½ minutes. Now, let's analyze the results of figure 6-12. At the bottom of the curve, you will notice that the log relative exposure is in increments of 0.3 and also that each increment of 0.3 is equivalent to doubling the mAs. Next, assume that your radiologist wants films taken at a certain kV voltage with a maximum density of 2.0. To reach this density, film A would need 11 mAs, film B would require 40 mAs, and film C approximately 270 mAs. Can you now see why proper developing becomes so very important in reducing radiation dosage to the patient? The film developed at 1½ minutes requires 24 times the exposure of film A.

**Exercises (107):**

1. According to figure 6-12, what developing time requires the most exposure to produce a specific density?
2. According to figure 6-12, what developing time requires the greatest patient exposure to produce a particular radiograph?
3. What can you conclude from the discussion about developing time vs. patient exposure?
4. What developing time should you use for all your radiographs?

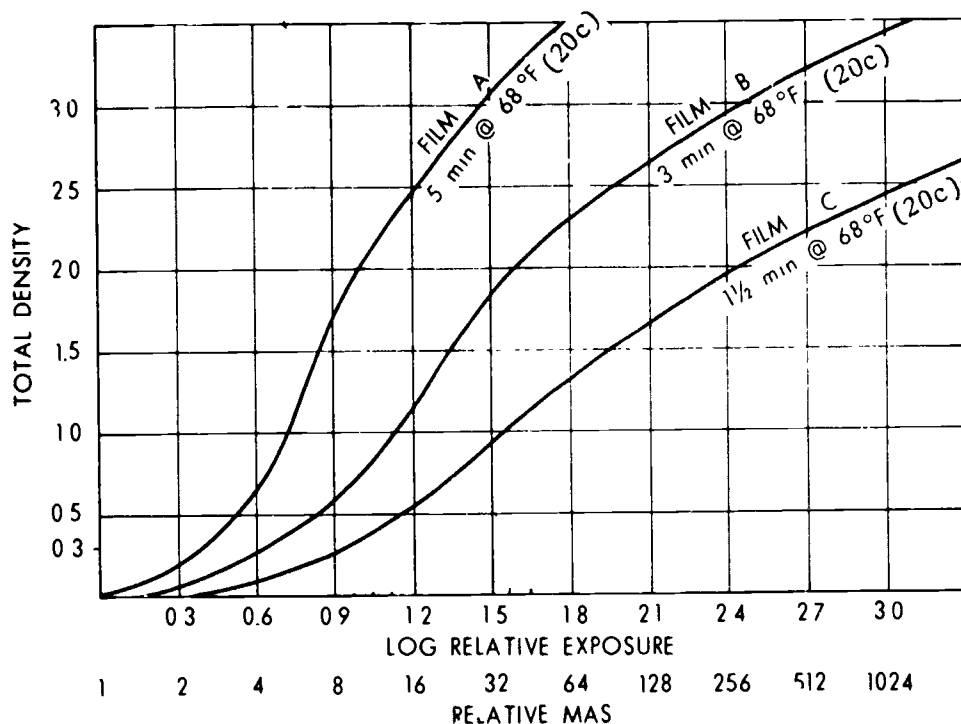


Figure 6-12. Characteristic curves of several identical films.

### 6-3. Radiation Hazards and Protection for Technicians

Good working habits, commonsense, and proper respect for ionizing radiation are very important in radiation protection. With present-day knowledge and the vast amount of protective resources at your disposal, there is absolutely no reason for you to even closely approach the maximum permissible dose. If proper precautionary measures are practiced daily, the risk involved in being a radiologic technologist is small when compared to such other risks as driving a car or crossing the street. The steps necessary to keep your exposure at a minimum can be divided into two categories: (1) those that protect you from the primary beam and (2) those that protect you from scatter radiation.

108. List four rules to follow to protect yourself from exposure to radiation.

**Protection from the Primary Beam.** Protecting yourself from primary radiation is very simple: do not expose any part of your body to the primary beam. This means that during exposure you should never hold a patient or cassette, or in any other way subject yourself to primary radiation. In addition, you should not allow another technician to perform these tasks. If assistance is needed to obtain a radiograph on uncooperative patients, use someone who is not occupationally exposed to ionizing radiation.

**Protection from Scatter Radiation.** Although the intensity of scatter radiation is less than primary radiation (for a given technique), the radiation hazard to the technician is perhaps greater with scatter. The reason for this is that scatter radiation can reach virtually all parts of the exposure room, while the primary beam is restricted to an area that is much smaller by comparison. Therefore, while it is a simple matter to remain clear of the primary beam, it is somewhat more difficult to elude scatter radiation. Following are some general rules to adhere to.

*Standing behind a protective barrier.* Always remain behind a protective barrier when making an exposure. Control booths are designed so that the technologist will not be exposed to any radiation that has scattered only once. In other words, the radiation must scatter at least twice before it reaches you. Use the lead impregnated glass window to observe the patient. Do not defeat the purpose of the control booth by leaning out from behind the barrier to make the exposure.

*Using distance for protection.* Distance is an effective means to reduce exposure. Since radiation intensity decreases as the distance from the source increases, exposure can be reduced by staying as far from the source as possible. This rule is particularly important to remember when you are taking portable radiographs, where protective barriers are usually not available.

*Protection during fluoroscopy.* During fluoroscopy, be sure to wear a protective apron. When you are not needed to assist the radiologist, remain in the control booth.

### Exercises (108):

In exercises 1 through 4 below, list four rules to follow to protect yourself from exposure to radiation.

- 1.
- 2.
- 3.
- 4.

### 6-4. The Personnel Dosimeter

The purpose of the USAF personnel dosimeter is to measure and record the accumulative dose of ionizing radiation to radiation workers like yourself. Let's begin our discussion with your responsibilities concerning the dosimeter. (NOTE: This section is based on AFR 161-28, *Personnel Dosimetry Program and the USAF Master Radiation Exposure Registry*. Refer to this regulation for additional information concerning the dosimetry program.)

### 109. Identify your responsibilities pertaining to the USAF Personnel Dosimetry Program.

**Supervisor Responsibilities.** Your responsibilities concerning this program are fairly simple—but important. If you are acting in the capacity of a supervisor, you must see to it that each person under your supervision is thoroughly indoctrinated in the proper use of the dosimeter. When a new technician is assigned to your department, go over the procedures with him. Do not assume that he already knows how and when to wear the dosimeter just because he has been in radiology for some time.

**Technician Responsibilities.** You are responsible for the proper use of the dosimeter issued to you.

### Exercises (109):

State your responsibilities, both as a technician and as a supervisor, pertaining to the dosimetry program.

1. Supervisor responsibilities.
2. Technician responsibilities.

110. Indicate whether statements pertaining to wearing and handling of the dosimeter are correct, and explain those that you indicate as "false."

**Wearing and Handling the Dosimeter.** There are certain problems that we will discuss that involve both the wearing and the handling of dosimeters. Our discussion will include dosimeter choice, when and where they are to be worn, and storage areas.

**Chest dosimeter.** The regular chest dosimeter (film badge) is worn below the shoulders and above the waist on the outside of the clothing. If you wear a lead apron, wear the dosimeter beneath the apron but still outside the clothing. The film must face outward from the body with the clip on the holder facing toward the body. This dosimeter, which we will call the chest dosimeter, is worn at all times during radiography, therapy, or fluoroscopy to measure whole-body exposure.

**Fluoroscopic dosimeter.** In addition to the chest dosimeter, you must wear an additional dosimeter during fluoroscopy. Wear this fluoroscopic dosimeter only on your front collar outside the protective apron. Its purpose is to assess the radiation exposure to the head and to the lens of the eye.

**Localized exposure dosimeters.** Additional dosimeters can be worn in certain situations, as during fluoroscopy, to assess localized exposures, such as to the neck or forearm. When wearing these additional dosimeters, be sure to wear the other required dosimeters.

Keep in mind that each dosimeter has a specific purpose. Consequently, during a specific reporting period, you shouldn't interchange the dosimeters. For example, the chest dosimeter should not be worn on other areas of the body. Also, if a dosimeter is used to record exposure to a localized area, it must not be worn at any other body site unless the dosimeter film is changed.

**Where to wear the dosimeters.** You must clip on the dosimeter(s) before entering the working area and remove it when leaving. The working area, as far as radiology departments are concerned, is the entire department. This means that you can wear the dosimeters anywhere inside the department. This also means that you cannot wear the dosimeter outside the department (except, of course, when you are performing portable radiographs).

**Dosimeter storage area.** While dosimeters are not being worn, they must be stored in a storage area designated by the commander of the facility. The storage area should be near to, but outside the radiation area. Radiation area, in this case, refers to the exposure-therapy rooms. For convenience, it is advisable to locate the storage area near the entrance of the department, thereby encouraging technicians to deposit or remove the dosimeter as they leave or enter the department.

*Identifying the dosimeters.* To insure that each technician wear only his own dosimeter, it should contain some individual identification, with the corresponding identification placed at a given location on a dosimeter storage rack. Do not permanently inscribe the identification on the dosimeter. Use embossing tape or other similar means to identify the dosimeter. You can identify the dosimeter on the front surface as long as the small window is not covered. To cover the window may cause false (lower than normal) readings.

**Exercises (110):**

Indicate whether the following statements pertaining to wearing and handling the dosimeter are true or false. If you indicate false, explain your answer.

- T F 1. The chest dosimeter can be worn attached to a shirt pocket.
- T F 2. The chest dosimeter can be worn attached to the belt.
- T F 3. The chest dosimeter is not worn during fluoroscopy.
- T F 4. At least two dosimeters must be worn during fluoroscopy.
- T F 5. During fluoroscopy, one dosimeter is worn beneath the apron, and one is worn outside the apron.

T F 6. The fluoroscopic dosimeter assesses whole-body exposure.

T F 7. When wearing a localized exposure dosimeter, you do not have to wear the chest dosimeter.

T F 8. The fluoroscopic dosimeter can be used to assess exposure to the hands.

T F 9. You cannot wear a dosimeter outside the radiology department.

T F 10. Dosimeters can be stored in an exposure room.

T F 11. Individual identification of dosimeters should be made on the dosimeter and on the storage rack.

T F 12. Identification should not be placed on the front of the dosimeter.

T F 13. At least three dosimeters must be worn to measure whole-body exposure.

## ANSWERS FOR EXERCISES

### CHAPTER I

**Reference:**

- 001 - 1. 1. Orbital shell.  
2. Proton.  
3. Electron.  
4. Nucleus.  
5. Neutron.

002 - 1. Matter to other matter, energy to energy, matter to energy, and energy to matter.

002 - 2. Matter and energy can be neither created nor destroyed.

003 - 1. Removal of an orbital electron from its shell.

003 - 2. It is integrally related to radiation production, film exposure, and biological damage due to radiation.

004 - 1 c

004 - 2. d.

004 - 3. a.

004 - 4. c.

004 - 5. b.

004 - 6. d.

004 - 7. c.

005 - 1. The flow of electrons through a conductor.

005 - 2. Difference between electrostatic charges, difference in potential, and resistance.

006 - 1. An insulator is a poor conductor of electricity, a conductor is a good conductor of electricity, and a semiconductor is neither a good conductor nor a good insulator.

- 006 - 2. a. Conductor.  
b. Semiconductor.  
c. Insulator.  
d. Semiconductor.  
e. Conductor.  
f. Conductor.

007 - 1. T.

007 - 2. T.

007 - 3. F. Under the conditions described, 0.33 ampere of current is flowing.

007 - 4. F. The symbol  $I$  refers to the intensity of current, or amperes, or coulombs per second.

007 - 5. T.

007 - 6. T

007 - 7. F. They are the same.

007 - 8. F. Voltage can exist between two positive charges if one is more positive than the other.

007 - 9. F. Current flows from negative to positive.

007 - 10. T.

008 - 1. The opposition to current flow.

008 - 2. Ohm.

008 - 3. That amount which allows exactly 1 ampere of current to flow when 1 volt is applied across the resistance.

008 - 4.  $R = 4\Omega$ .

009 - 1. No.

009 - 2. Less, more.

009 - 3.  $2\Omega$ .

009 - 4. Resistance depends upon the number of electron collisions, and the length of a conductor influences the number of collisions.

009 - 5.  $0.5\Omega$ .

009 - 6. Yes; increase.

009 - 7. Temperature.

010 - 1. 1. Crossed over wires.

2. Connected wires.

3. Battery.

4. Lamp.

5. Fixed resistor.

6. Voltmeter.

7. Switch.

8. Ground

9. Ammeter.

10. Fuse.

11. Variable resistor.

011 - 1.  $22\Omega$ .

011 - 2. 110 volts.

011 - 3. 3 amperes.

012 - 1. 0.5A; 0.5A; 0.5A.

012 - 2.  $24\Omega$ .

012 - 3. 6V; 2V; 4V.

013 - 1. 12V; 12V.

013 - 2. 4A; 6A; 12A; 2A.

013 - 3. 24A.

013 - 4.  $0.5\Omega$ .

014 - 1.  $7.8\Omega$ .

$$\text{Explanation: } \frac{1}{R_t} = \frac{1}{R_1} + \frac{1}{R_2} + \frac{1}{R_3}$$

$$\frac{1}{R_t} = \frac{1}{2} + \frac{1}{2} + \frac{1}{4}$$

$$\frac{1}{R_t} = \frac{5}{4}$$

$$5R_t = 4$$

$R_i = 0.8\Omega =$  equivalent resistance of the three parallel resistances

$$7\Omega + 0.8\Omega = 7.8\Omega$$

- 015 - 1. A force that attracts iron, steel, or other magnetic substances  
015 - 2. Around and inside the magnet.  
015 - 3. Outside the magnet, from the north pole to the south pole; inside the magnet, from the south pole to the north pole.  
015 - 4. The concentration of lines of force.  
015 - 5. Like magnetic poles repel each other; unlike poles attract each other.
- 016 - 1. Magnetic substances are strongly affected by a magnetic field; nonmagnetic substances are not noticeably affected.  
016 - 2. Magnetic: iron and steel. Nonmagnetic: wood, copper, and glass  
016 - 3. a. T  
b. T  
c. T
- 017 - 1. Current flow must be present through the conductor.  
017 - 2. No. Form the wire into one or more loops  
017 - 3. At each side of the coil.
- 018 - 1. The number of coil turns per inch. The higher the number of turns, the stronger the field.  
018 - 2. Current through the conductor. The higher the current, the stronger the field.  
018 - 3. Iron core. The core itself becomes magnetized, and its strength is added to that of the coil; and the core strengthens the field because lines of force concentrate themselves in the core.
- 019 - 1. T.  
019 - 2. T.
- 020 - 1. Fixed.  
020 - 2. Relay.  
020 - 3. Magnetic.  
020 - 4. Electromagnet; pivoting  
020 - 5. Opened; spring.
- 021 - 1. Electromagnetic effect.  
021 - 2. Permanent-magnet, moving-coil movement.  
021 - 3. Two: permanent and electromagnet.  
021 - 4. When current is introduced into the coil, the poles of the electromagnet attempt to repel the same poles of the permanent magnet.
- 022 - 1. a, b.  
022 - 2. a.  
022 - 3. b.
- 023 - 1.  $1/120$  second.  
023 - 2. No. When the sine wave reaches zero value, there is no current flow.  
023 - 3.  $1/240$  second (half a cycle).  
023 - 4. Two.  
023 - 5. One.  
023 - 6. The number of cycles per second.
- 024 - 1. The process of producing an EMF from the relative motion between a conductor and a magnetic field.  
024 - 2. A conductor, a magnetic field, and relative motion.  
024 - 3. The more lines of force that are cut per unit time, the higher the induced EMF.  
024 - 4. The more conductors, or number of turns in a coil, the higher the induced EMF.
- 025 - 1. T.  
025 - 2. F. Both self-induction and mutual induction do so  
025 - 3. T
- 026 - 1. The process of transferring electrical energy from one circuit to another by electromagnetic induction  
026 - 2. 11 volts, 50 amperes.  
026 - 3. 660 volts, 1 ampere.
- 027 - 1. To vary the kilovoltage output of the high-tension transformer and to regulate the supply voltages for operating the X-ray generator.  
027 - 2. Adjusting the auto transformer line voltage compensator control so that a predetermined reading is obtained on the line voltage compensator meter.  
027 - 3. The exposure will be lighter or darker than normal because the voltage across the X-ray tube is not consistent with the setting on the control panel  
027 - 4. The kVp major and minor selectors, which are located in the secondary side of the autotransformer.
- 028 - 1. a, b.  
028 - 2. a.  
028 - 3. c, d.  
028 - 4. a.  
028 - 5. c.  
028 - 6. b.  
028 - 7. a.  
028 - 8. d.
- 029 - 1. Voltage ripple is the difference between the minimum and maximum voltage of a single waveform pulse.  
029 - 2. The average kinetic energy of the electrons across the X-ray tube.  
029 - 3. Three-phase, 12-pulse.  
029 - 4. Slightly higher with 12-pulse  
029 - 5. Considerably higher with six-pulse.
- 030 - 1. The higher the average electron energy, the higher the average photon energy.  
030 - 2. Average photon energy is higher with three-phase  
030 - 3. Three-phase.
- 031 - 1. The intensity is greater with three-phase.  
031 - 2. With single-phase there is (1) a period of time when non-image-forming radiation is produced and (2) a period of time when no radiation is produced. With three-phase, image-forming radiation is continuously produced.
- 032 - 1. 106 kVp.  
032 - 2. It will maintain approximately the same scale of contrast and keep the patient's absorbed dose to a minimum.
- 033 - 1. Three-phase. There are no "hot spots" on the target, resulting in a more even thermal load.  
033 - 2. Approximately equal.  
033 - 3. Greater with single-phase.
- 034 - 1. To aim or focus the electrons to a specific area on the anode.  
034 - 2. Filament.  
034 - 3. Length.  
034 - 4. Large.  
034 - 5. The state of the filament when it is heated to the required emission temperature.  
034 - 6. Use the STANDBY button only when necessary and then only for a short period of time.
- 035 - 1. The anode is positively charged with respect to the cathode.  
035 - 2. Target.  
035 - 3. Because it has a high melting point and high atomic number.  
035 - 4. Its size affects the heat-loading capacity of the tube.  
035 - 5. (1) The size of the actual focal spot and (2) the angle of the target.



- 035 - 6 Basically, it is a design characteristic of an X-ray tube that produces a relatively large actual and relatively small effective focal spot
- 035 - 7. The smaller the target angle, the smaller the X-ray field, consequently, the field covers a smaller X-ray film at a specific FFD.
- 035 - 8. 12°.
- 035 - 9 A biased focal spot. It eliminates the concentration of electrons on the outer sides of the target, thus preventing a "double image" on the radiograph
- 036 - 1. Shorter exposures. The exposure can be synchronized to a particular portion of the sine wave.
- 036 - 2 Less radiation to the patient. (1) Exposures can be short enough so that portions of the wave that produce low energy are not used, and (2) X-ray exposures can be synchronized with cine camera shutters so that radiation is produced only when the shutter is open.
- 037 - 1. 1,600 H.U.
- 037 - 2. 1,498 H.U.
- 038 - 1. 200
- 038 - 2. 50
- 038 - 3. 1/20 sec
- 038 - 4. a Yes.  
b. No.  
c. Yes.
- 038 - 5. 110.
- 038 - 6. 125
- 038 - 7 0.05 sec.
- 038 - 8. a. No.  
b Yes.  
c No.
- 039 - 1 Yes
- 039 - 2. No. The factors listed require 52 exposures at 2,000 H.U. The chart allows only 50 exposures.
- 039 - 3. No. The factors listed require 6 exposures at 9,600 H.U. The chart allows only 5 exposures.
- 040 - 1. None. Explanation: 140,000 H.U. + 140,000 H.U. = 280,000 H.U. Capacity is 300,000 H.U.
- 040 - 2. Approximately 3½ minutes.
- 040 - 3. Indefinitely.
- 040 - 4. 8 minutes
- 040 - 5. Four.
- 043 - 1 The intensity of radiation in the primary beam is inversely proportional to the square of the distance from the target
- 043 - 2. 800; 50
- 043 - 3. No. Intensity as affected by the inverse square law has nothing to do with the number of photons emitted from the target. It is concerned with the number of photons per unit area
- 043 - 4. There is no connection between the two (at least not with the distances used in diagnostic radiology)
- 044 - 1. Longitudinal; anode heel effect.
- 044 - 2. Farthest
- 044 - 3 Anode.
- 044 - 4. Increases, decrease
- 044 - 5. 32°.
- 044 - 6. Cathode
- 044 - 7. Absorption; target material
- 045 - 1 a. Room #1.  
b. Since the difference between the sizes of the upper and lower portions of the thoracic spine is greater than normal, you would need the tube with the greatest variation in intensity to balance out the density on the radiograph. The 12° provides the greatest variation.  
c. Room #2.  
d. With his head toward the anode side of the tube
- 045 - 2. a. Any of the rooms could be selected.  
b. For spot-films of the gallbladder, you would only use the small central portion of the X-ray field. The variation in intensity for such a small area is negligible.
- 045 - 3 a. With the ankle toward the anode.  
b. The portable. At a 30-inch FFD, the beam intensity varies more.
- 046 - 1. F A small focal spot gives better detail.
- 046 - 2. F. A large focal spot produces more penumbra
- 046 - 3. F. The more penumbra, the worse the detail.
- 046 - 4. F. Penumbra is greatest on the cathode side.
- 046 - 5. F. Radiographs do have better detail on the anode side, but the reason has nothing to do with distance from the target. That portion is projected by a smaller focal spot.
- 047 - 1. Room #1. Room #2.
- 047 - 2. The 1.5 mm in room #1 because it has the smallest focal spot of the four able to withstand the exposure.
- 047 - 3. Your initial thought should be on the smallest focal spot you have available (0.2 mm in exposure room #1), since detail is most important on this examination. If the exposure factors do not exceed the rating of the 0.2-mm focal spot, it should be used. If you cannot safely use the 0.2 mm, check the exposure against the next largest focal spot (0.5 mm in room #2), and so on, until you find the smallest focal spot that can withstand the exposure. Remember, even though detail is important, do not exceed the maximum rating of the tube-rating chart.
- 048 - 1 The right lateral. The part-film distance for the right side would be less than for the left side; therefore, there would be less magnification and better detail of the right parietal bone.
- 048 - 2. a. Radiograph B.  
b. The posterior ribs of radiograph A.  
c. Radiograph B.
- 048 - 3. You could decrease the FFD. A shorter FFD increases magnification and therefore decreases detail.
- 048 - 4. The right lateral. It places the right lower lobe closer to the film, thereby providing better detail of that area.
- 048 - 5. An increase in FFD. Increased FFD increases detail.
- 049 - 1. Keep it to a minimum, but use it when necessary.
- 049 - 2. Yes. At times distortion is necessary to project a part clear of superimposed structures.
- 049 - 3. Perpendicular to a plane of the part and film.

## CHAPTER 2

- 041 - 1. T
- 041 - 2. F. Some X-ray photons must penetrate the part and reach the film for good visualization of a part
- 041 - 3. T
- 041 - 4. T.
- 041 - 5. T
- 041 - 6. F. The average energy depends upon the energies of the photons.
- 041 - 7. T.
- 041 - 8. F. An increase in kVp increases the maximum energy.
- 041 - 9. T.
- 042 - 1. It is the characteristic of the primary beam that affects radiographic density. It is a measure of the number of photons per unit area in combination with the mean energy of the photons.
- 042 - 2. 1. a; c.  
2. d.  
3. d.  
4. a; c.  
5. c.  
6. a.  
7. a; c; d.  
8. a; c.
- 043 - 1 The intensity of radiation in the primary beam is inversely proportional to the square of the distance from the target
- 043 - 2. 800; 50
- 043 - 3. No. Intensity as affected by the inverse square law has nothing to do with the number of photons emitted from the target. It is concerned with the number of photons per unit area
- 043 - 4. There is no connection between the two (at least not with the distances used in diagnostic radiology)
- 044 - 1. Longitudinal; anode heel effect.
- 044 - 2. Farthest
- 044 - 3 Anode.
- 044 - 4. Increases, decrease
- 044 - 5. 32°.
- 044 - 6. Cathode
- 044 - 7. Absorption; target material
- 045 - 1 a. Room #1.  
b. Since the difference between the sizes of the upper and lower portions of the thoracic spine is greater than normal, you would need the tube with the greatest variation in intensity to balance out the density on the radiograph. The 12° provides the greatest variation.  
c. Room #2.  
d. With his head toward the anode side of the tube
- 045 - 2. a. Any of the rooms could be selected.  
b. For spot-films of the gallbladder, you would only use the small central portion of the X-ray field. The variation in intensity for such a small area is negligible.
- 045 - 3 a. With the ankle toward the anode.  
b. The portable. At a 30-inch FFD, the beam intensity varies more.
- 046 - 1. F A small focal spot gives better detail.
- 046 - 2. F. A large focal spot produces more penumbra
- 046 - 3. F. The more penumbra, the worse the detail.
- 046 - 4. F. Penumbra is greatest on the cathode side.
- 046 - 5. F. Radiographs do have better detail on the anode side, but the reason has nothing to do with distance from the target. That portion is projected by a smaller focal spot.
- 047 - 1. Room #1. Room #2.
- 047 - 2. The 1.5 mm in room #1 because it has the smallest focal spot of the four able to withstand the exposure.
- 047 - 3. Your initial thought should be on the smallest focal spot you have available (0.2 mm in exposure room #1), since detail is most important on this examination. If the exposure factors do not exceed the rating of the 0.2-mm focal spot, it should be used. If you cannot safely use the 0.2 mm, check the exposure against the next largest focal spot (0.5 mm in room #2), and so on, until you find the smallest focal spot that can withstand the exposure. Remember, even though detail is important, do not exceed the maximum rating of the tube-rating chart.
- 048 - 1 The right lateral. The part-film distance for the right side would be less than for the left side; therefore, there would be less magnification and better detail of the right parietal bone.
- 048 - 2. a. Radiograph B.  
b. The posterior ribs of radiograph A.  
c. Radiograph B.
- 048 - 3. You could decrease the FFD. A shorter FFD increases magnification and therefore decreases detail.
- 048 - 4. The right lateral. It places the right lower lobe closer to the film, thereby providing better detail of that area.
- 048 - 5. An increase in FFD. Increased FFD increases detail.
- 049 - 1. Keep it to a minimum, but use it when necessary.
- 049 - 2. Yes. At times distortion is necessary to project a part clear of superimposed structures.
- 049 - 3. Perpendicular to a plane of the part and film.

- 049 - 4 Yes.  
 049 - 5. The plane of the part must be parallel with the plane of the film.

### CHAPTER 3

- 050 - 1. F A beam-restricting device reduces the size of the primary beam.  
 050 - 2 T.  
 050 - 3. T  
 050 - 4. T.  
 050 - 5. F You can reduce scatter by using a smaller X-ray field.  
 050 - 6. T  
 050 - 7 T.
- 051 - 1 Set the scale to a specific field size at a specific FFD. Make an exposure. Measure the X-ray field and compare it to the scale setting.  
 051 - 2.  
 a. Yes.  
 b. No.  
 c. No.  
 d. No.
- 052 - 1.  
 a. Place the 90° angles of the four wires so that they correspond to the four corners of the lighted field.  
 b. Two.  
 c. To insure visualization of the wire pieces.  
 d. By placing an orientation marker on the radiograph.  
 e. Measure the sides of the lighted field and the sides of the X-ray field.
- 052 - 2.  
 a. No.  
 b. Yes.  
 c. Yes.  
 d. No.
- 053 - 1 By absorbing most of the scattered radiation before it reaches the film.  
 053 - 2. No, but it absorbs the greatest portion.  
 053 - 3. No, a small portion is absorbed.  
 053 - 4. Because of the angles at which they approach the grid. Primary radiation approaches at angles the same as the lead strips, while scattered radiation approaches the strips at acute angles.  
 053 - 5.  
 1. a.  
 2. b.  
 3. a.  
 4. a.  
 5. b.  
 6. b.  
 7. c.
- 054 - 1.  
 1. a.  
 2. a; b.  
 3. a.  
 4. b.  
 5. b.  
 6. a.  
 7. a.  
 8. b.
- 055 - 1. The radiograph made with the 8:1, 100-line grid, because the strips are thinner and are not as high.  
 055 - 2. The more lines per inch, the lower the contrast; with more lines per inch, less scattered radiation is absorbed because there is less lead in the grid.
- 056 - 1.  
 1. a.  
 2. a; b.  
 3. a.  
 4. b.  
 5. b.  
 6. a; b.
- 057 - 1. T.  
 057 - 2. T.

- 057 - 3 F. A recipromatic Bucky permits the shortest exposure time  
 057 - 4 F A moving Bucky must be manually reset before each exposure  
 057 - 5. F The timer is manually set on a moving Bucky  
 057 - 6. T  
 057 - 7 T.  
 057 - 8. T.
- 058 - 1. Grid B. A higher ratio grid absorbs more scatter. The effective ratio of grid B is 10:1.  
 058 - 2. Grid B. A higher ratio absorbs more scatter.  
 058 - 3. Grid A. A greater proportion of the scatter is absorbed at 70 kVp because scattered radiation at 120 kVp is more likely to penetrate the lead strips and reach the film.  
 058 - 4. Grid A. Less scatter is absorbed because there is less lead in the grid.
- 059 - 1. It causes an even loss of density over the film.  
 059 - 2. The radiograph made with the 5:1 grid.  
 059 - 3. A grid with a long grid radius reduces density less than does a grid with a short radius.  
 059 - 4. 1 inch.  
 059 - 5. None.  
 059 - 6. The 5:1, 72-inch focused grid.
- 060 - 1. There would be a loss of density on the lateral margins of the film.  
 060 - 2. The radiograph for which the 32-inch focus-grid distance was used, because the loss of primary radiation and density is greater with "near" decentering than with "far" decentering.  
 060 - 3. A high-ratio grid causes greater loss of primary radiation than does a low-ratio grid.  
 060 - 4. Make experimental exposures and note the focus-grid distances where significant loss of primary radiation (density) occurs.
- 061 - 1. Two conditions could cause the variation. There could be far-distance decentering with lateral decentering over side B or near-distance centering with lateral decentering over side A.  
 061 - 2. Two conditions could cause the variation. There could be far-distance decentering with lateral decentering over side A or near-distance decentering with lateral decentering over side B.
- 062 - 1.  
 a. 8°.  
 b. 6°.  
 c. 3°.  
 d. 1°
- 062 - 2. An even loss of density over the film.

### CHAPTER 4

- 063 - 1.  
 1. a.  
 2. e.  
 3. a.  
 4. c.
- 064 - 1.  
 1. c.  
 2. b.  
 3. c; d.  
 4. a; b.  
 5. c.  
 6. c; d.  
 7. a.  
 8. a; b.  
 9. b.  
 10. d.

- 065 - 1 The ratio of light transmitted through a film to the incident light
- 065 - 2 a. 1.  
b. 2.  
c. 3.
- 066 - 1 60 mAs.  
066 - 2. Approximately 20 mAs (Remember that you are in the toe end of the curve.)
- 067 - 1. A.  
067 - 2. A; B  
067 - 3 C.  
067 - 4 A  
067 - 5. C  
067 - 6. A  
067 - 7. C  
067 - 8. A.
- 068 - 1. To reduce the exposure necessary to produce the desired radiographic density.  
068 - 2. a. Base—provides support.  
b. Reflecting material—reflects light photons emitted away from the film; back toward the film.  
c. Phosphor—emits visible light when exposed to X-rays.  
d. Protective coating—prevents static, protects the phosphor, and permits cleaning.
- 069 - 1. Screen films are especially sensitive to blue-violet light which is emitted by regular intensifying screens.  
069 - 2. Fast. Slow  
069 - 3. Slow. Fast.  
069 - 4. The larger the size of the crystals and the thicker the layer, the less the detail.  
069 - 5. Large crystals and a thick layer cause more light diffusion, which in turn causes overlapping of the areas under study.
- 070 - 1. T  
070 - 2. F. Rare earth system requires a GS-1 or equivalent filter.  
070 - 3. T.  
070 - 4. T  
070 - 5. F As kV is decreased, the rare earth screen response is slower.  
070 - 6 f.  
070 - 7. T
- 071 - 1. F. The test is made to determine whether there is a loss of detail  
071 - 2. F It results in more light diffusion.  
071 - 3. T.  
071 - 4. F Unsharp areas indicate poor screen-film contact
- 072 - 1 No  
072 - 2. Yes.  
072 - 3. Yes
- 073 - 1 1 f, i  
2. g  
3 d  
4. g  
5. c; k.  
6. b, f.  
7. e  
8. a; l.  
9. h.  
10. g  
11. f  
12. f; i.
- 074 - 1. Variation of film processing from one day to the next and from one processor to another.  
074 - 2. Expose a filmstrip to light and process it. Determine various densities from the film with a densitometer, and record the information on a chart.
- 075 - 1 A sensitometer produces equal repeated exposures from one day to the next. Exposure from a radiographic unit may vary from day to day.  
075 - 2. To prevent minor variations from one box of film to another from affecting film densities  
075 - 3. Immediately, because delays can affect the resulting film densities.
- 076 - 1. B  
076 - 2. C; day 6 or 7; day 10.  
076 - 3. You should be alerted that something may be wrong with the processor at days 3 and 4. On day 7, the density is outside the tolerable limits; you would still suspect processor trouble but should wait another day to see whether the density returns to normal. On day 17, you could conclude that the density is stable and well within the tolerable limits.
- 077 - 1. Increasing developer temperature.  
077 - 2. Increasing exposure to safelights.
- 078 - 1. Delayed recognition of potential problems.  
078 - 2. Place the daily strip alongside a base filmstrip from the film manufacturer and compare the density steps.  
078 - 3. Contrast. Because you must compare the difference between density steps rather than the actual step densities.
- 079 - 1. B.  
079 - 2. A.  
079 - 3. Yes, A and C.  
079 - 4. A.  
079 - 5 High developer temperature, high replenishment rates, and long immersion time.

## CHAPTER 5

- 080 - 1. T.  
080 - 2 F. Experience is perhaps more advantageous than any other factor.  
080 - 3. T.  
080 - 4. T.  
080 - 5. T.
- 081 - 1. Diagnostic; minimum.  
081 - 2. The mAs; kVp; both.  
081 - 3. Doing so reduces the possibility of error and teaches you how each factor affects the radiograph.  
081 - 4. Yes. Good technique charts usually provide sufficient kVp and mAs for a particular part. Consequently, you can usually change either the kVp or the mAs to correct a density problem.  
081 - 5. Background density, image density, and exposure factors used.  
081 - 6. mAs  
081 - 7. Underexposed; overexposed.  
081 - 8 Check; results.
- 082 - 1. Refer to the characteristic curve of your brand of X-ray film.  
082 - 2. Considerably more mAs is required to increase the density.  
082 - 3. Double the mAs to double the density; halve the mAs to halve the density.  
082 - 4. Add 15 percent of the kVp to double the density, and subtract 15 percent to halve the density.
- 083 - 1. The visible difference in density between the structures on a radiograph.  
083 - 2. a. Radiograph A.  
b. Radiograph B.  
c. Radiograph C.  
d. Radiograph A  
e. Radiograph C.

- 084 - 1. By affecting the selective absorption of X-ray photons, which is the difference in absorption by the various structures.
- 084 - 2. The radiograph of the distal portion of the leg, because the difference between the thickness of the distal tibia and fibula is less than the difference between the thickness of the proximal tibia and fibula. Consequently, there is less difference in photon absorption.
- 084 - 3. Bone. Fat. Because their atomic numbers are the highest and lowest, respectively, and the higher the atomic number of a structure, the more photon absorption due to the photoelectric effect.
- 084 - 4. Radiograph B.
- 084 - 5. Radiograph C.
- 084 - 6. Lower.
- 085 - 1. Radiograph C.
- 085 - 2. Radiograph B.
- 085 - 3. Radiograph A.
- 085 - 4. Radiograph A.
- 086 - 1. An even distribution of density, usually over the entire film, which is not caused by the selective absorption of photons.
- 086 - 2. It lowers the contrast.
- 086 - 3. It can increase the density to a point where we cannot distinguish the difference between densities.
- 087 - 1. 20 mAs and 92 kVp
- 087 - 2. 80 mAs and 68 kVp.
- 088 - 1. 150 mA
- 088 - 2. 1/10 sec.
- 089 - 1. 18 mAs.
- 089 - 2. 18 inches
- 089 - 3. 44 inches.
- 089 - 4. 25 mA.
- 089 - 5. 1/20 sec
- 090 - 1. It must produce consistent results. Make sure that technique charts are available and used by all personnel.
- 090 - 2. It must provide sufficient exposure of the film. Sufficient mAs and kVp must be established for each part.
- 090 - 3. It must be flexible. The mAs and kVp should be selected between the extremes of the values available on your X-ray machine control panel to permit change.
- 090 - 4. It must provide the desired contrast. Use the kVp range that will accomplish this.
- 091 - 1. mAs.
- 091 - 2. The thickness of the part.
- 091 - 3. Contrast varies from one examination to another.
- 091 - 4. It is easy to apply.
- 091 - 5. By trial and error.
- 091 - 6. 1; 4.
- 091 - 7. It allows you to determine the kVp by mental calculation rather than by referring to the technique chart for each measurement of a part.
- 091 - 8. 78 kVp.
- 091 - 9. 40.
- 092 - 1. T.
- 092 - 2. T.
- 092 - 3. T.
- 092 - 4. F. Contrast is consistent for all examinations of the same part. It may vary from part to part.
- 092 - 5. F. Preparation is difficult and time consuming.
- 093 - 1. Low mAs and high kVp (the highest kVp that will produce radiographs to satisfy your radiologist).
- 093 - 2. Lower patient dosage, less heat units per exposure to the X-ray tube target, and greater exposure latitude.

- 094 - 1. 71 kVp.
- 094 - 2. 101 kVp
- 094 - 3. 102 kVp.
- 094 - 4. 20 mAs
- 094 - 5. 20 percent.
- 094 - 6. a. 30 percent.  
b. 70 percent  
c. 75 percent

## CHAPTER 6

- 095 - 1. The person involved and his state of health. An elderly person or someone in poor health is particularly susceptible.
- 095 - 2. Part of the body involved. The heart or brain are especially susceptible.
- 095 - 3. Time of exposure. The longer the exposure, the greater the effect.
- 095 - 4. Type of current. Direct current is more dangerous than ac.
- 096 - 1. T.
- 096 - 2. F. A fuse is designed to protect the electrical circuit.
- 096 - 3. T.
- 096 - 4. F. Same as exercise answer 2 above.
- 096 - 5. F. Replacing a fuse with one of a higher rating is *never* permitted.
- 096 - 6. F. Have the medical equipment repairman replace the fuse and find out the cause of the blown fuse before you use the machine.
- 096 - 7. T.
- 097 - 1. Proper grounding of the equipment.
- 097 - 2. The housing is isolated from the electrical circuits. To prevent current from being introduced into the housing.
- 097 - 3. Probably not. The current returns to earth through the ground wire because it is the path of least resistance.
- 097 - 4. Probably not, but this is a dangerous situation.
- 097 - 5. You would be shocked. Because you have connected yourself between the circuit in the initial appliance and ground potential, you now are part of a completed circuit, and current would easily flow through your body.
- 097 - 6. a. Loose, bent, or otherwise defective power plugs.  
b. Frayed or cracked power cords or other outside electrical wires.  
c. The use of "cheater plugs."  
d. Missing ground prong on the power plug.
- 097 - 7. Do not use the equipment. Report the problem to the medical equipment repairman.
- 098 - 1. Very little. Because the resistance of the skin is bypassed by the catheter.
- 098 - 2. One one-thousandth.
- 098 - 3. Yes. There is danger from leakage current, which can exist even if no wiring defects are present.
- 098 - 4. The contrast medium in the catheter. Yes.
- 098 - 5. The patient is grounded through the film changer and/or X-ray table. Yes.
- 098 - 6. Yes. There may be a difference in potential between the injector and film changer, which could cause current to flow through the patient.
- 099 - 1. Make sure that all the electrical equipment in the room is grounded to the same ground potential. Have the room rewired if necessary.
- 099 - 2. Do not alter the power plugs, wiring, or anything affecting the equipment ground.
- 099 - 3. Have heavy-duty, three-way line plugs installed on all power cords.
- 099 - 4. Inspect the equipment before each examination for frayed line cords, broken plugs, deteriorated insulation, or other equipment defects.

- 100 - 1. The tank is probably grounded, and when in contact with it, you are at ground potential.
- 100 - 2. Yes, because you have placed yourself into a circuit and are subject to shock if the dryer wiring is defective.
- 100 - 3. Touching only one electrical appliance at a time. It can help prevent your body from being at ground potential
- 100 - 4. 1. b.  
2. a.  
3. d.  
4. e.
- 101 - 1. T.
- 101 - 2. T.
- 101 - 3. F. You *must* make sure that the subject you use to separate him from the source is nonconductive. Dry wood, clothing, rope, a blanket, or some other similar material should be used.
- 101 - 4. T.
- 101 - 5. F. The head position is not important for closed-chest heart compression but is important for mouth-to-mouth respiration. During mouth-to-mouth respiration, the head should be in the "sword-swallowing" position.
- 101 - 6. T.
- 101 - 7. T.
- 101 - 8. F. It should be depressed  $1\frac{1}{2}$  to 2 inches.
- 101 - 9. T.
- 101 - 10. T.
- 102 - 1. They are absorbed by the patient.
- 102 - 2. By removing a good portion of the low-energy photons
- 102 - 3. Filtration built into the X-ray tube. It is usually from 0.3 mm to 0.5 mm aluminum equivalency, depending upon the type of tube.
- 102 - 4. 0.2 mm.
- 102 - 5. 1.5 mm
- 102 - 6. 2.0 mm.
- 102 - 7. By reducing the number of low-energy photons and the minimum photon energy
- 103 - 1. They increase the mean energy of the beam.
- 103 - 2. They permit a short exposure time, thereby reducing repeat radiographs because of part motion.
- 103 - 3. They provide more exposure latitude, which reduces repeat radiographs due to the use of incorrect exposure factors.
- 104 - 1. It limits the area of exposure to that necessary to visualize the part under study. It prevents repeat radiographs due to excessive film fog
- 104 - 2. The outer limits of the X-ray field
- 104 - 3. Only that it was larger than the film. The collimator could have been wide open.
- 105 - 1. Hips, femurs, and lumbar spines.
- 105 - 2. Abdomens, intravenous pyelograms, sacrum, and coccyx.
- 105 - 3. Make sure that the shield does not interfere with the examination, and do not substitute the shield for proper beam collimation.
- 106 - 1. Less exposure is required to produce the radiograph.
- 106 - 2. Some detail.
- 106 - 3. Use medium or slow screens for body parts requiring maximum detail, and use high-speed screens for other radiographs.
- 107 - 1. C.
- 107 - 2. C.
- 107 - 3. The shorter the developing time, the greater the patient exposure.
- 107 - 4. The time recommended by the film manufacturer.
- 108 - 1. Never expose yourself to the primary beam.
- 108 - 2. Always remain behind a protective barrier when making an exposure.
- 108 - 3. Stay as far away from the radiation source as possible.
- 108 - 4. Wear a protective apron during fluoroscopy.
- 109 - 1. Make sure that all personnel under your supervision are thoroughly indoctrinated in the proper use of the dosimeter
- 109 - 2. You are responsible for the proper use of the dosimeter.
- 110 - 1. T
- 110 - 2. F. The belt is at waist level, and the dosimeter should be worn *above* the waist.
- 110 - 3. F. It is worn during fluoroscopy beneath the protective apron.
- 110 - 4. T.
- 110 - 5. T.
- 110 - 6. F. It assesses exposure to the head and lens of the eye.
- 110 - 7. F. It is worn in addition to the other dosimeters.
- 110 - 8. F. Dosimeters should be used only for the purpose specified and at the location specified.
- 110 - 9. F. As a general rule, this is true, but you must wear your dosimeter when performing portable radiographs.
- 110 - 10. F. They must be stored outside a radiation area.
- 110 - 11. T.
- 110 - 12. F. The identification can be placed on the front as long as the window is not covered.
- 110 - 13. F. The chest dosimeter only is used to measure whole-body exposure.

S T O P -

1. MATCH ANSWER SHEET TO THIS EXERCISE NUMBER.
2. USE NUMBER 2 PENCIL ONLY.

EXTENSION COURSE INSTITUTE  
VOLUME REVIEW EXERCISE

90370 01 22  
RADIOGRAPHIC FUNDAMENTALS

Carefully read the following:

DO's:

1. Check the "course," "volume," and "form" numbers from the answer sheet address tab against the "VRE answer sheet identification number" in the righthand column of the shipping list. If numbers do not match, return the answer sheet and the shipping list to ECI immediately with a note of explanation.
2. Note that item numbers on answer sheet are sequential in each column.
3. Use a medium sharp #2 black lead pencil for marking answer sheet.
4. Write the correct answer in the margin at the left of the item. (When you review for the course examination, you can cover your answers with a strip of paper and then check your review answers against your original choices.) After you are sure of your answers, transfer them to the answer sheet. If you have to change an answer on the answer sheet, be sure that the erasure is complete. Use a clean eraser. But try to avoid any erasure on the answer sheet if at all possible.
5. Take action to return entire answer sheet to ECI.
6. Keep Volume Review Exercise booklet for review and reference.
7. If mandatorily enrolled student, process questions or comments through your unit trainer or OJT supervisor. If voluntarily enrolled student, send questions or comments to ECI on ECI Form 17.

DON'Ts:

1. Don't use answer sheets other than one furnished specifically for each review exercise.
2. Don't mark on the answer sheet except to fill in marking blocks. Double marks or excessive markings which overflow marking blocks will register as errors.
3. Don't fold, spindle, staple, tape, or mutilate the answer sheet.
4. Don't use ink or any marking other than a #2 black lead pencil.

NOTE: NUMBERED LEARNING OBJECTIVE REFERENCES ARE USED ON THE VOLUME REVIEW EXERCISE. In parenthesis after each item number on the VRE is the Learning Objective Number where the answer to that item can be located. When answering the items on the VRE, refer to the Learning Objectives indicated by these Numbers. The VRE results will be sent to you on a postcard which will list the actual VRE items you missed. Go to the VRE booklet and locate the Learning Objective Numbers for the items missed. Go to the text and carefully review the areas covered by these references. Review the entire VRE again before you take the closed-book Course Examination.

90370-01-22

MULTIPLE CHOICE

1. (001) Which of the following is the smallest particle of the element tungsten that has all of the properties of tungsten?
  - a. Atom.
  - b. Mixture.
  - c. Nucleus.
  - d. Compound.
  
2. (001) Bohr's theory represents an atom as
  - a. a miniature planet.
  - b. a miniature solar system.
  - c. surrounded by waves of protons.
  - d. surrounded by waves of electrons.
  
3. (002) The law of conservation pertaining to matter and energy states that
  - a. matter and energy can neither be created nor destroyed.
  - b. severe explosions occur when matter and energy are combined.
  - c. when X-radiation interacts with an object, energy is destroyed.
  - d. when X-radiation interacts with an object, energy and matter are destroyed.
  
4. (003) An atom is said to be ionized when
  - a. it is no longer electrically neutral.
  - b. its inner shell is complete.
  - c. its nucleus is partly disintegrating.
  - d. all of its shells are complete.
  
5. (004) The primary beam emitted from the X-ray tube is composed of radiation produced by
  - a. secondary radiation and isotopes.
  - b. Bremsstrahlung and isotopes.
  - c. Bremsstrahlung and the heel effect.
  - d. characteristic and Bremsstrahlung interaction.
  
6. (005) In order to produce electron flow in a conductor, it is necessary to have
  - a. like charges.
  - b. no electrical resistance.
  - c. a difference in potential.
  - d. a transformer.

90370-01-22

7. (006) Material A has one valence electron, material B has three valence electrons, and material C has four valence electrons. Classify the materials as conductors, semiconductors, or insulators.
- A-conductor; B-semiconductor; C-insulator.
  - A-conductor; B-conductor; C-semiconductor.
  - A-insulator; B-semiconductor; C-conductor.
  - A-insulator; B-conductor; C-semiconductor.
8. (007) The standard symbol used for voltage is
- $\underline{E}$ .
  - $\underline{I}$ .
  - $\underline{R}$ .
  - $\underline{P}$ .
9. (008) In the value "10  $\Omega$ ," the "10" refers to the amount of resistance ( $R$ ) indicated and the symbol " $\Omega$ " is read as
- "amps."
  - "ohms."
  - "volts."
  - "watts."
10. (009) Which of the following statements is not true in regard to the resistance of a wire conductor of electricity?
- The longer a conductor, the greater its resistance.
  - The greater the cross-sectional area of a conductor, the lower the resistance.
  - The hotter the conductor material, the lower the resistance.
  - Iron offers more resistance than copper but less than aluminum.
11. (010) If, on a schematic of an electrical circuit, a number is shown alongside a symbol of a battery, the number represents the
- battery voltage.
  - battery current.
  - number of cells.
  - number of circuit components.
12. (011) How much resistance is present in a circuit if the voltage is 220 and the current is 10 amperes?
- 0.04  $\Omega$ .
  - 22  $\Omega$ .
  - 210  $\Omega$ .
  - 2,220  $\Omega$ .
13. (011) Which of the following accurately states Ohm's law?
- $\underline{E} = \frac{\underline{I}}{\underline{R}}$
  - $\underline{I} = \underline{E} \times \underline{R}$
  - $\underline{R} = \underline{E} \times \underline{I}$
  - $\underline{E} = \underline{I} \times \underline{R}$



14. (012) In a series circuit, current
- is the same at all points.
  - is raised across each resistor.
  - decreases across each subsequent resistor.
  - varies according to distance from the power supply.
15. (013) The reciprocal method is one of several methods for determining the
- effective resistance in a parallel circuit.
  - total current in a series circuit.
  - effective voltage in a parallel circuit.
  - total voltage in a series-parallel circuit.
16. (015) All of the following statements about magnetism are true except
- an invisible magnetic field is present around and inside a magnet.
  - like magnetic poles repel each other.
  - lines of force travel from the north pole to the south pole outside the magnet.
  - flux lines travel from the north pole to the south pole within the magnet.
17. (016) In an unmagnetized iron bar, the magnet dipoles of the material are
- arranged at random.
  - pointed toward the periphery.
  - molecular in size, have a north pole, and are arranged in definite pattern.
  - arranged so that their north poles point in one direction.
18. (017) A straight, current-carrying conductor has a magnetic field
- with few lines of force.
  - only if the current is dc.
  - with no north or south poles.
  - that does not expand or collapse with fluctuations of current.
19. (018) All of the following factors affect the strength of the magnetic field of a coil except the
- |                 |                       |
|-----------------|-----------------------|
| a. iron core.   | c. turns per inch.    |
| b. retentivity. | d. current magnitude. |

20. (019) The "centering effect" of an iron core is best described in which of the following statements?
- The centering of a lead core to a current-carrying coil tends to increase as current decreases.
  - An iron core does not remain inside a current-carrying coil.
  - An iron core inside a wire coil cannot be removed unless current is applied to the coil.
  - An iron core suspended inside a wire coil with current automatically centers itself to the length of the coil.
21. (020) A relay operates on the principle that
- electromagnetism increases current flow.
  - an electromagnet attracts magnetic substances.
  - arcing in high-voltage circuits is dangerous.
  - a current-carrying coil has two magnetic fields if the current is ac.
22. (0-1) The coil in a permanent-magnet, moving-coil meter rotates because the
- coil bar is attracted to the north pole.
  - magnetic field of the needle repels the electromagnetic south pole.
  - poles of an electromagnet oppose the poles of a permanent magnet.
  - permanent magnet aligns itself with the magnetic field of the electromagnet.
23. (022) Which one of the following statements best compares current flow of ac to that of dc?
- The ac flows from negative to positive; dc flows from positive to negative.
  - Both flow from negative to positive; ac constantly changes directions.
  - Both flow from positive to negative; direction of flow is the same.
  - The dc constantly changes in value; ac does not.
24. (023) In 60-cycle alternating current, there are how many alternations (impulses) per second?
- |        |         |
|--------|---------|
| a. 60. | c. 120. |
| b. 90. | d. 180. |

25. (024) All of the following are required for electromagnetic induction except
- direct current.
  - a conductor.
  - a magnetic field.
  - relative motion between conductor and magnet.
26. (025) Mutual and self-induction occur without moving the conductor, due to
- movement of the iron core.
  - the consistent value of dc.
  - the high current generated in the wire coil.
  - the expanding and collapsing magnetic field.
27. (026) What is the output voltage and amperage from a transformer if the input voltage is 220 volts, the input amperage is 10 amps, and the transformer ratio is 5 to 1?
- 22 volts and 50 amps.
  - 44 volts and 2 amps.
  - 44 volts and 50 amps.
  - 600 volts and 2 amps.
28. (027) When you adjust the line voltage compensator, you are in effect
- stepping up or down the incoming line voltage.
  - increasing or decreasing the quantity of electrons available for exposure.
  - adjusting the autotransformer to maintain the same volts per turn ratio.
  - checking the safety mechanisms of the X-ray unit.
29. (027) The function of the autotransformer is to
- stabilize the fixed voltage of the step-down transformer.
  - act as a rectifier to the filament.
  - help reduce power loss in the transformer due to resistance.
  - control voltage to the primary of the high-tension transformer.
30. (028) Three-phase ac produces how many pulses per cycle across the X-ray tube?
- One or two.
  - Six or twelve.
  - Two or twelve.
  - One, two, or six.

31. (029) Which one of the following statements pertains to the relationship between voltage waveform and electron energy?
- Twelve-pulse produces higher maximum electron energy than does six-pulse.
  - Twelve-pulse produces higher average electron energy than does two-pulse.
  - One-pulse produces higher average electron energy than does two-pulse.
  - Six-pulse produces higher maximum electron energy than does two-pulse.
32. (030) Average photon energy from a three-phase generator is higher than that from a single-phase generator because in the former the
- current is lower.
  - current is higher.
  - peak voltage is higher.
  - average electron energy is higher.
33. (031) The intensity of the X-ray beam is higher from a three-phase generator than that from a single-phase generator when equal tube currents are used because
- image-forming radiation is applied over a longer period of time.
  - low-energy photons are continuously produced.
  - non-image-forming radiation is produced only at the bottom of the wave.
  - high-energy photons are produced at a near-constant voltage level.
34. (032) If 100 kVp is used for a radiograph on a three-phase machine, what kVp should be used for the same radiograph on a single-phase machine?
- |        |         |
|--------|---------|
| a. 85. | c. 115. |
| b. 90. | d. 120. |
35. (033) How does tube capacity compare between single-phase and three-phase tubes for exposure times between one-half and one second?
- Lower with three-phase.
  - Higher with three-phase.
  - They are approximately equal.
  - Lower with three-phase when low tube voltage is used.

36. (034) Use of the STAND-BY button on the exposure switch should be kept to a minimum in order to
- reduce off-focus radiation.
  - prevent heat buildup in the anode.
  - reduce surface etching of the target.
  - reduce vaporization of the tube filament.
37. (035) The size of the actual focal spot of an X-ray tube affects the
- heat-loading capacity.
  - film coverage.
  - shape of the filament.
  - speed of the anode.
38. (036) Two advantages of a grid-controlled X-ray tube are
- short exposures and lower patient dosage.
  - short exposure and lower photon energies.
  - less heat units per exposure and homogenous photons energies.
  - more detail on an angiogram and lower photon energies.
39. (037) How many heat units are generated in a three-phase generator if the exposure factors are 100 mA, 1 sec, and 85 kVp?
- 850.
  - 8,500.
  - 11,100.
  - 11,475.
40. (038) Which one of the following can be determined from a single-exposure tube rating chart?
- Maximum mA and kVp only.
  - Maximum heat units only.
  - Maximum mA, kVp, and seconds.
  - Maximum kVp, seconds, and heat units.
41. (039) Angiographic rating charts enable you to determine
- whether the heat units per exposure exceed the tube limit.
  - whether the total number of exposures per second exceeds the tube limit.
  - anode cooling during serial filming.
  - anode and housing cooling during serial filming.
42. (041) A high-quality X-ray beam is a beam with relatively
- low penetrating power.
  - high penetrating power.
  - long wavelengths.
  - few photons per unit area.

43. (042) Which of the following X-ray machine controls can be used to alter the number of photons per square inch of the X-ray beam?
- mA and kVp only.
  - mA and exposure time only.
  - mA, kVp, and exposure time.
  - kVp, exposure time, and line voltage compensator.
44. (043) The inverse square law affects the primary beam by
- eliminating the low-energy photons.
  - regulating the mean energy of the beam.
  - affecting the number of photons per unit area.
  - increasing the intensity on the cathode side of the tube.
45. (044) The anode heel effect is caused when
- the target material absorbs photons.
  - some photons have less energy than others.
  - a small focal spot emits a heterogeneous beam.
  - a large focal spot provides greater variation in beam intensity.
46. (045) You may be able to use the anode heel effect advantageously for X-raying all of the following parts of the body except the
- hand.
  - femur.
  - leg.
  - AP thoracic spine.
47. (046) Which of the following focal spots should be used to provide the best detail?
- 0.3 mm.
  - 0.5 mm.
  - 1.5 mm.
  - 2.0 mm.
48. (047) The factor most important in deciding what focal spot to use with a particular examination is the
- necessity of detail.
  - capacity of the tube.
  - contrast scale desired.
  - number of exposures required.
49. (048) If a radiograph of the knee shows too much magnification, which one of the following changes could be made to decrease the magnification?
- Decrease the FFD.
  - Increase the FFD.
  - Decrease the exposure.
  - Increase the part-film distance.

50. (049) To minimize distortion, the plane of the part and the plane of the film should be
- perpendicular to each other.
  - at  $45^\circ$  angles to each other.
  - parallel.
  - the same.
51. (050) A practical way to provide contrast between the gallbladder and surrounding structures is to
- decrease the contrast.
  - increase the filtration.
  - double the size of the projected area.
  - use a collimator to restrict the field size.
52. (051) AFM 161-38 requires that all X-ray machine have a collimator except
- therapeutic units.
  - multipurpose units.
  - special-purpose units.
  - general-purpose unit.
53. (052) A collimator must be adjusted if any side of an X-ray field deviates by more than what percent of the FFD?
- 2.
  - 4.
  - 6.
  - 10.
54. (053) Grids are used to
- increase mAs values.
  - reduce scatter radiation reaching film.
  - prevent over exposure of a radiograph.
  - reduce amount of low energy photons reaching the patient.
55. (054) Grid ratio is directly related to all of the following except the
- efficiency of the grid.
  - tube alignment.
  - thickness of the grid.
  - height of a lead strip in relation to the width of the space between two strips.
56. (054) The grid radius is of importance primarily because of its effect on the
- FFD used.
  - tube alignment.
  - efficiency of the grid.
  - height of lead strips and interspaces.

57. (055) The greatest advantage of a stationary grid with many lines per inch is that the lead strips are less visible on the radiograph and therefore
- give better contrast.
  - have more lead content.
  - interfere less with interpretation.
  - can be safely moved during exposure.
58. (056) In contrast to a linear grid, a crossed grid
- has an unlimited usage.
  - has less lead in the grid.
  - has an effective ratio about twice its nominal ratio.
  - permits the tube to be angled in unlimited ways.
59. (057) Of the listed Potter-Bucky mechanisms, which is considered the fastest?
- Recipromatic.
  - Reciprocating.
  - Manual cocking.
  - Portable.
60. (058) Which of the following statements relating to grid efficiency is false?
- The higher the effective ratio of a grid, the better the absorption of scatter radiation.
  - Ideally, a grid would absorb all of the scatter and no primary photons.
  - High kVp with a microline grid results in lower efficiency than does moderate kVp.
  - The higher the lines per inch for a given ratio, the more likely that scatter will be absorbed.
61. (059) Transmission of primary radiation is reduced for any one of a number of reasons. Which of the following situations would not have that effect?
- Distance decentering exists.
  - The tube is aligned directly in the center of the transverse axis of the grid.
  - The tube is not positioned at the proper distance from the grid.
  - Lateral decentering is substantial in amount.
62. (060) What is the effect on a radiograph when a focused grid is used at the wrong FFD?
- None of the secondary radiation is absorbed.
  - All of the primary radiation is absorbed.
  - The film shows a loss of detail.
  - The outer edges of the film are underexposed.



63. (061) If a grid radiograph shows a loss of density on only one lateral margin of the film, which of the following types of decentering was likely present at the time of exposure?
- Focus decentering.
  - Lateral decentering only.
  - Distance decentering only.
  - Both lateral and distance decentering.
64. (062) Select the maximum tube angle across the lead strips that can be allowed to avoid a noticeable loss of density over the entire radiograph in a case where the grid ratio is 16:1.
- 1°.
  - 3°.
  - 6°.
  - 8°.
65. (063) In contrast to cellulose acetate, polyester used as base material in film offers all of the following advantage except
- more strength in thinner form.
  - less tendency to curl.
  - more flexibility in thicker form.
  - compatibility with temperatures used in 90-second processors.
66. (064) Which of the following types of film should be processed only in an automatic processor?
- Dental.
  - Blue-sensitive.
  - Green-sensitive.
  - Nonscreen.
67. (064) Which type of X-ray film provides excellent detail for small parts and because of its thick emulsion requires longer processing?
- Dental only.
  - Screen only.
  - Nonscreen.
  - Both dental and screen.
68. (065) A densitometer shows that part "X" of a radiograph has a density of 1.0, while part "Y" has a density of 3.0. Which statement below compares the incident light transmitted through "X" to the incident light transmitted through "Y"?
- 1 percent to 3 percent.
  - 3 percent to 1 percent.
  - 0.1 percent to 10 percent.
  - 10 percent to 0.1 percent.

69. (066) Which one statement below is typical of the characteristic curve of an X-ray film used to determine the specific mAs changes necessary to raise or lower a radiograph density?
- Density is plotted on the horizontal axis.
  - Log relative exposure is plotted on the vertical axis.
  - Values of mAs that can be applied to the scale are limited.
  - The horizontal axis' "log relative exposure" represents the mAs required to change density.
70. (067) The inherent film fog, as determined from reference to the toe of the film's characteristic curve and judged on a general basis, is not considered excessive unless it exceeds a density of
- 0.2.
  - 1.0.
  - 1.5.
  - 2.0.
71. (067) Which of the following is not a characteristic associated with "fast" film?
- Fewer heat units per exposure than "slow" films would cause.
  - Less detail, due to a grainy appearance on the radiographs.
  - Greater radiation dose for the patient.
  - Shorter exposure times.
72. (068) The name of the layer of material of an intensifying screen designed to expose the film is called a
- base.
  - phosphor.
  - protective coating.
  - reflecting material.
73. (069) As the speed of intensifying screens become higher, there is a resultant
- decrease in the life of the X-ray tube.
  - reduction in radiographic detail and clarity.
  - increase in the transmission of radiation to the patient.
  - increase in radiographic-exposure time necessary for clarity.
74. (070) Rare earth intensifying screens are faster than regular screens because
- lower mAs values are used.
  - higher capacity units can be used.
  - the phosphor layer absorbs more and has a higher conversion factor of the incident radiation.
  - the phosphor layer absorbs less; consequently, more incident radiation reaches the film.

90370-01-22

13

266

146

75. (071) A part of the process of making a valid screen-film contact test consists in inspection of a
- wire mesh image.
  - voltmeter reading.
  - densitometer reading.
  - thickness-gauge measurement.
76. (072) If, during a valid screen-lag test, half of the film is found to be exposed while the other half is not, it may be concluded that
- screen lag is present.
  - screen lag is not present.
  - fluorescence stopped at the time of exposure.
  - no phosphorescence occurred.
77. (073) Exposed crystals in films are changed to black metallic silver during film processing by
- sodium sulfite.
  - phenidone, metol, and hydroquinone.
  - potassium alum and sodium carbonate.
  - gluteraldehyde, acetic acid, and sodium thiosulfate.
78. (074) To ensure consistent high-quality production of radiographs, each processor should be checked daily by using a
- cleaning agent.
  - voltmeter only.
  - densitometer only.
  - sensitometric film strip, a densitometer, and a recording chart.
79. (075) One requirement pertaining to the use of the sensitometer and radiographic film in conducting a processor evaluation test includes
- standardizing the radiographic technique chart before beginning evaluation.
  - substitution of a radiographic unit for a sensitometer.
  - exposing film every 2 days and processing as a matter of convenience.
  - ensuring that all procedures remain the same.
80. (076) To measure the density in evaluating filmstrips, a density step between 0.9 and 1.2 is selected because these densities
- cover the average normal densities of a radiograph.
  - comprise the allowable upper limits of densities.
  - comprise the allowable lower limits of densities.
  - are located on the portion of the characteristic curve most sensitive to changes in processing.

90370-01-22

81. (077) The base fog of a filmstrip is easily determined by
- observing the contrast of two exposed steps.
  - looking at the manufacturer's specifications.
  - measuring the density of the unexposed density step.
  - increasing the developer temperature to a high value.
82. (078) If processor evaluation is accomplished without using a densitometer, the most difficult comparison to make is of
- contrast.
  - density.
  - base fog.
  - base fog coupled with density.
83. (079) Underdevelopment that permits variations between processors can be caused by such factors as
- low replenishment rates.
  - high replenishment rates.
  - low fixer immersion time.
  - high developer temperature.
84. (080) As measured with a densitometer, the average density for most radiographs should be approximately
- |         |         |
|---------|---------|
| a. 0.5. | c. 2.5. |
| b. 1.5. | d. 25.  |
85. (081) To change density with kVp or mAs, all of the following should be considered except
- image density.
  - background density.
  - exposure factors used.
  - increasing mAs while decreasing kVp simultaneously.
86. (082) The most reliable and accurate way to determine the exact mAs change required to make a specific change in the film density is to
- use a "rule of thumb."
  - make mathematical calculations.
  - double or halve the mAs to double or halve the density.
  - refer to the characteristic curve of the brand of X-ray film used.
87. (083) Long-scale contrast on a radiograph is
- characterized by little change from one density to another.
  - referred to as high contrast.
  - present when the number of useful densities is small.
  - present when the change from one density to another is abrupt.

90370-01-22

88. (084) Three factors--structure thickness, atomic number, and density--affect the contrast on a radiograph by
- eliminating film fog.
  - negating the effects of film contrast.
  - affecting the selective absorption of the photons.
  - shortening the exposure time and thereby affecting selective absorption.
89. (085) Increasing kVp causes primarily
- higher contrast (short-scale).
  - lower contrast (long-scale).
  - a decrease in the fog level.
  - a reduction in the penetrating ability of the primary beam.
90. (086) Film fog, as it occurs on radiographs to reduce their contrast, is caused by all of the following except
- scatter radiation.
  - improper processing.
  - deliberate film exposure.
  - exposure of the film to either light or radiation leaks.
91. (087) A radiograph made with 100 kVp and 30 mAs is properly exposed but lacks adequate contrast to demonstrate a particular structure. Which of the following values should be used to produce a second radiograph that is equal in overall density to the first with proper contrast
- |                       |                         |
|-----------------------|-------------------------|
| a. 50 kVp and 60 mAs. | c. 110 kVp and .15 mAs. |
| b. 85 kVp and 60 mAs. | d. 115 kVp and 15 mAs.  |
92. (088) The mA-sec formula that you should use in your computation to control undesirable motion and thus enhance image detail is
- $\underline{mA}_2 : \underline{mA}_1 :: \underline{sec}_2 : \underline{sec}_1$ .
  - $\underline{mA}_1 : \underline{mA}_2 :: \underline{sec}_2 : \underline{sec}_1$ .
  - $\underline{mA}_1 : \underline{sec}_1 :: \underline{mA}_2 : \underline{sec}_2$ .
  - $\underline{mA}_2 : \underline{mA}_1 :: \underline{sec}_2 : \underline{sec}_1$ .
93. (089) A technique chart specifies a technique of 50 mAs using a 72-inch FFD. However, because of limitations, it is necessary to use a 36-inch FFD. This requirement will then necessitate a new mAs of
- |         |          |
|---------|----------|
| a. .04. | c. 12.5. |
| b. .08. | d. 25.   |

94. (090) Which one of the following four basic requirements for establishing a standard system of exposure factors would be sought in keeping both the mAs and the kVp within a range from which either may be increased or decreased?
- a. Flexibility.
  - b. Consistent results.
  - c. Desired contrast range.
  - d. Sufficient exposure of film.
95. (091) One requirement for use of a chart employing variable kVp techniques is to
- a. also vary the mAs.
  - b. insist that no two individuals use the same chart.
  - c. know the part thickness in centimeters along the path of the CR.
  - d. make a 2-kVp change for each centimeter of part change, without exception.
96. (092) All of the following are descriptive of fixed kVp techniques except
- a. contrast is consistent for examinations of a particular body part.
  - b. the system is fast falling into disrepute.
  - c. mAs varies, depending upon the thickness of the body part.
  - d. a large amount of time and effort is necessary in order to prepare and finalize the techniques.
97. (093) All of the following statements list advantages of using kVp techniques except
- a. there is greater exposure latitude.
  - b. there is less absorption of photons by the patient.
  - c. the X-ray tube is subjected to fewer heat units per exposure.
  - d. the time and effort it takes to prepare the chart used is negligible.
98. (094) Refer to figure 5-8. You are required to perform a portable abdominal radiograph in surgery. The normal technique is 100 mAs, 90 kVp, 40-inch FFD, and a 12 to 1 grid. The 12 to 1 grid is in use; therefore, you must use an 8 to 1 grid. What is the new kVp?
- a. 80.
  - b. 86.
  - c. 95.
  - d. 100.
99. (095) The amount of current constituting a lethal shock varies with all of the following except
- a. type of current.
  - b. ionizing radiation
  - c. age of the patient.
  - d. part of the body involved.

100. (096) A burned-out fuse in an X-ray machine should be replaced
- by you with one of the same rating.
  - with one of a lower rating.
  - with one of a higher rating.
  - by a medical equipment repairman.
101. (097) An important safeguard to protect service personnel and patients from electrical shock is to
- properly ground the equipment.
  - replace blown fuses with smaller ones.
  - rely on the fuse for adequate protection.
  - touch both equipment housing and another grounded piece of equipment simultaneously.
102. (098) During angiography, in which a catheter is inserted into the blood stream, what measure of the lethal skin current is required to produce ventricular fibrillation?
- 1/10.
  - 1/100.
  - 1/1,000.
  - 1/10,000.
103. (099) An electrically safe atmosphere for an angiographic patient can be created by
- using nonconductive contrast media.
  - grounding all electrical equipment to metal water pipes.
  - using only three-prong, heavy-duty line plugs.
  - grounding all electrical equipment to the same ground potential.
104. (100) An effective precaution to help prevent electrical shock while you are manually processing films in the darkroom is to
- not turn the dryer switch on.
  - work with dry hands whenever possible and keep the floor dry.
  - always simultaneously contact the processing tank and the dryer.
  - make certain the dryer housing is not isolated from the powerline.
105. (101) If another person accidentally comes into contact with a hot wire, is knocked unconscious, and is frozen to the circuit, your very first action should be to
- turn the power off.
  - seek additional help.
  - phone for a physician
  - pull the victim from the electrical source.

106. (102) Filtration of the X-ray beam lowers the patient's exposure by removing
- most of the medium-energy photons.
  - the aluminum equivalency of the tube.
  - all of the low-energy photons and consequently lowering the patient's absorbed dose.
  - a portion of the low-energy photons and consequently increasing the mean energy of the primary beam.
107. (103) High kVp techniques reduce patient exposure in all of the following ways except to
- increase the mean energy of the beam.
  - lengthen the scale of contrast.
  - provide more exposure latitude.
  - permit shorter exposure times.
108. (104) One of the two ways that proper collimation reduces patient's exposure is that it
- standardizes a 2-inch unexposed border around the sides.
  - increases the area of exposure to include significant adjacent areas.
  - increases film fog, making the X-rays themselves less penetrating.
  - limits the area of exposure to that necessary for visualizing the part under study.
109. (105) All of the following are important to prevent needless exposure of a patient's gonads except
- careful shielding for hip examinations.
  - use of shielding in addition to collimation.
  - covering them with lead-rubber shielding material.
  - placement of the shield to ensure its superimposing over the part under study.
110. (106) High-speed films and screens reduce the patient's exposure to radiation but also result in a
- loss of detail.
  - loss of contrast.
  - gain in exposure time.
  - significant increase in film fog.



111. (107) From an examination of characteristic curves that relate developing time to a patient's exposure, it is possible to conclude that the shorter the developing time, the
- a. less the patient's exposure.
  - b. greater the patient's exposure.
  - c. less need there is for shielding.
  - d. less effect it has on the patient's absorbed dose.
112. (108) All of the following are valid rules for protecting oneself against radiation except
- a. remaining behind a protective barrier.
  - b. wearing a protective apron during fluoroscopy.
  - c. staying as far away from the radiation source as possible.
  - d. occasionally exposing oneself to scatter radiation since it is usually less hazardous than the primary beam.
113. (109) Technician responsibilities pertaining to a dosimeter include
- a. repair.
  - b. proper use.
  - c. processing, interpreting, and recording the data from the dosimeter film.
  - d. recording the data received from the Radiological Health Laboratory.
114. (110) If a dosimeter is used to record exposure to a localized area, what must be done before it can be worn at any other body site?
- a. Replace it.
  - b. Change the dosimeter film.
  - c. Recalibrate it for accuracy.
  - d. Record the localized exposure.

**STUDENT REQUEST FOR ASSISTANCE**

PRIVACY ACT STATEMENT

AUTHORITY: 44 USC 3101. PRINCIPAL PURPOSE(S): To provide student assistance as requested by individual students. ROUTINE USES: This form is shipped with every ECI course package. It is utilized by the student, as needed, to place an inquiry with ECI. DISCLOSURE: Voluntary. The information requested on this form is needed for expeditious handling of the student's need. Failure to provide all information would result in slower action or inability to provide assistance.

**SECTION I: CORRECTED OR LATEST ENROLLMENT DATA:** MAIL TO ECI, GUNTER AFS, ALA 36118

1. THIS REQUEST CONCERNS COURSE <input style="width:100%; height:20px;" type="text"/>	2. TODAY'S DATE <input style="width:100%; height:20px;" type="text"/>	3. ENROLLMENT DATE <input style="width:100%; height:20px;" type="text"/>	4. PREVIOUS SERIAL NUMBER <input style="width:100%; height:20px;" type="text"/>
5. SOCIAL SECURITY NUMBER <input style="width:100%; height:20px;" type="text"/>	6. GRADE/RANK <input style="width:100%; height:20px;" type="text"/>	7. INITIALS <input style="width:100%; height:20px;" type="text"/>	LAST NAME <input style="width:100%; height:20px;" type="text"/>
8. OTHER ECI COURSES NOW ENROLLED IN <input style="width:100%; height:20px;" type="text"/> <input style="width:100%; height:20px;" type="text"/> <input style="width:100%; height:20px;" type="text"/>	9. ADDRESS: (OJT ENROLLEES - ADDRESS OF UNIT TRAINING OFFICE/ALL OTHERS - CURRENT MAILING ADDRESS) <input style="width:100%; height:20px;" type="text"/> <input style="width:100%; height:20px;" type="text"/> <input style="width:100%; height:20px;" type="text"/> <div style="text-align: right; margin-right: 50px;">ZIP CODE <input style="width: 40px; height: 15px;" type="text"/></div>		11. AUTOVON NUMBER <input style="width:100%; height:20px;" type="text"/>
10. NAME OF BASE OR INSTALLATION IF NOT SHOWN ABOVE: <input style="width:100%; height:20px;" type="text"/>			12. TEST CONTROL OFFICE ZIP CODE/SHRED <input style="width:100%; height:20px;" type="text"/>

<input type="text"/>	<input type="text"/>	<input type="text"/>
<input type="text"/>	<input type="text"/>	<input type="text"/>
<input type="text"/>	<input type="text"/>	<input type="text"/>

**SECTION II: Old or INCORRECT ENROLLMENT DATA**

1. NAME:	2. GRADE/RANK:	3. SSAN:
4. ADDRESS:	5. TEST OFFICE ZIP/SHRED:	

**SECTION III: REQUEST FOR MATERIALS, RECORDS, OR SERVICE**

ADDITIONAL FORMS 17 available from trainers, OJT and Education Offices, and ECI. The latest course workbooks have a Form 17 printed on the last page.

(Place an "X" through number in box to left of service requested)

1	EXTEND COURSE COMPLETION DATE. (Justify in Remarks)
2	SEND VRE ANSWER SHEETS FOR VOL(s): 1 2 3 4 5 6 7 8 9 - ORIGINALS WERE: NOT RECEIVED, LOST, MISUSED
3	SEND COURSE MATERIALS (Specify in remarks) - ORIGINALS WERE: NOT RECEIVED, LOST, DAMAGED.
4	COURSE EXAM NOT YET RECEIVED. FINAL VRE SUBMITTED FOR GRADING ON (Date):
5	RESULTS FOR VRE VOL(s): 2 3 4 5 6 7 8 9 NOT YET RECEIVED. ANSWER SHEET(s) SUBMITTED ON (Date):
6	RESULTS FOR CE NOT YET RECEIVED. ANSWER SHEET SUBMITTED TO ECI ON (Date):
7	PREVIOUS INQUIRY (ECI FORM 17, LTR, MSG) SENT TO ECI ON:
8	GIVE INSTRUCTIONAL ASSISTANCE AS REQUESTED ON REVERSE:
9	OTHER (Explain fully in remarks)
REMARKS: (Continue on Reverse)	

OJT STUDENTS must have their OJT Administrator certify this request.  
ALL OTHER STUDENTS may certify their own requests.

I certify that the information on this form is accurate and that this request cannot be answered at this station. (Signature)



**SECTION IV: REQUEST FOR INSTRUCTOR ASSISTANCE**

**NOTE:** Questions or comments relating to the accuracy or currency of textual material should be forwarded directly to preparing agency. Name of agency can be found at the bottom of the inside cover of each text. All other inquiries concerning the course should be forwarded to ECI.

VRE ITEM QUESTIONED:

MY QUESTION IS:

Course No. \_\_\_\_\_

Volume No. \_\_\_\_\_

VRE Form No. \_\_\_\_\_

VRE Item No. \_\_\_\_\_

Answer You Chose  
(Letter) \_\_\_\_\_

Has VRE Answer Sheet  
been submitted for grading?

YES  NO

**REFERENCE**

(Textual support for the  
answer I chose can be  
found as shown below)

In Volume No: \_\_\_\_\_

On Page No: \_\_\_\_\_

In \_\_\_\_\_ (Left) \_\_\_\_\_ (Right)  
Column

Lines \_\_\_\_\_ Through \_\_\_\_\_

Remarks:

90370 02 8310


CDC 90370

# RADIOLOGY TECHNICIAN

(AFSC 90370)

Volume 2

*Osteology and Positioning*



Extension Course Institute

Air University

156

Prepared by  
MSgt Steven G. Hayes  
(AUTOVON 736-2809/2647)

Reviewed by  
Pamela Brown  
and  
Richard Taylor

Edited by  
David Crawford



SCHOOL OF HEALTH CAPE SCIENCES USAF (ATC)  
SHEPPARD AIR FORCE BASE, TEXAS 76311

EXTENSION COURSE INSTITUTE (AU)  
GUNTER AIR FORCE STATION, ALABAMA 36118

## Preface

WHAT DOES IT take to produce a diagnostic radiograph? Exact technique? Perfect processing? Proper film holder? Good equipment? As you know, it takes all of these factors, plus another very important one—proper positioning. All of the other factors can be perfect, but if the positioning isn't correct, the radiograph may not be diagnostic. You have, no doubt, taken your share of radiographs and realize the importance of proper positioning techniques. You are probably also aware of the fact that osteology and positioning go hand in hand. The ability with which you position the patient is directly related to your knowledge and application of osteology.

As you advance you will become more involved in quality control. You will have to evaluate radiographs and decide whether or not they are diagnostic. If not, you recommend the proper corrective measures to be taken. It is obvious that you will not be able to perform positioning quality control satisfactorily unless you have a good working knowledge of osteology and can apply the correct positioning techniques.

This volume is designed to provide you with information to aid you in quality control. The first three chapters review osteology. Chapters 4 through 8 include most all standard positions that are routinely done in every radiologic facility. Also, we present some frequently used special or additional positions. Some positions, standard and special, are covered in detail so that we may better explain important matters about those projections.

We do not recommend that you repeat all radiographs that were improperly positioned. There are other considerations, such as patient dosage, time element, and the amount of information revealed by the initial radiograph. We do recommend that you discuss quality control in detail with your radiologist. Get to know what he or she likes and dislikes and then repeat or accept the radiographs based on his or her preferences.

Foldout 1 is printed and bound at the back of this volume.

The inclusion of names of any specific commercial product, commodity, or service in this publication is for information purposes only and does not imply indorsement by the Air Force.

This volume is valued at 30 hours (10 points).

Material in this volume is technically accurate, adequate, and current as of 1983.

# Contents

	<i>Page</i>
<i>Preface</i> .....	iii
<i>Chapter</i>	
1 Osteology of the Extremities .....	1
2 Osteology of the Vertebral Column, the Ribs and the Sternum .....	25
3 Osteology of the Skull, the Facial Bones, and the Paranasal Sinuses .....	34
4 Positioning of the Upper Extremity .....	42
5 Positioning of the Lower Extremity .....	57
6 Positioning of the Chest and Abdomen.....	74
7 Positioning of the Vertebral Column .....	83
8 Positioning of the Skull.....	93
<i>Answers for Exercises</i> .....	108

## Osteology of the Extremities

WE BEGIN OUR study of osteology with the extremities. Some of the information in this chapter will, no doubt, seem "old" to you because you already have a good working knowledge of the material. Since you have performed many radiographs of the extremities, you must also realize by now that the effectiveness of your positioning is directly related to your knowledge of anatomy. Therefore, our review of basic osteology is reasonably complete.

In this chapter, we discuss anatomical reference terms, body planes, the lower extremity, including the pelvic girdle, and the upper extremity, including the shoulder girdle.

### 1-1. Body Planes and Anatomical Reference Terms

In addition to the specific anatomy, you must also know the relationships of the various parts. The imaginary planes of the body are important so, before we discuss the osteology of the extremities, let's quickly review some anatomical reference terms and the body planes.

#### 200. Identify the relative locations of various parts of the body.

**Anatomical Reference Terms.** To avoid any misunderstanding and confusion in describing the location of anatomical structures, we use the standard body position as a point of reference. This generally accepted standard position is called the normal anatomical position or anatomical position. This position is assumed when the body is standing erect, the arms are hanging at the sides, and the palms of the hands are turned forward (see fig. 1-1). When you use anatomical reference terms, you must visualize the body in this position.

"Anterior" and "ventral" refer to the front of the body; "posterior" and "dorsal," to the back. These terms may also be used to indicate relative positions within the body. For the hands, however, "palmar" is used instead of anterior. In describing the feet, "plantar" refers to the sole and "dorsal" to the upper surface. In describing the anterior surface of the forearm and hand, the term "volar" can be used.

"Medial" refers to structures located nearer the midline of the body; "lateral," to those nearer the side. For example, the tibia is medial to the fibula, and the fibula is lateral to the tibia. These terms may also be used to identify surfaces of various structures. For example, the thumb and little finger are located on the lateral and medial aspects of the hand respectively.

"Superior" refers to a position above a particular reference point; "inferior," to a position below a reference point. The thoracic vertebrae are superior to the lumbar vertebrae, and the lumbar vertebrae are inferior to the thoracic vertebrae.

"Proximal" means nearer the attachment of a limb or nearest the point of origin. "Distal" refers to a position remote from the point of attachment or farthest from the point of origin. For example, the shoulder joint is in the proximal arm, and the wrist joint is in the distal arm.

#### Exercises (200):

Indicate whether the following statements are true or false. If you indicate false, explain your answer.

- \_\_\_ 1. The elbow is proximal to the wrist.
- \_\_\_ 2. The ileum is proximal to the jejunum.
- \_\_\_ 3. The sole of the foot is the plantar surface.
- \_\_\_ 4. The sternum is on the anterior side of the body.
- \_\_\_ 5. The radius is medial to the ulna.
- \_\_\_ 6. The fibula is lateral to the tibia.
- \_\_\_ 7. The fourth cervical vertebra is superior to the first thoracic vertebra.

#### 201. Given definitions of the body planes, match each definition with the plane it describes.

**Planes of the Body.** The planes of the body are imaginary planes that divide it into sections. They are



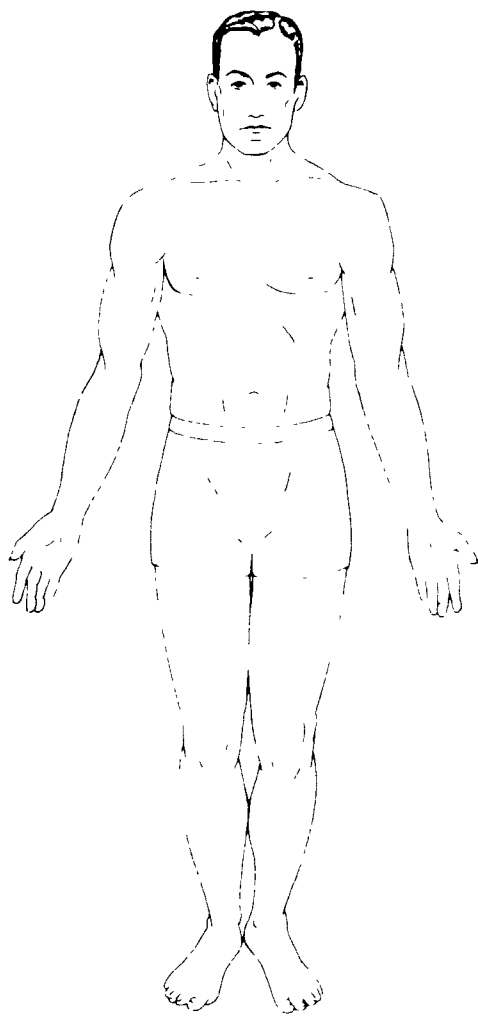


Figure 1-1 Normal anatomical position

useful as reference points for locating anatomical structure. The median or midsagittal plane divides the body into equal right and left halves. Any of the vertical planes that parallel the median are called sagittal planes. The frontal plane or coronal plane is any vertical plane that divides the body into anterior and posterior portions. The level of this plane must be given: for example, the umbilical plane cuts through the body at the level of the umbilicus (see fig. 1-2).

### Exercises (201):

- Match the body planes in column B with the information in column A.

Column A	Column B
— (1) Divides the right half of the body into medial and lateral portions.	a Median or midsagittal
— (2) Divides the body between the sternum and spine	b Sagittal or Frontal or coronal

Column A

Column B

- |   |                            |
|---|----------------------------|
| — (3) Divides the body into two equal halves                            | d Horizontal or transverse |
| — (4) Separates the umbilicus from the sternum                          |                            |
| — (5) Is perpendicular to the center of the film for an AP lumbar spine |                            |

## 1-2. The Lower Extremity and Pelvic Girdle

This section covers the toes and foot, the ankle, the leg, the knee and patella, the femur, and the pelvic girdle.

202. Indicate whether or not statements pertaining to the name, location, description, and number of bones and joints of the toes and foot are correct.

**The Toes and Foot.** The bones of the foot form an arch which, in an architectural sense, strongly resembles the old stone arches. The arch is comprised of wedges, cubes, and long, relatively straight sections, all of which join with each other to provide structural strength and mobility. The skeleton of the foot consists of three parts—the phalanges, the metatarsals, and the tarsal bones. Refer to figure 1-3 as you study the toes and foot.

**Phalanges.** The phalanges of the toes are arranged and identified in the same manner as are the phalanges of the hand. Each is composed of a body, a head, and a base. The tip of each distal phalanx terminates as the unguis tuberosity, or tuft. Each toe has three phalanges, except the first, which has only two. The phalanges of the first toe join in this way: the distal phalanx joins proximally with the distal end of the proximal phalanx, and the proximal phalanx joins the distal end of the first metatarsal.

The phalanges of the other toes join in much the same way as those of the first toe. The proximal portions, or bases, of the distal phalanges articulate with the distal portion, or heads, of the middle phalanges. The bases of the middle phalanges articulate with the heads of the proximal phalanges. The bases of the proximal phalanges, in turn, articulate with the heads of the metatarsals.

**Metatarsals.** The sole and lower instep are formed by the metatarsals, which are classified as short bones are identified by the numbers one through five from the medial to the lateral sides. Each bone has a body, a base, and a head. The metatarsals join distally with the corresponding proximal phalanges of the toes, and proximally they join the tarsal bones as follows:

a. The first metatarsal joins the distal end of the first cuneiform and the medial surface of the second metatarsal.

b. The second metatarsal joins the medial surface of the first cuneiform, the distal ends of the second and third cuneiforms, and the lateral and medial surfaces of the first and third metatarsals respectively.

c. The third metatarsal joins the distal end of the third cuneiform, the lateral surface of the second metatarsal, and the medial surface of the fourth metatarsal.

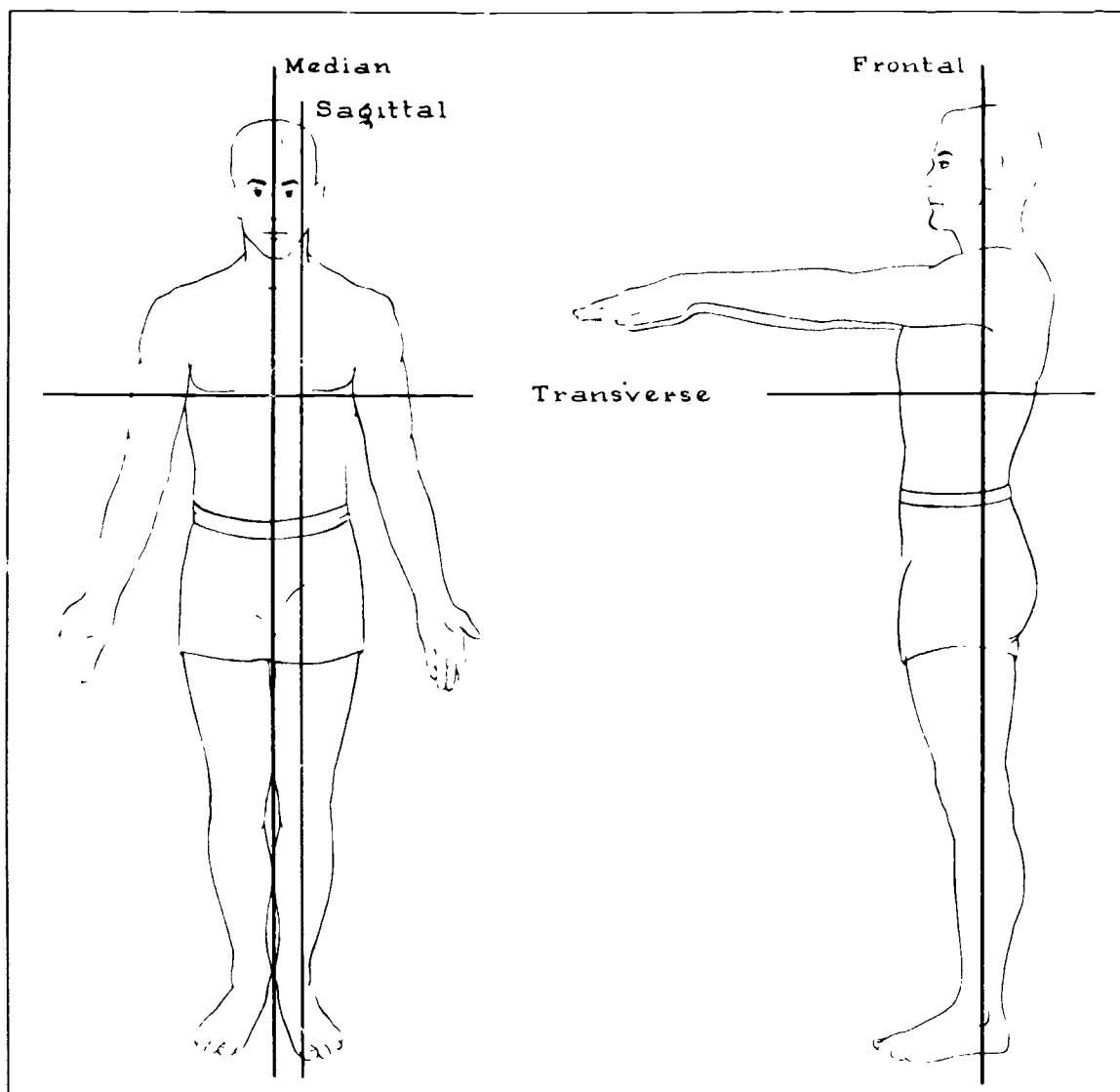


Figure 1-2 Planes of the body

d. The fourth metatarsal joins the distal end of the cuboid, the lateral surface of the third metatarsal, and the medial surface of the fifth metatarsal.

e. The fifth metatarsal joins the distal end of the cuboid and the lateral surface of the fourth metatarsal.

**Tarsals.** The tarsals, which are described below, make up the posterior part of the foot and part of the ankle. Because of their shape, they are classified as irregular bones. Some of them, like the carpals, are often referred to by more than one name.

The first, second, and third cuneiform bones are wedge shaped. They are located directly behind the first, second, and third metatarsals, and in front of the navicular. They are numbered from the medial to the lateral side.

The cuboid is on the lateral aspect of the foot, directly behind the fourth and fifth metatarsal bones. The navicular

(tarsal scaphoid) is on the medial side of the foot, directly behind the cuneiform bones.

The talus (astragalus), through which the body weight is transmitted to the foot, is the second largest tarsal. It is located behind the navicular and slightly higher than the other tarsals. The talus has a head, a neck, and a body. The head is directed slightly medially and upward to articulate with the navicular. The superior portion of the body is a smooth, trochlea-like surface, which articulates with the tibia. The inferior surface has two smooth surfaces, which articulate with the calcaneus. A deep groove, the sulcus tali, separates the smooth surfaces.

The calcaneus (os calcis), the largest of the tarsal bones, is located on the extreme posterior portion of the foot, beneath the talus. The superior surface of its anterior two-thirds supports the talus and receives the body weight

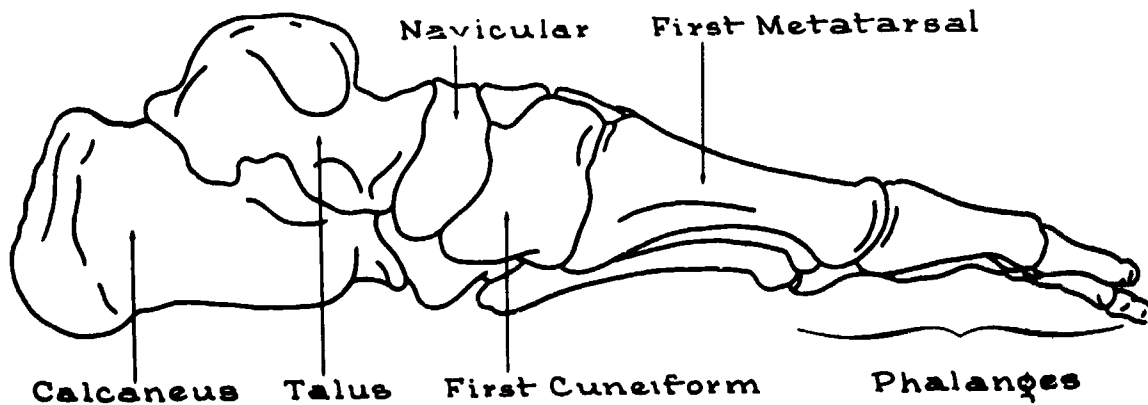
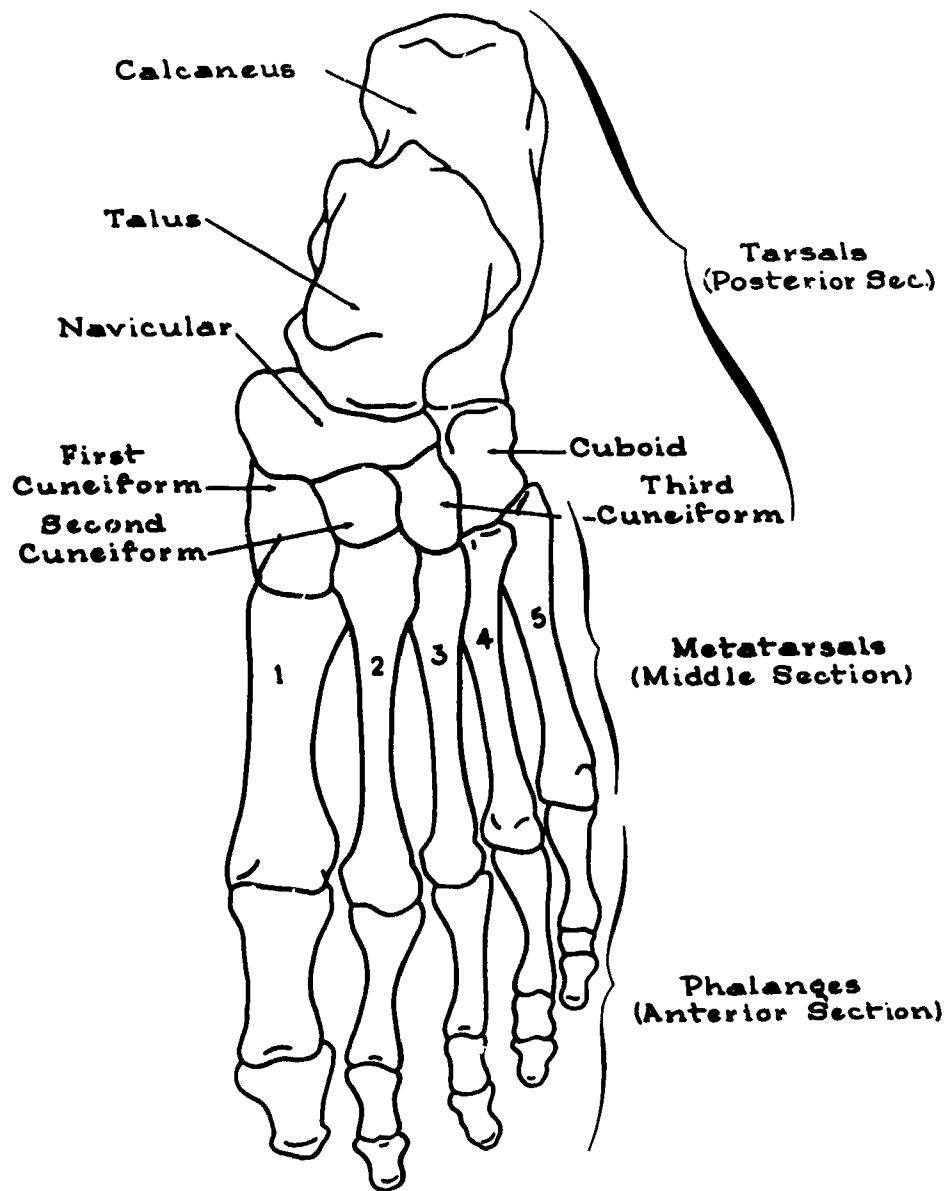


Figure 1-3. Skeleton of the toes and foot.

transmitted from the talus. The posterior one-third forms the heel. The calcaneal tuberosity lies on the posterior part of the interior surface. It is slightly depressed in the middle and runs to both sides to form the lateral and medial processes. A projection on the superoanterior part of the medial calcaneal surface is called the sustentaculum tali.

### Exercises (202):

Indicate whether the following statements are true or false (explain false statements).

- \_\_\_ 1. There are 14 phalanges in the toes.
- \_\_\_ 2. The third toe has two phalanges.
- \_\_\_ 3. The first toe has three phalanges.
- \_\_\_ 4. In the fourth toe, the head of the distal phalanx articulates with the base of the middle phalanx.
- \_\_\_ 5. There are five metatarsal bones.
- \_\_\_ 6. The fourth metatarsal is located on the lateral side of the third metatarsal.
- \_\_\_ 7. The metatarsals articulate distally with the phalanges.
- \_\_\_ 8. The first, second, and third metatarsals articulate with the cuneiform bones.
- \_\_\_ 9. Only four metatarsals join with another metatarsal.
- \_\_\_ 10. There are seven tarsal bones.

- \_\_\_ 11. The first cuneiform is located on the lateral side of the foot.
- \_\_\_ 12. The talus is the largest tarsal bone.
- \_\_\_ 13. The most superior tarsal bone is the talus.
- \_\_\_ 14. The navicular is on the medial side of the cuboid.
- \_\_\_ 15. The heel bone is the calcaneus.
- \_\_\_ 16. The sustentaculum tali is located on the talus.
- \_\_\_ 17. There are 27 bones of the foot and toes.

### 203. Describe the osteological structure of the ankle.

**The Ankle.** Our discussion of the osteology of the lower extremity continues with the ankle. The ankle is classified as a diarthrodial articulation, or a hinge-type joint. It is formed by the distal articular surface of the tibia, the medial malleolus of the tibia, the talus, and the lateral malleolus of the fibula. These bony structures form a "mortise"—a preshaped and fitted joint—which is held in place by various ligaments and muscle tissue. The distal articular surface of the tibia and the superior articular surface of the talus form the horizontal portion of the mortise. The medial malleolus, which is continuous with the distal portion of the tibia, articulates with the medial aspect of the talus and forms the medial side of the mortise. The lateral malleolus of the fibula articulates with the lateral aspect of the talus and forms the lateral side of the mortise. The distal articular surface of the tibia and the superior articular surface of the talus are parallel to each other and also parallel to the horizontal plane. The malleoli, however, are angled about  $10^\circ$  off the perpendicular plane; thus, they form an angle of about  $80^\circ$  with the horizontal articular surfaces of the tibia and the talus. These angles are important for weight bearing and mobility. Some injuries to the ankle mortise are severe, and every effort is made to maintain these angles during the treatment of the injuries. Figure 1-4 illustrates the ankle joint, and figure 1-5 illustrates the angles formed by the ankle mortise.

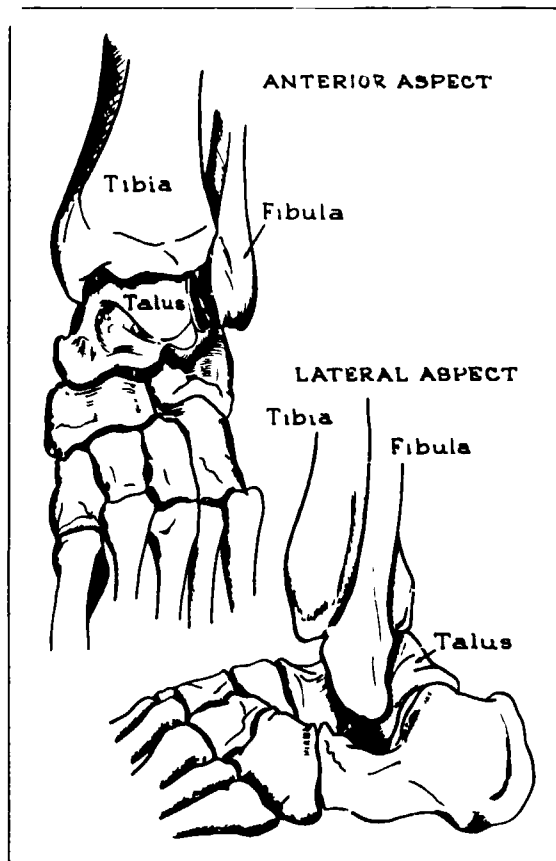


Figure 1-4 The ankle joint

**Exercises (203):**

1. What three major bones make up the ankle joint?
2. On which bone is the medial malleolus?
3. On which bone is the lateral malleolus?
4. Why are the angles formed by the ankle mortise important?
5. What type of joint is the ankle?

**204. Name, locate, and describe the osteological parts of the leg.**

**The Leg.** The leg consists of two bones—the tibia and the fibula. We shall consider each separately, starting with the tibia. Using figure 1-6 as a reference will help you understand the descriptions.

**The tibia.** The larger of the two bones, commonly called the shin bone, is the tibia, located on the medial side of the leg. It has a shaft and two ends. The distal end of the tibia is much smaller than the proximal end. The inferior surface is smooth and articular, and the medial surface extends downward to form the medial malleolus.

The shaft of the tibia is somewhat triangular with three surfaces and three borders. The anterior crest, or border, which runs from just above the tibial tuberosity to the anterior margin of the medial malleolus, can be easily located by palpation. The medial border begins at the posterior portion of the medial condyle and extends downward to the posterior portion of the medial malleolus. The lateral border, often referred to as the interosseous crest, begins in front of the articular surface of the fibular head and extends down the bone. The medial surface is smooth and slightly convex; the lateral surface is narrower than the medial. We can describe the posterior surface best if we divide it into thirds. The proximal third ends in the popliteal line. The middle third has a vertical ridge that starts at the popliteal line and gradually becomes indistinct as it descends. The distal third is smooth.

The major parts of the proximal tibia are the superior articular surface, the medial and lateral condyles, the intercondylar eminence, and the tibial tuberosity. The superior articular surface has two smooth articular surfaces which are separated by a groove. The smooth surface on the medial side is the superior surface of the medial condyle. The corresponding lateral surface is the superior articular surface of the lateral condyle. Both of these surfaces articulate with the condyles of the femur to form the knee joint. The grooves that separate these surfaces are the anterior and posterior intercondyloid fossae. Located in the middle of the intercondyloid fossa is the intercondyloid eminence or spine of the tibia. Just below the condyles, anteriorly, is the tibial tuberosity, which serves as the attachment place for the patellar ligament. The posterior surface of the proximal tibia contains the posterior intercondyloid fossa. On the posterior surface of the medial condyle a deep groove runs transversely, and on the posterior surface of the lateral condyle is an articular surface for the head of the fibula.

**The fibula.** The fibula, the smaller of the two leg bones, is located on the lateral side of the leg, where it acts as a split for the tibia. It also serves as an attachment place for muscles and forms the lateral portion of the ankle joint. Like the tibia, it has a shaft and two ends. The distal end of the fibula is shaped somewhat like a pyramid and contains the lateral malleolus, which extends downward to complete the ankle mortise.

The shaft of the fibula has four borders and four surfaces. The anterior portion is divided into the anterolateral and anteromedial borders. The anterolateral border begins,

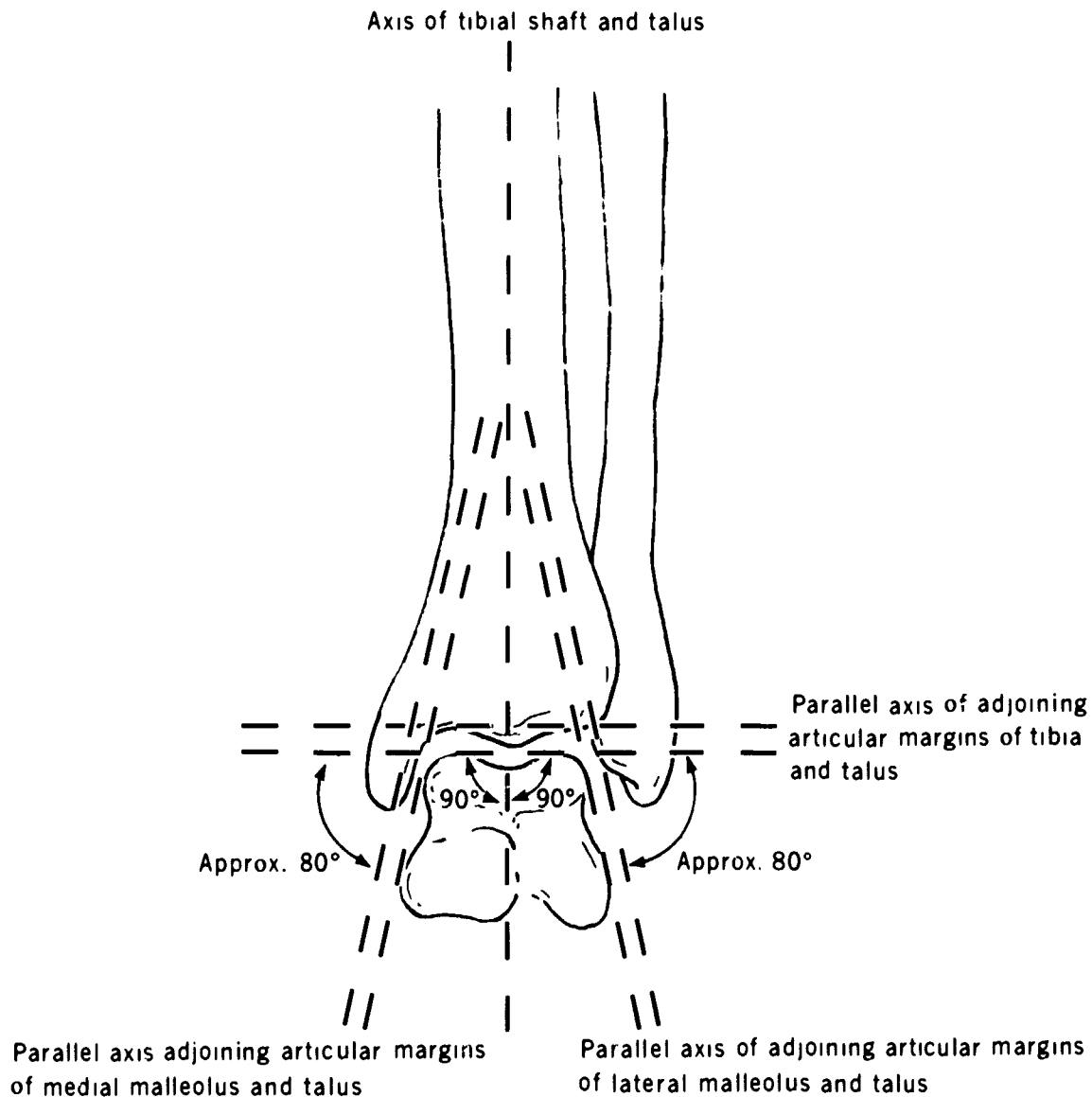


Figure 1-5 The angles formed by the ankle mortise

proximally, in front of the fibular head and runs distally for about half the length of the bone. The anteromedial border, often called the interosseous crest, begins just below the fibular head and runs distally, parallel with the anterolateral border, for the proximal one-third of the bone. The posterior portion of the shaft is also divided into two borders: the posterolateral and the posteromedial. The posterolateral border begins just above the fibular styloid process and extends downward to the posterior portion of the lateral malleolus. The posteromedial border, often called the oblique line, begins at the medial side of the fibula and extends obliquely downward to the interosseous crest. The anterior surface is between the anteromedial and anterolateral borders. The posterior surface is between the posterolateral and posteromedial borders.

The upper expanded end of the fibular head articulates with the fibular articular surface of the lateral condyle of the tibia. However, the head of the fibula does not enter into the formation of the knee joint. The styloid process is that portion of the head that rises to a point above the articular surface.

**Exercises (204):**

1. What two bones comprise the leg?

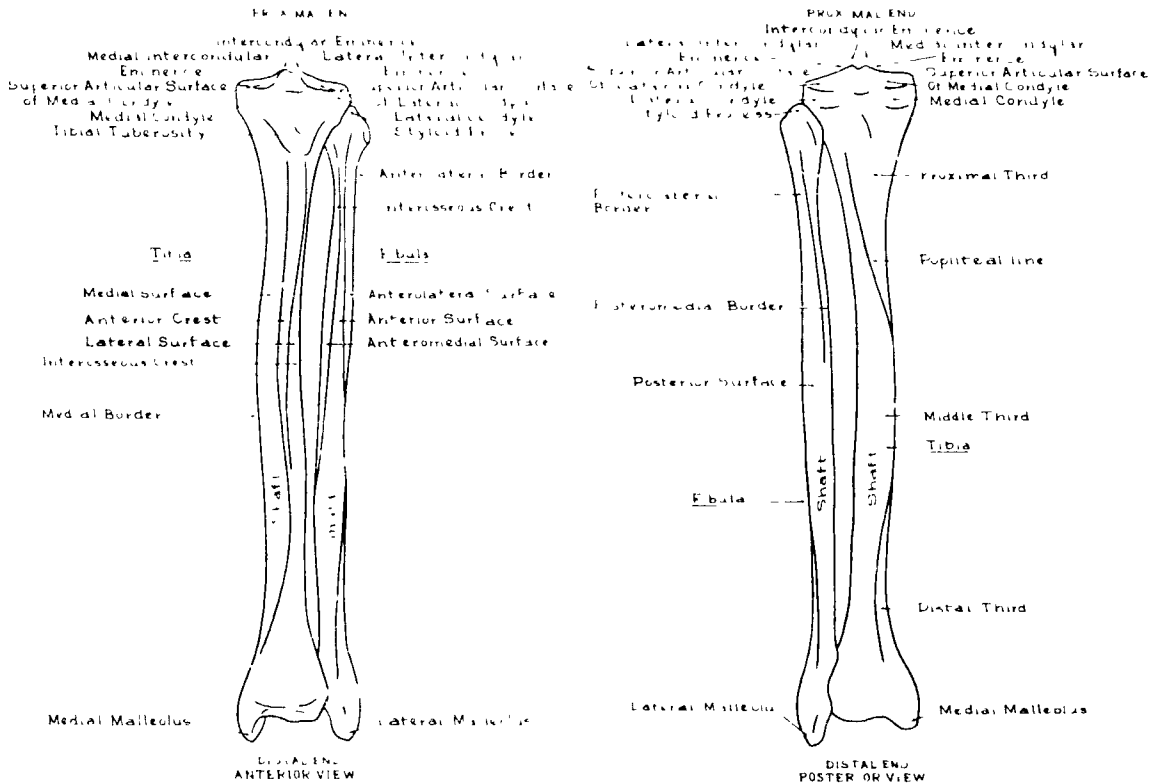


Figure 1-6 Bones of the leg

2. Which leg bone is smallest?
  3. What is the most distal portion of the tibia?
  4. What is another name for the lateral border of the tibia?
  5. Name the major parts of the proximal tibia.
  6. Where does the patellar ligament attach to the tibia?
  7. What is the most distal portion of the fibula?
  8. Where is the head of the fibula?
  9. Where is the fibula styloid process located?
  10. With what bone does the proximal portion of the fibula articulate?
205. Given a list of the parts of the knee and patella, match each with an appropriate descriptive statement or phrase.

**The Knee and Patella.** The knee is classified as a diarthrodial (hinge-type) joint. It consists, basically, of the proximal articular surface of the tibia, the distal articular surfaces of the femur, and the patella. The tibio-femoral articulations, though, are the parts most generally considered to be the "knee," while the patella is thought of as a separate entity. Therefore, we will first consider the knee as it is classically described, and then the patella.

**The knee.** We have already discussed the proximal articular surface of the tibia, so let's look at the femur. The distal articular surface of the femur consists of two large condyles, one medial and one lateral. They are separated by a large, tunnel-shaped notch, called the intercondyloid fossa. The distal portions of these condyles are smooth and convex to enable articulation with the tibial condyles.

Two rough elevations, one on the lateral side of the lateral condyle and the other on the medial side of the medial condyle, superior to the articular surfaces of both, form the lateral and medial epicondyles respectively. On these eminences are attached the ligaments that, with those attached to the tibia, bind the joint.

The articulation formed by the femoral and tibial condyles are referred to as the tibiofemoral joints (see fig. 1-7).

**The patella.** The largest sesamoid bone in the body is situated in front of the knee joint—hence its common name, "kneecap." It is regarded as a sesamoid bone because it is developed within a tendon, has an ossification center presenting a tuberculated outline, and is comprised of dense, cancellous tissue. The patella is roughly diamond-shaped, with the narrow end (the apex) pointed down (see fig. 1-8). The superior aspect of the patella is round and much wider than the apex. The anterior surface is somewhat convex and is pitted by orifices that permit the passage of nutrient vessels. The superior surface of the posterior patella is divided into two articular facets to permit articulation with the slightly V-shaped articular surface of the anterior portion of the distal femur (see fig. 1-7). The interior surface is roughened for the attachment of the patellar ligament. The patella is superiorly housed in the expansion of the quadriceps femoris tendon (the large muscle group of the anterior thigh) and is inferiorly contained by the fiber of the patellar ligament. Both fibrous bands are continuous with each other, which accounts for the apparent "suspension" of the patella.

### Exercises (205):

- Match the knee or patellar part in column B with the appropriate statement in column A. Each column B item may be used once or not at all.

#### Knee

##### Column A

- (1) Between the femoral condyles
- (2) Diarthrodial or hinge-type
- (3) Articulates with medial tibial condyle
- (4) Elevation on lateral side of femoral condyle

##### Column B

- a Knee joint
- b Intercondyloid fossa.
- c Femoral condyle
- d Condylar notch
- e Epicondyle

#### Patella

- (5) Inferior portion
- (6) Joins with femur
- (7) Receives nutrients

- a Articular facet
- b Anterior surface
- c V-shaped articular surface
- d Apex

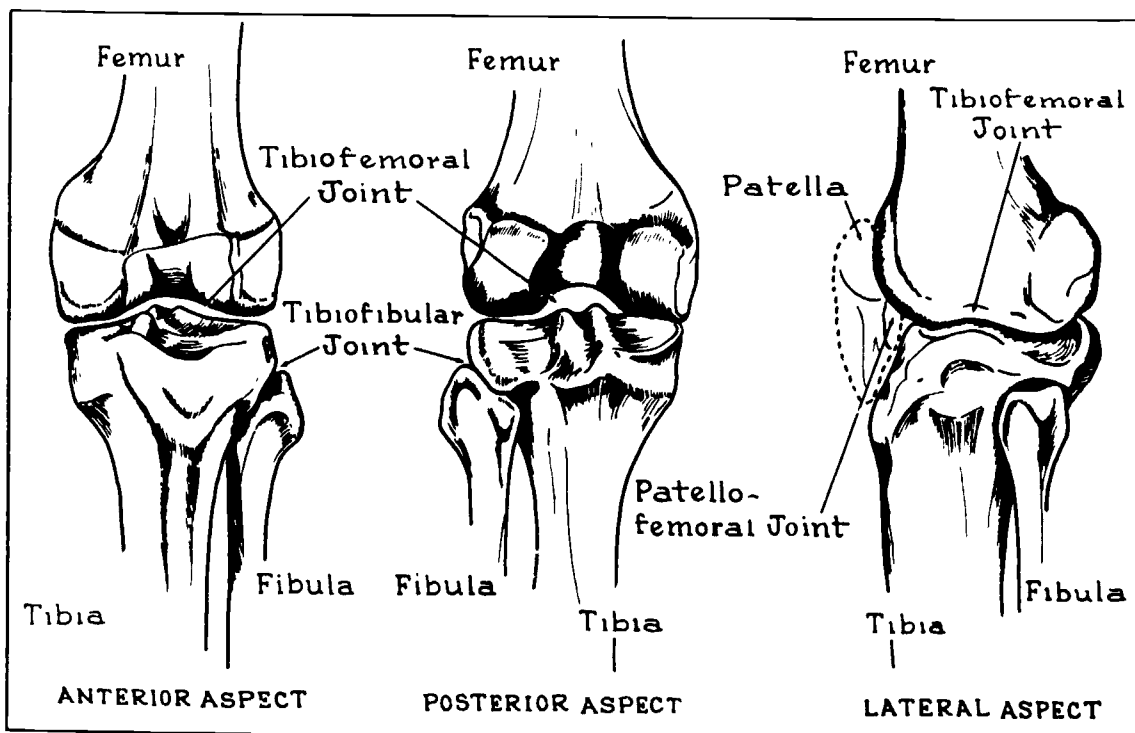


Figure 1-7 The knee joint



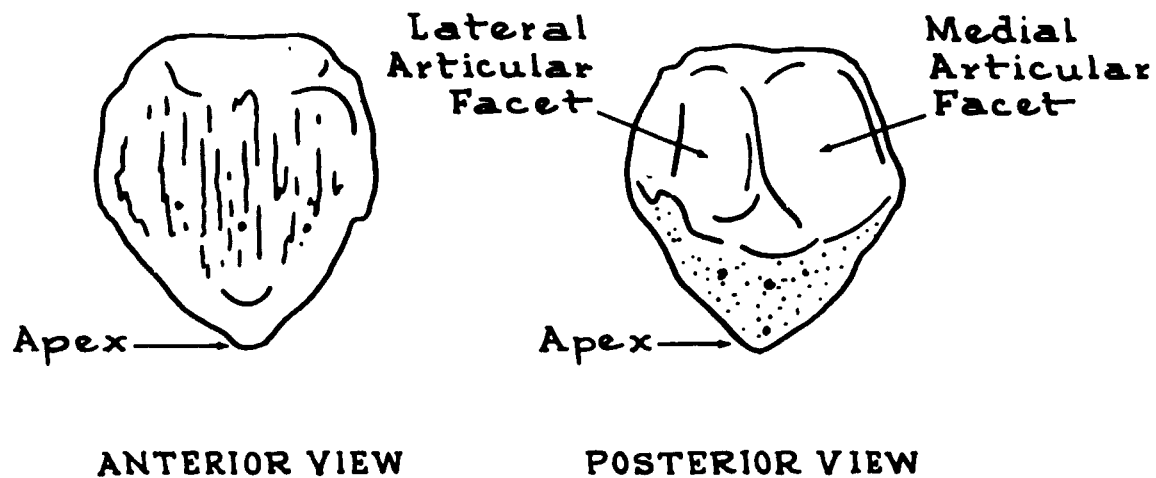


Figure 1-8 The patella

**206. Name, locate, and describe the osteological parts of the femur.**

**The Femur.** The femur, or thigh bone, extends from the knee joint to the hip joint. From the hip joint, the femur is directed somewhat medially and posteriorly so that, at the knee joint, it is near the center of gravity for the body. The femur, classified as a long bone, consists of a shaft and two ends. We have already discussed the distal end, so let's turn to the shaft.

**Shaft.** The shaft is the long, rounded portion of the bone that extends from the intertrochanteric crest, proximally, to just above the epicondyles, distally. It is broader at the ends than in the middle and is widest at the distal end.

The posterior surface of the shaft contains the *linea aspera*, a rough prominence that occupies the middle one-third. Several less prominent ridges extend above it; below it, two prominent ridges extend downward to form the triangle on the distal portion of the posterior femoral shaft. The area within the triangle, deriving its name from the popliteal artery, is called the popliteal space.

**Proximal end.** This part consists of the head, the neck, the greater trochanter, and the lesser trochanter. The lesser trochanter is a small, rounded prominence on the lower portion of the femoral neck. The greater trochanter is a large, palpable, irregular prominence that extends outward and slightly backward from the junction of the femoral neck with the femoral shaft. The intertrochanteric crest is the ridge of bone that extends obliquely downward from the greater trochanter to the lesser trochanter.

The neck is the constricted portion that unites the head with the body of the femur, and the head is the upper, rounded, expanded area that joins with the acetabulum to form the hip joint. Near the center of the head is an ovoid depression called the *fovea capitis* where the *ligamentum teres* attaches. The femur is shown in figure 1-9.

**Exercises (206):**

1. Name the rough area on the posterior middle third of the femur.
2. Give the configuration and location of the popliteal space.
3. On which side (anterior or posterior) of the femur is the intertrochanteric crest located?
4. In what direction(s) does the neck of the femur extend from the femoral body?
5. What part of the femur helps form the hip joint?
6. Can the greater trochanter be palpated?
7. Name the depression on the center of the femoral head.

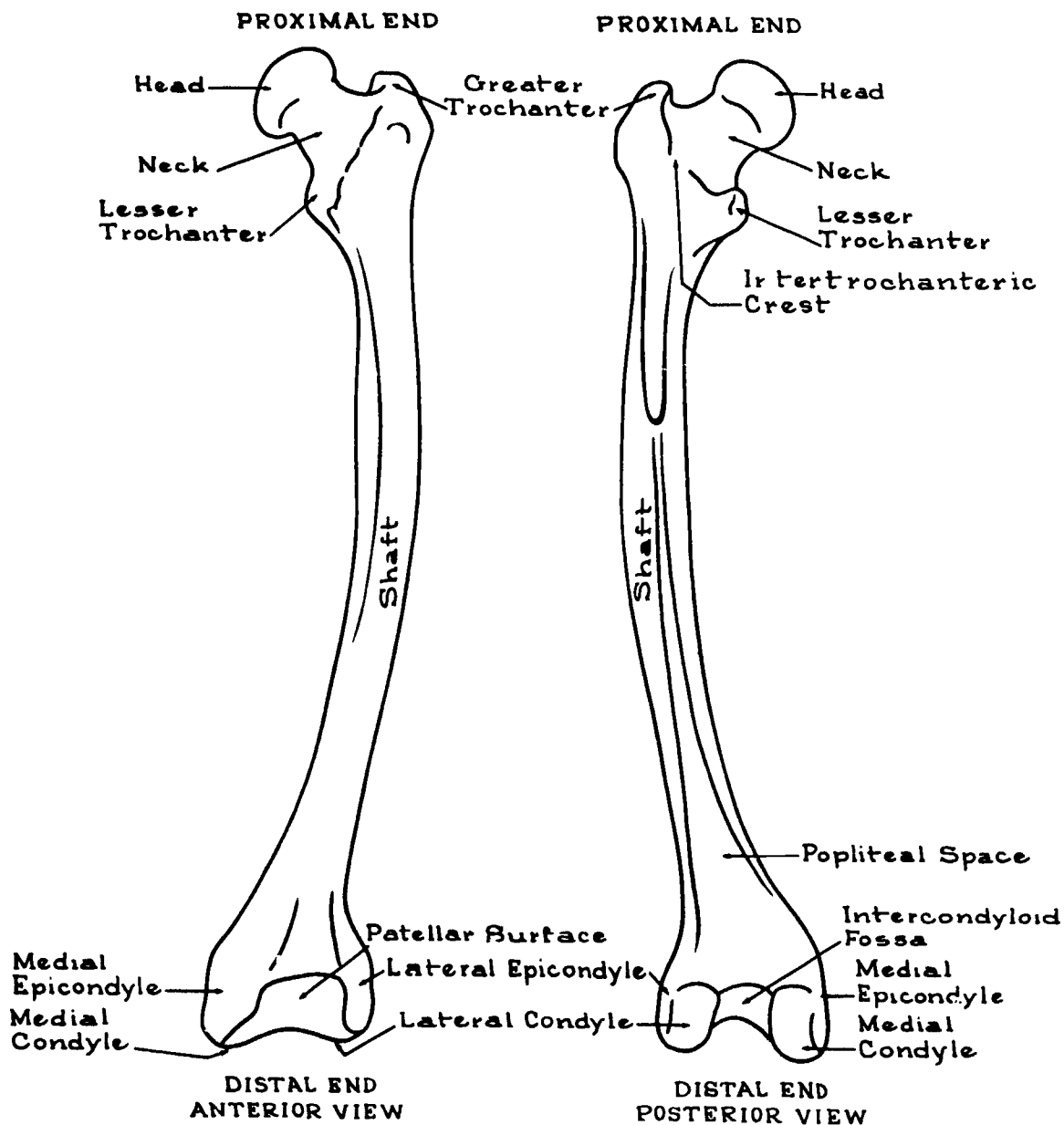


Figure 1-9 The femur

207. Identify the correct location or proximity of the innominate bones and pelvis.

**The Pelvic Girdle.** The pelvic girdle consists of the two innominate, or hip, bones; the pelvis; the sacrum; and the coccyx. It also provides five articular surfaces consisting of both hips, both sacroiliac joints, and the symphysis pubis. We will investigate the bony parts first, and then the articulations.

**The innominate bones.** Each innominate bone, commonly called the hip bone, is formed by the fusion of

what were once three separate bones. In the adult skeleton, the two innominate bones form the anterior and lateral walls of the pelvic girdle (see fig. 1-10).

The upper portion of the innominate bone is the ilium. Its major components and landmarks are: the body, the ala, the iliac fossa, the articular surface, the iliac crest, the anterosuperior iliac spine (ASIS), the anteroinferior iliac spine (AIIS), the posterosuperior iliac spine (PSIS), the posteroinferior iliac spine (PIIS), and the greater sciatic notch.

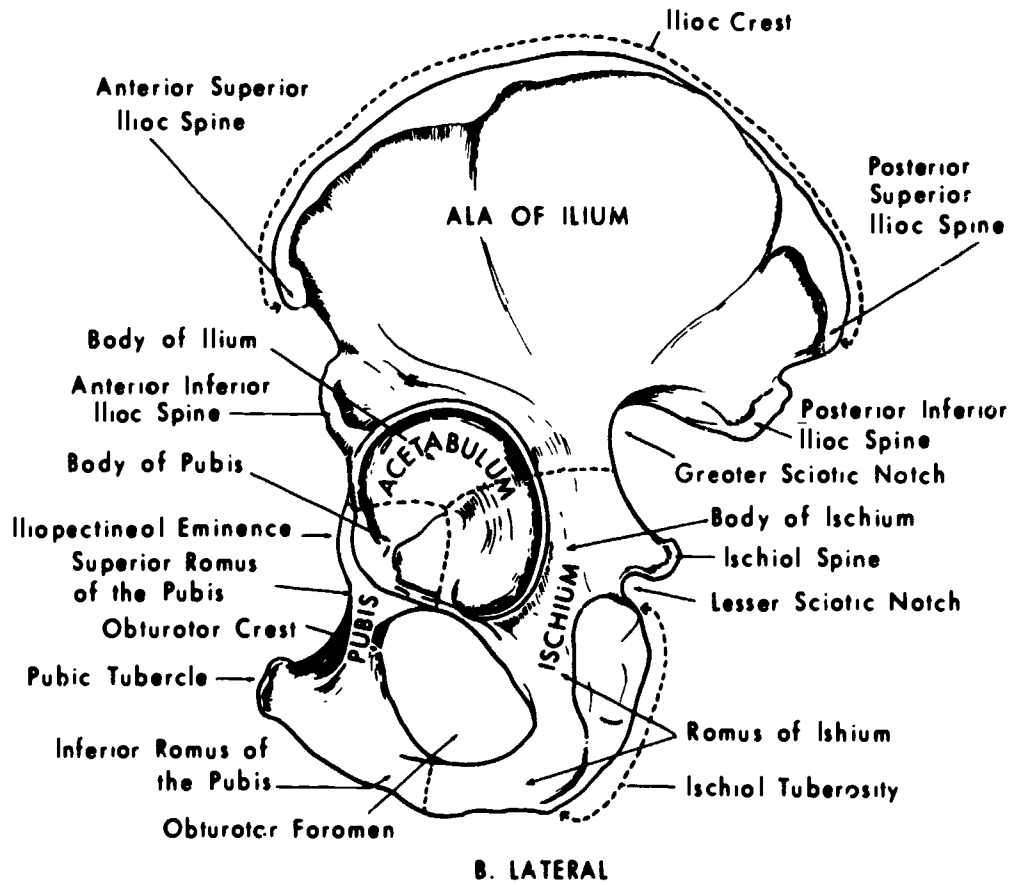
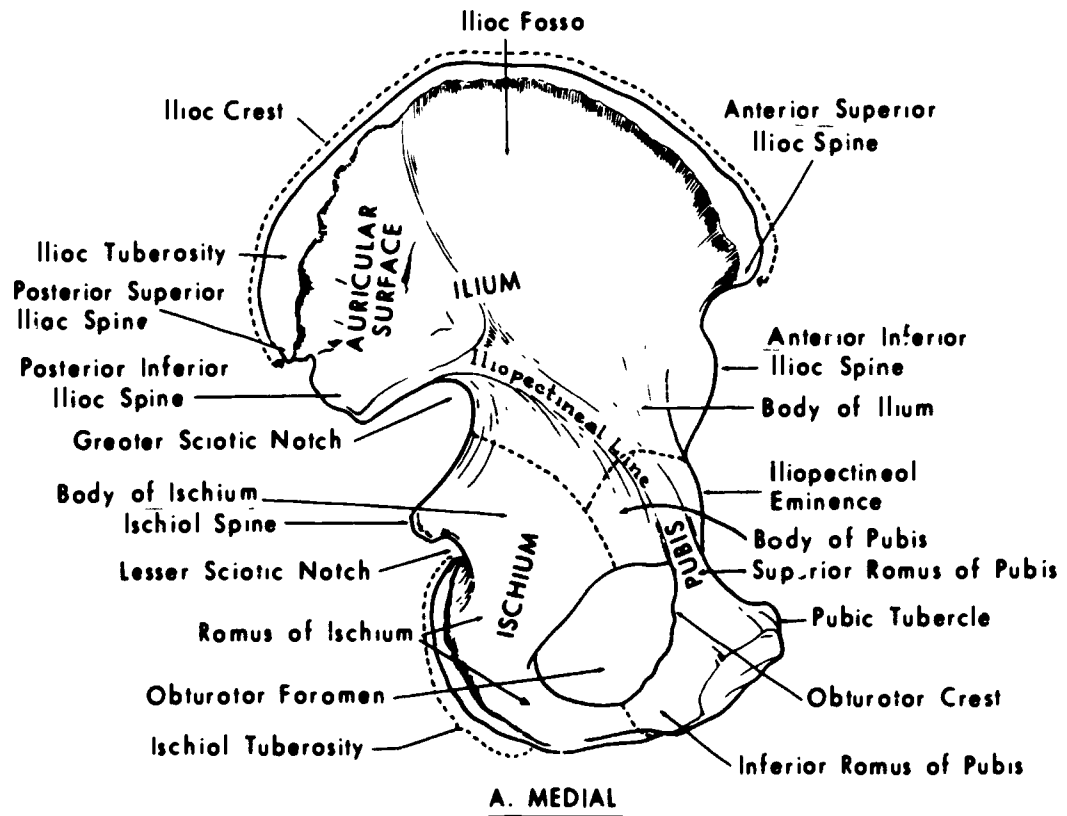


Figure 1-10. The innominate bone

a. The body of the ilium is the thick part of the bone just above the acetabulum.

b. The ala (from a Latin word meaning "wing") is the winglike portion of the ilium.

c. The iliac fossa is a large area on the inside surface of the ala—bounded by the iliac crest superiorly and by the arcuate line inferiorly.

d. The articular surface, often called the auricular surface because of its "ear" shape, is that part of the internal alar surface that articulates with the corresponding articular surface of the sacrum to form the sacroiliac joint.

e. The crest of the ilium (iliac crest) is the upper, curved border of the ala.

f. The easily palpable anterosuperior iliac spine is the bony prominence located where the iliac crest joins the rest of the anterior iliac border.

g. The anteroinferior iliac spine is a bony prominence located on the anterior border at a level about 1 inch lower than the anterosuperior iliac spine.

h. The posterosuperior iliac spine is the bony prominence located where the iliac crest joins the rest of the posterior border.

i. The posteroinferior iliac spine is the bony prominence directly below the posterosuperior iliac spine on the posterior border.

j. The greater sciatic notch is a large notch just below the posterior inferior iliac spine.

k. The ilium forms part of the acetabulum.

The ischium is the lower posterior part of the innominate bone. Its major parts and landmarks are the body, the ischial spine, the lesser sciatic notch, the superior ramus, the ischial tuberosity, and the inferior ramus.

a. The body of the ischium is the thick part of the bone directly behind and below the acetabulum. It also forms part of the acetabulum.

b. The ischial spine is a pointed prominence extending backward and medially from the posterior surface.

c. The lesser sciatic notch is a small notch just below the ischial spine.

d. The ramus is that part of the bone that descends from the ischial body.

e. The ischial tuberosity is the large expanded part located at the posterior surface of the ramus.

The pubis forms the lower anterior part of the innominate bone. Its major parts and landmarks are the body, the superior ramus, the pubic tubercle, the iliopectineal eminence, the obturator crest, and the inferior ramus.

a. The body makes part of the anterior portion of the acetabulum.

b. The superior ramus is somewhat triangular shaped and extends upward and backward from the pubic body to the acetabulum.

c. The pubic tubercle, often called the pubic spine, is a small prominence located on the upper border of the pubic body.

d. The iliopectineal eminence, sometimes called the iliopubic eminence, is a rough eminence marking the fusion site of the ilium and the pubis.

e. The obturator crest is the lower border of the superior ramus and extends from the pubic tubercle to the lower margin of the iliopectineal eminence in front of the acetabular notch. It is part of the obturator foramen.

f. The inferior ramus is the part of the bone that extends downward from the pubic body to join the ramus of the ischium.

g. The obturator foramen is a large hole between the ischium and the pubic bones.

h. The pubic arch is the arch formed by the ramus of the ischium and the inferior ramus of the pubis as they extend upward and join at the inferior aspect of the symphysis pubis. It is usually a broad, rounded curve in the female and a much smaller, narrower, inverted, V-shaped angle in the male.

i. The acetabulum is the cup-shaped depression that receives the head of the femur in forming the hip joint.

**The pelvis.** The pelvis is formed by the innominate bones, the sacrum, and the coccyx. The oval, bony ridge on the inner pelvic surface is the pelvic brim. It begins at the superior border of the symphysis pubis and extends upward on both sides along the superior rami of the pubis and the iliopectineal lines until it meets at the center of the sacral promontory.

The false pelvis, often called the major or greater pelvis, is the part of the lower abdomen bounded by the pelvic brim and by the alae of the ilia on the sides. The true pelvis, also called the minor or lesser pelvis, is bounded by the pelvic brim above, the sacrum and coccyx behind, and the symphysis pubis in front. These structures form the pelvic inlet and outlet (see fig. 1-11).

#### Exercises (207):

Indicate whether the following statements are true or false. If you indicate false, explain your answer.

- \_\_\_ 1. The three bones that comprise the innominate bones are the ilium, the pubis, and the ischium.
- \_\_\_ 2. The iliac crest extends from the ASIS to the PIIS.
- \_\_\_ 3. The sacrum articulates with a portion of the iliac wing.
- \_\_\_ 4. The PSIS is located on the ilium.
- \_\_\_ 5. The ASIS is easily palpable.

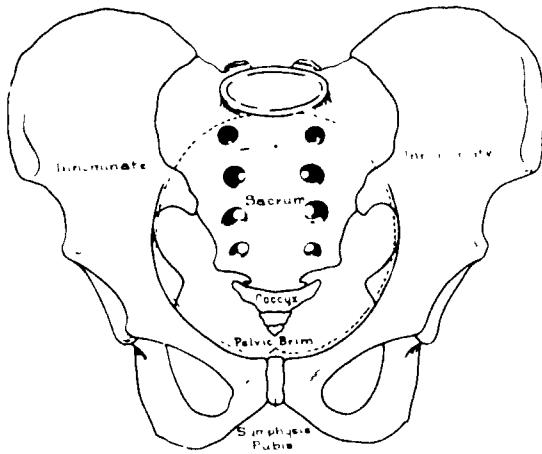


Figure 1-11 The pelvis

- 14. The posterior margin of the false pelvis is formed by the sacrum and coccyx.
- 208. Describe the anatomy of the sacrum and coccyx by giving the name, number, location, and description of the various parts.**
- The sacrum.* The sacrum is formed from five atypical individual vertebrae, which until about age 18, are separated by cartilage. The sacrum resembles a triangular wedge and is located between the two innominate bones at the lower part of the vertebral column directly below the lumbar vertebrae. In this location, it forms part of the posterior limit of the pelvic cavity. Its main components and landmarks are its anterior surface, posterior surface, lateral surfaces, base, apex, and sacral canal. We will consider the anterior surface first.
- a. The anterior surface is concave and has four transverse lines representing the original separation of the sacral vertebrae. Between these lines are the bodies of the vertebrae. The first, or top, vertebra is the largest; the others become smaller as the sacrum descends. On the sides of the transverse lines are the anterior sacral foramina, which provide passage for several nerves and arteries.
- b. The posterior surface is convex and has a prominent ridge, the midsacral crest, descending from its midportion. The first sacral vertebra has superior articular facets with smooth articular surfaces that extend posteromedially and articulate with the fifth lumbar vertebra. The inferior articular facets of the fifth sacral vertebra are round and extend downward to articulate with the articular processes of the first coccygeal vertebra. Laterally, from the articular crest, are the posterior sacral foramina.
- c. The lateral surfaces, in regard to the posterior portion, have bilateral, ear-shaped surfaces, which articulate with the ilia to form the sacroiliac joints. As the lateral surfaces descend, they become narrower towards the extreme tip of the lateral surface or the inferolateral angle.
- d. The base of the sacrum is formed by the superior surface of the first sacral vertebra and has three parts—a middle part and two lateral surfaces. The middle part consists of an oval articular surface on the body of the first vertebra. This area has an important bony landmark called the promontory. The two lateral surfaces of the sacral base, often called the ala of the sacrum, are represented by the fused costal and transverse processes.
- e. The apex is the inferior part of the sacrum that joins with the coccyx.
- f. The sacral canal is located near the posterior part of the sacrum and extends from the first to the fifth vertebra. It is formed by the posterior aspect of the sacral vertebral bodies and the fusion of the laminae and spinous processes (see fig. 1-12).
- The coccyx.* The coccyx, commonly called the tailbone, is the last segment of the vertebrae in the vertebral column and is generally formed by the fusions of four atypical vertebrae. It has an anterior surface, a posterior surface, a base, and an apex, shown in figure 1-13.
- 6. The greater and lesser sciatic notches are on the ilium.
- 7. The ischial spine is between the greater and lesser sciatic notches.
- 8. Part of the ilium, ischium, and pubis make up the acetabulum.
- 9. There are two obturator foramina in the innominate bones.
- 10. The inferior ramus of the pubis and the body of the ischium form the pubic arch.
- 11. The pubic arch in the male is shaped like an inverted V.
- 12. Four major bones form the pelvis.
- 13. The true pelvis is separated from the false pelvis by the pelvic brim.

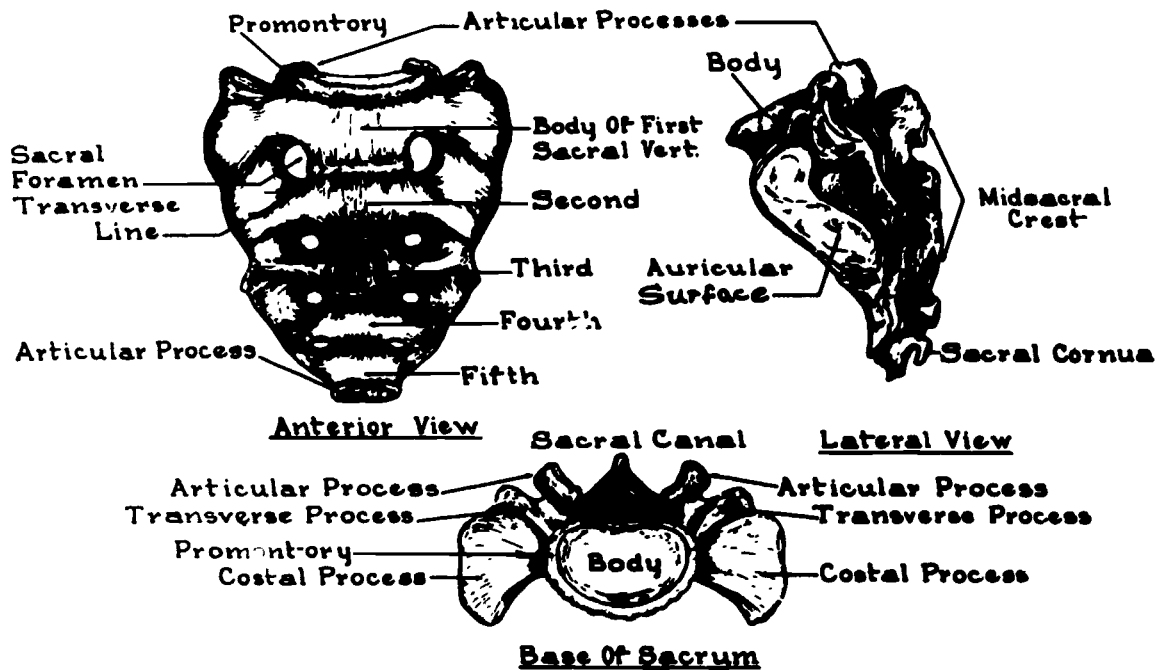


Figure 1-12 The sacrum.

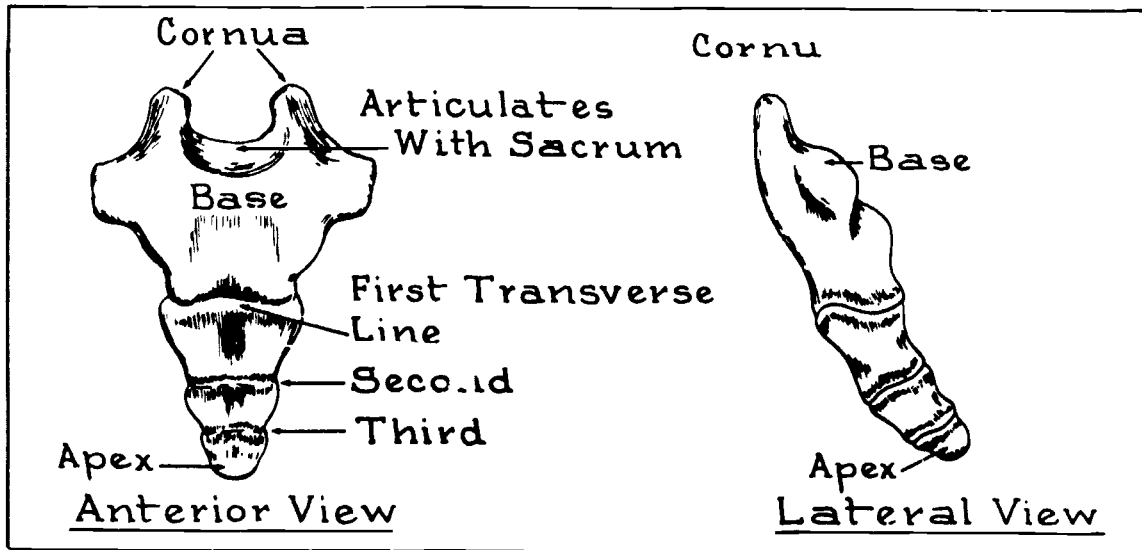


Figure 1-13 The coccyx.

a. the anterior surface resembles the anterior surface of the sacrum because it is concave and has three transverse lines that mark the former separations between the coccygeal vertebrae.

b. The posterior surface of the coccyx resembles, in miniature, the posterior surface of the sacrum. Extending upward from the coccygeal base are the coccygeal cornua that join the sacral cornua of the sacral apex.

c. The base is the superior surface of the first coccygeal vertebra and joins with the apex of the sacrum.

d. The apex is the extreme distal tip of the last coccygeal vertebra.

#### Exercises (208):

1. How many sacral vertebrae are there?
2. Which sacral vertebra is the largest? The smallest?
3. The midsacral crest is located on the \_\_\_\_\_ side of the sacrum.
4. With what vertebra does the superior articular facets of the sacrum articulate?
5. With what vertebra does the inferior articular facets of the fifth sacral vertebra articulate?
6. The lateral surfaces of the sacrum articulate with the \_\_\_\_\_ to form the \_\_\_\_\_.
7. What is the sacral promontory, and where is it located?
8. Where is the sacral canal located with respect to the sacral body?
9. How many coccygeal vertebra are there?
10. What are the transverse lines of the coccyx?

11. What are the two bony projections that extend superiorly from the coccygeal base?

12. The superior portion of the first coccygeal vertebra is called the \_\_\_\_\_ and the inferior tip of the fourth coccygeal vertebra is called the \_\_\_\_\_.

#### 1-3. Osteology of the Upper Extremity and Shoulder Girdle

The upper extremity includes the fingers and the hand, the wrist, the forearm, the elbow, the humerus, and the shoulder girdle.

**209. Characterize the anatomy of the fingers, hand, and wrist by giving the name, number, location, and description of the various parts.**

**The Fingers and the Hand.** Nineteen bones form the hand. They are divided into two groups—the phalanges, which form the fingers, and the metacarpals, which form the palm.

**The phalanges.** Each digit has three phalanges, except the thumb, which has two. Each phalanx has a body, a head or distal end, and a base or proximal end. The phalanges are not named but are identified by their location and number, counted from the thumb to the little finger (see fig. 1-14). For example, the phalanx of the thumb nearest the palm is the proximal phalanx of the first digit; the middle phalanx of the middle finger is the middle phalanx, third digit; and the distal phalanx of the little finger is the distal phalanx, fifth digit. The distal phalanges are distinguished by their small size and by the unguis tuberosity (or tuft) at their distal ends.

**The metacarpals.** The five metacarpals are the longer bones that form the palm of the hand. Each has a body, a head or distal end, and a base or proximal end. The metacarpals do not have names, but they are identified by the numbers 1 through 5, counted from the thumb to the little finger. Again, see figure 1-14. The first metacarpal is shorter and wider than the others.

**The Wrist.** The wrist, or carpus, is arranged in distal and proximal rows (see fig. 1-15). The carpals, classified as short bones, are cube-shaped and are identified by name from the radial or thumb side to the medial or ulnar side. Most of them are referred to by more than one name. The outstanding characteristics of the carpal bones are: (1) each one, except the pisiform, has six surfaces; (2) the superior surfaces are somewhat convex, the inferior surfaces are concave; and (3) the outer surfaces are either articular surfaces or roughened surfaces to provide attachment for ligaments.

**Greater multangular (trapezium).** This carpal is on the lateral or radial aspect of the distal row of carpal bones. It has a small tubercle projecting from its anterior surface.

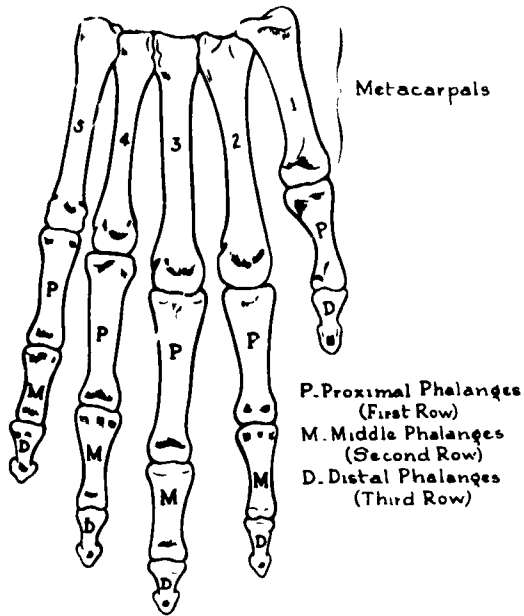


Figure 1-14 The fingers and hand

**Lesser multangular (trapezoid).** This is the smallest bone of the distal row. Its shape resembles that of a wedge.

**Capitate (os magnum).** This is the largest carpal bone. It forms the center of the wrist.

**Hamate (unciform).** This carpal is located on the medial, or ulnar, side of the distal row. It is somewhat wedge-shaped and has a hooklike process that rises from its anterior surface.

**Navicular (scaphoid).** This bone is the largest carpal in the proximal row. It is located on the lateral aspect of this row.

**Lunate (semilunar).** This carpal is located in the center of the proximal row between the navicular and triangular.

**Triangular (triquetral or cuneiform).** This bone is located on the medial, or ulnar, side of the proximal row. It is distinguished by its triangular shape.

**Pisiform.** This is the smallest carpal bone. It lies anterior to the triangular.

**Exercises (209):**

1. What are the three parts of a phalanx?
2. Which digit(s) has no middle phalanx?

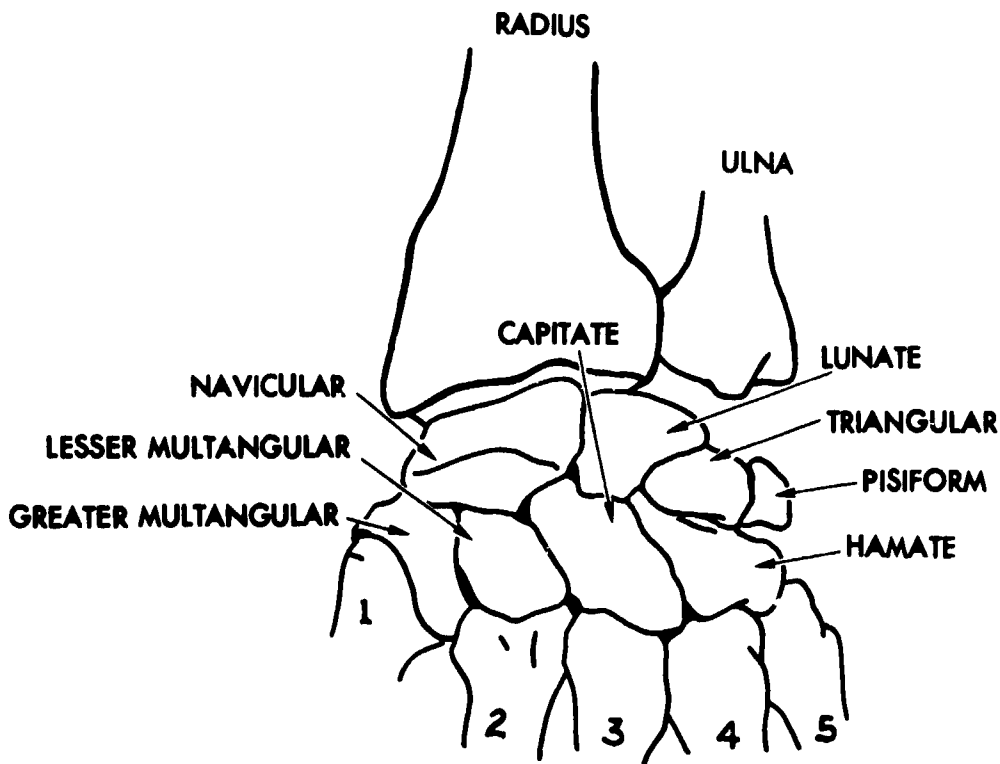


Figure 1-15. The wrist



3. How many phalanges are there in the hand?
4. What is the correct term for the center bone of the ring finger?
5. On which end of a metacarpal bone is the head? The base?
6. Which metacarpal joins the ring finger?
7. On which phalanges is the ungual tuberosity?
8. How many carpal bones are there in one hand?
9. Which bones make up the distal carpal row?
10. Which bones make up the proximal carpal row?
11. Which is the smallest carpal bone?
12. Which is the largest carpal bone?

**210. Given a list of the parts and descriptions of the two bones of the forearm, match each with the appropriate bone.**

**The Forearm.** The forearm extends from the wrist to the elbow and consists of two bones, the ulna and the radius. We will consider the ulna first. Coordinate your reading of this material by locating the forearm features in figure 1-16.

**The ulna.** The ulna, located on the medial side of the forearm, is classified as a long bone with a shaft and both distal and proximal ends. It tapers from the proximal to the distal ends, and the distal end bends laterally to form a slight bow. The distal end is much smaller than the proximal end and has two outstanding landmarks—the head and the styloid process. The shaft, somewhat rounded at its proximal end, becomes increasingly smaller toward its distal end. A rough wedge on the lateral aspect is the interosseous

border, to which the interosseous membrane is attached. On the proximal end are these prominent landmarks: the radial notch, the oblong depression on the lateral side of the coronoid process; the coronoid process, a large, pyramidal projection from the anterior surface; the semilunar notch, the arched depression extending between the olecranon and the coronoid processes; and the olecranon process, a large, curved eminence.

**The radius.** The radius, also shown in figure 1-16, is the lateral bone of the forearm and, like the ulna, is a long bone with a shaft and both distal and proximal ends. In contrast to the ulna, it tapers from the distal to the proximal end. Prominent landmarks on the distal end are the ulnar notch—a small depression on the medial side—and the styloid process—a conical projection of bone on the lateral side. The shaft becomes larger as it approaches the distal end and has a slight lateral curvature. The interosseous crest forms the sharp medial side of the shaft. The proximal end consists of the radial tuberosity—located on the medial side of the neck; the neck—the round, smooth, constricted part distal to the head; and the head—a cup-shaped, disclike structure for articulation with the capitulum of the humerus.

#### Exercises (210):

1. Match the forearm bone in column B with related information in column A. Each column B item may be used once or more than once.

Column A	Column B
_____ (1) Larger distal end.	a. Radius
_____ (2) Coronoid process.	b. Ulna
_____ (3) Radial notch	
_____ (4) Semilunar notch	
_____ (5) Radial tuberosity	
_____ (6) Olecranon process	
_____ (7) Medial bone.	

**211. Identify correct locations of the various parts of the elbow.**

**The Elbow.** The elbow is formed by the articulation of the proximal portions of the ulna and radius and the distal portion of the humerus. Since we have already discussed the proximal radius and ulna, let's look at the distal humerus.

**The distal portion of the humerus.** The flared, distal end of the humerus presents five surfaces—lateral, medial, anterior, posterior, and inferior—which in one way or another help form the elbow. The anteriorinferior surface is comprised of the articular surface. This surface is divided into two parts by a slight ridge. The medial aspect is formed by the trochlea, a deep depression between two well-marked borders. The lateral portion consists of the capitulum—a smooth, rounded eminence, marked by a slight groove on its medial aspect. Directly above and posterior to the capitulum is the radial fossa, a small, smooth depression. Medial to this fossa and directly above and behind the trochlea is the coronoid fossa. The medial aspect of the distal humerus is formed by the medial

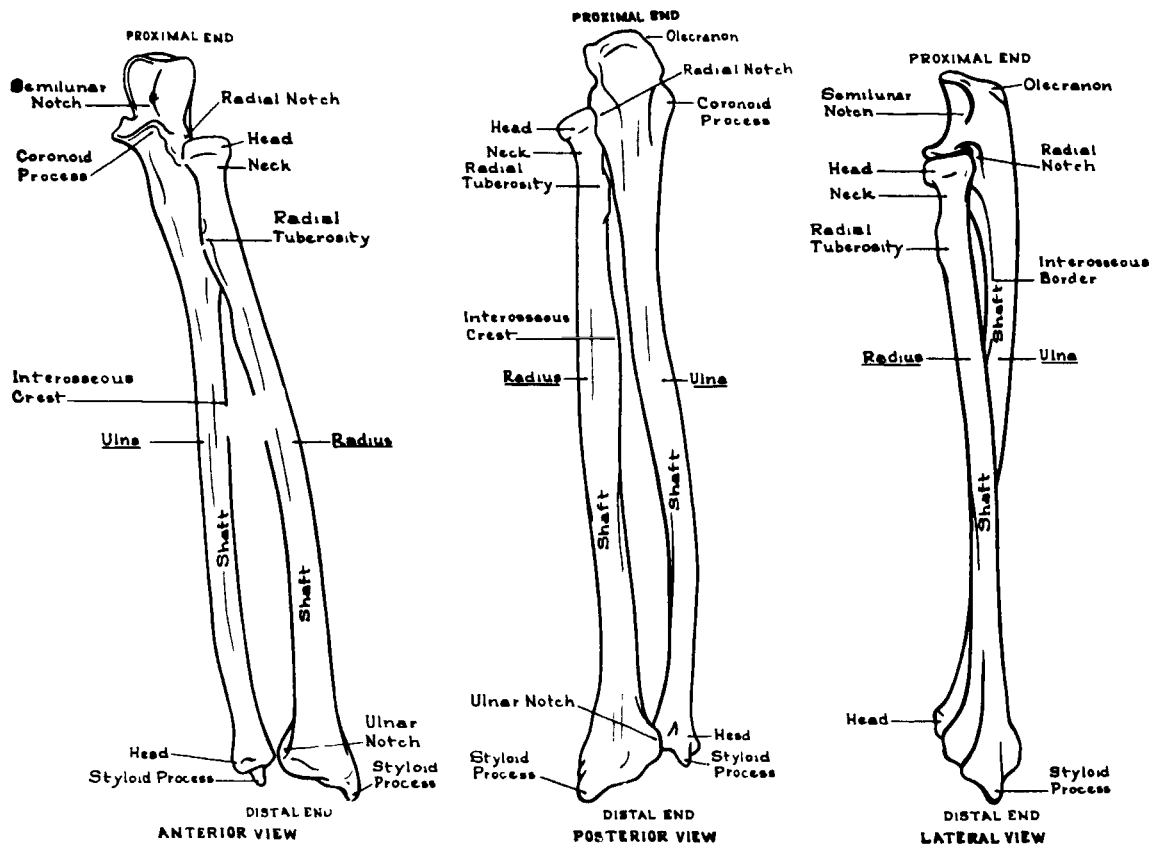


Figure 1-16 The forearm

epicondyle. This is a tubercular eminence, larger and more prominent than its lateral counterpart, to which are attached various ligaments, tendons, and muscles. The lateral epicondyle, though it serves the same purpose, is smaller. The posterior portion of the distal humerus is identified by a deep depression—the olecranon fossa—just above the posterior aspect of the trochlea. This fossa, the trochlea, the capitulum, and both coronoid and radial fossae are covered by a synovial membrane. They form the superior aspect of the articular capsule of the elbow (see fig. 1-17).

**The elbow joint.** The elbow is formed by articulation of the ulna, radius, and humerus. The head of the radius articulates with the radial notch on the lateral aspect of the coronoid process. An articulation is also formed by the capitulum and the fovea, on the superior surface of the radial head. The trochlea articulates with the semilunar notch of the ulna. In extreme hyperflexion, the medial margin of the radial head is received by the radial fossa on the anterior surface of the distal humerus and the tip of the coronoid process is received by the coronoid fossa. In extension, the olecranon process is received by the olecranon fossa. Both epicondyles give attachment to the ligaments that bind the joint together (see fig. 1-18).

**Exercises (211):**

Indicate whether the following statements are true or false. If you indicate false, explain your answer.

- (1) The olecranon fossa is located on the anterior side of the humerus.
- (2) The coronoid fossa is located on the anterior side of the humerus.
- (3) The radial fossa is located on the medial side of the humerus.
- (4) The lateral epicondyle is more prominent than the medial.

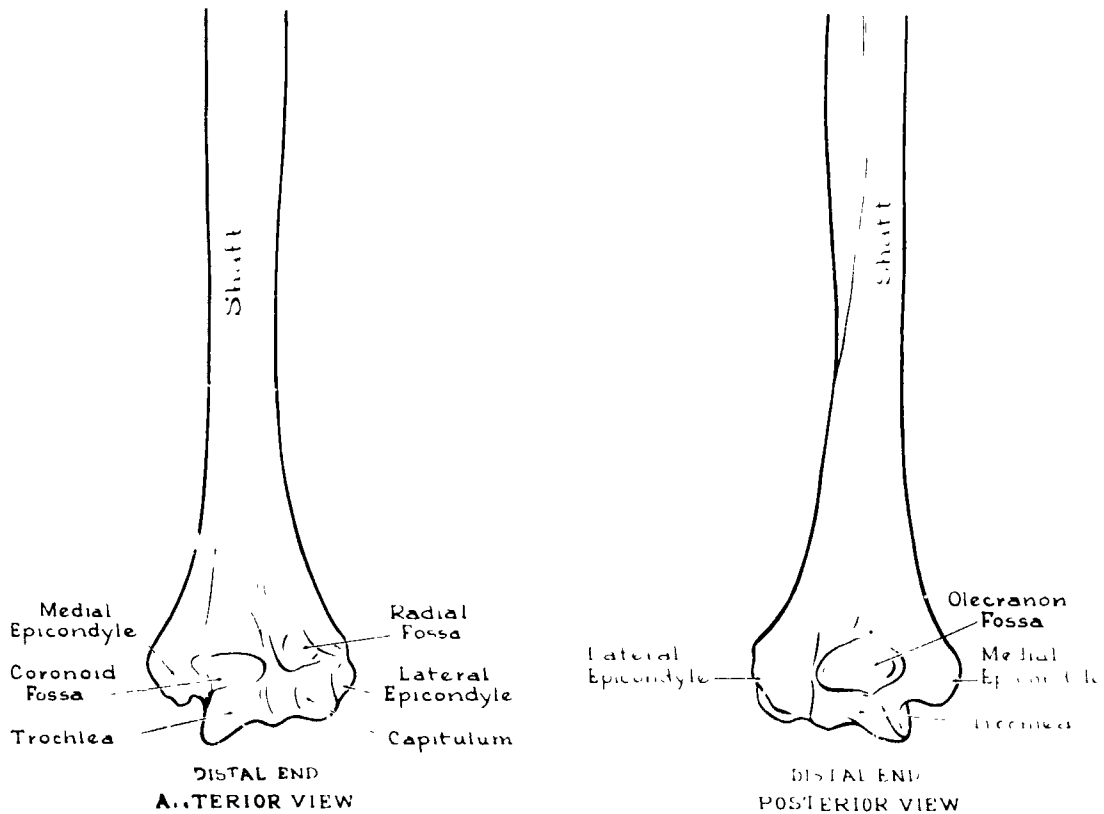


Figure 1-17 The distal end of the humerus

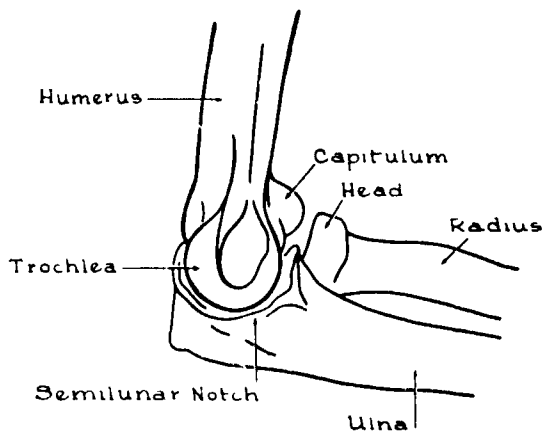


Figure 1-18. The elbow

— (5) The deep depression on the posterior surface of the humerus is the trochlea.

— (6) The radius articulates with the radial notch and the capitulum.

— (7) The ulnar semilunar notch articulates with the olecranon fossa.

— (8) The olecranon process is received by the olecranon fossa when the elbow joint is flexed.

212. Name the parts of the proximal humerus and describe each.

**The Humerus.** The humerus extends distally from the shoulder joint to the elbow joint. It is the largest bone of the upper extremity and is classified as a long bone. Since we have previously discussed the distal humerus, we will begin with the shaft (see fig. 1-19).

**Shaft.** The shaft extends from the tuberosities to the olecranon and coronoid fossae. It is round at the proximal end and becomes flattened toward the distal end.

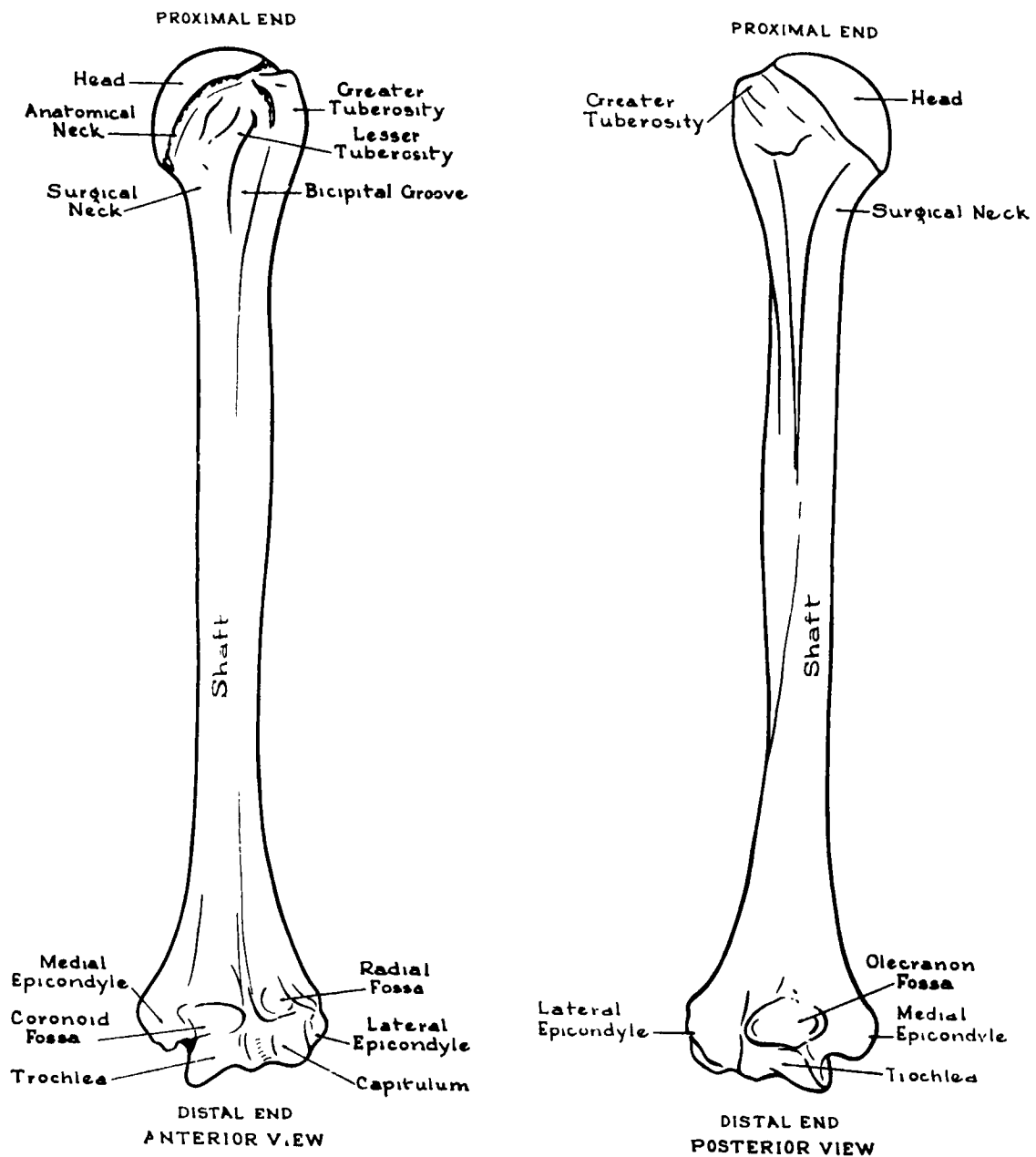


Figure 1-19. The humerus

**Proximal end.** There are several elements in the proximal end of the humerus. The surgical neck is the constricted portion of the humerus below the tuberosities; it comprises the proximal one-third of the shaft. The lesser tuberosity is a bony eminence located on the anterior surface of the proximal humerus just below the anatomical neck. The greater tuberosity is a rounded eminence on the lateral side of the proximal end just below the anatomical neck. It is an insertion place for the spinatus muscles. The bicipital groove is a deep furrow located on the anterior surface of the proximal humerus between the greater and lesser tuberosities. It runs distally in a slightly inferomedial direction, ending about one-third the length of the humerus, and is deeper at the proximal end than at the distal end. The anatomical neck is located between the greater and lesser tuberosities and the head. It connects the head with the shaft. The head is the uppermost portion of the humerus and sits obliquely on the proximal medial surface of the bone and is directed slightly backward.

### Exercises (212):

In exercises 1 through 6, name the parts of the proximal humerus and give a brief description of each part. For example: the shaft—the part of the humerus that extends from the tuberosities to the olecranon and coronoid fossae.

- 1.
- 2.
- 3.
- 4.
- 5.
- 6.

### 213. Describe the anatomy of the clavicle and scapula.

**The Shoulder Girdle.** The shoulder girdle consists of two bones—the clavicle and the scapula. We will examine the clavicle, then the scapula, and finally the joint itself.

**The clavicle.** The clavicle, commonly called the collarbone, is a long bone located on the superior anterolateral portion of the thorax and extends horizontally. As you can see in figure 1-20, important landmarks of the clavicle are:

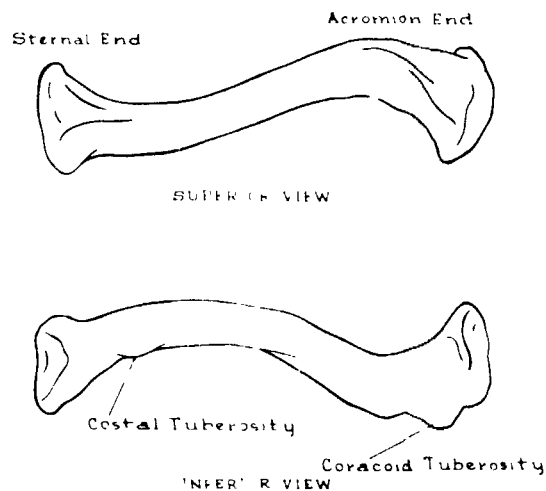


Figure 1-20. The clavicle

- *The sternal end*—medial portion.
- *The acromion end*—the lateral part.
- *The coracoid tuberosity*—a rough eminence located on the posterior border of the lateral third of the bone.
- *The costal tuberosity*—a rough area located on the medial part of the medial one-third.

**The scapula.** The scapula, or shoulder blade, is a flat, triangular-shaped bone located on the posterior superolateral part of the thorax, extending inferiorly from the level of the second rib to about the level of the eighth rib. It forms the posterior part of the shoulder girdle and is connected to the chest walls by muscles only. It has two surfaces, three borders, three angles, and the following other components that are important in radiographic studies: the subscapular fossa, the spine of the scapula, the supraspinatus fossa, the infraspinatus fossa, the acromion process, the neck of the scapula, the glenoid fossa, and the coracoid process. These parts can be seen in figure 1-21.

The anterior surface of the scapula is concave; the concavity is called the subscapular fossa. The medial two-thirds of the anterior surface contains ridges that begin at the vertebral border and extend superolaterally.

The posterior surface of the scapula is slightly arched. The spine of the scapula is a projecting plate of bone running superolaterally from the vertebral border. The area above the spine is the supraspinatus fossa; the area below is the infraspinatus fossa.

The scapula has three borders—the superior, the axillary, and the vertebral. The shortest and thinnest is the superior, which is concave and extends from the medial angle to the coracoid base. At the base of the coracoid process, where the superior border meets the base, is the scapular notch.

The three angles frequently used as anatomical landmarks are the medial angle, the lateral angle, and the inferior angle. The medial angle is formed where the superior and vertebral borders intersect. The lateral angle is located laterally on the superior part of the axillary border. The lateral angle contains the glenoid fossa.

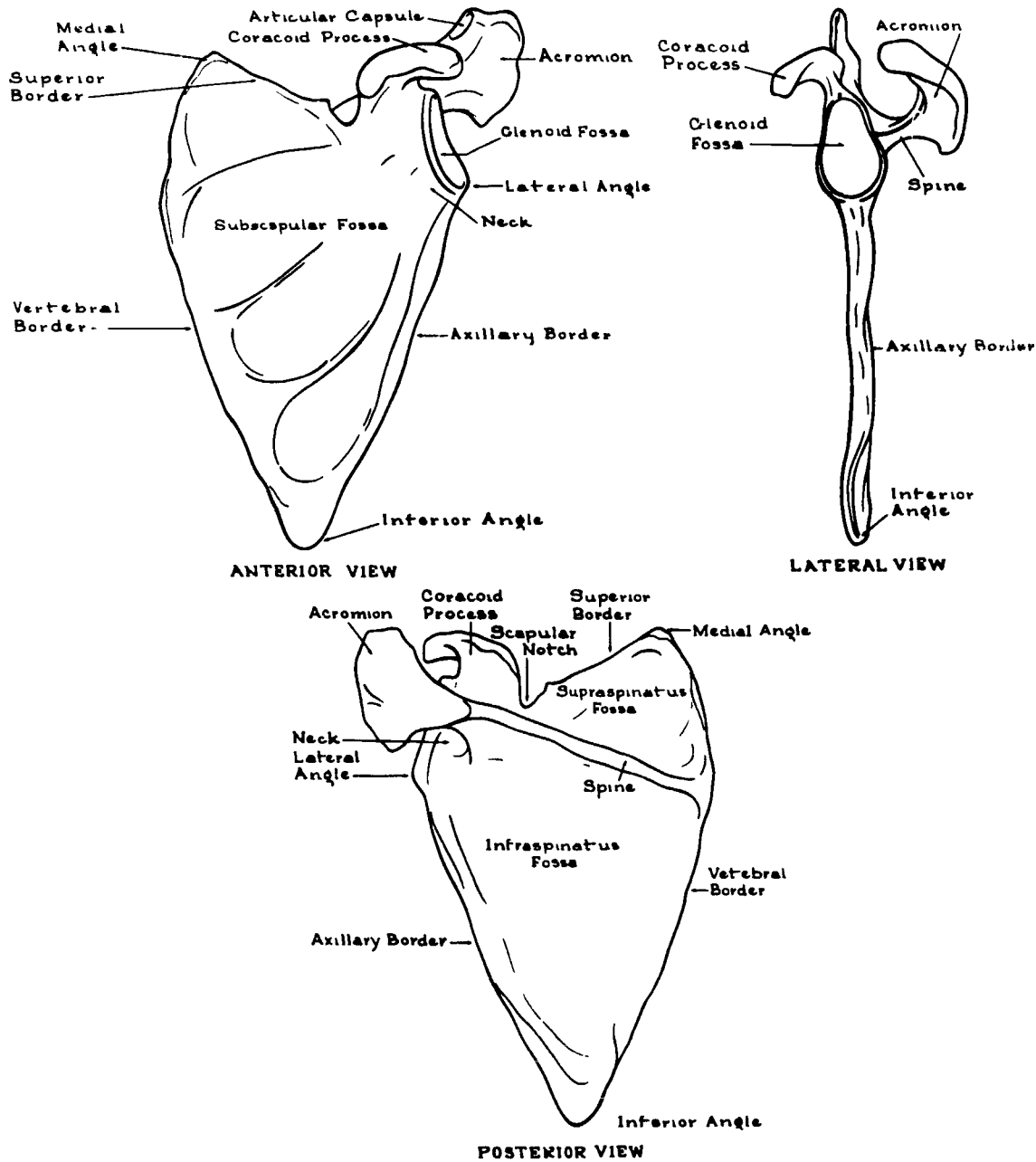


Figure 1-21. The scapula

The acromion process is a triangular projection which, at the lateral end of the scapular spine, extends slightly anteriorly and over the shoulder joint.

The glenoid fossa is the oval depression on the outer part of the scapular head at the lateral angle. It forms one-half of the shoulder joint.

The coracoid process resembles a bent forefinger and extends anterolaterally from the neck of the scapula.

**The shoulder joints.** There are two joints in the shoulder that are of particular interest to you. The glenohumeral or shoulder joint (an enarthrodial or ball and socket type of joint) and the acromioclavicular (A.C.) joint. The shoulder joint is formed by the head of the humerus and the glenoid fossa of the scapula. The A.C. joint is formed by the acromion process of the scapula and the distal end of the clavicle (see fig. 1-22).

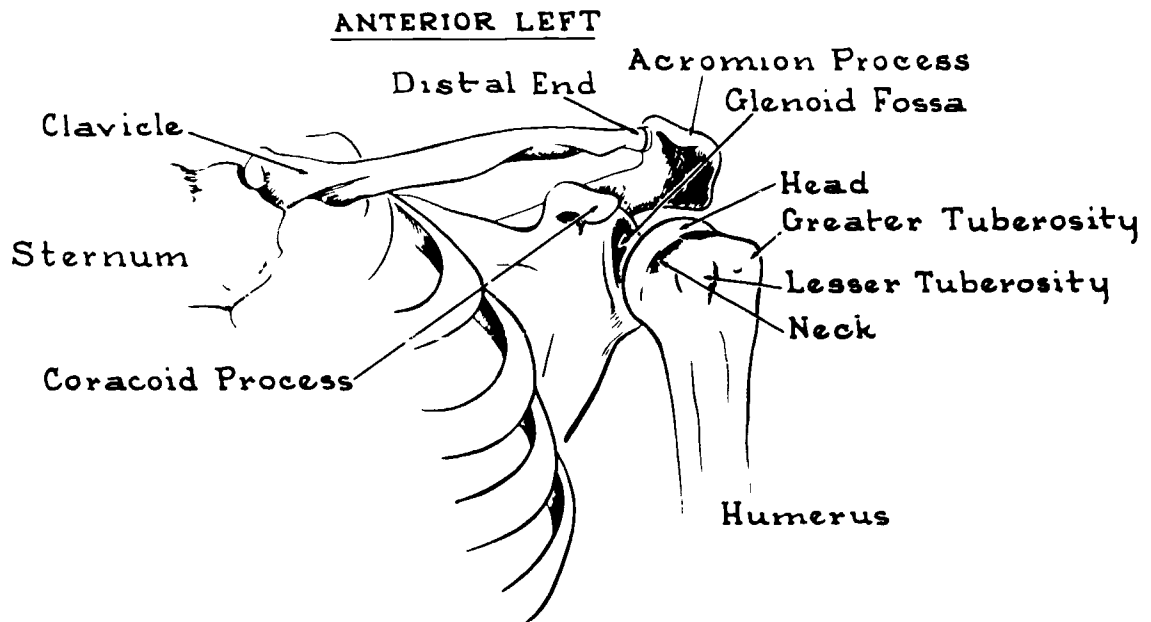


Figure 1-22 The shoulder

**Exercises (213):**

1. What is the medial portion of the clavicle? The lateral portion?
2. Give the names of the two tuberosities of the clavicle.
3. Name the concavity of .. anterior surface of the scapula.
4. What is the scapular spine, and where is it located?
5. Name the two areas directly above and below the scapular spine.
6. On which scapular border is the scapular notch?
7. Which scapular angle is formed by the junction of the vertebral and axillary borders?
8. Give the name of the large process that is located at the lateral portion of the scapular spine.
9. Name the oval depression at the lateral scapular angle.
10. What is the name of the projection that extends anterolaterally from the neck of the scapula?
11. What type of joint is the glenohumeral joint?
12. What two parts of the shoulder form the shoulder joint?
13. What two parts of the shoulder form the A.C. joint?

# Osteology of the Vertebral Column, the Ribs, and the Sternum

OUR STUDY OF osteology continues with the vertebral column, the ribs, and the sternum. As with the extremities, here we present a somewhat complete review of the basic osteology. We also discuss some material that will help you perform the quality control functions mentioned in the preface to this volume. We begin our discussion with the vertebral column.

## 2-1. The Vertebral Column

The spine is divided into five anatomic areas, each consisting of a specific number of vertebrae (see fig. 2-1). The most superior area is the cervical region, containing seven vertebrae. The thoracic spine is directly inferior to the cervical region and consists of 12 vertebrae. The third portion of the column is the lumbar region, composed of five vertebrae. Continuing down the spine, we see that the sacrum is one irregular vertebra, as is the coccyx at the lower end of the column. The sacrum and coccyx were discussed in Chapter 1.

### 214. Name and describe the anatomical parts of the lumbar spine.

**The Lumbar Spine.** Five typical vertebrae comprise the lumbar spine. They fit together to form the forward (lordotic) curve of the lower back. As you can see in figure 2-2, they are identified by number, from top to bottom. Characteristically, the lumbar are the largest of the typical vertebrae but have neither transverse foramina nor articular facets on their bodies. We will examine the parts that make up one of these vertebrae.

**The body.** This anatomic element forms the anterior part of a lumbar vertebra and is somewhat kidney shaped. In general, the body is rounded anteriorly and flattened posteriorly. The superior, inferior, and posterior surfaces are concave.

**The pedicles.** The pedicles extend posteriorly as short, bony projections on both sides of the posterior surface of the vertebral body. They connect the remaining vertebral parts with the body.

**The laminae.** These bony projections extend posteromedially from the pedicles to complete the vertebral arch by connecting the transverse processes to the spinous process. The vertebral arch, the largest part of the vertebral foramen, consists of the pedicles, the articular, spinous, and transverse processes, and the laminae.

**The articular processes.** There are four articular processes—two superior and two inferior. The superior

processes are located at the junction of the pedicles and the laminae. From here, they extend upward and face posteromedially. In turn, the inferior processes project downward from the junction and face anterolaterally to join with the superior articular process of the adjoining vertebra.

**The spinous process.** This is a single, bony projection attached to the vertebral arch. It extends posteriorly from the midpoint of the laminae junction.

**The transverse processes.** These processes arise from the pedicle-laminae junctions in L-1, L-2, and L-3, and from the pedicle-body junctions in L-4 and L-5. They are directed horizontally and slightly backward.

**The intervertebral discs.** The intervertebral discs are the shock absorbers for the vertebral column. Though they are integral parts of all sections of the spine, we discuss them now, and you can apply this knowledge to the discussions that follow. Each disc is composed of an outer layer of fibrocartilaginous material, called annulus fibrosus, and an inner area containing the pulpy substance, nucleus pulposus. The discs are extremely elastic and provide the cushioning effect needed to preclude or limit the transmission of shock from one end of the spine to the other.

**The joints.** Lumbar intervertebral joints are, for all practical purposes, of the same basic construction as those of the cervical and thoracic regions. Refer to figure 2-3 as you read.

The intervertebral joints are located between the bodies of typical vertebrae. The articular surfaces of each vertebral body join the intervertebral discs to form amphiarthrodial joints. Apophyseal or interarticular joints are formed by the inferior articular processes of one vertebra in articulation with the superior articular processes of the vertebra directly below it. The lumbosacral (sacrovertebral) joint is the point of union between the fifth lumbar vertebra and the sacrum.

### Exercises (214):

1. How many vertebrae are in the lumbar spine?
2. Name the large anterior portion of a lumbar vertebra.
3. Where are the pedicles located?



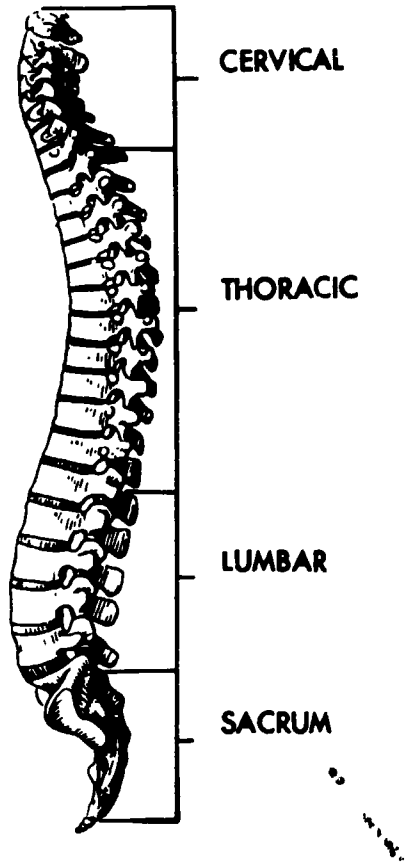


Figure 2-1 The spine

4. What part of the lumbar vertebra is located between the spinous and transverse processes?
5. Specifically, what do the inferior articular processes of the fourth lumbar vertebra articulate with?
6. What is the name of the most posterior projection of a lumbar vertebra?
7. How many transverse processes has each lumbar vertebra?
8. What is the name of the outer layer of an intervertebral disc? The inner layer?
9. Where are the intervertebral joints of the lumbar spine?

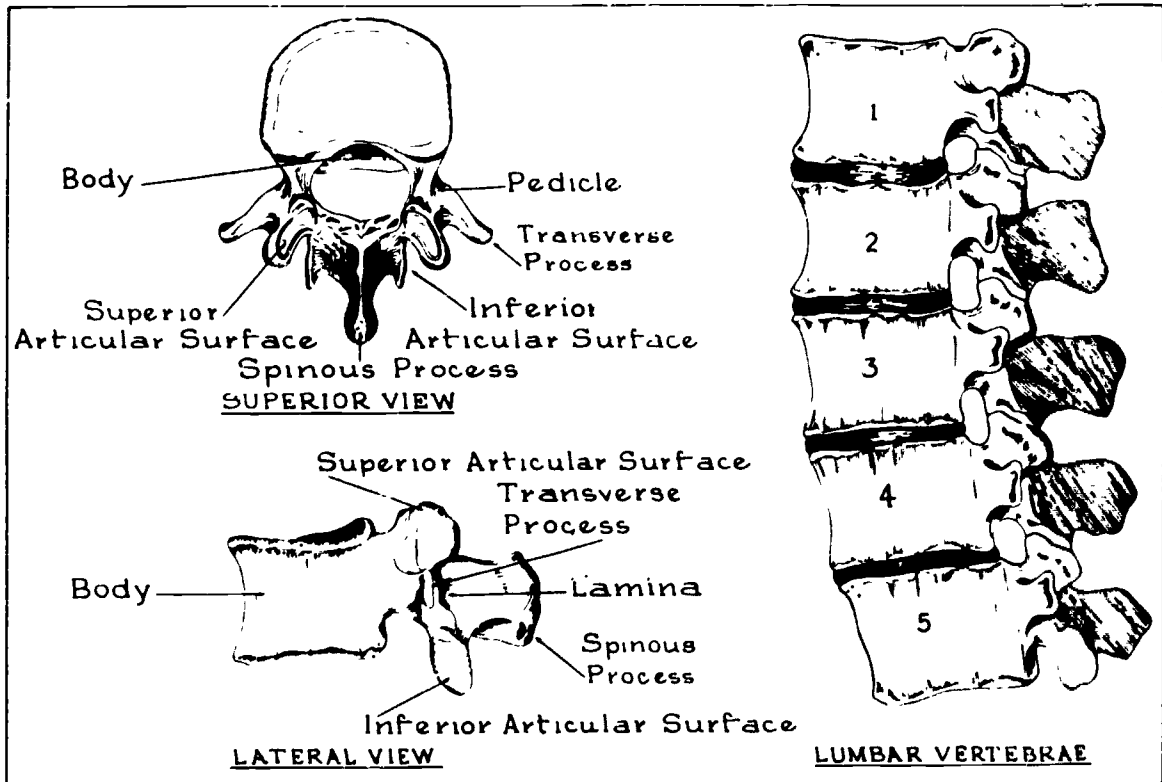


Figure 2-2. The lumbar spine.

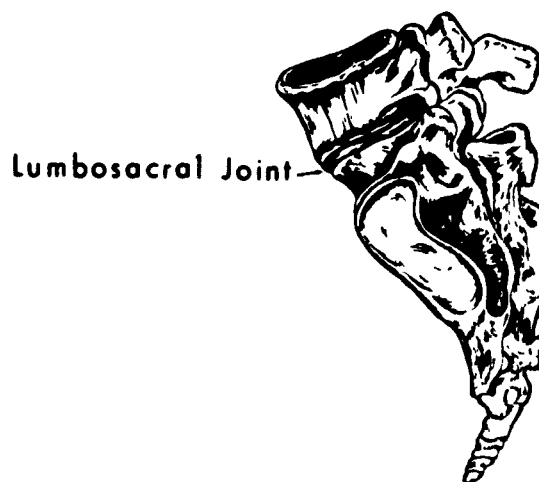
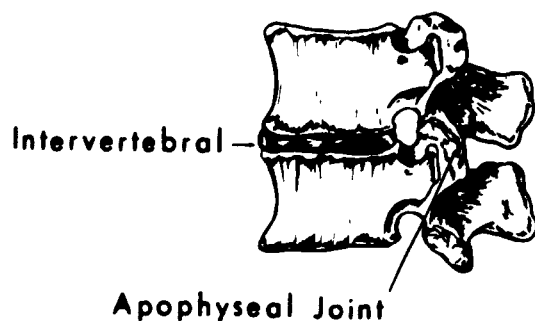


Figure 2-3 Joints of the lumbar spine

10. Name the lumbar joints that are formed by the articular processes.
11. What two parts form the lumbosacral joint?

**215. Identify characteristics of the thoracic spine.**

**The Thoracic Spine.** The thoracic vertebrae are located at the posterior portion of the bony thorax and form the posterior (kyphotic) curve. They include 12 typical vertebrae, to which 12 pairs of ribs are attached. By reference to figure 2-4, you can see they are identified by number, T-1, T-2, etc. They increase in size from T-1 to T-12. All of the thoracic vertebrae are typical in that they have the 12 characteristic parts. However, they are further distinguished by the costal articular facets located on the transverse processes of T-1 through T-10 and on the posterolateral surfaces of the bodies of all thoracic vertebrae.

**The typical thoracic vertebra.** Except for the articular facets, a typical thoracic vertebra is much like a lumbar vertebra. The lateral surface has two articular facets on each side of T-1 through T-8 and one articular facet on each side of T-9 through T-12. The posterior surface is concave and thicker than the anterior surface. The transverse processes extend posterolaterally and support the ribs. The spinous process is located posteriorly and extends backward and downward obliquely. The superior articular processes extend upward and posterolaterally. The inferior articular processes extend downward and anteromedially. The pedicles extend slightly upward and backward from each side of the posterior surface of the vertebral arch. The laminae extend posteromedially from the pedicle-transverse process junction to the spinous process. Figure 2-4

illustrates the structure of thoracic vertebrae and the lateral aspect of the thoracic spine.

**Joints of thoracic vertebrae.** The intervertebral and apophyseal joints are of the same type and formed by the same parts as the joints in the lumbar vertebrae. The costovertebral joints are between the vertebral bodies and the heads of the ribs. They are formed when the heads of the ribs articulate with the articular facets, or demifacets, of the vertebrae. The costovertebral joints, between the transverse processes of the vertebrae and the tubercles of the ribs, are formed when the articular facets of the transverse processes join the tubercles of the ribs. This articulation is not present on the last two vertebrae (see fig. 2-5).

**Exercises (215):**

Indicate whether the following statements are true or false. If you indicate false, explain your answer.

- \_\_\_ 1. There are 12 thoracic vertebrae.
- \_\_\_ 2. Costal articular facets are located on the transverse processes of all thoracic vertebrae.
- \_\_\_ 3. All of the thoracic vertebrae bodies have at least one articular facet.
- \_\_\_ 4. A thoracic vertebra is considerably different from a lumbar vertebra.

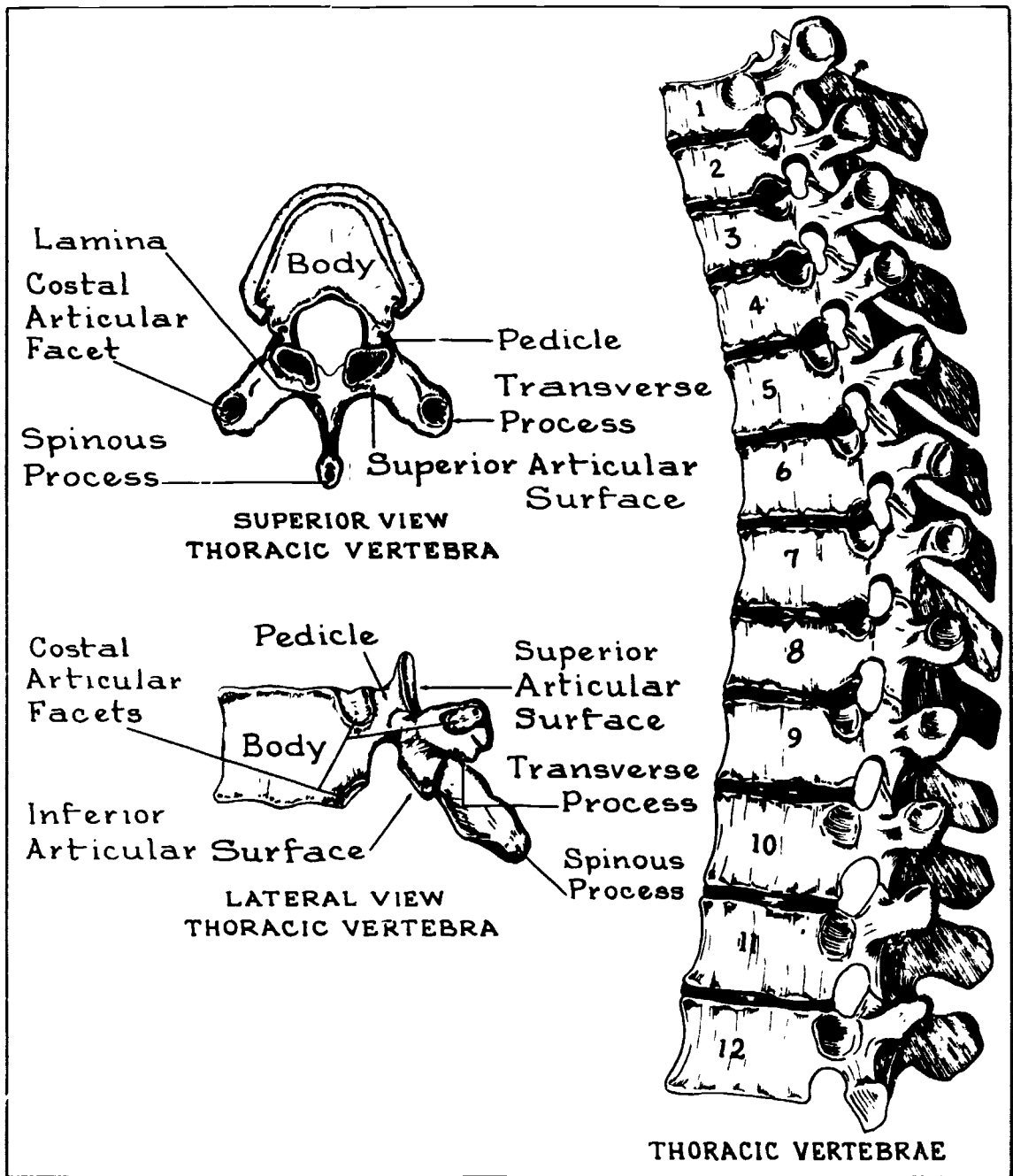


Figure 2-4. The thoracic spine.

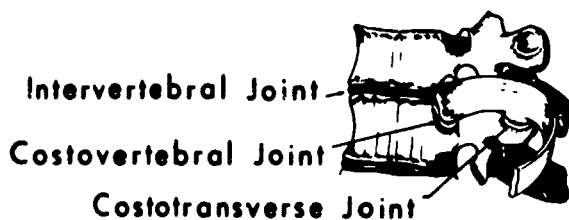


Figure 2-5 Joints of the thoracic spine

- \_\_\_ 5. The heads of the ribs join the thoracic vertebra at the costovertebral joints.
- \_\_\_ 6. Costotransverse joints are present on the first 10 thoracic vertebrae.
- \_\_\_ 7. Thoracic vertebrae have no apophyseal joints.

**216. Describe the anatomy of the cervical spine by selecting the name, location, or characteristics of the various parts.**

**The Cervical Spine.** Seven cervical vertebrae make up the cervical spine. Because of some peculiarities in the construction of certain of these vertebrae, we briefly discuss their differences. Follow the discussion by noting the described characteristics in figure 2-6.

**First cervical vertebra.** The first vertebra is described as being atypical, because it has no body or spinous process but has a larger vertebral foramen than does a typical vertebra. This vertebra is called the atlas, because it supports the head of the mythological Atlas supported the Earth. It is round and has an anterior arch, a posterior arch, a posterior tubercle, two lateral masses, two superior articular facets, two inferior articular facets, and two transverse processes.

**Second cervical vertebra.** The second cervical vertebra is also atypical, because it has the odontoid process (a rounded, perpendicular piece of bone that arises from its body). The name for this vertebra is "axis," because it serves as the pivot point for the atlas. Its spinous process is bifid.

**Cervical vertebrae 3 through 7.** The remainder of the vertebrae are similar to each other in construction. However, their bodies are smaller than the bodies of thoracic or lumbar vertebrae. Since each of them has 12 pairs, each is considered a typical vertebra, though all have characteristics peculiar to cervical vertebrae. Each one (including the atlas and axis) has a foramen in each transverse process, through which veins, arteries, and nerves pass. Such transverse processes are found only in the

cervical vertebrae. Another peculiar characteristic is the bifid (divided into two parts) spinous process of vertebrae 3 through 6. The seventh cervical vertebra is particularly distinctive in that its spinous process is long, not bifurcated, and extends farther outward than the spinous process of the other cervical vertebrae.

**Joints of cervical vertebrae.** The joints of cervical vertebrae are the atlanto-occipital joints (atlas and occipital bone), the atlanto-axis joint (atlas and axis), the intervertebral joints, and the interarticular joints. The atlanto-occipital joint is formed by the superior articular surfaces of the atlas in articulation with the condyles of the occipital bone of the skull. The atlanto-axial articulation is formed by the atlas and axis. The intervertebral and apophyseal joints are similar to those of other vertebrae (see fig. 2-7).

**Exercises (216):**

Select the correct word(s) from the list to complete the following. Some words may be used more than once.

- Bifid.
- Seventh.
- All.
- Atlas.
- Axis.
- Two.
- Atlanto-axial.
- Occipital; atlanto-occipita.

1. \_\_\_\_\_ is the first cervical vertebra.
2. The \_\_\_\_\_ is the second cervical vertebra.
3. \_\_\_\_\_ cervical vertebrae has transverse foramina.
4. The \_\_\_\_\_ has no spinous process.
5. The odontoid process is part of the \_\_\_\_\_.
6. The \_\_\_\_\_ cervical vertebra has the longest spinous process.
7. Cervical spinous processes are \_\_\_\_\_.
8. The atlas articulates with the \_\_\_\_\_ bone to form the \_\_\_\_\_ joints.
9. The atlas articulates with the axis to form the \_\_\_\_\_ joint.
10. \_\_\_\_\_ cervical vertebrae are considered atypical.

**2-2. The Ribs and the Sternum**

The area described as the ribs and the sternum includes the several parts of the sternum and the many types of joints involved.

**217. List the three groups of ribs, give the number of ribs in each group, and explain each classification.**

**The Ribs.** The ribs are curved, flat bones that form most of the posterior and anterior structure and all of the lateral structure of the bony thorax. Usually, there are 12 ribs on

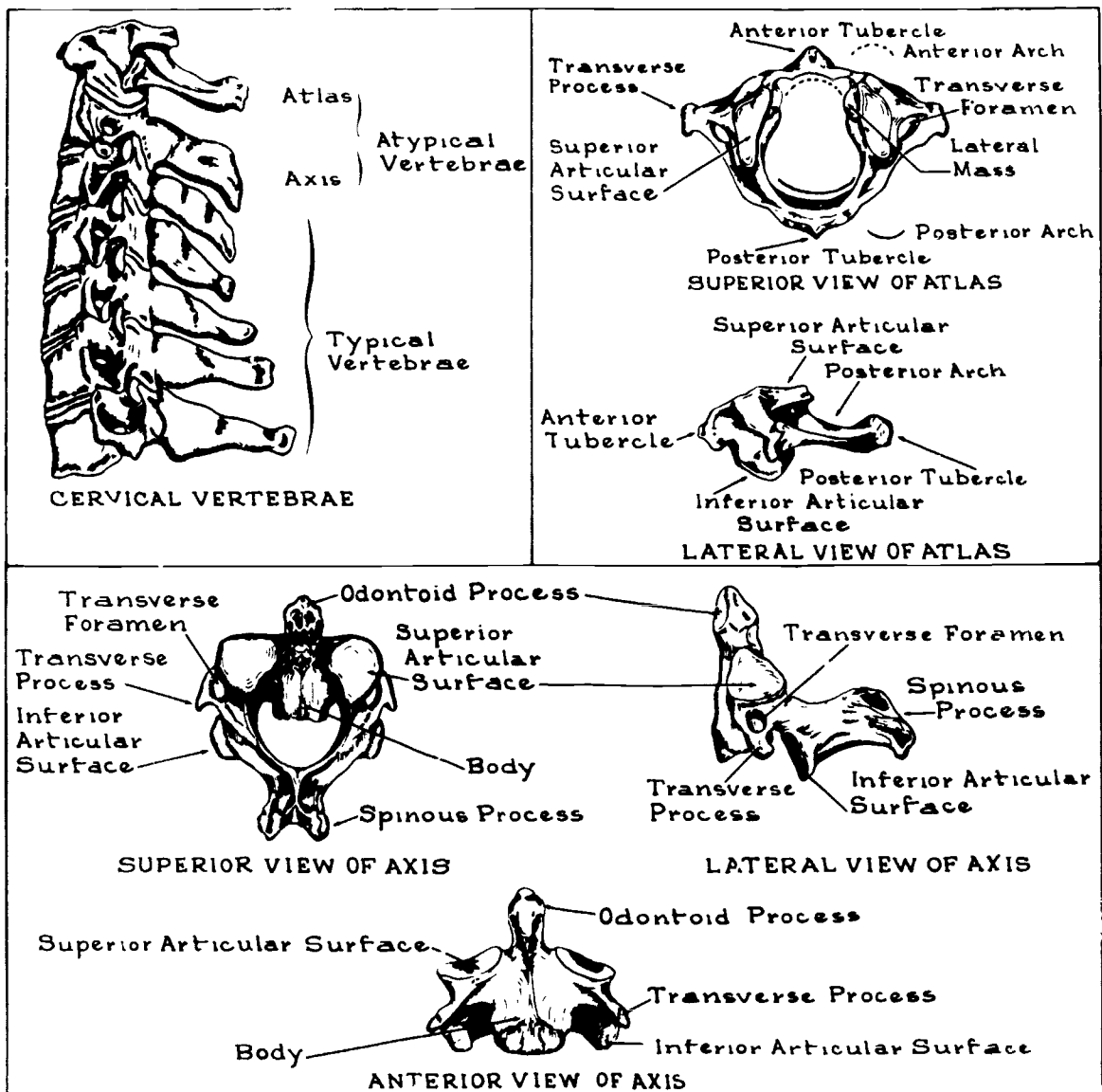


Figure 2-6. The cervical spine

each side of the median plane of the thorax, extending from the 1st through the 12th thoracic vertebra. As you can see in figure 2-8, ribs are identified by number and by the side of the body in which they are located. The first seven pairs are considered true ribs. They are attached to cartilage, which joins directly to the sternum. The remaining five pairs are considered false ribs. The costal cartilage does not articulate directly with the sternum. Ribs 8, 9, and 10 articulate anteriorly with the costal cartilage of the ribs directly above them. Because they do not articulate anteriorly, ribs 11 and 12 are frequently called floating ribs.

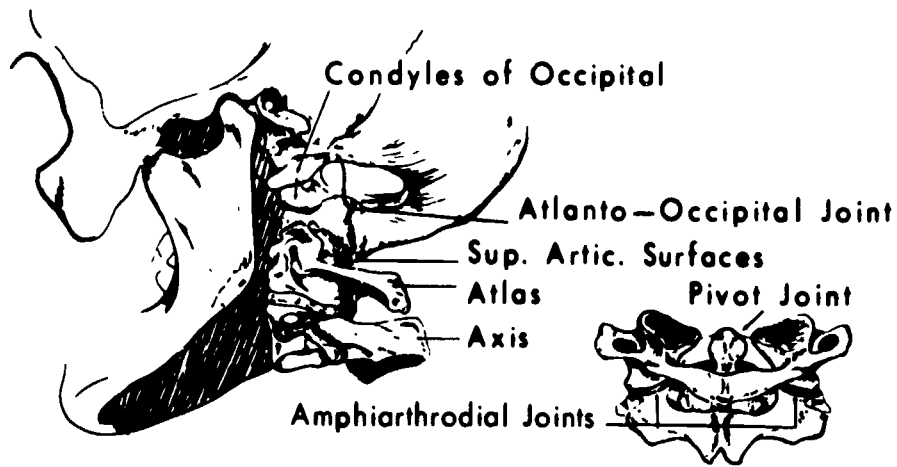
**Exercises (217):**

In exercises 1 through 3 below, list the three groups of ribs, give the number of ribs in each group, and explain why they are classified as such.

- 1.
- 2.
- 3.

**218. Describe the anatomical parts of the sternum.**

**The Sternum.** The sternum, commonly called the breastbone, is long and flat and is located almost vertically



**JOINTS OF CERVICAL VERTEBRAE**



Figure 2-7 Joints of the cervical spine

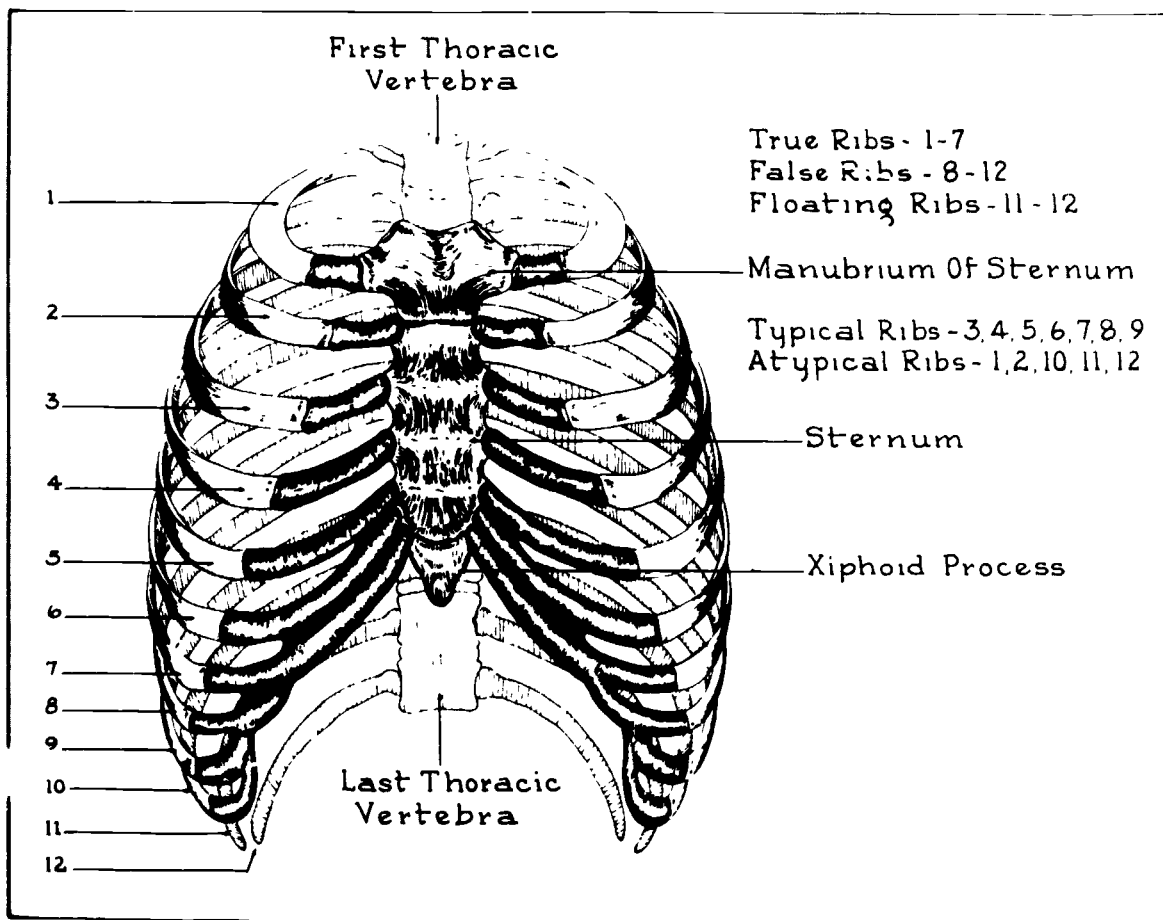


Figure 2-8. The ribs

at the midanterior part of the thoracic cage. The major parts and landmarks of the sternum are the manubrium, the body, the sternal angle, and the xiphoid process. The parts of the sternum are illustrated in figure 2-9.

**Manubrium.** The manubrium of the sternum is about 2 inches long and is the uppermost part of the sternum. It is thick and broad superiorly, and becomes narrow as it descends toward the body of the sternum. The superior surface contains the suprasternal notch, often called the manubrial notch. On both sides of this notch are the clavicular notches, where the clavicles articulate with manubrium. The manubrial notch can be used to locate "T-1, T-2."

**The body, or gladiolus.** The body of the sternum, also called the corpus, is about 4 inches long. The superior part of the body articulates with the inferior part of the manubrium. On each lateral border of the body are articular facets for ribs 2 through 7.

**Sternal angle.** The sternal angle, also called the angle of Louis, is formed by the articulation of the inferior border of the manubrium with the superior border of the sternal body.

**Xiphoid process.** The xiphoid, or ensiform, process forms the distal portion of the sternum. It is the smallest and thinnest of the three major sternal components and remains cartilaginous until advanced adulthood. Its posterior surface continues with the posterior surface of the sternal body, and each of its superolateral borders has a demifacet. As a palpation point it can be used to locate T-10, T-11.

#### Exercises (218):

1. What is the name of the upper portion of the sternum?

2. What are the names of the three notches of the upper portion of the sternum?
3. Name the angle formed by the sternal body and manubrium.
4. In what part of the sternum is the xiphoid process?

**219. Given a list of the joints of the ribs and the sternum, match each with an appropriate descriptive statement.**

**Joints of the Ribs and the Sternum.** We have already discussed the costovertebral and costotransverse joints, so let's examine the other joints of the ribs and sternum. Refer to figure 2-10 to see these joints.

**Costosternal joints.** Only the true ribs are involved in the costosternal joints, which are formed by the articulation of the costal cartilage of the ribs with the sternum. Only the first costosternal joint is synarthrodial; all of the others are diarthrodial joints.

**Interchondral joints.** The costal cartilage of ribs 6, 7, 8, 9, and 10 articulate with each other to form the interchondral joints.

**Costochondral joints.** These joints are formed by the costal cartilage in articulation with the sternal ends of the ribs.

**Sternoclavicular joints.** The sternoclavicular joints are formed by the sternal ends of the clavicles in articulation with the clavicular notches of the manubrium.

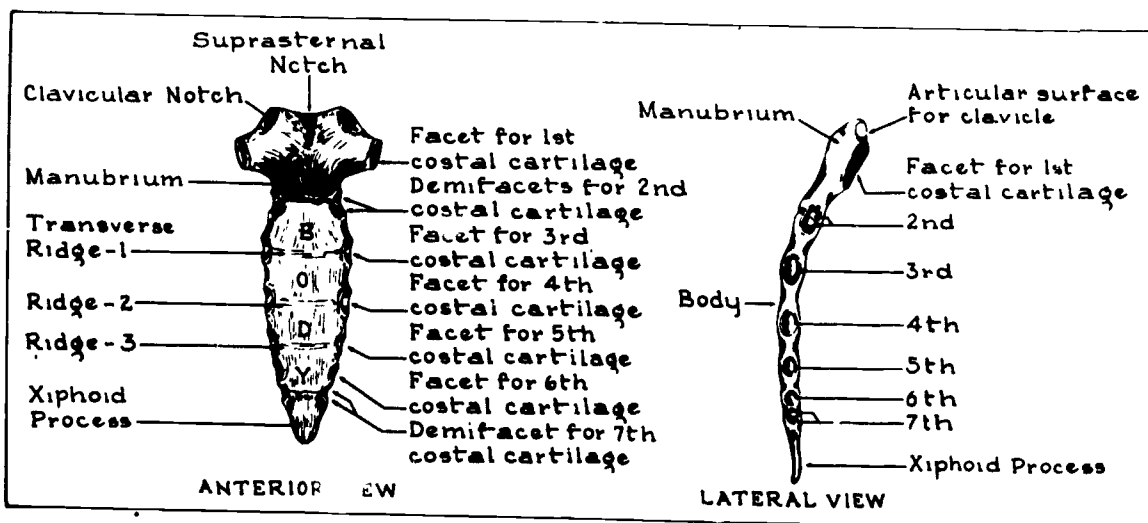


Figure 2-9. The sternum

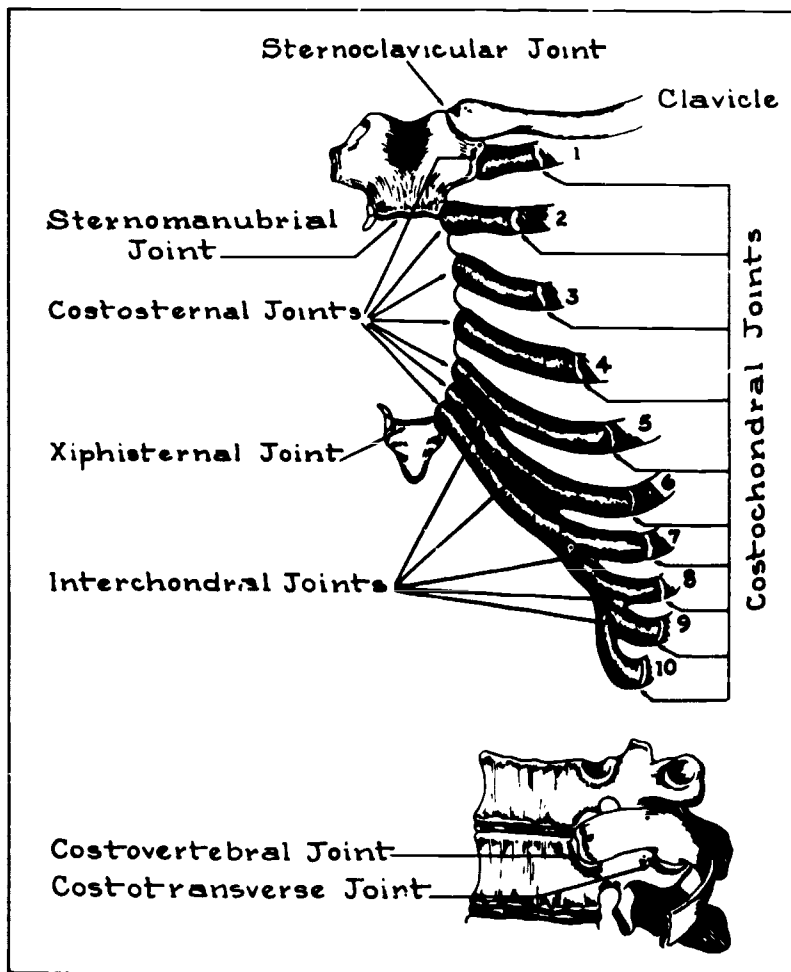


Figure 2-10 The costal joints

**Sternomanubrial joint.** The sternomanubrial joint is formed by the inferior surface of the manubrium in articulation with the superior surface of the sternal body to form an amphiarthrodial joint. Although the manubrium remains stationary, the sternal body is able to move anteriorly and posteriorly. This movement is important in the mechanics of respiration.

**Xiphisternal joint.** The xiphisternal joint is formed by the superior surface of the xiphoid process in articulation with the inferior surface of the sternal body.

**Exercises (219):**

1. Match the joints in column B with the appropriate statement in column A. Each column B item may be used once or not at all.

*Column A*

- (1) Anterior ends of ribs articulate with costal cartilage.
- (2) Sternal body and xiphoid process join
- (3) Manubrium joins with sternal body.
- (4) Costal cartilage of ribs in articulation with each other.
- (5) Costal cartilage of true ribs joins with sternum.
- (6) Clavical articulates with manubrium.

*Column B*

- a. Costosternal joints
- b. Interchondral joints
- c. Costotransverse joints.
- d. Costochondral joints.
- e. Sternomanubrial joint.
- f. Xiphisternal joint.
- g. Sternoclavicular joint.
- h. Costovertebral joint



## Osteology of the Skull, the Facial Bones, and the Paranasal Sinuses

PERHAPS NO other bony body parts are as difficult to demonstrate radiographically as are certain parts of the skull. The main reason for the difficulty is the many overlying structures. Many examinations require precise angulations of the skull, film, and CR. Evaluating the quality of skull radiographs is also difficult because of overlying structures. Without a good working knowledge of osteology, it is difficult both to position the skull properly and to evaluate the quality of the radiographs.

Our study of osteology continues in this chapter with the cranium, facial bones, and paranasal sinuses.

### 3-1. The Cranium

In our discussion of the cranium, we examine the cranial bones and the cranial sutures, junctions, and fontanelles.

#### 220. Name, locate, and describe the eight bones of the cranium.

The cranium has eight bones—one frontal, two parietal, two temporal, one occipital, one sphenoid, and one ethmoid. Use foldout 1 in the back of this volume as a reference while you study.

**Frontal Bone.** The frontal bone is the forehead, the anterior roof of the cranium, the superior part of the orbits, a part of the nose, and the anterior floor of the cranial fossa. In itself, it has two major parts—the squamosal and the orbital. The squamosal part of the frontal bone makes up the forehead. Its outstanding parts are the frontal eminences, the supraorbital foramina, the zygomatic processes, the nasal process, the frontal sinuses (discussed later in this chapter), and the sagittal sulcus. The frontal eminences are large, rounded, bony elevations located on each side of the anterior midline above the supraorbital ridges. The supraorbital ridges are the prominent bony ridges that form the upper anterior boundaries of the orbits and also mark the junction of the squamosal and orbital portions of the frontal bone. They can be easily felt under the eyebrows. The supraorbital foramina are the small holes that provide passage for the supraorbital nerve and the blood vessels. The zygomatic processes are prominent bony processes on the lateral parts of the supraorbital ridges, connecting the frontal and zygomatic bones. The nasal process is the piece of bone projecting downward and forward and extending from the nasion. It supports the bridge of the nose. The sagittal sulcus, a vertical groove on the internal surface of the frontal bone, is formed by the fusion site of the original two parts of the frontal bone. The orbital portions of the

frontal bone, which make up the superior parts of the orbits, are thin, triangular plates.

**Parietal Bones.** The two parietal bones make up most of the lateral walls and the roof of the cranium. In front they unite with the frontal bone, and on top, they unit with each other. The anterior, superior, and posterior borders are serrated for articulation with the frontal, parietal, and occipital bones. Inferiorly, they articulate with the temporal and sphenoid bones.

**Temporal Bones.** The two temporal bones form part of the inferolateral walls of the cranium, bilaterally. The parts of these bones that deserve special consideration are the mastoid processes, the petrous ridges, the styloid processes, the tympanic portions, the mandibular fossae, and the zygomatic processes.

**Mastoid processes.** These large, bony prominences are located on the inferoposterior part of each temporal bone, directly behind each external auditory meatus (EAM). They contain air cells of different sizes and shapes called mastoid cells.

**Petrous ridges.** These are the pyramidal wedges of bone that form the part of the cranial base between the sphenoid and occipital bones. They also house the inner ear.

**Styloid processes.** The styloid processes are long, slender projections extending forward and downward from the inferior part of the temporal bones.

**Tympanic portions.** Lying anterior to the mastoid processes and directly above the styloid processes, their anterior-inferior portions make up the superior part of the mandibular fossae.

**Mandibular fossae.** These depressions are located in the anterior-inferior portion of the tympanic parts of the temporal bones. They are also part of the temporomandibular joints, since they provide articulation for the condyloid processes of the mandible.

**Zygomatic processes.** These processes are slender bony projections extending anteriorly from the inferior aspects of the temporosquamosal areas just above each external auditory meatus (EAM). Their anterior ends are serrated for articulation with the temporal processes of the zygomatic bones, forming the zygomatic arches.

**Occipital Bone.** The occipital bone, which makes up part of the roof and the posteroinferior portion of the cranium, has these outstanding parts: the foramen magnum, the external and internal occipital protuberances, and the occipital condyles.

**Foramen magnum.** This foramen is a large opening in the base of the occipital bone, through which the lower parts of the medulla oblongata and spinal cord pass to the spinal column.

**External occipital protuberance.** The external occipital protuberance (EOP) is a bony prominence located in the middle of the area where the occipital bone curves inward to form the posterior portion of the cranial base. This prominence may be easily felt.

**Internal occipital protuberance.** The internal occipital protuberance is located on the internal surface of the occipital bone in the same area as the external protuberance, and marks the junction of the four divisions of the occipital bone.

**Occipital condyles.** These condyles, lying on each side of the foramen magnum on the external surface, are oval-shaped, smooth, bony prominences that articulate with the superior articular surfaces of the atlas. The skull joins the vertebral column at this point.

**Sphenoid Bone.** The sphenoid bone is located at the base of the cranium, where it makes up the middle portion of the cranial floor. Its major parts are the body, the optic foramina, the sella turcica, the anterior and posterior clinoid processes, the great wings, and the lesser wings.

**Body.** The body of the sphenoid bone is the middle part, hollowed out to form two sphenoid sinuses that lie directly behind the nose.

**Optic foramina.** These two foramina, one on each side, are located at the anterolateral part of the body of the sphenoid bone. Through these holes, the optic nerves and vessels leave the cranial vault and enter the orbits.

**Sella turcica.** This "Turkish saddle," located on the superior surface of the body of the sphenoid bone, is a saddle-shaped depression on which the pituitary gland is situated.

**Clinoid processes.** These bony projections arise from the lesser wings and dorsum sella respectively. They bend backward and forward over the sella turcica to form a partial protective roof over the pituitary gland.

**Great wings.** These wings extend laterally from the sides of the body. They form part of the floor of the cranium, a small part of its lateral walls just anterior to the temporal bones, and the posterior part of the lateral walls of the orbits.

**Lesser wings.** These wings lie anterior to the sella turcica, and are thin, triangular pieces of bone that extend laterally from the body. Part of the posterior roof of the orbits is formed by their inferior surface.

**Ethmoid Bone.** The ethmoid bone, the smallest of the cranial bones, is located behind the bridge of the nose and forms part of the anterior base of the cranium and the orbits. Its major parts are the cribriform plate, the crista galli, the perpendicular plate, and the labyrinths.

**Cribriform plate.** The plate has a vast number of foramina (cribriform foramina) through which the olfactory nerves (nerves of smell) pass to enter the nasal cavity. Articulating with the ethmoid notch of the frontal bone, this plate forms the roof of the nasal cavity.

**Crista galli.** This bony projection, shaped like a shark's fin, extends upward from the cribriform plate. It is the attachment for the anterior brain.

**Perpendicular plate.** This thin, bony projection extends downward from the inferior surface of the cribriform plate and forms part of the nasal septum.

**Labyrinths.** The two ethmoidal labyrinths are also called lateral masses. Each labyrinth contains the nasal conchae or turbinate bones. These project into the nasal cavity and allow for circulation and filtration of inhaled air before it passes to the lungs.

#### Exercises (220):

1. What bones make up the cranial roof?
2. Which bone forms the superior portion of the orbits?
3. Name the foramen that is located on the anterior portion of the frontal bone, just above the orbits.
4. Which portion of the frontal bone makes up the forehead?
5. Describe the sagittal sulcus of the frontal bone.
6. What bone(s) join posteriorly with the occipital and anteriorly with the frontal?
7. The mastoid process is part of what bone?
8. Name the pyramidal wedges of the bone that are part of the temporal bones.
9. What part of the temporal bone helps form the temporomandibular joint?
10. On which bone is the tympanic portion?
11. Name the large foramen in the occipital bone.

12. With what part(s) of the occipital bone does the first cervical vertebra articulate?
13. What palpable bony prominence is located on the occipital bone?
14. What bone makes up the midportion of the floor of the cranium?
15. Through what foramina do the optic nerves and vessels enter the orbits?
16. Where is the pituitary gland?
17. What processes located on the sphenoid bone partially protect the pituitary gland?
18. The great and lesser wings are part of what bone?
19. Which is the smallest cranial bone?
20. What portion of the ethmoid bone forms the roof of the nasal cavity?
21. Give the specific location of the crista galli.
22. What is the thin projection extending inferiorly from the bottom of the cribriform plate?
23. Which portion of the ethmoid bone circulates and filters inhaled air?

**221. Given a list of the cranial sutures, match each with the bones that unite to form them.**

**The Cranial Sutures.** The cranial sutures are as listed below (refer to fig. 3-1)

- (1) Coronal suture—the frontal bone in articulation with the parietal bones.
- (2) Sagittal suture—the two parietal bones in articulation with each other (not shown).
- (3) Lambdoidal suture—the occipital bone in articulation with the parietal bones.
- (4) Squamosal suture—the temporal bone in articulation with the parietal bone.
- (5) Sphenosquamosal suture—the sphenoid bone in articulation with the temporal bone.
- (6) Sphenofrontal suture—the sphenoid bone in articulation with the frontal bone.
- (7) Sphenoparietal suture—the sphenoid bone in articulation with the parietal bone.
- (8) Occipitomastoid suture—the occipital bone in articulation with the mastoid process of the temporal bone.
- (9) Parietomastoid suture—the parietal bone in articulation with the mastoid process of the temporal bone (not shown).

**Exercises (221):**

1. Match the cranial suture in column B with the bones in column A that unite to form it. Each column B item may be used once or not at all.

<i>Column A</i>	<i>Column B</i>
_____ (1) Occipital-parietals	a Sphenoparietal
_____ (2) Parietals	b Parietomastoid
_____ (3) Occipital-mastoid process	c Lambdoidal
_____ (4) Frontal-parietal	d Sagittal
_____ (5) Sphenoid-temporal	e Sphenosquamosal
_____ (6) Parietal-sphenoid	f Squamosal
	g Sphenofrontal
	h Coronal
	i Occipitomastoid

**222. Given a list of the cranial junctions, match each with (1) the sutures that unite to form them, and (2) the corresponding cranial fontanelles.**

**Cranial Junctions.** The cranial junctions are as listed below (refer to fig. 3-2).

- (1) The bregma—the anterior junction of the coronal and sagittal sutures.
- (2) The lambda—the posterior junction of the sagittal and lambdoidal sutures.
- (3) The asterion—the posterolateral junction of the lambdoidal, squamosal, occipitomastoid, and parietomastoid sutures.
- (4) The pterion—the anterolateral junction of the squamosal, sphenosquamosal, sphenofrontal, and sphenoparietal sutures.

**Cranial Fontanelles.** The cranial fontanelles are membranous areas in the cranium at several junctions of the

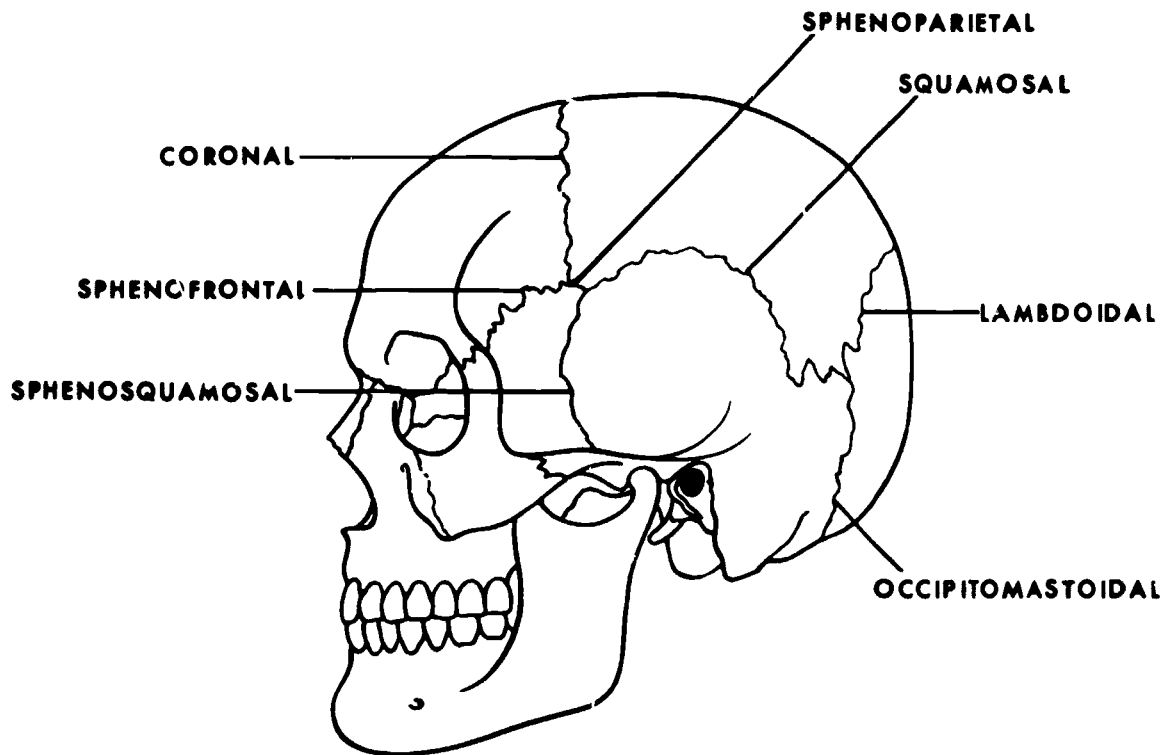


Figure 3-1 Cranial sutures

cranial bones. Usually, they are found only in infants and represent the future sites of the cranial junctions. The ossification of the fontanelles usually is complete at 2 years of age. There are six fontanelles—one anterior, one posterior, two anterolateral, and two posterolateral.

**The anterior fontanelle.** Often called the frontal fontanelle, the anterior fontanelle is located where the two parietal bones join the frontal bone. Usually, it is the future site of the bregma and is the last fontanelle to ossify.

**The posterior fontanelle.** Often called the occipital fontanelle, the posterior fontanelle is located where the two parietal bones join the occipital bone. It is the future site of the lambda.

**The anterolateral fontanelles.** Often called the sphenoidal fontanelles, the anterolateral fontanelles are located bilaterally at the junction of the parietal bones with the sphenoid and frontal bones. They are the future sites of the pterion.

**The posterolateral fontanelles.** Often called the mastoid fontanelles, the posterolateral fontanelles are located bilaterally at the junction of the parietal bone with the mastoid process of the temporal bone and the occipital bone. They are the future site of the asterion.

#### Exercises (222):

- Match the cranial junctions in column B (1) with the sutures in column A that form them and (2) with the corresponding cranial fontanelles in column A. Each column B item may be used only once in each part.

<i>Column A</i> <i>Sutures</i>	<i>Column B</i>
— (1) Squamosal, sphenosquamosal, sphenoparietal	a Asterion
— (2) Occipitomastoidal, squamosal, lambdoidal, parietomastoidal	b Bregma
— (3) Sagittal, lambdoidal	c Lambda
— (4) Sagittal, coronal	d Pterion
 <i>Fontanelles</i>	
— (5) Posterolateral	
— (6) Anterolateral	
— (7) Anterior	
— (8) Posterior	

### 3-2. The Facial Bones

The facial bones are the maxilla, lacrimal, zygomatic, palatine, nasal, inferior nasal conchae, vomer, and mandible.

#### 223. Identify correct characteristics of the facial bones.

The following bones make up the facial portion of the skull—two maxillae, two lacrimal bones, two zygomatic bones, two palatine bones, two nasal bones, two inferior nasal conchae, one vomer, and one mandible. The maxillae, the zygomatic bones, and the mandible form most

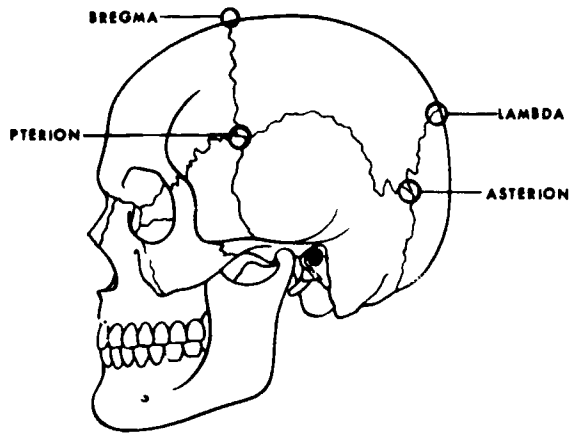


Figure 3-2 Cranial junctions

of the facial contour. See foldout 1 at the back of this volume.

**Maxillae.** The maxillae form the upper jaw and hold the upper teeth in place. They meet and fuse at the anterior borders of the face and in the midline. Also, they form part of the medial floor of the orbits, the medial part of the infraorbital ridge, the lateral parts of the nasal fossa, and the anterior part of the roof of the mouth. Each maxilla consists of the body, the frontal process, the infraorbital foramen, the infraorbital margin, the zygomatic process, the palatine process, the anterior nasal spine, and the alveolar process.

The body comprises most of the bone and has a large cavity, the antrum of Highmore, which contains the maxillary sinus. The frontal process of the maxilla extends upward to form part of the lateral border of the nose and the medial portion of the infraorbital margin. The infraorbital margin is the anteroinferior margin of the orbit formed partly by the maxilla. The infraorbital foramen is a small hole just below the center of the infraorbital margin, through which the infraorbital nerves and vessels pass to the cheeks. The zygomatic process extends laterally from the body and articulates with the maxillary process of zygoma. The palatine process is a horizontal plate of bone extending medially to meet the corresponding bone of the other side to form the anterior part of the roof of the mouth and the floor of the nose. The anterior nasal spine is a sharp projection of bone on the lower part of the midanterior surface of the maxilla. The alveolar process is the portion of the maxilla that contains the cavities of different sizes and shapes which hold the teeth of the upper jaw.

**Lacrimal.** These are the smallest and most delicate bones of the facial skeleton. They are located bilaterally to form a small portion of the antemedial part of the orbital walls. They also house the "tear" ducts.

**Zygomatic.** The two zygomatic or malar bones, often called the cheek bones, are located at the superolateral aspect of the face bilaterally and form the prominent portion of the cheeks and part of the orbits. The parts of each bone that deserve consideration are the frontosphenoidal, orbital, maxillary, and temporal processes. The frontosphenoidal

process is the part that articulates with the zygomatic process of the frontal bone. The orbital process is the part that extends medially from the infraorbital margin to form part of the floor and lateral walls of the orbits. The lateral part of the infraorbital margin is formed by the anterior process of the orbital process of the zygoma. The maxillary process is the part that articulates with the zygomatic process of the maxilla. The temporal process is the long, narrow projection that articulates with the zygomatic process of the temporal bone to form the zygomatic arches.

**Palatine.** The palatine bones are small L-shaped bones located behind the nose. The perpendicular part of each bone forms part of the lateral wall of the nasal cavity. The horizontal part of each articulates with the corresponding horizontal part of the other palatine to form the posterior part of the roof of the mouth.

**Nasal.** Two nasal bones form the bridge of the nose and articulate above with the nasal notch of the frontal bone; they project anteroinferiorly from this junction. Laterally, they articulate with the frontal processes of the maxillae.

**Inferior Nasal Conchae.** The inferior nasal conchae, also called the inferior turbinate bones, are long, thin bones located along the lateral walls of the nasal cavity.

**Vomer.** The vomer, a flat, thin bone, forms the posteroinferior part of the nasal septum and is located behind and below the perpendicular plate of the ethmoid bone. The upper border of its anterior part articulates with the inferior surfaces of the perpendicular plate of the ethmoid bone. The lower part of the anterior border articulates with the cartilage of the nasal septum.

**Mandible.** In the mandible, which makes up the lower jaw and houses the lower teeth, these areas should be studied.

**Body.** The body, the curved part of the bone, is shaped like a horseshoe extending from one mandibular angle to the other.

**Symphysis.** The symphysis, or symphysis menti, is the anterior part of the body where the two L-shaped halves fuse together early in life—usually during the second year.

**Mental foramen.** The mental foramina are located about 1/4 inches on each side of the symphysis menti below the level of the second premolar (bicuspid) tooth on the anterior surface of the body of the mandible.

**Angle.** The angles of the mandible are the rounded areas of the lower jaws where the horizontal part of the body bends upward to an almost vertical position. They are located bilaterally at the posteroinferior part of the mandible and mark the junctions of the body and the rami

**Ramus.** The rami of the mandible are those parts of the bone extending upward at about 45° from the angles of the mandible at the posterior aspects of the bone, bilaterally.

**Mandibular foramen.** The mandibular foramina are holes at the center of the medial surface of each ramus.

**Coronoid process.** The coronoid processes extend from the superanterior border of the rami.

**Condylod process.** The condylod processes are bony projections extending from the superoposterior borders of the rami. Each process has two parts—the neck and the condyle.

**Mandibular notch.** The mandibular notches are the semicircular, or half-moon, depressions between the coronoid and condyloid processes of the rami

**Exercises (223):**

Indicate whether the following statements are true or false. If you indicate false, explain your answer

- \_\_\_ 1. There are 14 facial bones.
- \_\_\_ 2. The bones that form the upper jaw are the maxillae.
- \_\_\_ 3. The antrum of Highmore is in the zygoma.
- \_\_\_ 4. The infraorbital foramen is part of the maxilla.
- \_\_\_ 5. The two palatine processes of the maxillae help form the upper margin of the nasal cavity.
- \_\_\_ 6. The lacrimals are small bones that form a small portion of the orbital walls.
- \_\_\_ 7. The prominent portions of the cheeks are formed by the two maxillary bones.
- \_\_\_ 8. The frontosphenoidal process of the zygoma articulates with the zygomatic process of the frontal bone.
- \_\_\_ 9. The zygomatic arches are formed entirely by the zygomatic bones.
- \_\_\_ 10. The palatine bones form the posterior portion of the roof of the mouth.
- \_\_\_ 11. There are two nasal bones that form the bridge of the nose.

- \_\_\_ 12. The inferior nasal conchae are located along the medial walls of the orbits
- \_\_\_ 13. The vomer forms part of the nasal septum
- \_\_\_ 14. The area between the mandibular angles is the mandibular body.
- \_\_\_ 15. The symphysis of the mandible is laterally located with respect to the mental foramen.
- \_\_\_ 16. There is only one mental foramen
- \_\_\_ 17. The mandibular angle is located between the coronoid and condyloid processes.
- \_\_\_ 18. The mandibular foramina are located on the rami.
- \_\_\_ 19. The condyloid process is anterior to the coronoid process
- \_\_\_ 20. The intercondylar notch is located between the coronoid process and the condyloid process.

**3-3. The Paranasal Sinuses**

There are four paranasal sinus categories: the frontal sinuses, the maxillary sinuses, the ethmoidal sinuses, and the sphenoidal sinuses.

**224. Match each of the four paranasal sinuses with a statement giving its location or other description.**

The paranasal sinuses are mucous-lined cavities in the frontal, maxillary, ethmoid, and sphenoid bones. Their location, of course, is responsible for their names—frontal, maxillary, ethmoidal, and sphenoidal sinuses. For our discussion, we begin by briefly describing each.

**The Frontal Sinuses.** These cavities are between the inner and outer tables of the frontal bone, in an area just above the bridge of the nose. These sinuses are highly

irregular in shape and size, extending upward, backward, and laterally from a more or less central point just above and behind the bridge of the nose. They are separated by a thin, bony septum, which very often deviates from one side to the other. They are lined with mucous membrane, and each cavity communicates with the nasal cavity on its side by means of the frontonasal duct (see fig. 3-3).

**The Maxillary Sinuses.** These are large, pyramidal cavities contained in the maxillae. They communicate to the nasal cavity through two small orifices in the superomedial aspects of each antrum. The floor of each cavity is formed by the alveolar processes of the maxillae, and if the sinuses are of average size, this floor is on a level with the floor of the nose. The maxillary sinuses, like the frontals, vary in size and configuration, even in the same patient. Both cavities are lined by a mucoperiosteal membrane that is continuous with that of the nasal cavity (see fig. 3-4).

**The Ethmoidal Sinuses.** These sinuses form the medial wall of each orbit as well as the superior portion of the nose

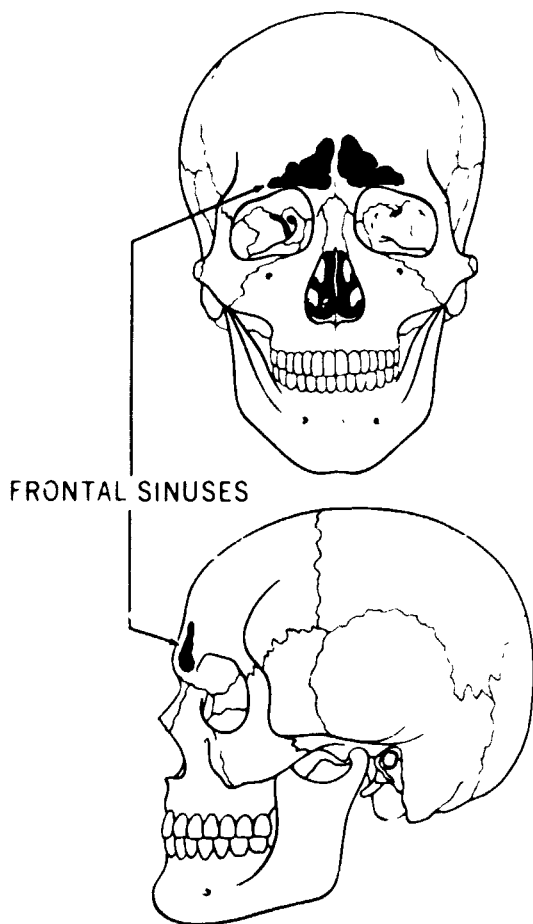


Figure 3-3 Frontal sinuses

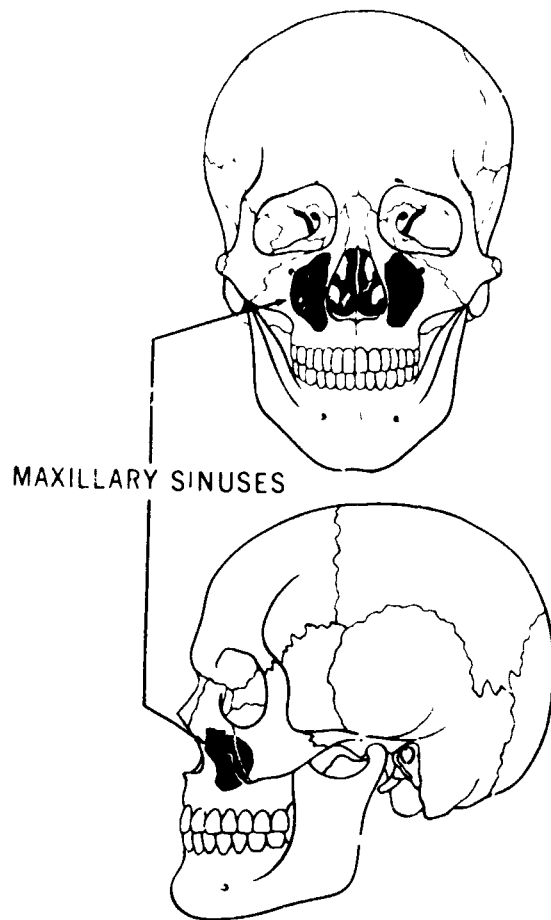


Figure 3-4 Maxillary sinuses

on either side. The air cells of the ethmoids vary in number and size. There may be many small cavities or fewer large cavities. The anterior ethmoidal cells communicate with the middle nasal meatus. The posterior cells, located at the back of the nasal fossa, communicate with the superior meatus. The ethmoidal cells are lined by mucoperiosteal membrane continuous with that of the nasal cavity (see fig. 3-5).

**The Sphenoidal Sinuses.** The sphenoidal sinuses are directly posterior to the ethmoidal sinuses. They are a pair of cavities in the body of the sphenoid bone, separated from each other by a bony septum. This septum is rarely perpendicular to the base of the body, but is bent to one side or the other. This accounts for the asymmetrical appearance of the sinuses. In many cases they are continuous with the ethmoidal sinuses. The sphenoids are lined by a mucoperiosteal membrane that is continuous with that of the nasal cavity. They communicate with that cavity through the phenoethmoidal recess, situated high in the posterior aspect of the nasal cavity (see fig. 3-6).

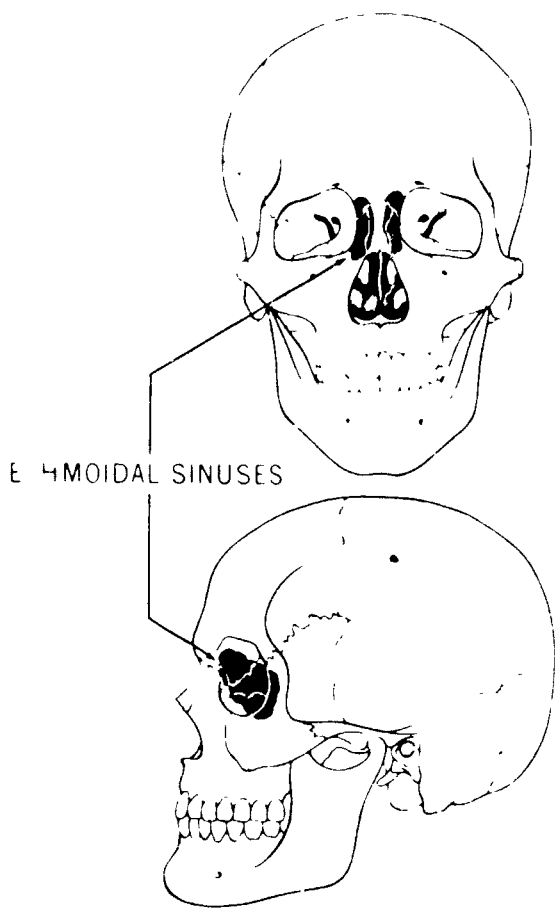


Figure 3-5 The ethmoidal sinuses

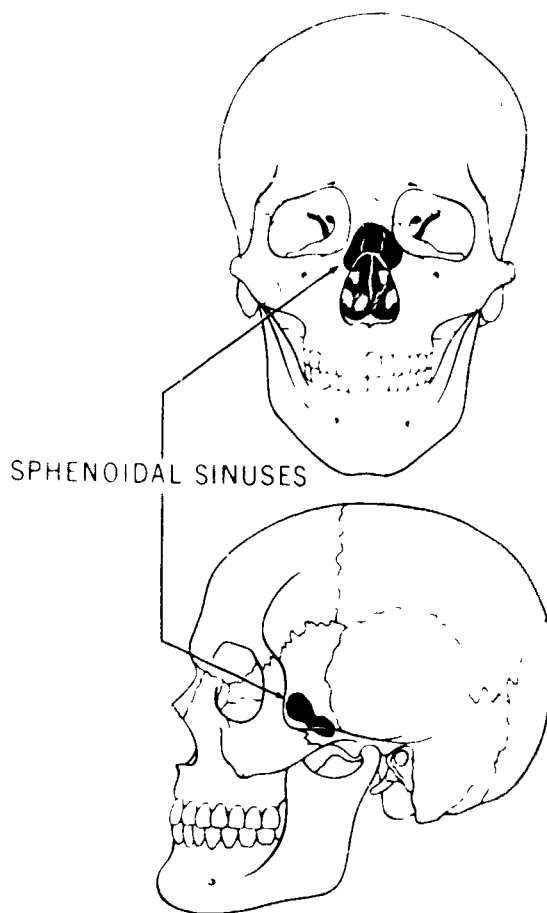


Figure 3-6 The sphenoidal sinuses

**Exercises (224):**

- Match each column A statement about the paranasal sinuses with the correct sinuses in column B. Each column B item may be used once or more than once

*Column A*

- (1) Located above and behind the bridge of the nose
- (2) Communicate with nasal cavity by means of the frontonasal duct
- (3) Located below the orbits
- (4) Located posterior to the ethmoidals
- (5) Form the medial walls of the orbits
- (6) Communicate with nasal cavity by means of the sphenothmoidal recess

*Column B*

- a Ethmoidal
- b Maxillary
- c Frontal
- d Sphenoidal



## Positioning of the Upper Extremity

THE CHAPTERS on positioning begin with the upper extremities. Although we try to cover all routine and some additional views of standard positions, we do not cover all minor details associated with the positions. We instead review some important points about standard positions and the related anatomy demonstrated by these selected projections. We also present certain information that will help you evaluate selected radiographs and perform the duties of a quality control technician.

### 4-1. The Thumb

Positioning of the upper extremity includes the fingers, hand, wrist, forearm, elbow, humerus, and shoulder. We begin with the thumb, which has three basic positions.

#### 225. Explain procedures for the routine radiography of the thumb and identify demonstrated structures.

**Anteroposterior (AP) Thumb.** To avoid motion or rotation, you should use your own hand to demonstrate this position. Keep in mind certain points when positioning the patient for the radiograph. With the forearm resting on the table, the hand is turned to a position of extreme internal rotation until the thumb rests on its posterior surface in contact with the film holder. If it is necessary to steady the part and clear the thumb of other digits, have the patient grasp the fingers of the affected hand and draw them backward out of the path of the central ray.

Usually all three views are obtained in the examination. Therefore, you should align the long axis of the thumb uniformly with the border of the film so all views are in the same direction on the film. Always use lead masking to cover areas not directly under the thumb to prevent scatter radiation fog and superimposing or overlapping two views. Center the first metacarpophalangeal (MP) joint to the center of the unmasked portion of the film and direct the perpendicular CR to that point.

**Oblique Thumb.** With the hand extended palm down, center the thumb on the unmasked portion of the film and direct the perpendicular central ray (CR) through the metacarpophalangeal joint. As with all thumb positions, be sure to include the entire first metacarpal within your collimation. Sometimes small linear or chip fractures may be present causing pain to irradiate to the phalanges of the thumb. This view shows chip fractures at the ends of phalanges not readily seen on the AP or lateral.

**Lateral Thumb.** From the oblique position, have the patient flex the fingers of the affected hand to form a natural arched position or fist with the thumb extended. This procedure places the phalanges of the thumb in true lateral.

Again, center the metacarpophalangeal joint to the center of the unmasked portion of the film and direct your perpendicular CR to that point.

**Anatomy Demonstrated.** All radiographs of the thumb show the two phalanges of the thumb, the first metacarpal, related soft tissue structures, and articulations. The interphalangeal joint and the first metacarpophalangeal joint should be visible.

#### Exercises (225):

1. What are the routine projections for the thumb?
2. Explain what you can do to help the patient control part motion or rotation during the AP thumb positioning.
3. Explain why the first metacarpal should be included on the film.
4. Describe how the thumb is placed in the lateral position.
5. What is the centering point for the CR during thumb positioning?
6. What articulations should be visible on a thumb radiograph?

### 4-2. The Fingers

The routine projections for fingers are PA, oblique, and lateral. The PA hand is included in some radiology departments. For our coverage in this section, we will discuss the first three positions.

226. State the correct position for the fingers and explain characteristics of finger positioning.

**PA Fingers.** Generally, the PA projection includes all the fingers. However, some radiologists prefer you to center on only the affected digit if only one finger is to be demonstrated. You should follow your department's list of routines for all projections.

When you are positioning for the PA finger, ensure that the finger is fully extended and placed flat on the film holder. Arching of the finger may superimpose articular surfaces upon themselves. This renders accurate diagnosis of interphalangeal pathology impossible. Furthermore, to keep those joint spaces open as much as possible, always direct the perpendicular CR into the proximal interphalangeal (PIP) joint space.

**Oblique Fingers.** The general survey oblique commonly done for fingers is the PA Medical Oblique (PAMO) of the hand. But disadvantages of that position are the increase in OFD for the index and middle fingers, and the closing of interphalangeal joint spaces because patients tend to drop their fingertips to the film. The closing of interphalangeal joint spaces is clearly seen in the difference of figures 4-1 and 4-2. Notice in figure 4-1, the fingers are parallel to the film and the joint spaces are open, in figure 4-2, they are not. This latter problem is overcome with the use of the polyfoam step wedge (see fig. 4-3). This device keeps the patient's fingers parallel with the film.

When radiographing a particular finger, you should use the oblique that will result in the least OFD. For instance, with index or middle fingers, from a PA position, curl the thumb to the palm and rotate the hand inward until the index finger is obliqued (PA lateral oblique) on the film (see

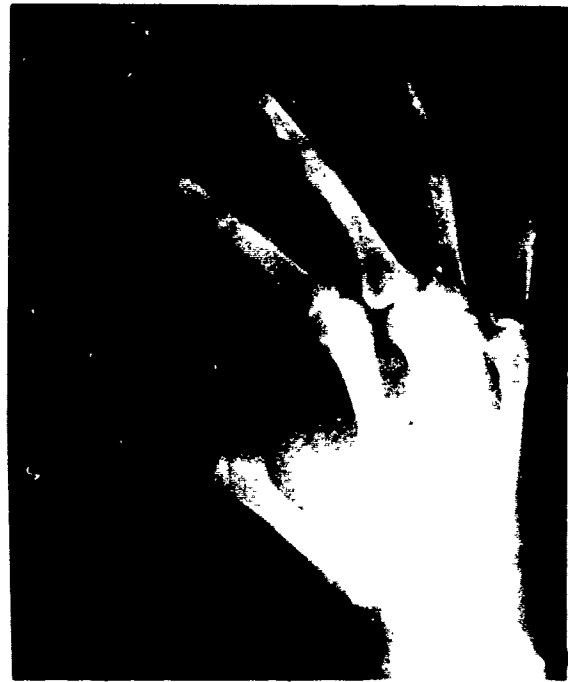


Figure 4-2 Oblique radiograph of the fingers showing superimposition of articular surfaces of interphalangeal joints

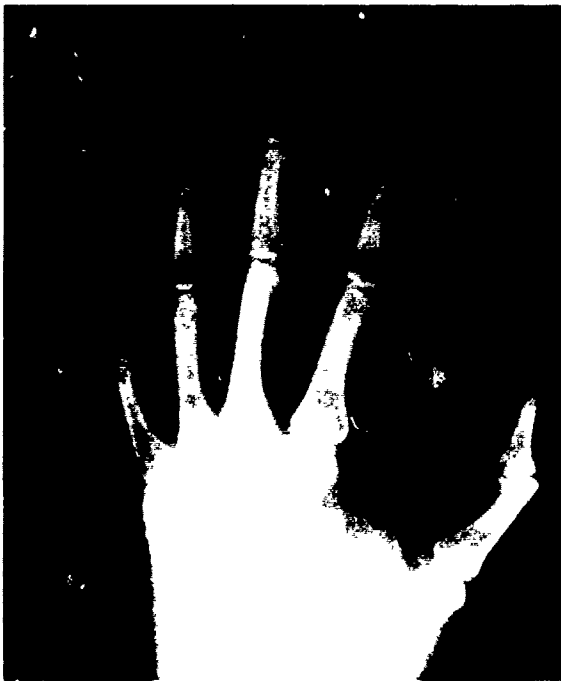

Figure 4-1. Oblique radiograph of the fingers showing good visualization of the center phalangeal joints




Figure 4-3. The polyfoam step wedge

fig. 4-4). Ensure the finger is parallel and direct the perpendicular CR through the proximal interphalangeal joint. Positioning of fourth and fifth fingers would be the same as the PAMO hand with the CR directed to the PIP joint.

**Lateral Fingers.** If you are doing a general survey lateral film for all the fingers, the lateral hand with fingers spread apart and parallel to the film is satisfactory (see fig. 4-5). This prevents superimposition of phalanges. However, if only one or two digits are involved, you should do the lateral that will place the affected finger closest to the film.




Figure 4-4 Oblique positioning of the index finger




Figure 4-5 Positioning for a lateral view of the fingers

A mediolateral projection is best for index and middle fingers while the lateromedial projection should be done for fourth and fifth digits.

Trauma and pain may cause part motion. A finger may be immobilized with the use of a polyfoam step wedge, wooden tongue depressor, or similar object. Always be sure the fingers are parallel to the film and not superimposed over each other.

**Anatomy Demonstrated.** The three phalanges (thumb has two), articulations, and the distal half of the related metacarpal should be visualized for each finger. The articulations are proximal interphalangeal, distal interphalangeal, and metacarpophalangeal joints.

#### Exercises (226):

1. Radiographs are needed on a patient's index finger. Your department routines require views of only the affected digit. What three positions should you perform?

2. Which oblique is used to demonstrate the fourth digit? Explain.
3. Why should fingers be parallel to the film?
4. List two devices used to immobilize a finger during positioning.
5. Which lateral should be used to demonstrate the index finger? Explain why.
6. How many articulations should be visualized on each finger radiograph?

#### 4-3. The Hand

Standard positions of the hand include PA, oblique, and lateral.

#### 227. State the correct position of the hand and evaluate hand positioning characteristics.

**PA Hand.** The PA projection presents an anterior view of the hand and, because it serves as the general survey film for the hand, should include all digits and the wrist. Therefore, proper centering on the unmasked portion of the film is of prime importance.

The ideal situation would have the patient sitting comfortably facing the end of the table to help control motion. With the forearm extended and resting on the table top, the hand is pronated until the palm is on the film holder. Ensure fingers are flat and only slightly spread apart. Direct the CR through the head of the third metacarpal to the center of the film.

When the MP joints are the points of interest and the patient cannot extend the hand enough to place its palmar surface in contact with the film holder, reverse the position of the hand for an AP projection. This position is also used for the metacarpals when, due to injury, pathology, or dressings, the hand cannot be extended.

**Oblique Hand.** Positioning for the oblique view is usually done on the same film with the PA. Center the hand on the unexposed half of the film and from the PA position, rotate the hand into a 45° medial oblique. Fingers should be extended and parallel to the film for maximum visualization of interphalangeal joint spaces. If the metacarpals are of prime importance, slightly flex fingers to place their tips on the film. Regardless of which method you perform, always

ensure the CR is projected through the head of the third metacarpal.

**Lateral Hand.** The lateral position can be done either of two ways. The lateromedial projection with fingers superimposed is the choice if foreign bodies or fractures in the metacarpals are suspected. If you wish to better visualize fingers, a lateromedial with fingers spread wide apart and parallel to the film is preferred. CR is perpendicular to the head of the second metacarpal

**Anatomy Demonstrated.** All views of the hand should show phalanges, metacarpals, carpals, and related joint structures.

#### Exercises (227):

1. What position is necessary to obtain an anterior view of the hand?
2. A trauma patient with an anterior wound to the hand is unable to extend the hand. What position is used to best demonstrate the metacarpals?
3. How many degrees is the hand rotated for the oblique position?
4. What is the centering point for the CR for the lateral projection?

#### 4-4. The Wrist

Every radiology department usually requires the three "standard" positions for the wrist—PA, medial oblique, and lateral.

#### 228. Identify routine wrist positions.

**PA Wrist.** Generally speaking, the three positions of the wrist can be done on the same film. The first position done is usually the PA. In this position, the patient's forearm is extended on the film with the hand pronated (palm down). Center the wrist to the unmasked portion of the film and partially flex the fingers to place fingertips on the film. This step reduces the normal curvature of the wrist and provides for a closer object-film contact. A perpendicular CR is directed to the midcarpal area.

**Oblique Wrist.** The oblique position that's routine for the wrist is the medial oblique (also referred to as the PA oblique). From the PA position, rotate the radial side up until an imaginary line through the radial and ulnar styloid processes is 45° to the film. Direct the perpendicular CR through the midpoint between the styloid processes.

This position demonstrates the carpals on the lateral side of the wrist, particularly the navicular, which is stacked upon itself in the direct PA projection.

**Lateral Wrist.** The lateromedial projection is the common lateral performed for the wrist. Place the forearm on the table with the wrist joint centered to the film. The wrist is in true lateral when the radial styloid process is directly superimposed over the ulnar styloid process. Slight supination (5°) of the hand will place the wrist in a true lateral position. The CR is perpendicular to the center of the film, directed through the carpals.

**Anatomy Demonstrated.** All routine views of the wrist should demonstrate carpals, distal radius and ulna, proximal metacarpals, and articulations.

#### Exercises (228):

Answer the following true or false. If you select false, explain your answer.

1. The routine projections for the wrist are PA, lateral oblique, and lateral.
2. The hand is supinated to prevent radial crossover when doing the PA wrist.
3. With the PA position, fingers are flexed and their tips placed on the film to put the anterior surface of the wrist closest to the film.
4. In the oblique position, the CR is perpendicular to the line that is through the radial and ulnar styloid processes.
5. The hand should be slightly supinated during the lateromedial lateral.
6. The line through the radial and ulnar styloids is perpendicular to the film in the lateral position.

#### 229. Given selected statements pertaining to the four additional positions of the wrist, match each with the specific position to which it relates.

**Additional Positions of the Wrist.** The PA, medial oblique, and lateral are routine positions that are standard in every radiology department. There are times, however, that your radiologist may request additional views to demonstrate particular structures of the wrist. Therefore, in

this section, we will cover certain wrist positions that are not usually done for every wrist series. These additional wrist positions include radial deviation, ulnar deviation, semisupination oblique, and carpal tunnel.

**Radial deviation.** This additional position is used primarily to demonstrate the carpal navicular. The position is also referred to as ulnar flexion, because the hand is flexed towards the ulna.

Radial deviation begins as a routine PA hand with the carpals centered to the film. At this point, have the patient immobilize the affected wrist and forearm. The hand is moved away from the radius (radial deviation), which places it nearer the ulna (ulnar flexion). A perpendicular CR is directed to the midcarpal area. Figure 4-6 shows radial deviation.

**Ulnar deviation.** Ulnar deviation (radial flexion) has opposite movement of the hand when compared to radial deviation. This position is used to demonstrate the pisiform and, like radial deviation, carpal interspaces of the deviated side. With ulnar deviation, the hand is moved away from the ulna, towards the radius. All other factors remain the same. Figure 4-7 shows the ulnar deviation position and radiograph. Notice in the radiograph how well carpal



Figure 4-6 Positioning and radiograph of radial deviation of the wrist.




Figure 4-7. Positioning and radiograph of ulnar deviation of the wrist

interspaces surrounding the triangular and pisiform are clearly visualized.

**Semisupination oblique.** As you recall, the PA medial oblique shows adequate visualization of the navicular. There are times when trauma to the medial aspect of the wrist may require a different view. The semisupination oblique is an AP oblique that demonstrates the pisiform and related structures on the medial side.

The hand is semisupinated from a lateral position until the interstyloid line forms a 45° angle to the film. This maneuver projects the pisiform free of superimposition. Direct the vertical CR through the midcarpal area to the center of the film. Figure 4-8 shows a semisupination oblique.

**Gaynor-Hart.** The Gaynor-Hart position is also referred to by other names: carpal canal, carpal tunnel, or inferosuperior projection. Regardless of which terminology you use, this position shows an axial projection of the anterior surface of the wrist—the carpal canal.

Have the patient extend the wrist until the palmar surface of the hand is as vertical as possible to the film. To support the forearm, place a small radiolucent pad (about three-fourths of an inch thick) under the wrist. Rotate the hand slightly toward the radial side of the wrist to separate the hamulus process and pisiform. Direct the CR through the carpal canal at an angle of 30° (from vertical) Figures 4-9 and 4-10 show this position and a radiograph of the carpal canal. Notice in the radiograph how well the pisiform and hamular process are visualized.




Figure 4-8 Positioning of the semisupination oblique of the wrist



Figure 4-9. Positioning of the hand and wrist for the Gaynor-Hart projection.



Figure 4-10 Radiograph of the carpal canal

#### Exercises (229):

- Match each column A statement about additional wrist positioning with the correct wrist position in column B. Each column B item may be used once or more than once.

<i>Column A</i>	<i>Column B</i>
— (1) Also called radial flexion	a Radial deviation
— (2) Requires the interstyloid line to be angled 45° to the film	b Ulnar deviation
— (3) Most likely requested for navicular fracture	c Semisupination oblique
— (4) Requires a 30° CR angulation	d Gaynor-Hart
— (5) Shows an axial view of the carpal tunnel	
— (6) Also called ulnar flexion	
— (7) A PA projection for the pisiform	

#### 4-5. The Forearm and Elbow

The forearm poses no particular problems to the radiologic technician, as it is comprised of two relatively straight bones with no complex angles or surfaces. Views for the elbow can be more difficult to obtain, especially when trauma affects positioning. In this section, we will cover positioning for both, beginning with the routine projections for the forearm—AP and lateral.

**230. State characteristics of positions for the forearm and select correct forearm positions for hypothetical situations.**

**AP Forearm.** The skilled technician ensures that the forearm is in true AP for this position. This can be achieved by having the interstyloid line and the humeral epicondylar plane parallel to the film. This is done by having the arm and forearm in full extension with the hand supinated. You may need to weight the thumb side of the hand with a sandbag to maintain true AP. The sandbag prevents rotation of the hand, which would cause the forearm to be obliqued, and pronation of the hand, which would cause the upper third of the radius to crossover the ulna.

**Lateral Forearm.** The lateral projection of the forearm is done by having the patient flex the affected elbow 90° to the upper arm. The whole extremity is then placed so that the anterior surface of the forearm is flush with the film holder with the arm on the tabletop. Rotate the wrist laterally 90°, or to the same position used for a lateral wrist. This places the interstyloid line and the epicondylar plane (of the humerus) perpendicular to the film for a true lateral forearm.

Certain additional considerations apply to both AP and lateral forearm positions. One is adequate visualization of the joint structure nearest the site of injury. Always show at least one joint on your radiograph. If your radiologist requires both joints on the film, you should routinely center the forearm on a film long enough to get both joints. If, on a previous or general survey film, a fracture invades the joint on either projection, include the entire joint on a radiograph.

Also, some radiologists require comparison views of the opposite extremity on children (16 years and younger) because the epiphyses do not fuse with the diaphyses earlier. This condition could be misinterpreted as a fracture without a comparison film.

**Exercises (230):**

1. What position is the forearm in if the upper extremity is extended and the interstyloid plane is parallel to the film?
2. Why should the hand be supinated, instead of pronated, for the AP position of the forearm?
3. A fracture of the olecranon process can be seen on a general survey radiograph of an adult. What should you do to ensure a complete study of the forearm?

4. A 5-year-old girl has a suspected fracture of the distal radius. What positions are necessary for a complete forearm series?

5. How is the elbow positioned for the lateral view of the forearm?

**231. Given various patient situations, select correct positions of the elbow and state characteristics of positions for the elbow.**

**AP Elbow.** The elbow is usually demonstrated by AP and lateral views, although an oblique may be included in some departments. The AP projection is performed by extending the arm and centering the elbow on the unmasked portion of the film. As with the AP forearm position, you must ensure true AP by maintaining the horizontal plane through the epicondyles of the humerus parallel with the film. Also, the hand must be supinated to prevent rotation of the radial head. Direct the perpendicular CR to the center of the film.

**Lateral Elbow.** Positioning for the lateral is the same as you did for a lateral forearm: elbow flexed 90° to the upper arm, humeral epicondylar plane and interstyloid line are perpendicular to the film, and vertical CR directed through the elbow. Be sure that the elbow is centered to the film.

An elbow that is properly positioned for the lateral view will be visualized with the epicondyles of the humerus superimposed. If not positioned correctly, the elbow will be viewed with slight rotation of the epicondyles from a superimposed position. This condition may obscure articular surfaces and prevent proper visualization of joint spaces.

**Medial Oblique Elbow.** This position could be classified as either a routine or an additional view, depending upon your radiologist's preference. It is easy to obtain if you begin as you did for the AP elbow: extend the elbow in true AP and center the epicondyles to the film. After completion of this step, pronate the hand and adjust the elbow until its anterior surface forms a 40-45° angle with the film as shown in figure 4-11. This position frees the coronoid process from superimposing the radial head.

**Additional Positions of the Elbow.** There are, of course, situations in which you will be required to demonstrate specific parts of the elbow, such as the olecranon process or the radial head. In such cases it is usually desirable to use the positions that produce the "additional" views. Some situations you may be too hardpressed—due to trauma to the elbow—to obtain even the standard views. You may need to use certain modifications that yield fairly accurate views in cases such as these. This portion explains additional views you may need to use someday.

**Jones position.** This is also called the acute flexion position because the elbow is in extreme (acute) flexion. It is used to demonstrate the olecranon process.




Figure 4-11 Medial oblique positioning of the forearm

The posterior aspect of the humerus is placed flat on the table so that its distal end is centered on the film. The elbow is flexed and the forearm is brought as near to the upper arm as possible. The hand and wrist should be rotated until the thumb is on the lateral side and the palm rests on the shoulder. Position the epicondylar plane parallel to the film and direct the perpendicular CR to the olecranon process. Figure 4-12 shows the Jones position.

**Lateral oblique elbow.** Earlier, the medial oblique position for the elbow was described and we stated that it demonstrates the coronoid process fairly well. The lateral oblique position is used when the radial head, the capitulum, or the radio-ulnar articulation needs to be seen.

For a lateral oblique, begin as you would position for an AP elbow and rotate both forearm and upper arm about 40° to 45° toward the lateral aspect of the arm. Direct the perpendicular CR through the elbow joint. Figure 4-13 shows the positioning for the lateral oblique elbow.

**AP elbow with partial flexion.** Injuries involving the elbow are usually serious, painful, and totally incapacitating as far as the affected arm is concerned. Generally, when you see a patient with an elbow injury, the injured arm is in a sling and the elbow is partially flexed. Your patient may not be able to extend or hyperflex the arm. This situation prevents you from obtaining the standard PA view, but there is a variation you can do.

When the patient is unable to extend the elbow completely, the lateral position offers little difficulty, but it is necessary to make at least two AP exposures to avoid distortion. The first is of the lower humerus.

With the patient seated low enough to place the entire humerus on the table, center the elbow to the film and support the elevated forearm on sandbags. Try to supinate the hand to rotate the radial head into true AP. Direct the perpendicular CR through the epicondylar plane. Figure 4-14 shows this projection.

Figure 4-15 shows the position of AP elbow with partial flexion for the upper forearm, the second necessary projection. You will note that the forearm is placed on the film and the humerus is raised off the table. The CR is perpendicular to the film, directed through the center of the elbow.

Occasionally, a third projection is included with the partial flexion views. This projection requires the

placement of the tip of the olecranon process on the film. Because of injury to the elbow, you must be careful to avoid hurting your patient in this position as the weight of the arm puts pressure on the injured olecranon process. You can help alleviate some of this discomfort by supporting the forearm and humerus with sandbags (see fig. 4-16). Position the CR as you did with the other partial flexion views.

#### Exercises (231):

1. How is the humeral epicondylar plane positioned for the lateral projection of the elbow?



A



B

A Position  
B Radiograph

Figure 4-12 Positioning and radiograph of the Jones projection of the elbow






Figure 4-13. Lateral oblique position of the elbow.



Figure 4-16 AP elbow with partial flexion for visualization of the olecranon process

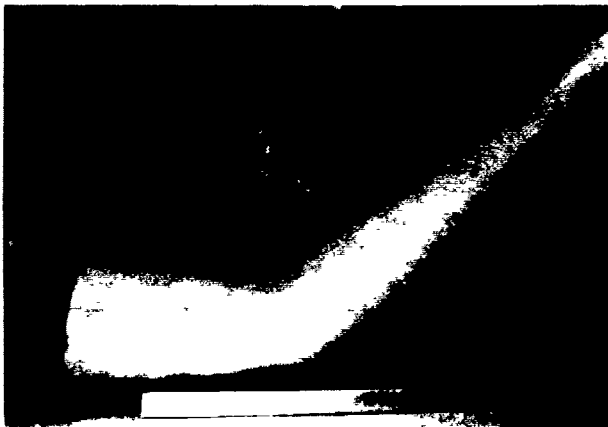


Figure 4-14 AP elbow with partial flexion for visualization of the distal humerus.



Figure 4-15. AP elbow with partial flexion for visualization of the upper forearm.

2. Which oblique of the elbow frees the coronoid process from superimposition with the radial head?
3. Why must the hand be supinated for the AP elbow position?
4. Your radiologist suspects a fracture of the radial head that is not clear on the AP and lateral views. Which oblique should you take for better demonstration of that area?
5. A trauma patient has a suspected fracture of the olecranon process. What additional position visualizes this structure when the arm is hyperflexed?

#### 4-6. The Humerus

The basic projections of the humerus, AP and lateral, are not difficult to obtain for the average radiology technician. We will not cover those views but, instead, will concentrate on the other positions that may not be common to each department. Also, since much of your performance is a direct result of trauma, some positions to use because of trauma will be covered in this section.

**232. Given three radiographs of a dry humerus, classify them as neutral, external, and internal rotation.**

**Rotation Projections of the Humerus.** The views of the humerus in external and internal rotation are classified as "additional" views. Although these views can be part of a shoulder joint series, they serve to demonstrate the

proximal humerus. In some cases they may be used as general survey films. Regardless of how they are used, it is easier to do these positions with your patient supine on the table.

**Internal rotation.** To position for the internal rotation projection, have your patient first place the palm of the hand flat on the table and then rotate the wrist toward the body. Although the wrist is being rotated, use the humeral epicondylar plane to determine correct rotation. Correct internal rotation is present when the epicondyles are perpendicular to the film. As you can see, the internal rotation position is a lateromedial projection of the humerus.

Classifying the rotation radiographs of the humerus is simply a matter of recognizing the position of the proximal humerus. In figure 4-17, when the arm is in internal rotation, only the superior portion of the humeral head is well visualized, since the rotation moves most of the head behind the other structures. The lesser tuberosity is shown in profile on the medial side of the humerus. The greater tuberosity is superimposed over other structures in the approximate center of the humerus.

**External rotation.** For external rotation, the hand is supinated and the wrist rotated away from the body. The arm is properly positioned when the epicondylar plane is parallel to the film, placing the humerus in true AP. The degree of rotation for this view is dependent upon your radiologist as some prefer slightly more rotation.

When the humerus is in external rotation, the greater tuberosity and humeral head are seen in profile (see fig. 4-18) and are well visualized. You can also see the depression of the anatomical neck between the greater tuberosity and head. The lesser tuberosity is superimposed over the lateral portion of the humerus.

**Neutral rotation.** In this position, the palm of the hand is placed against the thigh. This rolls the humeral head into a neutral position, placing the epicondylar plane 45° to the film (medial oblique). The central ray is perpendicular to the film and centered to the coracoid process for all three radiographs.

Figure 4-19 shows the arm in neutral position with the lesser tuberosity superimposed over the humerus a little toward the medial side. The humeral head is seen in the oblique position since it extends posteromedially from the humerus. The greater tuberosity is shown on the lateral side, although not so prominently as in the external rotation position.

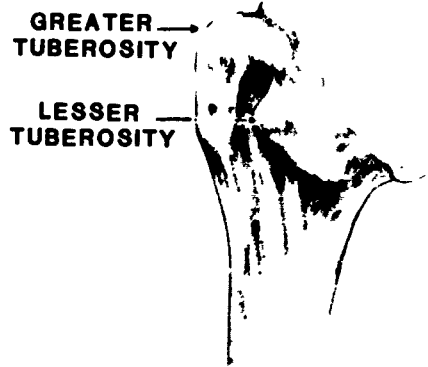


Figure 4-18 External rotation of the proximal humerus

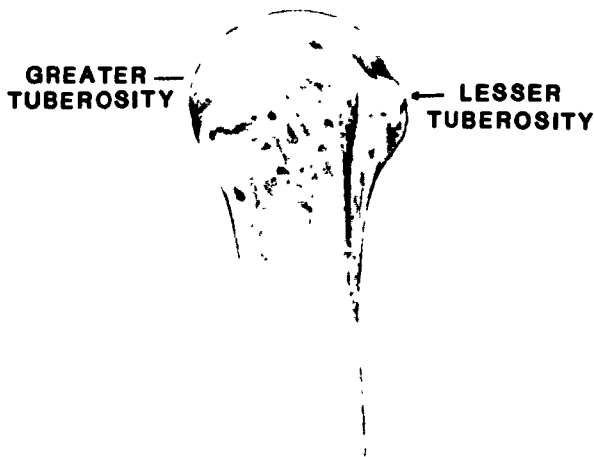


Figure 4-17 Internal rotation of the proximal humerus

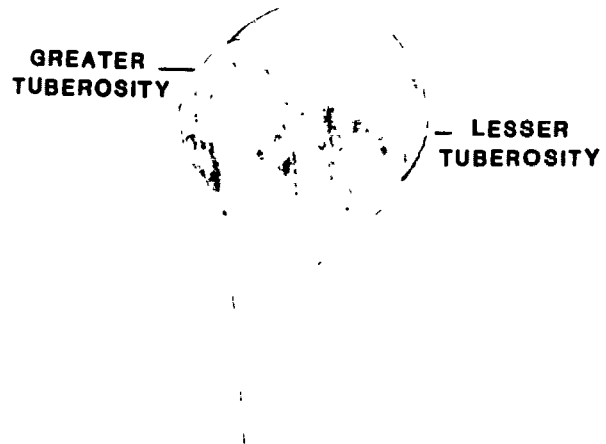


Figure 4-19 Neutral rotation of the proximal humerus

**Exercises (232):**

Figure 4-20 shows three radiographs of a dry humerus. Study them and classify them as neutral, external, or internal rotation. Write your answers below.

1. Radiograph A \_\_\_\_\_
2. Radiograph B \_\_\_\_\_
3. Radiograph C \_\_\_\_\_

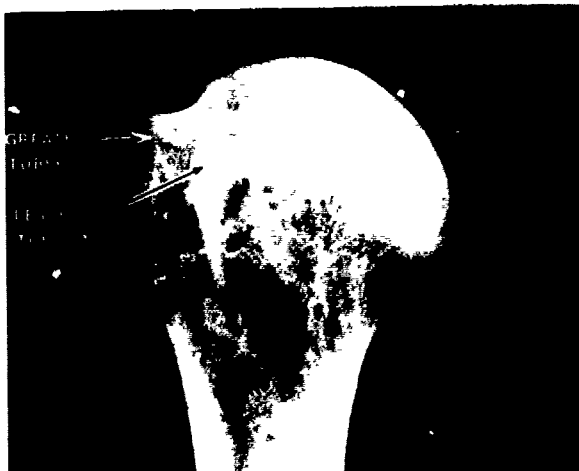
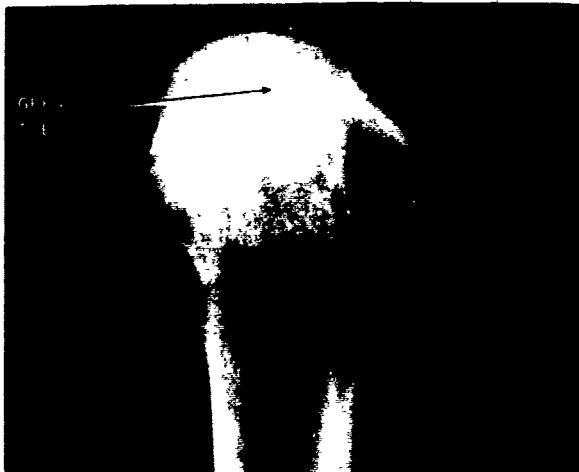
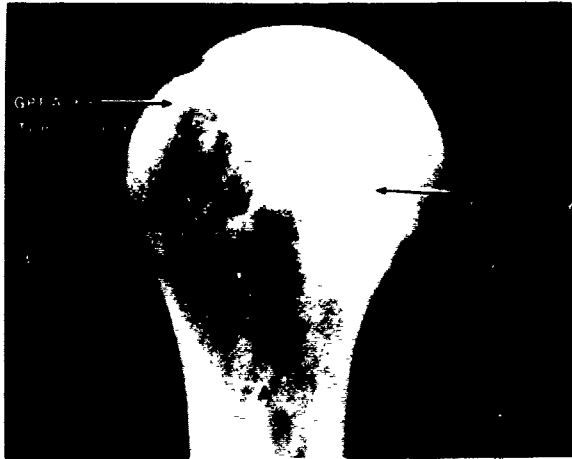Figure 4-20. Objective 232, exercises 1 through 3.

**233. State characteristics of positioning variations for a fractured humerus.**

**Special Radiographic Considerations of the Humerus.** Radiographic demonstration of the injured upper arm—especially fractures of the humerus—is complicated by two limiting factors. In the first place, because of its attachment and close proximity to the rib cage, the humerus is not easily demonstrated in cross-table projections as are the more distal parts of the extremity. Second, fractures of the humerus, like those of the femur, are quite serious in nature. Therefore, the upper arm must not be moved to any great degree while it is being positioned for radiographic examination.

Despite those limiting factors, we are still committed to produce two projections at right angles to each other; and in doing so, we are required to direct the CR at right angles to the long axis of the part and to its center. This procedure shows most fractures and any displacement of fractured bone. For instance, an AP radiograph may show any lateral displacement of bone at the fracture site; whereas, a lateral view may show anterior or posterior displacement.

To obtain necessary views and because of positioning limitations due to trauma, certain variations of standard positions become necessary.

**Positioning variations for AP humerus.** The routine AP position usually requires the patient to be supine on the table with the upper extremity fully extended along side the body. Severe pain or if the arm is in a sling would prevent full extension. You can still get the AP projection by one of two ways.

The first requires the patient sitting on a stool with the back of the upper arm barely touching an upright tabletop (see fig. 4-21). By rotating the patient into a posterior oblique towards the affected arm, you can move the humerus into a position that very closely approximates true



Figure 4-21 Positioning an injured patient for an AP projection of the humerus

AP. A horizontal beam is necessary to keep the CR perpendicular to the film

Another method achieves the same result on a patient unwilling to move from a wheelchair. This way requires a grid cassette since the Bucky is not being used. With the patient sitting in the wheelchair, place the film behind the humerus and direct the perpendicular CR to the center of the film. After you get the AP projection, the radiograph should be checked for severity of the fracture before positioning for the lateral.

**Positioning variations for lateral humerus.** After viewing the AP film, you can see where a fracture is located. Its location determines which lateral variation you should do. For instance, if the fracture is in the lower half of the humerus, you can get a good lateral by placing the film between the arm and ribs, as shown in figure 4-22. With the epicondylar plane and CR perpendicular to the film, anterior or posterior displacement of bone fragments can be seen on the radiograph.

If the fracture is in the upper half of the humerus, you may not be able to place the film high enough in the axilla to show the fracture. Therefore, a transthoracic lateral is needed.

**Transthoracic lateral.** In this position, as shown in figure 4-23, the lateral side of the upper arm is gently placed against the surface of an upright table. The patient's trunk is in true lateral and the opposite arm should be raised to place the forearm on top of the head. Because, as its name implies, the CR is directed through the chest, the exposure should be done when the patient is in full suspended inspiration. Having the lungs full of air improves the contrast and also decreases the exposure necessary to penetrate the body.

If the patient can be immobilized to prevent movement of the injured arm, breathing motion may be used. In this case,

instruct your patient to practice slow deep breathing. An exposure time of 5 to 10 seconds can give excellent results by allowing this breathing motion to blur out the superimposed structures (ribs and lung markings).

In figure 4-24, you can see how all those factors are brought together. Notice that ribs are somewhat blurred and because the lungs are filled with air, the radiographic contrast allows optimum demonstration of the humerus.

As you can see, positioning variations of the humerus affected by trauma are such that part movement is kept to a minimum. It is important that you do not add to the patient's injury. Unnecessary or excessive movement of the injured arm may cause additional complications. This can be avoided through your use of these positioning variations.

#### Exercises (233):

1. What determines the positioning for a lateral view of a fractured humerus?
2. Suppose an AP radiograph shows a fractured humerus. Why is it necessary to do a lateral film?
3. What radiograph should be taken to show anterior displacement of a fractured humeral head?
4. State two reasons why a transthoracic lateral of the humerus should be exposed with full inspiration of the patient.



Figure 4-22. Positioning an injured patient for a lateral projection of the distal humerus.



Figure 4-23. Positioning for a transthoracic lateral of the humerus



Figure 4-24 Radiograph of a transthoracic projection of a humerus

#### 4-7. The Shoulder

The shoulder, by definition, is the junction of the arm and trunk—the shoulder joint. It is also common to refer to the shoulder girdle—clavicle and scapula—as the shoulder. In the first part of this section, we will cover the shoulder joint, the latter part of this section will deal with the shoulder girdle. Most departments use internal and external rotation positions for their shoulder series. And since we already explained these positions earlier, we will concentrate on the more complex positions for the shoulder.

**234. Describe the additional positions for the shoulder joint by selecting the name or characteristic of each position.**

**The Grashey Position.** This position, commonly called Grashey's, shows the joint space between the humeral head and the glenoid fossa with the glenoid fossa in profile. This projection can be made with the patient in either the supine or the erect position. The latter is more comfortable for the patient and is usually easier for accurate adjustment of body rotation.

With the film centered to the shoulder joint, rotate the body about 45° toward the affected side. At this point, you may need to adjust the degree of rotation to place the scapula parallel with the film and the humeral head in contact with the table. Abduct the arm slightly in internal rotation and place the hand against the side of the body. Direct the perpendicular CR to the joint space. Figure 4-25 shows the Grashey position.

**Lawrence Position.** The Lawrence position is an inferosuperior axial projection. It is another additional view that is added to the routines for the shoulder in many departments. It shows the glenohumeral joint, lateral scapula and clavicle, and the proximal humerus.

Although this can be done with the patient sitting, you will find it easier to do if your patient is supine. As you can see in figure 4-26, the arm of the affected side is abducted and placed at right angles to the long axis of the body. The shoulder and arm should be elevated about 3 or 4 inches with folded sheets or firm pads to get the shoulder joint centered to the film. Rotate the arm externally into AP position for the humerus.

With the patient's head turned away from the affected side, place a vertical cassette on edge with its tube side against the top of the shoulder and as close to the neck as



Figure 4-25 The Grashey position for demonstration of the shoulder joint

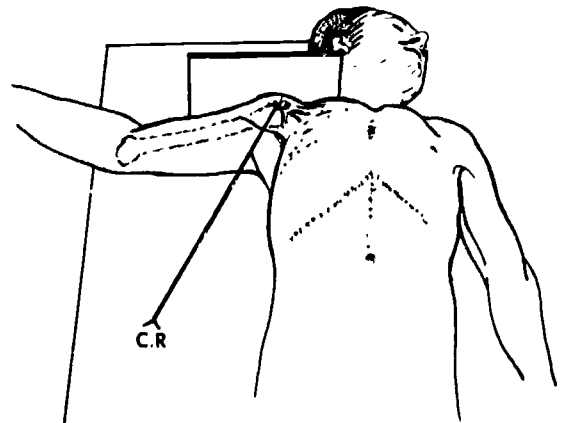


Figure 4-26 The Lawrence position

possible Support the cassette in this position with sandbags

Direct the CR horizontally through the axilla to the region of the acromioclavicular articulation. The degree of medial angulation of the CR depends upon the degree of abduction of the arm.

A superoinferior axial projection, an opposite projection to the Lawrence position, presents radiographically the same structures. It can, in some departments, be used instead of the Lawrence position. This position reverses the film placement and CR entrance point

#### Exercises (234):

Select the correct word(s) from the list to complete each statement. Each word(s) may be used only once or not at all.

Grashey position	Lawrence position
inferosuperior	laterally
superoinferior	medially
45°	20°

1. The CR is perpendicular to the film through the joint for the \_\_\_\_\_
2. It is easier to have the patient supine instead of sitting for the \_\_\_\_\_
3. Rotate the body \_\_\_\_\_ for the Grashey position.
4. The CR is angled \_\_\_\_\_ for the Lawrence position.
5. The \_\_\_\_\_ projection is a reverse projection of the Lawrence position.

#### 235. State characteristics pertaining to the positions of the shoulder girdle.

**Positions of the Scapula.** This bone is routinely demonstrated in body AP and lateral projections. The AP is positioned in a similar manner as an AP shoulder and offers no difficulty for the radiology technician. On the other hand, the lateral often needs to be repeated because of positioning error.

The lateral view is best made in the erect position with the table in an upright position. Have your patient place the affected arm across the chest and grasp the opposite shoulder. Rotate the patient's body into an anterior oblique position until a line from the acromion process to the midpoint of the vertebral border of the scapula is perpendicular to the film. Figure 4-27 shows patient positioning for a lateral scapula.

Reasons for repeating the lateral projection are usually technician's positioning errors. One mistake is the failure to keep the scapula in true profile, or lateral, to the film. This results in an oblique view instead of lateral. Another mistake is technician's carelessness of not properly centering the part of the film. You can avoid this by placing the superior border of the film about 2 inches above the top of the shoulder.

Direct the horizontal CR perpendicular to the film, centering on the vertebral border of the scapula.

The lateral projection for the scapula can also be done with the patient in a posterior oblique. In this manner, the CR is directed to the lateral border of the scapula. In both lateral projections, the scapula must be in profile to present a good lateral view

**Positions of the Clavicle.** The clavicle is the other bone of the shoulder girdle and is usually demonstrated in a single PA position with the CR perpendicular to the film. The PA position with the patient prone should not be done with a trauma patient. If the clavicle is fractured, the patient's weight may complicate the injury or cause the broken clavicle to puncture the lung, resulting in pneumothorax. You should avoid this situation by using the AP position instead of PA.

The AP position can be done either erect or supine. Be sure to include the entire clavicle on the film and direct the CR perpendicularly to the film. Respiration is suspended at the end of exhalation for a more uniform density and reduces the possibility of part motion.

In some departments, the radiologists may request a semiaxial view be included in the series. This film aids in demonstration of fractures not readily seen on the AP or PA. The semiaxial view is obtained by angling the CR cephalic in the AP position or caudad in the PA position.

The amount of angulation (15° to 45°) is determined by the chest thickness as measured from anterior to posterior. Since one purpose of the semiaxial projection is to project the clavicle on the film free of superimposition of ribs and scapula, the closer the clavicle is to the ribs, the more CR angulation (25° to 45°) is needed. If the clavicle is not in close proximity with the ribs, as with a large-chested person, the CR does not need to be angled much (15° to 25°) to project the clavicle without overlying ribs.

**Acromioclavicular (AC) Joint Positions.** The AC joints are usually demonstrated bilaterally on the same film with the patient erect and AP. Generally, the possibility of AC separation, commonly called shoulder separation, requires two AP erect films, one with the patient holding equal



Figure 4-27. Positioning for a lateral projection of the scapula.

weights (10 to 20 pounds apiece) in each hand, and one taken without weights. If shoulder separation is present, the use of weights will show an increased gap in the AC joint when compared to the film taken without the patient holding weights.

**Exercises (235):**

1. What position is the body rotated when the CR enters at the vertebral border of the left scapula for a lateral projection?
2. State the routine positions for the scapula
3. A trauma patient with a bulge in the midshaft of the clavicle needs radiographs. State projections that should be taken in this situation with the patient supine.
4. State two reasons why suspended expiration is used with an AP clavicle
5. What determines the direction of CR angulation for a semiaxial projection of the clavicle?

## Positioning of the Lower Extremity

THE BONES OF THE lower extremities together with their girdle, the pelvis, are divided into four parts: the foot, the leg, the thigh, and the hip. As with the upper extremity, the lower extremity also is subjected to a lot of injuries. Much of your work in clinical radiology is taking films of these structures. Therefore, we will cover each part's routines and a few additional positions that will help you with trauma patients.

### 5-1. The Foot and Toes

As you know, the foot consists of 26 bones: 7 tarsal bones, 5 metatarsal bones, and 14 phalanges. The phalanges, which form the toes, "lead" the body when walking and are set away from the body, making them prone to injury.

#### 236. Explain positioning characteristics pertaining to positions of the toes.

**Positioning of the Toes.** Positions to demonstrate toes usually are AP, oblique, and lateral. Sometimes, depending upon particular structures you want visualized, variations of these positions are necessary.

**AP toes.** Perhaps the easiest position to place the patient in to radiograph toes is AP. This position is also referred to as dorsoplantar (DP) and is used to show a general study of all toes. The accepted procedure requires the patient's plantar surface of the foot placed on the film holder and a perpendicular CR directed to the film through the second metatarsal-phalangeal joint. This simple method will show slight foreshortening of the phalanges and only partial opening of interphalangeal joints.

Because of the natural curvature of toes, to show open interphalangeal joints and phalanges without foreshortening, you need to position the foot in plantodorsal, or angle the CR  $15^\circ$  toward the ankle when using the dorsoplantar projection. The plantodorsal projection is done with the patient prone, and the film and toes elevated on one or two small sandbags. When toes are supported this way and horizontal, the long axis of the phalanges are parallel to the film. Therefore, when you direct a perpendicular CR to the film, the ray will pass through open joint spaces. Figure 5-1 shows the plantodorsal position for toes. Because radiologists readily accept the AP projection for toes, the plantodorsal projection is considered to be an additional projection that is only done on request.

**Oblique toes.** As you know, a plantodorsal projection produces maximum visualization of IP joint spaces. The same holds true when doing an oblique for toes. In this position, have your patient lateral recumbent and turned toward the prone position until the ball of the foot forms a  $30^\circ$  angle with the horizontal. Because of the awkwardness of this position, an AP medial oblique is usually the choice of most radiologists.

In the AP medial oblique, the foot is positioned as for AP toes. Rotate the foot medially so the great toe is closest to the film and the sole of the foot forms a  $45^\circ$  angle with the film. This position best shows the toes on the medial side of the foot with satisfactory demonstration of the toes on the lateral side. An AP lateral oblique gives better detail of the toes on the lateral side because, as compared to the medial oblique, these toes are closest to the film, which reduces object film distance (OFD). OFD also is important with lateral positioning.

**Lateral toes.** A true lateral of the toes involves superimposition of toes on top of each other; this presents a poor demonstration of them. It is best to do a lateral for a particular toe individually. The affected toe is the determining factor that decides how the lateral is best done. For example, if the great toe is injured, a lateromedial lateral places it nearest the film. On the other hand, if the little toe is injured, a mediolateral lateral projection is best to use. You can see how the recommended projection puts the hurt toe as close to the film as possible.

What if the affected toe is either the second, third, or fourth digit? In this case, for maximum detail, it is best to use dental or occlusal film placed between the affected toe and the subadjacent toe. It does not matter if the CR projection is mediolateral or lateromedial as long as tube-part-film alignment is correct. Make sure the patient holds the other toes out of the way, or you may need to tape them out of the way. Direct the CR at right angles to the film through the proximal interphalangeal joint of the digit.

Although all toes can have the lateral projection done with occlusal film, it is common to do all projections—AP, lateral, and oblique—on the same 10 by 12 film. Most radiologists accept the standard AP, lateral, and medial oblique in that way. Regardless of your radiologist's preference, always make sure the ungual tufts point in the same direction for all projections. Do not, for example, reverse the film holder after making one exposure. Doing so will produce two or three projections pointing in different directions. This forces radiologists to turn the film and disrupts their continuity of thought and anatomical orientation.






Figure 5-1 Positioning for the plantodorsal projection of the toes

#### Exercises (236):

1. When positioning for AP toes, why is it advantageous to angle the CR 15° toward the ankle?
2. Which AP oblique is used to demonstrate the great toe?
3. What determines the projection for a lateral view of a toe?
4. Explain why unguis tufts should point in the same direction when two or three positions are on the same film

#### 237. Explain characteristics of positions for the foot and state the positions necessary for various patient situations.

**Positioning of the Foot.** Generally, the foot is demonstrated with three radiographic positions—an AP, a medial oblique, and a lateral—on two 10 by 12 films.

**AP foot.** Like many other positions, the AP view of the foot can be done more than one way; the chosen method is usually determined by your radiologist. One AP view positions the plantar surface of the foot on the film holder so its long axis parallels the midline of the film. The third toe,

foot, ankle, and knee should form a straight line. The CR is angled 15° cephalic (toward the ankle), entering the dorsal surface of the foot at the base of the third metatarsal.

The CR angulation compensates for the natural curvature of the longitudinal arch formed by the long axis of the metatarsals and tarsals. With this method, as shown in figure 5-2, the CR enters the metatarsals at right angle to the longitudinal arch. Therefore, the metatarsals are projected on the film without foreshortening the metatarsal image.

Another way you can get an AP view of the foot is by directing the CR perpendicular to the film while leaving all other positioning factors the same as just covered. In this manner, because the CR is not perpendicular to the longitudinal arch, you project the metatarsals onto the film in a foreshortened image.

Although both methods produce adequate AP views of the foot, the method using the CR perpendicular to the film should be used when a foreign body in the foot is suspected. This enables you to present the radiologist two films at true right angles to each other—one AP and one lateral.

Neither AP method, however, demonstrates all bones of the foot (see fig. 5-3). The talus (astragalus) and calcaneus (os calcis) are not adequately visualized on an AP projection; phalanges, metatarsals, and tarsals anterior to the talus are satisfactorily demonstrated. Because of this reason, the oblique and lateral positions are included in the routine study of the foot.

**Oblique foot.** In most instances, the medial oblique view of the foot is made after the AP. As with the AP position, the patient is supine with the knee flexed enough to place the plantar surface of the foot on the film holder. Then, rotate the patient's foot medially until the sole forms a 30° angle with the film. Some radiologists may request a steeper oblique of 45° instead of 30°. A perpendicular CR is directed to the center of the film.

The medial oblique shows the lateral articulations of the tarsals. In figure 5-3, you can see joint spaces between the cuboid and calcaneus, between the cuboid and fourth and fifth metatarsals, between the cuboid and third cuneiform, and between the talus and navicular. Also, the metatarsals and phalanges are shown in an oblique view. If, however, the medial aspect of the foot and its articulations—between the first and second metatarsals, and between the first and second cuneiforms—are to be demonstrated, your radiologist may request an additional view, the lateral oblique.

The lateral oblique begins exactly as the medial oblique except for the rotation of the foot. In this position, the foot is rotated laterally until the sole forms a 30° angle with the film. The elevated side of the foot, in this case the medial aspect, could be supported with a 30° foam wedge to prevent motion and keep the foot at 30°.

**Lateral foot.** The lateral view can be either a lateromedial projection or mediolateral projection. Usually, it doesn't make any difference which method is done because both projections produce virtually identical radiographic images.

The main points to keep in mind are to keep the plantar surface and CR perpendicular to the film. If the foot should

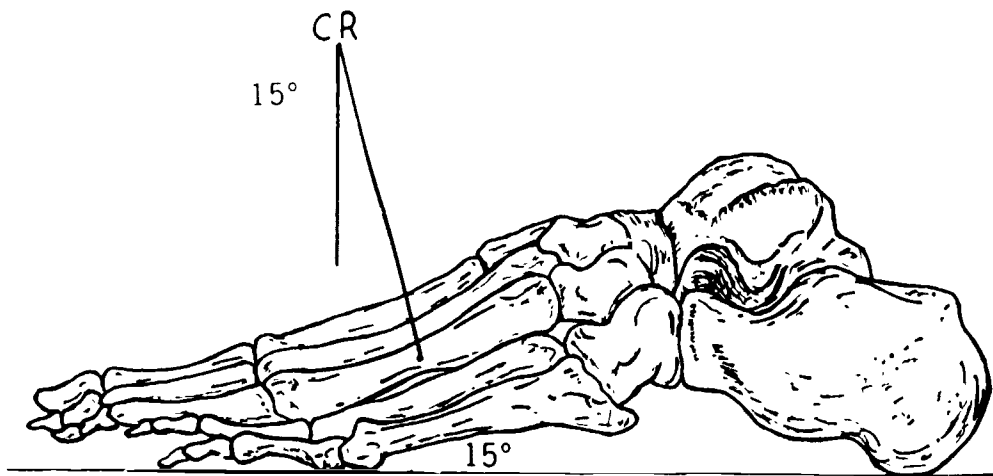


Figure 5-2 Central ray angulation for an AP projection of the foot



Figure 5-3 Radiograph of the foot showing AP and oblique views

rotate from true lateral', a slight oblique image will result. Of course, if the CR is not perpendicular to the film, distortion will result in this case if CR angulation is great.

An additional consideration of foot radiography is technique. The kilovoltage used should be in the 80 (kilovolts peak) range to reduce the difference in subject contrast. This is necessary because of the great difference in part thickness between the tarsus to the toes, especially in the AP and oblique views. This higher kvp technique provides a more uniform radiographic contrast over the range of foot densities. A wedge filter could also be used to compensate for the various thicknesses of the foot.

#### Exercises (237):

1. What is the purpose of angling the CR 15° cephalic for an AP of the foot?
2. An AP foot is done and the metatarsals appear foreshortened. What is the probable cause?
3. Which oblique of the foot is usually taken?
4. Which two views of the foot should be taken if the patient has a foreign object in the foot?
5. Explain why it doesn't make any difference which lateral projection is included in a foot series.
6. Why is the CR perpendicular on a true lateral of the foot?

**238. Given various patient conditions, state necessary additional positions of the foot and explain characteristics of these positions.**

**Additional Positions of the Foot.** You have learned that AP, medial obliques, and lateral are standard positions for

the foot. Although this is true for most studies of the foot, you will find different situations where additional views may add to the standard series, or that these supplemental films may be substituted in place of those routines. Generally, views that deviate from the standard series are necessary to demonstrate either certain structures or because of a particular condition of the patient. Positions to demonstrate the calcaneus and those for weight-bearing feet are examples of additional positions of the foot.

**The calcaneus positions.** Standard projections of the calcaneus are plantodorsal and lateral. The plantodorsal projection requires the patient seated or supine, with the legs fully extended and the ankle centered to the film. Be sure the plantar surface is perpendicular to the film. Angle the CR 40° from vertical and direct it toward the ankle. It should enter the plantar surface at the base of the fifth metacarpal and exit at the center of the film. Figure 5-4 shows the plantodorsal position.

The plantodorsal projection presents a semiaxial view of the calcaneus. However, one view is usually not enough for a complete study. This is why it's necessary to include a lateral view as well.

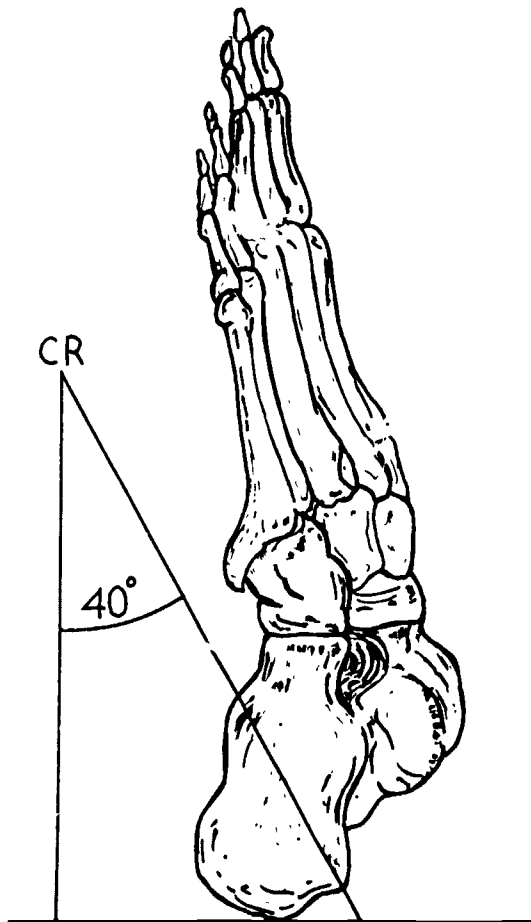


Figure 5-4. The plantodorsal projection of the calcaneus

In the lateral position, the foot is positioned for a mediolateral projection. If the plantar surface isn't perpendicular to the film holder, place a sandbag, a foam wedge, or a folded sheet under the knee. Direct the CR perpendicular to the film through the talocalcaneal joint space.

**Weight-bearing foot.** Weight-bearing projections of the foot are taken to show the relationships between the bones of the foot with the patient standing. The laterals are taken specifically for the longitudinal arch to demonstrate pes cavus (exaggerated height of the arch) and pes planus (lowering of the arch, flat feet).

Your radiologist evaluates these radiographs under the assumption that the patient's weight is evenly distributed on the feet. Consequently, you should keep even weight distribution in mind when you make the radiographs. One way to help ensure equal weight distribution is to stress its importance to the patient. In addition, have the patient remain in the same position for both comparison radiographs. This is no problem for the APs because you can take both feet simultaneously. For the laterals, if you have no commercial or "homemade" bench for this purpose, simply have the patient stand on two items of equal height (books will work nicely). Place two films vertically between the support items and feet with a sheet of protective lead between the films. Using a horizontal CR, expose one foot, swing the tube around, and expose the other.

#### Exercises (238):

1. What positions are necessary to demonstrate an injured heel?
2. What type of view is presented with the plantodorsal projection of the calcaneus?
3. What two positions are necessary on a patient suspected of having flat feet?
4. Why are lateral weight-bearing projections of the foot taken?
5. Specify two ways to help ensure equal weight distribution during radiography of weight-bearing projections of the feet.

## 5-2. The Ankle and Leg

Our coverage of the positional factors associated with the lower extremity continues with the ankle and leg. As you well know, these are sites of frequent injury—sometimes quite serious. This can hinder you in positioning the part for the routine views, resulting in your improvising. Therefore, in this section we will deal with both standard positioning and some alternate ways to produce necessary radiographs.

**239. Explain characteristics of each standard position for the ankle.**

### **Routine Radiographic Considerations of the Ankle.**

Since injuries to the ankle may affect the weight-bearing and locomotive capabilities of the patient, it is imperative that prompt and adequate treatment be given them. One of the very first steps in treating the ankle is to obtain radiographs that are necessary to determine the extent of injury. From these projections, a specific course of action is planned for treating the patient. Needless to say, the radiographs should be the most accurate and detailed possible. To satisfy this requirement, we generally employ the AP, medial oblique, and lateral projections.

**AP ankle.** Place the patient in either the supine or sitting position on the table with the affected leg extended. Place a film holder on the table so that its long axis coincides with the long axis of the leg. Mask one lengthwise half with lead shielding and place the posterior aspect of the ankle on the unmasked half. Position the ankle so that the midpoint of a line between the malleoli is in the center of the unmasked portion of the film. Flex the foot until the sole forms an angle of  $90^\circ$  with the surface of the film. Rotate the foot medially just a bit, until the intermalleolar plane of the ankle is parallel with the film. Direct a perpendicular CR to the anterior surface of the ankle at the midpoint of the intermalleolar line, and thus to the center of the film. Figure 5-5 shows a radiograph of this position.

**Medial oblique ankle.** The medial oblique projection is usually made right after the AP. Again, begin by centering the ankle to the unmasked half of the film as you did with the AP position. The major difference in this position is that the leg is rotated medially  $45^\circ$ . Do not rotate the foot alone. Rotate the entire leg, ankle, and foot. Direct the CR through the ankle joint, perpendicular to the center of the film. Figure 5-6 shows the medial oblique view of the ankle. You can see how well this position demonstrates the mortise between the lateral malleolus and the talus.

**Lateral ankle.** The lateral projection of the ankle is generally made last, and on a separate film. Although a lateromedial projection puts the mortise closer to the film, which minimally improves detail of the joint, the mediolateral projection is usually done because it is easier for the patient to assume the mediolateral position. Therefore, we will cover the mediolateral projection in detail.

The patient is placed in the lateral recumbent position with the affected side down. The ankle is positioned so that the malleoli are superimposed and centered to the film. The patient's foot should be flexed if possible. The CR is



Figure 5-5. Radiograph of an AP projection of an ankle.




Figure 5-6 Radiograph showing the medial oblique view of the ankle

perpendicular to the film, entering the ankle on the medial malleolus. Thus, this is a mediolateral projection. Figure 5-7 demonstrates this position and figure 5-8 shows a lateral ankle radiograph.




Figure 5-7. Positioning for the mediolateral projection of the ankle.




Figure 5-8. Radiograph showing the lateral view of the ankle

Notice that in all the radiographic projections of the ankle, the mortise is seen clearly. The AP demonstrates the horizontal plane and the medial-oblique plane, or that angle formed by the medial malleolus and the medial aspect of the talus with the horizontal plane. The lateral malleolus usually overlies the lateral aspect of the talus, and the lateral-oblique plane of the mortise is somewhat occluded in this projection. Notice, however, how well the lateral-oblique plane is visualized in the medial oblique position of the ankle (again refer to fig. 5-6).

When correctly made, the lateral view demonstrates the articular surfaces of the talus and the tibia, or the joint space. Since the superior surface of the talus is somewhat condyloid, it is imperative that both supralateral eminences

be superimposed. If they are not, then one or the other will be superimposed over the joint space. This fault renders diagnosis of joint pathology or trauma exceedingly difficult. This is why the leg and ankle must be placed in the true lateral position prior to exposure.

Observe, also, that the talus is extremely well visualized in these projections. Because of its superior location, the talus is not seen at all in the AP projection of the foot and is distorted in the medial oblique view. Its lateral aspect is shown in the lateral projection of the foot, but because of the entrance point of the CR, this view too is somewhat distorted. Thus, whenever you are dealing with an injury involving the talus, always include routine views of the ankle. This need of accurate projections accounts for many requests for both ankle and foot views.

Perhaps the most common error made in positioning the ankle for both the AP and the medial oblique is failure to flex the ankle until the plantar surface of the foot is perpendicular to the film. If the joint is extended (the normal relaxed position of the ankle when the patient is sitting or lying on the table), the calcaneus is pulled up and under the lateral malleolus. The resulting superimposition makes interpretation difficult. However, there are times when the patient cannot flex the ankle. When this occurs, angle the CR so that it parallels the plantar surface of the foot.

#### Exercises (239):

1. What are the standard positions for the ankle?
2. What is specifically demonstrated in a medial oblique view of the ankle?
3. Explain why a lateromedial projection improves detail as compared to a mediolateral projection of the ankle.
4. Where does the CR enter for a mediolateral projection of the ankle?
5. Which position of the ankle clearly demonstrates the horizontal plane of the mortise?
6. Explain why an AP ankle should be included with a foot series for injury to the talus.

7. Explain why the foot should be flexed for an AP ankle position.

**240. List injuries that affect the ankle and explain how they affect patient positioning.**

**Special Radiographic Considerations of the Ankle.**

Injuries of the ankle include sprains, strains, dislocations, fractures, and worst of all, fracture dislocations. Strains involve overstretching of some part of the musculature, and sprains are joint injuries in which some supporting ligament fibers are ruptured. They are relatively easy to deal with from the radiographic point of view; whereas, the others are not.

Since we are requested to make diagnostic radiographs of all injuries, we will continue our coverage of ankle positioning by investigating the various methods used to produce radiographs of those injuries. Also, we will look at additional positions (stress positions) of the ankle that are necessary because of certain injuries.

**Strains and sprains.** These are the most common and least serious of the injuries involving the ankle. However, for your radiologist to make a positive diagnosis of strain or sprain, the fracture or dislocation must be ruled out. The most expedient and practical means of doing this is through detailed radiographic examination. Therefore, when you are dealing with a patient whose ankle is swollen and painful, always assume that it is fractured and treat the part accordingly.

Generally, a patient with either a strain or a sprain can, and will, cooperate with you. Even though swelling is usually present, you can use the routine positions. You may need to immobilize the part, because trauma usually produces a certain amount of shock and the patient may not be able to maintain the position without help. So plan on having sandbags, folded hand towels, or sheets available.

Usually, there is no great difficulty with the AP and medial oblique positions. The AP may need to be stabilized with sandbags over the knee and against the sole of the foot. The medial oblique can easily be obtained if you help the patient rotate the entire leg, not just the foot.

The lateral position could be troublesome if there is excessive swelling to the point that it is impossible for you to see either of the malleoli. If this is the case, it may be necessary for you to build up the leg to keep both ankle and leg on the same plane. The use of sandbags and folded sheets not only keep the ankle and leg in the same plane, but also aids in relieving some weight and pressure on the lateral malleolus in the routine lateral position.

Also, if swelling of the malleoli is excessive and this prevents a routine lateral, you may need to do a cross-table lateral. In this position, the patient is supine and the film is placed vertically against either malleolus. A horizontal CR is perpendicular to the film, centered to the malleolus. Building up the ankle with pads may be necessary.

**Fractures, dislocations, and fracture dislocations.**

Injuries of this type are quite serious because they almost

always involve the ankle mortise. When dealing with patients suspected of having one of these injuries, be exceedingly careful in positioning the ankle. Even simple, nondisplaced fractures will produce swelling equal to that produced by a severe sprain and impair recognition of these injuries. Also, rough handling of a patient with a severe fracture could result in crepitus, the grinding produced by bone fragments. The dislocations and fracture dislocations are more readily identifiable because the foot will be unnaturally rotated or extended, producing a gross deformity of foot and ankle.

When no gross deformity is involved, use the routine positions, but be gentle and careful in positioning and handling the part. When dislocation is obvious, however, you must modify your positioning methods. For example, suppose you receive a patient, on a litter, who has sustained a complete dislocation of an ankle. Usually, the patient is lying supine with the affected foot in the lateral position with either the medial or lateral side up. In this situation it is best to leave the patient on the litter, as excessive movement may cause more damage. Simply slide a cassette under the ankle as it is and direct the perpendicular CR to the center. A cross-table lateral projection is probably the only lateral in this situation. Since you are unable to rotate the patient's leg, these two films provide two views at right angles, thereby satisfying the basic precept of radiographic positioning.

Although these injuries often require you to do variations of the routine positions, some injuries are cause for the special stress positions of the ankle.

**Stress positions of the ankle.** AP projections of the ankle joint are made to diagnose a tear of the medial or lateral ligament by showing a widening of the joint space of the side in question. The complete stress series consists of the following projections: A standard AP, and then an AP with forced inversion, and an AP with forced eversion. The ankle must remain in the AP position for the stress studies, and the foot is forcibly turned medially for one projection and laterally for the other. The procedure for turning the foot depends upon your radiologist because the examination may be quite painful. One method is to have another person (other than radiology personnel) hold the foot in position during the exposure. Another method is to have the patient hold his or her foot in position with a traction strap around the ball of the foot. In either case, the ankle must be held in position by some external force.

**Exercises (240):**

1. List the five types of injuries that are common to the ankle.
2. Explain how a severe sprain may affect the lateral position of the ankle.

3. What general appearance of the foot and ankle might suggest a fracture dislocation?
4. Explain why you should be gentle when handling a patient with a severe fracture.
5. What views should you take on a patient with a dislocated ankle? Explain.
6. What views are taken to demonstrate torn ligaments of the ankle?

**241. Indicate correct routine radiographic considerations of the leg.**

**Routine Radiographic Considerations of the Leg.**

Although the tibia provides half the articular surfaces for two major joints and is second only to the femur in length, neither it nor the fibula gives rise to any special radiographic problems. Both bones are routinely demonstrated in two projections, the AP and the lateral. However, certain points concerning these positions should be kept in mind.

The first is that if the adult tibia is too long to enable both projections to show both joints on one film, you need to place the leg diagonally if your radiologist requires both joints. On the other hand, if only one joint is required, the rule of thumb is to include the joint nearest the site of injury. For example, if the distal tibia is injured, include the ankle joint. If the injury is in the proximal half of the tibia, you should include the knee joint.

Another important consideration is to ensure that for the AP view, that the leg is in true AP. And, of course, the lateral view has the leg positioned in true lateral. This is best done by using the tibial condyles during positioning. For example, when an imaginary line through the tibial condyles is parallel with the film's surface, the leg is true AP. The leg is true lateral when the tibial condyles are superimposed; thus, this line is perpendicular to the film.

Finally, as in the case of all the previously mentioned parts of the extremities, detail is of prime importance. Therefore, the smallest focal spot size and the longest focal film distance should be employed to visualize the tibia and fibula. Remember also that since they are projected by divergent beams, neither the ankle nor knee joint spaces will be demonstrated accurately. They are included only as a matter of survey. That is, if the injury proves to be a fracture, then it is necessary to know whether or not it invades any of the articular surfaces. This point will be expanded later in this section. Do not try to use the AP and lateral projections of the leg in lieu of AP and lateral projections of either the knee or ankle.

**Exercises (241):**

Indicate whether the following statements are true (T) or false (F). If you indicate false, explain your answer.

- 1. The joint farthest from the site of injury should always be on the film.
- 2. The knee should be included if the tibial tuberosity is fractured
- 3. The leg is true AP when the tibial condylar plane is perpendicular to the film.
- 4. A large focal spot should be used to include both joints for radiography of the leg.
- 5. The articular surfaces of the leg are accurately projected with the use of the divergent portion of the beam.
- 6. The basic radiographic precept of two films are: right angles require at least one oblique with an AP of the leg.

**242. Explain characteristics of special radiographic considerations of the leg.**

**Special Radiographic Considerations of the Leg.**

Abnormalities involving the leg, with which you will most probably be concerned, may be divided into two groups. The first group includes the general survey examinations under nontraumatic pathologic conditions, such as osteomyelitis, osteogenic tumors, cysts, etc., plus bruises and severe lacerations. The other group includes the fractures—simple greenstick (or complete), complete (but not displaced), transverse, spiral, comminuted, compound, and worst of all, compound-comminuted fractures. We will consider the former group first.

**Group I.** It is relatively easy for you to deal with those conditions named in the first group. The leg may be demonstrated by using the routine positions without difficulty. Thus, your major concerns are true positioning of the leg and use of those technical factors that will produce the best radiographic detail.

As to the first of these concerns, good radiologic practice requires it for all positions involving all body parts. Aside from this, precise locations of cysts and tumors depend

upon precise positioning of the parts. As to the concern for detail, remember that all bones display a trabecular pattern. Very often the early detection of a serious systemic disease may be made by observing the changes in the trabecular pattern of the tibia (sickle cell anemia is an example). Osteogenic tumors and cysts often display a very delicate internal pattern that, when clearly seen, aids in their identification and classification. Therefore, when dealing with patients having conditions of this group, use the routine positions and make sure that they are indeed true APs and true laterals. Also, make sure that you use the correct radiographic technique for maximum detail.

**Group II.** Patients who have sustained the injuries classified in this group are not quite as easily dealt with as those with injuries classified in Group I. As a rule, leg fractures are readily identifiable by swelling and deformity. When handling patients with either of these clinical symptoms, always assume that the leg is fractured and proceed accordingly.

Generally, a patient with a suspected fracture will come to you on a litter with the affected leg elevated on folded sheets, towels, or pillows. The leg may or may not be splinted. When the leg is elevated in this manner, it is easier to make the lateral projection first. After all, the leg has been "built up" for you. Leave the patient on the litter whenever possible, as you want to avoid excessive movement of the part. Place a 14 by 17 cassette lengthwise against the side of the leg. If possible, use sandbags to hold the cassette in position. Direct a horizontal CR through the leg to the center of the film. If there is a severe fracture, this cross-table lateral may be the only lateral position possible since you would not want to place the patient lateral recumbent.

To make the AP view, gently raise the leg slightly until a cassette can be placed under the leg. Remember to support the entire tibia by placing one hand under the knee and the other hand under the ankle. This will help prevent crepitus if a fracture is present. The long axis of the leg should parallel the long axis of the film and the CR enters perpendicularly.

Once again, by using the diagonal length of the film, both joints will be included. Remember, however, that they are projected by divergent beams and, therefore, are not projected accurately. We include them as survey films only. When a fracture invades either joint, the problem of effecting therapeutic treatment is complicated. Fractures of or into these joint spaces are quite serious since they:

- Interrupt the smooth continuity of the articular surface.
- May rupture the synovial membrane of the articulation.
- Must be treated in such a way as to ensure healing that will not leave a roughened articular surface.
- May very well prove to be sites of future osteogenic pathology—such as osteoarthritis.

For these and other reasons, you must demonstrate the joint spaces as accurately as possible. If the fracture of the leg (as seen in the AP and lateral projections of the leg) appears to invade either of the joint spaces, then you must provide at least AP and lateral views of the affected joint. This will

enable accurate visualization of the joint space because the CR will pass through the joint space for both projections.

#### Exercises (242):

1. List five nontraumatic pathologic conditions that could affect the leg.
2. What is the most severe type of fracture to the tibia?
3. If a patient is suspected to have an osteogenic tumor, why is accurate positioning critical?
4. Explain why radiographic detail is important when X-raying the tibia for nontraumatic pathologic conditions.
5. Generally, how are leg fractures readily identifiable if the patient arrives on a litter?
6. How should the leg be positioned so that both joints are projected on the film?
7. When lifting the leg during positioning, why is it important to support both joints?

### 5-3. The Knee and Patella

Injuries to the knee or patella are serious, whether they involve the osseous tissue—as in the case of fractures and dislocations—or the soft tissue surrounding the joint—such as torn ligaments, ruptured menisci, etc. The result of either type of injury, despite the best possible orthopedic treatment, is often an unstable joint. Every effort must be made to produce accurate and sharply detailed radiographs to provide the radiologist and the orthopedic surgeon with as fine a set of films as possible.

#### 243. Explain characteristics of positions for the knee.

**Positions of the Knee.** Radiographs of the knee are, at the minimum, an AP (or PA) and lateral. Often, at least one additional projection—the "tunnel" view—usually is included in the series.

**AP knee.** The AP position, instead of the PA position, is preferred by most radiologists. Even though the PA offers



essentially identical radiographic representation of the knee, the AP position is most often the choice because of patient comfort and the ease of proper positioning and centering.

To properly position the knee for the AP view, ensure the long axis of the leg is centered to the centerline of the table and slightly rotate the entire extremity medially until a line through the epicondyles of the femur is parallel with the film. Center the apex and the CR to the center of the film.

Depending upon which structures you are demonstrating, you may or may not want to angle the CR. For example, if you are radiographing the joint space, tilt the tube so that the central ray will be directed to the joint at an angle of  $5^{\circ}$  to  $7^{\circ}$  toward the head. When the distal end of the femur or the proximal ends of the tibia and fibula are of primary interest, keep the CR perpendicular to the film and joint.

**Lateral knee.** The lateral position is routinely made by having your patient assume the lateral recumbent position with the affected side down. It is very important to have the femoral epicondylar plane perpendicular to the film and the knee flexed. A flexion of  $20^{\circ}$  to  $30^{\circ}$  allows the thigh muscles to relax and shows maximum volume of the joint cavity. To prevent the joint space from being obscured by the magnified shadow of the medial femoral condyle, angle the CR  $5^{\circ}$  cephalic.

Sometimes, especially with a severe trauma patient, you may be unable to do the routine lateral position. When you can't place your patient lateral recumbent, you can still get a good lateral view with the patient supine—the cross-table lateral.

With the cross-table lateral, the cassette is placed vertically against the medial condyle. The lower extremity may be supported on pillows to center the knee to the film. Direct a perpendicular CR horizontally to the center of the film through the joint.

The cross-table lateral has a distinct advantage. Because you are using a horizontal central ray, you are able to demonstrate any fluid levels that may be present. For example, let's say you have a patient who experienced trauma to the knee. The AP and lateral views appear normal. However, a cross-table lateral projection demonstrates a fluid level density. This could indicate a very small fracture of the tibia plateau, which allows fat cells and blood to escape from the bone marrow.

**Oblique knee.** Oblique views are sometimes added to a series at the request of the radiologist. These can be done with the patient supine (AP oblique) or prone (PA oblique). Neither method presents any positioning problems as long as you center the knee, use a perpendicular CR, and rotate the entire extremity until the femoral epicondylar plane is  $45^{\circ}$  to the film's surface.

**Homblad's position.** This position is an additional position of the knee that demonstrates the intercondyloid fossa of the femur and the tibial spines. It is also called the tunnel view.

Place the patient on the table in a kneeling position with the affected knee centered to the film. Keep the leg PA and parallel with the table by having the feet extend over the table's edge. Have your patient lean forward until the femur forms a  $70^{\circ}$  angle with the table surface ( $20^{\circ}$  from vertical)

as shown in figure 5-9. Direct the perpendicular CR through the intercondyloid fossa to the center of the film.

Figure 5-10 shows a view of the Homblad position. Several structures need to be well demonstrated to have a good radiograph. Notice that the tibial plateau is well visualized. The intercondylar eminence, consisting of two bony prominences (tibial spines) that project superiorly from the middle of the tibial plateau, also are well visualized. The rounded intercondyloid fossa should be clearly seen.

**Beclere's position.** When the patient is unable to assume the Homblad position, you can achieve the same results from the Beclere position. Notice in figure 5-11 that the femur and leg form an angle similar to the Homblad position. The film is supported to put it in contact with the posterior part of the knee. The CR is directed at right angles to the long axis of the tibia and through the knee joint.

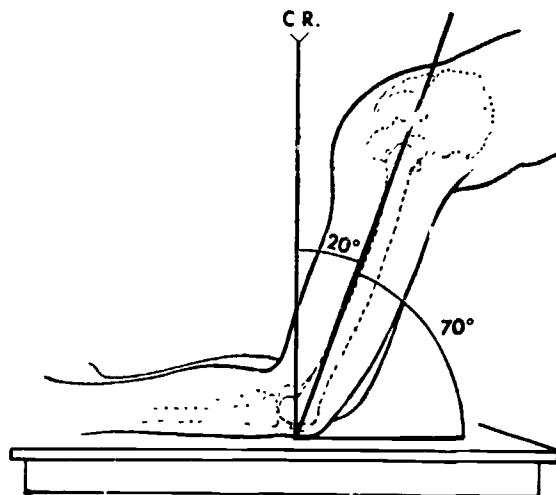


Figure 5-9. Positioning of the Homblad projection of the knee



Figure 5-10 Radiograph showing a Homblad projection.

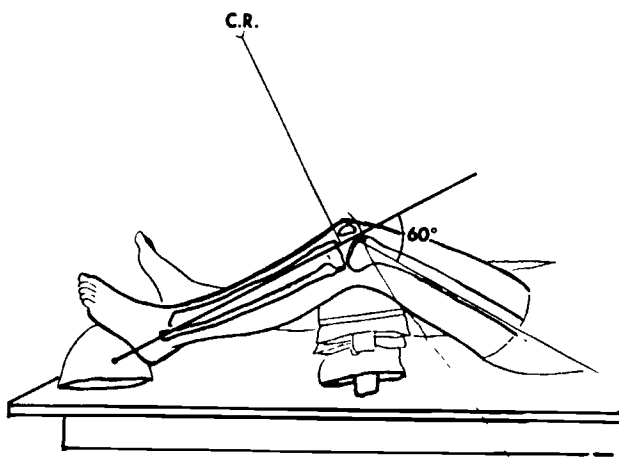


Figure 5-11 Positioning for the Beclere position

#### Exercises (243):

1. Briefly explain what determines whether or not the central ray is angled in the AP position of the knee.
2. How many degrees is the knee flexed for the lateral position of the knee?
3. Explain why the knee is flexed for the lateral position of the knee
4. What is the distinct advantage that a cross-table lateral of the knee might have when compared to the routine lateral?
5. What structures are primarily demonstrated in the tunnel view of the knee?
6. What position for the knee is similar to a reverse Homblad's but still shows the same structures?

#### 244. Indicate correct positions of the patella.

**Positions of the Patella.** The patella usually is demonstrated in three positions: PA, lateral, and Settegast.

**PA patella.** This position, as compared to an AP patella, is preferred because this places the patella closer to the film. Therefore, the reduction in OFD will result in better detail. On the other hand, the PA position may cause a great deal of pain to a patient, especially if the patella had received severe trauma. Careful positioning will prevent discomfort to your patient and allow you to obtain maximum detail.

The PA position of the patella begins with the patient prone on the table with the affected patella centered to the film. Because the weight of the leg overlies the injured patella, you may be subjecting your patient to excruciating pain. You can reduce this pressure by placing sandbags under the thigh and the leg.

After you have provided for your patient's comfort in that manner, you need to ensure that the patella is parallel with the film. You can do this by rotating the heel of the affected leg outward a few degrees.

Finally, direct the CR vertically to the center of the film. Since the femoral condyles overlie the patella, you usually need to increase the energy of the radiation by about 10 kilovolts above a knee technique.

**Lateral patella.** For the lateral position of the patella, the leg is placed in the same way as for the lateral position of the knee. Although the basic positioning is the same, the main difference is that the CR for the lateral patella view is perpendicular to the film. Also, keep in mind that if the patella is fractured (as shown in the PA view), do not adjust the flexion of the knee as much as with the lateral knee position. Instead of 20° to 30°, flex the knee that has a fractured patella only 10°. This will prevent separation of the fracture.

Because the patella is in profile and the CR is perpendicular to the film, the retropatellar space should be well visualized. If this space is obscured by the femoral condyles, then the femur and, therefore, the patella, are somewhat obliqued. This condition could prevent an accurate diagnosis of a fracture.

**Settegast position.** The Settegast position, commonly called the sunrise view, is the axial projection of the patella. It produces an inferosuperior view that is useful in showing vertical fractures of the patella, articulating surfaces of the femoropatellar articulation, and the retropatellar space. Although this view can be obtained with the patient sitting or lateral recumbent, we will cover only the prone position.

With your patient prone on the table, center the patella to the film and slowly flex the knee. The amount of flexion is dependent upon the extent of injury to the patella and directly affects the degree of CR angulation. For example, if the knee is flexed until the leg is perpendicular to the film, the CR should be angled 15° cephalic. If the flexion is increased to form an 80° angle between the tibia and femur (tibia is 10° from vertical), then you need to increase the CR angulation to 30° cephalic. As you can see in figure 5-12,

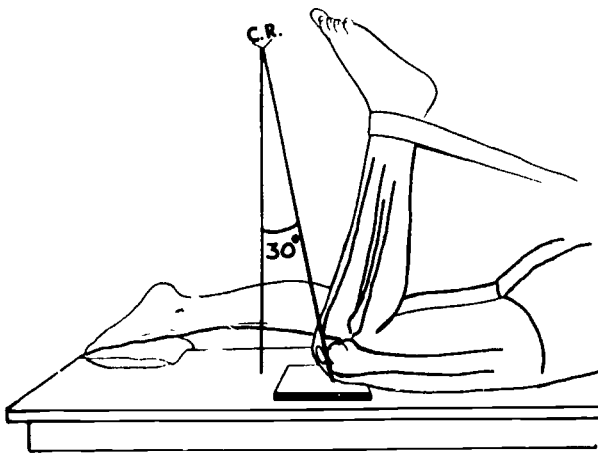


Figure 5-12 Positioning for a Settegast projection of the patella

the angled CR is directed at right angles and through the joint space between the femoral condyles and the patella. Figure 5-13 shows the sunrise view of a patella.

#### Exercises (244):

Indicate whether the following statements are true (T) or false (F). If you indicate false, explain your answer.

- \_\_\_ 1. The patella should be parallel with the film for the PA position.
- \_\_\_ 2. Like the AP knee, the PA position of the patella requires the CR angled 5° to 7° through the joint space.
- \_\_\_ 3. The knee is flexed only 20° to 30° for the lateral projection involving a fractured patella.
- \_\_\_ 4. In the Settegast position, the amount of flexion of the knee is dependent upon the amount of CR angulation.
- \_\_\_ 5. An axial (inferosuperior) view of the patella is produced with the sunrise view.
- \_\_\_ 6. If the tibia and femur form an 80° angle in the Settegast position, the CR should be angled 30° cephalic.

- \_\_\_ 7. The axial projection of the patella is used to demonstrate vertical fractures

#### 5-4. The Femur, Hips, and Pelvis

We continue our coverage of the lower extremity with radiography of the femur, hips, and pelvis. Since these structures are in close proximity with one another, a fracture involving one usually requires radiographs of the adjoining osteology. For instance, a fracture of the proximal femur may invade the hip joint and require radiographs of both the femur and hip, or even the pelvis. For this reason, we include these structures together in this section. We begin with the femur.

#### 245. Explain characteristics of positions for the femur.

**Positions of the Femur.** The femur is usually demonstrated with two radiographs, an AP and a lateral. Slight variations of routine positioning sometimes are necessary because of serious injury to the patient. We will briefly cover important points to remember about each position.

**AP femur.** A good AP film of the femur is not difficult to obtain, providing the technician pays close attention to radiographic basics. The first is proper tube-part-film alignment, which is true of all radiographs. In the case of the femur, tube-part-film alignment is important also because the length of the femur of an adult patient prevents demonstration of the entire femur on one radiograph. Therefore, the rule of including the joint nearest the site of injury is considered with this bone. If the entire femur needs

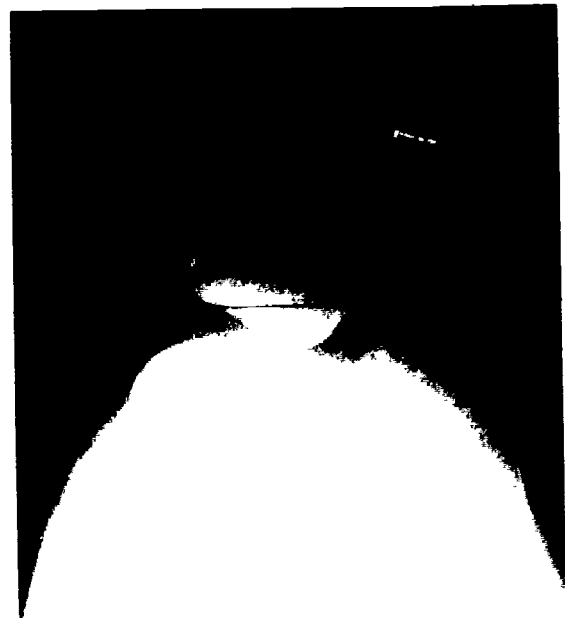

Figure 5-13 Radiograph showing the patella in the Settegast position

to be seen radiographically, then two AP films are necessary: one of the proximal portion with the hip and one of the distal portion with the knee.

Regardless whether or not one or two AP films are taken, you should ensure that the femur is true AP. This is done by rotating the entire extremity inward (medially) until the femoral epicondylar plane is parallel with the surface of the film. Even though your attention is directed at the distal end of the femur, this medial rotation also puts the hip joint in true AP. Do not attempt to rotate into true AP a femur suspected of being fractured. The femoral artery lies close to the femur and could be severed by jagged ends of broken bone. If this should happen, the patient could bleed to death. After the part is carefully positioned, direct your attention to the tube and film alignment.

The CR must be perpendicular to the center of the film. And, because of the varying thickness of the part, the tube should be positioned with the cathode over the upper thigh and the anode toward the knee end of the femur. This will use the "anode-heel effect" to your advantage and direct more of the primary radiation to the thickest part.

Also because of part thickness, the film cassette should be placed in the Bucky tray. This will cause secondary and scattered radiation to be absorbed by the grid in the table. Thus, the radiograph's quality is enhanced. However, if you are unable to move a severely injured patient from the litter to the X-ray table, use a cassette with a built-in grid directly under the patient's leg.

**Lateral femur.** The problem with the length of the femur also affects lateral positioning. For that reason, there are two ways of patient positioning for the basic lateral view, both dependent upon the site of injury. The first concerns viewing the distal part of the femur.

When the area of interest is distal, place the patient lateral recumbent with the affected femur on the midline of the table and the other leg drawn forward over the upper thigh, as shown in figure 5-14. This obscures the uppermost portion of the affected femur but presents the distal two-thirds without superimposition. The affected femur is lateral when the epicondylar plane is perpendicular to the film. Flex the knee slightly and direct the vertical CR to the center of the film.



Figure 5-14. Positioning for a lateral view of the distal femur

You need to vary the placement of the unaffected femur when injury of the affected femur extends to the hip area. You can prevent superimposition of the hip area by positioning the unaffected thigh behind the femur you are X-raying. Notice in figure 5-15 how the lower extremities are positioned. Sometimes this method causes you to adjust your patient's pelvis by rotating it backward just enough to prevent superimposition of the hips. Usually 10° to 15° will accomplish this without deviating too much from true lateral.

There are times that you should not, by any means, use the lateral recumbent position. When there is a fracture demonstrated with the AP view or suspected because of gross deformity and pain, do not attempt to use the routine lateral position. Instead, you should take all precautions to prevent additional injury to your patient. It is best to put a cassette vertically along the medial or lateral side of the thigh and direct a horizontal CR to the film's center. This cross-table lateral is useful for demonstrating the lower two-thirds of the femur.

If a femur fracture involves the femoral neck, you most certainly will need to include one of the special views for that area—the Danelius-Miller projection or the Johnson position.

**Danelius-Miller position.** This position should be included anytime a fracture of the femur involves the femoral head, neck, or trochanters. And since the Bucky is not used, this position can be obtained in the patient's bed on the ward, on a litter, or on the radiographic table.

The patient needs to be supine. The unaffected lower extremity is flexed to make way for the primary beam (see fig. 5-16). Place a cassette vertically with its upper border in contact with the patient at the level of the iliac crest. Angle the lower border away from the patient until the film is parallel with the femoral neck (fig. 5-17). Support the cassette with sandbags. Because of the body thickness that the CR will pass through, you should use a grid cassette. Angle the horizontal CR through the femoral neck so that the CR is perpendicular to the film, as shown in figure 5-17.

When performing the Danelius-Miller projection, keep in mind certain key points: (1) Do not rotate or otherwise move the patient's leg—it could aggravate the injury, (2) use a small cone field and a grid cassette to reduce film fog, and (3) make sure the film is in the vertical position.



Figure 5-15 Positioning for a lateral view of the proximal femus.



Figure 5-16 Positioning for the Danelius-Miller projection

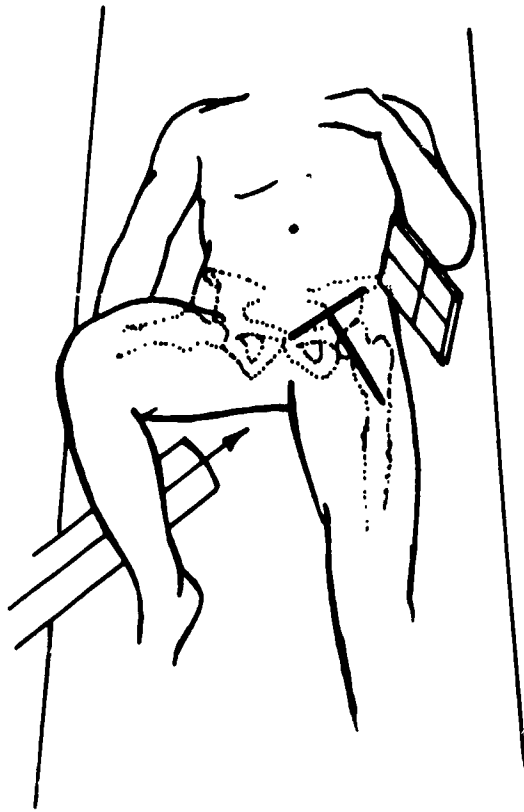


Figure 5-17 Tube-part-film alignment for the Danelius-Miller projection

**Johnson position.** The Johnson position presents a radiograph similar to the Danelius-Miller; it can usually be used in lieu of the Danelius-Miller. The patient is supine and a vertical cassette is placed aside the hip, parallel to the midline of the body. Tilt the top of the cassette away from the body  $25^\circ$ , as seen in figure 5-18, and press it flush against the patient. The CR is aligned perpendicular to the cassette, then angled  $25^\circ$  cephalad to the center of the film.

As with all radiographic positioning of the femur—and the hip and pelvis, as well—protect your patient from unnecessary radiation exposure to the gonads. Shield the testes or ovaries from the primary beam whenever possible. Use of the lead-impregnated contact shield is very good for this purpose. Although radiation protection is very important, you defeat its purpose if the shield superimposes structures you are trying to demonstrate, causing you to repeat the radiograph. Therefore, use shielding carefully.

**Exercises (245):**

1. Explain why it is sometimes necessary to do two AP films of a femur.
2. How is it determined that a femur is in true AP position?
3. Why should you not attempt to rotate a femur that may be fractured?
4. How do you use the anode-heel effect to your advantage for the AP film of the femur? Why?
5. For radiography of the femur, why should the film be placed in the Bucky tray?
6. When positioning for the routine lateral of the proximal femur, why is the pelvis rotated backward  $10^\circ$  to  $15^\circ$ ?

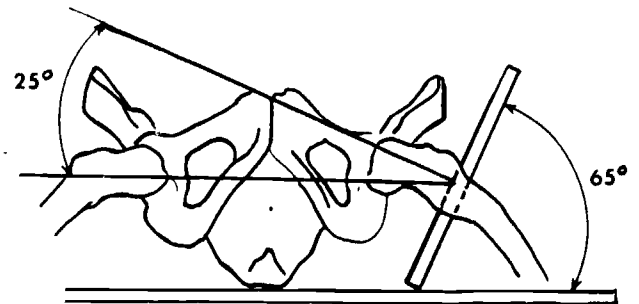


Figure 5-18 Tube-part-film alignment for the Johnson position of the femoral head and neck

7. Generally, what prevents you from positioning your patient lateral recumbent from the routine lateral view of the femur?
8. If a patient has a confirmed fracture 2 inches superior to the femoral condyles, how should a lateral view be obtained?
9. When should a Danelius-Miller radiograph be included in the femur series?
10. In the Danelius-Miller position, why should you angle the lower border of the cassette away from the patient?
11. How is the central ray directed to the film for the Danelius-Miller position?
12. What position produces a radiographic image similar to the Danelius-Miller?
13. How many degrees is the top of the cassette tilted away from the patient in the Johnson position?
14. Briefly explain the central ray placement for Johnson's position of the femur
15. What structures are shielded during radiography of the femur?

**246. State characteristics for positions of the hip and the pelvis.**

**Positions of the Hip.** Routine views to demonstrate the hip are AP and lateral. Some departments vary these requested positions to possibly include an AP pelvis or "frogleg" lateral.

**AP hip.** While the AP projection of the hip joint is generally not difficult to perform, projecting the joint into a small field can be a problem if you cannot locate the joint. There are at least two ways to pinpoint the head of the femur. One way is to visualize a transverse plane through

the most superior point of the greater trochanter and a sagittal plane 2 inches medial to the ASIS. They will intersect at the head of the femur, as shown in figure 5-19. You can also locate the head of the femur by drawing an imaginary line between the ASIS and the upper margin of the symphysis pubis. The head of the femur is 1 inch along another imaginary line that is perpendicular to and bisects the first line, as shown in figure 5-20.

For the AP view, have your patient supine with the affected hip joint over the midline of the table, and centered to the film and Bucky. Remember to use one of the procedures we just covered to locate the head of the femur. Place the hip in true AP by rotating the leg medially until the femoral epicondylar plane is parallel with the film. Avoid any movement of the femur if a fracture of the affected area is suspected. The CR is directed through the femoral head to the center of the film.

The resultant radiograph, figure 5-21, demonstrates the proximal portion of the femur—most importantly, the neck and head—and the inferior, lateral aspect of the pelvis—most importantly, the acetabulum.

When both hips are required, they are usually demonstrated on the same film by positioning the patient for an AP of the pelvis. Sometimes, this is routine with children or adults when comparison studies are requested. In this case, your radiologist may ask that you center the CR at the midpoint between the hip joints.

Regardless whether or not the request is for one hip or both, whenever possible, always use proper patient protection. Shielding gonads is an effective means of protection from the primary beam.

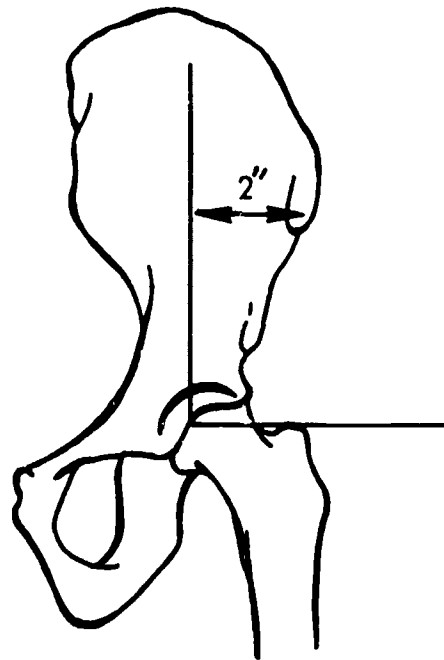


Figure 5-19 Location of the hip joint

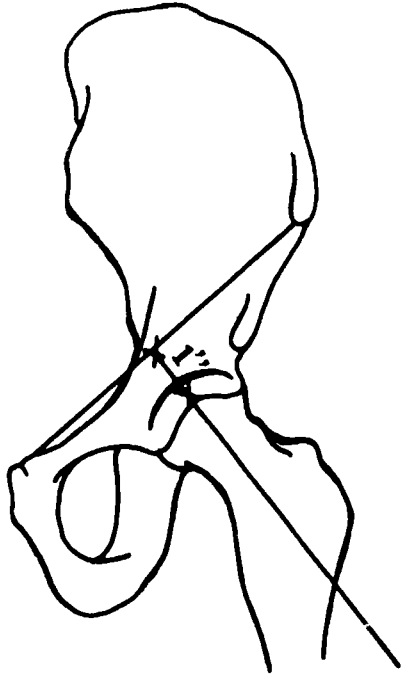


Figure 5-20 Location of the hip joint




Figure 5-21 Radiograph showing an AP view of a hip joint

**Lateral hip.** The lateral view can be obtained more than one way. A common method to get a lateral view of a hip is by performing a position that is similar to a frogleg lateral of only the affected side. This position begins as an AP of the hip but with the hip and knee slightly flexed. Notice in figure 5-22 how the lateral side of the affected extremity is placed on the table and the hip is centered to the film. It may be necessary to roll the unaffected side of the pelvis a few degrees off the surface of the table to place the lateral side of the affected thigh on the table. The CR is



Figure 5-22 Positioning for a lateral view of a hip joint.

perpendicular to the film. This position is the most widely used, providing there is no serious injury to the hip structures.

On the other hand, if serious traumatic injury resulting in a fracture involving the hip joint caused your patient to need X-rays, you should avoid movement of the affected extremity. Use the Danelius-Miller position to get the lateral view. If there is some positioning problem that prevents the use of the Danelius-Miller projection, you can still get an acceptable lateral view with the Johnson position. Both of these positions were covered in the preceding section.

All these positions for the lateral view of the hip thus far covered deal with radiographing an individual hip. There is a position commonly used when both hips are required to be visualized. In this case, you should use the bilateral frogleg, or frog position. Although its proper name is the Cleaves position, it is almost always referred to as the frogleg position.

The frogleg position begins with the patient supine and centered to the midline of the table. Notice that the thighs are abducted in figure 5-23 and that the soles of the feet are in contact with each other. The thighs should be abducted at least  $40^\circ$  from vertical. The central ray is supposed to be angled  $10^\circ$  cephalic; however, in actual practice, most radiologists prefer the CR perpendicular to the film and centered to a point between the femoral heads.

**Positioning for the Pelvis.** Unless an additional film is requested by your radiologist—a lateral view—a general survey study of the pelvis requires only an AP. The patient is positioned to ensure that there is no rotation of the pelvis. An easy way to check for rotation is to measure the distance from the ASIS to the tabletop on each side of the pelvis. Correct any rotation by using foam cushions to raise the side that is low. Center the pelvis to the film and direct the vertical CR to the midpoint of the film.

There are, however, other positions used to demonstrate a specific portion of the pelvis. Some of these are the PA for the anterior pelvis bones (pubic and ischial bones), acetabulum views, and the obliques for the ilium. Since the



additional pelvic views are seldom, if ever, requested, we will not explain them in this course

**Exercises (246):**

1. What are the two routine views that demonstrate the hip?
2. What are the three most important structures visualized on the AP view of the hip?
3. When both hips are required on the same film, where is the central ray located?

Which is the first position you should use to obtain a lateral view of a fractured left hip?

What position demonstrates both hips in the lateral position at the same time?

Which hip position calls for the central ray to be angled 10° cephalic?

How can you check for rotation of the pelvis in the AP position?

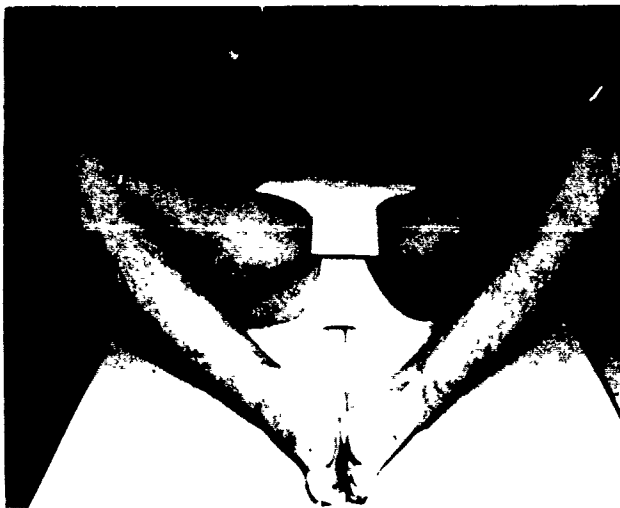

Figure 5-23 Positioning for the Cleaves (frogleg) position to demonstrate bilateral hip joints

8. What additional pelvis position produces an anterior view of the pubis and ischium?



## Positioning of the Chest and Abdomen

OF ALL THE radiographic examinations performed in your department, none are done more frequently than those of the chest and abdomen. This shouldn't be too surprising since they are survey films to a great degree. In a great many instances, they are scout films for special studies, whether the study is a relatively common intravenous pyelogram (I.V.P.), or a heart catheterization procedure.

Also in this chapter, we will cover positions for the bony thorax—ribs and sternum. This is because when trauma affects the chest, often rib films are requested.

### 6-1. The Chest

We will cover routine positions and the more common additional positions for the chest. In this section, emphasis will be on quality control.

**247. Evaluate selected PA chest radiographs or positions and state whether or not they are properly positioned; if not, recommend corrective action.**

**PA Chest.** The PA chest is no doubt performed more often than any other single radiograph. You perform them on many patients who are well, for example, as part of a routine physical. Because you perform so many and because some patients are not ill, you may become complacent in doing this examination.

We assume you already know the proper procedure for performing a chest examination, as most radiology students usually begin their radiographic experience with chest films. Therefore, we will concentrate on quality control. You must be able to evaluate the radiograph and determine whether it was properly done while keeping in mind certain principles.

**Breathing instructions.** Chest X-rays are usually done for lungs, and when these structures are of prime interest, the exposure should be made at the end of full inhalation (inspiration). Don't request your patient to inhale to the point of strain. It is better to have your patient take a second breath since this allows more air into the lungs without causing the patient to strain. This fact can be used to your advantage with large or obese patients.

If you have a patient with a possible pneumothorax, you should take two PA chest films; one made with full inspiration, and the second made with full expiration (exhalation). The exhalation film may demonstrate small amounts of air that might be obscured on the inhalation film. Inhalation and expiration are also used to show the amount of displacement of the diaphragm and are sometimes used to visualize foreign bodies in the thorax.

Exposures for heart size should be made at the end of normal inhalation. Strained inhalation may force the diaphragm downward too much and result in an elongated heart image.

**Technical procedures.** Technical procedures, that is, the exposure factors and accessories used for getting chest films, depend upon radiographic characteristics of its pathology. For instance, if lungs are normally aerated, you can get satisfactory films with a non-Bucky technique, except for obese patients. Exposure factors, mAs and kVp, should be set to obtain sharply defined pulmonary markings from the hilus to the periphery (outer borders of the lungs). If your kVp factor is too low, short-scale contrast becomes evident. This is indicated by a chalky appearance of the film that obscures the finer lung markings, especially near the periphery.

Exposure time and focal-film distance (FFD) also have importance. Exposure time should be one-tenth of a second or less to overcome heart motion. Some of this heart motion vibrates against adjacent lung tissue, producing some isolated blurring. The FFD should be 72 inches to minimize magnification of the heart shadow and to increase detail of delicate lung markings.

Sometimes it is necessary to use a Potter-Bucky or a stationary grid technique—when the patient is rather large chested or obese, for example. Also, if there is an opaque area of a lung to be better visualized or thickened pleural membranes, a grid technique is recommended. Pneumonia, pleural effusion, tumors, or cancer may require grid technique, though not all the time. Emphysema, on the other hand, requires a decrease of technique because of the inflation and condition of the lungs.

**Position of the shoulders.** One of the most common errors made in performing the PA chest is failure to rotate, roll, or push the patient's shoulders far enough forward. To obtain maximum rotation, the back of the patient's hands should be placed on the waist. Try this experiment; place the palms of your hands on your waist and roll your shoulders forward as far as possible; then simply turn your hands over so the back of your hands are on your waist. Notice how much more your shoulders roll. By doing the exam in this manner, the scapulae are almost totally removed from the lung fields. This results in a radiograph that yields more unobscured information.

Some technicians feel, if an AP projection is made of the chest, as during a bedside examination, it is not necessary to consider the scapulae. This is not true. If the patient's condition permits, the shoulders should be rolled forward just as on the PA projection.

**Rotation.** Another common error made is failing to position the patient with both shoulders against the film. If

the patient is rotated, some structures are hidden, some are distorted, and the true relationship between structures is not maintained.

To check for rotation, when viewing a radiograph, start with the sternoclavicular joints. They should appear the same. Rotation usually produces an asymmetrical appearance. In addition, one of the joints may be obscured by the spine. When this is the case, it is easy to determine the direction of the rotation. If the right joint is obscured, the patient's left side is rotated away from the film. To reduce the likelihood of this happening, both shoulders should be touching the film and *the hips not rotated*.

The location of the spinous processes of the vertebrae can also be used to check the rotation of the chest. Normally, they should appear in the center of the vertebrae. Since the processes are located on the posterior surfaces of the vertebrae, they move in the opposite direction of the rotation. Be sure to check several continuous vertebrae. The deviation of a single spinous process is not uncommon in a properly positioned chest.

Locating the heart shadow with respect to the spine is another factor that can show patient rotation on a PA chest. Normally, the right border of the heart, the right atrium, lies slightly to the right of the spine on the PA projection. If you can see the right spinal border without the heart superimposed, it can be an indication of chest rotation toward the left side. This is easy to understand if you visualize the heart located in the anterior chest and imagine rotating the chest into a slightly right-anterior oblique position. The heart obviously moves toward the patient's left side.

**Inspiration.** The number of ribs visualized above the diaphragm indicates the degree of inspiration by the patient during exposure. Some radiologists like to count anterior ribs, while others count posterior ribs. In either case, count them in the right hemithorax. Also, the particular portion of the rib must be entirely above the diaphragm.

When you count posterior ribs, be careful when you begin the count. The tendency is to miss the first rib and begin with the second. Most radiologists require nine posterior ribs or six anterior ribs as proof of a full inspiration chest.

Generally, problems with full inspiration chest films on adults are limited to obese patients. If they are allowed to inspire twice before the exposure, with the film made on the second inspiration, the degree of inspiration is usually greater.

Figure 6-1 shows a PA chest film. Notice that with proper inspiration, the film shows the proper number of ribs. Also, the use of correct exposure factors enables the delicate lung markings to be visualized.

#### Exercises (247):

1. A PA radiograph of the chest shows dense nonpathological shadows superimposed over the superolateral lung fields. What is the probable cause of the shadows?

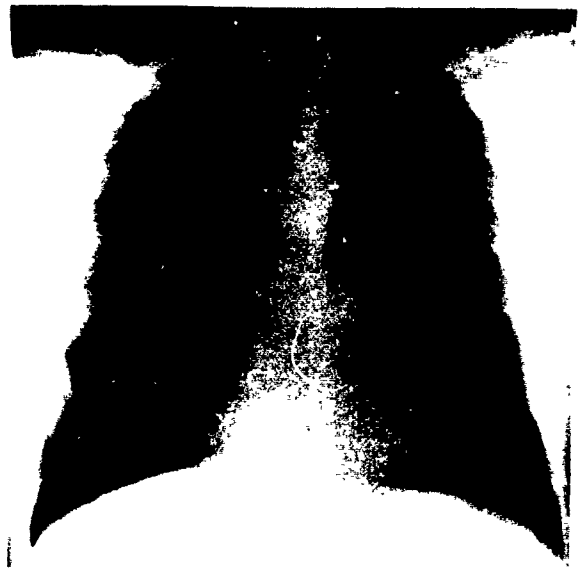

Figure 6-1 PA chest radiograph.

2. The right sternoclavicular joint on a PA chest radiograph is projected to the right of the spine. The left sternoclavicular spine is not visualized. Does this chest appearance indicate improper positioning? If so, how should the position be corrected?
3. A PA chest radiograph shows a symmetrical appearance of the sternoclavicular joints. Is the chest properly positioned? If not, how should the position be corrected?
4. A PA chest radiograph shows the spinous processes of T1 through T7 shifted to the left. Specifically, what does the shift indicate? How should it be corrected?
5. The right border of the thoracic spine is clearly seen without the superimposition of the heart on a PA radiograph of the chest. Does this indicate rotation? If so, how should the position be changed to correct the rotation?
6. A PA radiograph of the chest shows eight posterior ribs projected above the diaphragm. Is this a good inspiratory film? If not, how many posterior ribs should be seen?

7. A PA radiograph of the chest shows five anterior ribs above the diaphragm. Is this a good inspiratory film? If not, how many anterior ribs should be seen?
8. A PA chest radiograph on a patient for heart size measurement shows 10 posterior ribs. Is this a good film in this situation? If not, why?
9. A PA chest radiograph exhibits a chalky appearance, especially near the outer edges of the lungs. Explain the technical error that causes this problem.
10. Excessive heart motion is observed on a PA chest radiograph. What could the technician do to correct this problem?

**248. Indicate correct lateral and oblique positions and projections of the chest.**

**Lateral Chest.** The lateral chest position, when used with the PA radiograph, completes the routine chest series. Some of the problems that affect the PA positioning also affects the lateral view. In addition to those already covered, a problem associated with the lateral chest film is an apparent underexposure of the upper lung fields.

The underexposure to the upper lung fields is generally not caused by radiographic technique. (If it were, wouldn't you have corrected the technique chart?). Usually, it's caused by failure to raise the patient's arms high enough. The proper height can be attained by folding the raised arms over the head. This not only raises the shoulders to a maximum but also tends to steady the patient, thereby reducing the possibility of motion.

Furthermore, the side of the body that is against the film for the lateral position is determined by the radiologist or, for specific pathology, the requesting physician. The left lateral position, left side nearest the film, is routine because it places the heart closer to the film, thereby reducing magnification of the heart. However, if pathology, such as pneumothorax or pneumonia, affects the right lung, then the right lateral should be included because this places the right lung nearest the film.

**Anterior Obliques.** The right anterior oblique is positioned correctly when the patient is obliqued 45°. As with the lateral, the arms should be folded over the head. This provides maximum removal of the scapulae from the lung fields.

The reason for obliquing the patient is to move the spine away from the heart so it can be seen without superimposition over the spine. Since most of the heart lies in the left half of the thoracic cage, the left anterior oblique

requires more obliquity than the right. Therefore, the patient is turned 55° to 70° away from the film for the left anterior oblique. The projections derived from these positions are used extensively, but not exclusively, for determining the size and configuration of the heart, as in cardiac series (esophagram). The esophagus passes in close proximity to the descending aorta, pulmonary vessels, and posterior cardiac structures. Changes in the course of the esophagus could indicate cardiovascular problems. Accurate measurements and determinations are dependent on accurate projections. It is a simple matter to make an angle board that everyone can use, thereby producing consistent results.

One final point pertaining to all chest projections is radiation protection. No doubt you use abdominal shielding for children and on women who are pregnant or suspected of being pregnant. This same shielding, along with close collimation, should be used on all patients regardless of age or condition.

**Exercises (248):**

Indicate whether the following statements are true (T) or false (F). If you indicate false explain your answer.

- 1. The upper lung field on a lateral chest appears underexposed. This was probably caused by faulty radiographic techniques.
- 2. The correct obliquity for a left anterior oblique position of the chest is 55° to 70°.
- 3. Radiation protection devices need only be used on children and pregnant women.
- 4. The right anterior oblique position is obliqued more than the left anterior oblique.

**249. Explain characteristics pertaining to lateral decubitus, AP lordotic, and portable AP radiographs of the chest.**

**Additional Positions of the Chest.** As you recall, the PA and lateral chest radiographs are the routine. Occasionally, oblique positions may be included upon request. For special instances, certain chest positions are necessary. Among these are lateral decubitus and apical lordotic positions.

**Lateral decubitus.** The lateral decubitus position of the chest is a frontal projection that demonstrates a change in fluid position and reveals previously obscured lung areas, or the presence of any free air, as in the case of a suspected pneumothorax. It can be done as either a right or left lateral decubitus; regardless, the basic procedures are the same.

The patient should be in a lateral recumbent position and facing a film cassette, which is placed vertically against the chest (see fig. 6-2). The body should be raised off the table by placing radiolucent pads under the thorax. This important step ensures demonstration of the entire costophrenic angle of the lung that is down. This is extremely important when fluid levels are present. The CR is directed horizontally through the fourth thoracic vertebrae to the center of the film.

Certain points should be kept in mind when performing a lateral decubitus position. The first is terminology: the lateral decubitus position is referred to by which side is down (the side of the thorax that is closest to the table). For example, a right lateral decubitus position will have the right side of the chest down, or closer to the table. You should always place the appropriate right or left marker on the side of the film that corresponds with the side of the chest that is up (away from the table). Properly marking the film aids in orientation for your radiologist and enables proper viewing of the radiograph.

Another point to remember is how to determine which lateral to perform. Usually, this is spelled out for you on the X-ray form by the requesting physician. However, if the request does not specify which lateral decubitus, you can determine the correct position by reading the clinical history, that is, the reason the radiograph was requested. For instance, if there is a presence of fluid in the chest cavity, it is best to place the affected side down. This allows collected fluid to be demonstrated at the costophrenic angle. In this case, if you had the affected lung up, the fluid would collect along the medial border of the lung and would be obscured by the vertebral bodies. On the other hand, if free air in the thorax is suspected, it is best to have the affected side up. This allows the free air to rise and be clearly visible without superimpositioning of vertebrae.

**AP lordotic projection.** This position, also specially requested, demonstrates a specific portion of the lungs—the apices—and is commonly called the apical lordotic position.

Begin by having your patient standing AP against a vertical film holder. The patient moves forward about 12 inches, flexes the knees, and arches the lumbar area into acute lordosis until the coronal plane forms a 45° angle with the plane of the film (see fig. 6-3). With the scapulae against the film and hands on the waist, rotate shoulders and elbows forward. This particular maneuver pulls the scapulae laterally, thus, removing them from superimposition of the apices. The horizontal CR directed to the center of the film with the body positioned in this manner projects the clavicles above lung fields.

**Portable AP chest.** Portable radiography usually is not held in high regard by most x-ray technologists. This may be because technician errors often cause the film to be repeated. This need not be the case if you follow the procedures you use for chest radiography inside the exposure room. For example, ensure CR is perpendicular to the film. A sitting erect or semierect AP chest radiograph is preferred over a supine film. Three reasons are given for this: the diaphragm is usually lower on inspiration with the patient sitting instead of supine, fluid levels that may be



Figure 6-2. Positioning for a lateral decubitus of the chest.



Figure 6-3 Positioning for an AP lordotic projection

present can be demonstrated, and a longer FFD (preferably 72 inches) can be used.

Furthermore, the patient should be measured so the correct exposure factors can be used. If the recommended 72-inch FFD can not be obtained, use the mAs-FFD relationship to adjust the technique. Needless to say, proper radiation protection procedures need to be used.

As we stated before, if the patient's condition permits, the shoulders should be rolled forward. As in the routine PA chest film, rolling the shoulders forward removes the scapulae from the lung fields.

### Exercises (249):

1. Which lateral decubitus position should be used to demonstrate a right lung pneumothorax? Why?
2. Which lateral decubitus position should be used to demonstrate a left lung pleural effusion? Why?
3. Why should a radiolucent pad be used when positioning for a lateral decubitus to demonstrate pleural effusions?
4. Which side of the chest is up in a right lateral decubitus position?
5. Which side of a lateral decubitus chest film should be identified?
6. Explain why you should not perform a left lateral decubitus position to demonstrate fluid levels in the right lung.
7. Which side of the chest should be up when positioning a lateral decubitus if free air in the thorax is suspected?
8. Which specific anatomy is demonstrated in the AP lordotic position of the chest?
9. Where should the clavicles be projected in a properly positioned AP lordotic position of the chest?
10. Why should you measure the patient when performing portable chest radiography?
11. What should the FFD be for portable chest radiography?
12. What is the advantage of rolling the shoulders forward when positioning for a portable AP chest film?
13. List three reasons why a sitting erect portable AP chest film is preferred instead of a supine radiograph.

### 6-2. Bones of the Thorax

Bones of the thorax consist of the sternum and ribs. As you already know, they serve to protect the thoracic viscera, primarily the heart and lungs. Occasionally, pathogenic changes or trauma cause the patient to enter a radiology department for views that specifically demonstrate these bones. In this section, we will cover projections for ribs, the sternum, and related joint structures.

**250. Explain characteristics of positioning for the ribs and evaluate trauma patients by choosing positions that best demonstrate injured ribs.**

**The Ribs.** Fractures provide the chief reason for radiography of the ribs. In some cases, fracture fragments may protrude into the pleura and lungs, causing severe complications. Also, the ribs may be the site of tumors, osteomyelitis, tuberculosis, and other conditions. Regardless of the reason for the X-ray request, certain considerations are to be kept in mind.

**The ribs in relation to the diaphragm.** The diaphragm plays an important part in rib positioning. The lower ribs partly surround the diaphragm and upper abdominal contents, while the upper ribs surround the heart and lungs. Because of the markedly different densities of these two areas, ribs are classified into two groups for purposes of positioning: (1) those that are projected above the diaphragm—pairs 1–8; and (2) those that are projected below (or through) the diaphragm—pairs 9–12.

Three factors affect the position of the diaphragm: (1) the body build; (2) the position of the patient, and (3) the phase of respiration. The diaphragm is low in the abdomen for thin patients, whereas it is higher with patients who are large or obese. If the patient is standing, the diaphragm is lower than if the patient is supine. And, finally, deep inspiration forces the diaphragm to its lowest point.

Therefore, ribs above the diaphragm are examined with the patient erect, whenever possible, and the exposure is made after full inspiration is suspended. These two procedures will place the diaphragm as low as possible, allowing a more uniform background density for the upper ribs.

Ribs below the diaphragm are examined with the patient recumbent on the X-ray table, whenever possible, and the exposure is made after expiration is suspended. These steps release pressure on the diaphragm, allowing it to rise to a higher level. This makes it possible for the lower ribs to be

radiographed against a uniform background of abdominal contents.

**Radiographic technique considerations.** Because of the difference in background densities of upper ribs as compared to lower ribs, radiographic technique factors that you choose are somewhat determined by the location of the rib in relation to it being above or below the diaphragm. Generally, because ribs are relatively thin and flat, low kVp should be used to prevent overpenetration of the rib. A technique of low kVp-high mAs produces the desirable short-scale contrast that is necessary for optimum visualization of rib structures. Kilovoltage less than that for a standard PA chest radiograph is usually sufficient for upper ribs. Since structure density is increased below the diaphragm, an increase of kVp (as compared to ribs above the diaphragm) is necessary for adequate penetration.

**Positions of the Ribs.** As you already know, the diaphragm plays an important part in rib positioning because of its effect on background density, radiographic technique, and breathing instructions. Furthermore, the location of the affected rib, with respect to the diaphragm, determines the combination of radiographs that should be made.

Regardless of the type of rib injury or disease or the area involved, it is recommended that routine PA and lateral chest projections be included with rib films. This is especially important with trauma patients because of the possibility of pneumothorax. Once the chest films are examined for gross injuries, you can proceed with rib films as determined by the area of interest.

As usual, rib radiographs are determined not only by site of injury, but also your radiologist's preferences. However, most departments use the same routine positions based on whether or not the affected ribs are anterior or posterior, and if they are above or below the diaphragm. For example, if anterior ribs above the diaphragm are injured, you should do a PA ribs and an anterior oblique (PA oblique) of the affected side with the patient erect and the exposure taken on suspended full inspiration. If the posterior ribs above the diaphragm are injured or affected by pathology, take an AP ribs and a posterior oblique (AP oblique) of the affected side with the patient erect and taken on full inspiration. When ribs below the diaphragm are the area of interest, whether anterior or posterior, always take an AP ribs and a posterior oblique of the affected side. Remember, for these ribs below the diaphragm, the patient should be recumbent and the exposure taken on suspended expiration.

The AP or PA rib film offers no difficulty for the X-ray technician. On the other hand, deciding which oblique to position for has been confusing at times. The key points to remember are to attempt to get the affected ribs nearest to the film and not have the vertebral column superimposing them. The latter part is most important when only one oblique is required by your radiologist. For injuries above the diaphragm, use this rule of thumb: anterior obliques for anterior injuries, posterior obliques for posterior injuries. Remember to prevent the superimposition of vertebral column over affected ribs. Always try to imagine how you are positioning the vertebral column when you rotate the patient into an oblique. For anterior ribs above the

diaphragm, the affected side should be away from the film. Therefore, a left anterior oblique (LAO) places the vertebral column over the left ribs, allowing the right side to be away from the film and free of vertebral superimposition. Posterior obliques should always be positioned with the affected side closest to the film. For instance, a left posterior oblique (LPO) places the vertebral column on the right side of the chest, allowing the left side, which is nearest to the film, to be viewed free of superimposition. You may notice that not only does the oblique demonstrate the affected ribs free of vertebral superimposition, but it also attempts to place the affected area parallel with the film. Therefore, you should not oblique the patient more than 45°. Since some radiologists prefer less body rotation, such as 30°, you should always consult your department routines

#### Exercises (250):

1. How are ribs classified for positioning?
2. What three factors affect the placement of the diaphragm?
3. Explain how the position of the patient affects the position of the diaphragm.
4. When should the exposure be taken for ribs below the diaphragm? Explain why.
5. Explain why there is a difference in radiographic technique factors between radiographs of the upper and lower ribs.
6. What type of technique provides optimum visualization of rib structures?
7. What additional films should always be included with a rib series on a trauma patient? Why?
8. Explain the two factors that specifically determine which routine radiographs are taken for ribs.

9. List all the projections that should be taken on a patient with injured fifth, sixth, and seventh left anterior ribs.
10. An automobile accident caused injury to the left lower three ribs in the back of a patient. What films should be taken on this patient?
11. Which ribs are demonstrated free of vertebral superimposition in the left anterior oblique position?
12. How many degrees should the patient be rotated for obliques of the ribs?

**251. Indicate correct positions of the sternum or sternoclavicular articulations.**

**Positioning of the Sternum.** The location of the sternum makes it one of the more difficult bones to demonstrate satisfactorily. Because of its anterior relationship to the thoracic spine, a direct AP or PA view without bony superimposition is impossible, unless tomography is used. Therefore, some form of angulation is necessary; either the central ray or the patient must be angled. The usual routine that is used to obtain as near an anterior view as possible is the right anterior oblique (RAO). The RAO and a lateral projection completes a routine exam of the sternum.

**RAO sternum.** When it is preferred to oblique the patient (instead of angling the CR), the RAO position is the choice because it enables the sternum to be overshadowed by the heart. This provides a homogeneous density for the sternum, whereas the LAO, which projects the sternum to the right side of the thorax and vertebrae, causes an increase of pulmonary markings. These markings cast confusing shadows, especially with elderly patients and heavy smokers, that could be misinterpreted as fractures or pathology affecting the sternum.

Positioning the RAO sternum is not difficult as long as you ensure the entire sternum is projected on the film and patient rotation is within proper limits. Too little body rotation projects thoracic vertebrae over the sternum. The proper amount of rotation is dependent on the depth of the patient's chest from anterior to posterior. That is, the deeper the chest, the less body rotation is necessary to clear the sternum of the vertebrae. Therefore, the oblique limits should be in the 20° to 30° range.

Pulmonary markings overlying the sternum are a problem. They can be somewhat eliminated by using a long exposure time while the patient is breathing slowly. An exposure time of at least 5 seconds helps diffuse lung markings. You need to use a low mA setting when using the shallow breathing and long exposure technique. If this

method is undesirable or can't be done because of the patient's condition, you will need to take the exposure on suspended expiration to obtain a more uniform density.

The resultant radiograph shows a slightly oblique posteroanterior projection (anterior oblique view) of the sternum.

**Lateral sternum.** The lateral projection is usually obtained with the patient erect, although it can be done either supine or lateral recumbent if necessary. Key points include having the patient true lateral, shoulders rotated backward, and the CR perpendicular to the center of the sternum. To produce excellent contrast of the posterior aspect of the sternum and adjacent structures, take the exposure while the patient suspends full inspiration.

**Sternoclavicular (SC) Articulations.** Although, views of the SC joints are routine, most technicians don't have the chance to perform them often. Therefore, some are unsure of the procedures to demonstrate SC joints.

Demonstrating SC joints is hampered by the same restriction that prevents a direct AP or PA projection of the sternum. As you recall, the anterior relationship of the sternum to the thoracic spine causes bony superimposition in a direct AP or PA projection. And like the sternum views, to demonstrate the SC joints without bony superimposition, you must either angle the CR or the patient. Therefore, there are two methods to project SC joints unilaterally.

The first method, and perhaps the more common of the two, requires patient rotation and a direct perpendicular central ray. This position obliques the patient until the vertebrae no longer overlay SC joints. Again, like the sternum, the amount of rotation depends upon the depth of the patient's chest. Usually, 30° to 45° is sufficient. Both anterior obliques are required since only the sternoclavicular joint nearest the film is best demonstrated.

The second method maintains the patient in a PA prone position but angles the CR. The central ray is angled medially 15° from the side being examined. That is, the left sternoclavicular articulation is being demonstrated when the CR is located above the patient's left shoulder, and vice versa.

**Exercises (251):**

Indicate whether the following statements are true (T) or false (F). If you indicate false, explain your answer.

- 1. A direct PA projection clearly shows the sternum.
- 2. Because the heart is on the left side of the chest, the LAO position should be used to superimpose the sternum with the heart.
- 3. Lung markings over the sternum could be misinterpreted as fractures.

- 4. Overlying lung markings are best eliminated by shallow breathing techniques.
- 5. The lateral position for the sternum should be taken with shallow breathing to diffuse any lung markings.
- 6. The LAO view for sternoclavicular articulations best demonstrates the left SC joint.
- 7. Depending upon the depth of the patient's chest, the patient should be rotated 45° to 60° to position for SC joints.
- 8. The patient should be true PA and the CR directed 15° medially to demonstrate an SC joint when using the angled CR method.

### 6-3. The Abdomen

Abdomen films are frequently requested as general survey films. And like we mentioned earlier in this chapter, they are often used as scout films for special studies.

In this section, we cover some frequently done abdominal examinations.

**252. Given situations of patients requiring abdominal radiographs, describe the examination that probably would be done.**

**Radiography of the Abdomen.** A good abdomen/KUB (kidneys, ureters, bladder) radiograph exists when the abdomen is positioned and exposed so that the film demonstrates structures of interest. This should be obvious; but, in the past there was a distinction between an abdomen radiograph and a KUB radiograph. Recently, however, the trend is, an abdomen/KUB means the same. That is, the lower border of the film is at the level of the symphysis pubis, thereby demonstrating most structures in the abdominal cavity in the supine or erect position. If the physician suspects free air under the diaphragm, it can be demonstrated on the erect PA chest or decubitus film. Free air can also be seen on an erect abdomen radiograph if the film is centered high enough to include the diaphragm.

Abdomen radiographs are requested for a variety of reasons such as to demonstrate free air or fluid in the peritoneal cavity, gaseous distension of any part of the alimentary canal, evidence of intraabdominal masses, foreign bodies or any other number of reasons.

**Foreign bodies in the abdomen.** The first abdominal examination we cover is of the person who swallowed a foreign object. Generally, the attending physician is interested in locating the object and making sure it is not obstructing or perforating. Generally, a flat plate of the abdomen is all that is necessary.

However, there are some physicians who want the entire alimentary tract demonstrated on the initial film. Entire alimentary tract means from the mouth to the anus. If it is necessary to use two films, due to patient size, then the film must overlap so as not to miss any structures. Subsequent followup films need only be taken from the location of the object to the anus.

**The KUB radiograph.** The KUB abdomen is usually requested on patients with urinary system difficulties. The anatomy required are the entire kidneys, ureters, and urinary bladder. As with all abdominal radiographs, they should exhibit a relatively short scale (high contrast) of contrast.

The short scale of contrast better delineates the soft tissue structures. For example, the renal outline versus surrounding structures. The patient should urinate prior to the examination so as not to have a distended bladder that might obscure pathology. If a urinary calculus (stone) is suspected, instruct the patient to strain the urine through some gauze. The purpose for the straining is to catch any calculi that may be eliminated. The radiographs taken are generally an AP and upright abdomen. The AP demonstrates the renal and abdominal area in general and the upright determines the mobility of the structures and surrounding tissue.

**The acute abdomen.** An acute abdomen usually consists of at least three radiographs: an erect PA chest, an erect abdomen, and a supine abdomen, preferably taken in the order listed. The erect films are taken for many reasons, one of which is to demonstrate abnormal air or fluid levels in the abdominal cavity or within a structure. To do these films correctly, a horizontal X-ray beam is used and the air or fluid needs time to seek its level. Therefore, the patient should remain in an erect position several (5 to 10) minutes prior to taking the radiographs. Remember, if the patient is ambulatory or in a wheel chair, he or she is already in an erect position. By doing the erect films first, you will shorten the time necessary for the examination, thereby rendering better care to the patient. However, many of these patients are too ill to maintain an erect position even with the aid of an upright radiographic table. In these instances, a left lateral decubitus (patient lying on left side) is recommended. With the left side down, free air will rise over the lateral surface of the liver. This tends to avoid confusing shadows caused by air in the stomach.

#### Exercises (252):

1. A child is suspected of swallowing a coin. The AP film demonstrates the manubrial notch to the anus; also the coin is apparently in the stomach. Was the film centered correctly? Should the examination be repeated?



2. A patient has acute pain in the right midabdominal area. History: rule out renal calculus. Of the listed techniques, which would you use (assume both produce a diagnostic abdominal radiograph)? Why?
  - a. 50 mAs; 90 kVp.
  - b. 100 mAs; 76 kVp
3. Patient has acute generalized abdominal pains. Patient arrives in a wheelchair. What films should be taken? What order and why?
4. Patient has acute abdominal pains. Patient arrives on a litter and is unable to attain an upright position even with the aid of the X-ray table. What films should be taken? In what order and why?

## Positioning of the Vertebral Column

WE CONTINUE OUR study of positioning by explaining projections of the vertebral column. In this chapter, we cover various positions for the cervical, the thoracic, and the lumbar regions of the vertebral column. We also include views for the sacrum and coccyx.

### 7-1. The Cervical Spine

The cervical spine, more commonly referred to as the C-spine, is perhaps the easiest of the three major portions of the vertebral column to center on the film. This is due to the relative ease of locating its seven vertebrae. However, some of the C-spine's routines offer considerable positioning difficulty.

Usually, five films compose a C-spine series: AP, lateral, open mouth, and both obliques. The AP offers a general view of the lower five cervical vertebrae. The patient is positioned supine with median plane over the midline of the table. Tilt the head slightly so that the mandible does not superimpose the middle vertebrae. Angle the CR 15° cephalic and directed through the fourth cervical vertebra.

The lateral view is done best when you apply certain procedures. With your patient standing erect, make sure the median plane is vertical through the entire length of the spine. Raise the mandible until its rami no longer superimpose the spine. The CR is perpendicular to the center of the C-spine and directed from an FFD of 72 inches. The longer FFD is needed to overcome the OFD of the C-spine to the film. Patients with a thick neck or high shoulders may need to hold sandbags of equal weight in each hand to depress the shoulders. This allows better demonstration of C-6 and C-7.

Since most problems of C-spine positioning develop with the open mouth and oblique positions, we cover those more in depth. In addition, we describe procedures to use in X-raying the C-spine of a litter patient.

**253. Evaluate four AP radiographs and determine whether they meet prescribed procedures and standards; indicate corrective measures if necessary.**

**AP Open Mouth (George Position).** This projection is taken to demonstrate the atlas (C-1) and axis (C-2) in the AP position. Commonly called an open-mouth odontoid, and specifically the George position, it requires the patient's head to be precisely positioned; otherwise, the atlas and axis are not projected clear of overlying structures.

To position the patient, open the patient's mouth as wide as possible and adjust the head so that a line through the inferior edge of upper incisors and the inferior border of the

mastoid tip is perpendicular to the film. This line closely parallels the acanthomeatal line. Use a perpendicular CR. Since the position is uncomfortable for the patient, be sure to have the technique and tube-film placement ready so that you can make the exposure quickly. Also, have the patient say "Ah" during the exposure to prevent any movement of the jaw and to fix the tongue on the floor of the mouth. The shadow of the tongue is then projected below the vertebrae under study and does not interfere with detail. As usual, for examinations in this area, have the patient remove any dentures. Figure 7-1 shows an ideal demonstration of this projection.

Usually, when the patient is improperly positioned for this projection, it is because the head is either tilted too little or too much. The result is the superimposition of the base of the skull or incisors (depending upon the direction in which the imaginary line is tilted) over the structures under study. You can easily check the position on the radiograph by noting the lower margins of the upper incisors and the base of the skull. If the base of the skull is lower than the incisors, the head is extended too much. If the two parts are reversed, the head is not extended enough. At times, although the head is tilted correctly and the incisors and base are in the same vertical line, there is still some superimposition over the vertebrae.

#### Exercises (253):

Four AP "open-mouth" radiographs of the atlas and axis are made:

Radiograph A shows the lower margins of the upper incisors superimposed over the area under study. The base of the skull is projected above the upper incisors.

Radiograph B shows the base of the skull superimposed over the vertebrae. The lower margins of the upper incisors are projected above the base of the skull.

Radiograph C shows the base of the skull and the lower margins of the upper incisors superimposed over each other. Both of these structures are projected above the atlas. A dense shadow, representing the tongue, is superimposed over the axis.

Radiograph D shows the base of the skull and lower margins of the upper incisors superimposed over each other. Both of these structures are superimposed over the atlas and odontoid process.

Based upon the information presented in the text, answer the following questions about each radiograph.

Is the radiograph properly positioned? If not, what is specifically wrong with the position and how should it be corrected?



Figure 7-1 Radiograph showing C-1 and C-2 with the use of an open-mouth projection

1. Radiograph A
2. Radiograph B
3. Radiograph C.
4. Radiograph D

234. State the purpose, projection, and the angulation used for oblique projections of the cervical spine.

**Oblique Projections of the Cervical Spine.** The usual reason for making oblique projections of the cervical spine is to show the intervertebral foramina, although the pedicles are also seen, as well as the other cervical structures. The foramina open at a 45° angle off both anterolateral aspects of the vertebrae. They also open slightly downward, 15° to 20°, from the vertebrae.

Obliques of the cervical spine can be taken erect or recumbent as well as with or without a grid. Also anterior or posterior obliques can be taken. Keep in mind that the intervertebral foramina open from the anterolateral aspects of the vertebrae; therefore, posterior obliques demonstrate the foramina farthest from the film and anterior obliques show the foramina nearest the film.

For example, figure 7-2 shows a radiograph of a cervical spine in an oblique position. Without the use of the film's identification block and a side identification marker, we are unable to say whether this was positioned as an anterior or posterior oblique. So let's say that it is properly being viewed and assume it is a posterior oblique. Since we view the patient's left on our right and because the vertebral bodies project to the patient's right and the spinous processes project to the patient's left, we can say that the patient is in RPO. Therefore, intervertebral foramina of the side away from the film are being demonstrated. Thus, the left side foramina are shown. Now, if we assume this radiograph shows an anterior oblique, then the patient is left anterior oblique (LAO) and the side nearest the film is demonstrated—the left side.

To position the patient for an oblique projection, rotate the entire body 45° to coincide with the opened foramina. Turn the median plane of the head slightly more than 45° from its position perpendicular to the film to prevent the superimposition of the ramus of the mandible over the spine. Direct the CR to the fourth cervical vertebra so that the CR coincides with the inferiorly angled opening of the foramina. The CR is angled 15° caudad for anterior (PA) obliques or 15° cephalic for posterior (AP) obliques.




Figure 7-2. Radiograph of a cervical spine in an oblique position.

### Exercises (254):

1. For what specific reason are obliques of the cervical spine usually made?
2. Which oblique projection(s) demonstrates the structures indicated in exercise 1, on the right side of the vertebrae and on the left side of the vertebrae?
3. What is the specific part rotation and CR angulation for a right posterior oblique of the cervical spine? For a right anterior oblique?
4. If an oblique radiograph of the cervical spine shows the ramus of the mandible superimposed over the vertebrae, what should you do to eliminate this superimposition on a subsequent radiograph?

**255. Given specific information about a patient, describe the projection and courses of action to demonstrate the cervical vertebrae.**

**Cervical Spine Projections on a Litter Patient.** When we refer to a litter patient in this case, we mean a patient who experienced trauma and is on a stretcher or litter, usually in the supine position. This type of patient must be handled very carefully to prevent further injury and complications.

When a patient is to be radiographed in this condition, first make a cross-table lateral of the C-spine without moving the patient to the X-ray table, or changing the patient's position on the litter. Show the radiograph to the radiologist or attending physician before doing anything else. This is very important because the physician may, after seeing the initial film, not want to move the patient at all until traction has been applied.

Now, suppose the initial cross-table lateral does not show any abnormality. Your next course of action is determined by the physician. The radiologist may direct you to make AP and oblique projections with the patient still on the litter or to move the patient to the table for the remaining radiographs.

If the physician wants you to perform the remaining films with the patient on the litter, do the AP first and have it checked by the physician before proceeding with the obliques. If obliques are then required, you can easily perform them with the patient supine. All you have to do is place a cassette under the patient's spine and direct the CR 15° cephalically and 45° medially. In other words, the CR is directed through the intervertebral foramina as for conventional obliques, except that the tube is angled 45° instead of the patient. Ask the physician to supervise the lifting of the patient for the film placement. If it is not

possible for the patient to move without assistance, be sure that the physician understands what you must do to place the film under the patient's neck. That way, the physician can give you precise instructions on how to lift the patient.

If the physician wants you to move the patient to the X-ray table for the remaining radiographs, again ask the physician for supervision or guidance in moving the patient. As you can see, you must be extremely careful when moving a patient with a spinal injury. Take all precautions necessary to prevent injury to your patient. When you get the patient on the table, you can perform the obliques as on the litter, but you will have to remove the Bucky grid to prevent grid cutoff due to the 45° angle of the tube.

### Exercises (255):

1. A patient is brought to the radiology department on a litter in the supine position. The physician suspects a fracture of C4. Describe the initial projection you should perform and why.
2. The cross-table lateral on the patient in exercise 1 shows a fracture of C4. What is your next course of action, if any?
3. How much part rotation, if any, or what CR angulation and direction, if any, should you use for oblique projections on the patient in exercise 1?
4. What should you do to prevent grid cutoff if you are performing the obliques on the X-ray table on the patient in exercise 1?
5. Before moving or lifting the patient in exercise 1 or adjusting his position, what action should you take?

### 7-2. The Thoracic Spine

The thoracic spine, commonly called the T-spine, consists of 12 vertebrae; therefore, it is the longest portion of the vertebral column. Because many conditions, both pathological and traumatic, can affect it, accurate positioning is a must.

**256. Explain certain characteristics pertaining to the AP and lateral positions of the thoracic spine.**

**AP Thoracic Spine.** The AP projection demonstrates vertical alignment of thoracic vertebrae. Therefore, any lateral displacement of vertebral bodies, or curvatures of

the spine, are well visualized in the AP radiograph. When dealing with the arthritic, kyphotic, or scoliotic patient, it is much easier on them and on yourself if you make the radiographs in the upright position. Where there is gross deformity of the spine—as seen in kyphosis or scoliosis—position the patient as best you can. Imagine where the patient's midline is and center it to the table and film. Accuracy of projection is critical, as the radiograph will be used to determine the exact amount of curvature.

When dealing with patients suspected of having fractures of the T-spine, be just as careful and cautious as you would if the condition were in the C-spine. Handle the patient in precisely the same manner with as little movement of the patient as possible.

One main point to remember is proper use of the "anode-heel effect." With T-spine positioning, always place the cathode end of the tube toward the abdomen. This will allow the greater percentage of rays from the anode to pass through the diaphragm, the thickest part of the body overlying the T-spine.

**Lateral Positions of the Thoracic Spine.** The usual routine T-spine series consist of AP and lateral radiographs. Most adult patients require an additional lateral view, either Twining (swimmer's position) or the Pawlow position, to demonstrate the upper thoracic spine. For our purposes, we will consider both lateral views.

**Lateral T-spine.** The routine lateral T-spine radiograph is designed to give a full view of thoracic vertebrae. In actual practice, it best demonstrates T-3 through T-12 because T-1 and T-2 are usually superimposed by shoulders. This lateral provides the means for determining the amount of kyphotic curvature. This is extremely important, because kyphosis causes the anteroinferior margins of the vertebra to touch and sometimes fuse to the anterosuperior lip of the vertebra below it. The lateral projection is the only view in which the degree of compression of intervertebral disks may be accurately evaluated. Compression fractures are also best demonstrated with the lateral. Therefore, every effort must be made to position the patient correctly and to direct the CR to the prescribed point. Rotation, mispositioning, and distortion of the T-spine prevent accurate diagnosis.

When positioning for the lateral, ensure that you have the entire T-spine centered and parallel to the table. You may need to support the narrow portion of the abdomen with foam cushions. If the narrow lumbar region is unsupported, the lower thoracic spine will sag toward the table. This condition projects those vertebrae onto the film with their intervertebral spaces closed because adjoining vertebral bodies appear to overlap. Use of a perpendicular CR helps to visualize intervertebral spaces clearly.

In addition to tube-part-film alignment, breathing instructions are very important with the routine lateral. Some technicians take the lateral on suspended inspiration, as for the AP. Unfortunately, ribs can superimpose vertebral bodies. A special breathing technique may be used to demonstrate these vertebral bodies free from superimposed ribs. The positioning factors are the same as those already described. However, instead of having the patient suspend respiration on deep inspiration, have the

patient breathe quickly and in a very shallow manner—very much as if the patient was panting. Make sure that only the ribs move, and not the spine. The motion of the ribs will blur them out, and the vertebrae will be clearly demonstrated.

**The Twining position.** This position, commonly called the swimmer's position, presents a lateral view of the cervicothoracic region. That is, more specifically, the lower cervical spine and the uppermost thoracic spine. It is used as an additional film anytime C-6, C-7, T-1, and T-2 are not well visualized on a lateral radiograph. Although this projection may be done as part of a cervical spine series, it is more often added with a T-spine series.

Positioning procedures for the Twining are very similar to its "cousin position," the Pawlow position: patient lateral to the film and the vertebral column is parallel to the film. The arm nearest the film should be raised and the shoulder away from the film should be depressed and slightly rotated either backward or forward to move the humeral head away from vertebral bodies. If the shoulder can be depressed, direct a perpendicular CR to the film. If the shoulder cannot be depressed to clear the vertebrae, angle the CR 5° caudad. Twining's position calls for the patient to be sitting or erect, whereas Pawlow's position has the patient lateral recumbent. Although the differences are minor, both positions produce virtually identical results and are often referred to as one and the same.

#### Exercises (256):

1. Why is an AP T-spine performed on a patient with scoliosis?
2. How should you use the anode-heel effect to your advantage when positioning for the T-spine?
3. Why don't T-1 and T-2 visualize well on a routine full lateral T-spine on most adults?
4. What type of spinal curvature is best demonstrated on the lateral view of the T-spine?
5. Which position of the T-spine would best demonstrate a fracture of T-6 vertebral body?
6. The vertebral spaces of the distal third of the T-spine did not visualize well in the lateral projection. What could be done to improve the radiograph?

7. A lateral T-spine that was exposed on suspended inspiration resulted in a radiograph with ribs that clearly superimpose vertebral bodies. What could be done to improve this situation?
8. Your radiologist requests a Twining position on a patient who cannot depress the shoulders. How should you obtain this view in this situation?

**257. Correlate the position of the patient with the structures to be shown on the radiograph on oblique projections of the thoracic spine.**

**Oblique Projections of the Thoracic Spine.** Oblique positions of the thoracic spine are usually taken to demonstrate apophyseal joints. These joint spaces appear opened if they are seen at an angle of  $20^\circ$  from the vertical with the patient in the lateral recumbent position. If the patient is in this position and the side away from the film is rotated  $20^\circ$  forward, then joints nearest the film are demonstrated. If the elevated side is rotated backward  $20^\circ$  (coronal plane posteriorly forms  $70^\circ$  angle to the table), the joints farthest from the film are demonstrated. For example, if the patient is in the right lateral recumbent position and the left side is rotated forward, the joints of the right side are visualized. If the left side is rotated backward, the left apophyseal joints are seen.

Whether you use anterior or posterior obliques depends upon your radiologist. There is a little difference in the part-film distance between the different obliques, so you shouldn't mix them. Comparing the sides is more difficult if the obliques are mixed. Also, be sure to elevate the lumbar and lower thoracic areas to place the thoracic spine parallel with the film.

**Exercises (257):**

1. If the patient is supine on the table, how many degrees should the left side be elevated from the table to demonstrate apophyseal joints on the left side of the thoracic spine?
2. If a left posterior oblique of the thoracic spine is performed (coronal plane forms a  $70^\circ$  angle with the table), which apophyseal joints (right or left) are demonstrated?
3. If a right posterior oblique of the thoracic spine is performed, what other oblique should also be performed?

### 7-3. The Lumbar Spine

Since this part of the vertebral column supports a great part of body weight, even minor injuries may incapacitate the patient. Serious injuries, such as fractures, are extremely dangerous and could possibly result in paralysis if the spinal cord is damaged. Therefore, accurate diagnosis of the cause for "low back pain" includes radiographic examination of the lumbar spine.

It is standard procedure to demonstrate the lumbar spine in AP, posterior obliques, and lateral projections. We shall consider certain characteristics of each position, starting with the AP.

**258. Explain certain characteristics pertaining to radiographs and positioning procedures of the AP and lateral lumbar spine.**

**AP Lumbar Spine.** When done correctly, the AP projection adds much information to a lumbar series. Unfortunately, inaccurate positioning all too often happens. Perhaps one of the most frequent errors of positioning the AP lumbar spine is failure to "straighten" the spine. This results because the technician fails to flex the patient's hips and knees. The correct procedure calls for this flexion until the feet are flat on the table. This will "straighten" the lumbar spine somewhat by reducing the amount of normal lordotic curvature. This adjustment places the intervertebral spaces at an angle closely paralleling that of the divergent beam of radiation. The resultant radiograph shows delineation of the intervertebral disk spaces.

An AP lumbar film also aids in measuring the amount of scoliosis. For this reason, it is important that the patient's shoulders and hips are parallel with each other, and that the entire vertebral column must be in perfect alignment, as well as at right angles to hips and shoulders. It is imperative that positioning be in this manner; if not, the resultant radiograph will be inaccurate due either to slant of the spine or, even worse, a mediolateral curvature.

Rotation of the spine must be prevented when positioning from the AP. If a soft tissue abnormality, such as swelling or atrophy, is causing rotation because of a side of the pelvis is elevated, adjust a support under the lower side. Check to make sure that each ASIS is equal distance from the midline of the table and from the surface of the table.

The AP projection of the lumbar spine may be made with the patient erect. Indeed, it should be done erect under certain circumstances. For example, to demonstrate the degree of pelvic tilt associated with either a shortened leg or scoliosis, you should use the erect position. In fact, most radiologists require an erect AP lumbar film on scoliosis patients, and taken with the patient "barefoot." This prevents pelvis tilting due to uneven shoes.

**Lateral Lumbar Spine Projections.** Two lateral projections are routinely included in a lumbar series; a full lateral and a "spot" lateral. The full lateral is commonly called the lateral lumbar spine because it produces a lateral view of the entire lumbar spine; particularly lumbar bodies, intervertebral disk spaces and foramina, and spinous processes as shown in figure 7-3. The spot lateral is coned-




Figure 7-3. Radiograph of a lateral lumbar spine.

down to show the lower one or two lumbar bodies and the upper sacrum, particularly the lumbosacral joint (L-5, S-1). Some radiologists prefer that the sacrum, and even the coccyx, be included on the lateral. In that manner, the spot film may not be required. Regardless of which is preferred as the department routine, certain characteristics are prevalent.

**The lateral projection.** To produce good visualization of intervertebral disk spaces, you must prevent the lumbar spine from "sagging." When the patient is lateral recumbent, the lumbar spine tends to sag, especially with patients that have a narrow waist and a wide pelvis. Since it is necessary to have the vertebral column at right angles to the CR, you may need to maintain the spine parallel to the table by placing support cushions under the lower thorax. If the film is exposed without the spine parallel to the table, the intervertebral disk spaces may appear closed because vertebral bodies will seem to overlap their adjoining spaces. In some case, depending upon the patient's body habitus, the divergence of the primary beam compensates for the lateral curvature of the lumbar spine.

In addition to part alignment, tube alignment is equally important. Therefore, with the spine parallel to and over the midline of the table, direct the perpendicular CR to a point about 2 inches above the iliac crest. This should correspond with L-3. Keep in mind that no matter how large or obese the patient, the long axis of the spine is located in the midaxillary line.

Although the lateral is routinely done with the patient lateral recumbent, it can be obtained with the patient erect or supine. For example, an injured patient arriving in the X-ray department on a litter may have a fractured lumbar spine. AP and lateral projections would have to be made without moving the patient. In this case, a lateral taken with the patient supine may not be optimum but it would be diagnostic. Erect positions involving flexion and extension (forward and backward bending) are used to demonstrate mechanical obstruction at the posterior portion of intervertebral joints. Regardless of how they are done, all laterals of the lumbar spine are exposed on suspended expiration.

**Spot lateral of L-5 and S-1.** This projection may or may not be performed, depending upon your radiologist. It is usually necessary to do this view on narrow-waisted and

wide-hipped patients. These patients experience a wide difference of radiographic density between those two areas on a single exposed film due to the thickness and density of body structures. Also, because of lumbar sag that was previously explained, these patients may require the localized projection of the lumbosacral function as the only means of viewing that articulation.

If made correctly, the "spot" is a valuable film; if not, it is totally useless. All of the body, superimposed pedicles and laminae, the spinous process, and, above all, the superior and inferior articular surfaces on the side closest to the film must be seen. The superior articular surface of the sacrum, the anterior and posterior margins of this bone, and one lateral aspect of it must be seen. If these portions of the L-5 and S-1 area are not seen, the projection is useless. For example, one of the many causes of low back pain is spondylolisthesis, which is basically a slipping of the fifth lumbar vertebra forward on the sacrum. While it can be either L-4 on L-5, or L-5 on S-1, the latter is more frequently seen. The problem is caused by a failure of the superior and inferior surfaces (facets) to join, a condition that produces a cleft between them. Usually these clefts are bilateral and cause the vertebra of which they are a part to slip forward. The degree of slippage is best measured by dividing the lateral margin of the superior articular surface of the sacrum into fourths. The posteroinferior lip of the fifth lumbar vertebra then acts as an indicator, in which it points to a particular area of the sacral articular surface. If, for example, it pointed to the third position, or zone, then the condition would be classified as a third-degree spondylolisthesis. If, however, the articular facets were to be "cut off" on the radiographic projection, no diagnosis could be made. In a like manner, if the anterior portion of the first sacral segment were to be cut off, no accurate measurement of slippage could be made. Hence, no diagnosis. Once again, patient positioning and CR alignment must be accurate.

The spot lateral is usually done immediately after the routine full lateral. Because the patient is already lateral recumbent, only a small positioning adjustment is necessary. To properly center the lumbosacral joint, move the patient about 1 to 2 inches anteriorly. With the joint now centered to the midline of the table, direct a perpendicular CR to the center of the film through a point 2 inches below the level of the iliac crest. If the spine is not parallel to the film, using a vertical CR may not show this joint fully "opened." In this case, angling the CR caudally will project the CR perpendicularly through L-5, S-1 joint. The average amount of caudal angulation should be 5° for males, and 8° for females, depending upon the patient's body habitus.

#### Exercises (258):

1. What should be done to reduce the amount of lordotic curvature when performing the AP projection of the lumbar spine?

2. Why should the patient be barefoot when performing an erect AP lumbar spine for scoliosis measurement?
3. An AP lumbar spine radiograph shows a mediolateral curvature of the spine. What positioning mistake probably caused this error?
4. An AP lumbar spine radiograph shows rotation of the spine. What positioning error could cause this? What common pathology of the pelvis could cause this?
5. What should be done if each ASIS is not equal distance from the tabletop when positioning for an AP lumbar spine?
6. Which lumbar radiograph best demonstrates intervertebral foramina of L-2 and L-3?
7. Intervertebral disk spaces appear closed on a lateral radiograph of the lumbar spine. What positioning error probably caused this mistake?
8. A spot lateral radiograph shows the lumbosacral joint closed. Assuming the patient was correctly positioned and the CR was perpendicular, what could the technician do to improve the radiograph?

**259. Evaluate certain characteristics of specific oblique projections and radiographs of the lumbar spine.**

**Oblique Projections of the Lumbar Spine.** The oblique projections of the lumbar spine are usually taken to demonstrate the apophyseal joints. Remember that the apophyseal joints are formed by the superior articular process of one vertebra and the inferior articular process of the next lower vertebra. These joints open from the

posterolateral portions of both sides of the vertebrae at about a 45° angle. Usually, the joints can be visualized if the patient is rotated 45° in either the anterior or posterior oblique positions. However, the exact degree of angulation may vary from patient to patient, and after having seen the initial 45° radiographs, you may have to rotate the patient to some other angle to make the joint spaces visible. In fact, the degree of patient rotation is the most common positioning error made in performing these obliques, even when the joints are situated at a 45° angle. You can determine whether the patient has been rotated 45° from the AP or from the PA position by looking at the medial portion of the transverse process, seen on end as a dense circular area with a lucent center. If the joint spaces are not visualized and the medial portion of the transverse process is toward the anterior portion of the vertebral body, the patient is not rotated enough from the supine position. If the medial portion of the transverse process is toward the posterior portion of the vertebral body, the patient is rotated too much. This bony landmark should be in the approximate center of the vertebral body. In addition, the width of that structure changes with different amounts of body rotation (see fig. 7-4).

As we previously mentioned, posterior or anterior obliques of the lumbar spine can be made, depending upon your radiologist's preference. If posterior obliques are made, the joints nearest the film are visualized. With anterior obliques, those farthest from the film are seen.

**Exercises (259):**

Three oblique radiographs of the lumbar spine are made. Radiograph A shows the medial portions of the transverse processes projected in the horizontal center of the vertebral bodies. Radiograph B shows the same structures projected toward the posterior portions of the bodies. Radiograph C shows them projected toward the anterior portions of the bodies. The relative (horizontal) widths of the processes are: Radiograph A—medium; radiograph B—narrow; radiograph C—wide. Based upon the information presented in the text, answer exercises 1 through 6.

1. Which radiograph shows approximately 45° rotation?
2. Which radiograph shows more than 45° rotation?
3. Which radiograph shows less than 45° rotation?



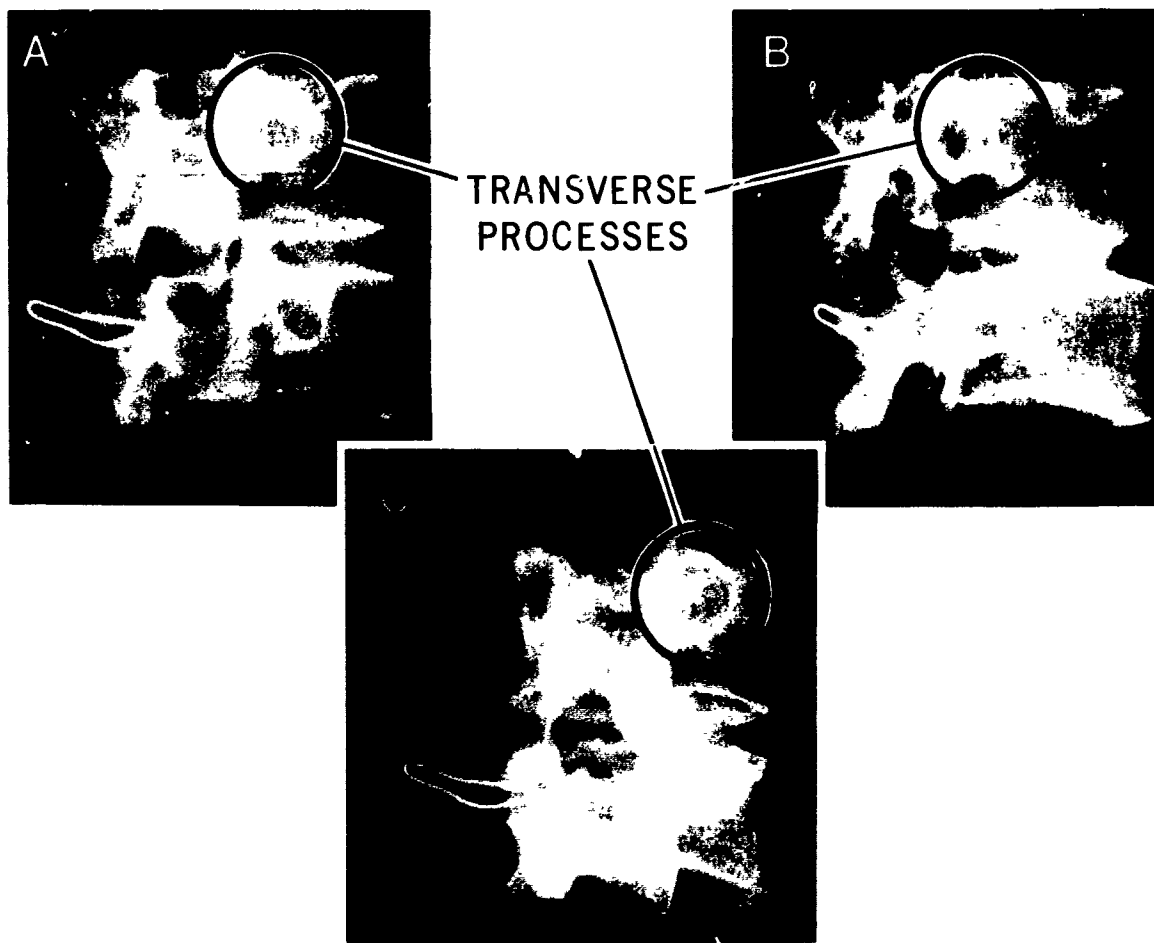


Figure 7-4. Three left posterior oblique radiographs of dried lumbar vertebrae showing how body rotation affects visualization of the apophyseal joints. A is correctly rotated. B is rotated too much. C is not rotated enough.

4. If radiograph A does not demonstrate the apophyseal joints, what can you assume about the joints?
5. A right posterior oblique of the lumbar spine is correctly made. Which (right or left) apophyseal joints are demonstrated?
6. A right anterior oblique of the lumbar spine is correctly made. Which (right or left) apophyseal joints are demonstrated?

#### 7-4. The Sacrum, Coccyx, and Sacroiliac Joints

In this section we briefly explain the routine projections of the sacrum and coccyx. We also cover two ways to accomplish oblique projections for the sacroiliac joints.

##### 260. Identify correct positions of the sacrum and coccyx.

**Positions of the Sacrum.** Routine positions of the sacrum are AP and lateral.

**AP sacrum.** For the AP projection, the patient is placed on the table in a supine position in exactly the same manner as for the AP pelvis—the midline of the patient should be directly over and parallel to the centerline of the table. Angle the CR 15° cephalic, and direct it to the anterior abdominal surface so that it will enter at a point on the median plane of the body, midway between the symphysis pubis and the ASIS. By doing this, you will direct the CR at right angles to the sacrum, which is angled at about 15° off the horizontal plane with the patient supine.

The AP position is preferred over the PA position because the AP decreases part-film distance. However, when the patient has sustained an injury to the sacrum, the routine may not be possible. In this case, the prone (PA) position may be used. The part-film distance will produce a certain amount of magnification, but the situation warrants the use of the position. All factors associated with the AP remain constant for the PA, except that the CR is angled 15° caudally.

**Lateral sacrum.** The lateral of the sacrum is made by having the patient assume the lateral recumbent position on either side. Adjust the pelvis so that the sacrum is aligned over the centerline of the table. Ensure that the pelvis is in true lateral and not rotated. Direct a perpendicular CR to the midpoint of the sacrum.

Again due to traumatic injury, you may not be able to perform the routine lateral position. With the trauma patient, you can get a lateral view immediately after performing the PA without moving the patient. A cross-table lateral with the patient prone will produce a diagnostic film.

**Positions of the Coccyx.** Positions used to demonstrate the coccyx include AP and lateral.

**AP coccyx.** Patient positioning for this view is identical as for the AP sacrum or pelvis. Central ray angulation is, however, directed differently. To place the CR at right angles to the coccyx with the patient supine, angle the CR 10° caudally. The CR should enter the patient at the same midpoint as for the AP sacrum.

In the event of serious trauma, you may be unable to have your patient supine. In this case, you can get an anterior view by angling the CR 10° cephalic at the coccyx.

**Lateral coccyx.** Like the sacrum, the coccyx is easy to position for the lateral view because you can feel its posterior surface. With the patient lateral recumbent, make sure the coccyx is over the midline of the table. Be gentle when touching a coccyx that has been traumatically injured—the slightest pressure can cause intense pain. The vertical central ray is directed to the middle of the coccyx.

A lateral coccyx can be obtained with the patient prone. Seriously injured patients that need views of the coccyx should have the lateral performed cross-table, especially when it may be too painful to place the patient lateral recumbent.

Some departments require patient preparation before performing routine views of the coccyx, or for that matter, the sacrum, too. A cleansing enema prior to the examination helps eliminate any gas or fecal material that may obscure the patient's body structures.

#### Exercises (260):

Indicate whether the following statements are true (T) or false (F). If you indicate false, explain your answer.

- 1. The CR angulation for the AP sacrum should be 15° cephalic.

— 2. The PA position is preferred over the AP position of the sacrum because the PA decreases magnification

— 3. The prone position may be used for the lateral sacrum with trauma patients.

— 4. When performing the AP coccyx, the CR is angled caudally to place the CR at right angles to the coccyx.

— 5. A PA coccyx view can be obtained with the CR angled 10° cephalic.

— 6. A lateral view of the coccyx should be obtained with the patient supine when the patient cannot hold the lateral recumbent position

— 7. A cleansing enema may be given the patient prior to routine examinations of the sacrum or coccyx.

#### 261. Match each oblique position of the sacroiliac joint with the side demonstrated.

**Sacroiliac (SI) Joints.** As you are probably aware, there are two methods for doing the oblique projections of the SI joints: posterior and anterior obliques. Which one you select depends, of course, on the procedures established in your department. The SI joints are the articulations between the sacrum and the iliac portions of the innominate bones. The joint surfaces form an angle of approximately 25° to 30° anteriorly from the median plane. Therefore, to demonstrate them adequately, either the tube or the patient is angled. Tube angulation is not practical since you would be angling across the lead strips of the Bucky. By obliquing the patient 25° to 30°, you place an SI joint perpendicular to the film, enabling it to be demonstrated.

Figure 7-5 depicts a pelvis positioned for a left posterior oblique. Notice by rolling the right side up 25° to 30°, the right SI joint is nearly perpendicular to the film. This allows the perpendicular CR to traverse through the joint and, in this case, demonstrate the joint farthest from the film.

Figure 7-6 illustrates a pelvis positioned for a right anterior oblique. In this position, the joint nearest the film is best demonstrated. Notice on both illustrations that the opposite side would be obscured since you are in effect increasing (in relationship to the CR and film) an angle which they form.

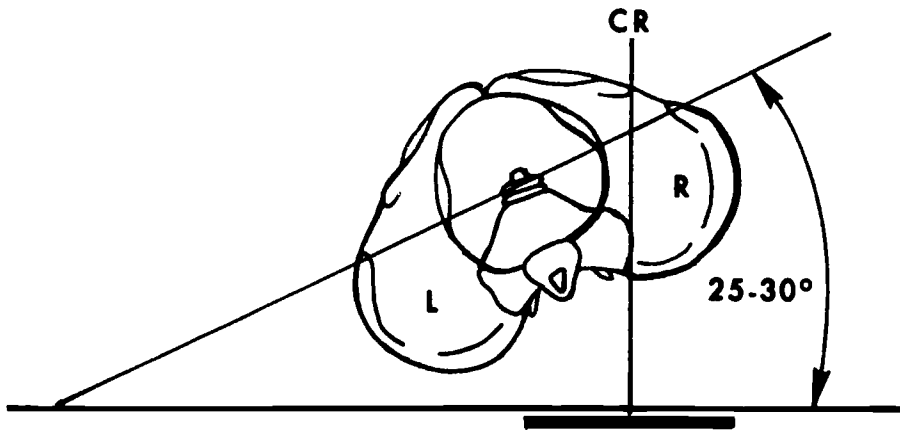


Figure 7-5 Left posterior oblique

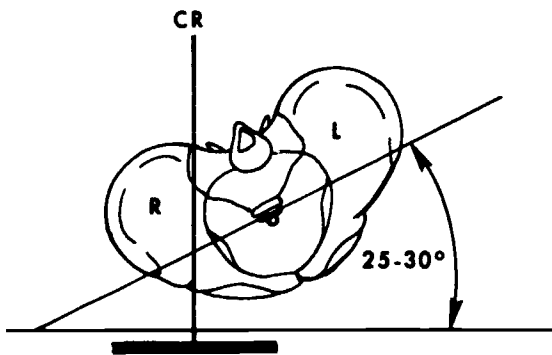


Figure 7-6 Right anterior oblique

**Exercises (261):**

1. Match the SI joint in column A with the projection in column B. Each projection is used twice.

- | <i>Column A</i>                    | <i>Column B</i>           |
|------------------------------------|---------------------------|
| — (1) SI joint away from the film. | a Right posterior oblique |
| — (2) SI joint nearest the film    | b Left posterior oblique  |
|                                    | c Right anterior oblique  |
|                                    | d Left anterior oblique   |

## Positioning of the Skull

WHILE IT IS relatively easy to produce diagnostic radiographs of many parts of the body, the skull and its contents present some problems not encountered with other body structures. Perhaps, the greatest reason for the problems is that the skull must be positioned precisely. There is not as much margin for error. If, for example, the rotation of skull is off as little as  $5^\circ$ , the structure under study may not be demonstrated on the radiograph. You must be "on the money," so to speak, to produce consistent diagnostic radiographs of the skull and its contents.

It is not practical to present in this CDC the seldom-used projections of the skull. They are available in commercial publications found in most Air Force hospitals. We present most of the projections that are used commonly. These include basic skull projections, sinus positions, positions of the mastoids, petrous ridges, and internal auditory meati; optic foramina; and projections for some of the facial bones, such as zygomatic arches and the mandible. We begin with the basic positions of the skull.

### 8-1. Basic Positions of the Skull

The basic projections of the skull are: lateral, PA or AP, submentovertebral or verticosubmental, and Chamberlain-Towne's. These projections are used to demonstrate various structures and are often used in different exams. Regardless of the structure examined, the basic position is the same.

#### 262. Specify how you should position the patient for various lateral projections of the skull.

**Lateral Projection.** Perhaps you have noticed on occasion that cross-table lateral projections of the skull usually demonstrate the skull in the true lateral position. This is understandable because, with the patient in the supine position, it is relatively easy to adjust the head so that the median plane is parallel with the vertical X-ray film.

Most lateral projections, as you know, are performed with the patient in the semiprone position, and it is with this position that some technicians have problems. The problems usually stem from two factors. First, it is almost impossible to position some patients properly without elevating the head on some radiolucent material or elevating the patient's chest and shoulders so that the cervical spine is parallel with the film. Second, it is difficult for some technicians to "eyeball" the skull and determine whether it is in the proper position.

So that you can better understand how to cope with these problems, we first define four improper skull positions.

**Anterior or posterior rotation.** The skull is rotated so that the face is either too close to, or too far away from, the table (see fig. 8-1).

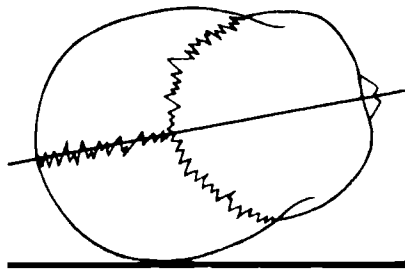
**Superior or inferior longitudinal angulation.** The skull is tilted so that the top of the head is either too close to, or too far away from, the table (see fig. 8-2). Usually, with a thin patient, the top of the head is tilted away from the table, and, with an obese patient, it is tilted toward the table.

It is easier to prevent longitudinal angulation of the head than to prevent anterior or posterior rotation. The reason for this is that there are two simple ways to check the position. One is to use a rectangular piece of cardboard 3 x 8 inches. Lay the longer edge of the cardboard on the table in front of the face and check the upper edge with the median plane. Adjust the position of the head until the upper edge of the cardboard is parallel with the median plane, as shown in figure 8-3. It is helpful to have on hand several pieces of cardboard of different widths because it is easier to check the alignment if the upper edge of the cardboard is the same height as the median plane. You may have to elevate the top portion of the head or elevate the patient's chest and shoulders to achieve the correct position.

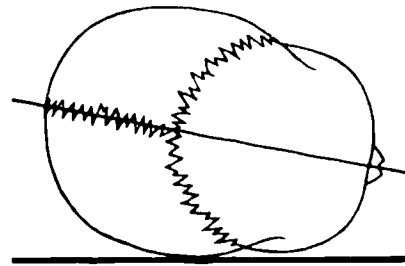
Another way to check the longitudinal position of the head is to stand the cardboard on end and see if the interpupillary line is vertical with respect to the longitudinal plane of the table, as shown in figure 8-4. If not, correct the position of the head. To check the position of the head with respect to anterior or posterior rotation, position yourself at the end of the X-ray table and check the position of the head using the same piece of cardboard, as seen in figure 8-5. Rotate the head until the median plane is parallel with the table. Remember, you must check the head for anterior or posterior rotation from this position.

Center the midpoint of the film and direct the CR to the sella turcica if the examination is for nontraumatic reasons. This is very important because the radiologist may have difficulty evaluating the sella turcica if it is projected with divergent rays. The sella is located at a point three-quarters of an inch anterosuperiorly to the external auditory meatus. For trauma, center the film and direct the CR to the center of the skull. Many radiographs of the skull and facial bones are made with the head in the true lateral position. Four examples are as follows:

- (1) Sella turcica—use a small cone field.
- (2) Sinuses—center the midpoint of the film and the CR to the outer canthus of the eye—take all sinuses with the patient erect to demonstrate fluid levels.

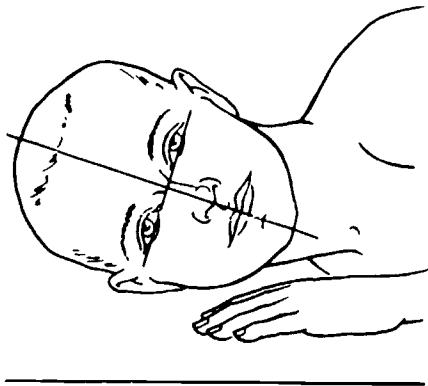


POSTERIOR ROTATION

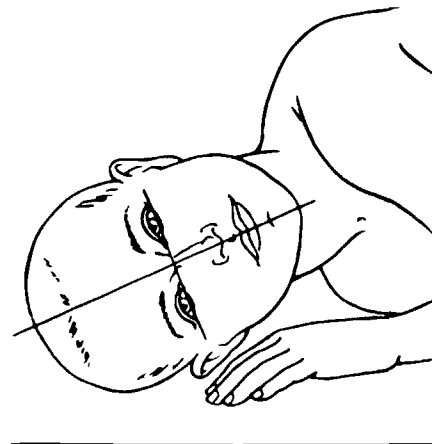


ANTERIOR ROTATION

Figure 8-1 Anterior and posterior rotation of the lateral skull



INFERIOR LONGITUDINAL  
ANGULATION



SUPERIOR LONGITUDINAL  
ANGULATION

Figure 8-2 Superior and inferior longitudinal angulation of the lateral skull



Figure 8-3. Photograph demonstrating the use of a rectangular piece of cardboard to align the medium plane of the skull parallel with the film.



Figure 8-4. Photograph demonstrating the use of a rectangular piece of cardboard to align the interpupillary line perpendicular to the film.

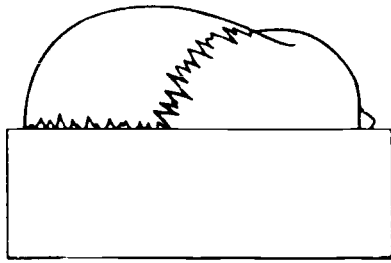


Figure 8-5 Using a rectangular piece of cardboard to align the median plane of the skull parallel with the film

- (3) Nasal bones—take both laterals.
- (4) Facial bones—center the film to the zygoma.

**Exercises (262):**

1. What positioning errors are you most likely to make when you are aligning the skull for the lateral? What errors are you least likely to make? Why?
2. In your own words, explain how you should position the skull in the true lateral position. Be specific. Tell what you would check and how you would go about it.
3. For a lateral projection of the sinuses, where is the film centered and to what point is the CR directed?
4. Name four examinations, other than a regular skull radiograph, that require the skull to be positioned in the true lateral position.

**263. Given a list of six pairs of structures demonstrated on a lateral projection of the skull, indicate whether they can show anterior or posterior rotation, superior or inferior longitudinal angulation, or both.**

To check the lateral radiograph of the skull for the true lateral position, there are several bony structures to look for. Refer to figure 8-6 as we discuss them. The orbital plates of the frontal bone and the lesser wings of the sphenoid bone appear on the radiograph as solid, dense lines extending from behind the frontal sinuses to just anterior to the sella turcica. These dense lines should appear superimposed over each other when the skull is in the true lateral position. If they are separated, the skull is angled longitudinally.

The anterior borders of the middle fossa (the greater wings of the sphenoid) should also appear superimposed over each other. If not, the skull is rotated anteriorly or posteriorly. These borders appear as a curved, dense line extending superoinferiorly about 1 inch anterior to the sella turcica.

The bilateral anterior and posterior clinoid processes of the sella turcica also should be superimposed. Depending on the direction of the displacement, they can indicate anterior or posterior rotation or longitudinal angulation of the skull.

The mandible can also help you determine if rotation or longitudinal angulation is present. Keep in mind that longitudinal rotation of the skull may be present on the radiograph even though the mandibular rami are superimposed over each other. Also, anterior or posterior rotation may be present, and the mandibular bodies may be superimposed over each other. In both cases, however, the second of the two mandibular parts does not appear superimposed.

**Exercises (263):**

1. Match the description of an improperly positioned lateral skull in column B with the bony structures that can be used to confirm the position in column A. Each column B item may be used once or more than once.

<i>Column A</i>	<i>Column B</i>
— (1) Posterior clinoid processes	a Anterior or posterior rotation
— (2) Mandibular bodies	b Superior or inferior longitudinal angulation
— (3) Anterior borders of the middle fossa.	c Both a and b above.
— (4) Anterior clinoid processes.	
— (5) Orbital plates of the frontal bone and lesser sphenoid wings	
— (6) Mandibular rami	

**264. Specify structures demonstrated in PA projections of the skull and the procedures for performing these projections; differentiate between the appearance of the PA skull and the Caldwell's projection.**

**PA Projections of the Skull.** There are two main PA projections of the skull that are widely used in radiology departments: The PA skull and the Caldwell's. The structures to be demonstrated determine the projection to be taken.

**PA skull.** The PA skull shows an anterior view of the cranium and facial bones with the petrous ridges superimposed over the lower three-fourths of the orbits. This position is preferred when the frontal bone is the main area of interest.

The PA skull, routine in most skull series, usually requires the patient prone with the nasion centered over the midline of the table. Ensure that both the orbitomeatal line and the median plane are perpendicular to the film. A

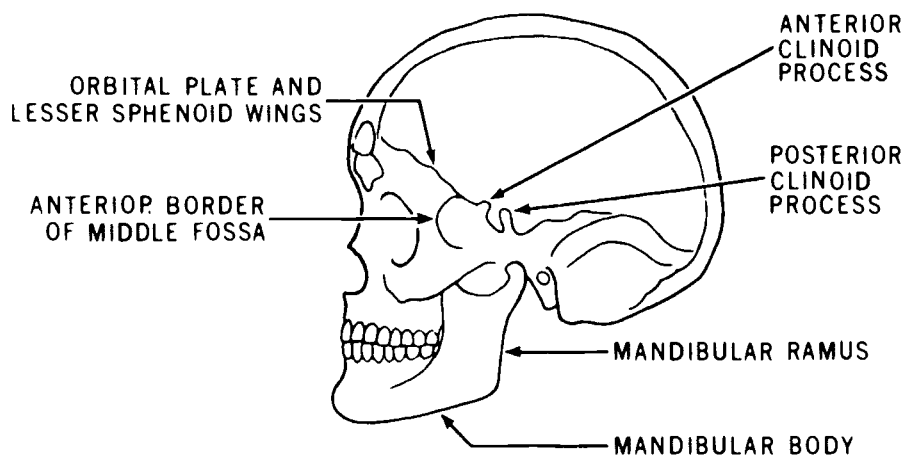


Figure 8-6 Structures visualized in a lateral projection of the skull

vertical CR is directed to the EOP, through the nasion, to the center of the film.

**PA Caldwell.** A Caldwell's projection is taken to demonstrate several bony structures of the skull. Among them are the upper two-thirds of the orbits, the frontal and temporal bones, anterior ethmoidal sinuses, frontal sinuses, and the greater and lesser wings of the sphenoid, which are projected in the upper third of the orbits. The petrous ridges are projected to the level of the lower margins of the orbits. This projection is used in sinus studies, but is also used as a general survey radiograph.

The patient is positioned in true PA skull position. For demonstration of sinus fluid levels, the patient must be erect. The CR is directed to the glabella at an angle of 15° caudad, providing that the orbitomeatal line is perpendicular to the film. If the glabellomeatal line is perpendicular to the film, then angle the CR 23° caudad (true Caldwell's). Caldwell's with 15° caudal CR angulation to the orbitomeatal line is referred to as the modified Caldwell's, but commonly called Caldwell's. The modified method is easier to perform, thus making it more widely used even though both methods produce identical results.

#### Exercises (264):

1. Give one instance when you should perform a straight PA projection of the skull.
2. Which radiographic positioning line and plane of the skull are perpendicular to the film for the PA skull?

3. Name several structures demonstrated by Caldwell's projection.
4. Differentiate between the position of petrous ridges in respect to the orbits in Caldwell's projection and in the PA of the skull.
5. What CR angle and direction should be used for modified Caldwell's?

#### 265. Differentiate between the Chamberlain-Towne's projection and the straight AP projection of the skull by specifying positioning procedures and demonstrated structures.

**AP Projections of the Skull.** Like the PA projections of the skull, there are two main AP projections that are commonly used in routine, general survey studies of the skull: the AP skull and the Chamberlain-Towne's.

**AP skull.** The AP skull has reverse part positioning from the PA skull. The median plane and orbitomeatal line are still perpendicular to the film, but the patient is supine instead of prone. The CR is still directed perpendicularly to the nasion. This position is used to demonstrate only the posterior portion of the cranial vault. It does not show the inferior portion of the occipital bone and, consequently, may not demonstrate a basilar skull fracture. However, the ease of positioning for this projection makes it advantageous to use for certain circumstances. Some of which are: infants and small children; elderly patients; seriously injured, unconscious, or intoxicated patients; and portable studies of the skull.

**Chamberlain-Towne.** The Chamberlain-Towne's projection, also a Grashey's position, is commonly called Towne's. It is an AP projection using an angled central ray of various degrees, depending upon the specific anatomy to be demonstrated. This projection is taken to visualize the occipital bone, the posterior portion of the parietal bones, the petrous ridges, the posterior portion of the foramen magnum, as well as other structures. It is especially useful in diagnosing basilar skull fractures, such as when a greater CR angle is used.

The Towne's projection that is routine with the average skull series requires the patient in true AP: median plane and orbitomeatal line are perpendicular to the film. The CR is then angled 30° caudad, entering at the hairline of the forehead and exiting at the EOP. The resultant radiograph presents a semiaxial (or half-axial) view of the skull.

When we speak of the tube angle for this projection, we actually mean the angle formed by the CR and the orbitomeatal line. The standard position of the head for this projection, as you know, requires the orbitomeatal line to be perpendicular to the film. When such is the case, we can say that the specific CR angle used is a certain number of degrees (30°) from vertical. At times, however, it is not possible to position the orbitomeatal line perpendicular to the film because of the patient's condition. Such is the case with a kyphotic patient, or the obese patient with rounded shoulders. These situations require a compensatory adjustment of the CR. Therefore, when the orbitomeatal line cannot be perpendicular to the film, position the skull with the infraorbitomeatal line perpendicular to the film and angle the CR 37° instead of 30°. Since there is a 7° difference between the orbitomeatal and infraorbitomeatal lines, the increase of CR angulation still projects the CR through the skull at the same angle (to the orbitomeatal line); thus, resulting in virtually identical radiographs. Figure 8-7 shows these angles.

A variation from the routine Towne's is used to demonstrate selected structures. To visualize the entire foramen magnum and jugular foramina, angle the CR 50° to 60° with the orbitomeatal line perpendicular. The greater CR angle also can show basilar skull fractures.

#### Exercises (265):

1. Name and describe the projection used to demonstrate the posterior portion of the cranial vault.
2. What is the major difference of tube-part-film alignment between the AP skull and the routine Towne's positions?
3. What patients or situation justify the use of an AP instead of a PA skull?

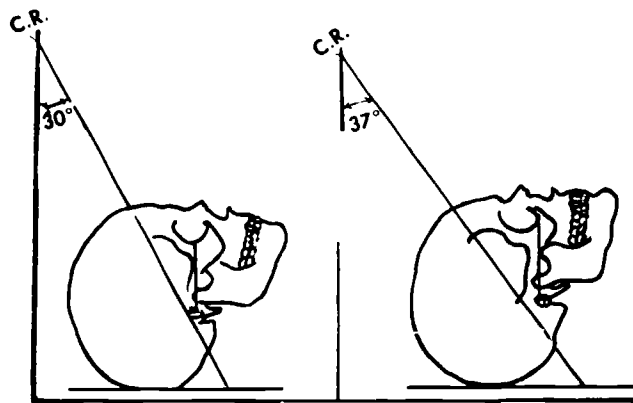


Figure 8-7 Central ray angulations for Chamberlain-Towne projections.

4. Briefly describe the part positioning and CR angulation for the routine Towne's projection.
5. A large patient with rounded shoulders is unable to get the orbitomeatal line perpendicular to the film. What should you do to get a Towne's view on this patient?
6. If the skull is in the standard AP position, what CR angulation and direction should be used to demonstrate the petrous ridges? To demonstrate the posterior portion of the foramen magnum?
7. What projection described in the text should not be used to demonstrate a basilar skull fracture?

**266. Name eight structures demonstrated by the verticosubmental or submentovertical projections of the skull, and specify positioning procedures for these projections.**

**Submentovertical (SMV) and Verticosubmental (VSM) Projections.** These projections are so named because of the central ray projection. For example, the submentovertical (also called submentoververtex) has the CR enter the base of the skull below the mental symphysis of the mandible (submento-) and exit at the top of the skull (-vertex). Both projections (also called basal projections) are used to demonstrate various structures of the skull and facial bones. Among them are sphenoid and ethmoid sinuses, external and internal auditory meati, mastoid areas, base of the skull, mandible, and zygomatic arches.

The structures are best demonstrated if the skull is positioned so that the infraorbitomeatal line is parallel with



the film, as shown in figure 8-8. Depending upon the patient's ability to cooperate, it is sometimes difficult to achieve this position with the SMV projection and impossible with the VSM projection. Therefore, direct the CR perpendicularly to the infraorbitomeatal line in all cases.

The best basal view of the skull is obtained with the SMV projection. To achieve the desired position of the head and to make the position more comfortable for the patient, perform this projection while the patient is sitting. If you use the recumbent position, elevate the patient's trunk on pillows or pads.

#### Exercises (266):

1. Name eight structures or pairs of structures that are demonstrated by the verticosubmental or submentoververtical projections of the skull.
2. Which of the two projections discussed in the text best demonstrates the structures in exercise 1?
3. How should the submentoververtical projection be done and why?
4. What is the CR-orbitomeatal line relationship for all basilar projections?

## 8-2. Positioning for the Sinuses

When we think of skull positioning, the basic projections that we covered in the first section of this chapter come to mind. Those are the positions that are generally used for survey studies or routine examinations of the skull, even though some structures are specifically demonstrated in a

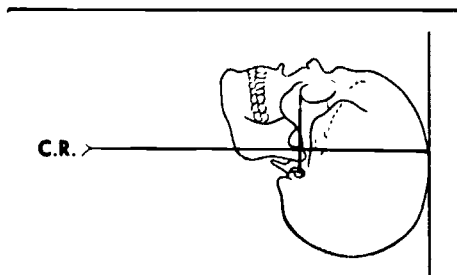


Figure 8-8 Submentoververtical projection of the skull.

particular projection. Once we leave the basic projections of the skull, we enter an area that involves "special" positions that demonstrate specific, instead of general, structures. Views of the sinuses are examples of skull positioning for definite structures.

### 267. Differentiate positioning of the sinuses by listing structures that are demonstrated and positioning procedures.

**The Sinus Positions.** A routine sinus series usually includes Caldwell's, Waters', lateral, and either SMV or Pirie's positions.

**Caldwell's projection.** Since we already covered this projection in our basic projections of the skull, we won't go into detail with it at this time. Although either Caldwell projection may be used, the modified method (CR angled 15° caudad and the orbitomeatal line perpendicular to the film) is usually preferred. As with all projections for sinuses, the patient must be sitting (or standing) to demonstrate any fluid levels within sinus cavities. Caldwell's is taken to demonstrate the frontal sinuses.

**Waters' position.** Waters' projection of the skull demonstrates most of the facial bones, the orbits, the maxillary sinuses, the frontal and ethmoidal sinuses, and various other structures. It is the best position for demonstrating the maxillary sinuses and, while the ethmoidal and frontal sinuses are somewhat distorted, they are fairly well seen.

One of the more common errors made in positioning the patient for the Waters' is the improper alignment of the orbitomeatal line. When this positioning line forms a 37° angle with the table (and film), the petrous ridges will be projected below the floor of the maxillary sinuses. An angle of more than 37° may superimpose petrous ridges over maxillary sinuses; thus obscuring fluid levels or sinusitis. If the angle is decreased excessively, maxillary sinuses are foreshortened, which also fails to demonstrate the antral floors. The CR is perpendicular to the center of the film, directed through the acanthion.

**Lateral position for sinuses.** Patient positioning for a lateral view of the sinuses requires the median plane parallel with, and the interpupillary line perpendicular to the film. Since this is the only position that adequately demonstrates all four sets of sinuses, it is important that the central ray be perpendicular to the center of the film and directed through the outer canthus of the orbit away from the film. Keeping in mind that structures nearest the film are best detailed, always do the lateral that best demonstrates the patient's problem sinuses.

**Submentoververtical position.** This is the same position used in the basic study of the skull. It is used as part of a sinus series to demonstrate sphenoid and ethmoid sinuses. The SMV (or its cousin, the VSM) usually is preferred over the Pirie position even though both projections visualize sphenoid sinuses.

**Pirie's position.** The Pirie position is used to demonstrate sphenoid sinuses, and is also called the open-mouth sphenoid projection because the sphenoid sinuses are projected through the open mouth of the patient.

Perhaps the easiest way to perform this position is to begin by positioning the patient like you would do for the Waters'. The patient's mouth is then opened wide and centered to the film. The central ray is angled slightly caudad and projected through the sella turcica and the open mouth.

#### Exercises (267):

1. Describe briefly the Caldwell projection that is usually preferred in sinus studies.
2. Which sinuses are best demonstrated in the Caldwell projection?
3. How should sinus films be taken? Why?
4. What is the best position for demonstration of maxillary sinuses?
5. What is probably the most common error of patient positioning in the Waters' position?
6. How can you tell by looking at a radiograph that the orbitomeatal line is considerably more than 37° with the table?
7. A Waters' radiograph shows foreshortening of the maxillary sinuses. What specific error of positioning caused this situation?
8. Which projection best demonstrates all four sets of sinuses?
9. Which lateral should you perform on a patient that has sinusitis of the right maxillary sinus? Why?
10. Which sinuses are demonstrated in the submentovertical position?

11. Which position projects the sphenoid sinuses through the open mouth of the patient?
12. Explain how the central ray is projected for the open mouth position.

### 8-3. Mastoids and Internal Auditory Canals

There are many projections that demonstrate the mastoids and internal auditory canals (IACs). Some of the basic projections of the skull, such as Chamberlain-Towne's and the submentovertical already covered, demonstrate them and are used in various departments. Also, some radiologists require extra views to complement basic skull projections. Some additional views include Law's, Stenver's, Arcelin's, Mayer's, and Schuller's projections.

**268. Specify some significant features about the techniques for increasing details on radiographs of the mastoids and internal auditory canals.**

**Standard Procedures.** Before discussing the specific projections, let's examine some standard procedures to follow with all "mastoid" projections. Tape the patient's ears forward on oblique and lateral projections to prevent the superimposition of soft tissue shadow over the area under study. The structures are somewhat difficult to demonstrate in the first place and, even though the shadow cast by the ear is minimal, it does obscure detail.

The standard rule to cone down to the smallest field size possible is important. Film fog due to excessive secondary and scatter radiation is particularly detrimental to film quality where such small structures as in the mastoid area are examined.

Use the small focal spot to provide better detail when possible. If the patient is comfortable in this position and you have the head properly immobilized, the longer exposure will not be a problem.

Some radiologists prefer to use medium- or slow-speed screens for these examinations to further increase detail. Since slower screens increase the radiation dose to the patient, they should be used only at the direction of the radiologist.

#### Exercises (268):

1. Why should the patient's ears be taped forward for oblique and lateral projections?

2. A collimated field of what relative size should be used and why?
3. When can you use a small focal spot and the resultant long exposure?
4. Should you decide what type of screens to use? If not, who should?

position. Adjust the head so that the infraorbitomeatal line is parallel with the long axis of the film on all Law's projections. Angle the CR  $15^\circ$  toward the feet and  $15^\circ$  toward the face (see fig. 8-9). Direct the CR to a point about 2 inches superior to and 2 inches posterior to the external auditory meatus farthest from the film. The CR should exist from the skull at the lower mastoid process. This projection should not be taken with a grid because the  $15^\circ$  angle toward the face is across the lead strips and causes considerable grid cutoff. Consequently, the use of a small cone field to reduce secondary and scatter radiation takes on added significance.

### 269. Identify characteristics of Law's projection.

**Law's Projection.** There are three different methods for performing Law's projection. All three demonstrate basically the same structure, a lateral view of the mastoid.

The first projection, which we will call the tube-tilt projection, is made with the head in the true lateral

The second projection, which we will call the combination tube-tilt, part-rotation projection, is made with the CR angled  $15^\circ$  caudad and the face rotated  $15^\circ$  toward the table (see fig. 8-10). The angle of the part eliminates the requirement to angle the tube toward the face. It also permits the use of a grid, since the CR is not directed across the lead strips as in the basic projection. This position is also a little more comfortable for the patient than the tube-tilt projection because the head is in a more natural, relaxed position, preventing part motion on the radiograph.

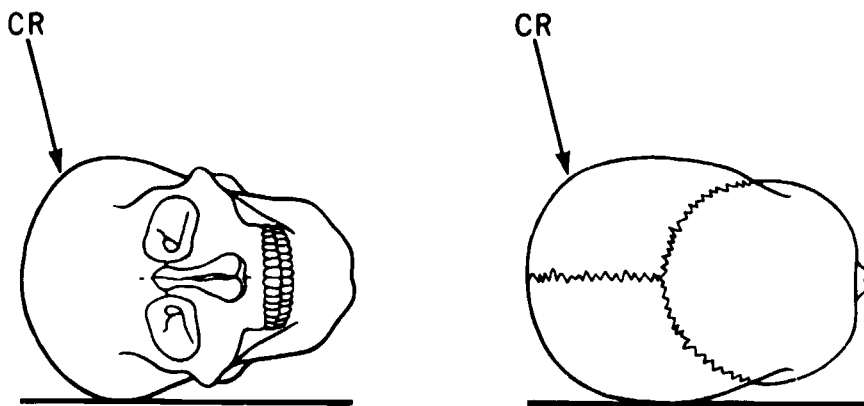


Figure 8-9 Law's tube-tilt projection

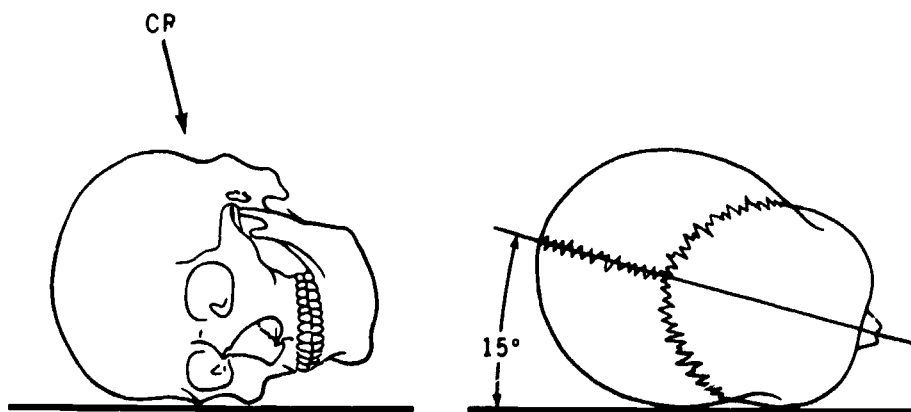


Figure 8-10. Law's combination tube-tilt, part-rotation projection

The third projection, which we will call the part-rotation projection, is made with the CR vertical and the head rotated 15° toward the face and tilted 15° longitudinally toward the feet, as seen in figure 8-11. This position is the most comfortable of the three for the patient. Obviously, the vertical CR presents no grid cutoff problems.

#### Exercises (269):

- Match the Law's projection in column B with the appropriate statement in column A. Each column B item may be used once or more than once.

Column A	Column B
___ (1) Vertical CR	a Tube-tilt method.
___ (2) Do not use a grid	b Combination tube-tilt, part-rotation method
___ (3) Small cone field most important	c Part-rotation method
___ (4) CR angled 15° caudad	
___ (5) Face rotated 15° toward table	
___ (6) Double angle of head	
___ (7) Tube angled 15° caudad and 15° toward face	
___ (8) Most comfortable for patient	
___ (9) Least comfortable for patient	

270. Given descriptions of hypothetical clinical situations requiring Stenver's and Arcelin's projections, specify the position or procedure required.

**Stenver's and Arcelin's Projections.** The Stenver's and Arcelin's projections are similar in that they are made with the petrous ridge parallel with the film. Before we discuss the actual positions, first look at the petrous ridges as they are situated in the three types of skulls. Refer to figure 8-12 as you study.

Notice the overall shape of each skull. The brachycephalic skull is short from front to back and wide from side to side. Also, notice the angle that the petrous ridges form with the median plane—55°. The mesocephalic skull is the most common or average type with the petrous ridges forming a 45° angle with the median plane. The third and last skull type, the dolichocephalic, is long from front to back and narrow from side to side. The petrous ridges in this skull form the most acute angle, 36°, of the three.

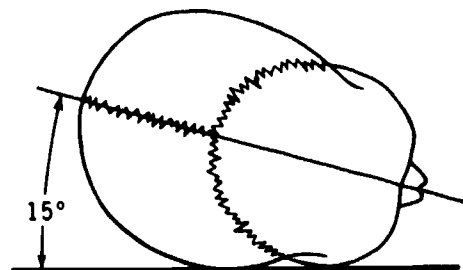
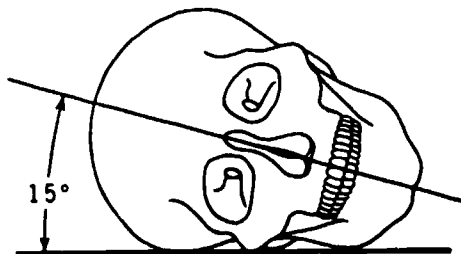


Figure 8-11. Law's part-rotation projection.

As you can imagine, to place the petrous ridges parallel with the film, you must consider the type of skull with which you are dealing. In all cases, rotate the face to the left to examine the right petrous ridge and rotate the face in the opposite direction to demonstrate the left petrous ridge.

Now, back to the Stenver's and Arcelin's projections. Both are made with the head rotated so that the petrous ridge being examined is parallel with the film. Also, the infraorbitomeatal line is parallel with the upper border of the film for both projections. From this point on, differences in positioning become apparent. For example, refer to figure 8-13 of a Stenver's position. Note that when the median plane is 45° to the film, then the petrous ridge of the side closest to the film is parallel with the film. This is routine with the most common type of skull, the mesocephalic. The brachycephalic requires less rotation and the dolichocephalic requires more rotation than the usual 45° Stenver's. Notice that soft tissue structures of the forehead, the nose, and the zygoma are in contact with the table; this is why this PA oblique position of the skull is called a three-point landing. The CR is always angled 12° cephalic for the Stenver's position, regardless whether the median plane is the usual 45° or the variations of 35° or 54°.

The Arcelin position is sometimes called the reverse Stenver's because it produces a radiograph similar to a Stenver's. Notice in figure 8-14 that the skull is in an AP oblique and the CR is angled 10° caudad. Also, the petrous ridge away from the film is parallel to the film. Although the Arcelin's increases the part-film distance slightly more (about 2 cm.) than Stenver's, it is not too much to cause an appreciable loss of detail. Therefore, Arcelin's is a preferred position when demonstrating petrous ridges on children or when patients are unable to maintain the Stenver position.

#### Exercises (270):

A patient with a brachycephalic skull requires a repeat Arcelin's projection of the right petrous ridge. Based on the information in the text, answer exercises 1 through 4 below.

- Is the projection PA or AP?
- What is the CR angulation and direction?

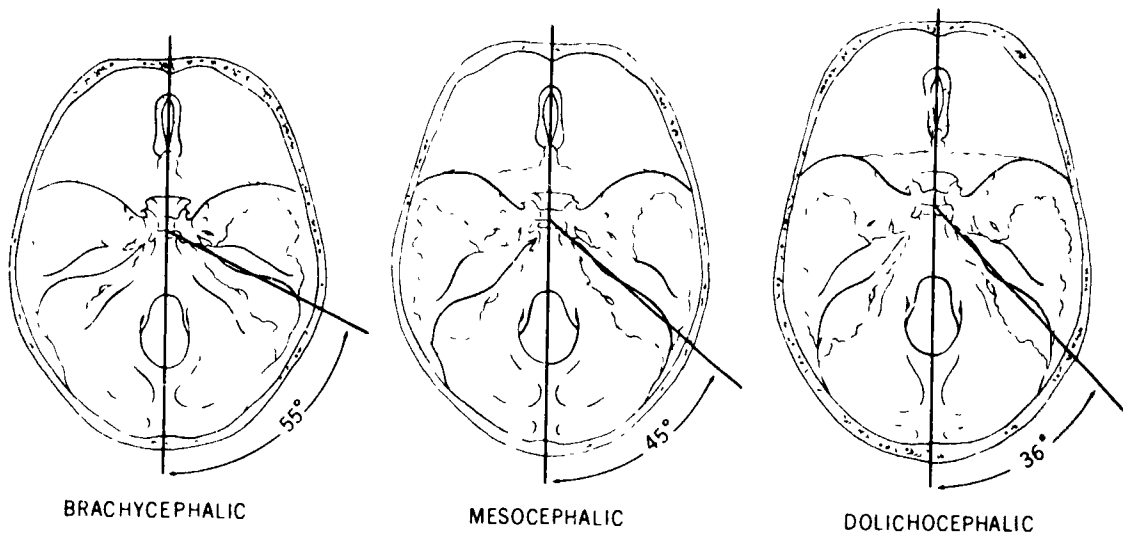


Figure 8-12 The types and shapes of skulls showing the angle formed by the median plane and petrous ridge

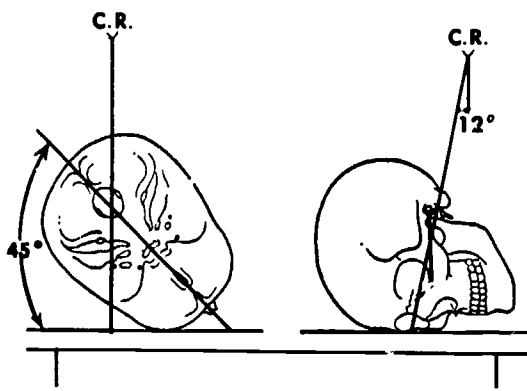


Figure 8-13. The Stenvers' projection

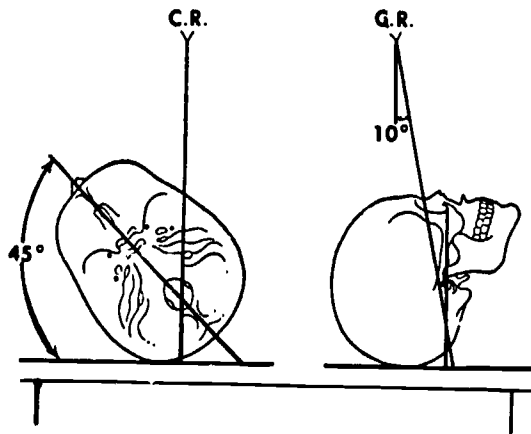


Figure 8-14. The Arcelin projection

3. In what direction is the face rotated?

4. How many degrees is the head rotated?

A patient with a mesocephalic skull requires a repeat Stenver's projection of the left petrous ridge. Based upon the information presented in the text, answer exercises 5 through 8 below.

5. Is the projection PA or AP?

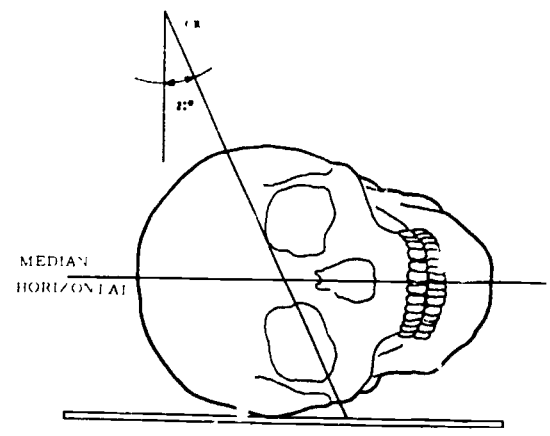
6. What is the CR angulation and direction?

7. In what direction is the face rotated?

8. How many degrees is the head rotated?

A patient with a dolichocephalic skull requires Stenver's projections of both petrous ridges. Based upon the information presented in the text, answer exercises 9 through 12.

9. In which direction is the face rotated to radiograph the right petrous ridge?
10. In which direction is the face rotated to radiograph the left petrous ridge?
11. How many degrees is the head rotated to demonstrate the left petrous ridge?
12. How many degrees is the head rotated to demonstrate the right petrous ridge?



**271. Identify characteristics of Mayer's and Schuller's projections.**

**Mayer's and Schuller's Projections.** Mayer's projection usually is used to demonstrate the mastoid process and petrous ridge of the side nearest the film. It is sometimes referred to as the 45-45 projection because the median plane forms a 45° angle and the central ray is angled 45° (see fig. 8-15).

Mayer's projection is made with the patient supine. Position the head so that the face is rotated 45° toward the mastoids under study. Flex the chin so that the infraorbitomeatal line is parallel with the transverse axis of the film. Direct the CR through the external auditory meatus of the side (lower) being examined, at an angle of 45° caudad.

For Schuller's projection, place the head in the true lateral position. Flex the chin so that the infraorbitomeatal line is parallel with the transverse axis of the film. Direct the CR 25° caudad through the external auditory meatus of the side nearest the film (the side being examined). Figure 8-16 is an example of this Schuller's position.

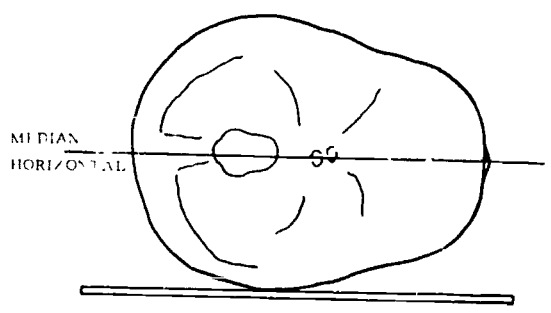


Figure 8-16 Schuller's projection

The Schuller's projection is commonly used in a mastoid series because it produces an excellent lateral view of the mastoid process closest to the film. It is also used to demonstrate temporal mandibular joints (TMJs) in the open- and closed-mouth positions.

**Exercises (271):**

1. Match the projection in column B with the characteristic in column A. Each column B item may be used more than once. In addition, both column B items may apply to a single characteristic in column A.

Column A	Column B
— (1) Lateral.	a Mayer's
— (2) CR 25° caudad	b Schuller's
— (3) Oblique	
— (4) Infraorbitomeatal line parallel with transverse axis of film	
— (5) CR 45° caudad.	
— (6) 45° rotation of head	
— (7) Side being examined is nearest the film	

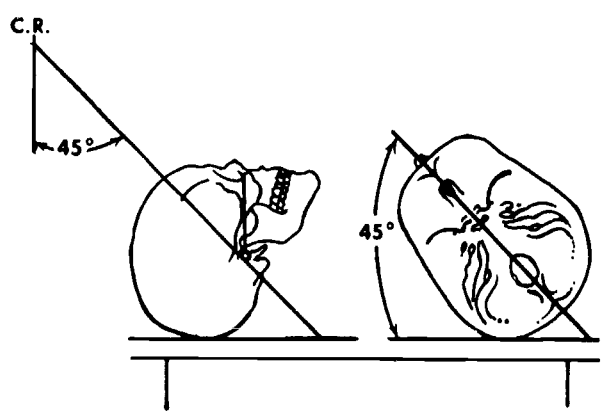


Figure 8-15. Mayer's projection

## 8-4. Orbits and Facial Bones

In this section, we emphasize some special views and significant points of some additional projections of the skull. We continue our study with positions for demonstrating orbits, specifically optic foramina, and positions for various facial bone studies, such as zygomatic arches and the mandible.

**272. Compare the PA and AP Rhese projections of the optic foramina as to their demonstration of the optic foramen, and the degree and direction of rotation of the patient's head.**

**The Rhese Projections.** Rhese projections are included in studies of orbits to give the radiologist views of the orbital rim and optic foramen (optic canal). Other films that may be included (such as Caldwell's or Waters') usually don't present positioning difficulties that are inherent of a Rhese position. To properly visualize the optic foramen, precise skull positioning is necessary.

**PA Rhese.** The best Rhese projection for the optic foramen is made with the patient prone, resting the head with the nose, the zygoma, and the chin of the affected side touching the table. Adjust the head until the acanthomeatal line is perpendicular to the plane of the film. Rotate the posterior portion of the head toward the side under study as shown in figure 8-17. The median plane should form a  $53^\circ$  angle with the plane of the film or a  $37^\circ$  angle with a vertical plane. Since this positions the optic foramen in the inferolateral quadrant of the orbit, you should center the film to, and direct the perpendicular (vertical) CR to, this point.

**AP Rhese.** The Rhese projection can be made with the patient supine (AP) if the prone (PA) position cannot be used. If this is the case, there is an increase of about 2 inches in the part-film distance and resultant magnification on the radiograph. Still, though, this is easier to position with young children.

The AP Rhese is made in the same way as the PA Rhese, except that the patient is supine. You still need to place the median plane at an angle of  $53^\circ$  to the film, as shown, in figure 8-18. Notice that the acanthomeatal line is still considered vertical to the film. Direct the perpendicular CR through the orbit to the center of the film. This position demonstrates the orbit and optic foramen that is farthest from the film (the side that is up).

### Exercises (272):

1. Which projector, PA or AP, shows the optic foramen magnified and why?
2. If you are using PA projections of the optic foramina, how many degrees and in what direction should the head be rotated for the left foramen?
3. If you are using AP projections of the optic foramina, how many degrees and in what direction should the head be rotated for the right optic foramen?

**273. Given four line drawings representing radiographs of the optic foramina, evaluate them for the proper head position.**

If the skull is correctly positioned for the Rhese projection, the optic foramen appears in the approximate center of the lower outer quadrant of the orbit. More than  $53^\circ$  rotation projects the foramen medially from the normal location and less than  $53^\circ$  rotation projects it laterally. Flexion of the head beyond the correct acanthomeatal-film relationship projects the foramen superior to the normal location. Overextension projects it inferior to the normal location.

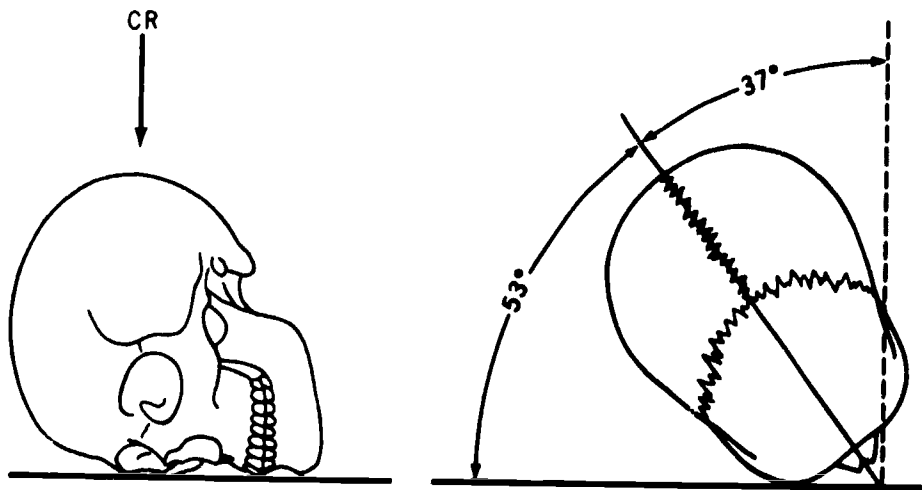


Figure 8-17. The PA Rhese projection

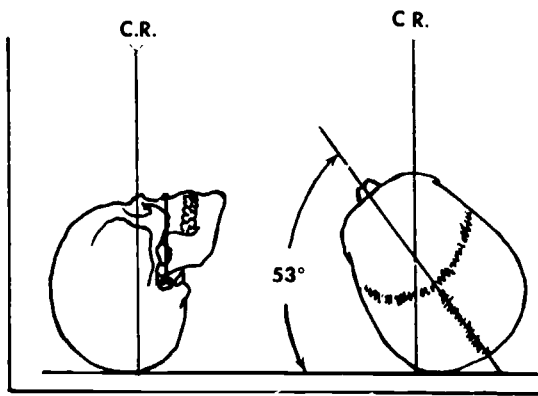


Figure 8-18. The AP Rhese projection

1. Drawing A.
2. Drawing B
3. Drawing C.
4. Drawing D.

**Exercises (273):**

Figure 8-19 represents line drawings of four optic foramina radiographs, with the circles inside the orbits representing the foramina. Indicate below in the appropriate space whether or not the position is correct. If not, describe how the position is "off."

**274. Explain positioning procedures for demonstrating zygomatic arches.**

**Positioning for Zygomatic Arches.** You will recall that the submentovertical and verticosubmental (basal) projections demonstrate the zygomatic arches. At times, one of these projections reveals each zygomatic arch clear

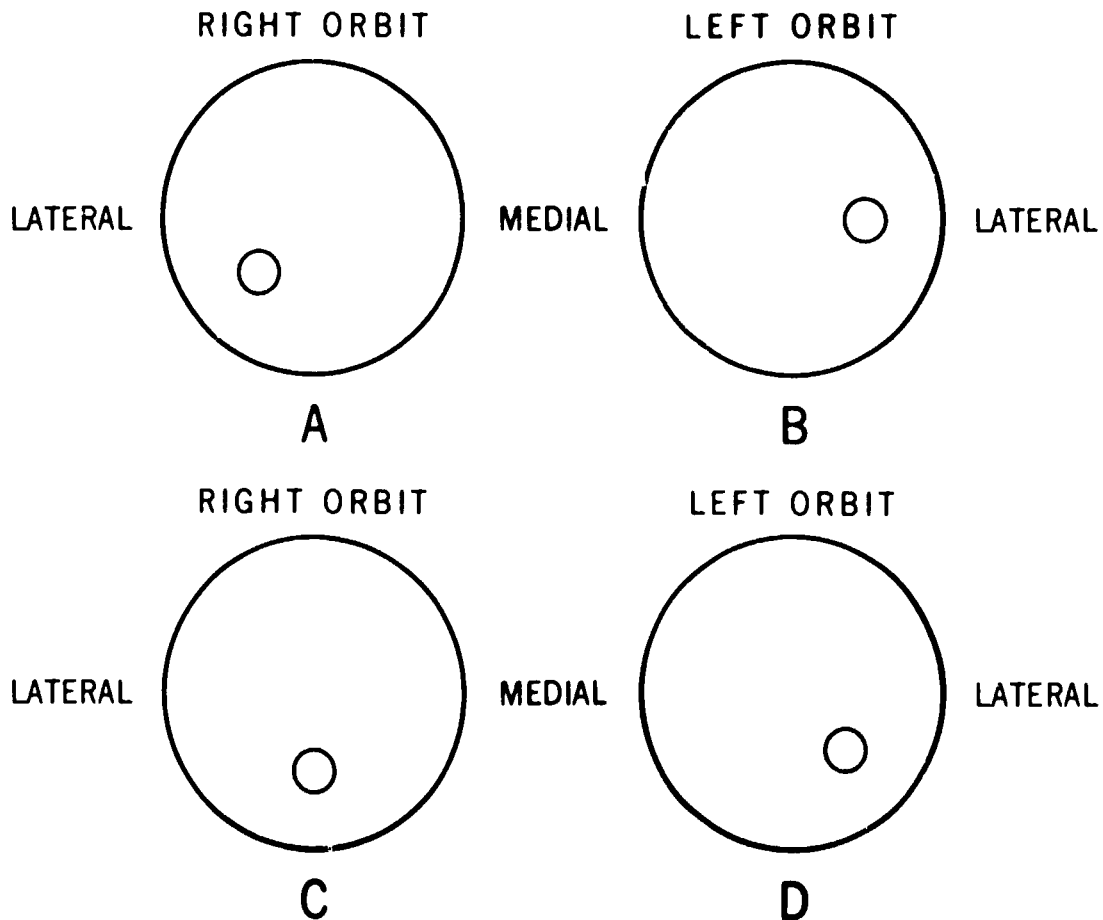


Figure 8-19. Objective 273, exercises 1 through 4



of superimposed structures and no further studies are required. Sometimes, however, the arches do not protrude enough from the side of the face to be visualized simultaneously on a basal projection. When this is the case, they should be radiographed one at a time.

To demonstrate arches individually, you need to use a variation of the basic submentovertical or the verticosubmental projection. The positioning procedures remain basically the same except that the top of the head should be tilted about 15° away from the arch under study for both projections. We can also say "tilt the mandible toward the side under study." Notice that we said "tilt the head." This does not mean to rotate the head. To see the difference, refer to figure 8-20. Detail A is an inferior view of the skull. Detail B shows the skull rotated 15°. Notice that the relationships between zygomatic arches and the skull do not change. Detail C shows the top of the head tilted 15° toward the right side. This movement throws the left zygomatic arch farther away from the side of the head allowing visualization of the entire structure without superimposition.

When a verticosubmental position is tilted 15° for zygomatic arches, the projection becomes known as the

May's position. Proper alignment of the CR and the infraorbitomeatal line are very important in both the May's projection and the variation of the SMV. Be sure to direct the CR perpendicularly to the infraorbitomeatal line, which should be parallel with the film. The line is parallel with the zygomatic arch, and if the CR-infraorbitomeatal line relationship is not maintained, the arch will appear foreshortened on the radiograph. The best results are obtained if the head is adjusted so that the infraorbitomeatal line is parallel with the film. If the head is not properly adjusted and the CR is perpendicular to the infraorbitomeatal line, the zygomatic arch is elongated. This distortion must be tolerated at times, however, since some patients cannot achieve the desired position.

#### Exercises (274):

1. In your own words describe the movement of the head for radiographing the zygomatic arches one at a time.

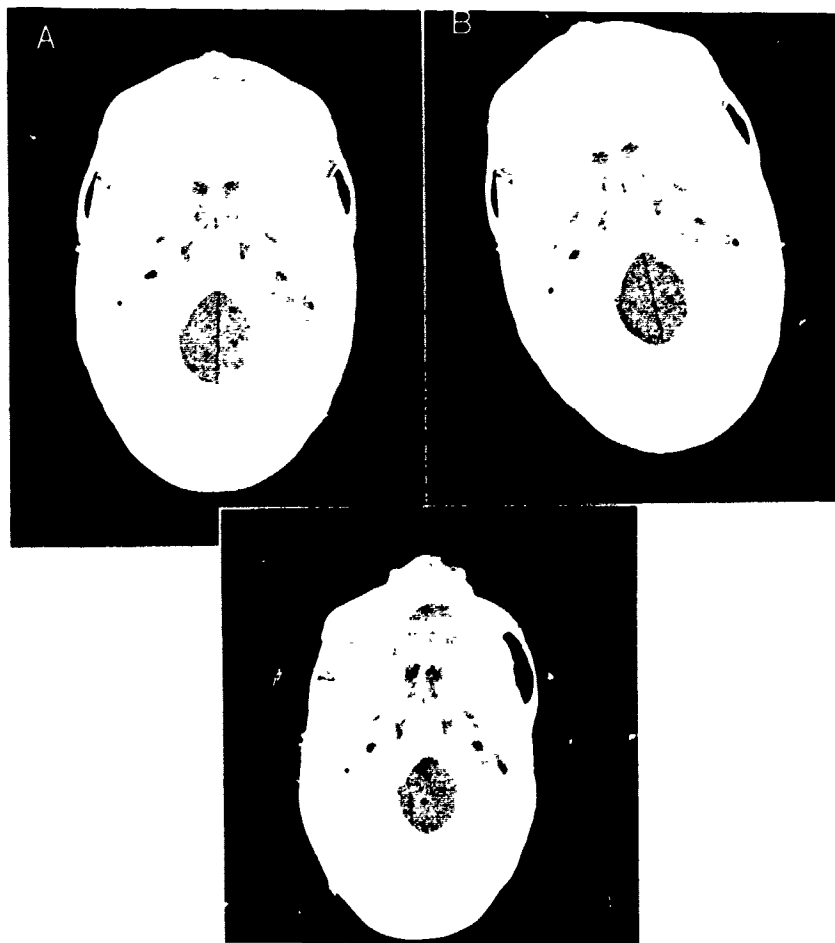


Figure 8-20. Inferior views of the skull showing the proper method to project the zygomatic arch away from the skull.

2. How should the head be tilted for a submentovertical projection of the right zygomatic arch? For a verticosubmental projection of the right zygomatic arch?
3. How many degrees should the head be tilted to individually radiograph the zygomatic arches?
4. Why should the CR be directed perpendicularly to the infraorbitomeatal line?
5. If the infraorbitomeatal line-film relationship is not maintained, what is the effect on the radiograph? Is this effect sometimes acceptable? If so, under what conditions?

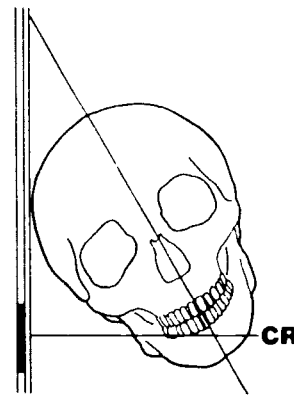


Figure 8-21 Lateral oblique of the mandible

the median plane forms approximately a 30° angle with the film. This tilting of the head prevents the side of the mandible away from the film from superimposing the side nearest the film. In this lateral oblique, the CR is perpendicular to the film.

#### 275. Explain characteristics of positions that demonstrate the mandible.

**The Mandible.** In most cases, a mandible series includes a PA projection and both lateral obliques.

**PA mandible.** Usually, the PA projection is standard because it offers a full anterior view of a mandible with emphasis on the rami. The skull is positioned as for a PA skull with the median plane perpendicular to the film. If this plane is slightly rotated, the mandible will appear slightly obliqued. Some radiologists prefer the chin touching the table (or film cassette) to decrease the OFD to a minimum. Unfortunately, a portion of the mandibular body is obscured by superimposition of cervical vertebrae.

**Lateral oblique mandible.** There are various ways that you can obtain a lateral oblique view of the mandible. Regardless of the method preferred in your department, projections showing both sides of the mandible should always be taken even though only one side may be affected by trauma.

One method requires the patient supine with the head true lateral and resting on a cassette supported by sandbags. It may be necessary to oblique the patient's trunk slightly. The mandible is centered to the film and the lower border of the mandible should be parallel with the lower border of the film. The CR should be angled 30° cephalic to prevent superimposing both sides of the mandible.

Another method requires part angulation instead of CR angulation. Notice in figure 8-21 that the head is tilted until

#### Exercises (275):

1. Why is a PA projection usually included in a standard series of the mandible?
2. A radiograph of a PA projection shows the mandible slightly obliqued. What was the probable cause of this error?
3. Why does the CR have to be angled 30° cephalic for a lateral oblique view of the mandible when the head is true lateral?
4. How many degrees is the median plane tilted in the part-angulation method of obtaining a lateral oblique of the mandible?

## ANSWERS FOR EXERCISES

### CHAPTER 1

**Reference:**

- 200 - 1 T  
 200 - 2 F The ileum is distal to the jejunum.  
 200 - 3 T  
 200 - 4 T  
 200 - 5 F The radius is lateral to the ulna  
 200 - 6 T  
 200 - 7 T
- 201 - 1 (1) b  
 (2) c  
 (3) a  
 (4) d  
 (5) a
- 202 - 1 T  
 202 - 2 F The third toe has three phalanges  
 202 - 3 F The first toe has only two phalanges  
 202 - 4 F The base of the distal phalanx articulates with the head of the middle phalanx in the fourth toe  
 202 - 5 T.  
 202 - 6 T  
 202 - 7 T.  
 202 - 8 T  
 202 - 9 F Each metatarsal joins with another metatarsal  
 202 - 10 T  
 202 - 11 F The first cuneiform is on the medial side  
 202 - 12 F The calcaneus is the largest tarsal bone  
 202 - 13 T  
 202 - 14 T.  
 202 - 15 T  
 202 - 16 F The sustentaculum tali is on the calcaneus  
 202 - 17 F. There are 26 bones of the foot and toes
- 203 - 1. Talus, tibia, and fibula  
 203 - 2 Tibia.  
 203 - 3 Fibula  
 203 - 4. They are important for weight bearing and mobility and attempts are made to maintain them during treatment of injuries  
 203 - 5 Diarthrodial or hinge-type joint
- 204 - 1. Tibia and fibula  
 204 - 2 Fibula  
 204 - 3. Medial malleolus.  
 204 - 4. Interosseous crest  
 204 - 5. Superior articular surface, medial and lateral condyles, intercondylar eminence, tibial tuberosity  
 204 - 6 On the tibial tuberosity  
 204 - 7 Lateral malleolus  
 204 - 8 Proximal  
 204 - 9 On the fibular head  
 204 - 10 The tibia
- 205 - 1 (1) b.  
 (2) a  
 (3) c  
 (4) e  
 (5) d  
 (6) a  
 (7) b
- 206 - 1 Linea aspera
- 206 - 2 A triangular-shaped area on the posterior side of the distal humerus  
 206 - 3 Posterior  
 206 - 4. Superior and medial  
 206 - 5 Head.  
 206 - 6. Yes  
 206 - 7 Fovea capitis
- 207 - 1 T.  
 207 - 2 F Extends from the ASIS to the PSIS  
 207 - 3 T  
 207 - 4 T  
 207 - 5 T.  
 207 - 6 F The lesser sciatic notch is located on the ischium  
 207 - 7. T  
 207 - 8 T  
 207 - 9 T  
 207 - 10 F The pubic arch is formed by the inferior ramus of the pubis and the ramus of the ischium  
 207 - 11 T  
 207 - 12 T  
 207 - 13. T  
 207 - 14 F The sacrum and coccyx form the posterior margin of the true pelvis
- 208 - 1 Five  
 208 - 2 The first The fifth  
 208 - 3 Posterior  
 208 - 4. The fifth lumbar  
 208 - 5. The first coccygeal  
 208 - 6. Iliac; sacroiliac joints  
 208 - 7 An oval articular surface located on the body of the first sacral vertebra  
 208 - 8 Posteriorly  
 208 - 9. Four  
 208 - 10 Lines that mark the former separations of the coccygeal vertebrae.  
 208 - 11 Coccygeal cornua  
 208 - 12. Base, apex
- 209 - 1 Body, base, and head  
 209 - 2. The first (thumb)  
 209 - 3 Fourteen.  
 209 - 4 Middle phalanx, fourth digit  
 209 - 5 Distal. Proximal  
 209 - 6. Fourth.  
 209 - 7. Distal  
 209 - 8 Eight.  
 209 - 9 Greater and lesser multangulars, capitate, and hamate  
 209 - 10 Navicular, lunate, triquetrum, and pisiform  
 209 - 11 Pisiform  
 209 - 12 Capitate.
- 210 - 1 (1) a  
 (2) b  
 (3) b  
 (4) b  
 (5) a  
 (6) b  
 (7) b
- 211 - 1 F Located on the posterior humerus  
 211 - 2 T  
 211 - 3. F Located on the lateral humerus

- 211 - 4 F The medial epicondyle is more prominent
- 211 - 5 F The deep depression is the olecranon fossa
- 211 - 6. T.
- 211 - 7. F Articulates with the trochlea
- 211 - 8. F The olecranon process fits into the olecranon fossa when the elbow is extended
  
- 212 - 1. Surgical neck—the constricted portion of the humerus below the tuberosities.
- 212 - 2. Lesser tuberosity—bony eminence on the anterior surface.
- 212 - 3 Greater tuberosity—rounded eminence on the lateral side
- 212 - 4 Bicipital groove—deep furrow between the tuberosities
- 212 - 5 Anatomical neck—the portion that connects the head with the shaft
- 212 - 6. Head—uppermost portion
  
- 213 - 1 Sternal end. Acromial end
- 213 - 2. Coracoid tuberosity and costal tuberosity
- 213 - 3. Subscapular fossa.
- 213 - 4 A projecting plate of bone that extends superlaterally from the vertebral border on the posterior side
- 213 - 5 Above—supraspinatus fossa  
Below—infraspinatus fossa
- 213 - 6 Superior border
- 213 - 7 Inferior angle
- 213 - 8. Acromion process.
- 213 - 9. Glenoid fossa.
- 213 - 10 Coracoid process.
- 213 - 11 Enarthrodial or ball and socket
- 213 - 12 The head of the humerus and the glenoid fossa of the scapula
- 213 - 13 The acromion process of the scapula and the distal end of the clavicle

CHAPTER 2

- 214 - 1 Five
- 214 - 2 Body.
- 214 - 3 Posterior to the sides of the vertebral body
- 214 - 4 Lamina
- 214 - 5 The superior articular processes of the fifth lumbar vertebra
- 214 - 6 Spinous process
- 214 - 7 Two
- 214 - 8 Annulus fibrosus Nucleus pulposus
- 214 - 9 Between the bodies of the vertebrae
- 214 - 10 Apophyseal joints.
- 214 - 11. The fifth lumbar vertebra and the sacrum
  
- 215 - 1 T
- 215 - 2 F Costal articular facets are only located on the transverse processes of T-1 through T-10
- 215 - 3 T
- 215 - 4 F They are very much alike except for the articular facets
- 215 - 5 T
- 215 - 6 T
- 215 - 7 F Thoracic vertebrae have apophyseal joints
  
- 216 - 1 Atlas
- 216 - 2. Axis
- 216 - 3 All
- 216 - 4 Atlas
- 216 - 5 Axis
- 216 - 6 Seventh
- 216 - 7 Bifid
- 216 - 8 Occipital, atlanto-occipital
- 216 - 9 Atlanto-axial
- 216 - 10 Two
  
- 217 - 1 True—14 ribs (7 pairs)—they are attached to cartilage that joins directly with the sternum
- 217 - 2 False—6 ribs (3 pairs)—they are attached to cartilage that does not join directly with the sternum
- 217 - 3 Floating—4 ribs (2 pairs)—they do not articulate anteriorly with anything
  
- 218 - 1. Manubrium
- 218 - 2 The suprasternal or manubrial notch, and the clavicular notches
- 218 - 3 Sternal angle, or angle of Louis

- 218 - 4 Distal part
- 219 - 1 (1) d  
(2) f  
(3) e  
(4) b  
(5) a  
(6) g

CHAPTER 3

- 220 - 1 Frontal, parietals, occipital
- 220 - 2. Frontal.
- 220 - 3 Supraorbital foramen
- 220 - 4 Squamosal
- 220 - 5 It is a vertical groove on the internal surface, formed by the fusion of the original two parts of the frontal bone
- 220 - 6 Parietals
- 220 - 7 Temporal
- 220 - 8 Petrus ridges
- 220 - 9. Mandibular fossa
- 220 - 10 Temporal
- 220 - 11 Foramen magnum
- 220 - 12. Occipital condyles.
- 220 - 13. External occipital protuberance (EOP)
- 220 - 14 Sphenoid
- 220 - 15 Optic foramina.
- 220 - 16. On the sella turcica.
- 220 - 17. Anterior and posterior clinoid processes
- 220 - 18. Sphenoid
- 220 - 19 Ethmoid.
- 220 - 20 Cribriform plate
- 220 - 21 On the superior portion of the cribriform plate of the ethmoid
- 220 - 22 Perpendicular plate
- 220 - 23. Labyrinths/conchae
  
- 221 - 1 (1) c.  
(2) d  
(3) i  
(4) h  
(5) f  
(6) e  
(7) a
  
- 222 - 1 (1) d  
(2) a  
(3) c  
(4) b  
(5) a  
(6) d  
(7) b  
(8) c
  
- 223 - 1 T
- 223 - 2 T
- 223 - 3 F In the maxilla
- 223 - 4 T
- 223 - 5 F Form the anterior part of the roof of the mouth and the floor of the nasal cavity
- 223 - 6 T
- 223 - 7 F Formed by the zygomatic bones
- 223 - 8 T
- 223 - 9 F Formed by both the zygomatic and temporal bones
- 223 - 10 T
- 223 - 11 T
- 223 - 12 F Located along the lateral walls of the nasal cavity
- 223 - 13. T
- 223 - 14. T
- 223 - 15 F Medially located with respect to the mental foramen
- 223 - 16 F. There are two
- 223 - 17 F Located at the junction of the body and ramus
- 223 - 18. T
- 223 - 19 F Posterior to the coronoid process
- 223 - 20 F The mandibular notch
  
- 224 - 1

- (1) c
- (2) c
- (3) b
- (4) d
- (5) a
- (6) d

#### CHAPTER 4

- 225 - 1 AP, oblique, and lateral
- 225 - 2 You should demonstrate the position with your hand. When positioning the patient, have your patient pull backward the fingers of the affected hand
- 225 - 3 There could be a linear or chip fracture present that is causing pain throughout the thumb
- 225 - 4 From the PA position for the hand, the fingers are flexed to form an arch or fist.
- 225 - 5 First metacarpophalangeal joint.
- 225 - 6 Interphalangeal joint and first metacarpophalangeal joint
- 226 - 1 PA, oblique, and lateral (mediolateral)
- 226 - 2 PAMO Less OFD than the other oblique (PALO)
- 226 - 3 To prevent superimposition of articular surfaces, thus, resulting in closing of interphalangeal joint spaces
- 226 - 4 Polyfoam step wedge and wooden tongue depressor
- 226 - 5 Mediolateral Less OFD than the lateromedial lateral
- 226 - 6 Three
- 227 - 1 PA hand
- 227 - 2 AP hand
- 227 - 3 45
- 227 - 4 Head of the second metacarpal
- 228 - 1. F PA, medial oblique, and lateral
- 228 - 2. F The hand is pronated
- 228 - 3 T
- 228 - 4 F The C<sup>2</sup> is vertical to the film
- 228 - 5 T
- 228 - 6 T
- 229 - 1 (1) b
- (2) c
- (3) a
- (4) d
- (5) d
- (6) a
- (7) b
- 230 - 1 AP
- 230 - 2 To prevent radial crossover
- 230 - 3. Include the entire elbow joint
- 230 - 4 AP and lateral views of both forearms to include the entire wrist
- 230 - 5 Flexed 90° and have the humeral epicondylar plane perpendicular to the film
- 231 - 1 Perpendicular to the film
- 231 - 2. Medial oblique
- 231 - 3 Supination prevents radial head rotation, thus, keeping the radial head in true AP
- 231 - 4 Lateral oblique
- 231 - 5 Jones position
- 232 - 1 Neutral
- 232 - 2. Internal
- 232 - 3. External
- 233 - 1 Location of fracture
- 233 - 2. To show anterior or posterior displacement of bone at the site of fracture
- 233 - 3 Transthoracic lateral of the humerus.
- 233 - 4 It improves contrast and decreases necessary exposure
- 234 - 1 Grashey position
- 234 - 2 Lawrence position
- 234 - 3 45°.
- 234 - 4 Medially.
- 234 - 5 Superior

- 235 - 1 Left anterior oblique
- 235 - 2 AP and lateral
- 235 - 3 Direct AP and AP with CR angled cephalic
- 235 - 4 Presents a more uniform density and reduces the possibility of part motion
- 235 - 5 AP or PA position of the patient

#### CHAPTER 5

- 236 - 1 To show open interphalangeal joints and phalanges without foreshortening
- 236 - 2 Medial oblique
- 236 - 3 Which toe is injured
- 236 - 4 Prevents radiologists from turning the film and disrupting their thought continuity or anatomical orientation
- 237 - 1 To project the metatarsals onto the film without foreshortening them
- 237 - 2 The CR was perpendicular to the film
- 237 - 3 Medial oblique
- 237 - 4 An AP with the CR perpendicular to the film and a lateral
- 237 - 5 Both projections produce virtually identical results
- 237 - 6 To prevent distortion
- 238 - 1. Dorsoplantar and lateral of the calcaneus
- 238 - 2 Semiaxial.
- 238 - 3. AP and lateral of weight-bearing feet
- 238 - 4 To demonstrate pes cavus and pes planus
- 238 - 5 Stress to the patient the importance of equal weight distribution. Leave the patient in the same position for both radiographs
- 239 - 1. AP, medial oblique, and lateral.
- 239 - 2 Lateral malleolus and the mortise space between the lateral malleolus and the talus.
- 239 - 3 A lateromedial projection puts the mortise closest to the film.
- 239 - 4 On the medial malleolus.
- 239 - 5 AP
- 239 - 6. The talus is not well visualized in the AP foot position.
- 239 - 7 Flexing prevents the calcaneus superimposing the mortise or lateral malleolus
- 240 - 1 Strains, sprains, fractures, dislocations, and fracture dislocation
- 240 - 2 Pain and swelling over the malleoli may cause you to do a cross-table lateral position
- 240 - 3 The foot may be rotated or extended, resulting in gross deformity of the foot and ankle
- 240 - 4 To avoid additional injury to the patient and crepitus
- 240 - 5 An AP and cross-table lateral with the patient supine on the litter
- 240 - 6 Standard AP, AP with forced inversion, and AP with forced eversion
- 241 - 1 F The joint nearest
- 241 - 2 T
- 241 - 3 F The leg is in true lateral
- 241 - 4 F A small focal spot
- 241 - 5 F Divergent beams distort the dimensions and articular surfaces of joints
- 241 - 6 F An AP projection and oblique projection are not at right angles to each other
- 242 - 1 Osteomyelitis, osteogenic tumors, cysts, bruises, and lacerations
- 242 - 2 Compound-comminuted fractures
- 242 - 3 Precise positioning of the part aids in determining the precise location of tumors
- 242 - 4 Changes in the trabecular pattern indicate systemic disease, and cysts or tumors can be identified by their internal pattern.
- 242 - 5 Swelling and deformity of the leg is present
- 242 - 6 Diagonally on the film
- 242 - 7 This prevents crepitus if a fracture is present
- 243 - 1 Whether or not the joint space or the distal femur and proximal tibia are of primary interest
- 243 - 2 20-30°.

- 243 - 3. It allows thigh muscles to relax and shows maximum volume of the joint cavity.
- 243 - 4. Shows fluid level densities
- 243 - 5. Intercondyloid fossa and tibial spines
- 243 - 6. Beclere's
- 244 - 1. T
- 244 - 2. F. The CR is perpendicular to the film
- 244 - 3. F If the patella is fractured, flex the knee only 10°
- 244 - 4. F. Dependent upon the extent of injury, the amount of CR angulation is dependent upon the amount of knee flexion
- 244 - 5. T
- 244 - 6. T
- 244 - 7. T.
- 245 - 1. Because of the length of the femur and to show both joints.
- 245 - 2. When the epicondylar plane is parallel with the film.
- 245 - 3. Rotation of the femur may sever the femoral artery.
- 245 - 4. Position the cathode over the thickest part of the thigh. To direct more of the primary beam through that portion of the thigh
- 245 - 5. So that secondary and scattered radiation can be absorbed by the Bucky grid.
- 245 - 6. To prevent superimposition of hips.
- 245 - 7. A confirmed or suspected femoral fracture.
- 245 - 8. Cross-table with the patient supine and the film vertical
- 245 - 9. Anytime a fracture of the femur involves the femoral head, neck, or trochanters
- 245 - 10. It positions the film parallel with the femoral neck
- 245 - 11. Perpendicularly to the center of the film through the femoral neck.
- 245 - 12. The Johnson position
- 245 - 13. 25.
- 245 - 14. First, direct the CR perpendicular to the film, then, 25° cephalic
- 245 - 15. The gonads
- 246 - 1. AP and lateral
- 246 - 2. Acetabulum, femoral head, and femoral neck
- 246 - 3. At a midpoint between the femoral heads
- 246 - 4. Danelus-Miller
- 246 - 5. Frogleg (Cleaves)
- 246 - 6. Cleaves.
- 246 - 7. Measure the distance from the ASIS to the tabletop on each side of the pelvis.
- 246 - 8. PA

## CHAPTER 6

- 247 - 1. The scapulae were not rolled forward during the examination
- 247 - 2. Yes. Rotate the right side of the patient's chest back toward the film
- 247 - 3. Yes
- 247 - 4. Rotation in the left anterior oblique position. Rotate the right side of the patient's chest toward the film
- 247 - 5. Yes. Rotate the patient's left side back toward the film
- 247 - 6. No. Nine.
- 247 - 7. No. Six.
- 247 - 8. No. Too much inhalation puts pressure on the diaphragm, which enlarges the heart.
- 247 - 9. The kVp was too low, which produced short-scale contrast
- 247 - 10. Use a time factor that is less than one-tenth of a second.
- 248 - 1. False. Probably due to patient's arms in the way.
- 248 - 2. True.
- 248 - 3. False. Should be used on all patients.
- 248 - 4. False. The patient is obliqued 45° for the right anterior oblique.
- 249 - 1. Left lateral decubitus. Because free air will rise and should be viewed without vertebral superimpositioning.
- 249 - 2. Left lateral decubitus. Because fluid levels should collect and be viewed at the costophrenic angle.
- 249 - 3. To raise the ribs off the table and demonstrate the entire costophrenic angle
- 249 - 4. Left
- 249 - 5. The side that is up.
- 249 - 6. Fluid levels may be obscured by the vertebral column
- 249 - 7. The affected side up
- 249 - 8. The apices of the lungs
- 249 - 9. Above the apices
- 249 - 10. To obtain proper radiographic technique
- 249 - 11. 72 inches
- 249 - 12. Pulls the scapula from superimposition of lung fields
- 249 - 13. To help lower the diaphragm, to demonstrate fluid levels, and to use 72-inch FFD
- 250 - 1. Whether or not they are above or below the diaphragm
- 250 - 2. The patient's body build, the position of the patient, and the phase of respiration
- 250 - 3. The diaphragm is low when the patient is standing, and it is higher into the chest when the patient is recumbent.
- 250 - 4. On suspended expiration. Because this relaxes the diaphragm, moving it to its highest point, and helps provide a uniform background density for lower ribs.
- 250 - 5. Upper ribs have mostly aerated tissue as background density; lower ribs have diaphragm and abdominal organs as background densities.
- 250 - 6. Low kVp—high mAs for a short-scale contrast
- 250 - 7. PA and lateral chest films. To rule out pneumothorax
- 250 - 8. Whether or not the ribs are above or below the diaphragm, and if they are anterior or posterior
- 250 - 9. PA chest, lateral chest, RAO ribs, and PA ribs. (LAO ribs optional.)
- 250 - 10. PA chest, lateral chest, AP ribs, and LPO ribs. (RPO ribs optional.)
- 250 - 11. Right ribs
- 250 - 12. According to your individual radiologist, but at least 30° and not more than 45°
- 251 - 1. F. The thoracic spine is superimposed over the sternum in the direct PA projection
- 251 - 2. F. The RAO projects the heart over the sternum
- 251 - 3. T.
- 251 - 4. T.
- 251 - 5. F. Use suspended inspiration when doing the lateral position for the sternum
- 251 - 6. T
- 251 - 7. F. Usually, 30° to 45°
- 251 - 8. T
- 252 - 1. No. Not in this case since foreign body is evident.
- 252 - 2. Technique b would provide more structure contrast, increasing the probability of demonstrating calculus
- 252 - 3. Upright chest AP/PA. Preferably standing; if unable while sitting in wheelchair or on end of table. Upright abdomen and finally supine abdomen. Should be taken in the order listed; since patient is already in an upright position, the air/fluid levels (if any) will be maintained.
- 252 - 4. First accomplish an AP chest and abdomen. Then have patient roll into a left lateral decubitus position; maintain position for several minutes. Then produce the radiograph using a horizontal beam

## CHAPTER 7

- 253 - 1. No. The head is flexed beyond the point where the incisor-baseline is perpendicular to the film. Extend the head until the imaginary line is perpendicular.
- 253 - 2. No. The head is extended beyond the point where the incisor-baseline is perpendicular to the film. Flex the head until the imaginary line is perpendicular.
- 253 - 3. No. The imaginary line is aligned as required, but the tongue is positioned too high in the mouth. Have the patient say "Ah" during the exposure to lower the tongue shadow below the atlas and axis.
- 253 - 4. Yes. (NOTE: Even though the two structures are superimposed over the atlas and odontoid process, they, the incisors and base, are in the same vertical plane. Consequently, this position is as good as it can be.)
- 254 - 1. To demonstrate the intervertebral foramina.

- 254 - 2 Left posterior oblique and left anterior oblique. Right posterior oblique and left anterior oblique
- 254 - 3. Part rotation—45°, CR angulation—15° cephalic Part rotation—45°, CR angulation—15° caudal.
- 254 - 4. Rotate the median plane of the skull slightly more than 45° from perpendicular
- 255 - 1. The first film should be a cross-table lateral. Make it without moving the patient at all. The reasons for this action are to help determine whether the injury requires traction before moving the patient and to determine the course of action for the remaining radiographs.
- 255 - 2. Take no action until the radiologist or physician instructs you on what to do next.
- 255 - 3. No part rotation on this patient. Angle the CR 15° cephalically and 45° medially.
- 255 - 4 Remove the grid.
- 255 - 5 Discuss the movements needed with the radiologist or physician. Request supervision of moving the patient if possible. If direct assistance is not possible, ask for specific moving instructions
- 256 - 1 To demonstrate any lateral curvature of the spine.
- 256 - 2 Always place the cathode end of the tube toward the abdomen
- 256 - 3 They are usually superimposed by the shoulders.
- 256 - 4 Kyphosis
- 256 - 5 Lateral.
- 256 - 6 Make sure the thoracic spine is parallel with the table by supporting the narrow portion of the abdomen with foam cushions and use a perpendicular CR
- 256 - 7 Have the patient breathe shallow and quickly to blur out the ribs
- 256 - 8 Angle the CR 5° caudad
- 257 - 1 70
- 257 - 2 Right
- 257 - 3 Left
- 258 - 1 Flex the patient's hips and knees until the feet are flat on the table.
- 258 - 2 To prevent pelvic tilt due to uneven shoes
- 258 - 3. The patient's shoulders and hips are not parallel with each other
- 258 - 4 Each ASIS is not equal distance from the tabletop. Soft tissue abnormality (swelling or atrophy)
- 258 - 5 Adjust a support under the lower side of the pelvis
- 258 - 6. Full lateral
- 258 - 7. Lumbar spine not parallel with the table
- 258 - 8. Angle the CR caudally 5° for males, 8° for females
- 259 - 1. Radiograph A
- 259 - 2 Radiograph B
- 259 - 3 Radiograph C
- 259 - 4 The joints do not open at a 45° angle
- 259 - 5 Right
- 259 - 6 Left
- 260 - 1 T
- 260 - 2 F The AP position decreases magnification of the sacrum
- 260 - 3 T
- 260 - 4. T
- 260 - 5. T
- 260 - 6 F A cross-table lateral of the coccyx is done with the patient prone
- 260 - 7 T
- 261 - 1 (1) A, B  
(2) C, D
- 262 - 1 Anterior or posterior rotation Superior or inferior angulation. There are two ways to check the skull for longitudinal angulation and only one way to check for rotation.
- 262 - 2 Your answer to this exercise should reflect the importance of aligning the median plane parallel with the film. You should also use some type of device, such as the piece of cardboard, to help you align the skull, since "eyeballing" the alignment is subject to error. In addition, you should mention the fact that you must check the alignment of the skull from two positions: in front of the patient's face, and at the end of the table above the top of the patient's head
- 262 - 3 The outer canthus of the eye
- 262 - 4 Sella turcica, sinuses, nasal bones, and facial bones
- 263 - 1 (1) c  
(2) b  
(3) a  
(4) c  
(5) b  
(6) a
- 264 - 1 When the examination is performed to visualize the frontal bone
- 264 - 2 Orbitomeatal and median
- 264 - 3 Upper two-thirds of the orbits, frontal and temporal bones, anterior ethmoidal sinuses, frontal sinuses, and wings of the sphenoid.
- 264 - 4 Only the lower third of the orbit is covered by petrous ridges in Caldwell's projection, whereas with the PA skull, petrous ridges superimpose almost the entire orbit
- 264 - 5. 15° caudad
- 265 - 1 Straight AP skull with the orbitomeatal line, median plane and CR vertical.
- 265 - 2 CR angulation, vertical for the AP skull, but 30° caudad for the Towne's.
- 265 - 3 Infants or small children, elderly patients, seriously injured, unconscious or intoxicated patients, and portable studies of the skull.
- 265 - 4 True AP skull (median plane and orbitomeatal line perpendicular to the film) and the CR angled 30° caudad
- 265 - 5 Position the infraorbitomeatal line perpendicular to the film and angle the CR 37° caudad
- 265 - 6. 30° caudad. 50° to 60° caudad
- 265 - 7 AP skull
- 266 - 1 Sphenoid and ethmoid sinuses, external and internal auditory meati, mastoids, base of skull, mandible, and zygomatic arches.
- 266 - 2 Submentovertical
- 266 - 3 With the patient seated. It is easier to place the infraorbitomeatal line parallel with the film, and the position is more comfortable with the patient
- 266 - 4 The CR is always perpendicular to the infraorbitomeatal line
- 267 - 1 Modified Caldwell's. skull PA, orbitomeatal line perpendicular to the film, CR angled 15° caudad and directed to the nasion, and the patient should be sitting.
- 267 - 2 Frontals.
- 267 - 3 With the patient sitting or standing upright. To demonstrate any fluid levels.
- 267 - 4 Waters'
- 267 - 5 Improper alignment of the orbitomeatal line
- 267 - 6 Petrous ridges will superimpose maxillary sinuses.
- 267 - 7 Orbitomeatal line forms an angle with the table of considerably less than the recommended 37°
- 267 - 8 Lateral
- 267 - 9 A right lateral (right side of the skull nearest the film). Because the side nearest the film on a lateral projection shows the best detail
- 267 - 10. Sphenoid and Ethmoid
- 267 - 11 The Pirie position
- 267 - 12 The central ray is angled slightly caudad and projected through the sella turcica and the open mouth
- 268 - 1. To prevent a loss of detail due to the shadow cast by the ears
- 268 - 2 Small, to prevent loss of detail because of secondary radiation.
- 268 - 3 When the patient is comfortable and the head is properly immobilized
- 268 - 4 No The radiologist
- 269 - 1. (1) c  
(2) a

## CHAPTER 8

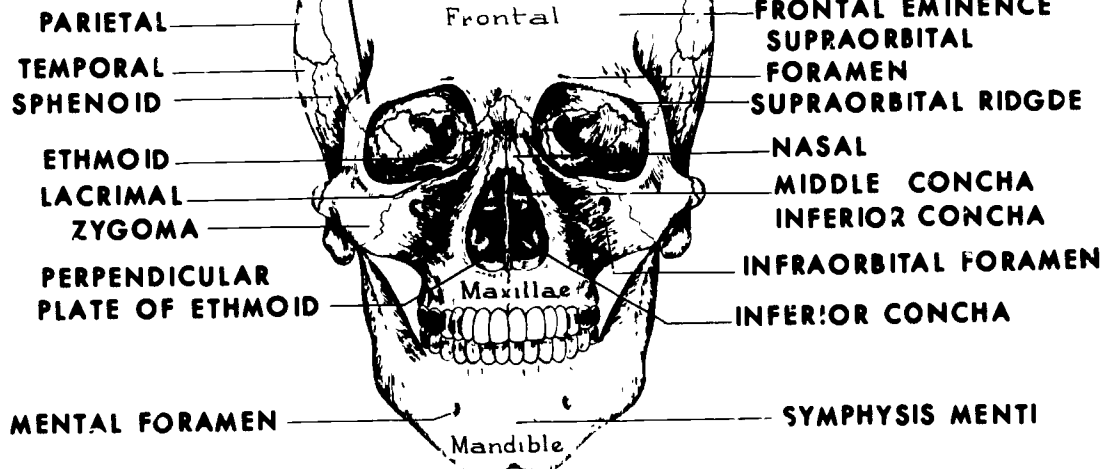
- 262 - 1 Anterior or posterior rotation Superior or inferior angulation. There are two ways to check the skull for longitudinal angulation and only one way to check for rotation.
- 262 - 2 Your answer to this exercise should reflect the importance of aligning the median plane parallel with the film. You should also use some type of device, such as the piece of cardboard, to

- (3) a
  - (4) b
  - (5) b
  - (6) c
  - (7) a
  - (8) c
  - (9) a.
- 270 - 1 AP
- 270 - 2 10° caudad
- 270 - 3 To the left
- 270 - 4 35°
- 270 - 5 PA
- 270 - 6 12° cephalic
- 270 - 7 To the right
- 270 - 8 45°
- 270 - 9 To the left
- 270 - 10 To the right
- 270 - 11 54°
- 270 - 12 54°
- 271 - 1 (1) b
- (2) b
- (3) a
- (4) a, b
- (5) a
- (6) a
- (7) a, b
- 272 - 1 AP The foramen is farther from the film.
- 272 - 2 The head should be rotated so that the median plane forms a 53° angle with the plane of the film or a 37° angle with a vertical

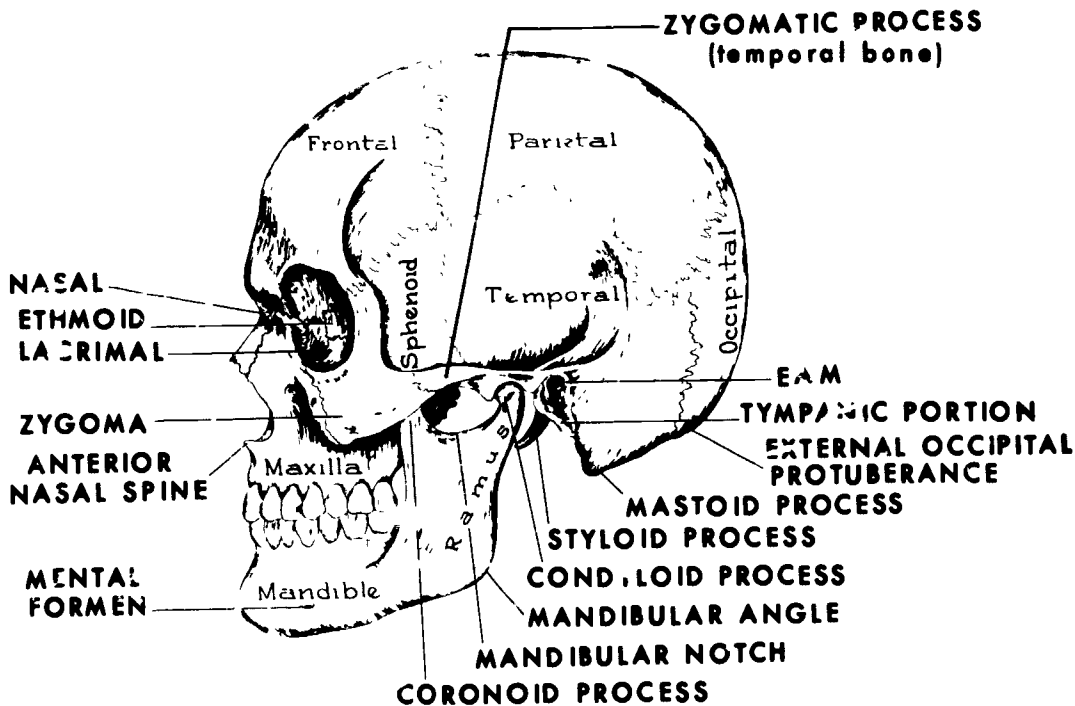
- plane For the left foran. rotate the posterior portion of the head to the left
- 272 - 3 The head should be rotated so that the median plane forms a 53° angle with the plane of the film or a 37° angle with a vertical plane For the right foramen rotate the posterior portion of the head to the right
- 273 - 1 The position is correct—the optic foramen is projected in the lower outer quadrant of the orbit
- 273 - 2 The position is incorrect—indicated by projection of the optic foramen above the normal location. The head is overflexed.
- 273 - 3 The position is incorrect—indicated by projection of the optic foramen medial to its normal location The median plane forms an angle of more than 53° with the plane of the film
- 273 - 4 in the lower outer quadrant of the orbit
- 274 - 1 The head is tilted This means the head is moved so that the mandible goes in one lateral direction and the top of the head in the other.
- 274 - 2 The mandible is tilted to the right, or the top of the head is tilted to the left Same answer
- 274 - 3. 15°.
- 274 - 4. To prevent foreshortening the arch
- 274 - 5 Elongation of the arch Yes When the patient cannot assume a position with the infraorbitomeatal line parallel with the film.
- 275 - 1 Because the PA projection offers a full anterior view of the mandible with emphasis on the rami
- 275 - 2 The median plane was not perpendicular to the film
- 275 - 3 To prevent superimposing both sides of the mandible
- 275 - 4 30°

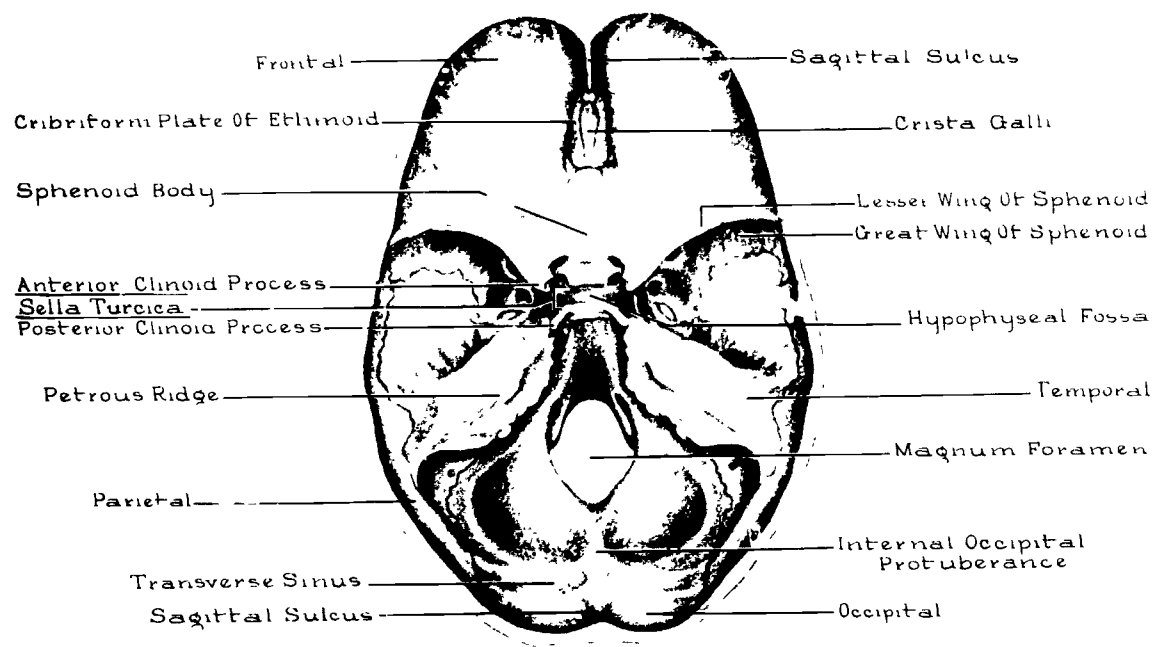


**ZYGOMATIC PROCESS  
(frontal bone)**

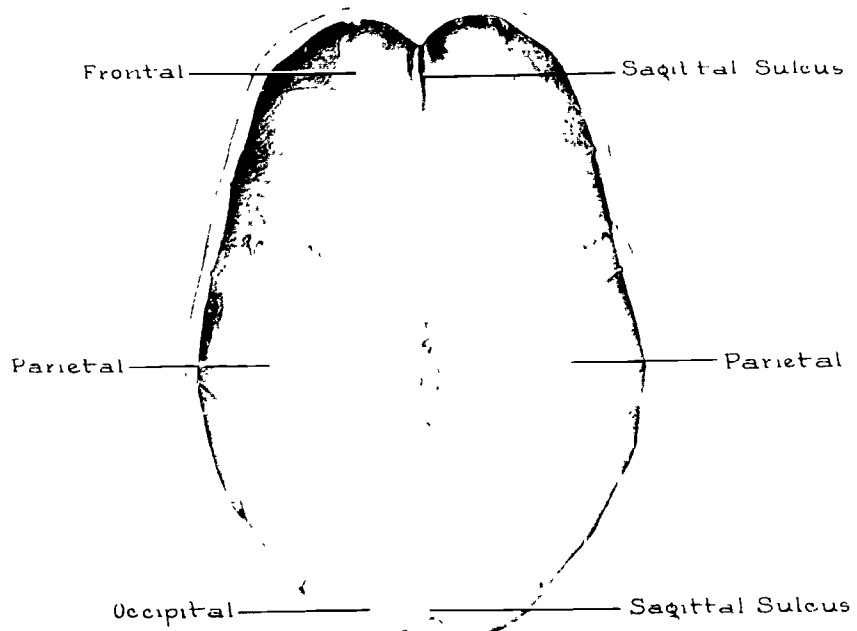


**ZYGOMATIC PROCESS  
(temporal bone)**



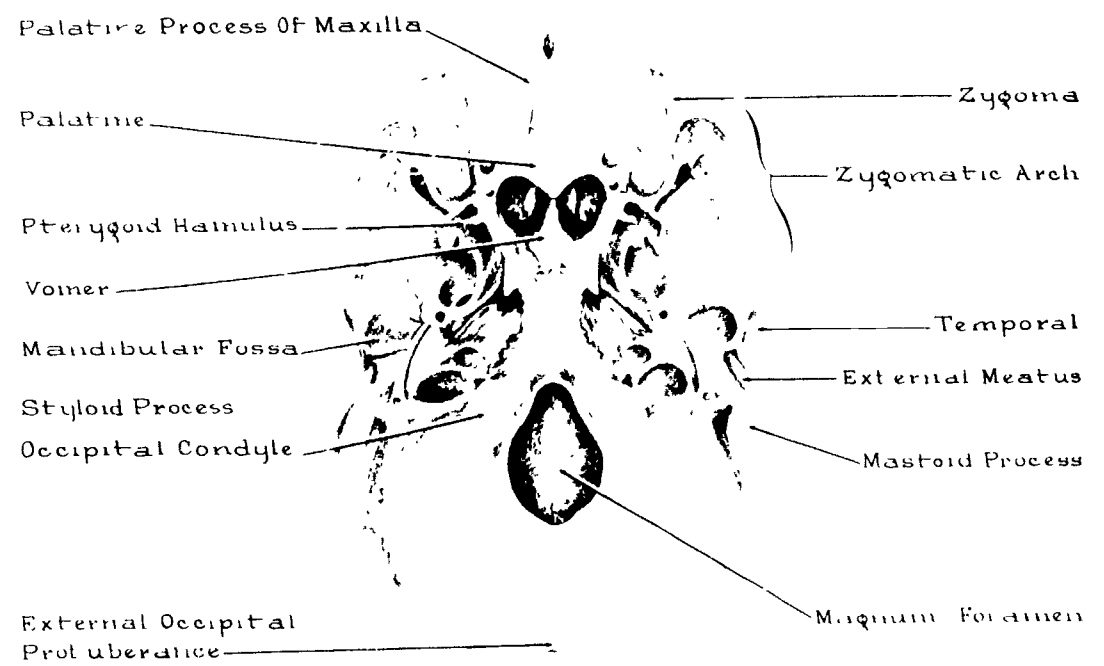
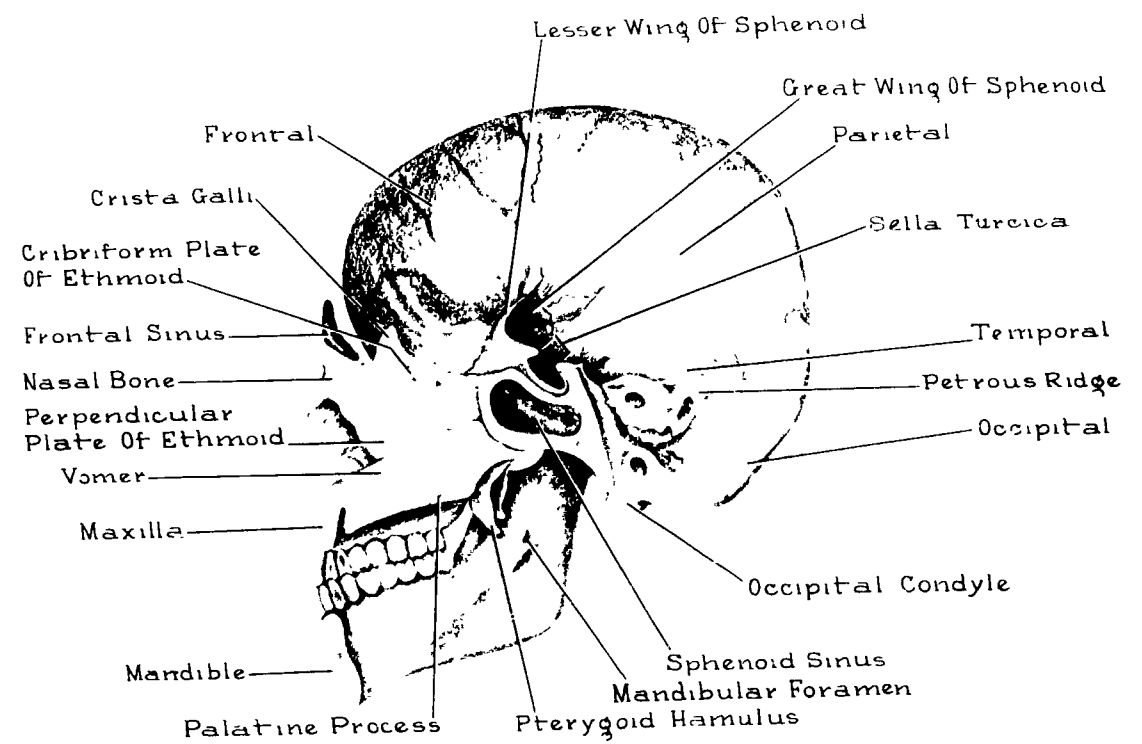


INNER SURFACE OF CRANIAL BASE



INNER SURFACE OF CRANIAL ROOF

Anatomy of the human skull.



STOP -

1. MATCH ANSWER SHEET TO THIS EXERCISE NUMBER.
2. USE NUMBER 2 PENCIL ONLY.

EXTENSION COURSE INSTITUTE  
VOLUME REVIEW EXERCISE

90370 02 23

OSTEOLOGY AND POSITIONING

Carefully read the following:

**DO's:**

1. Check the "course," "volume," and "form" numbers from the answer sheet address tab against the "VRE answer sheet identification number" in the righthand column of the shipping list. If numbers do not match, return the answer sheet and the shipping list to ECI immediately with a note of explanation.
2. Note that item numbers on answer sheet are sequential in each column.
3. Use a medium sharp #2 black lead pencil for marking answer sheet.
4. Write the correct answer in the margin at the left of the item. (When you review for the course examination, you can cover *your* answers with a strip of paper and then check your review answers against your original choices.) After you are sure of *your* answers, transfer them to the answer sheet. If you *have* to change an answer on the answer sheet, be sure that the erasure is complete. Use a clean eraser. But try to avoid any erasure on the answer sheet if at all possible.
5. Take action to return entire answer sheet to ECI.
6. Keep Volume Review Exercise booklet for review and reference.
7. If *mandatorily* enrolled student, process questions or comments through your unit trainer or OJT supervisor. If *voluntarily* enrolled student, send questions or comments to ECI on ECI Form 17.

**DON'Ts:**

1. Don't use answer sheets other than one furnished specifically for each review exercise.
2. Don't mark on the answer sheet except to fill in marking blocks. Double marks or excessive markings which overflow marking blocks will register as errors.
3. Don't fold, spindle, staple, tape, or mutilate the answer sheet.
4. Don't use ink or any marking other than a #2 black lead pencil.

**NOTE: NUMBERED LEARNING OBJECTIVE REFERENCES ARE USED ON THE VOLUME REVIEW EXERCISE.** In parenthesis after each item number on the VRE is the *Learning Objective Number* where the answer to that item can be located. When answering the items on the VRE, refer to the *Learning Objectives* indicated by these *Numbers*. The VRE results will be sent to you on a postcard which will list the *actual* VRE items you missed. Go to the VRE booklet and locate the *Learning Objective Numbers* for the items missed. Go to the text and carefully review the areas covered by these references. Review the entire VRE again before you take the closed-book Course Examination.

## MULTIPLE CHOICE

*Note to Student* Consider all choices carefully and select the best answer to each question.

1. (200) Which pair of anatomical reference terms should you use to refer to the anterior surface of the hand?
  - a. Palmar or volar.
  - b. Palmar or plantar
  - c. Dorsal or volar
  - d. Dorsal or plantar
2. (200) Which anatomical term describes the dorsal surface of the foot?
  - a. Lateral.
  - b. Medial.
  - c. Upper
  - d. Plantar.
3. (201) Which description of the body plane is correct?
  - a. The frontal plane divides the body into equal right and left halves.
  - b. The median plane divides the body into equal right and left halves.
  - c. The transverse plane divides the body into equal anterior and posterior halves
  - d. The midsagittal plane divides the body into equal anterior and posterior halves
4. (202) The sole and lower instep of the foot are formed by the
  - a. phalanges.
  - b. metatarsals.
  - c. cuboid and navicular.
  - d. articulation between the talus and metatarsals.
5. (202) Which bone forms the heel of the foot?
  - a. The astragalus.
  - b. The tarsal scaphoid.
  - c. The talus.
  - d. The os calcis.
6. (203) Identify the bones that form the ankle joint.
  - a. Tibia, fibula, and os calcis
  - b. Talus, calcaneus, and tibia.
  - c. Scaphoid, tibia, and fibula.
  - d. Talus, tibia, and fibula.
7. (203) The medial malleolus is a part of which bone?
  - a. The tibia.
  - b. The fibula.
  - c. The talus.
  - d. The calcaneus.
8. (204) Which structures are located on the proximal portion of the tibia?
  - a. Tibia tuberosity and popliteal region.
  - b. Intercondylar eminence and tibial tuberosity.
  - c. Medial malleolus, apex, and bicipital groove.
  - d. Intercondylar eminence, lateral malleolus, and medial and lateral condyles.
9. (205) Where does the patellar ligament attach to the patella?
  - a. At the articular facets.
  - b. At the inferior surface.
  - c. At the posterior condyles.
  - d. At the medial condyles.
10. (205) Which part of the femur articulates with the tibia to form the knee joint?
  - a. The epicondyles.
  - b. The condyles.
  - c. The intercondyloid fossa.
  - d. The intertrochanteric crest.

- 11 (206) Identify the structures that are located on the proximal femur
- a Trochanters, head, and neck
  - b Head, trochanters, and intercondyloid eminence
  - c Popliteal space, trochanters, and fovea capitis.
  - d Condyles, intertrochanteric crest, and intertrochanteric line
- 12 (206) Where is the fovea capitis located on the femur?
- a On the proximal shaft
  - b On the nearest trochanter
  - c Near the intertrochanteric crest.
  - d Near the center of the head
- 13 (207) What structures make up the pubic arch?
- a The pubic rami.
  - b The pubic tubercles and tuberosities.
  - c The ramus of the ischium and the inferior ramus of the pubis
  - d The symphysis pubis and the ischial tuberosities.
- 14 (208) Which specific parts of the sacrum and ilium form the sacroiliac joints?
- a The articular surfaces of each bone.
  - b The apex of the sacrum and the greater sciatic notch
  - c The body of the first sacral segment and the body of the ilium.
  - d The body of the first sacral segment and the acetabulum.
15. (208) The apex of the coccyx is the
- a surface that articulates with the sacrum.
  - b proximal coccygeal segment.
  - c. extreme distal tip of the last coccygeal vertebra
  - d. posterior, convex surface of the true pelvis.
16. (209) Identify the carpal bones that are located in the proximal row of the wrist.
- a Lunate, triangular, pisiform, and hamate.
  - b. Navicular, lunate, capitate, and pisiform.
  - c. Greater and lesser multangulans, capitate, and hamate.
  - d. Pisiform, triangular, lunate, and navicular.
17. (209) Where is the scaphoid located in the wrist?
- a. Medial side of the distal row.
  - b. Lateral side of the distal row.
  - c. Medial side of the proximal row.
  - d. Lateral side of the proximal row.
- 18 (209) Where are the ungual tuberosities located in the fingers?
- a. Distal end of the middle phalanges.
  - b. Distal end of the distal phalanges.
  - c. At the interphalangeal joint of the thumb.
  - d. At the metacarpophalangeal joints of the fingers.

19. (210) Which bony structures are located on the ulna?
- Olecranon process, trochlea, and styloid process.
  - Radial notch, olecranon process, and coronoid process
  - Coronoid process, styloid process, and capitulum.
  - Radial notch, olecranon process, and radial tuberosity.
20. (211) The articulating surface on the medial aspect of the distal humerus is the
- trochlea.
  - capitulum.
  - medial epicondyle
  - lateral epicondyle
21. (211) Which structure articulates with the radial head?
- Trochlea
  - Capitulum.
  - Ulnar head.
  - Humeral head.
22. (212) Select the best description of the surgical neck of the humerus.
- Rounded eminence on the lateral side.
  - Deep furrow between the tuberosities.
  - Constricted portion distal to the tuberosities.
  - Rounded portion between the tuberosities and the head.
23. (212) Identify the structures that are on the proximal humerus.
- Head, greater and lesser trochanters, and bicipital groove.
  - Head, greater and lesser tuberosities, and anatomical neck
  - Head, greater and lesser tubercles, and capitulum.
  - Head, greater and lesser tuberosities, and trochlea.
24. (213) Identify the four bony structures that form the two joints of the shoulder.
- Glenoid fossa, humerus, acromion process, and clavicle.
  - Clavicle, humerus, scapula fossa, and acromion process.
  - Glenoid fossa, acromion process, manubrium, and humerus
  - Humerus, scapular spine, coracoid process, and acromion process
25. (214) The laminae of the lumbar vertebra is located
- superior to the pedicle.
  - between the transverse processes.
  - between the body and the transverse processes.
  - between the spinous and transverse processes.
26. (214) What type of curvature is formed by the lumbar vertebrae?
- Lordotic.
  - Scoliotic
  - Kyphotic.
  - Posterior.
27. (214) Which structures extend posteriorly from the body of lumbar vertebrae?
- Pedicles.
  - Laminae.
  - Spinous processes.
  - Transverse processes.
28. (215) What type of curvature is formed by the thoracic vertebrae?
- Lordotic
  - Scoliotic.
  - Kyphotic.
  - Anterior.

29. (215) Identify the structures that form the costovertebral joints
- The heads of ribs and the transverse processes
  - The transverse processes and the costal tuberosities.
  - The vertebral bodies and the heads of the ribs
  - The vertebral bodies and the apophyseal articulations
30. (216) Which characteristic describes all cervical vertebrae?
- They are atypical.
  - Their spinous processes are bifurcated.
  - They do not have intervertebral disks
  - Their transverse processes have foramen.
31. (216) Why is the first cervical vertebra described as being atypical?
- Because it has no transverse processes.
  - Because it has no body or spinous process.
  - Because it has the odontoid process
  - Because its superior surface forms the atlanto-axial articulation
32. (217) What type of bones are ribs?
- Irregular bones.
  - Flat bones
  - Long bones.
  - Short bones.
33. (218) What are the three major parts of the sternum?
- Clavicular end, manubrium, and body.
  - Manubrium, angle of Louis, and xiphoid process
  - Manubrium, body, and xiphoid process
  - Gladiolus, angle of Louis, and clavicular notch.
34. (218) With what part of the sternum does the clavicle articulate?
- With the manubrium.
  - With the gladiolus
  - With the xiphoid process.
  - With the sternal angle.
35. (219) Which joint is formed by the articulation between true ribs and the sternum?
- The xiphisternal
  - The interchondral.
  - The sternoclavicular.
  - The costosternal
36. (220) Which structures are located on the frontal bone of the cranium?
- Infraorbital foramina and vomer.
  - Zygomatic process and nasal process.
  - Frontal eminences and perpendicular plate.
  - Supraorbital foramina and tympanic portions.
37. (220) Which structures are part of the temporal bone?
- Mastoid process, styloid process, and zygomatic process.
  - Mandibular fossa, condyloid process, and zygomatic process.
  - Styloid process, tympanic portion, and coronoid process.
  - Posterior clinoid process, mastoid process, and tympanic portion.

38. (221) Which bones join to form the coronal suture?
- a. Occipital and parietals.
  - b. Parietals and sphenoid
  - c. Frontal and parietals
  - d. Temporal and sphenoid
39. (221) Which bones join to form the lambdoidal suture?
- a. Frontal and parietals
  - b. Temporal and parietal
  - c. Sphenoid and temporal
  - d. Occipital and parietals
40. (222) Which two fontanelles, when ossified, become the bregma and lambda junctions?
- a. Both anterolaterals.
  - b. Both posterolaterals
  - c. Anterior and posterior.
  - d. Anterior and right posterolateral
41. (223) Which structures are located on the maxilla?
- a. Infraorbital foramen, zygomatic process, and palatine process
  - b. Infraorbital foramen, anterior nasal spine, and temporal process.
  - c. Inferior turbinate, anterior nasal spine, and zygomatic arch.
  - d. Anterior nasal spine, orbital process, and perpendicular plate
42. (224) Which sinuses have the alveolar processes as their floor?
- a. Frontal.
  - b. Maxillary.
  - c. Ethmoidal.
  - d. Sphenoidal
43. (224) Which sinuses form the medial wall of each orbit?
- a. Frontal
  - b. Maxillary
  - c. Ethmoidal
  - d. Sphenoidal.
44. (225) How is the hand placed when positioning for a radiograph of the anteroposterior (AP) thumb?
- a. True AP
  - b. True PA.
  - c. Internal rotation.
  - d. External rotation.
45. (226) Why should fingers be spread apart when positioning for a lateral film of all fingers?
- a. To prevent superimposition of phalanges.
  - b. To superimpose articular surfaces.
  - c. To place phalanges parallel to the film
  - d. To place the interphalangeal joint spaces perpendicular to the film
46. (227) Identify the *best* description of the PA radiographic hand position.
- a. Hand supinated, posterior surface on film
  - b. Hand supinated, anterior surface on film.
  - c. Hand pronated, posterior surface on film.
  - d. Hand pronated, anterior surface on film.
47. (227) What is the centering point for the central ray (CR) for an oblique projection of the hand?
- a. Head of the second metacarpal.
  - b. Head of the third metacarpal.
  - c. Proximal end of the second metacarpal.
  - d. Proximal end of the third metacarpal.



48. (228) Which radiographic position of the wrist involves 5° supination of the hand?
- PA.
  - Medial oblique
  - Lateral oblique
  - Lateral.
49. (229) Which position of the wrist requires the hand pronated and moved towards the ulna?
- Radial deviation.
  - Ulnar deviation.
  - Radial flexion.
  - Gaynor-Hart.
50. (229) Which radiographic position of the wrist results in an axial view of the carpal canal?
- Semisupination oblique.
  - Gaynor-Hart.
  - Radial deviation.
  - Ulnar deviation.
51. (230) What condition must be present to prevent radial crossover during the AP position of the forearm?
- Interstyloid plane perpendicular to the film.
  - Humeral epicondylar plane perpendicular to the film.
  - Pronation of the hand.
  - Supination of the hand.
52. (231) Identify the structure that is of primary interest in the Jones position.
- Olecranon fossa.
  - Olecranon process.
  - Coronoid fossa.
  - Coronoid process.
53. (232) Which structures are visualized on the external rotation better than on the neutral or internal rotation radiograph of the shoulder?
- The humeral head and lesser tuberosity.
  - The humeral head and greater tuberosity.
  - The bicipital groove and lesser tuberosity.
  - The bicipital groove and greater tuberosity.
54. (232) How is the humeral epicondylar plane positioned in a neutral rotation of the shoulder?
- 45 degrees to the film.
  - 90 degrees to the film.
  - Parallel to the film.
  - Perpendicular to the film.
55. (233) Identify the procedure that is used to remove lung markings superimposed over a humerus in the transthoracic lateral position.
- Suspended inspiration.
  - Suspended expiration.
  - Rapid breathing.
  - Slow breathing.
56. (233) After completing an AP projection on a suspected fractured humerus, what should you do before taking the lateral?
- Do an AP humerus with internal rotation.
  - Do an AP humerus with external rotation.
  - Make sure the epicondylar plane is parallel to the film.
  - Check AP film for fracture location.
57. (234) Which projection does the CR take in the Lawrence position of the shoulder?
- Caudad.
  - Lateral.
  - Inferosuperior.
  - Superoinferior.

- 58 (234) Why should the scapula be placed parallel to the film when doing the Grashey position for a radiograph of the shoulder?
- To put the glenoid fossa in profile
  - To open the acromioclavicular joint.
  - It projects the coracoid process free of superimposition
  - To show the lateral end of the clavicle free of superimposition
59. (235) In what position is the body rotated when the CR enters at the vertebral border of the right scapula for a lateral projection?
- Left anterior oblique.
  - Left posterior oblique.
  - Right anterior oblique
  - Right posterior oblique
- 60 (235) Which radiographic positions are used to demonstrate a "shoulder separation"?
- Erect AP acromioclavicular joints, with and without weights.
  - AP shoulder joint with internal and external rotation.
  - Erect AP clavicle with CR angled 20° cephalic.
  - Erect AP clavicle with CR angled 20° caudad.
- 61 (236) What angulation should the sole of the foot form with the film for an AP oblique of toes?
- 30° medial.
  - 30° lateral
  - 45° medial.
  - 45° lateral.
- 62 (236) Which radiographic projection of the toes best shows phalanges and interphalangeal joint spaces?
- Dorsoplantar with perpendicular CR.
  - Plantodorsal with perpendicular CR.
  - Dorsoplantar with caudal CR angulation.
  - Plantodorsal with cephalic CR angulation.
63. (237) What procedure is necessary to prevent foreshortening of metatarsals in the AP view of the foot?
- Metatarsals perpendicular to the film.
  - CR perpendicular to the film
  - CR angled 15° caudad.
  - CR angled 15° cephalic.
64. (237) How is the foot rotated and CR directed for an oblique to best demonstrate the articulations of the cuboid?
- Foot rotated 45° medially and CR 15° cephalic.
  - Foot rotated 30° medially and CR perpendicular
  - Foot rotated 30° lateral and CR 15° cephalic.
  - Foot rotated 15° lateral and CR perpendicular.
- 65 (237) Why should techniques in the region of 80 kilovolts peak (KVP) instead of 60 KVP be used for the AP of the foot?
- To produce high radiographic contrast.
  - To reduce the difference in subject contrast.
  - To show fractures of the metatarsals and phalanges.
  - To show soft tissue swelling due to trauma.

- 66 (238) A patient's foot is properly positioned for the plantodorsal projection of the calcaneus when the
- foot is in a relaxed position
  - ankle is in extension and foot laterally obliqued 10°.
  - plantar surface of the foot is perpendicular to the central ray
  - plantar surface of the foot is perpendicular to the film
- 67 (238) What structure is demonstrated purposely in the lateral projection of weight-bearing feet?
- Interphalangeal articulations
  - Talocalcaneal joint space
  - Longitudinal arch
  - Latitudinal arch
- 68 (239) How is the intermalleolar line positioned to the film in the lateral projection of the ankle?
- 45° medially
  - 45° laterally.
  - Parallel
  - Perpendicular
- 69 (239) Why should the plantar surface of the foot be perpendicular to the film in the AP position of the ankle?
- This forces the intermalleolar line parallel to the film.
  - This visualizes the medial malleolus free of superimposition.
  - To prevent the calcaneus from superimposing the lateral malleolus.
  - To superimpose the malleoli.
- 70 (240) The presence of crepitus in an injury would indicate
- grinding of bone fragments.
  - excessive pain.
  - edema and epidermal abrasions.
  - a nondisplaced fracture
- 71 (241) What must you do to demonstrate both joints on the same film when doing a routine radiograph of the leg?
- Use the longest practical focal film distance.
  - Use a small focal spot size
  - Use a large focal spot size.
  - Place the leg diagonally on the film
72. (241) What indicates that the leg is in true AP during radiographic positioning?
- The fibular styloid process is free of superimposition.
  - The patella superimposes the intercondylar eminence
  - The tibial condylar plane is perpendicular to the film.
  - The tibial condylar plane is parallel with the film.
73. (242) Detail of the trabecular pattern during an X-ray of the leg is of prime importance because
- compound fractures are difficult to visualize.
  - bruises and lacerations require a soft-tissue technique.
  - early detection of serious systemic disease is possible.
  - a fluid level indicates a fracture.
74. (242) How are fractures of the leg readily identified?
- Osteoporosis is indicated.
  - Patient complains of pain in either joint.
  - Bruises and lacerations are present.
  - Swelling and deformity are observable.

75. (243) How should the leg and femur be positioned with respect to the X-ray table for Homblad's projection?
- Leg and femur parallel.
  - Leg parallel; femur forms a 70° angle
  - Leg parallel; femur forms a 20° angle
  - Leg parallel; femur perpendicular.
76. (243) Which position of the knee might show a fluid level density if the tibia plateau is fractured?
- Homblad's.
  - Beclere's.
  - Cross-table lateral.
  - AP with vertical central ray.
77. (244) Identify the position that produces an axial production of the patella.
- PA.
  - Homblad.
  - Settegast.
  - Beclere.
78. (244) Identify the correct positioning of the leg for the Settegast position.
- Leg vertical to the film; CR 30° cephalic.
  - Leg parallel to the film; CR 15° cephalic.
  - Leg forms an 80° angle to the femur; CR 15° cephalic.
  - Leg forms an 80° angle to the femur; CR 30° cephalic
79. (245) The Danelius-Miller position should be used anytime a fracture of the femur involves the
- pelvis or hip joint.
  - femoral head, neck, or trochanters.
  - femoral head, trochanters, or condyles.
  - pubis, ischium, or femoral head.
80. (245) How is the central ray directed for the Danelius-Miller position of the femur?
- Perpendicular to the film and at right angles to the femoral neck.
  - Perpendicular to the film and 45 degrees to the femoral neck.
  - Perpendicular to the femur and 25 degrees cephalic.
  - Horizontal central ray and 25 degrees cephalic.
81. (246) Which position of the hips requires the central ray angled 10 degrees cephalic and the thighs abducted at least 40 degrees from vertical?
- Cleaves.
  - Danelius-Miller
  - Johnson.
  - AP.
82. (247) How many ribs should be demonstrated on a full inspired PA chest radiograph?
- Eight posterior or eight anterior.
  - Nine posterior or nine anterior.
  - Ten posterior or seven anterior.
  - Nine posterior or six anterior.
83. (247) When checking the spinous processes for rotation of a PA chest, why should you evaluate several continuous vertebrae?
- Because thoracic vertebrae are atypical.
  - Because deviation of a single spinous process indicates the CR is not horizontal
  - Because the spinous process of the third thoracic vertebra is usually deviated.
  - Because it may be common for one spinous process to be deviated in a properly positioned chest.

- 84 (248) What is the probable cause of the upper lung fields appearing underexposed on a lateral chest film?
- Patient rotation.
  - Faulty radiographic technique
  - The patient's arms were in the way.
  - Processor not working correctly.
- 85 (248) Which patients require abdominal shielding while having a chest radiograph?
- Children
  - Pregnant women
  - Elderly patients.
  - All patients.
- 86 (249) Why should you use a radiolucent pad under a patient when performing a right lateral decubitus of the chest?
- To keep the thoracic spine parallel with the table.
  - To place the coronal plane 45 degrees to the film.
  - To visualize the costophrenic angle of the right lung.
  - To visualize the costophrenic angle of the left lung.
- 87 (249) Why should the patient be sitting instead of supine when positioned for a portable AP chest radiograph?
- To demonstrate possible fluid levels.
  - To demonstrate both costophrenic angles.
  - To decrease the focal-film-distance.
  - To raise the diaphragm to its highest position
88. (250) How are ribs below the diaphragm best demonstrated?
- Patient supine; exposure taken on suspended inspiration.
  - Patient supine; exposure taken on suspended expiration
  - Patient erect; exposure taken on suspended inspiration
  - Patient erect; exposure taken on suspended expiration.
- 89 (251) Why should you use both anterior obliques when positioning the patient for sternoclavicular articulations?
- To project the heart as background density for both SC joints.
  - To diffuse lung markings.
  - Because only the SC joint away from the film is best demonstrated.
  - Because only the SC joint nearest the film is best demonstrated.
- 90 (252) A patient has acute generalized abdominal pains and arrives in a wheelchair. In what order of precedence should you take radiographs?
- PA chest, AP supine abdomen, left lateral decubitus abdomen.
  - PA chest, AP upright abdomen, left lateral decubitus chest.
  - PA chest, AP upright abdomen, AP supine abdomen.
  - PA chest, left lateral decubitus abdomen, AP supine abdomen.

- 91 (253) An AP (open mouth odontoid) radiograph shows upper incisors projected below the level of the base of the skull and superimposed over the atlas. What should you do to correct the patient's position on a subsequent radiograph?
- Tilt the head caudally 10° if possible; if unable, angle the CR 10° caudally
  - Tilt the head cephalically 10° if possible; if unable, angle the CR 10° cephalically
  - Tilt the head caudally—the amount depending upon the distance between the lower edge of the upper incisors and the base of the skull
  - Tilt the head cephalically—the amount depending upon the distance between the lower edge of the upper incisors and the base of the skull
- 92 (254) What is the *primary* purpose for doing oblique views of the cervical spine?
- To demonstrate intervertebral foramina
  - To show comparison films of spinous processes.
  - To demonstrate the vertebral arches.
  - To demonstrate subluxation of the odontoid
- 93 (255) When performing oblique projections of the cervical spine on a supine patient suspected of having a vertebral fracture, what CR angulation should you use?
- 15° medial and 45° cephalic.
  - 15° medial and 45° caudad
  - 45° medial and 15° cephalic
  - 45° medial and 15° caudad
- 94 (256) Which radiograph of the thoracic spine *best* demonstrates the amount of kyphosis on a patient?
- Erect AP
  - Full lateral
  - Supine AP
  - Twining position
- 95 (256) A lateral radiograph of the thoracic spine shows ribs superimposing the vertebral bodies. What should you do to correct the superimposition?
- Rotate the patient anteriorly until the coronal plane forms a 70° angle with the table.
  - Rotate the patient posteriorly until the coronal plane forms a 70° angle with the table
  - Angle the CR 5° caudad.
  - Have the patient breathe quickly and shallow
- 96 (256) Your radiologist requests a Twining position on a patient who cannot depress the shoulders. How should you obtain this view?
- Angle the CR 5° caudad
  - Angle the CR 5° cephalic.
  - Increase the kilovoltage 15%.
  - Take the exposure on suspended expiration
- 97 (257) How is a patient positioned to demonstrate the right apophyseal joints of the thoracic spine?
- From the left lateral recumbent position, the patient's right side is rotated anteriorly 20°.
  - From the right lateral recumbent position, the patient's left side is rotated anteriorly 20°.
  - From the supine position, the patient's right side is rotated upward 45°.
  - From the supine position, the patient's left side is rotated upward 45°.
- 98 (258) Why should you flex the hips and knees on a supine patient when positioning for the AP lumbar spine?
- To raise the diaphragm.
  - To flatten the abdomen and improve contrast.
  - To reduce the lordotic curvature.
  - To increase the lordotic curvature.

- 99 (258) If an angled CR is used for the lateral projection of the lumbar spine, the direction and the average amount of the angulation is
- caudad—8° for males and 5° for females
  - caudad—5° for males and 8° for females
  - cephalic—10° for males and 5° for females
  - cephalic—5° for males and 10° for females
- 100 (259) What is the *most* common positioning error made when performing obliques of the lumbar spine?
- Improper FFD
  - Improper CR angulation
  - Improper patient angulation
  - Improper breathing instructions
- 101 (259) Where should the medial portion of the transverse process be located with respect to the vertebral body on a properly positioned oblique radiograph of the lumbar spine?
- Toward the anterior portion of the vertebral body
  - Toward the posterior portion of the vertebral body
  - In the approximate center of the vertebral body
  - Outside of the vertebral body
- 102 (260) Why is the AP position preferred to the PA position when demonstrating the sacrum?
- The AP reduces OFD
  - The PA reduces OFD
  - No CR angulation is required with the AP
  - AP puts the sacrum at right angles with the film
- 103 (261) Which position *best* demonstrates the right sacroiliac joint?
- Lateral recumbent
  - Right posterior oblique.
  - Left anterior oblique
  - Right anterior oblique
- 104 (262) To what point should the CR be directed for a lateral skull if the examination is being performed as part of a workup for headaches?
- Three-fourths of an inch anterosuperiorly to the external auditory meatus
  - One and one-half inches posterosuperiorly to the external auditory meatus
  - To the external auditory meatus
  - To the center of the skull
- 105 (263) How should the bilateral anterior and posterior clinoid processes of the sella turcica appear on a true lateral radiograph of the skull?
- Superimposed
  - Anterior or posterior rotation
  - Superior or inferior longitudinal angulation
  - Anterior clinoid processes one inch above the posterior clinoid processes
- 106 (264) Where are the petrous ridges projected on Caldwell's radiograph of the skull?
- Over the maxillary sinuses.
  - In the middle of the orbits.
  - Slightly superior to the supraorbital ridges
  - To the level of the lower margins of the orbits.

- 107 (264) A straight PA projection of the skull, rather than a Caldwell's projection, should be performed when the
- greater wings of the sphenoid are under study.
  - patient cannot tolerate the prone position
  - frontal bone is specifically to be demonstrated
  - examination is to demonstrate sinus fluid levels
- 108 (265) With the skull in true AP position, what CR angulation and direction should be used to demonstrate the entire foramen magnum?
- 15° caudad
  - 30° caudad
  - 37° caudad
  - 50° to 60° caudad
- 109 (265) Which of the following best describes the routine Chamberlain-Towne's projection?
- Orbitomeatal line—perpendicular; CR—30° caudad.
  - Orbitomeatal line—perpendicular, CR—37° caudad
  - Infraorbitomeatal line—perpendicular; CR—30° caudad
  - Infraorbitomeatal line—perpendicular, CR—50° caudad.
- 110 (266) A patient is properly positioned for a submentovertical projection when the
- orbitomeatal line is parallel with the film and the CR is perpendicular to the film
  - head is tilted 15° toward the side under study, and the CR is angled laterally 5°
  - infraorbitomeatal line is parallel with the film and the CR is perpendicular to the film.
  - median plane is parallel to the film, and the CR is perpendicular to the infraorbitomeatal line.
- 111 (266) What do both basal projections of the skull have in common?
- CR is perpendicular to the orbitomeatal line.
  - CR is perpendicular to the infraorbitomeatal line
  - Median plane is parallel with the film.
  - Orbitomeatal line is parallel with the film
- 112 (267) Which sinuses are best demonstrated in the Pirie position?
- Sphenoid
  - Ethmoid
  - Maxillary.
  - Frontal.
- 113 (267) What would be the results of a Waters' position radiograph taken with the orbitomeatal line forming an angle considerably more than the recommended 37° to the table?
- Frontal sinuses superimposing maxillary sinuses
  - Ethmoid sinuses superimposing maxillary sinuses
  - Foreshortening of maxillary sinuses.
  - Petrous ridges superimposing maxillary sinuses.
- 114 (267) Which sinus position best demonstrates all four sets of sinuses?
- Caldwell's
  - Lateral
  - Pirie's or submentovertical.
  - Waters'.
- 115 (268) Why should ears be taped forward for certain projections of mastoids?
- To reduce detail.
  - To prevent motion.
  - Because extraneous shadows of the ear reduce detail
  - Because less secondary radiation will be absorbed.



- 116 (269) How should the CR be projected for a Law's position if the patient's face is rotated 15° toward the table?
- 15° caudad
  - 15° toward the face
  - Perpendicular to the film
  - 15° caudad and 15° toward the face
- 117 (270) Which position requires the AP skull to be rotated 45° and the CR angled 10° caudad?
- Schuller's
  - Pine's
  - Stenvers'
  - Arcelin's
- 118 (271) Which projection produces an excellent lateral view of the mastoid process nearest the film?
- Mayer's
  - Stenvers'
  - Schuller's
  - Arcelin's
- 119 (271) Which position requires the skull to be true lateral, the infraorbitomeatal line parallel with the transverse axis of the film, and the CR angled 25° caudad?
- True Law's
  - Modified Law's
  - Mayer's
  - Schuller's
- 120 (272) What is the *major* disadvantage of the AP Rhese position as compared to the PA Rhese position?
- Use of the infraorbitomeatal line instead of the acanthiomeatal line.
  - The angling of the CR at 12° cephalic
  - Magnification of the optic foramen
  - No use of a grid
- 121 (273) Where is the optic foramen demonstrated when the head is properly positioned for the Rhese projection?
- In the middle of the lower outer quadrant of the orbit
  - In the upper outer quadrant of the orbit
  - Just inferior to the lower level of the petrous ridge
  - In the center of the orbit.
- 122 (274) If you use the basic submentovertical projection to demonstrate the left zygomatic arch, what procedure should you use to project the structure away from the side of the head?
- Direct the CR perpendicular to the orbitomeatal line
  - Tilt the top of the head to the right 15°
  - Tilt the top of the head to the left 15°
  - Direct the CR 20° medially
- 123 (274) Which plane should be parallel to the film when positioning the skull for the May's projection?
- Orbitomeatal
  - Infraorbitomeatal
  - Acanthiomeatal
  - Median

124 (275) One method of positioning for the lateral oblique of the mandible requires the patient to be supine with the skull turned to a true lateral position. Why should you angle the CR 30° cephalic for this projection?

- a To elongate mandibular ramus
- b To project the CR perpendicular to the mandibular body
- c To superimpose mandibular ramus
- d To prevent superimposing both sides of the mandible

**END OF EXERCISE**

## STUDENT REQUEST FOR ASSISTANCE

### PRIVACY ACT STATEMENT

**AUTHORITY** 10 USC 8012 and EO 9397 **PRINCIPAL PURPOSES** To provide student assistance as requested by individual student; **ROUTINE USES** This form is shipped with ECI course Package. It is utilized by the student, as needed, to place an inquiry with ECI. **DISCLOSURE** Voluntary. The information requested on this form is needed for expeditious handling of the student's need. Failure to provide all information would result in slower action or inability to provide assistance to the student.

### SECTION I: CORRECTED OR LATEST ENROLLMENT DATA *(Mail to ECI Gunter AFS 41 3611)*

1 THIS REQUEST CONCERNS COURSE (1-6)	2 TODAY'S DATE	3 ENROLLMENT DATE	4 AUTOVON NUMBER
5 SOCIAL SECURITY NUMBER ( / 15)	6 GRADE/RANK	7 NAME (First initial, second initial, last name) (17) (18) (19-32)	
8 ADDRESS <i>(OJT Enrollees -- Address of unit training office with zip code. All others -- current mailing address with zip code.)</i>		(33 93)	(54 75)
9 NAME OF BASE OR INSTALLATION IF NOT SHOWN ABOVE			10 TEST CONTROL OFFICE ZIP CODE/SHR'D (33-39)

### SECTION II: REQUEST FOR MATERIALS, RECORDS, OR SERVICE

*(Place an X through number in box to left of service requested)*

### FOR ECI USE ONLY

1 Request address change as indicated in Section I.	16	
2 Request Test Control Office change as indicated in Section I	G	33
3 Request name change/correction (Provide Old or Incorrect data)	K	Vol 33-35 GR 36-38
4 Request Grade/Rank change/correction.	M	33 34 35 40
5 Correct SSAN. (List incorrect SSAN here) (Correct SSAN should be shown in Section I)	N	33 38
6 Extend course completion date. (Justify in REMARKS)	P	Vol 33-35 TC 36-37
7 Request enrollment cancellation.	Q	33 34 Volume 35 37
8 Send VRE answer sheets for Vol(s): 1 2 3 4 5 6 7 8 9 Originals were: <input type="checkbox"/> Not received <input type="checkbox"/> Lost <input type="checkbox"/> Misused	38	39 42
9 Send course materials. (Specify in REMARKS) <input type="checkbox"/> Not received <input type="checkbox"/> Lost <input type="checkbox"/> Damaged	1	39 42
10 Course exam not yet received. Final VRE submitted for grading on _____ (date)	2	39 42
11 Results for VRE Vol(s) 1 2 3 4 5 6 7 8 9 not yet received. Answer sheet(s) submitted _____ (date).	3	39 42
12 Results for CE not yet received. Answer sheet submitted to ECI on _____ (date)	16	
13 Previous inquiry ( <input type="checkbox"/> ECI Fm 17, <input type="checkbox"/> Ltr, <input type="checkbox"/> Msg) sent to ECI on _____ (date)		
14 Give instructional assistance as requested on reverse		
15 Other (Explain fully in REMARKS)		

REMARKS *(Continue on Reverse)*

OJT STUDENTS must have their OJT Administrator certify this request

I certify that the information on this form is accurate and that this request cannot be answered at this station. *(Signature)*

ALL OTHER STUDENTS may certify their own requests

ECI FORM OCT 82 17

(PREVIOUS EDITIONS MAY BE USED)

**SECTION III REQUEST FOR INSTRUCTOR ASSISTANCE**

**NOTE** Questions or comments relating to the accuracy or currency of subject matter should be forwarded directly to preparing agency. For an immediate response to these questions, call or write the course author directly, using the AUTOVON number or address in the preface of each volume. All other inquiries concerning the course should be forwarded to ECI.

**VRE Item Questioned**

Course No \_\_\_\_\_  
Volume No \_\_\_\_\_  
VRE Form No \_\_\_\_\_  
VRE Item No \_\_\_\_\_  
Answer You Chose \_\_\_\_\_  
(Letter)

Has VRE Answer Sheet  
been submitted for grading?  
 Yes  No

**REFERENCE**

(Textual reference for the  
answer I chose can be  
found as shown below)

In Volume No \_\_\_\_\_  
On Page No \_\_\_\_\_  
In  left  right column  
Lines \_\_\_\_\_ Through \_\_\_\_\_

**MY QUESTION IS**

**REMARKS**

ADDITIONAL FORMS 17 available from trainers, OJT and Education Offices, and ECI. Course workbooks have a Form 17 printed on the last page.

90370 03 8311


CDC 90370

# RADIOLOGY TECHNICIAN

(AFSC 90370)

Volume 3

*Special Techniques*



Extension Course Institute

Air University

294

Prepared by  
MSgt Steven G Hayes  
(AUTOVON 736-2809/2647)

Reviewed by  
W B McCraney

Edited by  
Jane C Hartin



SCHOOL OF HEALTH CARE SCIENCES USAF (ATC)  
SHEPPARD AIR FORCE BASE TEXAS 76311

EXTENSION COURSE INSTITUTE (AU)  
GUNTER AIR FORCE STATION, ALABAMA 36118

295

## Preface

THIS VOLUME is devoted to various examinations or methods that we call special techniques. As we mention throughout this volume, the exact procedural steps used depend mostly upon the preference of your radiologist, although some other factors also influence procedures used.

You may not be performing some of these examinations in your radiology department at present. Also, you may not have performed any of them in the past. These circumstances should not lessen your desire to learn, however, because at one time or another during your Air Force career you will be required to perform and supervise the performance of these special techniques.

In addition to the special radiographic techniques covered in the following chapters that are common to most radiology departments, we also include two diagnostic imaging methods that quickly are becoming commonplace: ultrasound and computed tomography. Even though ultrasonography is not a radiographic examination, it remains a procedure that applies to radiology departments. Therefore, we consider it a special technique.

There may be some confusion as to what constitutes a routine or special procedure, technique, or method. We agree that this deals with word games and often depends on the individual technician, department, or situation. However, in this volume we try to include some techniques or methods which may not be common to all radiological facilities. Thus, they are *special techniques*.

Chapter 1 deals with mammography and xeroradiography. We review breast anatomy and physiology and cover common projections of the breast. Since xeroradiography has become closely associated with mammographic procedures, we include basic physics and procedures of xeroradiography.

Chapter 2 covers the main projections of obstetrical radiography. In Chapter 3 you will study fundamentals and exam procedures of ultrasonography. Routine radiographic tomography is examined in Chapter 4, and in Chapter 5 we explain an advanced form of tomography—computed tomography.

Purposes, principles, and procedures of scanography are covered in Chapter 6; arthrography also is found in that chapter. Performing mobile radiographic exams on bedridden patients or in surgery is explained in Chapter 7. Our last chapter in this volume, Chapter 8, deals with principles and procedures of duplicating radiographs, and film subtraction techniques.

The inclusion of names of any specific commercial product, commodity, or service in this publication is for information purposes only and does not imply indorsement by the Air Force.

This volume is valued at 27 hours (9 points).

Material in this volume is technically accurate, adequate, and current as of July 1983.

# Contents

	<i>Page</i>
<i>Preface</i> . . . . .	<i>iii</i>
<i>Chapter</i>	
1 Mammography and Zeropradiography . . . . .	1
2 Obstetrical Radiography . . . . .	14
3 Ultrasonography . . . . .	24
4 Tomography . . . . .	46
5 Computed Tomography . . . . .	60
6 Scanography and Arthrography . . . . .	72
7 Bedside and Surgical Radiography . . . . .	79
8 Film Duplication and Subtraction . . . . .	85
 <i>Bibliography</i> . . . . .	 91
<i>Answers for Exercises</i> . . . . .	92



# Mammography and Xeroradiography

**INTRAMAMMARY** masses, such as carcinoma, were once detectable only by palpation and identifiable only via biopsy. In many cases, by the time they were detected, the masses were so large that radical mastectomy was the only course of therapeutic action, and metastasis had already occurred. Today some of these masses can be radiographically demonstrated in an early stage. Consequently, treatment can often be initiated at a time when it can do the most good.

As is the case with most radiographic examinations, an understanding of the anatomy involved is necessary. Therefore, we begin our coverage with a review of the anatomy of the breast. Following that, we explain some of the technical aspects of producing mammograms and xeroradiographs.

## 1-1. Anatomical Considerations of the Breast

Functionally, the female breasts are accessory glands of the reproductive system. They are made up of various types of tissue in varying amounts, depending upon the age and obstetrical condition of the patient.

### 400. Identify parts of a breast with their composition or location.

**External Structure of the Breast.** The surface landmarks of the breast include the nipple and the areola (see fig. 1-1). The nipple is perforated by 15- to 20-minute ducts. The areola is the highly pigmented area surrounding the nipple.

**Internal Structure of the Breast.** Here we are mainly concerned with the three types of breast tissue and the retromammary space (see fig 1-2).

**Fibrous tissue.** Fibrous breast tissue consists of two layers of fascia, suspensory ligaments, and an irregularly pitted framework for the glandular tissue. The fascia layers, superficial and deep, are joined and completely house the mammary gland. The suspensory ligaments are vertical bands of elastic fibrous tissue and connect the deep layer of fascia with the skin. The remainder of the fibrous tissue comprises the honeycombed framework for the mammary gland.

**Glandular tissue.** The glandular tissue (mammary gland) consists of 15 to 20 lobes, each of which is made up of numerous lobules. All are interconnected by the lactiferous ducts, which form a distinct network. The tiny ducts from the lobules, called terminal ducts are acini, empty into the larger main ducts. These in turn empty into the lactiferous tubules that extend from each lobe into the nipple.

**Fatty tissue.** Fatty (adipose) tissue completely surrounds, and is distributed in, the glandular tissue in varying amounts, depending upon the patient's age and obstetrical condition.

**Retromammary space.** Between the posterior portion of the mammary gland and the pectoral muscle is the retromammary space. This space is radiographically significant, as we shall see later in this chapter.

### Exercises (400):

- Match the breast structure in column B with the appropriate statement or phrase in column A. Each column B item may be used once, more than once, or not at all. In addition, more than one column B item may match a single column A entry.

Column A	Column B
— (1) External landmarks	a Nipple
— (2) Composed of numerous lobules	b Fatty tissue
— (3) Fascia.	c Glandular tissue
— (4) Surrounds and is distributed in the mammary gland	d Areola
— (5) Extend from glandular lobes to the nipple	e Fibrous tissue
— (6) Between the mammary gland and the chest wall	f Terminal ducts
— (7) Suspensory ligaments	g Lactiferous tubules
	h Retromammary space
	i Lactiferous ducts

### 401. Specify the relative densities of the three types of breast tissue, and name the types that require the least and the most exposure.

**Structural Variations of the Breast.** The density of the breast and, consequently, the exposure required depends in part upon the ratio of fibroglandular (fibrous and glandular) tissue to fatty tissue. Fibrous tissue and glandular tissue are approximately equal in densities while fatty tissue is the least dense of the three types of breast tissue. The more fibroglandular tissue there is in the breast, in relation to the amount of fatty tissue, the greater the density of the breast.

The breasts usually undergo a gradual change in tissue ratio from the adolescent years to the postmenopausal years. This gradual change is the basis for categorizing the breasts into five types (see fig. 1-3).

**Adolescent breast.** The adolescent (virginal) breast has a rudimentary ductal system and consists mainly of fibroglandular tissue.

**Mature breast.** In the mature breast, there is an increasing amount of adipose tissue and a corresponding decrease in fibroglandular tissue.

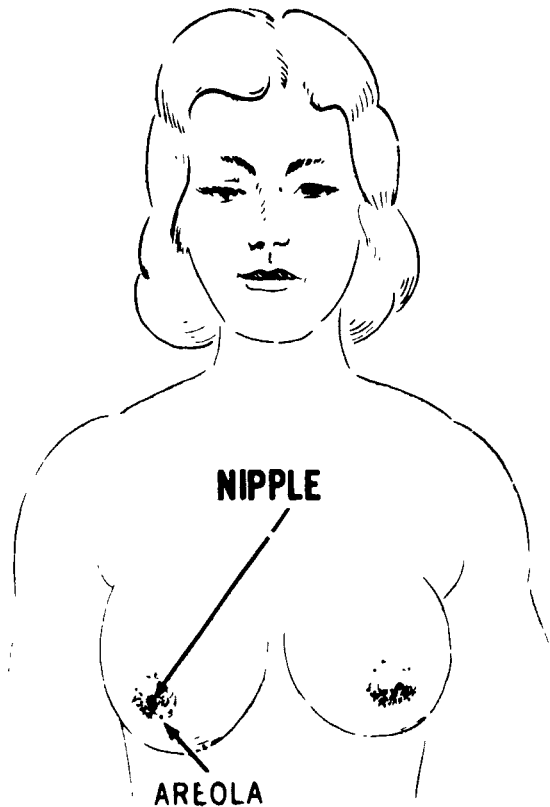


Figure 1-1

**Lactating breast.** During pregnancy, hormonal stimulation causes an increase in the size of the breast. Glandular tissue grows and replaces much of the fat. As a result, the lactating, or milk-producing, stage compares with the adolescent breast in terms of density.

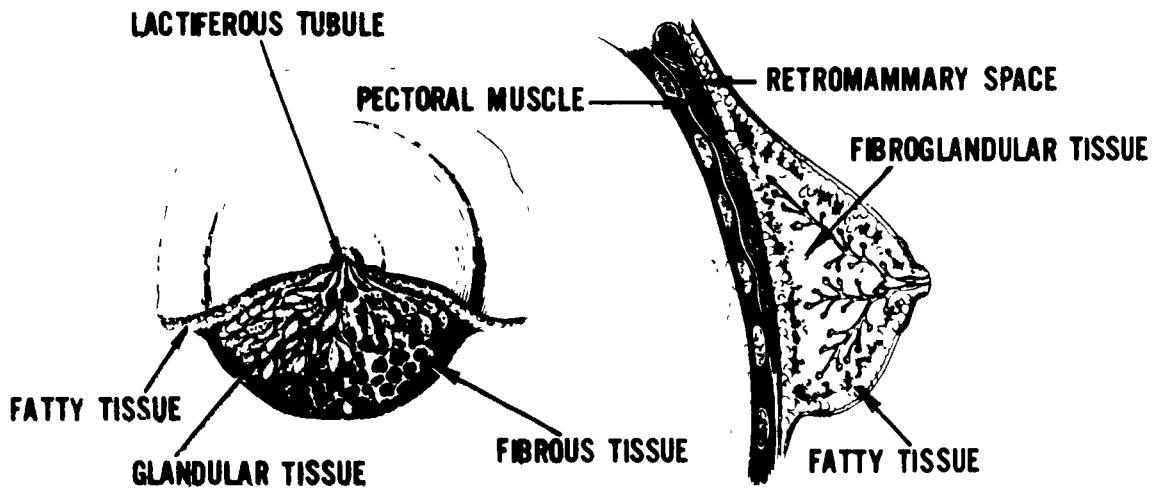


Figure 1-2 Internal structures of a breast

**Menopausal breast.** As a woman approaches and passes through menopause, there is a further increase in adipose tissue, with little fibroglandular tissue present.

**Atrophic breast.** At this stage, adipose tissue has completely replaced the fibroglandular tissue. The atrophic breast is less dense than any of the others

**Exercises (401):**

1. What are the relative densities of the three types of breast tissue?
2. Assuming all other factors are equal, what type of breast requires the least exposure and why?
3. Assuming all other factors are equal, what type(s) of breast require(s) the most exposure?

**1-2. Technical Considerations of Mammography**

In this section, we will discuss the technical aspects of producing good mammograms. Areas covered include tube requirements, films, screens, exposure factors, and standard projections

**402. Identify X-ray tube requirements for producing good mammograms.**

**Tube Requirements.** Factors such as focal spot size, tube capacity, filtration, and beam restrictors must be given special consideration in order to produce good mammograms.

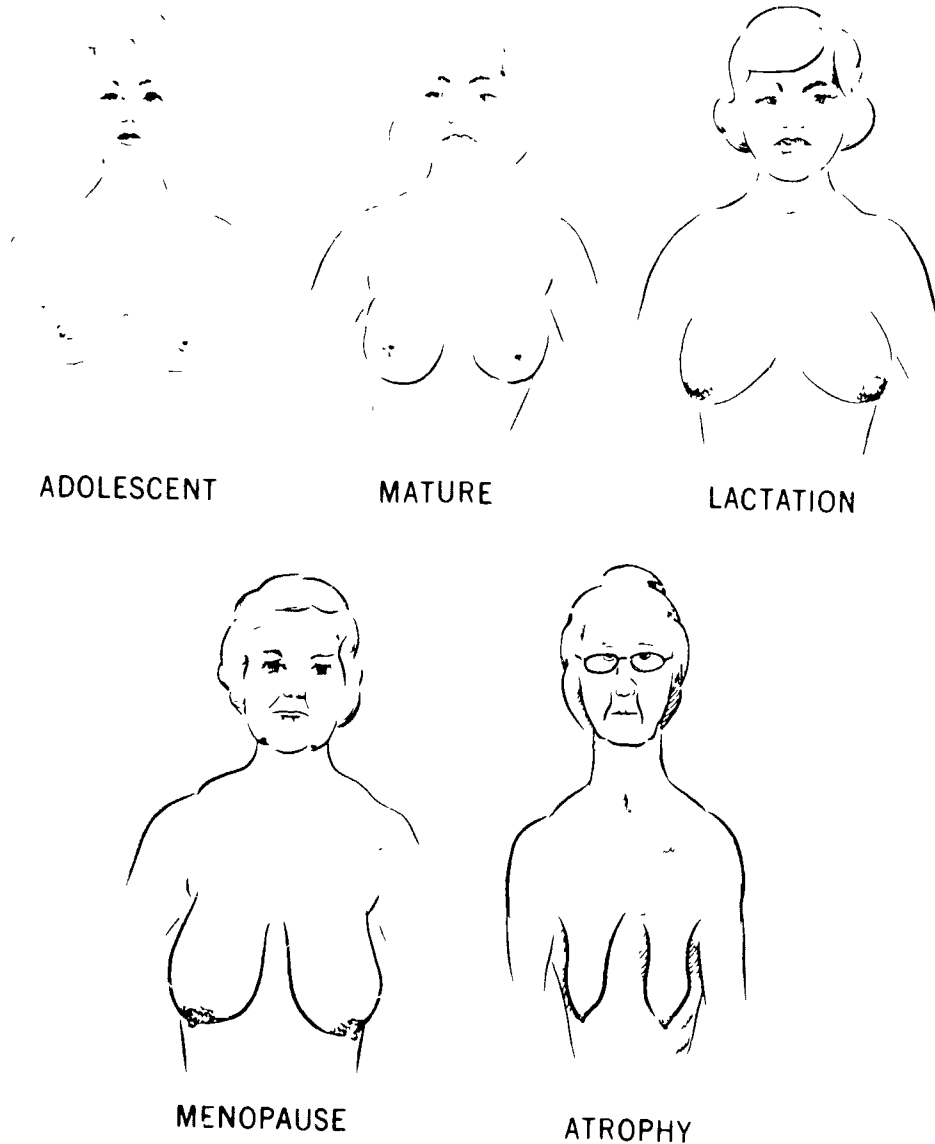


Figure 1-3

**Focal spot size.** A factor to consider in selecting the focal spot is its capacity to withstand the heat generated in a single exposure. Naturally, a large focal spot can tolerate higher exposures than a small one. Consequently, when high exposure factors are used, you may need to use a large focal spot. However, if the exposure factors are low enough to permit the use of a small focal spot, then you should do so. A smaller focal spot gives better detail, and detail on a mammogram is extremely important.

**Anode storage capacity.** To produce the desired contrast on a mammogram, you must use low kVp. Low kVp in conjunction with high milliampere seconds (mAs) (which is generally used in mammography) produces a tremendous amount of H.U. (heat units) in the X-ray tube. For example, suppose the technique for a single projection is 26 kVp and 1,800 mAs. This would amount to 46,800 H.U. ( $26 \times 1,800 = 46,800$ ). Since three views of each breast are

normally included in a mammographic study, the total would be 280,800 H.U. ( $6 \times 46,800 = 280,800$ ), which considerably exceeds the anode storage capacity of some X-ray tubes. Therefore, to prevent damage to the anode, it would be necessary to allow for cooling time between exposures. Cooling time is based on the anode cooling curve found on the tube rating charts explained in Volume 1.

**Filtration.** Demonstrating the differences between breast tissue requires a soft, heterogeneous X-ray beam. Ideally, then, mammography should be done using no filtration. However, as we discussed in Volume 1, to keep patient exposure to a minimum, you must use a minimum amount of filtration, depending upon the kVp used.

Generally the minimum requirements are exceeded by using at least 2.5 millimeters (mm) of aluminum for all radiographic examinations. However, for mammography

you should not exceed the minimum requirements. Doing so would increase the number of low energy photons filtered out thereby decreasing overall contrast. Due to the relatively homogeneous structure of the breast, this decreased contrast would result in less information on the radiograph. Therefore, if the inherent filtration of your tube is 0.5 mm of aluminum, you should remove all of the added filtration. Keep in mind that an ordinary collimator usually contains a certain amount of aluminum equivalent filtration and, therefore, must be removed. Special collimators are available with minimum filtration and can be used. Special tubes are also available, however, some have less than the required filtration. For example, some beryllium window tubes may have from 0.1 to 0.3 mm. If this is the case, additional filtration to bring the total to 0.5 mm must be added.

**Beam restrictors.** The radiation field for a mammogram should be restricted so that it covers the breast plus no more than a 1-inch border. This tightly restricted X-ray field is necessary because scatter radiation can cause film fogging and lower the contrast. Since adequate contrast on a mammogram is somewhat difficult to obtain, film fogging must be kept to an absolute minimum.

The particular beam restrictor used for a mammogram should be designed to reduce the off-focus radiation reaching the film. Off-focus radiation is that radiation emitted from areas of the anode other than the target. Off-focus radiation reaching the film reduces image detail because, in actuality, it causes an increase in the effective focal spot size. Notice in figure 1-4 that the aperture of the cylinder in drawing A is different from that in drawing B. Notice that the aperture in drawing B absorbs some off-focus radiation which would reach the film in drawing A. Specially constructed cylinders are made with small, conical-shaped apertures, like the one shown in drawing B, to reduce off-focus radiation.

#### Exercises (402):

Indicate whether the following statements are true (T) or false (F). If you indicate false, explain your answer

- 1. A maximum of 0.1 mm of aluminum or its equivalent is required when accomplishing a mammogram.
- 2. You should use the smallest focal spot to perform mammography.
- 3. The generation of H.U. during a mammogram is especially significant because of the exposure factors.
- 4. Anode storage capacity is the only tube rating consideration necessary for mammography.
- 5. The X-ray field for a mammogram should cover the breast plus a 1-inch border.
- 6. Reduction of the contrast on a mammogram can result from improper beam restriction.

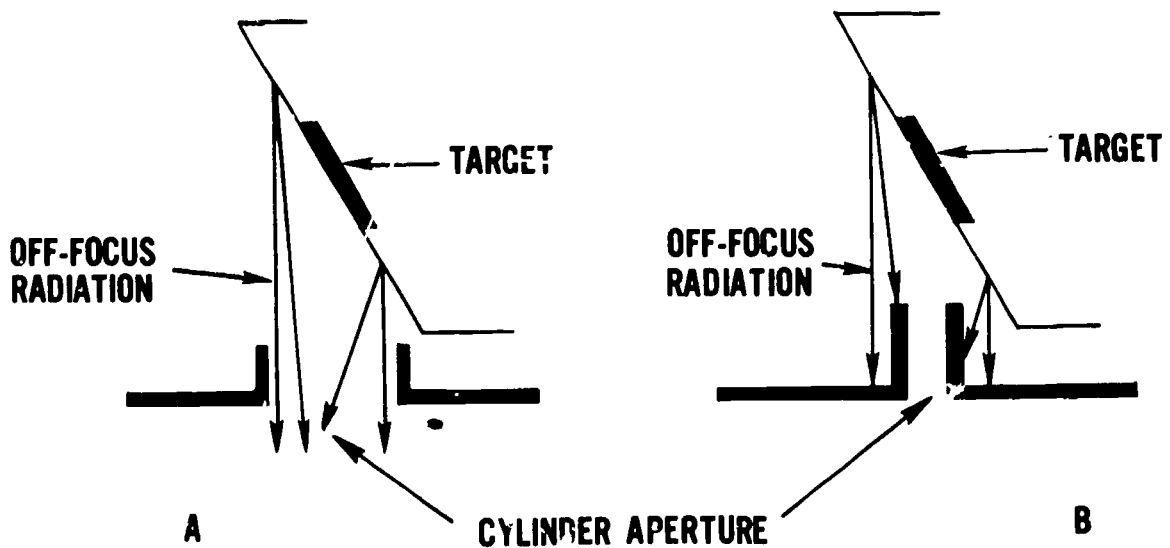


Figure 1-4

— 7 Off-focus radiation can reduce image detail on a mammogram

— 8 A beam restrictor designed to reduce off-focus radiation has a large aperture

— 9 Minimum amounts of filtration are used in mammography to enhance contrast

3 Give two ways of obtaining radiographs with various densities from a single exposure.

4. What is the advantage of using film with different densities from a single exposure?

5 If intensifying screens are used for mammography, what type should be used?

6 Give one disadvantage and one advantage in using intensifying screens for mammography.

#### 403. Cite criteria for using films and intensifying screens in mammography.

**Films and Screens.** Standard coarse-grained radiographic film is not suitable for the fine detail required in mammography. Thus, fine-grained industrial or special mammographic film is used. Such film is available from several manufacturers.

Since the film is available with different speeds in a single package, you can produce radiographs with different densities from a single exposure. Some prefer multifilm exposures because they permit good visualization of both thick and thin portions of the breast from a single exposure. You can easily assemble films of various speeds in a direct exposure film holder to serve the same purpose.

Some industrial or mammographic film can be processed in automatic processors while others must be hand processed. In either case, be sure to follow the film manufacturer's processing instructions.

While intensifying screens have not been used extensively in the past for mammography, they are now preferred by some radiologists. The problem with using screens is the normal loss of detail that results. However, special high-detail screens made for mammography which result in less detail loss are now available and are recommended for use. The big advantage of using screens is that mammographic exposure times can be reduced, thus helping to eliminate patient motion and reducing the number of heat units produced.

#### Exercises (403):

1. Why shouldn't you use standard radiographic film for mammography?

2. What is the difference in the grain between standard and industrial or mammographic film?

#### 404. Cite the factors to consider in establishing the mAs and kVp to be used for mammographic examination.

**Exposure Factors.** The mAs and focal film distance (FFD) used for mammograms are somewhat flexible, as we will point out later in this section. However, kVp must be used within certain limits.

When you perform a radiograph of a bony structure—the leg, for example—it is easy to get adequate contrast between the bones and muscle, as we explained in Volume 1. We stated that because of the significant difference between the atomic numbers of bone and muscle, the selective absorption of X-ray photons is sufficiently different to show two distinct densities on the radiograph—or adequate contrast.

In the breast, we are primarily concerned with three types of tissue. Two of them we covered at the beginning of this chapter—fibroglandular and fatty. The third type is the pathological tissue we are trying to demonstrate on the radiograph. Providing adequate contrast between these three types of tissue is much more difficult than doing so between bone and muscle because the absorption properties of fibroglandular, fatty, and pathological tissue are *nearly* equal. We emphasized "nearly" because there is some difference—and the difference can be recorded. To demonstrate this difference you must use low kVp—20 to 30 for most craniocaudal and lateral projections. The axillary projection sometimes requires up to 50 kVp because a certain amount of muscle tissue must be penetrated.

**Milliamperere Seconds and Focal Film Distance.** The specific mAs and FFD you use depend upon several factors. They are also closely related to each other since both affect the quantity of radiation reaching the film.

One factor that obviously affects the mAs needed is the speed of the film. Some slow fine-grained films need up to 1,800 mAs for the proper amount of blackening, while others need less. The use of intensifying screens obviously reduces the mAs required.

When establishing the mAs, you must also consider the individual mA and time values. Keep exposure time as short as possible since part motion is the most common cause of detail loss on mammograms. A long exposure used with a small mA station increases the need to repeat examinations because of part motion. If the small focal spot on your unit needs a long exposure to fulfill the mAs requirement, it is probably better to use a larger focal spot and sacrifice some detail than to *continuously* repeat examinations because of part motion.

If you must use a large focal spot, the loss of detail can be partially offset by using a relatively long FFD—in this case, up to 40 inches. The FFD range for mammograms is normally 20 to 40 inches. Some radiologists prefer to use nearly 40 inches for all mammograms because this reduces the skin dose to the patient; however, the long FFD requires more exposure due to the inverse square law. While a short FFD can reduce the exposure, it results in a loss of detail due to increased magnification. Naturally, a short FFD increases the skin dose to the patient.

#### Exercises (404):

1. What kVp should be used for the craniocaudal and lateral projections of the breasts? Why?
2. What kVp should be used for the axillary projection of the breast? Why?
3. Name three factors that affect the mAs needed for a mammographic examination.
4. What is the most common cause of detail loss on a mammogram? How can you help reduce this detail loss?
5. What is the normal FFD range used in mammography?
6. Give two advantages and one disadvantage of using the long FFD during mammography.
7. Give an advantage and two disadvantages of a short FFD.

#### 405. Identify patient positions for making craniocaudal, mediolateral, and axillary projections of the breasts.

**Craniocaudal Projection.** The craniocaudal projection is made with the patient seated at the end of the X-ray table, as shown in figure 1-5. The breast should be positioned so that it is in profile and lies flat on the film, as seen in figure 1-6,A. Elevate the film or adjust the chair so that the patient does not have to raise or lower her chest to achieve the position. She must be seated comfortably; otherwise, she may not be able to maintain the position; and part motion is likely to occur. The patient's chest wall should be in contact with the end of the table to help stabilize her position. Figures 1-6,B, and 1-6,C, show the film positioned too low and too high respectively.

Position the film so it is against the chest wall. The film position is important because the posterior portion of the breast may not be visualized if the film is improperly placed. Some prefer to bend the film holder down, as seen in figure 1-7. Bending the film has the advantage that the entire breast is visualized but the posterior position (base) is somewhat distorted due to the angle of that edge of the film.

Make sure the skin is not wrinkled or folded. These conditions may obscure or suggest pathology. Also, make every effort to demonstrate the nipple in profile. Retraction of the nipple on the radiograph could be an indication of pathology.

Position the patient's arm on the side of the breast being radiographed so it is relaxed on the table, as shown in figure 1-5. This allows the full weight of the breast to lie on the film and helps to insure good part-film contact. Also, she can use the hand to hold the film holder firmly against the chest wall.

One common problem with the craniocaudal projection is that structures superior to the breast are superimposed over the base of the breast. These structures are the clavicle, clavicular and supraclavicular tissue, and glandular tissue of the upper outer quadrant of the breast. You can best eliminate the superimposed shadows by having the patient sit straight in her chair and by pulling her shoulders back. Inspecting of this position from above can help you to adjust the shoulders to eliminate the shadows.

**Mediolateral Projection.** The mediolateral projection is made with the patient in the lateral recumbent position, as seen in figure 1-8. The film is elevated 2 to 3 inches from the table, as shown, and placed under the patient so that the chest wall is included on the radiograph. Including the chest wall helps to insure demonstration of the retromammary space, which visualizes only on this projection.

Rotate the patient so that the breast lies flat on the film and the nipple is in profile to prevent simulation of nipple retraction. Have the patient retract the opposite breast to prevent its being superimposed over the breast being radiographed. Disregarding these two procedures is a common mistake with this projection.

**Axillary Projection.** Make the axillary projection with the patient positioned as shown in figure 1-9. Place the patient's arm at a 90° angle to the body. Rotate her until the tail (axillary portion) of the breast is in profile—usually 15° to 30°. Place the film flat on the table and align it to include



Figure 1-5

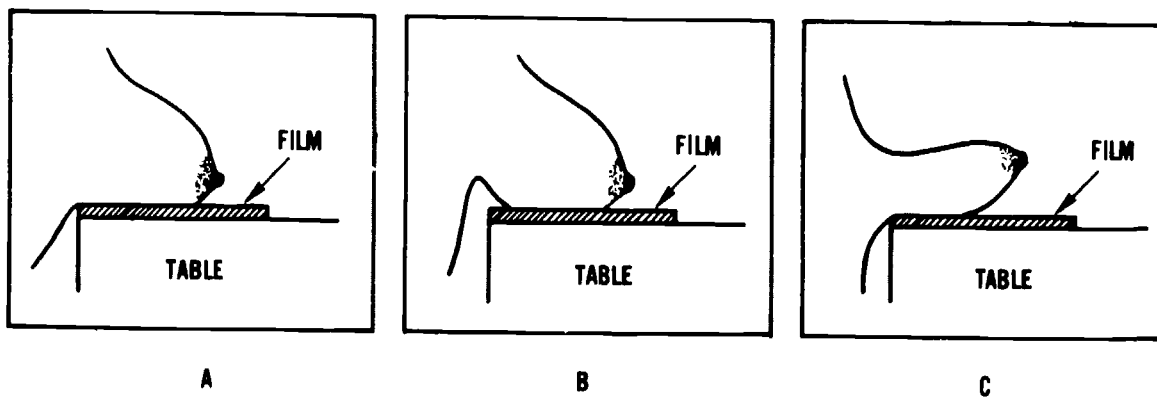


Figure 1-6

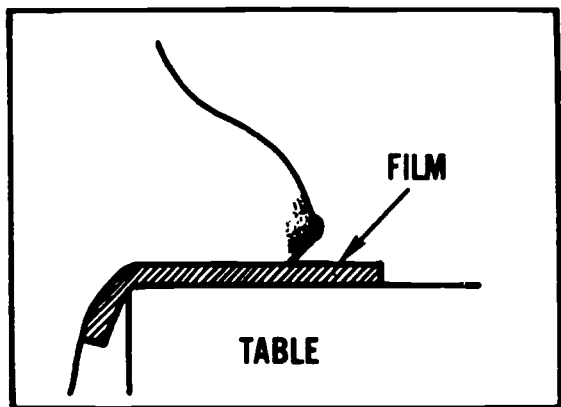


Figure 1-7 Craniocaudal projection showing film curved against the chest wall

the axillary area, tail of the breast, and upper outer quadrant.

**Exercises (405):**

Indicate whether the following statements are true (T) or false (F) If you indicate false, explain your answer.

- 1. The breast is positioned so the nipple is in profile only on the craniocaudal projection.
  
- 2. The end of the X-ray table can be used to advantage to prevent part motion on the craniocaudal projection.

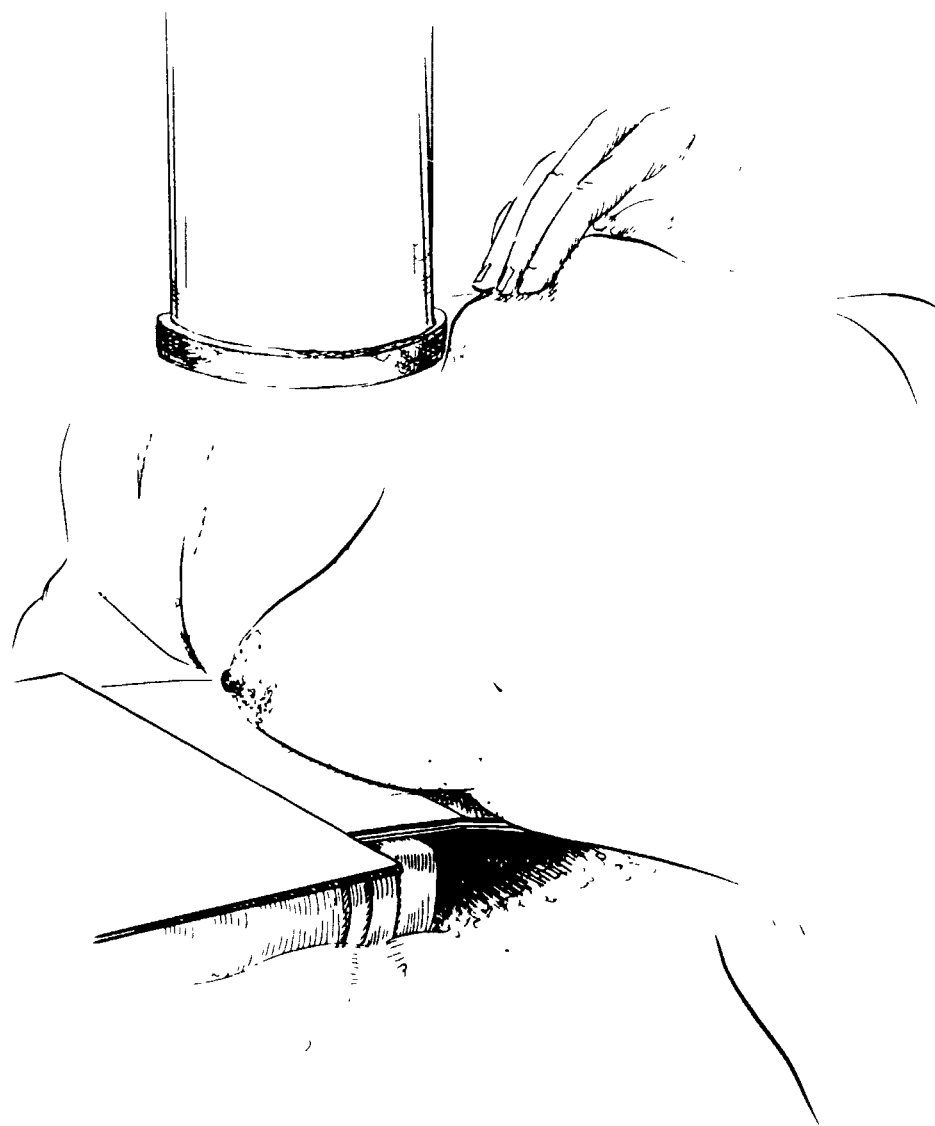


Figure 1-8



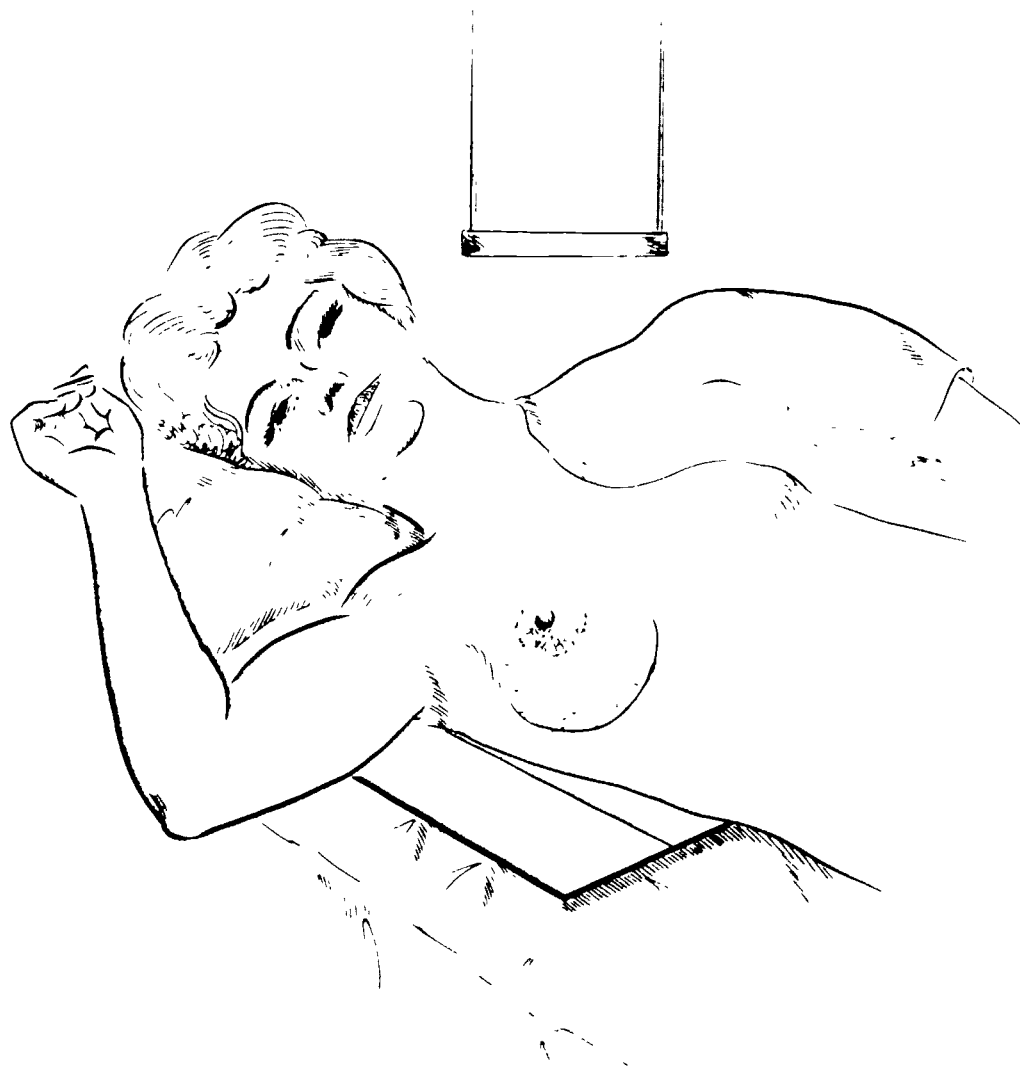

Figure 1-9 Axillary projection of the breast

- 3 Distortion of the posterior portion of the breast is caused by bending the film against the chest wall on the craniocaudal projection.
- 4 Firm contact between the film and chest wall is not important on the craniocaudal projection.
- 5 Failure to position the breast so that the nipple is in profile could simulate pathology on the radiograph.
- 6 Dense structures superimposed over the base of the breast may indicate improper positioning.
- 7 The axillary projection demonstrates the tail of the breast.
- 8 Unwanted shadows can be eliminated on the mediolateral projection by retraction of the opposite breast.

— 9. The amount of rotation of the patient for the axillary projection depends upon the relative position of the upper outer quadrant.

— 10. The mediolateral projection is the only radiograph which demonstrates the retromammary space.

### 1-3. Xeroradiography

Xeroradiography is an imaging system used in diagnostic radiology. While it was introduced many years ago, its clinical use has developed in the past few years. Xeroradiographs have been used principally in mammography because they give better resolution with higher subject contrast. Also, radiation exposure (when compared to standard mammography) to the patient is reduced. Using xeroradiography on other body parts continues to develop, particularly in thinner body parts. In this section, we do not propose to compare the relative merits of one system over the other; this decision is made in the radiology department. Instead, we will discuss some of the common terms associated with xeroradiography.

#### 406. State the major similarity and the major differences between conventional radiography and xeroradiography.

In xeroradiography, conventional X-ray equipment is used to make the exposure; but this is where the similarity ends. The xeroradiographic image is recorded by a special process which is photoelectric, not photochemical. Xeroradiographic plates are used instead of conventional film. These plates are coated with selenium, a photoconductor, upon which is deposited a positive electrical charge. The plate is inserted into a special cassette. Then the part is positioned and the exposure made. The resulting image, called an electrostatic latent image, is processed in a special unit. The processing unit uses a charged developing powder, called toner, which is literally blown on to the positively charged plate. The result is a visible image formed of powder on the plate. This image is then transferred and sealed onto opaque paper, rather than X-ray film. The entire process is dry, and no darkroom is needed.

#### Exercises (406):

1. State the major similarity between conventional radiography and xeroradiography.
2. State three major differences between conventional radiography and xeroradiography.

#### 407. State the functions of the components of the conditioner.

**Plate Preparation.** A xeroradiography plate consists of a sheet of aluminum coated with selenium, which is a photoconductor. A photoconductor is a special class of semiconductor (conductors, semiconductors, and insulators were discussed in Volume 1) in which the movement of electrons is normally inhibited. However, when external energy, such as X-rays, is applied, photoconductors become better conductors.

Before the plate can be loaded into a cassette for use, the selenium layer must be given a positive electrostatic charge. A conditioner (see fig. 1-10) does this and also stores the plates and loads the cassettes. A plate is removed from the storage box and is transported to a relaxation oven. By heating the plate, relaxation removes any residual charge pattern. This step prevents ghosting or carrying over of information from the previous examination. After relaxation, the plate has a uniform low level of surface potential. The plate then moves on to the storage elevator. When you insert an empty cassette into the conditioner, a plate passes under an ionization device, where a surface charge of positive ions is placed on the selenium layer. The ions are attracted to the plate by the large potential difference existing between the plate and ionization device. At this point you can control the sensitivity of the plate. The contrast selector adjusts the charge placed on the plate. The higher the plate voltage (actual voltage depends on your unit), the more sensitive the plate is to X-ray exposure; consequently, image contrast is higher. (This is generally desired in mammography, where subject contrast is low.) The charged plate is then automatically loaded into a cassette. The cassette protects the plate from light, which would discharge the positive electrostatic charge.

#### Exercises (407):

1. Match each term from column B with its function in column A. Each column B item is used once.

Column A	Column B
— (1) Places a charge on the selenium layer	a. Conditioner
— (2) Regulates the charge on the selenium layer	b. Relaxation
— (3) Prepares and stores plates and loads cassettes	c. Ionization device
— (4) Removes previous charge	d. Cassette
— (5) Protects plate from light	e. Contrast selector

#### 408. Explain discharge as it pertains to xeroradiographic exposure.

**Exposure.** The X-ray exposure in xeroradiography is carried out in the same manner as in conventional radiography. During exposure a discharge occurs which forms a charge pattern. Discharge is a reduction in the positive surface charge on the selenium plate. The degree to which a particular portion of the selenium layer is discharged depends on the intensity of the radiation striking

that portion. The greater the intensity, the greater the discharge. Figure 1-11,A, shows a uniformly charged selenium plate. Figure 1-11,B, depicts varying degrees of discharge caused by an X-ray beam with variations in intensity. This variation in X-ray beam intensity is caused by selective absorption of the part being examined. Where the X-ray photons are readily absorbed (as in bone), the remaining charge will be relatively high. Where the photons easily penetrate the structures (as in soft tissue), the remaining charge will be low. Consequently, the variation in tissue thickness and density are represented on the plate

surface as variations in the charge. This variation in discharge is called a charge pattern or electrostatic image.

**Exercises (408):**

1. What does "discharge" mean as it pertains to xeroradiographic exposure?

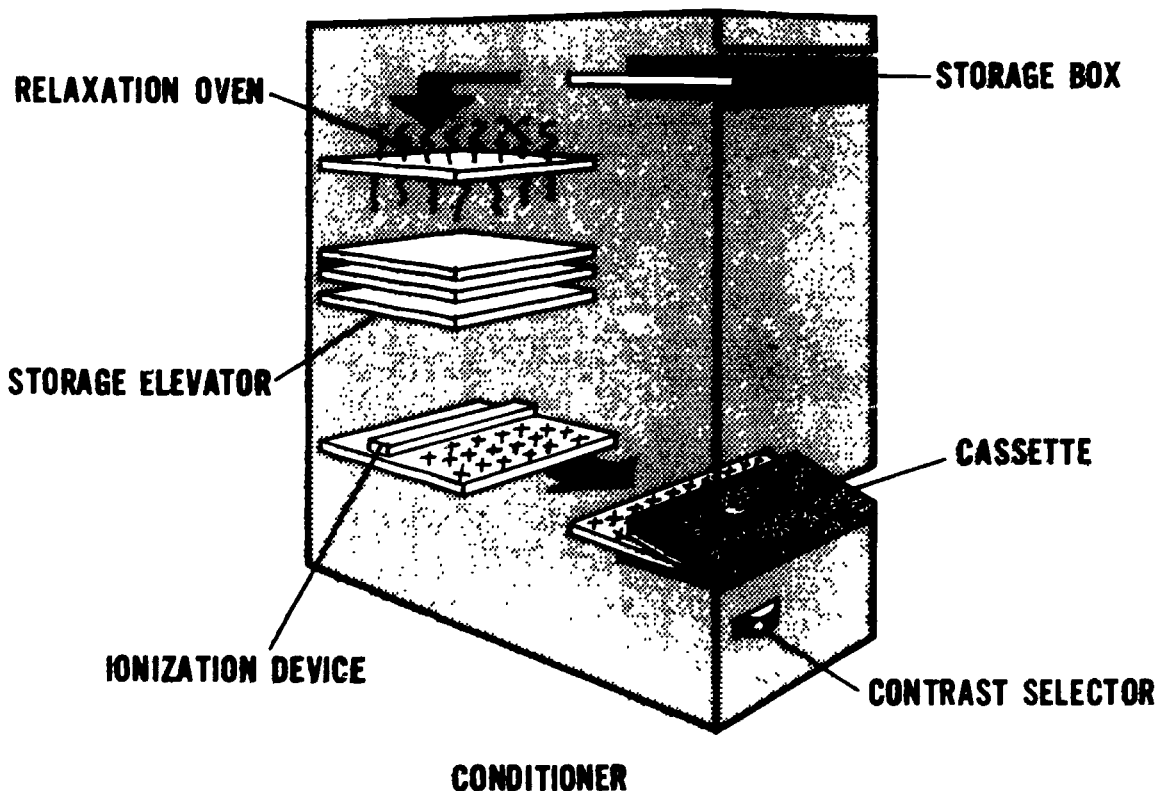


Figure 1-10 A xeroradiographic conditioner

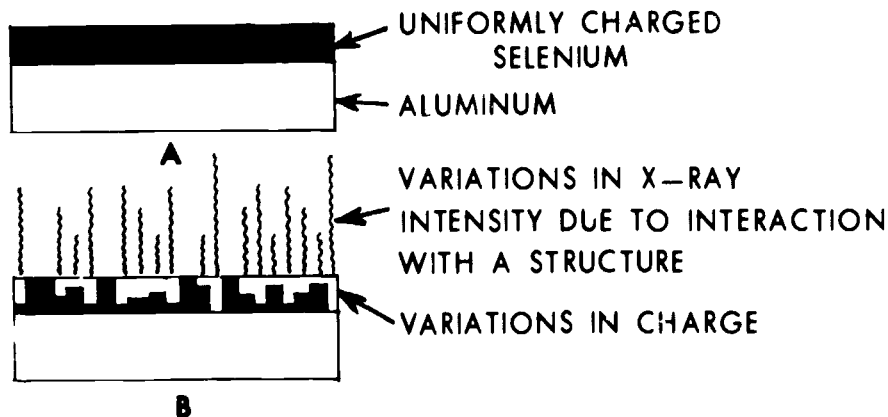


Figure 1-11

**409. Identify xeroradiographic plate processor components with their functions.**

**Processor.** The processor, shown in figure 1-12, automatically develops the electrostatic image, transfers the image to paper, and cleans the plate.

After exposure, insert the cassette into the processor. The plate is removed and transported to the development chamber. A charged blue powder, called toner, is blown against the selenium surface. You select the charge of the powder and the back bias voltage, either negative or positive, by adjusting the mode selector. Back bias is the voltage applied to the back side of the plate in the development chamber. This voltage and the existing charge pattern on the plate attract the charged toner particles to the plate surface. The positive mode uses a positive back bias voltage which attracts negatively charged toner particles. In a positive image, thick or dense areas (such as bone) appear

dark and blue while thin or less dense areas (soft tissue) are lighter blue. In this frequently used mode, the burst number, the number of times the toner is blown against the plate, is automatically controlled by the processor.

The negative mode uses a negative back bias voltage which attracts positively charged toner particles. In a negative image, dense structures appear white to light blue while surrounding soft tissue is a dark blue, similar to a conventional radiograph. In this mode you select the number of bursts by adjusting the density selector on the unit. The number of bursts determines the blueness or density of the final image.

As we have said, the toner is attracted to the electrostatic image on the plate. The amount attracted depends on the remaining charge and the back bias voltage. The image is made visible when a pattern of toner forms on the plate surface. Figure 1-13 (A and B) illustrates negatively charged particles being attracted to form the image.

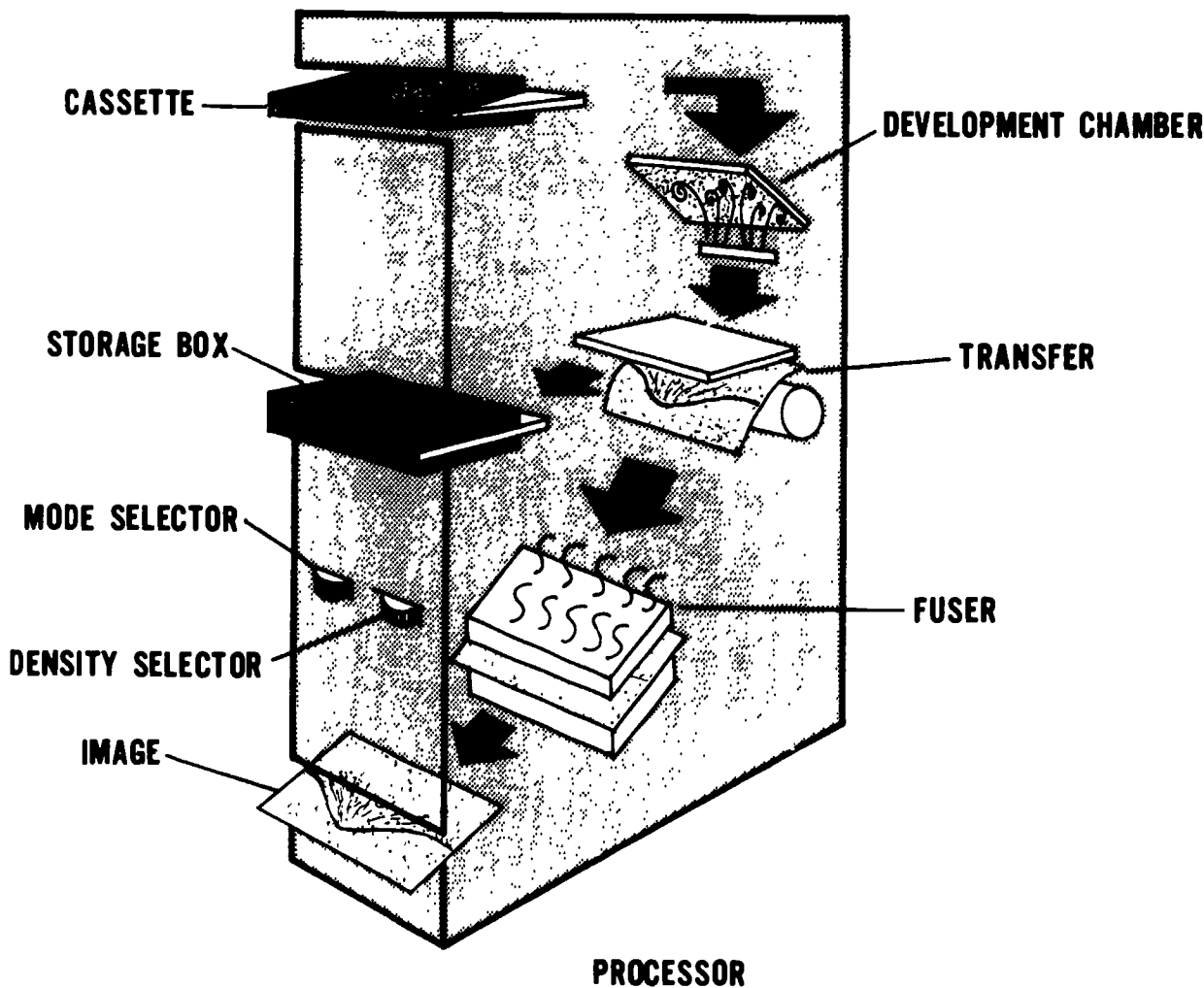


Figure 1-12 Xeroradiographic processor

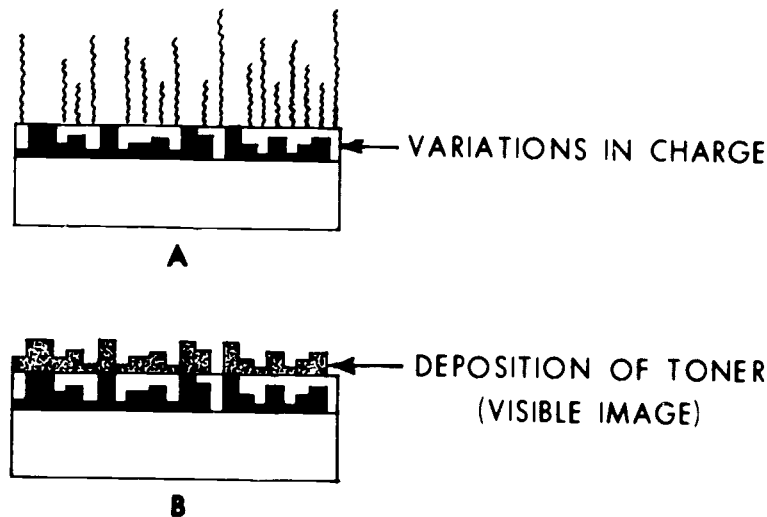


Figure 1-13

After it is developed, the plate is transported to the transfer area where the toner image is transferred to paper. The paper with the surface toner pattern is transported to a fusing station where heat is applied. Heat softens the plastic coating of the paper. When cooled, the image permanently adheres to the paper. The image is then ready for interpretation. Processing time is approximately 1½ to 2 minutes.

Another process occurs while the paper is being fused. After image transfer, the plate moves over a rotating brush which removes residual toner from the plate surface. The plate is then inserted into a storage box, which you will, in time, remove and place in the conditioner.

**Exercises (409):**

1. Match each term from column B with its function in column A. Each column B item is used once.

- | <i>Column A</i>  | <i>Column B</i>     |
|--|---------------------|
| _____ (1) Produces a reversed image                              | a Toner             |
| _____ (2) Toner image placed on paper                            | b Back bias voltage |
| _____ (3) Removes residual toner from plate                      | c Positive toner    |
| _____ (4) Permanently adheres image to paper                     | d Negative toner    |
| _____ (5) Charged blue powder                                    | e Transfer          |
| _____ (6) Either negative or positive, applied to back of plate. | f Fuser             |
| _____ (7) Produces an image similar to conventional radiography  | g Cleaner           |

## Obstetrical Radiography

SUCH PHYSICAL factors as unnatural fetal position or incompatibility of fetal and pelvic signs can sometimes present serious obstetrical problems. These complications are still widely evaluated by radiographic means even though ultrasonography is rapidly taking over obstetrical studies.

Since ultrasonography is not yet available at every USAF radiological facility, we must still be proficient in fetography and pelvimetry.

### 2-1. Fetography

Fetography, or a fetogram, is done to demonstrate the fetus. In this section, we cover some general radiographic considerations pertaining to fetography and the procedures involved.

You know that all patients should be protected from ionizing radiation as much as possible. However, *obstetrical* patients require special consideration.

**410. Specify precautions taken to protect obstetrical patients from excessive radiation exposure, and state three ways fetal motion can be reduced during exposure.**

**Obstetrical Patient Protection.** Ionizing radiation, such as that produced by your X-ray machine, can cause irreversible alterations in the cellular structure of organic tissue. Gonadal and immature growing tissues are highly susceptible to alteration. These two types are present in obstetrical patients. Since it is not known precisely how much radiation it takes to permanently damage these tissues, you should insure that exposure to your obstetrical patients is kept as low as possible.

**Patient positioning.** Probably the most common cause of excessive exposure to the patient and fetus is repeat examinations made necessary by improper positioning. The position of these patients, particularly for pelvimetry projections, must be "on the money" so to speak. Slight rotation or angulation can make accurate evaluation of the radiographs impossible.

**Fetal motion.** Another common cause of excessive patient exposure is repeat examinations required because the fetus moves during exposure. There are several ways to prevent this. One is to ask the patient to tell you when there is no noticeable fetal movement. Also, you can have the patient breathe deeply several times and ask her to hold her breath before the exposure. Repeated deep breaths hyperaerate the maternal blood and help control the fetal motion.

A short exposure time also should be used to prevent fetal motion on the film. Naturally, the specific exposure time used in your department depends upon several factors, including machine capacity, screen speed, and grid ratio. The point is to use the shortest exposure time possible.

**Exposure factors.** Naturally, high mAs values contribute to excessive patient exposure. However, due to size of the fetal and fluid-filled abdomen, high mAs values are difficult to avoid. High-speed screens and films should be used so mAs values can be kept relatively low. Furthermore, high kVp techniques (over 100 kVp) will reduce the mAs necessary and at the same time reduce the absorbed dose. Finally, you should use proven and reliable exposure techniques to prevent the need for unnecessary repeats.

### Exercises (410):

1. Why is protection of an obstetrical patient from ionizing radiation especially important?
2. Why is obstetrical patient positioning so critical?
3. What is probably the most common cause of excessive exposure to obstetrical patients?
4. Explain three ways fetal motion can be reduced on an obstetrical radiograph.
5. How can exposure factors (other than exposure time) be used to advantage in reducing patient exposure?

**411. Identify fetography in terms of its purposes and precautions to take in its use.**

**General Fetographic Considerations.** Fetography is performed to detect the presence of a fetus, its age, position, or general condition. Multiple pregnancies are also demonstrated on a fetogram.

**Presence of the fetus.** A fetogram may be, on rare occasions, performed to determine whether a patient is pregnant. Radiographic indication of pregnancy is, of course, visualization of the fetal skeleton. Usually, the first visible parts of the skeleton are the ossification centers for the vertebral bodies, which appear in a curved row. These ossification centers are usually visible at 12 to 16 weeks.

The fetal tissue is more susceptible to alteration by ionizing radiation at this early stage than it is later in the pregnancy. Consequently, it is extremely important for you to produce a good radiograph the first time to avoid the added fetal exposure due to a repeat study. Good detail and sufficient contrast are important because the ossification centers may be superimposed over the vertebra.

**Fetal age.** A fetogram is sometimes performed to determine the approximate age of the fetus. Several parts of the skeleton can be evaluated to estimate maturation. Since accurate evaluation of these parts depends upon the detail and contrast on the radiograph films of the highest quality must be used.

The presence of the distal femoral and proximal tibial epiphyses are an indication of the age of the fetus. They usually appear at the 36th week of fetal life. Other skeletal parts and the time of appearance are semicircular canals, 20th week; parietal bones, 20th to 24th week; calcaneus, 20th week; talus, 24th week; cuboid, 40th week; and the femoral head, 40th week in some females. We do not provide you with this information to help you estimate the age of the fetus because your radiologist interprets the radiographs. We mention them to stress the importance of high quality radiographs, since most of the parts are relatively small.

**General condition of the fetus.** A fetogram is also taken to evaluate various conditions of the fetus. These conditions include hydrocephalus (characterized by enlargement of the skull), anencephaly (absence of the skull), and deformed extremities or other parts of the fetal skeleton.

**Death of fetus.** Fetal death can also be diagnosed on a fetogram. Gas in the fetal circulatory system is a sign of fetal death. The gas usually appears as a thin line of radiolucency—which is very difficult to demonstrate unless the fetogram is of the highest quality. Overlapping of the bones of the skull is another indication of fetal death if the patient is not in labor.

#### Exercises (411):

Indicate whether the following statements are true (T) or false (F). If you indicate false, explain your answer.

- 1. Visualization of the fetal vertebrae is normally the first radiographic indication of pregnancy.
- 2. Radiographic visualization of the fetus can occur as early as the 20th week.

- 3. Exposure of the fetus to radiation is equally dangerous whether the fetogram is performed at 14 or 36 weeks into the pregnancy.
- 4. Superimposition of other structures over the fetus is of no concern if a fetogram is performed to detect pregnancy.
- 5. Evaluation of fetal age on a radiograph requires a high-quality film.
- 6. Distal femoral and proximal tibial epiphyses appear on the fetus at the 36th week of pregnancy.
- 7. Small bones located in the foot, skull, and hip of the fetus can indicate the age of the fetus.
- 8. Demonstration of the bones of the skull is not necessary when fetal death is suspected.
- 9. A fetogram taken to diagnose fetal death must be capable of demonstrating a thin radiolucent line representing gas in the fetal circulatory system.
- 10. Anencephaly of the fetus is seen on the radiograph as an enlarged fetal skull.

#### 412. Specify patient positions to use in performing a fetogram.

**Projections for Fetography.** We cannot tell you specific projections to take, since different radiologists and obstetricians require different projections. We will, however, teach you the procedures for the most commonly used projections.

**AP fetogram.** Perform the AP projection in much the same way that you would perform an AP abdomen. (See fig. 2-1.) Center the film for all fetograms to the iliac crests. If the purpose of the radiograph is to detect a fetus, be sure to include the symphysis pubis since the newly formed fetus may lie low in the pelvis.

**PA fetogram.** The PA projection is usually considered better than the AP in terms of detail because the fetus is closer to the film on the PA. If the PA is taken to detect

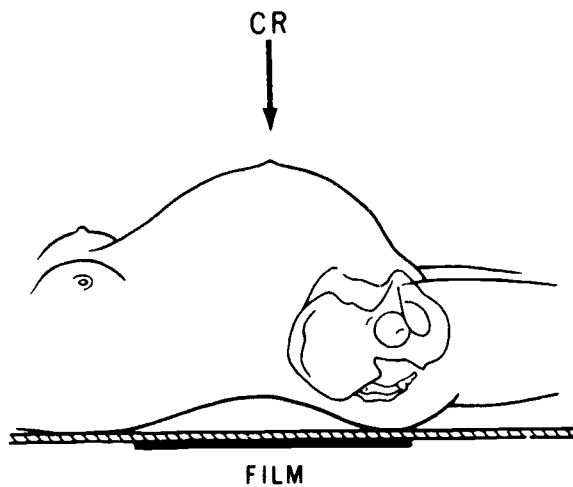


Figure 2-1

pregnancy, include the symphysis pubis for the reason stated above.

There are two ways to position the patient for PA projection. One is to have her support herself on her knees and forearms and lower her abdomen until the anterior portion of her abdomen is slightly depressed by the tabletop (see fig. 2-2). This position causes little discomfort to the patient. Before using the PA projection, demonstrate the position to the patient.

Another way to position the patient for a PA projection is to place some supportive material, such as pillows, foam positioning blocks, or blankets beneath her chest, extreme lower pelvis, and lower extremities (see fig. 2-3). In other words, the only area not supported is the area over the film. The film is centered to the iliac crest. The height of the support material depends upon the forward extension of the patient's abdomen. If the proper amount of material is used, the patient's abdomen is *slightly* depressed by the X-ray table.

**Oblique projections.** Normally, an AP or PA projection is sufficient to evaluate the fetus. When a diagnosis cannot be made from either of these projections because the

skeletal parts in question are superimposed over the spine, an oblique projection may be requested. A posterior oblique is usually made if the initial projection is AP, and an anterior oblique is usually made if the initial projection is PA. In either case, the degree of obliquity is determined from the initial radiograph. Be sure to properly support your patient during the obliques to aid in her comfort and to prevent part motion on the radiograph. The anterior oblique is sometimes called the "position of comfort" because the patient's abdomen shifts to the side and does not support her weight.

#### Exercises (412):

1. Who decides which fetographic projection you will perform?
2. Where is the film centered when you perform a fetogram?
3. If a fetogram is performed to diagnose pregnancy, the \_\_\_\_\_ should be included in the film.
4. On which type of projection is part-film distance greater?
5. How is the patient supported during a PA fetogram?
6. In which projection is the patient's abdomen slightly depressed by the table?

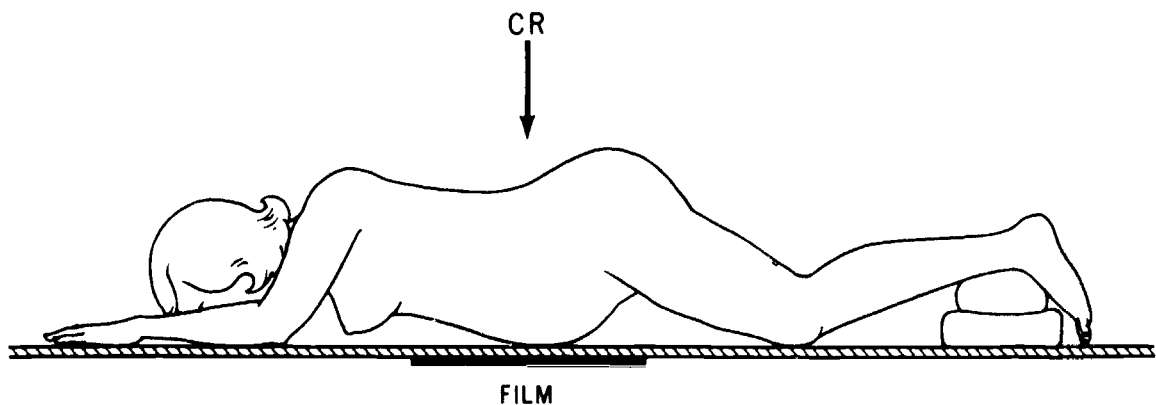


Figure 2-2.



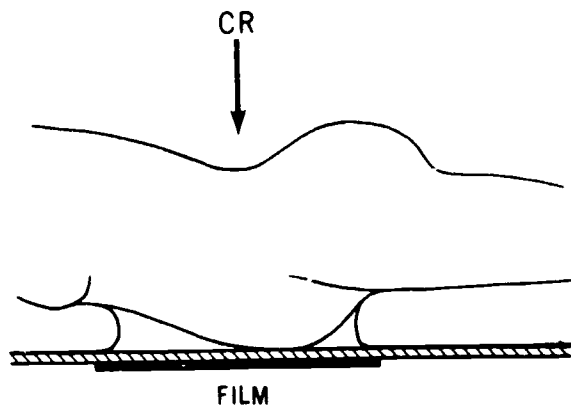


Figure 2-3

7. If an AP fetogram is made initially, a subsequent projection is probably a(an) \_\_\_\_\_ oblique.
8. What determines the degree of obliquity for an oblique fetogram?
9. What is the anterior oblique sometimes called?

## 2-2. Pelvimetry (Colcher-Sussman)

Normal delivery depends upon several factors, one of which is the relationship between the size of the fetal head and the size of the pelvic opening through which the fetus must pass. Several methods are used to measure the pelvic dimensions. However, we will limit our coverage to the most common method used—the Colcher-Sussman method.

**413. Specify how the Colcher-sussman pelvimeter is used to measure the pelvic opening.**

**Colcher-Sussman Measurements.** We believe you cannot produce a good pelvimetry unless you know what is to be demonstrated. This is true whether you take the radiographs yourself or evaluate them as a quality control technician.

The measurements are made at three levels of the pelvic opening—the inlet, the midpelvis, and the outlet. Two intersecting diameters are measured at each level, as shown in figure 2-4. Three anteroposterior diameters are measured on the lateral projection, and three transverse diameters are measured on the AP projection. In figure 2-4, A1 and A2 are the diameters of the inlet; B1 and B2 are the diameters of the midpelvis; and C1 and C2 are the diameters of the outlet.

**Colcher-Sussman Pelvimeter.** Since the size of the pelvis and, consequently, the distance between the pelvic diameters and the film vary from patient to patient, there must be some way to determine the degree of magnification of the diameters on the radiographs. The device used for this purpose is the pelvimeter shown in figure 2-5.

The pelvimeter consists of a base, a vertical cylinder, an arm, and a ruler. The cylinder is marked in 1-cm increments from 5 to 20 cm, and the ruler is 15 cm long and perforated at 1-cm intervals.

**Lateral projection pelvimeter placement.** When the projections are performed, the pelvimeter ruler is included on the radiographs. On each projection, the ruler is placed at a level which corresponds to the level of the diameter to be measured. For example, on the lateral projection the ruler is placed between the gluteal folds, as shown in figure 2-6. The AP diameters which are measured on the lateral projection are also parallel with the film and located at the same level. In other words, the distance between the ruler and film and the distance between the AP diameters and film are the same. Consequently, the centimeter perforations on the ruler are magnified to the same degree as the AP diameters (see fig. 2-7). This built-in compensation allows the radiologist to determine the actual diameters, even though they are magnified on the radiographs.

**AP projection pelvimeter placement.** For the same reason described above, the ruler is placed on the AP projection to coincide with the level of the transverse diameters. Specifically, the level corresponds to the level of the ischial tuberosities, as seen in figure 2-8. In practice, the exact level of the ischial tuberosities is somewhat difficult to palpate. The level can be found more simply by palpating the upper (anterior) margin of the symphysis pubis and setting the perforated ruler 10 cm below that margin, as seen in figure 2-9.

### Exercises (413):

1. Name six diameters measured on a Colcher-Sussman pelvimetry. After each diameter, indicate the level of the pelvic opening measured and the projection from which it is taken.
2. Why is the Colcher-Sussman pelvimeter used?
3. At what specific location is the pelvimeter placed on the lateral projection, and why?
4. At what specific level is the pelvimeter placed on the AP projection, and why?

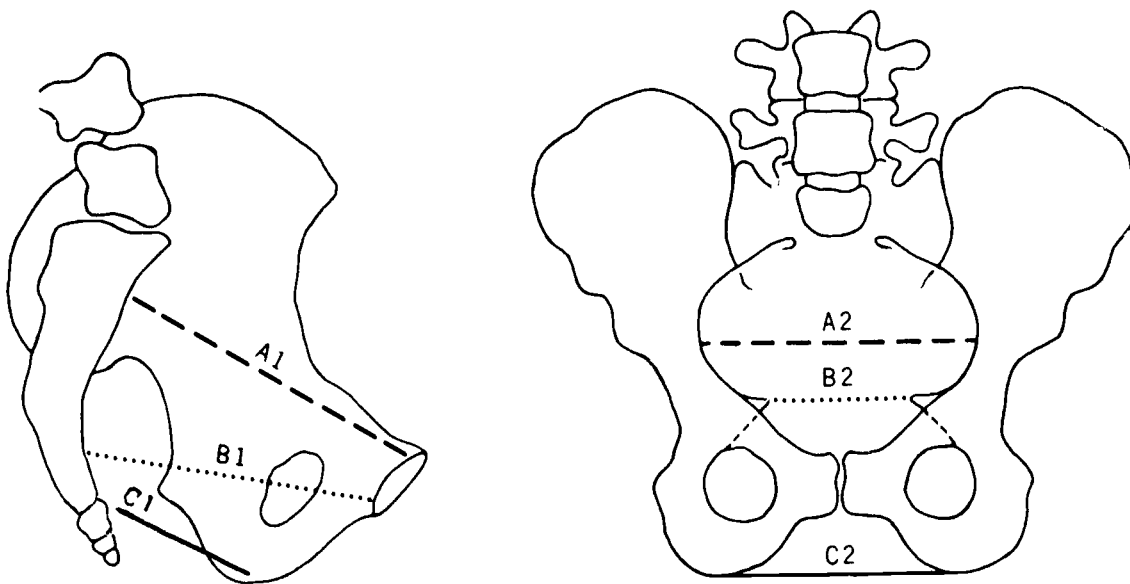


Figure 2-4

5. Describe a simple method for determining the placement of the pelvimeter on the AP projection.

414. Explain how and why given positions affect interpretation of radiographs.

**Importance of Pelvimeter Placement.** To insure accurate evaluation of the maternal pelvis, the pelvimeter must be positioned so the ruler is parallel with the film. If it is not, the distances between the ruler "dots" on the

radiograph are shortened. Notice in figure 2-10 that the distances between the dots on the films are not the same. The dots projected by the ruler in detail B are closer together than those in drawing A, even though the part-film distance is approximately the same. This is due to foreshortening of the ruler. You can see how a nonparallel ruler and film could result in a higher centimeter count for each pelvic diameter and, consequently, the assumption that the diameters are longer than they actually are. The film interpreter might assume the pelvis is large enough for normal delivery when it may not be.

The pelvimeter must also be placed at the specified level of the pelvis to insure accurate evaluation of the pelvic dimensions. In figure 2-11 we have illustrated three rulers radiographed, each with a different part-film distance. Consider detail B in the figure to represent the correct level of the ruler for an AP projection. Also, consider details A and C to represent the same AP projections of the same patient but with the ruler higher and lower than normal. Notice that the distances between dots are not the same. This is obviously due to the difference between the magnification caused by the varied part-film distance. If the ruler is closer to the film than the prescribed distance, the effect on evaluation of the diameters is the same as if the ruler and film are not parallel. If the ruler is farther from the film, the diameters are presumed to be shorter than they actually are; and this could lead to the assumption that the pelvis is inadequate for delivery when, in actuality, it may be adequate.

**Exercises (414):**

1. On a lateral projection, the pelvimeter is not placed parallel with the film. How would this condition affect evaluation of the pelvis, and why?




Figure 2-5.

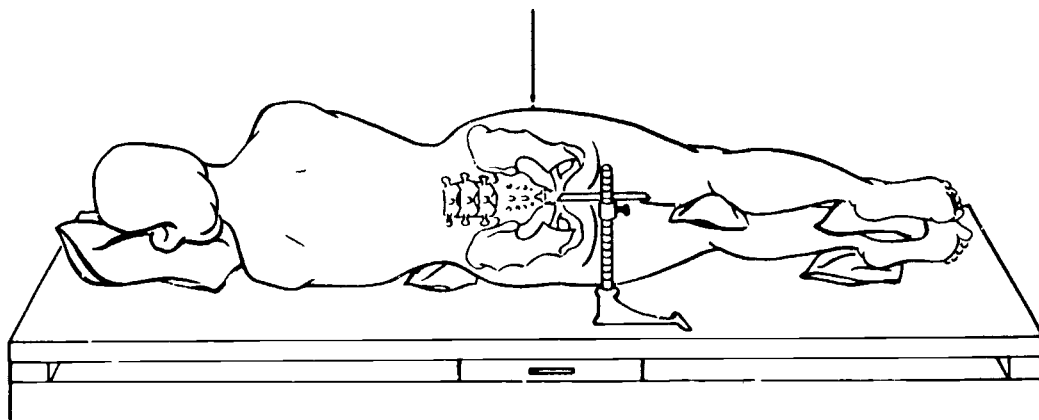


Figure 2-6

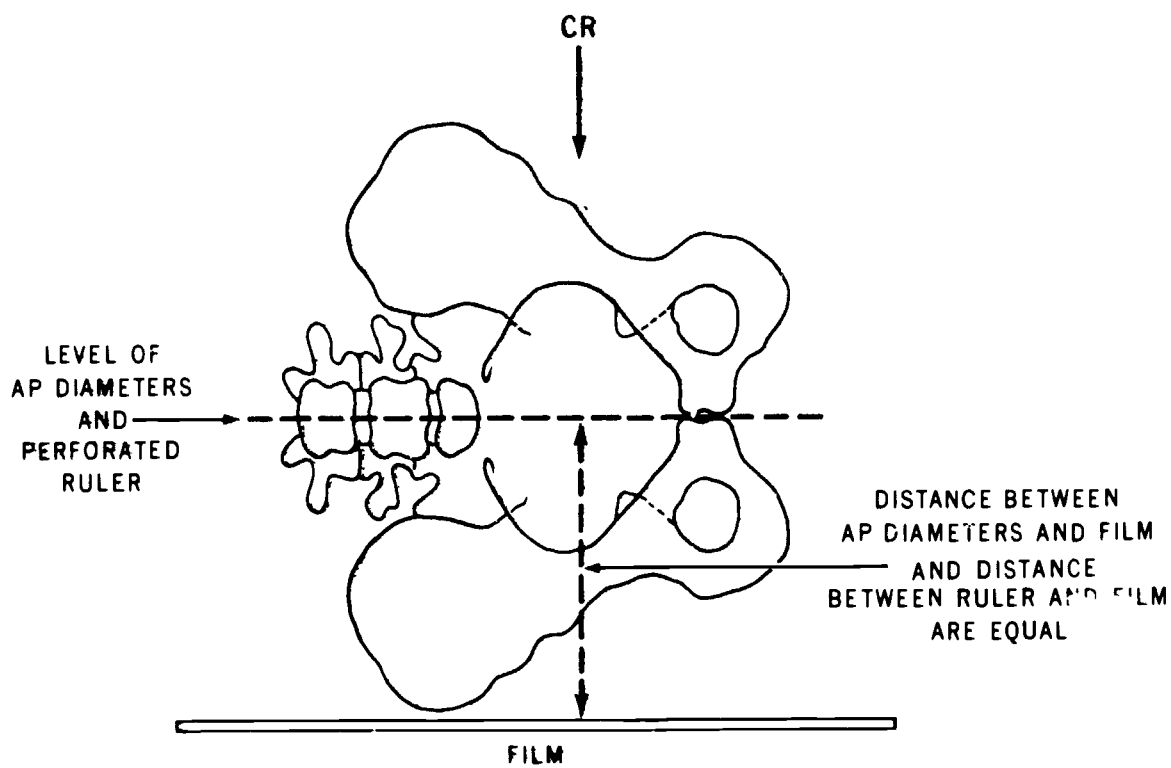


Figure 2-7

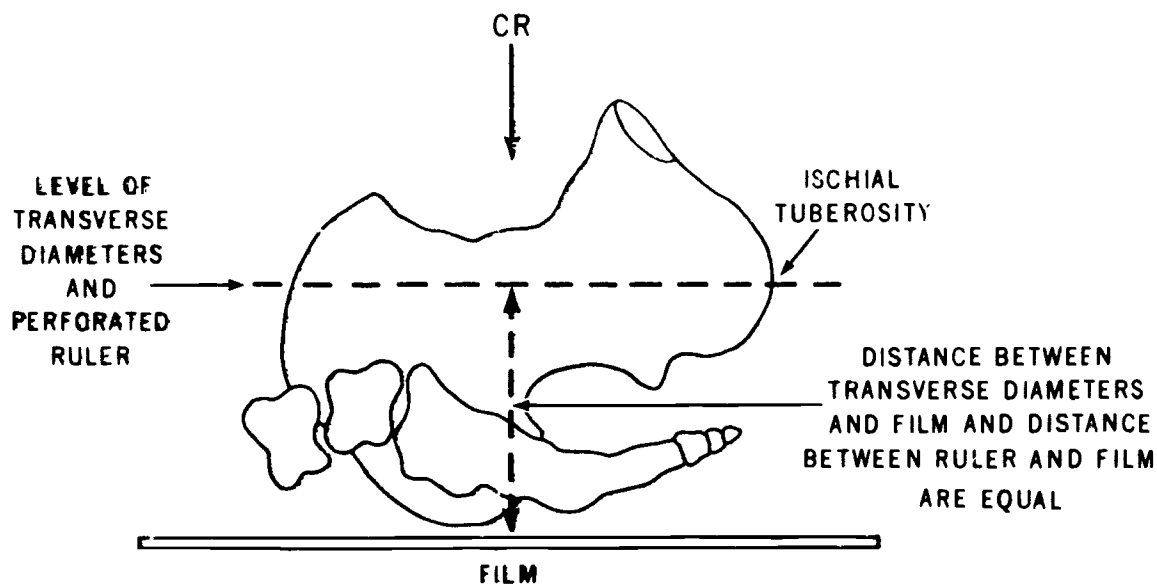


Figure 2-8

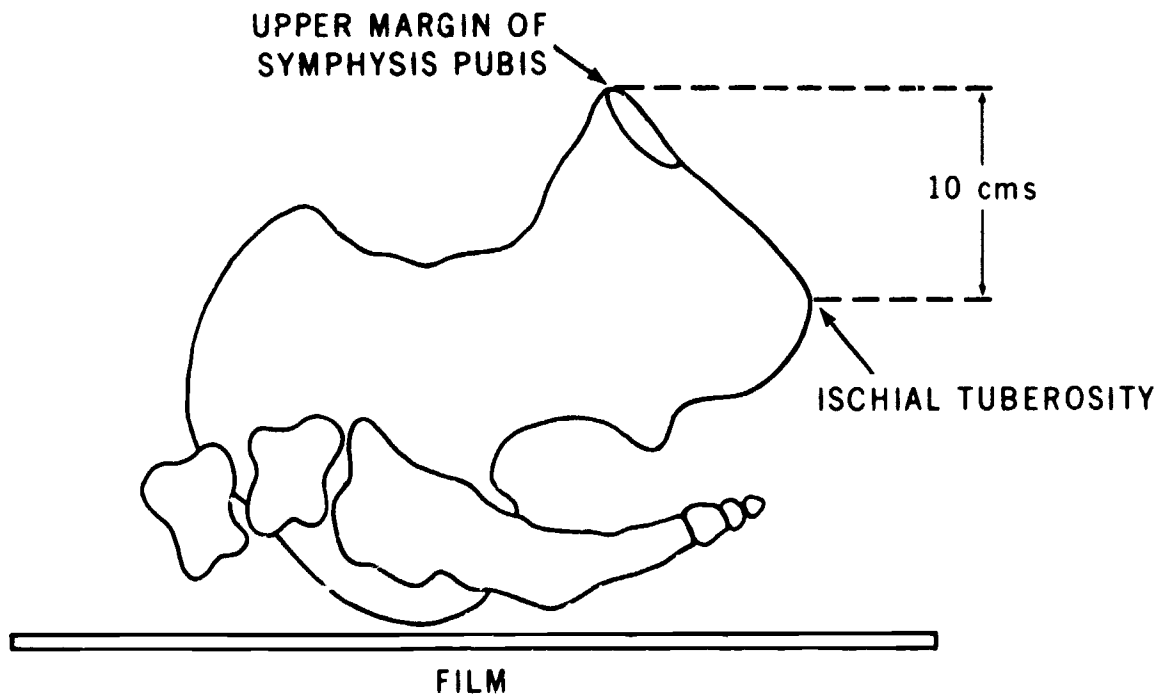


Figure 2-9

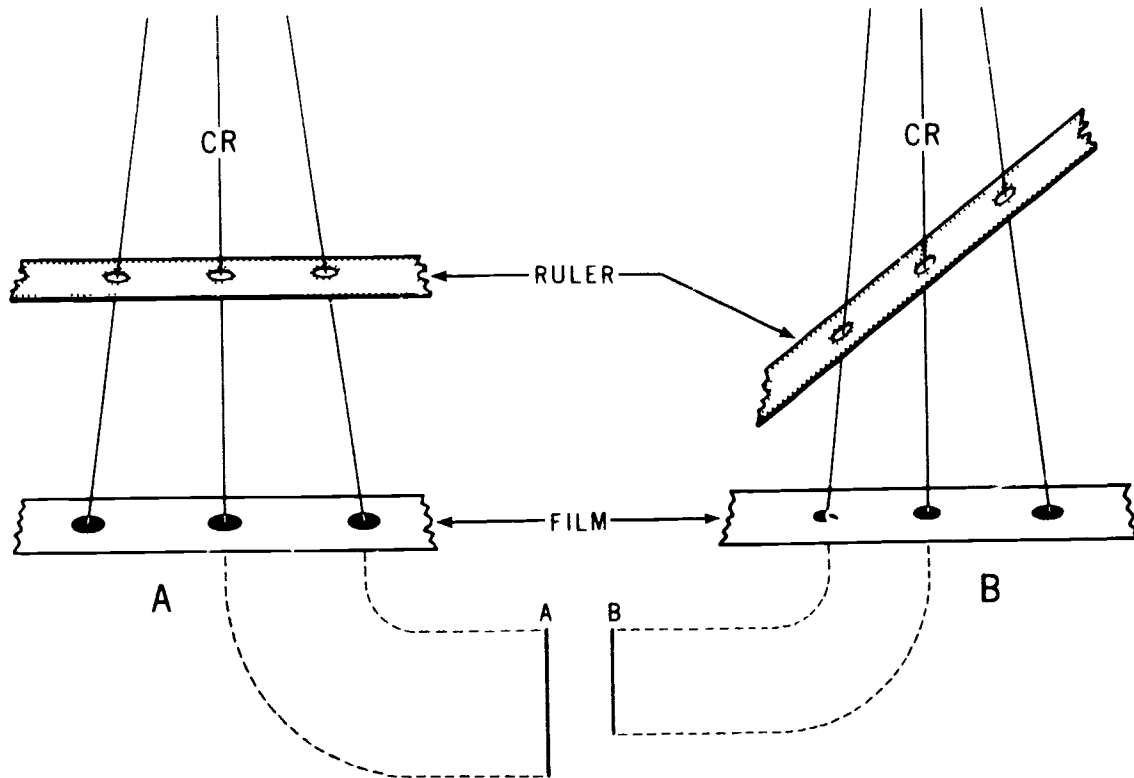


Figure 2-10

2. On a lateral projection, the pelvimeter is placed parallel to the film, above the level between the gluteal folds. How would this condition affect evaluation of the pelvis, and why?
3. On an AP projection, the pelvimeter is placed parallel to the film, 7 cm below the upper margin of the symphysis. How would this condition affect evaluation of the transverse diameters, and why?

**415. Identify common mistakes made in positioning a patient for an AP Colcher-Sussman projection in terms of how each affects evaluation of the radiograph and how to avoid them.**

**Common Problems with the AP Projection.** Although the AP Colcher-Sussman projection is normally easy to perform, there are some mistakes that are commonly made by technicians.

**Rotation of the pelvis.** One common error made in positioning the patient for the AP projection is failing to position her so the median plane is perpendicular to the table. This rotates the pelvis, which, in turn, obscures the ischial spines and prevents accurate measurement of the transverse diameter of the midpelvis. Also, accurate measurement of the other transverse diameters is made difficult. Check for rotation by measuring the height of the anterior superior iliac spines—they should be equidistant from the table. Also check the greater trochanters—they should also be equidistant from the table.

**Missing ruler.** The 14- by 17-inch cassette should be centered  $1\frac{1}{2}$  inches above the symphysis pubis for the AP projection. This centering point allows ample space on the lower margin of the film to include the ruler. Some technicians have a tendency to center the film higher; consequently, the ruler is not included on the radiograph. Of course, if the ruler is not present, the magnification of the transverse diameters cannot be determined and the radiograph is of no use.

**Overexposure.** The radiograph is overexposed occasionally because some technicians measure the abdomen through the thickest portion rather than through the CR. An overexposed radiograph may keep the radiologist from identifying the bony landmarks between the transverse diameters.

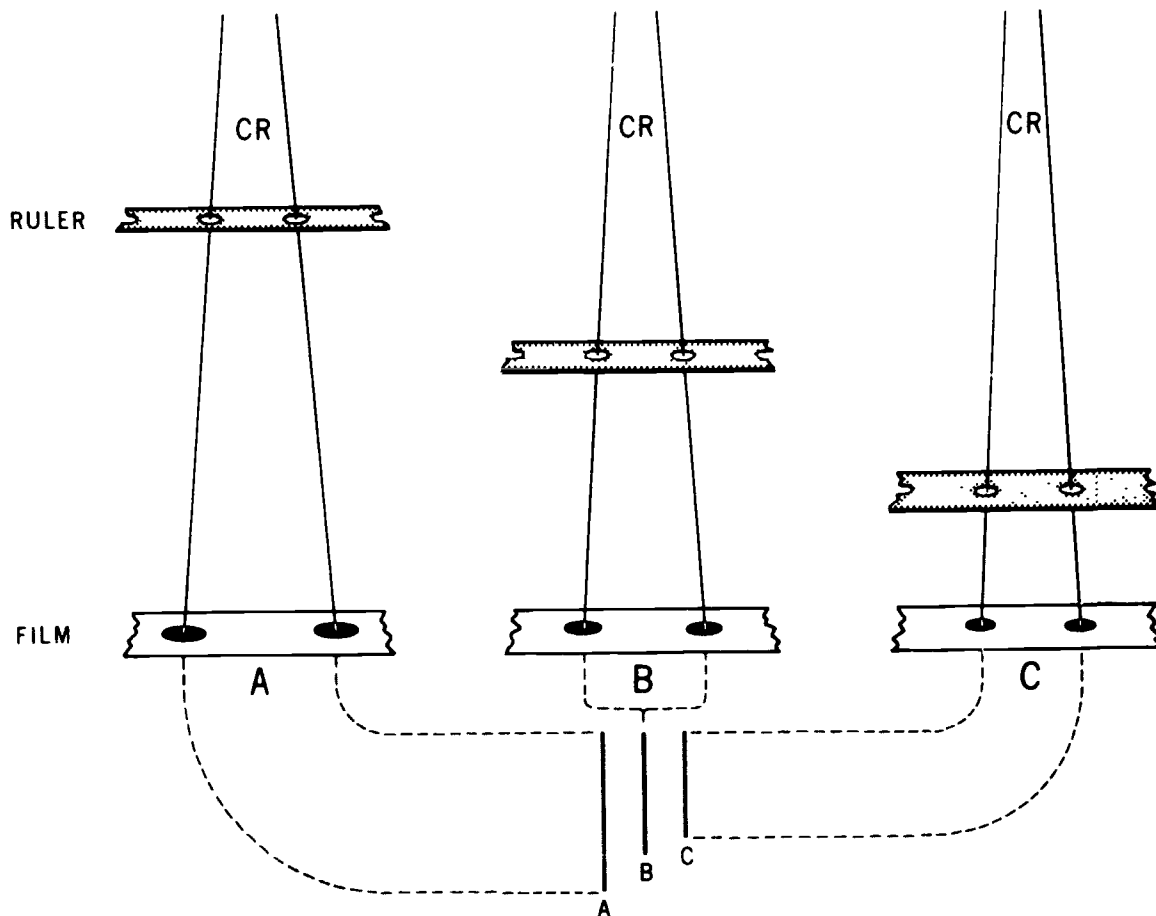


Figure 2-11

**Exercises (415):**

1. List three common mistakes made in positioning a patient for an AP Colcher-Sussman projection. How does each affect the evaluation of the radiograph? How can they be avoided?

**416. Identify common errors made in positioning a patient for a lateral Colcher-Sussman projection in terms of how they affect evaluation of the radiograph and how they can be avoided.**

**Common Problems with the Lateral Projection.** As a general rule, mistakes are more commonly made with the lateral Colcher-Sussman projection than with the PA. Let's look at the errors.

**Anterior rotation of the pelvis.** Perhaps the most common mistake made on the lateral is failure to position the pelvis in the true lateral position. More specifically, the pelvis is usually rotated anteriorly. Obviously, the rotation distorts the diameters and results in erroneous measurements. This problem is not especially common when the lateral projection is taken with the patient erect. When the patient is recumbent, she has a natural tendency to assume the previously described position because of the weight of her abdomen. Consequently, give careful attention to the patient's position for this projection. Elevate the anterior portion of the abdomen slightly with a wedge-shaped sponge, and superimpose her legs exactly. Also, place supportive material between her knees and ankles to help achieve the true lateral position.

**Inadequate visualization of the symphysis pubis.** Another common error made when the patient is positioned for the lateral is to allow flexion of the femurs to the point where they superimpose the symphysis pubis. Notice in figure 2-12 that the radiologist would have difficulty

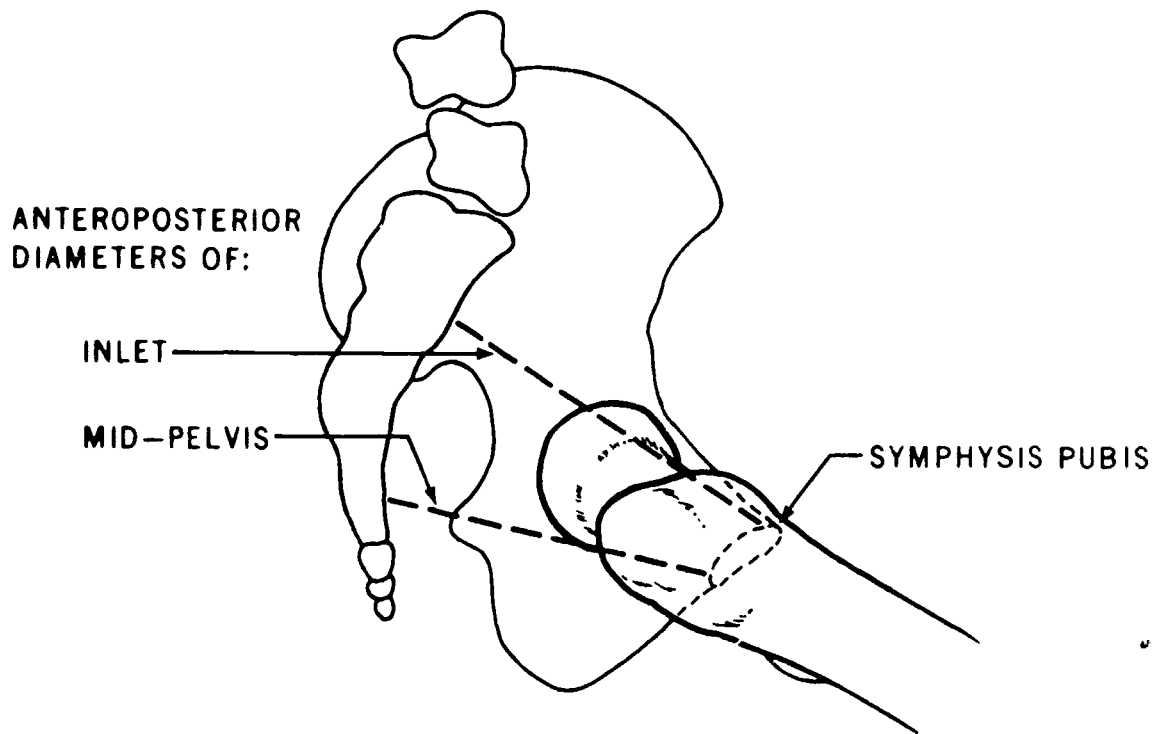


Figure 2-12

determining the anterior ends of the AP diameters of the inlet and midpelvis if the symphysis pubis is not visualized, since those two diameters extend to the posterior border of the symphysis pubis. To avoid this condition, extend the femurs when you perform the lateral projection.

**Exercises (416):**

1. List two errors commonly made in positioning the patient for a lateral Colcher-Sussman projection. How do they affect evaluation of the radiograph? How can they be avoided?

## Ultrasonography

ULTRASOUND IS a rapidly growing diagnostic modality that has become an important part of radiology. Although it has been used in other fields for quite some time, its application to the medical field is still in the early stages of development.

### 3-1. Ultrasound Physics

As a radiology technician, you are very much concerned with positioning the patient. However important patient positioning is, it is no more important than the other factors to consider in producing radiographs. For that reason, you were taught the physics of radiation and radiograph production. The study of ultrasonography also demands a working knowledge of related physics. In this section we explain ultrasound physics that enable you to better understand ultrasonography.

#### 417. State the characteristics of sound.

Your studies up to this point have dealt with radiation and its characteristics. But since ultrasonography uses a sound beam instead of a radiation beam, you need to understand the fundamental characteristics of sound.

**Characteristics of Sound.** All sound, be it audible or ultrasound, is a series of repeating pressure disturbances of molecules or, to put it another way, mechanical vibrations of particles. A particle is a small portion (molecule) of the medium through which sound is traveling. We call these mechanical vibrations sound waves.

Unlike light waves or radio waves, sound needs a medium through which to travel. Sound cannot pass through a vacuum since a vacuum is void of particles. When particles vibrate, their back and forth motion parallels the direction of wave travel. This helps keep sound waves directional and, as we will see later, able to be focused.

A sound wave can be illustrated as a sine wave form, as shown in figure 3-1. Line A shows a single wave or cycle. As we move along the horizontal axis, which represents time, the pressure starts at zero, rises to some peak, then falls back to zero and continues to a negative value before returning to zero. Line B shows a continuous wave form of many cycles. The single wave could be compared to a quick beep of a car horn while the continuous wave represents the horn stuck in the on position.

**Parameters of a sound wave.** We must know more about a wave before we can predict how it will behave. For example, in figure 3-2 we see different parameters of a

sound wave, each telling us something unique about a sound wave.

**Amplitude** is the height of the wave, or peak pressure. This is a measure of the strength or loudness of the sound wave. Naturally, a loud yell would have a higher amplitude than a whispered word. We can use "intensity," "loudness," "strength," and "power" interchangeably to describe amplitude.

**Period** is the time in microseconds that it takes to complete a single cycle (a microsecond is one-one-millionth of a second).

**Velocity**, the propagation (speed) of the wave, depends upon the type of material or medium in which the sound is traveling. For example, sound travels in air at 741 miles per hour or 331 meters per second. Sound travels at 3100 meters per second in stainless steel and at 1540 meters per second in human soft tissue at normal body temperature. You can see that as the material becomes denser, sound travels through it faster.

**Frequency** is the number of times the wave is repeated per second. One cycle per second is known as a hertz (Hz); a million cycles per second is called a megahertz (MHz).

**Wavelength** is the distance a sound wave travels during a single cycle. It is calculated by dividing the velocity by the frequency. Thus, as the frequency increases, the wavelength decreases. The wavelength of ultrasound is expressed in millimeters.

**Comparing Ultrasound to Audible Sound.** Now we can see how ultrasound differs from sound that we can hear. First, and most important, is frequency. Since the normal range of human hearing is approximately 20 to 20,000 Hz, ultrasound must be above that range. Medical ultrasound is in the frequency range of 1 to 20 MHz, which makes the sound beam inaudible to the human ear. Also, because ultrasound is at such a high frequency, the sound waves are more directional.

Our next consideration is velocity. We have noted that the sound we hear travels in air at 331 meters per second. Since we are concerned with human soft tissue in medical ultrasound, we are interested in the speed of 1540 meters per second. This speed is important for machine calibration.

Wavelengths differ also. The wavelengths of audible sound range from 2 to 200 centimeters (cm), which is considerably longer than the wavelength range of ultrasound. For instance, B-mode ultrasound wavelength is 0.3 to 1.5 millimeters (mm).

In addition to frequency, velocity, and wavelength, ultrasound amplitude is different from that of audible



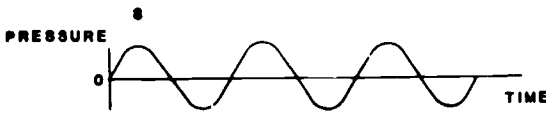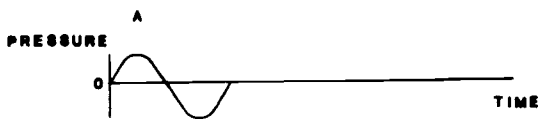


Figure 3-1 Sound waves illustrated in sine wave form. Line A shows a single cycle, line B is a continuous cycle sound wave.

sound. Since amplitude can be considered synonymous with power for our purposes, we can use the decibel (dB) notation to compare the power of two different sound waves. For scanning procedures of ultrasound, the amplitude and, therefore, decibels are less than that needed to shout "Hello."

We have noted briefly how frequency, velocity, wavelength, and amplitude differ between sound that we hear and ultrasound. Later in this chapter we will examine how these factors influence the ultrasound beam and the image.

#### Exercises (417):

1. What is sound?
2. Why can't sound pass through a vacuum?
3. What is amplitude?
4. What determines sound velocity?
5. What is frequency?
6. What is a megahertz?
7. How does frequency differ between ultrasound and audible sound?

8. How does ultrasound velocity in human soft tissue compare to audible sound velocity in air?
9. How do wavelengths differ between ultrasound and audible sound?
10. How does amplitude of ultrasound differ from that of audible sound?

#### 418. Explain the pulse-echo principle and its use in ultrasonography.

**Pulse-Echo Principle.** Ultrasound applications are based on the pulse-echo principle. We can easily explain this principle by comparing it to a person who stands on one side of a canyon and shouts "Hello!" toward the other side. The shout would be the "pulse." That pulse travels through the air at about 331 meters per second until it hits the opposite wall of the canyon. It would then bounce back (reflected) toward the person (the source of the pulse). The pulse becomes an "echo" because it has been reflected. The echo travels at the same speed on its return trip. This, basically, is the pulse-echo principle. Therefore, we can state that ultrasonography works on the principle of transmitting sound through a medium and detecting any echoes that are reflected back.

**Applying the Pulse-Echo Principle to Ultrasonography.** One remarkable use of the pulse-echo principle is the ability to measure distances between the source of the sound pulse and the object that causes the reflection. We can describe this advantage by relating to the person at the canyon. We can judge the distance the sound traveled by multiplying the number of seconds it took for the shout to be echoed back by the speed of sound in air. If the echo is heard in 4 seconds, then the sound traveled 1324 meters (4 seconds times 331 meters per second equals 1324 meters). Because 1324 meters is our total distance that the sound traveled (two trips across the canyon), simply divide by 2 to get the distance of one trip across the canyon.

Measuring distances by sound is not new. Some animals, such as bats, have this ability. This principle has been used

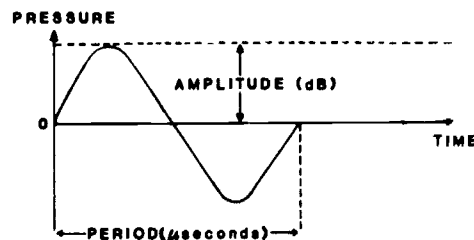


Figure 3-2 Parameters of a sound wave

for years by naval forces with SONAR (sound navigation and ranging) to detect submerged submarines. Only recently has it been used for medical diagnosis.

#### Exercises (418):

1. Briefly explain the pulse-echo principle.
2. When does a sound pulse become an echo?
3. For what purpose is sound used in ultrasonography?

#### 419. Identify terms and components as they relate to ultrasonography.

Comparing our description of the pulse-echo principle to ultrasonography can help clarify some ultrasonography terms. Ultrasound equipment needs something to create a sound pulse, and to "here" the echo; this device is known as a *transducer*. (Later, we will cover transducers in detail.) Just as the man's voice was reflected by an object, a pulse of ultrasound also must be reflected by an object. We would call this *striking an interface*.

An *interface* is a surface that forms the common boundary between two parts of matter or space. An interface occurs whenever two tissues that have different *acoustic impedance* are in contact with each other. Acoustic impedance of a tissue is the product of the density of the tissue and the speed of sound in the tissue. Since the speed of sound in tissue is constant, we can state that the only thing that affects the acoustic impedance is the density of tissue. For our purposes we can assume that acoustic impedance is the same thing as the density of tissue.

#### Exercises (419):

1. What is the purpose of an ultrasonography transducer?
2. Define interface.
3. Explain the importance of an interface as it relates to the pulse-echo principle.
4. What specifically produces an interface?

5. Generally speaking, what is acoustic impedance?

#### 420. Differentiate between three methods of ultrasonic beam attenuation.

**Interaction of Ultrasound and Tissue.** Sound traveling through air, such as the "Hello" of our friend at the canyon, has a pretty uncomplicated life. It only zips across the canyon, hits the far wall, and echoes back. Probably the only noticeable change is in the strength of the echo; it is not nearly as loud as the shout. An ultrasonic pulse traveling through soft tissues also undergoes modifications.

**Attenuation.** The most significant change of the ultrasound beam is attenuation. For our purposes, attenuation is the progressive weakening of the sound beam as it travels through tissue. As with our echo at the canyon, the farther the sound travels through tissue, the weaker it gets. The sound beam is attenuated primarily through three processes: absorption, reflection, and scattering.

**Absorption.** Absorption of the sound beam refers to an all or nothing phenomenon, as in the photoelectric absorption of an X-ray. It occurs when sound energy is captured (or absorbed) by the tissue. Most of this captured sound energy is changed to heat within the tissue.

The absorption process is the basis for ultrasound diathermy, a common therapeutic use of ultrasound. At the lower energy levels used in diagnostic ultrasound, this biological effect of absorption is minimal. Absorption of the sound beam increases as the frequency increases. This results in less penetration of the sound beam.

**Reflection.** Reflection is the redirection of some of the ultrasound beam back toward its source, the transducer. Reflection produces the echoes that form the basis of diagnostic ultrasound scanning, the pulse-echo principle.

Whenever a sound beam passes from a tissue of one acoustic impedance to a tissue of a different acoustic impedance, a small portion will be reflected and the rest of the beam will continue on. The transmitted beam, passing through the interface, leaves that interface at a slightly different angle from that of the incident beam. This deviation, called "refraction," is sometimes confused with reflection. Your principle interest lies in the reflected beam or actually its intensity relative to the incident beam.

The refracted beam continues on to strike another interface and produce another echo. This repeats until its energy is depleted. In soft tissues, refraction is so small that it is of no concern to you. But when you scan across a soft tissue-bone interface, refraction greatly increases.

**Scattering.** As the name suggests, a portion of the beam is "scattered" in all directions. This occurs when the beam encounters an interface which is irregular and smaller than the sound beam. Since the interfaces which produce scattering are small, only a small percentage of the beam is affected. Therefore, you need not be concerned too much with scattering other than to know that it does occur.

### Exercises (420):

1. Match the method of attenuation in column B with the correct statement or phrase in column A by placing the letter of the column B item in the space provided in column A. Each column B item may or may not be used more than once.

Column A	Column B
____ (1) Produces an echo	a. Absorption
____ (2) Affects only a small portion of the beam.	b. Reflection
____ (3) Basis for ultrasound diathermy	c. Scattering
____ (4) Occurs when sound energy is captured by the tissue.	

### 421. Specify the three biological effects of ultrasound and state dose-response relationships of them.

**Biological Effects of Ultrasound.** Unlike radiography, which uses ionizing radiation, ultrasound uses nonionizing energy to demonstrate and record data. For this reason, ultrasound is considered to be a "safe" diagnostic tool. However, this consideration must be taken with caution because little is known about the biological action of ultrasound.

In Volume 1 of the CDC, we covered the law of conservation of energy by stating: "... matter and energy can neither be created nor destroyed but can be changed from one form to another." Since ultrasound delivers energy to tissues, there must be some sort of biological action.

The manner in which a biological effect is produced is called *the mechanism of action*. For ionizing radiation the mechanism of action is ionization and excitation. With ultrasound, the mechanism of action is in three forms: thermal effects (temperature elevation), cavitation, and various viscous stresses.

**Thermal effects.** Ultrasound can raise the temperature of tissue through the molecular agitation and relaxation produced by sound waves. An excessive power level may raise tissue temperature and damage the molecular structure and membranes.

**Cavitation.** Cavitation is the formation of tiny gas bubbles or cavities in tissues as a result of violent relaxation forces upon the molecules.

**Viscous stresses.** The viscosity of tissue on each side of an interface will probably not be equal. As ultrasound interacts along the interface, a "viscous stress" is exerted on the boundary. Within cellular layers near the boundary, small-scale fluid motions called *microstreaming* are produced. These stresses can disrupt membranes and cells near the interface.

**Dose-Response Relationships.** The power output or intensity of the ultrasound beam is measured in watts per square centimeter ( $W/cm^2$ ) when biological effects are considered. The power level of diagnostic ultrasound scanners falls in the range of 1 to 20 milliwatts per square centimeter ( $mW/cm^2$ ; a milliwatt is one-thousandth of a watt). The absolute minimum dose level reported for observable effects in experimental tissues is  $100 mW/cm^2$

and then only after many hours of continuous ultrasound exposure. Of course, if the intensity is increased, the exposure time factor is decreased. Fortunately, our diagnostic power levels are far below any damaging level of dosage.

In summary, we can state that *diagnostic ultrasound causes no known biological effects, somatic or genetic, at the low power levels presently used*. At power levels far above the levels needed for diagnostic studies, some of the effects described earlier can be produced.

### Exercises (421):

1. Match the biological effect from column B with the correct statement or phrase in column A by placing the letter of the column B item in the space provided in column A. Each column B item may or may not be used more than once.

Column A	Column B
____ (1) Causes an increase in tissue temperature.	a. Thermal effects
____ (2) Results in microstreaming.	b. Cavitation.
____ (3) Usually results along a interface.	c. Viscous stresses
____ (4) Formation of tiny gas bubbles.	

2. What measurement is used to indicate a beam's intensity?
3. What minimum dose level is needed to observe damaging effects of ultrasonography?
4. Is diagnostic ultrasound considered safe? Why?

### 3-2. Transducer Characteristics

Every ultrasound unit has certain components that are unique to ultrasonography functions. Perhaps the most important component is the transducer. In this section, we explain various characteristics of transducers.

### 422. State the purpose of an ultrasound transducer and how it operates.

**Ultrasound Transducer.** We have said that ultrasound equipment needs something to create a sound and "hear" the echo. The device that does this is a transducer. Specifically, an ultrasound transducer converts electrical energy into sound energy and sound energy into electrical energy. Its operation is based on the piezoelectric effect, which is graphically demonstrated in figure 3-3. Notice that when a suitable crystalline material is electrically

stimulated, expands. When the polarity of the electrical signal is reversed, the crystal contracts. Ultrasound equipment operates at a high electrical frequency which causes the crystal to oscillate at a high frequency. It is this very rapid motion of the crystal that produces the ultrasound wave. More precisely, an ultrasound transducer converts electrical signals into mechanical motion and the mechanical motion into sound waves.

The reverse is also possible. Indeed, in order to have pulse-echo ultrasound, we must have a means to "hear" our echo sounds. The transducer, with its crystal and because of the piezoelectric effect, serves this purpose also. When a returning echo reaches the crystal, its energy causes a slight compression and expansion of the crystal. This oscillation produces a weak electrical signal that becomes visual on an image display.

**Transducer Components.** An ultrasound transducer (fig. 3-4) is made up of several components. The case

provides structural support for the internal filling and allows the ultrasonographer to manipulate the transducer without damaging it. An electrical cable enters the case through a connector on top. Two electrode leads conduct the electrical charge to the piezoelectric crystal.

The crystals are made of ceramic materials. Since the crystal vibrates when activated by an electrical stimulus or sound pressure, it must not be allowed to reverberate or ring too long. Since the transducer must also receive the returning echo sound, the crystal must stop its motion. A backing material in the case damps the movement of the crystal when the electrical stimulus is removed. In pulse-echo ultrasound, transducers emit sound pulses only about 1 percent of the time; 99 percent of the time the transducer waits for returning echoes.

The size of the crystal is also a prime factor in the operation of a transducer. The thickness of the crystal affects the efficiency of the transmission and reception of

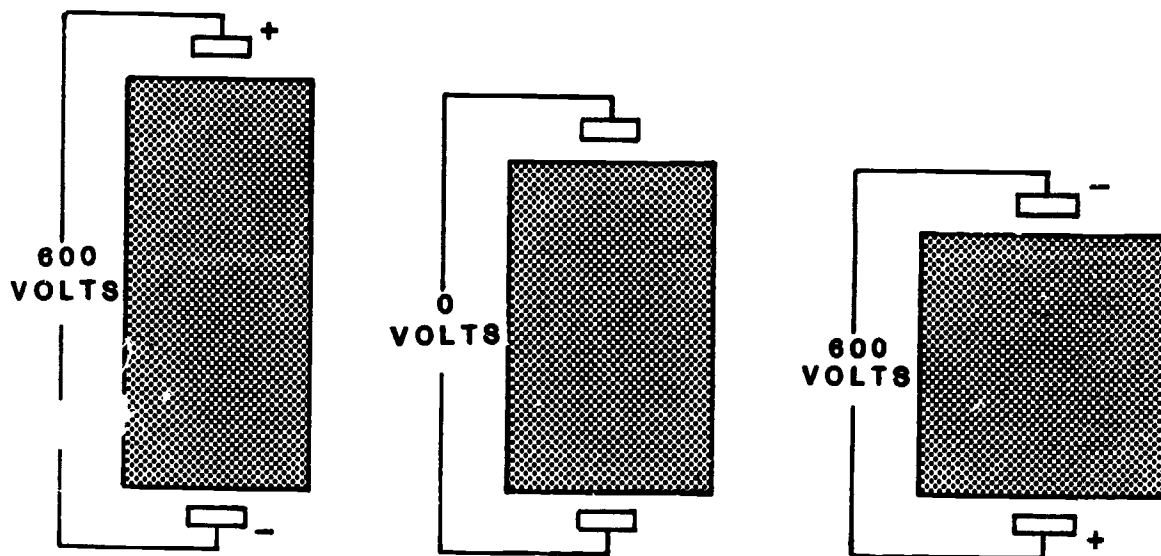


Figure 3-3 Illustration showing how electricity distorts the size and shape of a crystal (piezoelectric effect)

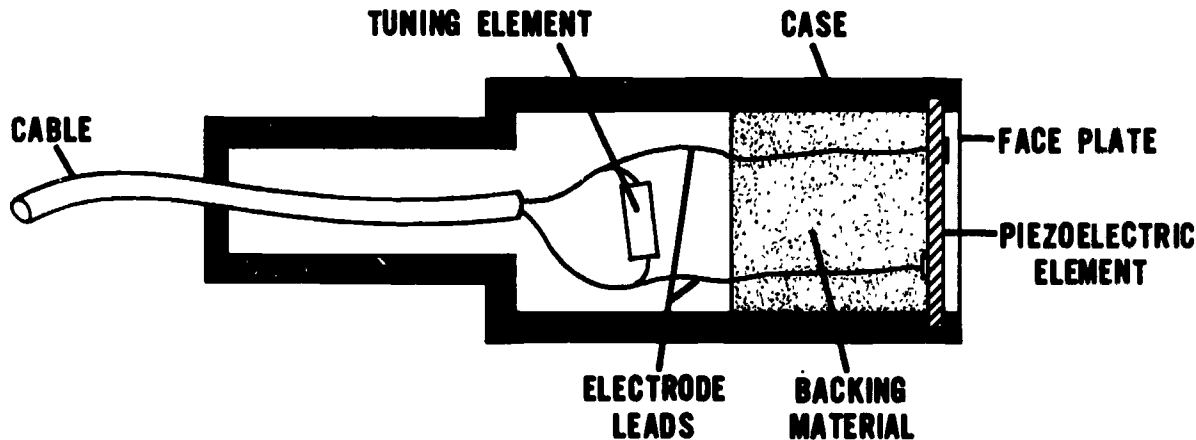


Figure 3-4. Components of a piezoelectric transducer

ultrasound. Manufacturers slice the crystal so that its thickness will be a half wavelength. For example, for a 2.5 MHz transducer, crystal thickness is 0.31 mm. The diameter of the crystal controls the width of the beam, which is very important to resolution and focusing.

The face plate of the crystal provides a protective acoustic window for transmitting the ultrasound to the patient. The face plate, along with the crystal, can be shaped to focus the beam.

**Exercises (422):**

1. What is the purpose of a transducer?
2. On what principle is a transducer's operation based?
3. Explain the piezoelectric effect.
4. What takes place in the transducer when it receives an echo?
5. What is the purpose of the backing material in a transducer?
6. What percent of time operation is a transducer emitting sound?
7. What prevents damage to a transducer when it is handled by a technician?

8. Generally speaking, what determines how thick the crystal should be?
9. What parts of a transducer can be shaped to focus the beam?

**423. Explain characteristics and methods of beam focusing.**

**Beam Focusing.** The primary importance of beam focusing is that resolution (the ability to identify closely spaced interfaces) is greatly improved with a focused beam as compared to an unfocused beam. Ultrasound beams have two zones: a Fresnel zone and a Fraunhofer zone. Notice in figure 3-5 that the Fresnel zone is the near field of focused beam, while the Fraunhofer zone is the far field of unfocused beam. The focused beam has a constant width; whereas, the unfocused beam diverges. The best image resolution is obtained in the near field. On the other hand, the beam's intensity is more uniform within the far field. The divergence of the beam causes a loss of resolution and increases attenuation.

Most transducers are internally focused. This means that the crystal itself focuses the beam. Figure 3-6 shows how a beam's shape changes because of the concave shape of the crystal. External focusing (shown in fig. 3-7) uses acoustic lenses to change the shape of the beam. These lenses are usually built into the transducer in the path of the beam.

Radiology departments that have only one ultrasound unit should have more than one focused transducer. For example, suppose you are trying to visualize an object that is 9 cm into the abdomen. One type of focused transducer may enable good visualization only within 5 cm, while another may give optimum resolution as deep as 10 cm. You can readily see which one you should use.

**Exercises (423):**

1. What is the primary importance of beam focusing?

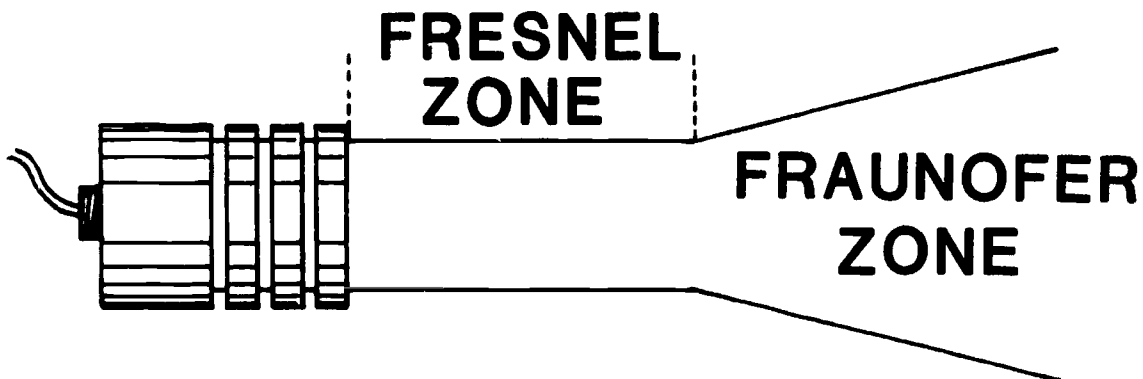


Figure 3-5. The two zones of an ultrasound beam

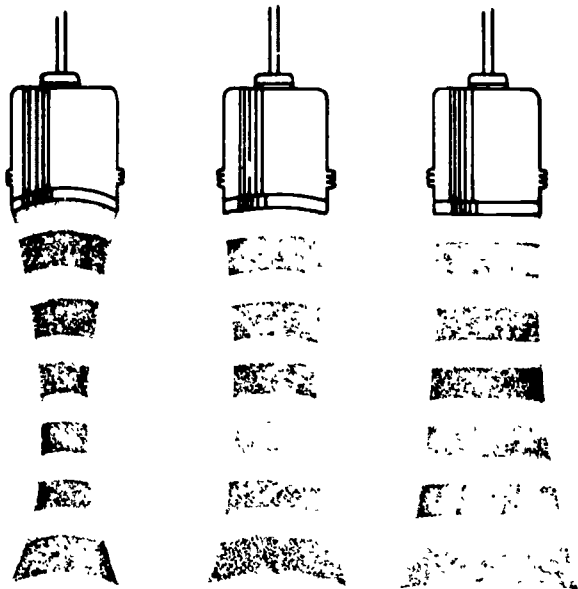


Figure 3-6 Illustration showing how a sound beam is focused by the shape of the crystal (internal focusing).




Figure 3-7 Illustration showing how a sound beam is focused by acoustic lenses (external focusing).

2. What are the two zones of a beam?
3. Which field of the beam has the best image resolution?

4. How are transducers focused internally?
5. What are used to externally focus the beam?
6. Why should departments have more than one focused transducer?

**424. Explain the two types of resolution and state individual characteristics of each type.**

**Ultrasound Resolution.** Many factors affect the quality of the ultrasound image; one of the most important factors is resolution. Resolution is the ability to separate two closely spaced tissue interfaces. Ultrasound imaging involves two types of resolution: axial and lateral.

**Axial resolution.** Axial resolution is the ability of the ultrasound system to identify closely spaced interfaces that lie on the axis or along the path of the ultrasound beam. Several factors can affect axial resolution; but for our purposes, the most important is the length of the ultrasound pulse.

What we have been calling the ultrasound "beam" is actually a series of pulses. Each pulse has a small, but definite, length. If two interfaces are separated by more than one-half the pulse length, the image is easily resolved. This means that as the ultrasound pulse is partially reflected by the first interface and then continues through the tissue to the next interface, the first echo is already on its journey before the second echo originates. Thus, two separate distinct echoes result; and axial resolution is displayed (see fig. 3-8).

On the other hand, if two interfaces are separated by less than one-half pulse length, the second echo will originate before the first echo has completely left the first interface. These two echoes overlap and the transducer picks up only one echo. This results in poor axial resolution (again, see fig. 3-8).

Since axial resolution depends on the length of the ultrasound pulse, you can improve axial resolution by controlling the pulse length. Earlier we said that as the ultrasound frequency increases, the wavelength decreases and, therefore, the length of the pulse decreases. Consequently, you can reason that better axial resolution is obtained at higher frequencies. Unfortunately, as the frequency increases, its penetrability decreases because the beam's interaction and absorption with tissues increases. A general rule to use, then, is: "For optimum axial resolution you should use the highest frequency which will still provide the necessary tissue penetration."

**Lateral resolution.** Lateral resolution (azimuthal resolution) is the ability to identify two closely spaced interfaces that are perpendicular to the long axis of the sound beam. Lateral resolution can also be thought of as

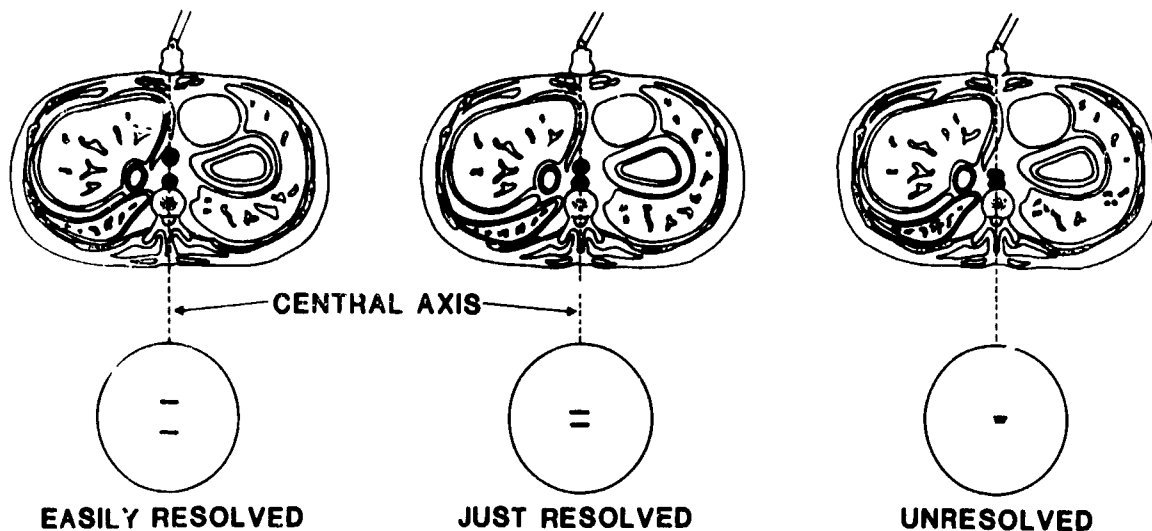


Figure 3-8 Axial resolution

side-to-side resolution. It is dependent on the diameter or width of the beam.

Let's assume you are scanning with a transducer that emits a beam 3 centimeters wide. As the beam encounters an interface, it gives rise to an echo. As the transducer moves laterally the beam strikes another interface and gives rise to a second echo. These two echoes will be separate and distinct if the interfaces are at least 3 centimeters apart. If this is the case, then good lateral resolution is visualized (see fig. 3-9).

If these two interfaces are less than 3 centimeters apart the two echoes will originate from the interfaces at the same time and arrive at the transducer simultaneously. This would be recorded as a single echo and result in poor lateral resolution (again, see fig. 3-9).

Fortunately, we have the means to improve lateral resolution. Our primary consideration is beam width; the smaller the beam width, the better the lateral resolution. And since the beam emits from a transducer, by using a smaller diameter transducer, you can improve lateral resolution. Today's improved transducers emit a beam width of 1 to 2 centimeters.

#### Exercises (424):

1. What is axial resolution?
2. What is the primary factor that affects axial resolution?
3. What is meant when an image is said to be easily resolved?
4. What can you assume about two interfaces that lie on the axis of the beam and appear as one echo?
5. Why does axial resolution improve at a high frequency?
6. What is lateral resolution?
7. What is lateral resolution dependent on?
8. What results if a beam laterally scans two interfaces that are separated by a distance that is less than the width of the beam?
9. What is the relationship between the width of the beam and lateral resolution?

#### 3-3. Image Display, Image Recording, and Operational Modes

After an echo is received by the transducer, it is processed and sent to the display system to be converted to a visual form and permanently recorded. This section deals with viewing and recording the image. And, because of

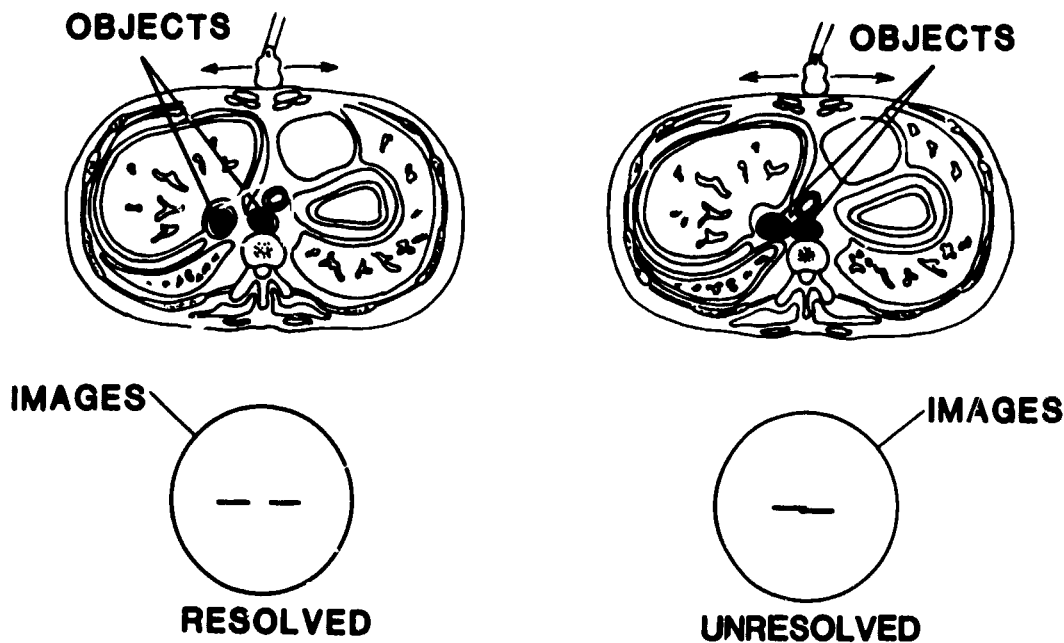


Figure 3-9 Lateral resolution

their visual differences, we also include various operational modes.

**425. Explain operation principles of two image display systems.**

**Image Display.** What good is an echo that is received by the transducer if we can't "see" it? This is why image display is so important. The ultrasonographer must be able to see the echoes and the physician needs to see the scan to make an accurate diagnosis. There are two basic types of image display systems: oscilloscope and television (TV).

**The oscilloscope display system.** Commonly used with A-mode and B-mode, this method employs a storage oscilloscope. An oscilloscope is a cathode ray tube that has an electronic gun which shoots a tiny electron beam at a phosphor target. The electrons striking the target cause the phosphor to glow. The greater the amplitude of our signal (echo) the greater the intensity of the electron beam. The brightness of the dot is proportional to the intensity of the electron beam. Therefore, a strong echo will generate a brighter dot.

Unfortunately, not all returning echoes are as strong as we would like them to be. Remember that the beam is being attenuated as it passes through tissues. Echoes become progressively weaker as distances between the transducer and interfaces increase. The intensity of an echo signal is called *gain*. To visualize low gain signals (that is, those echoes from greater depths), a gain control is usually adjusted. Some controls, such as the time compensated gain (TCG), compensate low gain by amplification. Amplification of weak echoes allows those signals to be changed into an electron beam, along with other echoes of higher gain. Gain controls are common to most type of image display systems.

In the display system, the scan can be recorded on film while the scan is being performed. On a regular oscilloscope the dots for a given echo appear only when the echo is being received. So only after the film is developed can someone see the complete scan. Since this is not practical, the oscilloscope used in the display system has been modified to store dots. This type of oscilloscope is called a *storage oscilloscope*.

A storage oscilloscope holds the image on the screen. This enables an ultrasonographer to view an entire image and decide whether to record it. A disadvantage of this method is that it cannot show differences in the amplitude of the signal.

**Television display.** A TV monitor is used to store and display play dots as well as differences in amplitude. The image is stored in a manner similar to a storage oscilloscope; but a fliscan converter, in conjunction with other electronic devices, is used to assign a shade of gray to each echo. This type of display gives us the gray scale image.

**Exercises (425):**

1. What are two methods of displaying ultrasound images?
2. What effect does echo amplitude have on the electron beam intensity of an oscilloscope?



3. What is "gain"?
4. How does distance affect gain?
5. How is low gain compensated?
6. What major advantage exists with a storage oscilloscope display system?
7. What is the purpose of a scan converter?
8. What type of display system uses a scan converter?

#### 426. Identify characteristics of image recording systems.

**Image Recording.** After an image is displayed, you must decide whether to record it—to produce a "hard copy" of the image. The two most commonly used recording systems are the instant photograph camera and the multi-imaging system.

**The instant photograph camera system.** With this system a camera and film are attached to the unit. The camera views the image as you see it on the screen. Some advantages of this system are its easy-to-use format, initial low cost, virtually service-free, and—most importantly—ready access to images. Disadvantages include the relatively high cost of the film compared to the cost of materials used in other systems and the difficulty of displaying scans for group viewing. Because instant photograph copies are individual, some departments tape the prints in sequence or use special mounting forms.

**Multi-imaging system.** This method uses a special camera and device which projects four, six, or nine images onto an 8 x 10 inch X-ray film. Although the initial costs are higher than for the instant photograph system, the cost of film is a distinct savings because less film is needed for each examination. Another advantage of this system is that its exposure latitude is wider than the other's; so exposure control is not as critical. Also, these films are easier to use for group viewing and can be readily copied like any other X-ray film.

Unfortunately, the multi-imaging systems also has disadvantages besides its initial high cost. Because it uses X-ray film, proper handling and storage of film is necessary. You must have access to a developer, and the developing process is more time consuming. Furthermore, since this system is more complicated, there are usually more servicing problems.

#### Exercises (426):

- 1 Match the image recording system from column B with the characteristic that it applies to in column A by placing the letter of the column B item in the space provided in column A.

Column A	Column B
— (1) Initial low cost	a Instant photograph camera system
— (2) Initial high cost	b Multi-imaging system
— (3) Less film costs/usage	
— (4) Uses X-ray film	
— (5) Virtually service free	
— (6) Increased service problems	
— (7) Better group viewing of films	
— (8) Requires special mounting for films	

#### 427. Differentiate between various operational modes used in ultrasonography.

**Operational Modes.** Operational modes are various ways to visualize echoes. Do not confuse this with image display systems (oscilloscope and TV). An oscilloscope displays an image, but how that image is visualized is determined by which operational mode you select.

**A-Mode.** A-mode (amplitude mode) is the simplest mode. It uses one transducer to send and receive sounds. The echoes then appear on an oscilloscope as "spikes" or vertical deflections (see fig. 3-10). The height of the spike is proportional to the amplitude of the echo. Distances between spikes are proportional to distances between interfaces, as well as the distance from the transducer to the first interface. Therefore, A-mode is used to measure the depth of interfaces and to detect their separation accurately.

**B-Mode.** B-mode (brightness mode) is mainly used in abdominal and pelvic ultrasonography. Chances are, as a sonographer, you will use this mode more than any other. We can describe this mode by comparing its similarities to A-mode (fig. 3-11).

If you could turn the A-mode spike on end and look at it from the top, it would appear as a dot. B-mode dots vary in brightness (that's why this mode is also called the *brightness mode*) according to the amplitude of the echo. This means that as the strength of an echo increases, that particular dot appears brighter.

One reason why B-mode is so popular is that it produces a two-dimensional picture of the area covered by the transducer. Through a procedure called *scanning*, the transducer is moved across the patient. When this happens, all the echoes produced by the various interfaces are displayed and recorded in the position from which they are produced.

The concept of B-mode scanning may be a little difficult to understand when put into words, but it is easier to grasp visually if you look at figure 3-12. Notice the position of the transducer and the projection of the sound beam in the first drawing. As the transducer is shifted across the patient, the dots build up an image of the interfaces within the patient, as shown in the image display part of each drawing. The image represents a crosssectional slice of anatomy.

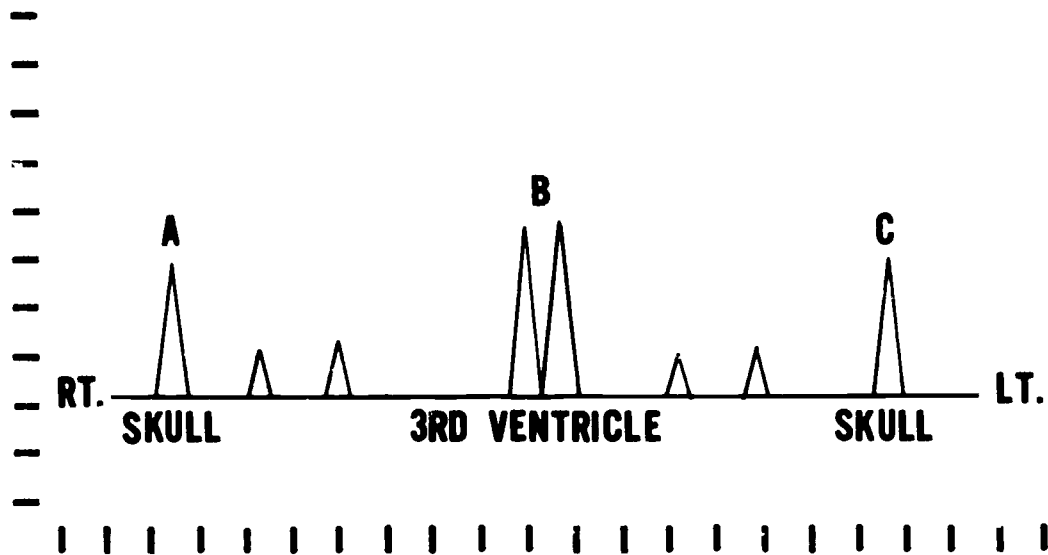


Figure 3-10 Graphic example of a brain scan, using A-Mode

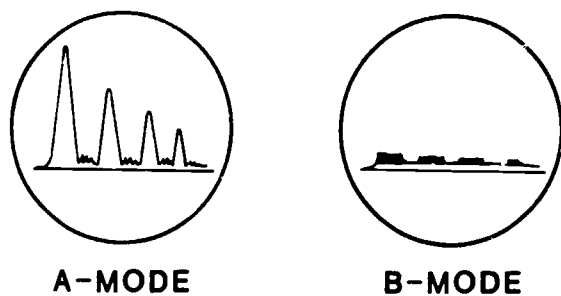


Figure 3-11 Comparison of A-Mode display to B-Mode display

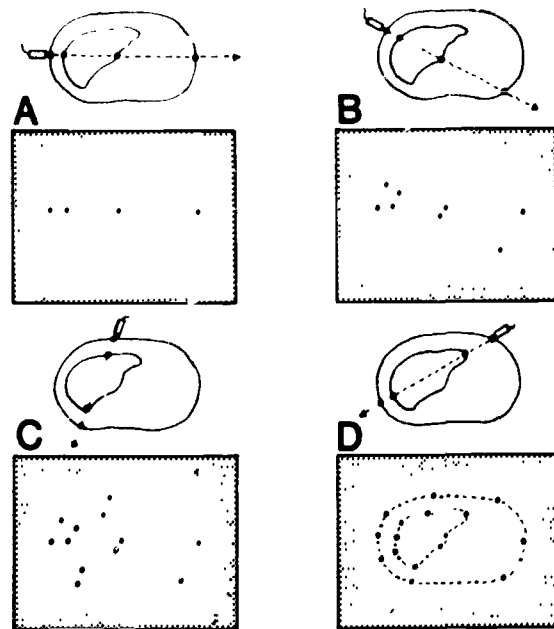


Figure 3-12. Graphic example of B-Mode scanning.

B-mode also has two variations: gray-scale and real-time imaging. Both of these are widely used and have separate characteristics.

**Gray-scale.** Early B-scanners used a visible display mode which, as just described, shows high contrast of bright dots on a screen. Gray-scale display provides a range of intermediate display intensities. This is achieved with the use of a special computer and a scan converter. These devices sense the strength of echoes and assign a shade of gray to each. Therefore, a gray-scale image may have 8 to 10 shades of gray which provides contrast to the image, making it more pleasing to the eye.

**Real-time.** Real-time ultrasound is the other major variation of B-mode and, like gray-scale, is widely used for diagnostic ultrasonography of the abdomen and pelvic areas. Real-time scans compound B-mode as fluoroscopy does to radiography—that is, instead of a stationary picture, real-time produces a motion picture of the structure under study

In real-time scanning, a transducer with multiple crystals is used. Usually, either a linear array transducer or a phased array transducer is used so that more than one sound wave generated, reflected, and displayed. The image can be frozen on the monitor and a hard copy made.

**M-mode.** The M-mode, or time-motion, is used to study moving parts or organs, particularly the heart. In this mode, the transducer remains stationary; and the movement of the organ creates differences in echo amplitude. A diagnosis is made by comparing the difference in the height of various

peaks (spikes) and the length of time it takes for the peaks to develop.

M-mode is used almost exclusively for echocardiography. There is very little application of it in diagnostic ultrasonography.

**Doppler ultrasound.** Up to this point, operational modes we have covered work on the pulse-echo principle. Doppler ultrasound is called *continuous ultrasound* and works on the principle of the Doppler effect. This effect can be compared to a moving fire truck with its siren on. As the truck approaches, the pitch or frequency of the siren increases; as it leaves, the frequency decreases. In Doppler ultrasound, a Doppler transducer is directed toward an artery to detect reflections from the moving particles in the blood. By electronic processing, the differences in frequency between transmitted and detected sounds produce a frequency in the audible range. The pitch of the audible sound, listened to on a speaker or with headphones, can be used to calculate the velocity (speed) of blood flow. Doppler ultrasound can be used to detect intrauterine life, placenta location, detection of multiple pregnancies, patency of arteries or veins, and etc. The interpretation of Doppler ultrasound is based on the frequency produced by the Doppler effect. For example, narrowing a vessel produces a turbulent flow. The faster the blood flows, the greater the difference between the frequency transmitted and the frequency detected (heard).

#### Exercises (427):

1. How do echoes visually appear when operating on A-mode?
2. With what do distances between A-mode spikes relate to?
3. What is the visual difference between A-mode and B-mode?
4. What procedure moves the transducer across the body during B-mode?
5. Which operational mode produces a two-dimensional image?
6. What are two variations of B-mode?

7. Which variation of B-mode produces a motion picture study?
8. What type of scanning mode uses a transducer with multiple crystals?
9. Which operational mode is used for echocardiography?
10. Which operational mode works on continuous ultrasound instead of pulse-echo?

### 3-4. Ultrasound Procedures

There are many things to consider when you are performing ultrasonography. Obviously, a thorough understanding of related physics is important; and we previously covered those main points. But when most technicians think about "performing an exam," the patient becomes involved. In this section we cover some matters that you will encounter when working with patients and performing ultrasonography.

#### 428. Explain anatomical considerations that are pertinent to ultrasound scanning procedures.

**Anatomical Considerations.** At the risk of stating the obvious, it should be said that when you begin to study any part of the body, you must have a clear understanding of the anatomy of the area so that you can readily recognize important landmarks.

**Cross-sectional anatomy.** Human anatomy never changes; you demonstrate the same anatomy with ultrasound that you do with radiation. The main difference is how the anatomy is viewed. Radiographically speaking, you usually view the anatomy anterior to posterior, or laterally. And the structures are superimposed. An ultrasonographic image demonstrates structures from a cross-sectional (transverse or longitudinal) point of view. This way only a "slice" of the body is demonstrated and without superimposed structures.

We can further illustrate ultrasonographic demonstration of anatomy with figures 3-13 and 3-14. Figure 3-13 shows a cross-sectional slice of the abdomen. This represents a transverse (from side to side) scan at a particular level above the iliac crest. It looks as if the torso was sawed in half crosswise, exposing various organs. The interfaces of these structures at this "slice" of the body will reflect echoes to form an image. Figure 3-14 shows a longitudinal

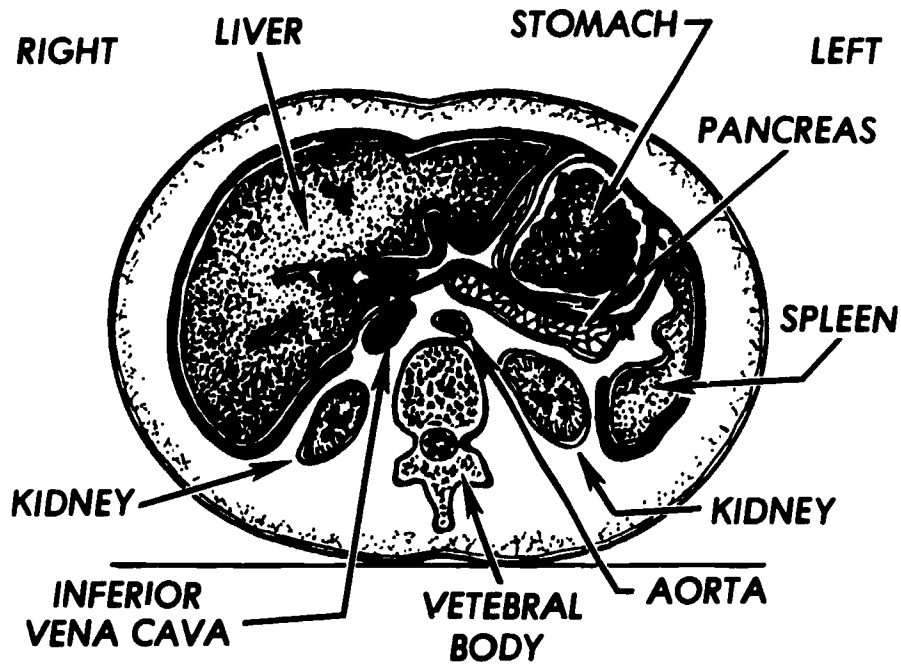


Figure 3-13 Illustration showing cross-sectional anatomy of the abdomen (transverse slice)

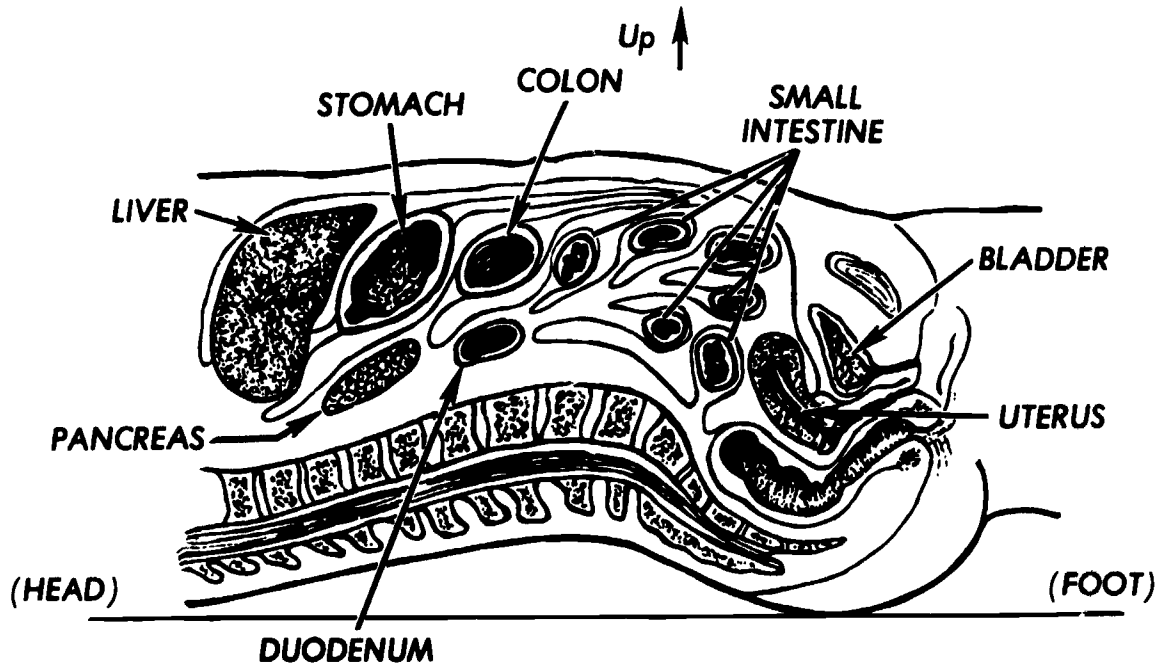


Figure 3-14 Illustration showing cross-sectional anatomy of the abdomen (longitudinal slice)

“slice” of the abdomen. This represents main organs that the sound beam interacts with when scanning from the xiphoid to the symphysis pubis.

Without an understanding of cross-sectional anatomy your scanning efforts could be worthless. This knowledge is vital for two reasons: (1) It serves as a check on technique—that is, it lets you know whether the organs you want to see are visible on the scan; and (2) it allows you to relate your pathologic findings to anatomical structures. The first is important for organ location. For example, if you are examining a gallbladder to verify the presence of gallstones, you must be sure that you are seeing the gallbladder. If not, then your scanning technique is inaccurate. The second reason is important because you must be able to recognize normal anatomy no matter where you scan so that you will recognize abnormal anatomy.

**Anatomical landmarks.** Various anatomical landmarks aid you during your scanning procedures—some are inside the body and are seen on the image, and some are at the surface of the body that you can see and feel.

The first landmarks you note when you begin a scan are at the surface of the body. Those most important are the xiphoid, umbilicus, symphysis pubis, and iliac crest. The first three are on the median sagittal plane, which is the dividing line for the right and left halves of the body. The iliac crest sometimes is used in ultrasonography to locate scanning levels for transverse scans.

Almost all scanning is parallel to either the median plane (midline) or the level of the iliac crests. Longitudinal scanning (also called *sagittal scanning*) is from the diaphragm (or xiphoid) area toward the symphysis pubis and parallel to the median plane. This type of scanning usually begins on the median plane and moves in increments of 1 centimeter to the right or left and is identified by special codes. For example, a scan 1 centimeter to the right of the median plane might be identified as “R+1.” A scan 1 centimeter to the left of the median plane might be identified as “L+1.” Some departments ask that all longitudinal scans be coded with a “L” (for longitudinal) and a plus number for the right side or a minus number for the left side.

Transverse scan coding is similar to longitudinal scan coding. A plus number usually means above (toward the head) a landmark; whereas a minus number refers to the number of centimeters below (toward the feet) a landmark level. Again, various departments may use different landmarks. Some use the level of the umbilicus while some use the iliac crest level or the xiphoid.

Regardless of which landmarks are used, all transverse or longitudinal scans should be viewed consistently and as directed by departmental procedure. For example, transverse scans are viewed as if you are standing at the patient's feet looking towards the head. Since most transverse scans are done with the patient supine, the patient's right side will be to your left and vice versa. Figure 3-15 shows the proper viewing of that type of a transverse scan.

Since most longitudinal scans also are done with the patient supine, they are viewed as if you are looking through the patient's right side. The patient's head is to

your left and the feet are to your right. Figure 3-16 shows the proper viewing of a longitudinal scan of the pelvis.

Although our coverage of cross-sectional anatomy and anatomical landmarks centered on the abdomen, the same general principles pertain to other parts of the body.

#### Exercises (428):

1. In general terms, explain how anatomy appears in transverse and longitudinal scanning.
2. Explain how the knowledge of cross-sectional anatomy can serve as a check on your scanning techniques.
3. What four anatomical landmarks that can be palpated are used as scanning reference points?
4. In general terms, describe longitudinal scanning.
5. Why should all scans be coded?
6. How should a longitudinal scan of an abdomen with the patient supine be viewed?

#### 429. Differentiate between four scanning motions.

**Scanning Motions.** Four transducer movements are used in scanning: linear, sector, compound, and arc. Each involves a different movement of the transducer.

**Linear scanning.** Also called simple scanning, this method involves moving the transducer in a straight line across the skin without angling the sound beam. As shown in figure 3-17, the sound beam strikes an interface only once and at only one angle.

**Sector scanning.** Sector scanning requires an angular movement of the transducer. Notice in figure 3-18 how the transducer pivots so that the sound beam is rotated about the transducer face. The pattern of the sound beam produces an image that resembles a wedge of pie. In sector scanning, as in linear scanning, only one pass of the sound beam is made over the interfaces. Therefore, each interface reflects sound only once and at only one angle.

**Compound scanning.** Compound scanning is a combination of linear and sector scanning. Figure 3-19 should show how those two movements are used on the same scan. After a sector scan motion is made over one part of



Figure 3-15. The proper viewing of a transverse scan

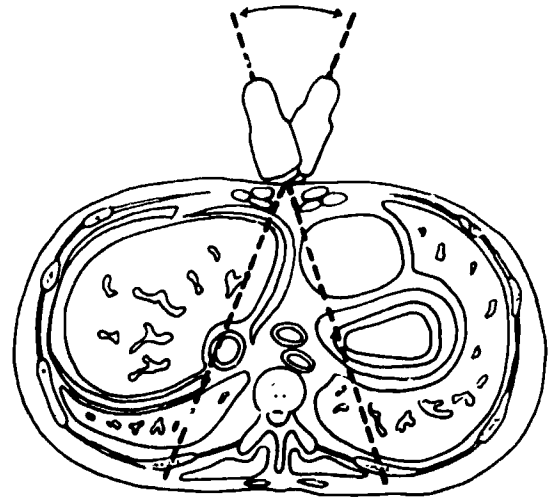


Figure 3-18 Sector scanning



Figure 3-16 The proper viewing of a longitudinal scan

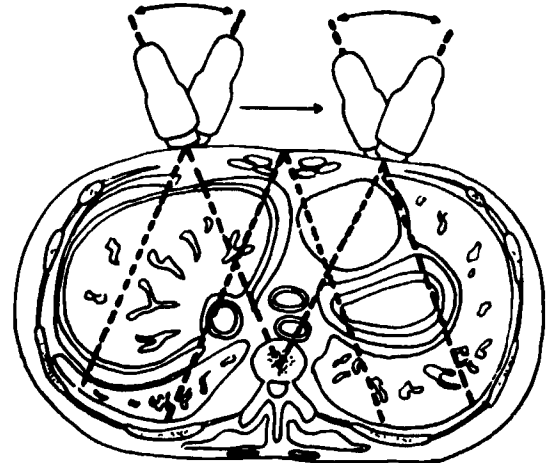


Figure 3-19. compound scanning

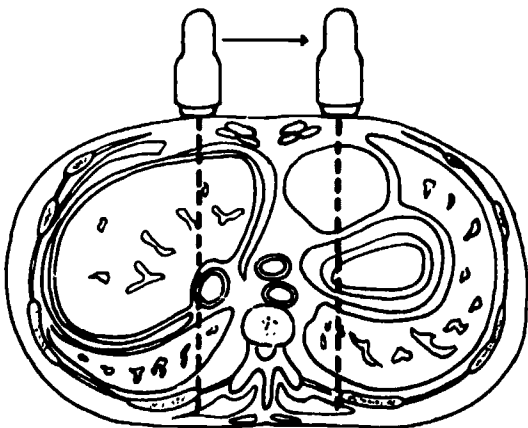


Figure 3-17 Linear scanning

the abdomen, the transducer is moved a few centimeters; and another sector scan is made. A major difference with this method is that the image shows more echo reflections because the sound beam passes over some interfaces more than once and at different angles.

**Arc scanning.** With arc scanning, the transducer is moved over the body with the beam directed (by transducer angulation) to a central point within the patient (see fig. 3-20).

**Exercises (429):**

1. Explain the transducer movement of each of the following scanning motions.
  - a. Linear scanning.

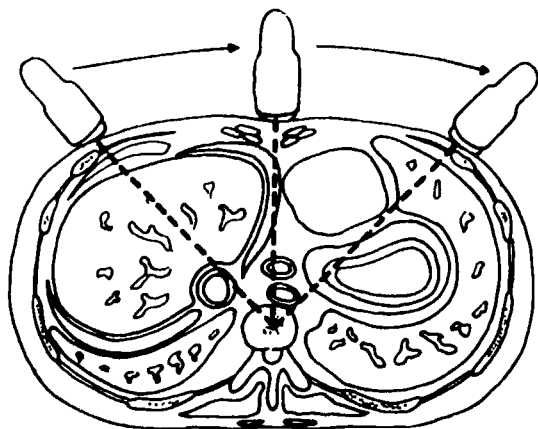


Figure 3-20 Arc scanning

- b. Sector scanning.
- c. Compound scanning.
- d. Arc scanning.

2. Which scanning motion has the sound beam pass over some interfaces more than once?

430. Describe how various pathology affects differential diagnosis.

**Disease Entities.** A disease entity is a distinct parameter of a disease. In ultrasonography, disease entities are important to you because you need some knowledge of various pathology, including their signs and symptoms, and differential diagnosis.

**Ultrasound pathology.** You have learned how an echo originates within the body: sound is reflected by an interface; and, of course, each interface occurs because tissues of different densities are in contact with each other. Because of acoustic impedance, various pathology is seen on ultrasound scans. To put it another way, pathology alters the acoustic impedance of normal tissues, causing an increase or decrease in the number of interfaces.

Many forms of pathology can be seen; some are common to more than one area of the body or to more than one specific organ, while some pathology is unique to certain structures. In general, some common pathology and other reasons for doing ultrasound exams are tumors (masses), cysts, aneurysms, pregnancy evaluations, and intrauterine contraceptive device (IUD) localization.

**Differential diagnosis.** Since pathology affects how tissues are visualized, you also need some ability to diagnose those visual differences. This is called *differential diagnosis*. This is not the same as a doctor's diagnosis of a patient's condition. But rather an ability—indeed, a responsibility—of each ultrasonographer to see differences between normal and abnormal tissues. Without this skill, you would be unable to perform accurate studies because you wouldn't know for sure whether you had adequately visualized enough anatomy.

Most pathology exhibits specific characteristics on ultrasound scans. For example, solid masses contain many interfaces within the structure and reflect many echoes; whereas a cystic mass (fluid filled) doesn't reflect echoes because of the homogenous density of its fluid and because it has a strong back interface. This is clearly seen in figure 3-21. This longitudinal scan of the lower abdomen shows two structures distinct from surrounding tissues. The larger clear area above the smaller structure is the urinary bladder. Notice how it is free of echoes and has a strong back interface. This is characteristic of fluid-filled cysts and masses. Below the urinary bladder is a mass that shows numerous echoes within its structure. Those echoes suggest that there are many interfaces within that mass, so it is a complex mass.

A fluid cyst and the urinary bladder are shown in figure 3-22. The urinary bladder is inferior (in the body) to the cyst. On this scan, the bladder is to your right. The fluid-filled cyst (to the left of the bladder is relatively free of echoes and has a strong back interface. Because this longitudinal scan shows a "slice" at 3 cm to the right of the midline and because the cyst is located just above the bladder, we can assume that it is a right ovarian cyst. Since you were able to make this differential diagnosis, you should give the radiologist enough scans on the right side of the patient to adequately show the entire size and location of the cyst.

Another example of pathology is stones or, more formally, calculi. Stones exhibit a certain characteristic on the scan because they are very dense. This density prevents transmission of the sound wave through the stone, which, in turn, causes an echo-free shadow on the side of the stone away from the incident sound beam. Figure 3-23 shows a longitudinal scan 8.5 cm to the right of the midline high in the abdomen. The small, echo-free, oblong-shaped area is the gall-bladder. The strong short interface next to the gallbladder is the cystic duct. The echo-free shadow (acoustic shadow) below the cystic duct is present because the sound beam was unable to pass through the cystic duct. This suggests a stone in the cystic duct.

Even though ultrasound is used for many reasons, it is probably used more for pregnancy evaluations than for any other reason. Some common pregnancy evaluations are fetal status (age, size, death, number), ectopic pregnancy (a pregnancy outside of the uterus), and placenta previa (formation of the placenta which blocks the birth canal, preventing the passing of the baby through the opening of the uterus). The scan in figure 3-24 shows twins. In this scan, the homogenous density structure above the fetal skulls is the placenta. This placenta location is normal.



Figure 3-21 Ultrasound scan showing a fluid-filled cyst and a complex mass



Figure 3-24 Ultrasound scan showing twins.



Figure 3-22 Ultrasound scan showing two fluid-filled cysts




Figure 3-23. Ultrasound scan showing an acoustic shadow produced by a stone in the cystic duct

However, in figure 3-25 it extends low in the uterus, surrounding the fetal skull and preventing the passage of the fetus. Notice how easily the placenta is distinguishable from surrounding structures. The placenta shows a homogenous density, usually lighter in gray tones than adjacent tissues, and has a strong black-line interface—the chorionic plate (a dense membrane of the placenta).

**Exercises (430):**

1. What causes pathology to be visualized on ultrasound scans?
2. Define "differential diagnosis."
3. What does a solid mass look like on a scan?
4. What does a cystic mass look like on a scan?
5. What may be seen on a scan that may indicate that a stone is present?
6. What does a placenta look like on a scan?
7. What is the chorionic plate, and how does it appear on a scan?





Figure 3-25. Ultrasound scan showing placenta previa.

#### 431. Explain patient and technician preparation procedures.

**Preparing For An Examination.** Like most scheduled X-ray examinations, ultrasound procedures also need some preparation by the patient and the ultrasound technician.

**Patient preparation.** Not every exam needs special patient preparation. However, some general considerations apply individually. The procedure should be explained to the patient to relieve anxiety. This might be done by the physician or by you when the patient is scheduled.

Some examinations do require special patient preparation. For example, the patient should fast when you will be visualizing organs of the upper abdomen, such as the gallbladder or pancreas. With the gallbladder, fasting helps to maximize passive dilation and prevent the physiologic contracting and emptying. Drinking carbonated beverages, such as colas, can produce gas in the lower stomach and duodenum and can hinder visualization of the pancreas. And because of undesirable acoustic shadows from barium, ultrasound exams should be done before barium studies.

When you will be scanning into the pelvic area, you may ask the patient to retain urine. This distends the urinary bladder. The patient may need to drink several glasses of water 1 hour before the test to fill the bladder. This full-bladder technique has certain advantages. First, a full bladder is an excellent conductor of sound to the uterus and pelvic sidewalls. Second, the distended bladder displaces higher, troublesome loops of intestine into the abdomen, as well as the uterus.

**Technician preparation.** Of course, you also need to prepare for the examination. Generally, you should make sure that all equipment is operational, all supplies are at hand, the room is clean and not too cool, and that clean sheets are on the table or gurney.

You have to specially prepare the patient's skin at the beginning of each examination. You do this by rubbing an acoustic coupling agent, such as mineral oil, onto the area you intend to scan. This ensures that the sound beam will

transmit properly into the body tissues. Without this coupling, the air gap between the skin and the transducer face dissipates the transmitted and reflected beams. After this has been applied, you are ready to begin scanning.

#### Exercises (431):

1. Explain the effect that fasting has on the gallbladder
2. Why should a patient not drink a cola just before a pancreas scan?
3. When both are requested, why should an ultrasound exam of the pancreas be performed before an upper GI?
4. List five general things a technician can do to prepare for an exam.
5. Why is mineral oil applied to the patient's skin?

#### 432. Specify factors to consider in performing ultrasound examinations of the abdomen.

**Performing Abdominal Ultrasonography.** With ultrasound application being changed and expanded constantly, it is very difficult to list specific procedures for certain examinations. As with diagnostic radiography, many radiologists like to do some examinations in ways that vary from the textbook way of doing things. So we won't state procedures for doing these exams only in our way. Instead we explain some generalities about common ultrasonography exams with the understanding that individual standard operating procedures (SOP) may cause variations. Specifically, we cover most major studies that you may do, why they are requested, and some common SOPs.

Four structures that are frequently examined are the aorta, the gallbladder, the liver, and the pancreas.

**Scanning the aorta.** Ultrasonography of the aorta is usually done to confirm or measure an aorta aneurysm. After routine patient preparation, such as applying an acoustic coupling agent, you begin the examination by doing longitudinal scans first. Begin at the midline, and scan along either side of the median plane. Make sure your scans show the greatest diameter of the vessel, shown in figure 3-26. Notice how the aorta narrows as it descends in the body and then becomes enlarged because of the aneurysm.



Figure 3-26 Ultrasound scan showing an aorta aneurysm.

Transverse scans are done at 2 to 3 cm intervals so that the entire length of the aorta can be evaluated. If you know that an aneurysm exists, you should scan the aneurysm at 1 cm intervals.

**Scanning the gallbladder.** Two of the more common reasons for examining the gallbladder are to confirm gallstones and to evaluate disease, such as cholecystitis. Before you begin this exam, be sure that the patient has been NPO 10 to 12 hours before the exam. This keeps bile in the gallbladder, increasing its visualization, since a fluid-filled cyst is rather easily seen.

Begin your scanning with the patient supine. Because of the gallbladder's location (near the right costal margin), you may have to do these scans while the patient holds a deep breath. This pushes the gallbladder caudally so that ribs don't interfere with the sound beam. Do the transverse scans first, starting at the level of the umbilicus or iliac crest and working toward the right ribs at 1 to 2 cm intervals.

As the gallbladder's location becomes known, you should mark its outline on the patient's skin. This enables you to do longitudinal scanning parallel to the gallbladder's long axis. When you are scanning for stones, make your scans at intervals of about 5 mm.

Since stones reflect most of the sound, they generally cast a well-defined, echo-free acoustic shadow. Intestinal gas can also cast an acoustic shadow. So, you should include a decubitus or upright scan to evaluate stone movement. This patient position may cause intestinal gas to rise out of the way, or the stone may drop slightly lower. In either case, this position may eliminate false-stone echoes.

**Scanning the liver.** The liver is a nice organ to study because it is large and much of it can be seen well (see fig. 3-27). We scan the liver to assess its overall size, evaluate hepatic texture, and to check for dilated bile ducts. Hepatic texture is easy to evaluate because, while a normal liver is uniform in echo densities, a diseased liver produces a striking change in echo activity. Such is the case of cirrhosis, which increases echo production. Dilated bile ducts could indicate extrahepatic biliary obstruction, such as stones in the common bile duct.

One problem in scanning the liver deals with its location under the right lower ribs. The ribs interfere with longer movement scans. You can avoid poor imaging caused by these ribs by doing sector scans.

**Scanning the pancreas.** The pancreas is quite unlike other abdominal organs—a normal pancreas cannot always be clearly identified because it produces very dark echoes which are very similar to adjacent structures. On the other hand, pancreatic disease can be easily seen if the pancreas is not hidden by bowel gas. Almost any gross pathologic process which affects the pancreas—tumor, edema from pancreatitis, or cyst—will enlarge this gland and decrease its echo production.

Pancreatic scanning procedures usually begin with transverse scans. It is easier to find the pancreas if you first locate the splenic vein. This vein normally runs along the upper margin of the pancreas. Transverse scans that move caudally from that starting point will cover the pancreas. Followup with longitudinal scans.

#### Exercises (432):

1. What type of scans should be used, and where should you begin them when scanning the aorta?
2. Why do you make transverse scans of the aorta?
3. What are two common reasons why gallbladder scanning is requested?
4. What breathing technique can be done by the patient to aid in visualization of the gallbladder? Why?



Figure 3-27. Ultrasound scan showing the liver

5. Why should you include either a decubitus or upright scan of the gallbladder?
6. What pathology may cause an increase of echoes in the liver?
7. What scanning motion should you do to visualize the liver? Why?
8. Why is a normal pancreas difficult to visualize?
9. What effect does pathology have on the pancreas?
10. What anatomical structure in the body is used as a landmark to locate the pancreas?

**433. Specify factors to consider in performing urologic ultrasonography.**

**Urologic Ultrasonography.** Ultrasound can also be used to demonstrate key structures of the urinary system: kidneys, ureters, and the bladder. Studies of the kidneys are

most often requested to find such pathology as tumors, masses, stones, and hydronephrosis.

**Scanning the kidneys.** Unlike sonography of abdominal structures, you can demonstrate kidneys best when the patient is prone and holding her breath at the end of a deep inspiration. A prone position puts a kidney in the direct path of a sound beam without intervention of bowel or other structures which might interfere with the passage of sound and cause a poor image. Maximum inspiration helps to push the upper pole of a kidney to a point where it is below the lower border of the rib case; thus, you can scan the whole kidney without overlying ribs.

Once the patient is prone, place a pillow underneath the stomach area to elevate the midabdomen. This helps to bring the kidneys out from underneath ribs.

Begin with transverse scans at the level of the iliac crest and proceed toward the head at 1 to 2 cm intervals. As shown in figure 3-28, you should angle the transducer about 15° cephalically for transverse scans. This aims the beam at right angles to the long axis of the kidney. Mark with a wax or washable ink marker on the patient's skin the medial and lateral borders of each kidney. This is an accurate way to identify the long axis of each kidney so that longitudinal scans can be parallel to the long axis.

A kidney is seen as bean-shaped; the parenchyma gives off very weak echoes while the internal, central collecting system gives off strong echoes.

**Scanning the ureters.** Ureters are not scanned as often as kidneys and the bladder. But when they are of primary interest, it is usually because of the presence of calculi. The patient is placed in the prone position and scanning procedures are very similar to those described for kidneys.

**Scanning the bladder.** Pathology of interest in the bladder include tumors and calculi. The patient should be supine and have a full bladder. Both transverse and longitudinal scanning should be done to show the entire bladder.

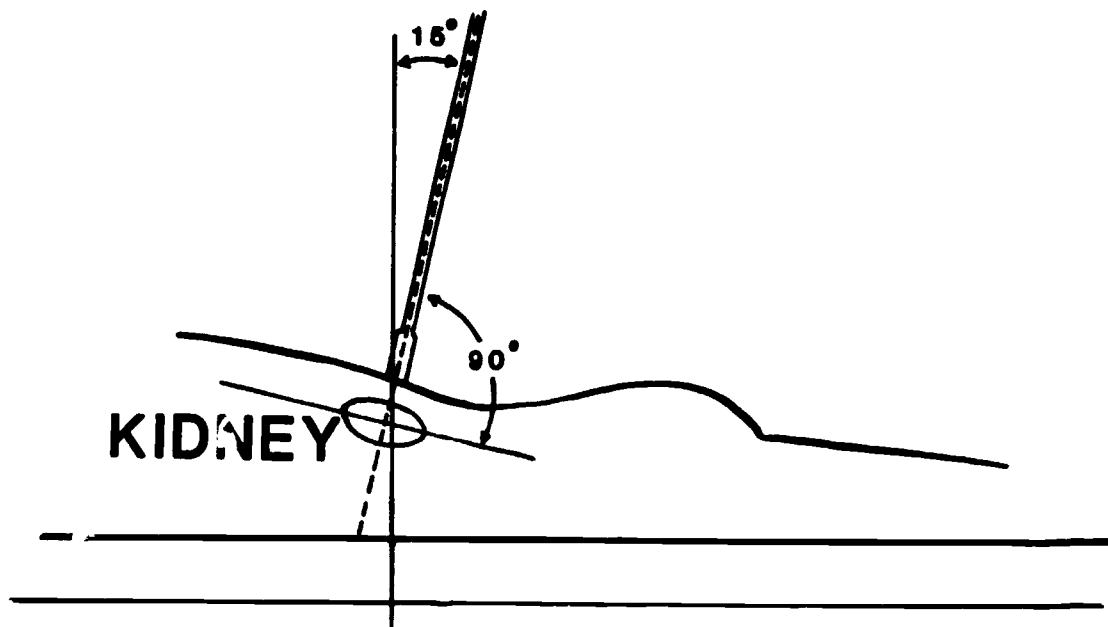


Figure 3-28. Positioning a transducer for scanning a kidney

### Exercises (433):

1. How should you position a patient when you scan the kidneys?
2. What breathing technique should a patient do that enables better demonstration of kidneys?
3. How many degrees and in what direction should you angle the transducer when scanning kidneys?
4. Which structures of the kidney give off strong echoes?
5. What common abnormality may require scanning of the ureters?
6. How should you position the patient when you scan the urinary bladder?

### 434. State characteristics of OB, GYN, and pelvic ultrasonography.

**Obstetric (OB), Gynecologic (GYN), and Pelvic Ultrasonography.** We group OB, GYN, and pelvic studies together because scanning procedures and visualized structures are sometimes common. Obviously male patients don't undergo OB/GYN ultrasonography, but they do experience pelvic studies.

These examinations begin with the patient supine. See that your patient has a full urinary bladder to ensure a good acoustic window.

Longitudinal scans are usually done first. Use the bladder as an acoustic window to its utmost advantage by angling the transducer cephalically and sector scan.

Sometimes when you are scanning in the lower pelvis, fecal material and bowel gas in the rectum and sigmoid colon interfere with the sound beam. This may cause false readings of a mass. In this case, the patient may need a cleansing enema. Depending upon the type of examination, to include the need for a cleansing enema on the morning of the exam in patient instructions at the time of scheduling.

It is most likely that you will do many OB studies since they are the most often requested. And there are good reasons for that. First, there is no medical proof of damaging biological effects of ultrasound on the fetus. Second, much information about pregnancy can be gained even very early in the pregnancy. Some of this information includes gestational age, placental localization, more than

one fetus, and fetal location. Pathology such as hydrocephalus (enlargement of the head), anencephaly cephal (absence of a cranial vault), and collapse of the cranium (because of fetal death) can also be recognized.

### Exercises (434):

1. When scanning for pelvic contents, which type of scanning motion of the transducer should be used?
2. What may cause false readings of a mass in scans of the lower pelvic area?
3. Give two general reasons why OB studies are the most frequently requested ultrasound examinations.

### 435. Explain characteristics of miscellaneous ultrasound examinations.

**Miscellaneous Ultrasonography.** In addition to the common studies already covered, ultrasound is used to visualize other structures of the body. Some of these include the eye, the thyroid, the breast, tumor localization for radiotherapy, and the brain.

**Scanning the eye.** Because it is filled with fluid, the eye is a good organ to scan. B-mode and A-mode may both be used. Ophthalmic ultrasonography is done to determine the size of the eye as well as the presence of retinal detachment, hemorrhage, tumors, or foreign bodies.

**Scanning the thyroid.** The thyroid gland is usually scanned to complement an isotope scan, although they are helpful even when an isotope scan has not been done. Primarily, ultrasound is used to differentiate between cystic and solid thyroid masses (nodules). It is also used to assess the overall size of the thyroid gland.

It is not difficult to scan the thyroid if the patient is positioned so that the gland is easily accessible. This is best achieved if the patient is supine with a bulky pillow under the upper thorax so that the head hangs over the top edge of the pillow. This extends the neck, causing the thyroid to be pulled up from the manubrium and thrust forward.

A coordinate system, unique to scanning the thyroid, is needed. The same coordinates that are used for the abdomen are appropriate for longitudinal scanning because the midline is still your central point. For transverse scanning, however, coordinates need to be indicated with reference to the manubrium.

**Scanning the breast.** The breast can be studied to differentiate between cystic and solid masses. But there are some drawbacks. For instance, the contour of the breast is easily distorted by contact with the transducer. When the underlying tissue is moved because of surface contact, the interfaces move and the picture becomes meaningless. For

this reason, X-ray mammograms give better detail than does ultrasound.

**Scanning for tumor localization.** This has become a very helpful tool to the radiation therapist in radiotherapy planning. It is used to demonstrate patient contours and location of tumors so that treatment areas can be determined. This may be done before treatment and also during treatment to check on the progress of treatment.

Ultrasound is also used to locate normal structures in patients receiving radiotherapy. The structures outlined on the scan and on the patient's skin may be protected from the damaging radiation being delivered to the affected area.

**Echoencephalography.** This procedure demonstrates internal structures of the brain.

A transducer is placed on the temporal region of the skull and held stationary. The echoes are viewed on the A-mode screen as vertical spikes. The first echo represents the transducer-skull interface. The echoes received from structures, such as ventricles and the midline of the brain, will be demonstrated. The far side of the skull will be seen also. This image can then be recorded.

The transducer is then placed on the opposite side of the skull at the same level. Again, the echoes are recorded and measurements taken to determine the position of these structures.

This procedure can be used to determine the presence of space-occupying lesions. This type of lesion may cause a shift in position of internal structures of the brain, especially the ventricles.

#### **Exercises (435):**

1. Why is the eye a good organ to scan?

2. What modes may be used to scan the eye?
3. What are scans of the thyroid nodules used for?
4. What structure should you use as a landmark reference when you do transverse scans of the thyroid?
5. What is a major disadvantage of scanning the breast?
6. Why are normal structures scanned in patients receiving radiotherapy?
7. What procedure demonstrates internal structures of the brain?
8. Describe the placement and motion of the transducer during echoencephalography with A-mode.

# Tomography

WITH CONVENTIONAL methods of radiography, images are often superimposed that obscure the structure under study. Sometimes stereoscopy, tube or film angles, along with additional projections, may be used to alleviate this condition. However, under some conditions, tomography may be required to eliminate the superimposition.

Our study of tomography begins with a review of terminology and types of tomographic systems. After that, we explain the principles involved. We conclude this chapter with some specific tomographic examinations.

## 4-1. Tomographic Terminology, Tube Movements, and Operating Principle

To fully understand tomography, you must know certain terms. Basic understanding of the various types of tomographic tube movements is also necessary. We discuss these subjects in this section and then explain the basic tomographic principle.

### 436. Define terms pertaining to tomography.

**Tomographic Terms.** Although several names are applied to the concept of radiographing a certain section or "slice" of the body, the *International Commission on Radiological Units and Measurements (ICRU)* recommends that *tomography* be used to describe all body section techniques using similar principles. A radiograph produced by these techniques is called a *tomogram*.

A *lever* is a connecting rod which couples the tube and film carrier (cassette tray) so that tube and film movement are proportional (see fig. 4-1). The *fulcrum* is the point about which the lever pivots. When you do a tomogram, you adjust the fulcrum to correspond to the layer or plane to be radiographed.

The *focal plane* is the layer of the body which appears sharpest on the tomogram. You know the term *blurring*. In tomography, blurring represents the unsharp body area outside (above or below) the focal plane.

*Amplitude* is the distance the tube travels during the exposure—expressed in inches. *Rate* is the speed of tube travel—usually expressed in inches per second.

*Exposure angle* is the angle, in degrees, of the tube travel during exposure (see fig. 4-2).

*Zonography* is tomography with a small exposure angle—less than  $10^\circ$ .

### Exercises (436):

Define the following tomographic terms:

1. Tomography.
2. Tomogram.
3. Lever.
4. Fulcrum.
5. Focal plane.
6. Blurring.
7. Amplitude.
8. Rate.
9. Exposure angle.
10. Zonography.

437. Given a figure showing seven tomographic tube movements, identify each movement by name.

**Tomographic Tube Movements.** The more a tomographic motion differs from the shape of the object

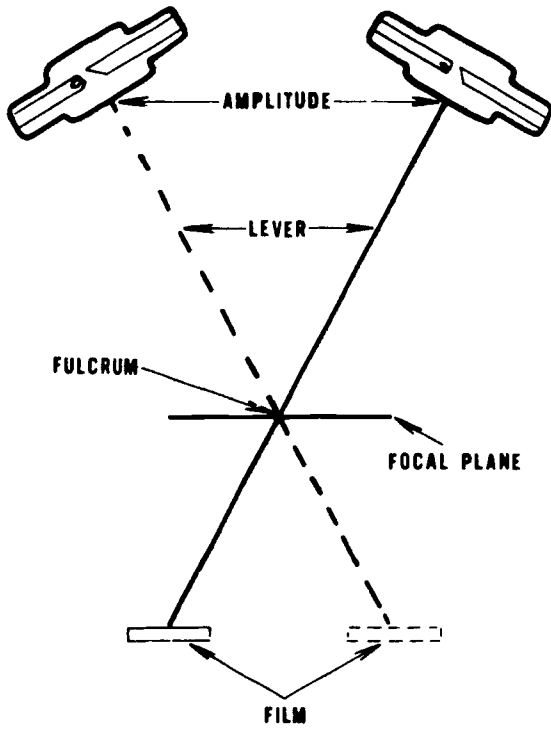


Figure 4-1 Tomographic terms and points of interest

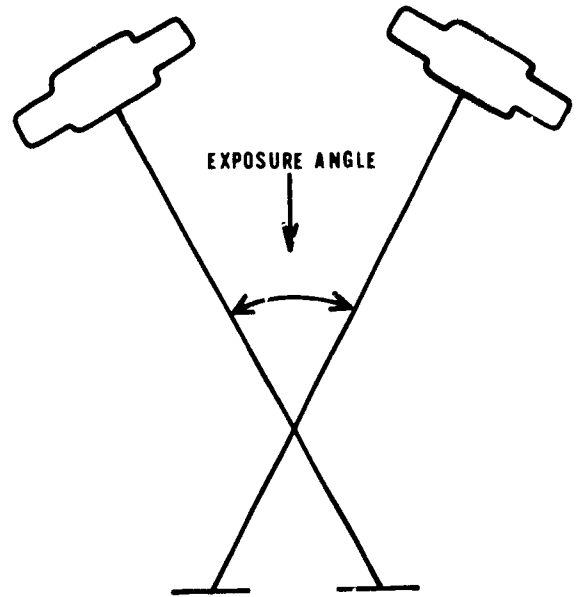


Figure 4-2 Exposure angle

being radiographed, the more uniform the image. The specific movement of the X-ray tube during tomography depends on the type of system used. The simplest and most common is rectilinear (or linear) tomography.

In rectilinear tomography, the tube moves in a straight line, along the axis of the table. In pluridirectional tomography, also called polytomography, there is a wide variety of movements. Polytomography systems, as a general rule, produce better tomograms of areas which require maximum blurring. The most common polytomographic terms and their movements are:

- |                         |                               |
|-------------------------|-------------------------------|
| Circular . . . . .      | Complete circle               |
| Elliptical . . . . .    | Oblong circular path          |
| Hypocycloidal . . . . . | Pretzel-like pattern.         |
| Random . . . . .        | No specific pattern.          |
| Spiral . . . . .        | Circle toward a central point |
| Sinusoidal . . . . .    | Wavy line                     |

The circular movement, the simplest of the polytomographic movements, offers complete blurring. The most complex movement is hypocycloidal; it makes a pretzel-like cut that produces the most perfect blurring.

**Exercises (437):**

Identify the tomographic tube movements in figure 4-3 by writing the name of the movement opposite the appropriate letter below.

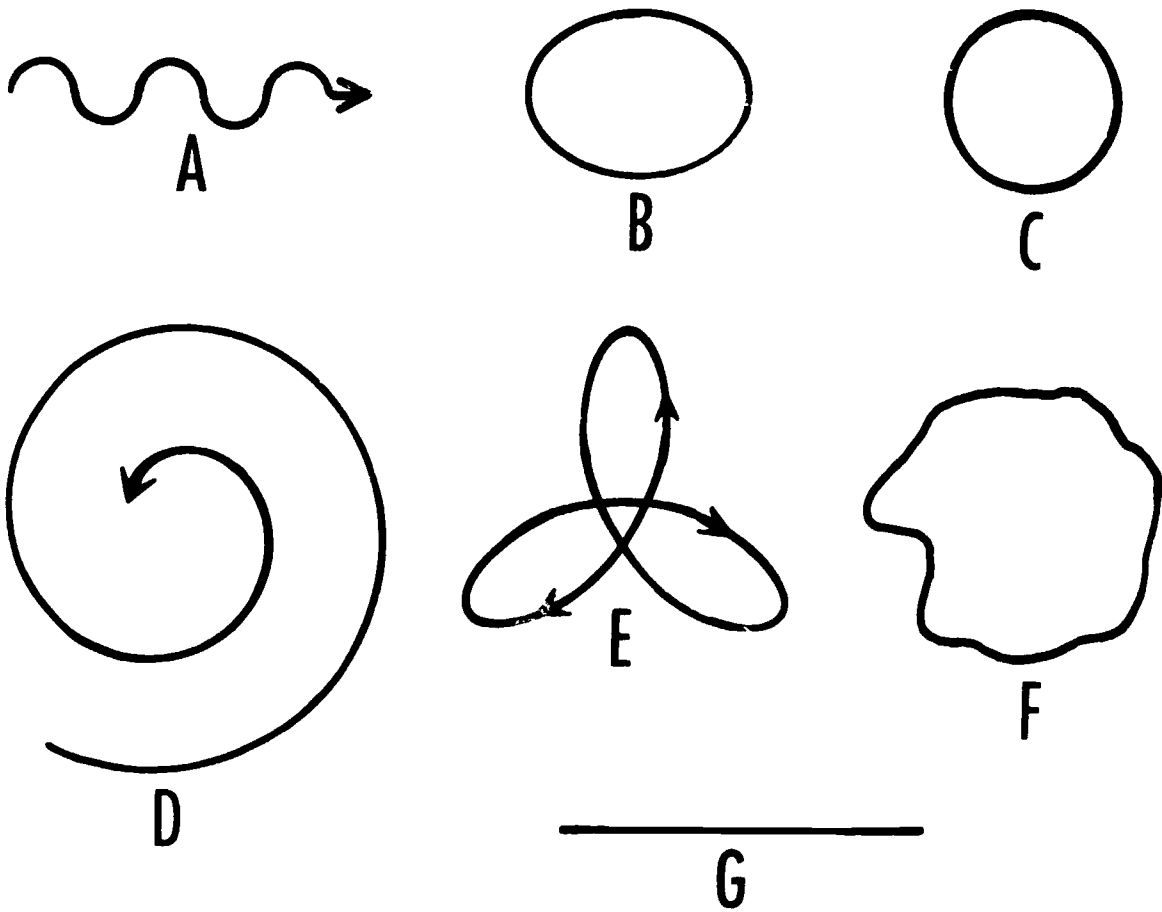


Figure 4-3 Objective 441, exercise 1-7

- |       |       |
|-------|-------|
| 1. A. | 6. F. |
| 2. B. | 7. G. |
| 3. C. |       |
| 4. D. |       |
| 5. E. |       |

**438. State the operating principles of tomography.**

**Principle of Tomographic Operation.** If you do a PA projection of the chest, the radiograph will show the relatively dense ribs superimposed over particular portions of the lung tissue. If a lesion is present in the lungs between an anterior and a posterior rib, visualization of the lesion is not good because of this superimposition of the ribs.

**Blurring.** Let's see how tomography can eliminate these rib shadows or eliminate various other superimposed



structures. Figure 4-4 shows five structures in a vertical plane. Assume that circle number three is the lung lesion and circles one and five are the ribs. Notice in film position A (the beginning of the exposure) the relative locations of the projected circles. Circle one is projected on the left side of the film, circle number three is projected on the center of the film, and circle number five is projected on the right side of the film.

As the tube and film shift during the exposure, the relative positions of the projected circles, except for circle number three, also shift. When tube movement and film movement stop (film position B), the circles are projected on opposite sides of the film. Notice that circle number one, which was projected on the left side of the film at the beginning of movement, is projected on the right side when movement stops. Positions of circles two, four, and five also change. This change in the projected positions of the circles blurs the images and more or less eliminates them from the radiograph. Projected circle number three stays in the center of the film throughout the movement and is not blurred. Consequently, the lung lesion is visualized without the superimposed shadows of the ribs.

**Absence of blurring in the focal plane.** Recall that at the beginning of this chapter we defined focal plane as the layer of the body which appears sharpest on a tomogram. Let's see why images in the focal plane are not blurred. Notice in figure 4-5 that the three circles are projected to the same relative locations on the film during the tube movement and film movement. Consequently, the three circles are clearly projected on the radiograph.

**Exercises (438):**

1. Why is a structure located at the fulcrum not blurred on a tomogram?
2. Why is a structure located above or below the fulcrum level blurred on a tomogram?

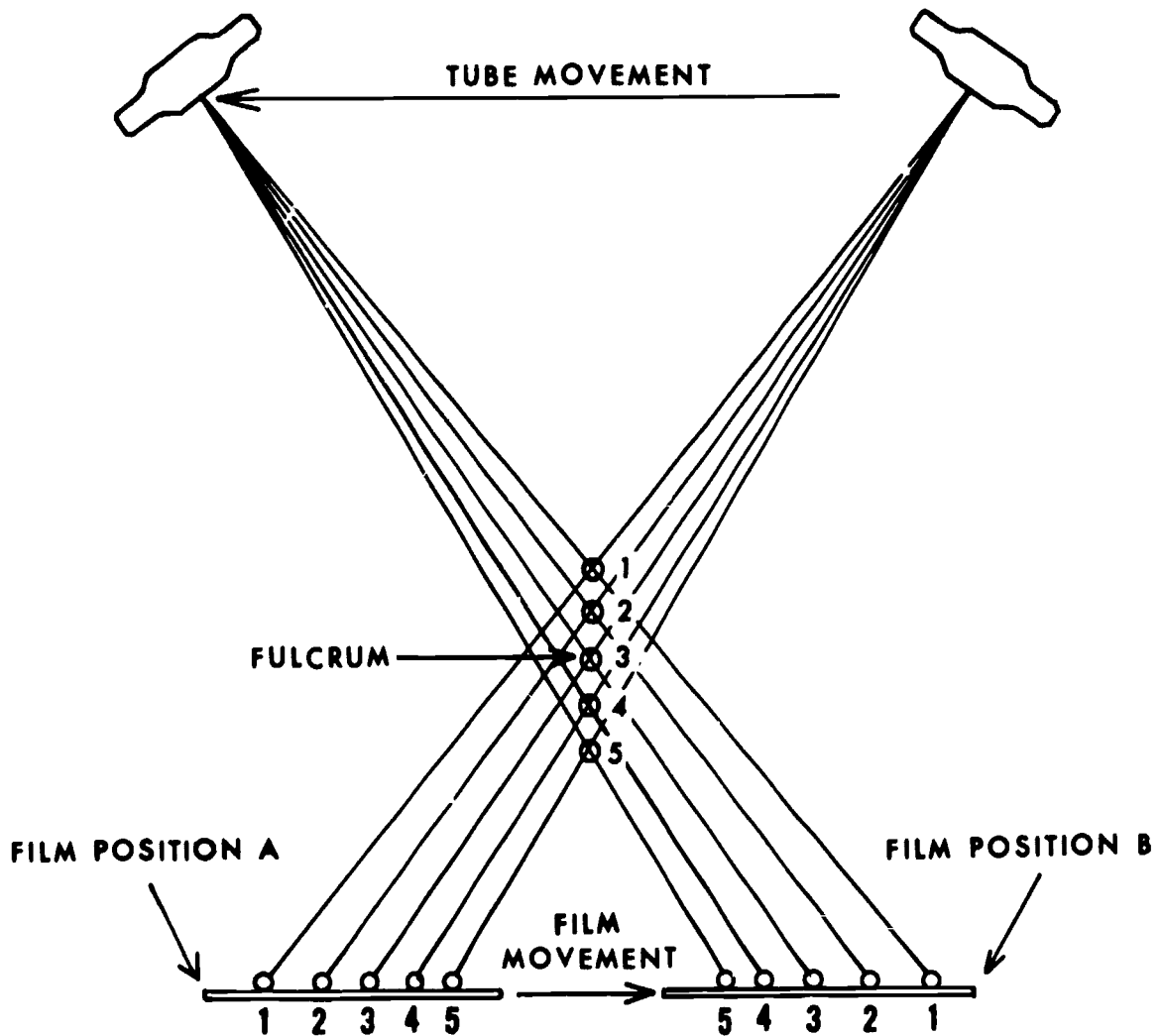


Figure 4-4 Illustration showing why some structures are blurred and some are sharp on a tomogram

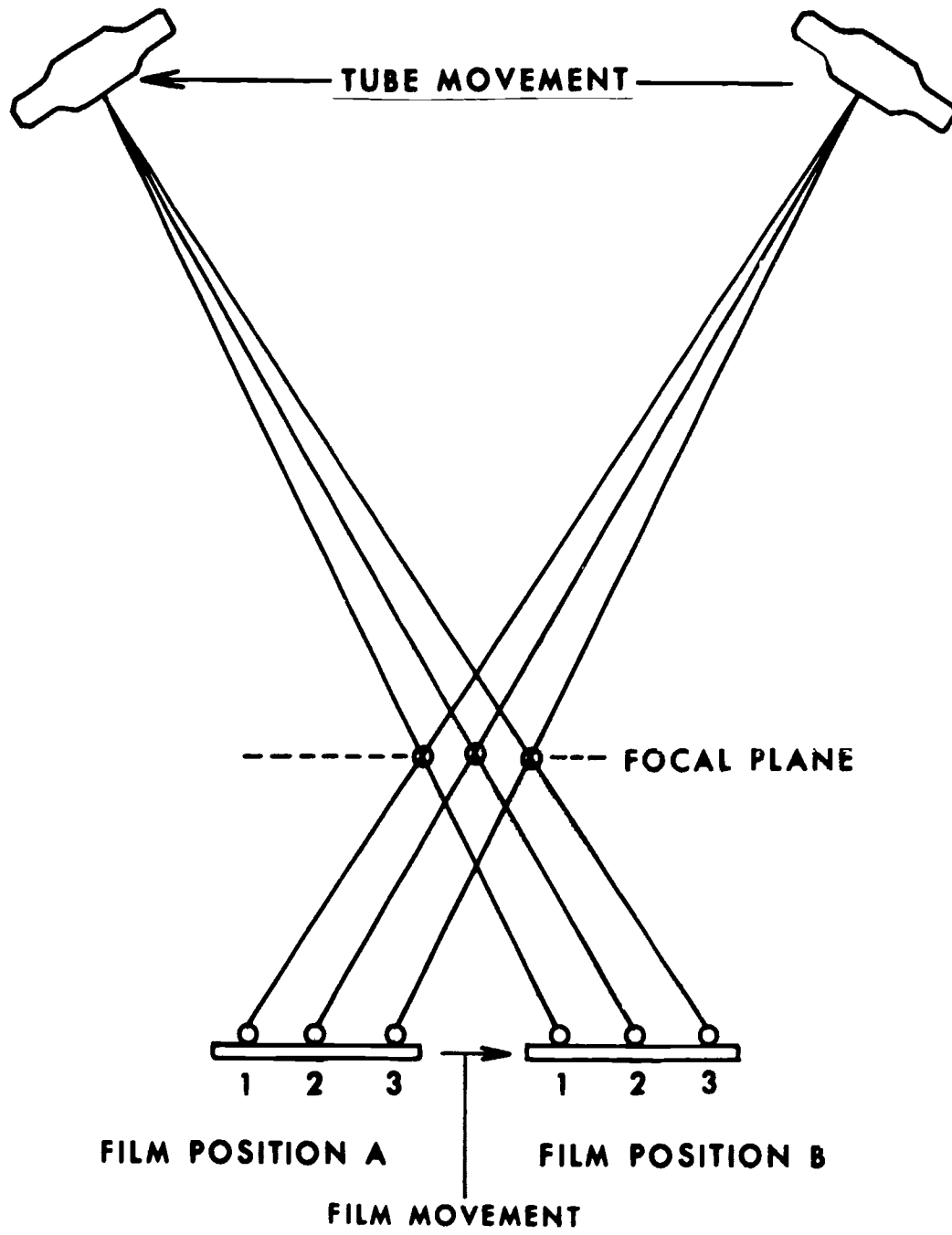


Figure 4-5 Illustration showing why structures located in the focal plane are not blurred

3. Explain the connection between the focal plane and blurring.

3. Structures located within a section are \_\_\_\_\_, while those located outside the section are \_\_\_\_\_.

439. State the effect of exposure angle on section thickness.

4. Which causes more blurring, a large or small exposure angle?

**Description of Section Thickness.** When you do a tomogram, you actually radiograph a layer or section of the body. Generally speaking, everything above and below the section is blurred to the extent that it is not visualized. In actuality, there are no definite lines between the sharp and the blurred images. The degree of blurring gradually increases as the distance from the focal plane increases. By the same token, sharpness increases nearest the focal plane.

5. Which produces a thicker section, a large or a small exposure angle?

For all practical purposes, it may be said there are lines that divide the images sharp enough for interpretation from those too blurred for interpretation. The portion of the body between those lines is called the *section thickness*. Notice in figure 4-6 that we have illustrated a specific section thickness of 10 mm. All structures within the 10-mm section are considered sharp, while those outside the section are considered blurred. Naturally, the focal plane is at the center of the section thickness.

440. State the factors to consider in selecting exposure angles.

**Factors Affecting Exposure Angle.** Four factors affect the exposure angle.

**Exposure Angle and Section Thickness.** The thickness of the section is not the same for all tomograms. Basically, the thickness of the section depends upon the exposure angle used for the examination. Notice that in figure 4-7 we have illustrated tube movements through two different exposure angles. In detail A, the projected dots on the film move considerably less than do the dots in detail B. So there is less blurring with the small exposure angle in detail A. Or we can also say the section is thicker with the small exposure angle.

**FFD.** If the amplitude is constant, a long FFD produces a thicker section than does a short FFD. Notice in figure 4-8 that both detail A and B show the same amplitude; but due to the difference between the FFDs, the exposure angle is different.

**Amplitude.** If the FFD is constant, a short amplitude produces a thicker section than does a long amplitude. Details A and B in figure 4-9 both show the same FFD. The exposure angle is smaller in detail A because of the short amplitude.

**Exercises (439):**

1. What does a tomogram record?
2. What factor determines the sharpness of a tomograph image?

**Distance of a structure from the focal plane.** Now let's look at a single exposure to see how the angle changes. Notice in figure 4-10 that the three structures, A, B, and C, are projected by different exposure angles that vary by the number of degrees shown in the figure. Angle A is greater than angle B, and structure A is more blurred than is structure B. So we can deduce that the farther a structure is from the focal plane, the more it is blurred.

**Distance of a structure from the film.** The farther a structure is from the film the greater the angle and, consequently, the more blurred it is on the radiograph. As figure 4-11 shows, angle A is greater than angle C, which means that a structure located at A is blurred more than a structure located at C. Keep in mind both structures A and C are equidistant from the focal plane.

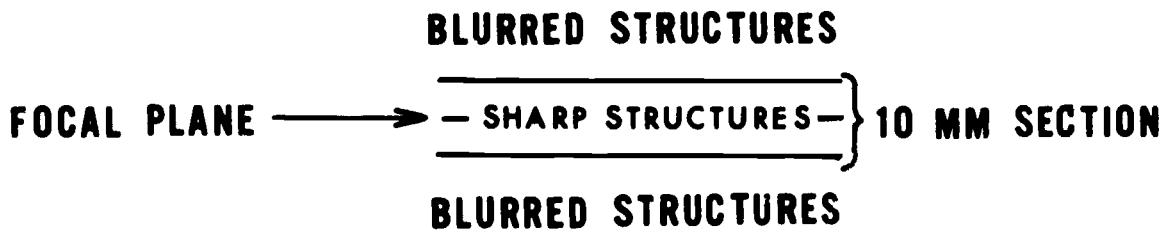


Figure 4-6. Section thickness.

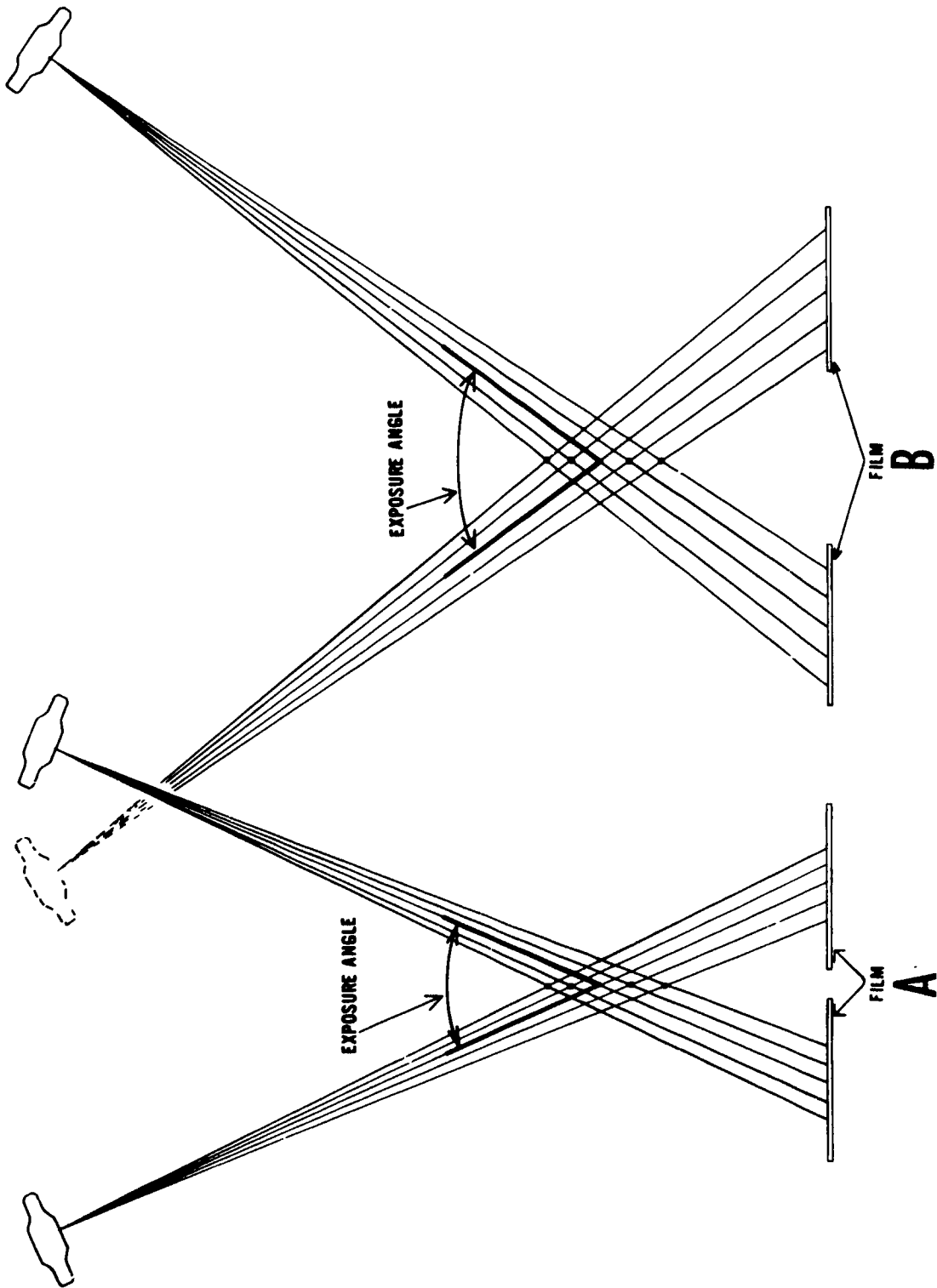


Figure 4-7 Effect of exposure angle on section thickness

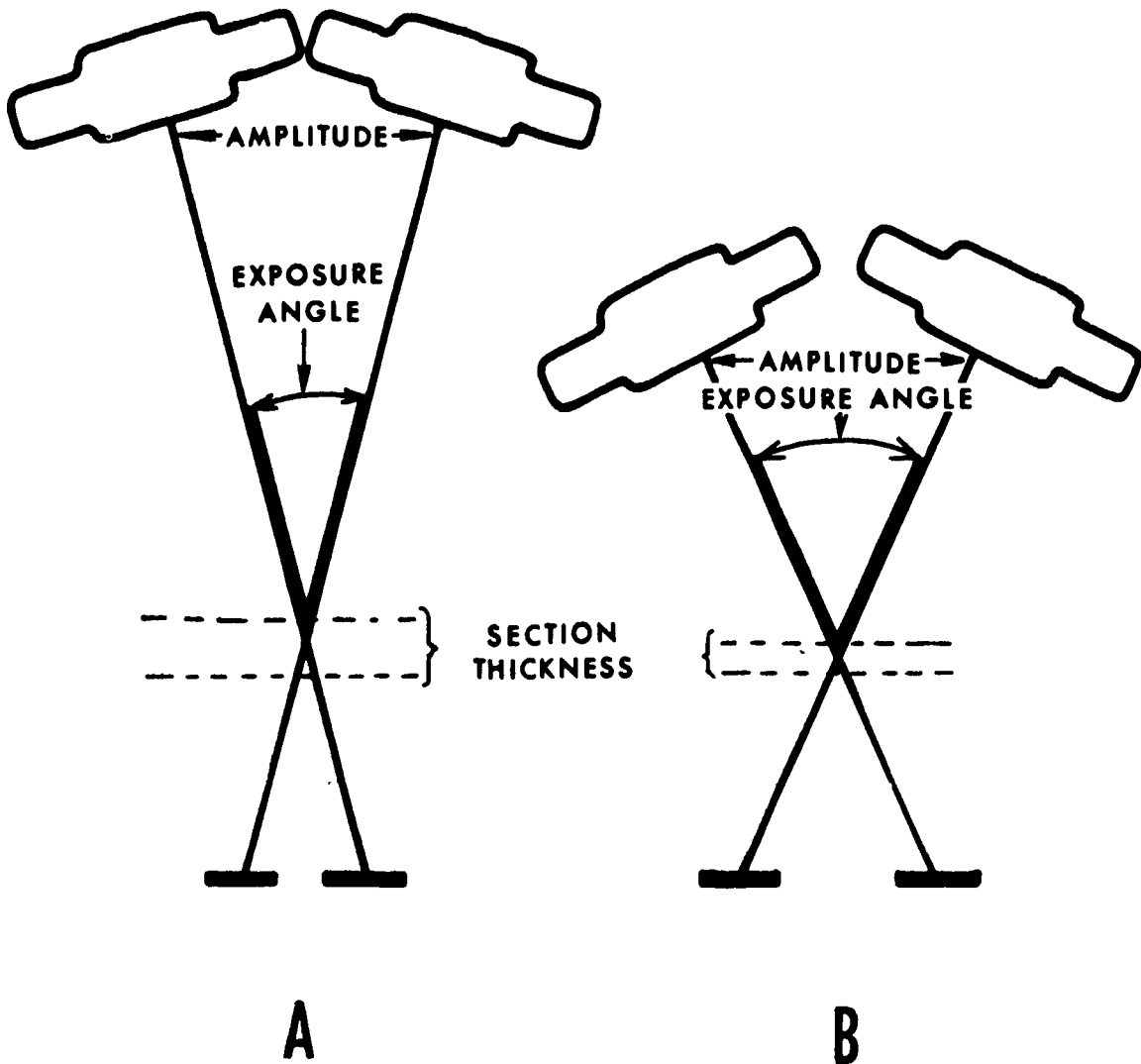


Figure 4-8 Effect of FFD on exposure angle and section thickness

**Exercises (440):**

Indicate whether the following statements are true (T) or false (F). If you indicate false, explain your answer.

- \_\_\_ 1. Exposure angles are reduced when short amplitudes are used.
- \_\_\_ 2. You should use a long amplitude to produce a thick tomographic section.
- \_\_\_ 3. There is no relationship between FFD and exposure angle.
- \_\_\_ 4. On a single tomographic exposure, structures located in the same vertical plane are projected by the same exposure angle.
- \_\_\_ 5. The degree of blurring of a structure is determined by its distance from the focal plane.

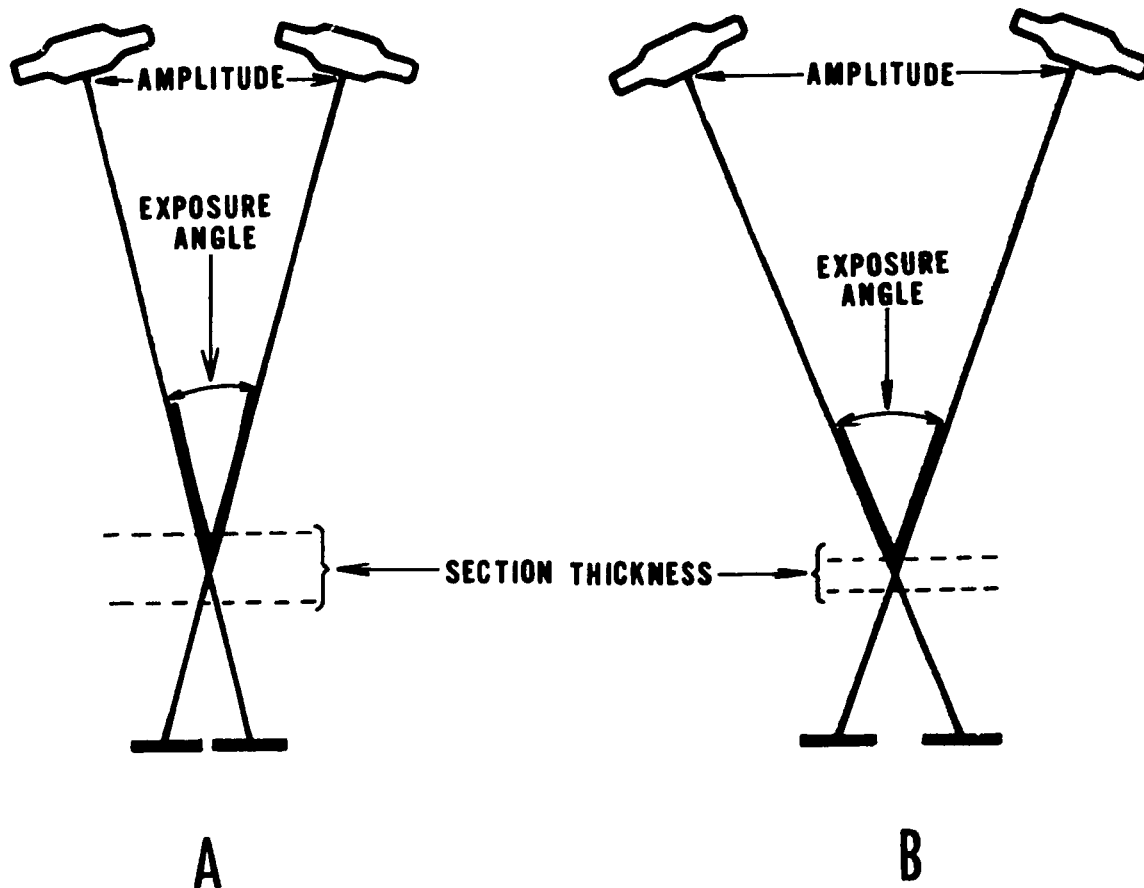


Figure 4-9. Effect of amplitude on exposure angle and section thickness

- 6. The exposure angle increases as a structure's distance from the film increases.
- 7. For increased blurring of a structure, a patient should be positioned so the structure is farther from the film.

#### 4-4. Multisection Radiography

With multisection radiography, you can do radiographs of several sections or "cuts" in a single tomographic exposure. There are some definite advantages to using this procedure. We begin with a description of the special cassette used in multisection radiography.

**441. State how a book cassette records different sections.**

**Book Cassette.** Basically, the difference between performing a single tomographic cut and performing

several simultaneous cuts is that the latter procedure uses a special "book" cassette (fig. 4-12), which has more than one pair of intensifying screens and accommodates more than one film. A five-film book, for example, cassette contains five *pairs* of screens. The number of films used in the cassette varies, and a tomographic examination produces a cut of a different section on each film. The distance between the cuts is equal to the space between each film in the cassette. For example, if the film interspace is 1 cm, you produce simultaneous cuts 1 cm apart. Keep in mind that we are not talking about the thickness of the section—thickness is determined by the exposure angle.

The speeds of the five pairs of intensifying screens in a book vary because photons are absorbed as they pass through the films, screens, and interspace material. The top (tube side) pair of screens are the slowest, and the remaining pairs are progressively faster. The variable screen speeds compensate for the reduced beam intensity and result in even densities on each film.

**Principle of Operation.** The principle of multisection radiography is shown in figure 4-13. Notice that points 1 and 2 in the structure are both projected to the centers of films 1 and 2 respectively. The reason for this is each film has, in effect, its own fulcrum due to the space between the films.

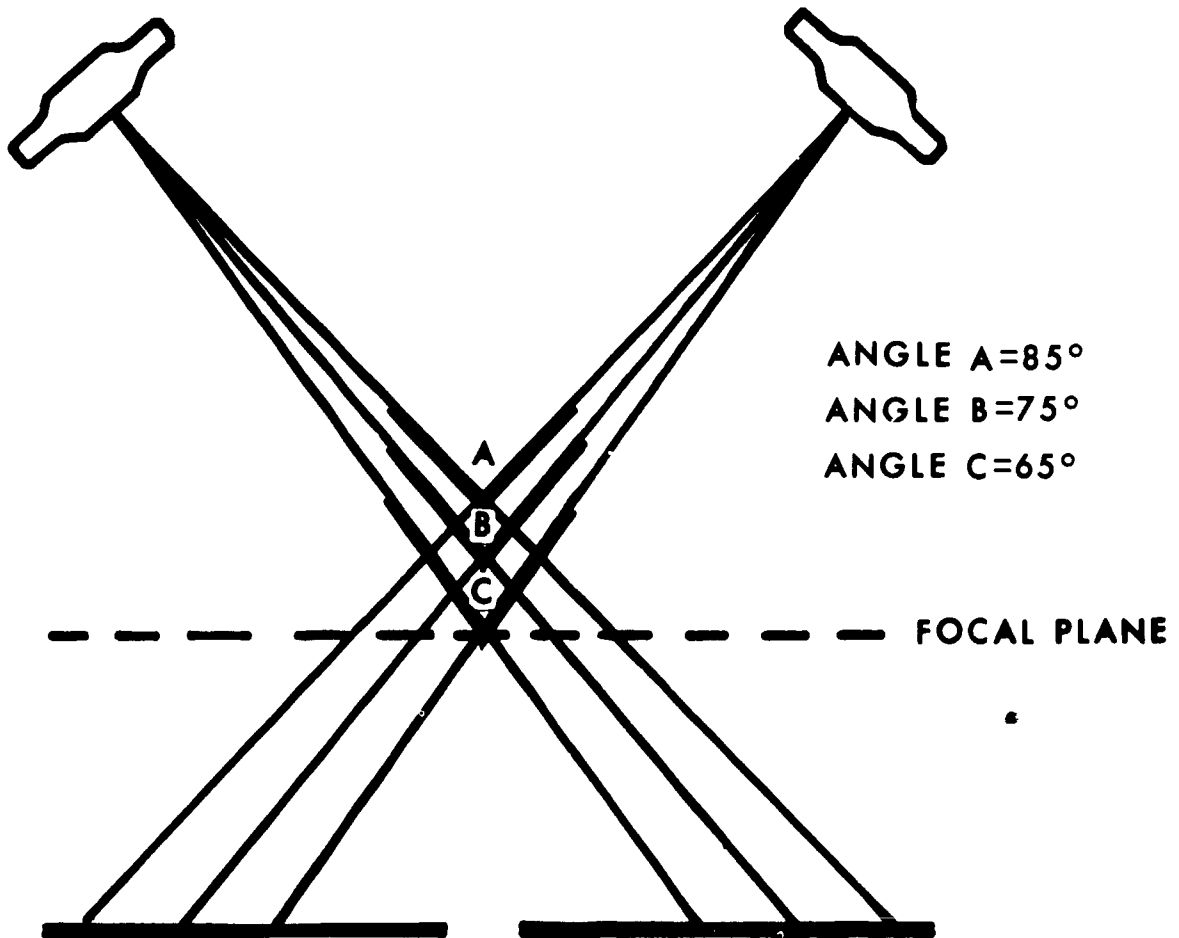


Figure 4-10 Effect of the distance of a structure from the focal plane on exposure angle and blurring

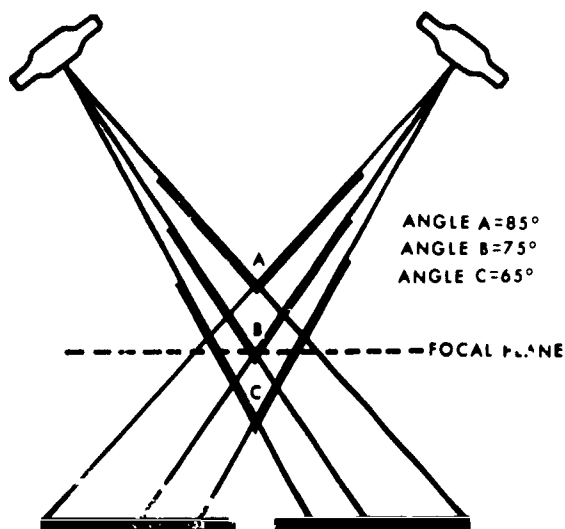


Figure 4-11 Effect of the distance of a structure from the film on exposure angle and blurring.

The top film in the book cassette demonstrates the section corresponding to the fulcrum you set on your machine indicator. The second film from the top demonstrates the level below the fulcrum; the third film demonstrates the third level, etc.

**Exercises (441):**

1. How many sections are radiographed simultaneously with a book cassette constructed with six intensifying screens?
2. Which pair of intensifying screens in a book cassette is the fastest? The slowest?

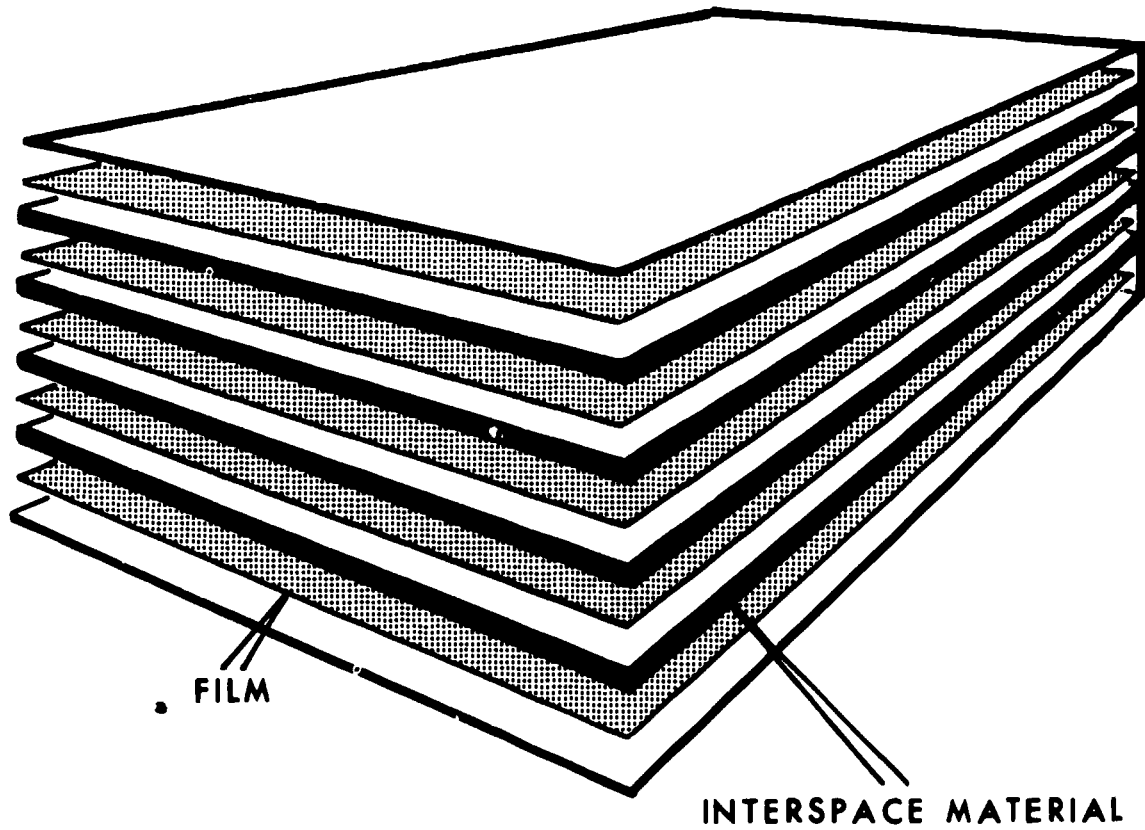


Figure 4-12. A book cassette.

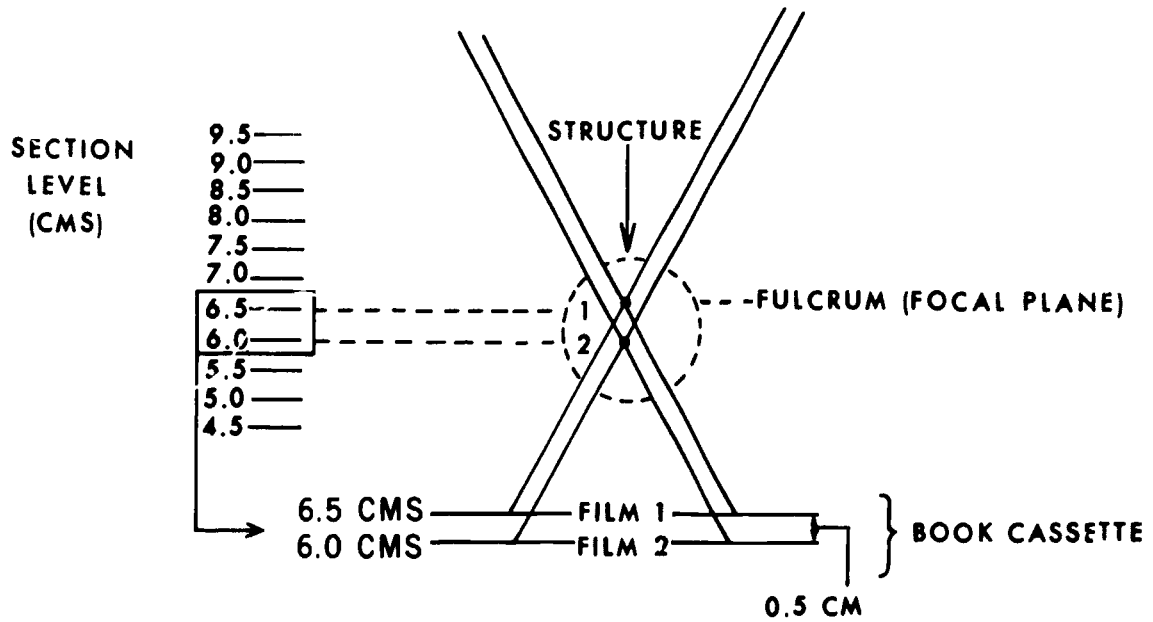


Figure 4-13. Principles of multisection radiography



3. Why do the speeds of the screens vary?
4. If a book cassette with 0.5 mm of interspace material is used, what is the width of the space between each cut?
5. Why does a book cassette record different sections?
6. If a book cassette containing five films and 1.0 cm of interspace material is used with a fulcrum setting of 15 cm, what level is demonstrated by the top film of the cassette? The bottom film?

**442. State the effects book cassettes have on X-ray tube loading, radiation exposure to the patient, image quality, and examination time.**

As is true in many areas of radiology, the use of multisection radiography versus single film tomography varies from one radiologist to another. Some radiologists use the book cassette regularly, while others do not use it at all. We will look at the advantages first and then the disadvantages.

**Advantages.** If you make five simultaneous cuts with a book cassette, the patient's dose is less than if you make five individual cuts. However, more exposure is required for a book cassette than for a single-film tomogram using a conventional cassette because the exposure for the book is determined by the speed of the top pair of screens, which is usually very slow.

The X-ray tube is subjected to fewer total heat units when a book cassette is used. Obviously, this reduction is due to

the single book exposure compared to the combined exposures needed for individual cassettes.

An advantage which has significance in a busy department is the overall reduction in examination time. As you know, using individual cassettes is time consuming because of the repetitive steps. Depending on the number of films there are in the book, many cuts are done at one time.

**Disadvantages.** The lower films in a book cassette reproduce less detail than do the upper films because of the variation in the intensifying screen speed. Since the lower screens are faster, detail is not as good.

The fact that the lower films also are subjected to more scattered radiation than are the upper films produces uneven film contrast from one film to another. Both the interspace material and the intensifying screens scatter photons that strike the films. So the bottom film receives the greatest number of scattered photons.

#### Exercises (442):

1. Why is the X-ray tube subjected to fewer total heat units when a book cassette is used?
2. If a three-film book cassette is used in lieu of three single cuts, is the exposure to the patient one-third as much? Why?
3. How does the use of the book cassette affect examination time?
4. List and explain how the book cassette degrades image quality.

#### 4-3. Exposure Factors and Positioning

In this section we will discuss the difference between conventional exposures and tomographic exposures of the same parts. We will also discuss the relationships between amplitude, rate, and exposure time in linear tomography. We will conclude this chapter with a brief discussion of tomographic positioning.

#### 443. Compare tomographic exposures with conventional exposures.

**Tomographic Exposures Versus Conventional Exposures.** A tomographic exposure normally should be greater than an exposure of a conventional radiograph, assuming that all other factors, such as projection, part, FFD, etc., are equal. We can best illustrate the reason for the difference with the diagrams in figure 4-14. Diagram A represents a conventional radiograph with a perpendicular CR, while diagrams B and C represent tomography with a small and a large exposure angle. Compare the different thicknesses through which the CR travels for each diagram. Obviously, the more tissue there is between the tube and the film, the greater the exposure required. As a general rule, exposure angles between 20° and 25° require approximately a 50 percent increase in mAs. Zonographic angles require nearly the same mAs, and wide (25° and up) exposure angles require about 100 percent more mAs. The kVp can be regulated as well as the mAs to compensate for the increased thickness.

#### Exercises (443):

1. If 100 mAs is used for a conventional radiograph, what mAs should be used to tomograph the same part using a 20° exposure angle?

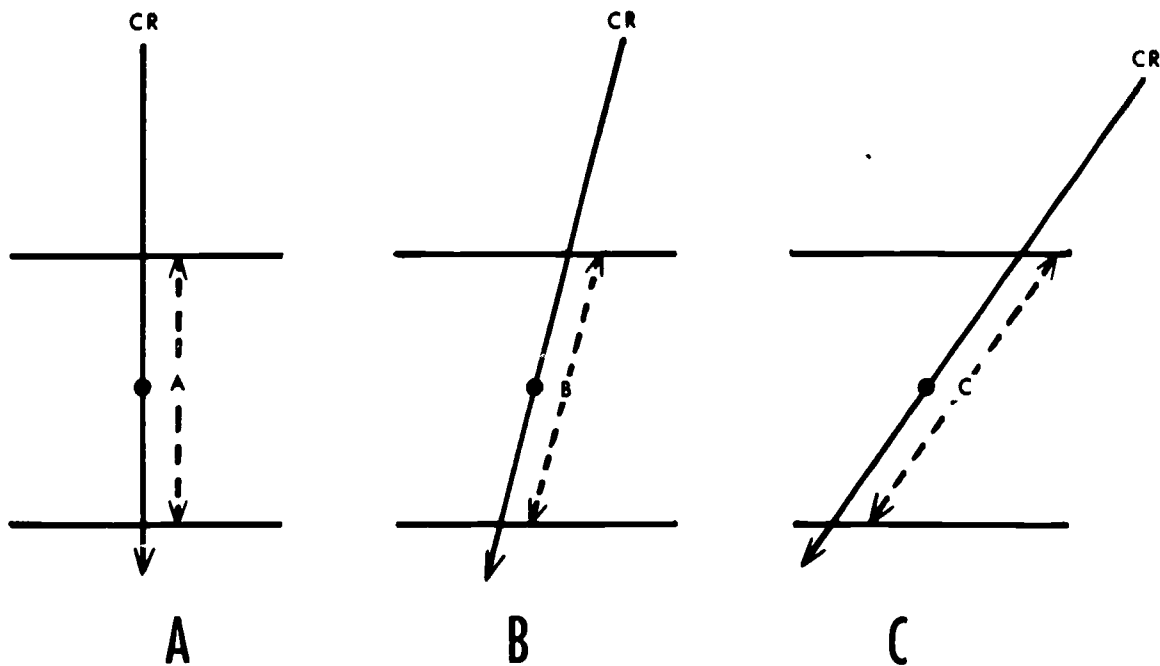


Figure 4-14 Comparison of structure thickness between conventional radiography, small and large angle tomography

2. If 50 mAs is used for a conventional radiograph, what mAs should be used to tomograph the same part using a 40° exposure angle?
3. Why is more exposure required for tomography with a wide exposure angle than for zonography?

a = amplitude in inches

r = rate of tube travel in inches per second

For example, if the amplitude is 15 and the rate is 10, the exposure time is 1.5 seconds since

$$\begin{aligned} \text{sec} &= \frac{a}{r} \\ &= \frac{15}{10} \\ &= 1.5 \end{aligned}$$

**444. Find the amplitude, rate, or exposure time for linear tomography when other factors are known.**

**Amplitude, Rate, and Exposure Time.** In pluridirectional tomography (circular, elliptical, etc.), the amplitude, rate, and exposure time are automatically determined when a particular movement is selected. With many linear tomographic attachments, you must determine these factors.

The three formulas for determining the factors are:

$$\begin{aligned} \text{sec} &= \frac{a}{r} \\ a &= r \times \text{sec} \\ r &= \frac{a}{\text{sec}} \end{aligned}$$

where:

sec = exposure time in seconds

**Exercises (444):**

Find the factor (amplitude, rate, or exposure time) missing from each exercise below.

1. Amplitude; 12 inches.  
Rate: 4 inches per second.
2. Rate: 2 inches per second.  
Sec: 4.

3. Amplitude: 20 inches.  
Sec: 4.

**445. State how parts should be positioned for tomographic examination.**

**Positioning.** For maximum blurring of unwanted structures, the X-ray tube should travel at right angles to the structure's longitudinal axis. Pluridirectional tube movements blur these structures effectively because the tube moves in many directions and in most cases crosses the longitudinal axis.

Since the tube moves in one direction only in linear tomography, the patient must be positioned, when possible, so the longitudinal axis of the parts to be blurred are at right angles to the tube movement. Such a position is not always possible, as we see in the following example.

If you do a PA tomogram of the sternum and position the patient as shown in figure 4-15,A, the longitudinal axis of the thoracic spine is in the same direction as the tube travel; consequently, the spine is not effectively blurred. If you position the patient as seen in figure 4-15,B, the spine is blurred because it is correctly oriented to the tube travel; but the longitudinal axis of the ribs are in the same direction as the tube travel; the ribs are then not effectively blurred. The solution is to position the patient at a 25° to 35° angle on the table (fig. 4-15,C).

**Exercises (445):**

Indicate whether the following statements are true (T) or false (F). If you indicate "false," explain your answer.

- \_\_\_ 1. Pluridirectional tube movements produce better blurring than does a linear movement
- \_\_\_ 2. Patient positioning is important with linear tomography.
- \_\_\_ 3. For maximum blurring, a part's longitudinal axis should be positioned at a right angle to linear tube movement.
- \_\_\_ 4. The sternum should not be positioned at a right angle to linear tube movement.

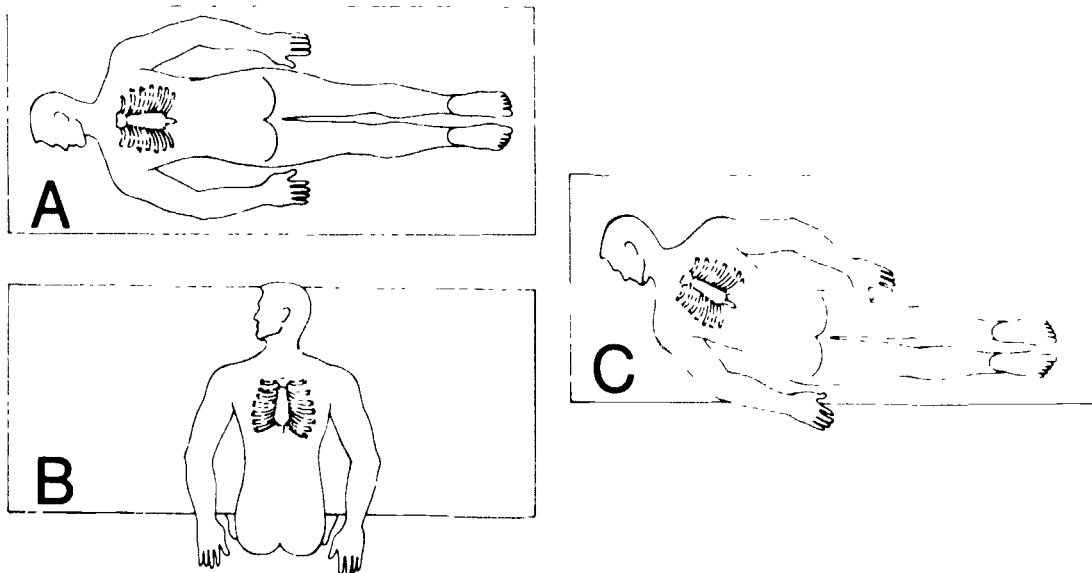


Figure 4-15 Correct and incorrect patient positions for tomography of the sternum

# Computed Tomography

COMPUTED tomography is perhaps the most significant discovery in this field since Roentgen discovered X-rays in 1895. In the last few years it has been called computerized axial tomography (CAT), computerized transverse axial tomography (CTAT), reconstructive tomography (RT), and computerized tomography or computed tomography (CT). Computed tomography is the term that has been accepted to identify this new diagnostic tool.

CT has not been in use very long. The first CT head scanner was installed at Atkinson Morley's Hospital, London, England in 1971. The Mayo Clinic and Massachusetts General Hospital obtained the first units for the U.S. in 1973. The first whole-body scanner was installed at Georgetown University Medical Center in 1974. Since then CT has gone through many improvements, though the fundamentals remain the same.

In this chapter we cover those fundamentals and look at some of the improvements. We also look at some general CT applications.

## 5-1. Basic Computed Tomography Physics

The study of physics is essential to learning various technical and complex special procedures. In this section, we look at what CT is and its principles of operation.

### 446. State the operating principles of computed tomography.

**Principles of Operation.** By definition, computed tomography is the process of creating a cross-sectional tomographic plane (slice) of any part of the body. This reconstructed image is created by a computer using X-ray absorption measurements collected at multiple points about the part's periphery.

The CT scanner differs from routine radiography in that it does not record an image in the conventional way. There is no image receptor (such as film), image intensifier tube, or a xeroradiography plate in a CT scanner.

Simply stated, a collimated X-ray beam is directed on a patient and the attenuated remnant radiation is measured by a detector. The detector creates an electronic signal that is directly proportional to the intensity of the remnant radiation. This signal is sent to a computer where it is analyzed and converted into a numerical value of density. Finally, the information generated by the computer is converted into a form that can be used to produce a visible image on a television screen. More of this process will be covered in detail later in this chapter when each system component is explained.

### Exercises (446):

1. How does computed tomography work?
2. What role does remnant radiation have in the CT process?
3. What basic difference exists between CT imaging and conventional methods of radiology?
4. What device creates an electrical signal?

### 447. Differentiate between conventional radiography and computed tomography.

**Comparison of CT to Conventional Radiography.** Comparing CT to conventional radiography helps explain the value of CT. When a conventional X-ray exposure is made, remnant radiation from the patient is detected by X-ray film or an image-intensifier phosphor. This produces one diagnostic image with fixed density and contrast for each exposure. Also, all body structures are superimposed on each sheet of X-ray film. Thus, to show certain anatomy calls for exact positioning, often the use of contrast media, and usually multiple exposures.

Low tissue density that would usually be obscured by higher density anatomy on a conventional radiograph can be clearly visualized with CT. This is why CT is excellent for demonstrating the brain, as shown in figure 5-1. A conventional radiograph of the skull is of little value in trying to visualize the brain because the high-density cranial vault obscures low density brain tissue. On this same line of thought, CT can see more minute differences in X-ray attenuation than can be recorded by conventional radiography. For example, conventional radiography needs a minimum difference in tissue density of 2 to 5 percent to separate structures. CT can show adjacent structures that have a difference in tissue density as low as 0.5 percent. This makes CT an excellent tool for showing contrast differences of soft tissue structures within the brain and abdomen. Figure 5-2 shows different structures that are commonly seen on an abdomen scan.

Because a CT image shows the entire cross section of a slice of anatomy, the size and location of a pathologic condition can be seen accurately. Conventional radiography often needs contrast media and multiple exposures to estimate the size and location of a diseased area.

Another advantage that CT has over conventional radiography is that the image can be manipulated. Conventional radiography produces a single radiograph with fixed contrast, density, and part size for each

exposure. To get another image, the patient must be irradiated again and another film processed. The CT image is stored in the computer memory and can be altered in various ways when it is displayed on a cathode ray tube. For example, a CT operator can adjust the density and contrast of the image, and have the computer magnify the image. Furthermore, some units have the ability to demonstrate a sagittal and a coronal reconstructed image of the neck and upper thorax from data obtained from various contiguous transverse slices with no additional exposures. This process produces a lateral or anterior-posterior tomographic plane similar to conventional tomography.

**Limitations of CT.** We have listed many advantages of CT, but it also has some limitations. The first that comes to mind is the time it takes to perform a single examination. Most exams take 15 to 30 minutes, sometimes longer, so that only 15 to 20 exams can be done in a 8-hour day.

Another major drawback is its use in studies involving the mechanics of motion (dynamic studies), such as cerebral angiography or aortography. Recent models of CT scanners can obtain a slice of anatomy in as little as one second, then the table is indexed and the next slice is taken. Thus, a considerable amount of time is needed to image a large anatomical area. Conventional radiography with rapid film changers would be better suited for dynamic studies.

Another limitation of CT compared to conventional radiography is its ability to resolve small objects. If there is sufficient contrast conventional radiography can resolve objects as small as 0.1 mm; CT can only resolve anatomy larger than 1 mm.

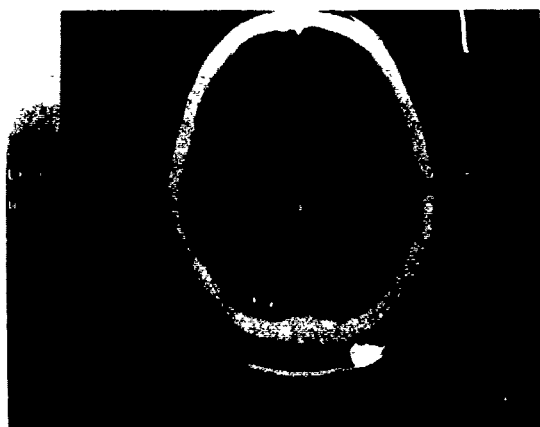

Figure 5-1 CT scan of a brain showing good tissue differentiation

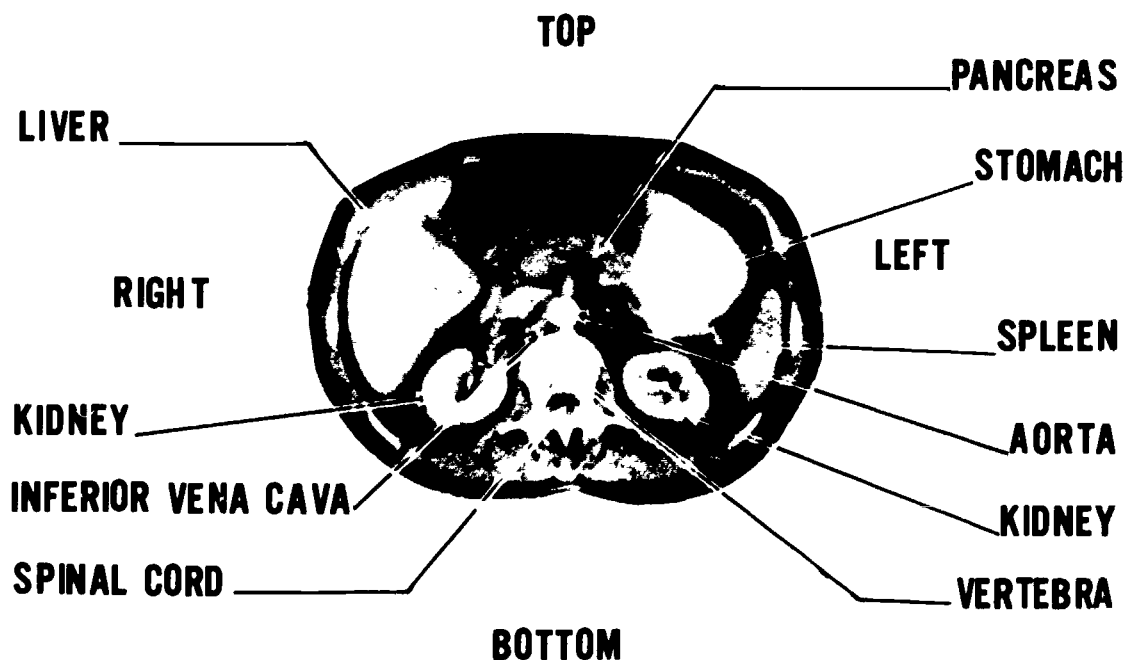


Figure 5-2 Abdominal structures commonly seen on a CT scan

### Exercises (447):

1. Match each characteristic in column A with the system in column B. Each column B item may be used more than once.

Column A	Column B
_____ (1) Preferred for demonstrating brain tissue	a Conventional radiography
_____ (2) Preferred for demonstrating arteries of the brain	b Computed tomography
_____ (3) Can show a tissue density difference of 0.5 percent	
_____ (4) Allows for image manipulation	
_____ (5) More exams per time element can be done with this system	
_____ (6) Best for dynamic studies	
_____ (7) Best for showing small objects	

### 5-2. System Components and Categories of Scanners

In this section we apply the basic physics of CT to various components of a CT scanner. Then we see how the three main components—the gantry, the computer, and the control console—relate to each other's functions. Finally, we examine major differences found in scanner generations.

#### 448. Specify the purpose or characteristics of the subsystems of the gantry assembly.

**The Gantry Assembly.** The gantry assembly includes the X-ray tube, the detector array, the high-voltage generator, the patient support and positioning couch, and the mechanical support for each. These subsystems receive electronic commands from the operating console and transmit data to the computer for analysis and image production. Thus, these components are called the *data acquisition system (DAS)*.

**X-ray tube.** X-ray tubes used in CT units have special requirements. The anode heating capacity must be at least 400,000 heat units. Some tubes designed just for CT work can accommodate one million heat units. High-speed rotors are used to help dissipate the heat. X-ray tube failure is a principle cause of scanner malfunction and is the primary limitation in doing frequent multiple exposures.

Focal-spot size is relatively unimportant in most designs because a scanner does not operate on principles of direct geometric imaging.

**Detector assembly.** The very sensitive detectors used in CT sense remnant X-rays and transmit an output signal to the computer. While early CT scanners used only one detector, later units use anywhere from 10 to 1,000 detectors packed tightly together in an array.

There are two categories of detectors: scintillation and gas; scintillation detectors are the most common. Each scintillation detector consists of a crystal-photomultiplier tube assembly. The crystal, usually sodium iodide, emits a flash of light when irradiated. Each flash of light is directly proportional to the amount of radiation that is incident to the detector. These light flashes are changed into electrical

impulses by the photomultiplier and transmitted to the computer.

Gas-filled detectors (simply called *gas detectors* in CT jargon) have a large chamber with baffles spaced at about 1 mm intervals. These baffles are like grid strips and divide the large chamber into many small chambers. Each small chamber acts as a separate radiation detector. The entire unit is filled under pressure with a high atomic number gas, such as xenon, and then sealed. When irradiated, the gas releases electrons that produce an electrical impulse through an electrode.

**High-voltage generator.** All CT scanners operate off 3-phase power. This accommodates the higher X-ray tube rotor speeds and instantaneous power surges characteristic of pulsed systems.

**Patient support and positioning couch.** The patient couch (more like a positioning table) not only must support the patient comfortably, but it must be built of a low atomic number material that will not interfere with X-ray beam transmission. It should be smoothly and accurately motor driven so that the patient can be positioned precisely. The couch should be capable of indexing automatically so that the operator does not have to enter the room between slices. This feature reduces the examination time because the table automatically advances the patient for each slice.

### Exercises (448):

1. What are the four major subsystems of the gantry assembly?
2. Why is the gantry assembly called the *data acquisition system*?
3. What are two requirements of an X-ray tube that is to be used in a CT unit?
4. What device of a gantry assembly is the principle limitation to doing frequent multiple exposures?
5. What two types of detectors are used in CT units?
6. What is the purpose of a detector?

7. Briefly describe the function of the crystal and the function of the photomultiplier of a scintillation detector.
8. List four characteristics of a good patient support and positioning couch.
9. What feature of the patient support and positioning couch helps reduce examination time? Explain.

**449. Explain how a CT computer operates.**

**The Computer.** The computer is a unique subsystem of a CT scanner. It receives and analyzes data from the detector array system and data acquisitions electronics. Using this accumulated data, the computer begins a series of complicated mathematical equations called *algorithms*. It considers the linear attenuation coefficient for each section of the slice.

A linear attenuation coefficient is a numerical value that indicates how much the X-ray beam is attenuated by a particular part of the body at a particular kVp level—a physical quantity used for differentiating tissues. For example, at a low kVp, body structures attenuate the beam more than they do at a higher kVp when the beam is hardened. So at a lower kVp, each structure or tissue has a higher linear attenuation coefficient than it would have if the kVp level were raised. This is shown in figure 5-3. Notice that the coefficient value for each tissue type increases with the atomic density of the tissues. In other words, bone, which greatly attenuates the beam, has a higher attenuation coefficient than fat, which attenuates the beam less. From these linear attenuation coefficients the computer assigns a CT number to each section of the image.

The CT number for each section of the image is transformed into a level of density on a video screen during image reconstruction. At this point the electronic and mathematical data becomes an image.

The CT image is made up of several components. The first of these is the *matrix*—an array of numbers arranged in rows and columns. Each CT number corresponds to an element (or cell) of a matrix. Figure 5-4 shows three matrices. The CT scan image format consists of imaginary cells, each assigned a CT number and displayed as a density or brightness level on the video monitor. The most common matrices used in CT scanning are 160 by 160, 256 by 256, 320 by 320, and 512 by 512.

Each of these imaginary cells is called a *pixel* (picture element). The pixel is a two-dimensional representation of a corresponding tissue volume (see fig. 5-5). Associated with a pixel is a *voxel* (volume element). The voxel is the area of a pixel multiplied by the thickness of the slice (see fig. 5-5).

Each pixel is displayed on the video monitor as a level of brightness and on the photographic image as a level of optical density. These levels correspond to a range of numbers from -1000 to +1000 for each pixel (fig. 5-6).

Tissue	Linear attenuation coefficient (cm <sup>-1</sup> )		
	60 keV	84 keV	122 keV
Air	0.0004	0.0003	0.0002
Fat	0.185	0.162	0.144
Water	0.206	0.180	0.160
CSF	0.207	0.181	0.160
Blood	0.208	0.182	0.163
Gray matter	0.212	0.184	0.163
White matter	0.213	0.187	0.166
Dense bone	0.528	0.460	0.410

Figure 5-3 Linear attenuation coefficients for various tissues at different kVp levels

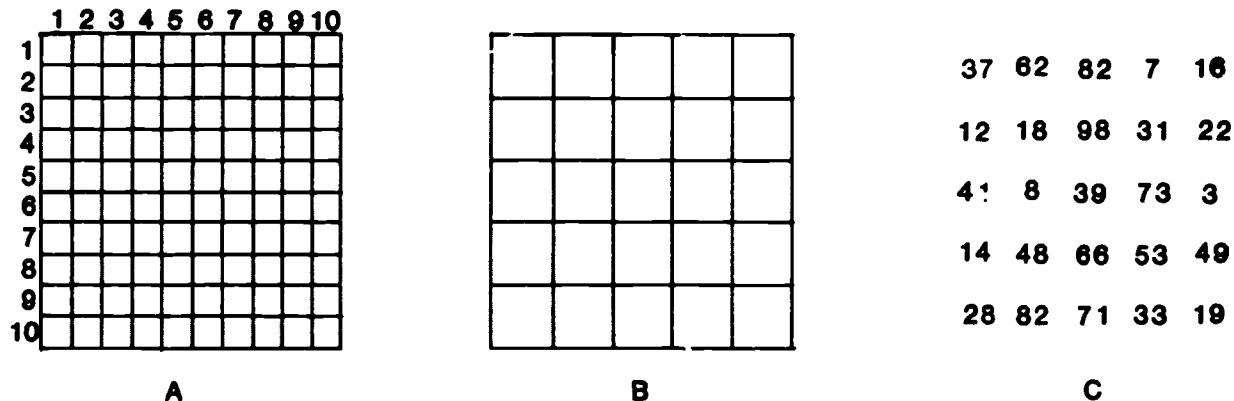


Figure 5-4 Three matrices

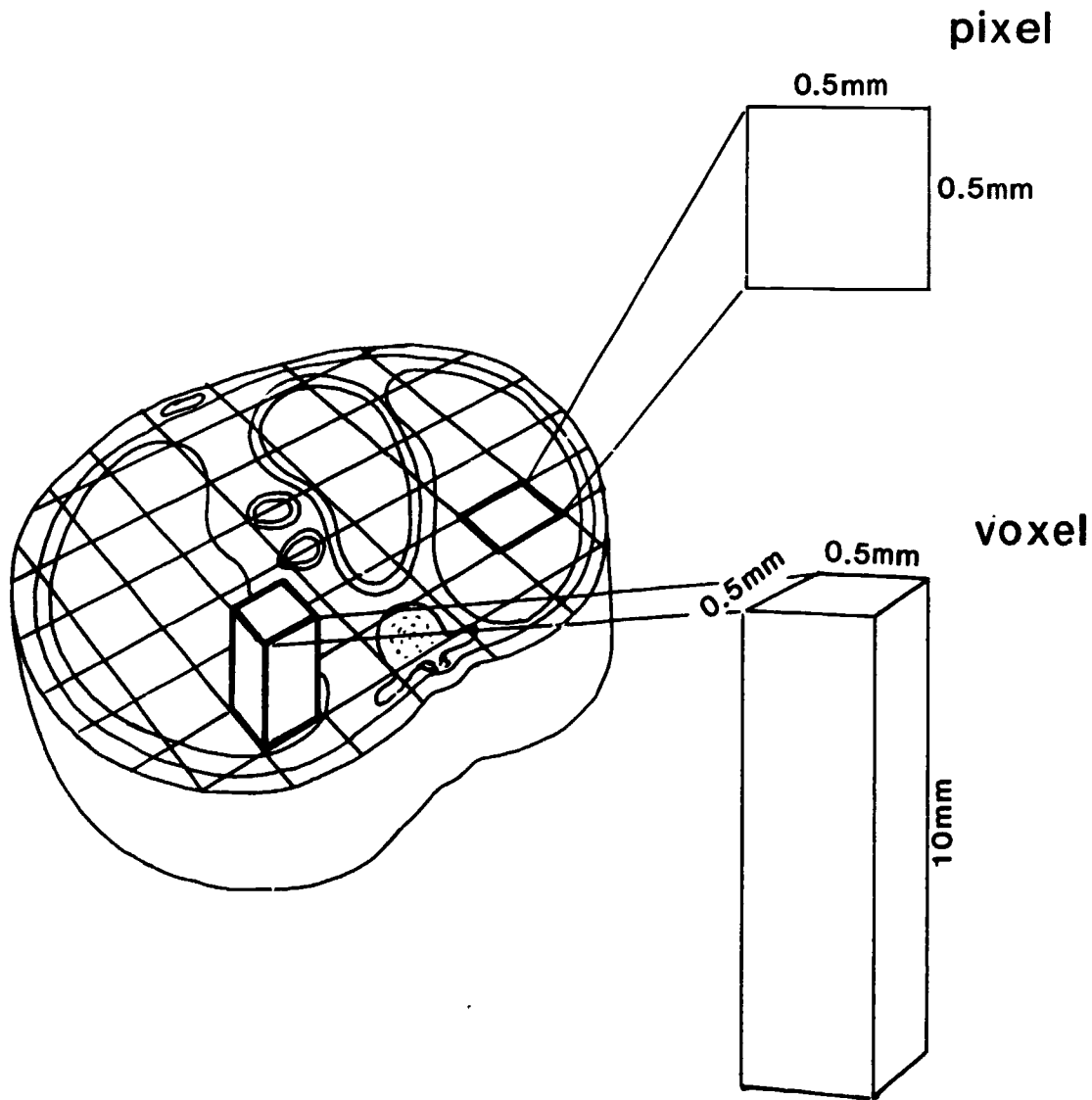


Figure 5-5. Graphic representation of a pixel and a voxel from a CT slice

Tissue	CT number
Air	-1000
Fat	-100
Water	0
CSF	15
Blood	40
Gray matter	43
White matter	46
Dense bone	1000

Figure 5-6. CT numbers for air and various tissues

Notice that air has a CT number of  $-1000$  and that bone has a value of  $+1000$ . Each CT number relates to the linear attenuation coefficient of the tissue contained in the voxel, and indicates a particular shade of gray for each pixel of the image. The computer sorts out all this data and arranges the shades of gray to form an image.

**Exercises (449):**

1. List four operations of a CT computer.
2. Define "linear attenuation coefficient."



3. How is a linear attenuation coefficient for a particular structure affected by kVp changes?
4. How does the atomic density of various tissues affect linear attenuation coefficients?
5. Define "pixel."
6. Define "voxel."
7. What numerical information is assigned by the computer to each pixel?
8. Explain the purpose of a CT number.
9. Which has a higher CT number value, fat or blood? Explain your answer.

#### 450. Specify functions of CT control consoles.

**CT Control Consoles.** Many scanners have with two consoles, one for the technician to operate the unit and one for the physician to view the scan image and change its contrast, size, and general visual appearance. The operator's console has meters and controls to select proper radiographic technique factors, to the gantry and patient couch, and to make computer commands for image reconstruction and transfer. The physician's viewing console retrieves data from the computer and allows display of an image for viewing, manipulation, and diagnosis.

**Operator's console.** A typical operator's console contains controls and monitors for kVp and mA. The kVp controls are usually set above 100 kVp. The mA station used depends upon the type of beam employed. That is, a low mA station (20 to 50 mA) should be used if the X-ray beam is continuous. Several hundred mA may be used if it is a pulsed beam. A typical technique for a continuous beam may be 120 kVp at 50 mA. Scan time (length of time required per scan slice) is often selectable and falls within the range of 1 to 10 seconds with the faster units.

The operator can also adjust the thickness of the slice. Most units offer a slice thickness of 1.5 mm, 5 mm, or 10 mm (1 cm). Selecting a slice thickness from the console produces an automatic collimator adjustment at the X-ray tube. The thinner cuts require an increase in radiographic

technique because collimation reduces exposure to the patient, decreasing detectable remnant radiation.

The operator's console will have one or two cathode ray tube (CRT) monitors that allow the computer to reconstruct electronic data into a video image. One monitor allows an operator to show patient data on the scan (hospital identification, name, SSN, age, sex, etc.) and to identify each scan (scan number, technique, couch position, etc.). The second video screen might be used to view an image before it is transferred to a permanent image format.

**Physician's viewing console.** This console is essential in a department that has a high workload and fully utilizes the CT system. It allows a physician to review and manipulate any previous image for maximum information without interfering with scanner operations. For example, a physician can adjust contrast and density, view the region of interest, and magnify the image.

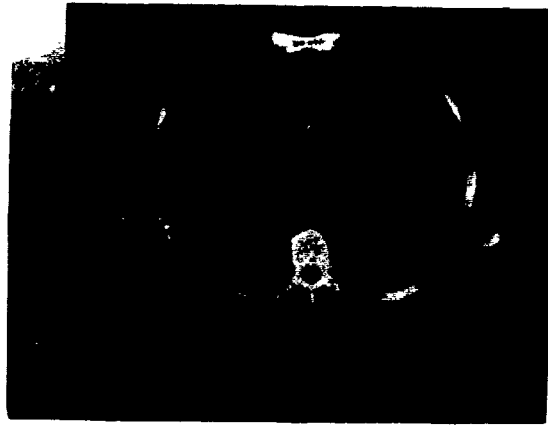
Contrast and density (brightness) are looked on in a CT image much the same as they are in a radiograph. The main difference with CT is that you can change its contrast and density after the exposure is made by adjusting the *window* and the *level*. The window is used to set the number of CT numbers you want to show on the reconstructed image. The anatomy you are scanning helps determine where the window will be set. For example, in viewing heads or anatomy where the range of CT numbers is limited, the window may be lowered for greater contrast. Brain scan images use a low window number to give a short scale of contrast. On the other hand, body scans have many similar densities within its structures and so have a wider range of CT numbers. These would use a higher window to show low contrast, or a long scale contrast of many densities (shades of grays). In other words, an increase in the window number gives you an increase in the number of grays and, of course, vice versa. The level control sets the CT number that applies to the mid-portion of the gray scale to control the overall density of the image and is used in conjunction with the window. As you increase the level, you increase the density, which makes the image darker.

The two CT scans of a chest in figure 5-7 show how changes in the window and the level alters contrast and density. These scans show the same anatomical slice, but look different. Scan A has a low level number (-503) and a high window number (1000). This low level produces a light image density and the high window shows a long scale contrast needed to visualize vascular markings of each lung. Scan B has a high level (+7) which causes the overall density of the image to be darker, and a low window (500) to create a short-scale contrast. In this scan, the short-scale contrast is needed to show greater contrast of heart tissue and structures outside the rib cage.

Each console can be electronically connected to its own computer so that stored images can be reviewed. Image data is temporarily stored on the computer's magnetic disk pack (disk module) which speeds information retrieval from either the operator's control console or the physician's viewing console. This data is stored permanently on either *floppy magnetic disks* or *magnetic tapes*. A disk stores data from a single patient and may be placed in the patient's file



A



B

Figure 5-7 Two CT scans showing differences in image contrast and density because of changes in level and window settings

with other reports and film. Magnetic tapes can store data from 150 scans, or 10 to 20 patients.

A permanent visual image can be recorded in one of two ways. Some units may have an instant camera to record an image from the video screen. Probably the most favored image recorder is the multiformat camera which records as many as 11 images on a single piece of 14- by 17-inch x-ray film.

#### Exercises (450):

1. Describe the kVp range and mA stations that may be used for CT procedures.
2. What are three slice thicknesses that are available on most CT units?
3. How should radiographic technique be adjusted if you are changing slice thickness from 1 cm to 1.5 mm? Why?
4. Why should a department that has a high CT workload have a physician's viewing console?
5. List three adjustments that can be made at the physician's viewing console.
6. What CT console control adjusts image contrast?
7. What CT console control adjusts image density?
8. What effect on the image results when the level control is increased?
9. What are the two ways to store an image within the computer's memory?
10. What are the two ways to record a permanent CT image?

#### 451. Differentiate among first-, second-, third-, and fourth-generation scanners.

**Categories of Scanners.** CT scanners are often identified best in terms of their geometry and detector array (number of detectors). Sometimes they are also described by their *generation*. Generation is a term used in technical fields to denote an improvement or change in model. In some cases generation can be used to signify an improvement in capability and, therefore, an improvement in quality. To date, CT scanners can be broken down into four generations.

**First-generation scanner.** A basic configuration was used with first-generation scanners. It consisted of an X-ray tube that was connected mechanically to a detector array. The detector array consisted of two scintillation crystal detectors (some had only one) coupled to a photomultiplier. The X-ray beam was collimated to a pencil beam measuring about 2 by 16 mm.

The scanning motion consisted of *translation* and *rotation*. Translation means to move without a change in angulation; rotation means to change angulation. The X-ray tube/detector array assembly thus moves directly across the body part (see fig. 5-8); it then indexes one degree and repeats the translation, rotates one degree and translates again, and so on until it transverses  $180^\circ$  of angulation. Figure 5-9 shows this translation/rotation process. During this period, the detector array senses the remnant radiation and sends electronic signals to the computer.

These first-generation scanners offer accurate data readings for reconstructing images. This is due to its geometry—specifically one degree rotations. The principal drawback to these units was the three to five minutes required to complete one scan.

**Second-generation scanner.** A second-generation of scanners was developed that would reduce the scanning time. The second-generation scanners use a fan-shaped beam rather than the pencil beam of the first scanners (fig. 5-10). Multiple scintillation detectors are mechanically connected to the tube head assembly for proper movement. The translation/rotation movement of the first-generation units is also used in second-generation units.

The major advantage to the second-generation scanner is speed. A single translation with the fan beam and multiple detector array gives the same number of data points as several translations with a first-generation scanner. Also, each translation is separated by rotation increments of five degrees or more. This means that fewer exposures are

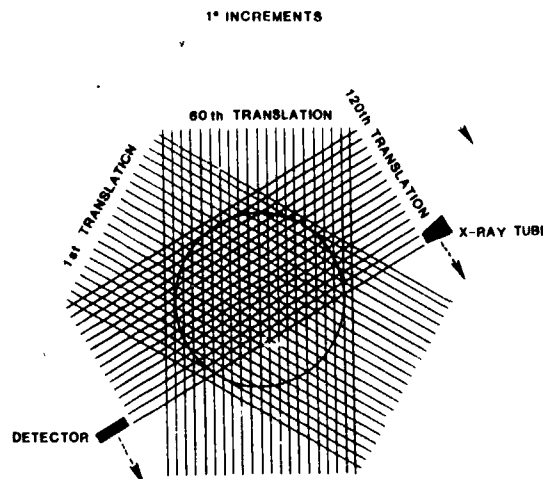


Figure 5-9 Translation and rotation movements of a first-generation scanner

needed for a  $180^\circ$ -scan. Scanning times are 10 to 18 seconds per slice. Although the reduced scanning time is a significant improvement over the first scanner, it does not prevent artifacts due to peristalsis, vascular pulsations, or respiratory motion (unless the patient can hold his or her breath). Unfortunately, the fan beam increases the overall radiation exposure to the patient and the amount of scatter radiation, which can affect the final image in much the same way as in conventional radiography.

**Third-generation scanner.** A third-generation unit further reduces examination time through its  $360^\circ$ , rotation-only movement. This category of scanner uses a curvilinear detector array of at least 30 xenon (gas) ionization chambers and a fan beam. Both the number of detectors and the width of the fan beam, between  $30^\circ$  to  $60^\circ$ , are substantially larger than for second-generation scanners.

In third-generation scanners the fan beam and detector array view the entire patient slice thickness at all times. In the second-generation unit equipped with a linear detector array, the X-ray path length is shortest for the central detector and increases in length as one moves to the periphery of the detector array. The curvilinear detector array gives a constant source-to-detector path length, which is an advantage for good image reconstruction. This also allows for better X-ray beam collimation to reduce the effect of scatter radiation. This type of collimation is called *predetector collimation*, and it functions like a radiographic grid in conventional radiography. Predetector collimation does *not* eliminate the need for prepatient collimation, which restricts patient dose. Figure 5-11 compares linear and curvilinear detector arrays.

The major advantage of third-generation scanners is that they reduce scanning time to one second. A major disadvantage is the occasional appearance of ring or circular artifacts caused by a malfunction of a single detector or bank of detectors.

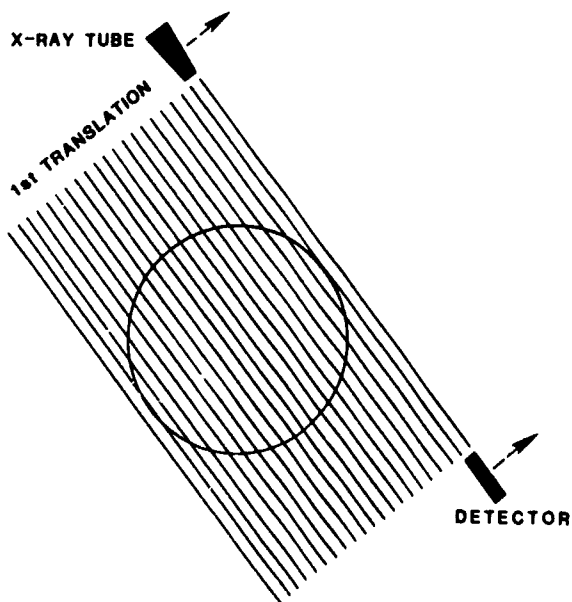


Figure 5-8. Translation movement of a first-generation scanner

**Fourth-generation scanner.** Like the third-generation scanner, the fourth-generation scanner uses a fan beam and a rotation-only motion. However, in this unit only the X-ray tube rotates; the detector array is stationary. In this machine, remnant radiation is detected by a fixed circular array fig. 5-12 that may hold as many as 1000 individual elements. This geometry gives fourth-generation scanners excellent imaging reconstruction and exposure times as low as 1 second. Major disadvantages are the high patient radiation dose and the high initial cost of the unit.

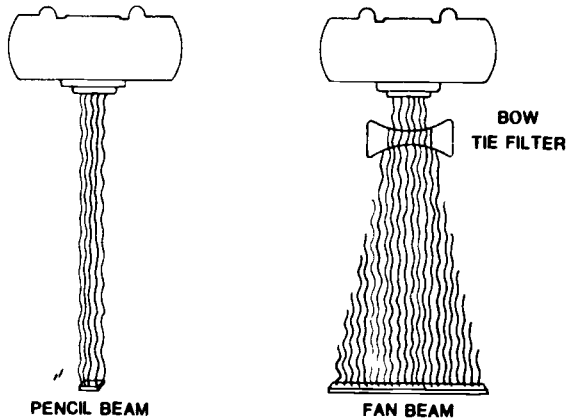


Figure 5-10 Graphic representation showing the difference of a pencil beam and a fan beam.

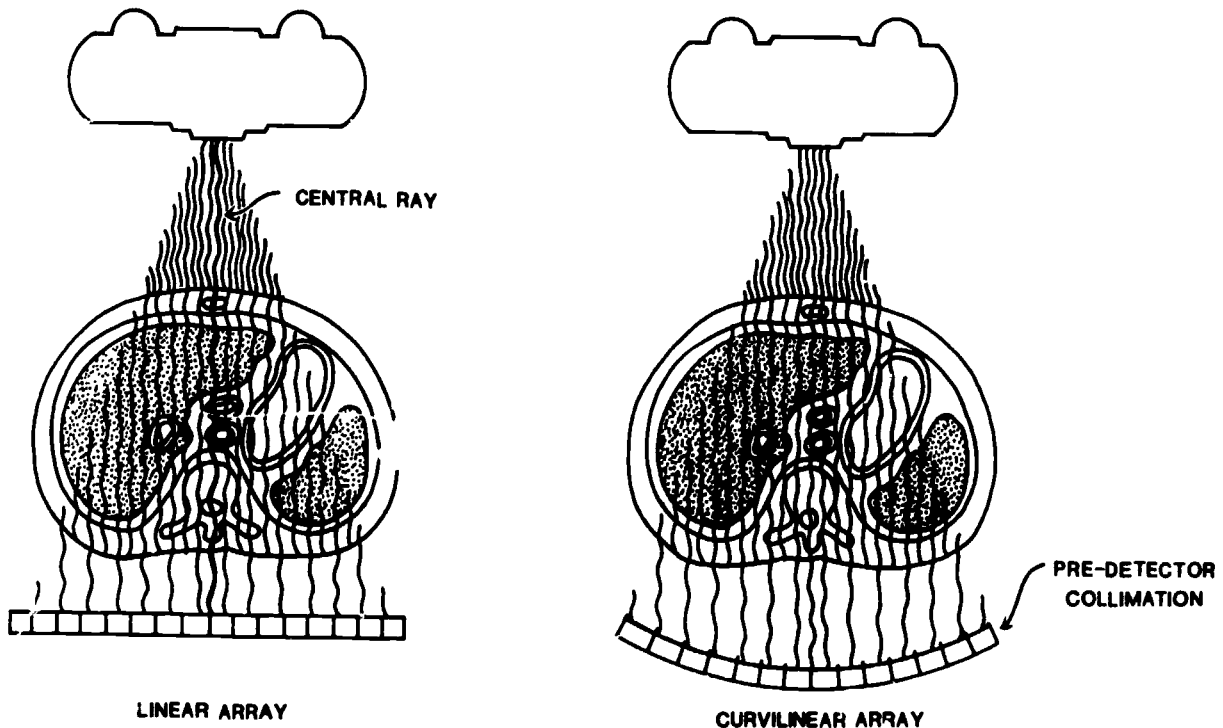


Figure 5-11. Graphic representation of the difference between a linear array and a curvilinear array

### Exercises (451):

- Match the characteristic of column A with the scanner that it applies to in column B by placing the letter from column B in the space provided in column A. Each column B item may be used more than once. Each column A item may or may not require two choices from column B.

#### Column A

- (1) Uses a 360° rotation-only movement
- (2) Its detector array remains stationary.
- (3) Has only one or two detectors
- (4) Uses translation-rotation movement.
- (5) First unit to reduce scanning time to one second.
- (6) Uses a "pencil-shaped" beam
- (7) Scan time is 3 to 5 minutes for one scan.
- (8) First unit to use a "fan-shape" beam.
- (9) Has the most detectors.
- (10) First to use a curvilinear array

#### Column B

- a First-generation scanner
- b Second-generation scanner
- c Third-generation scanner
- d Fourth-generation scanner

### 5-3. CT Examination Procedures

Because of the many variables that determine step-by-step procedures for doing CT examinations, we cannot list a sequence for particular studies. This section gives general guidelines that should be used in conjunction with SOPs and preferences of the radiologists in your department.

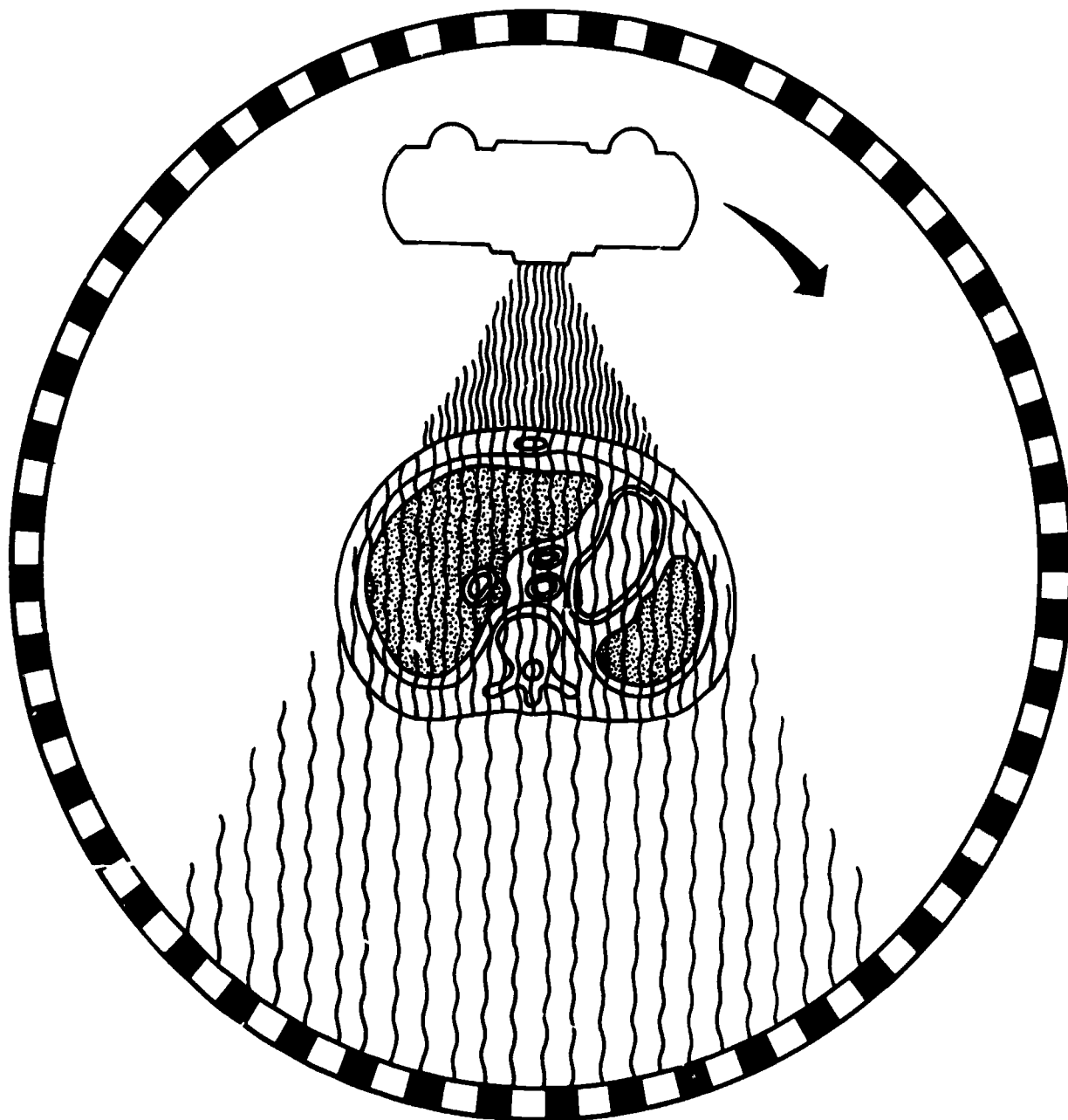


Figure 5-12 Fourth-generation CT scanner movement (rotation-only motion with a fixed-circular array)

**452. Specify patient preparations and use of contrast media for CT examinations.**

**Patient Preparation.** In most departments your first contact with the patient is when an appointment is requested. At that time you are able to give a patient a brief explanation of the examination and whatever preparation steps the patient may need to follow before arriving for the CT procedure. The patient preparation for most CT examinations is minimal and varies according to the type of CT examination and the radiologist's preference.

Generally, the following preparations are used for the scans listed:

- a. Brain scans—Without contrast, no preparation; with contrast, NPO at least 4 hours before the examination.
- b. Abdomen and pelvis scans—NPO after midnight; if an afternoon appointment is set up, a clear liquid breakfast may be permitted. If the patient had any barium GI study done in the last day or so, a standard bowel preparation may be preferred to remove any residual barium that could cause artifacts.
- c. Chest and extremity scans—No preparation.

**Contrast Media Use in CT.** Contrast media enhance specific areas to better show tissue differentiation. This often helps a radiologist to distinguish between normal anatomy and pathologic tissues. Whenever a scan uses contrast media, the patient will usually be NPO prior to the exam. This will help prevent vomiting if the patient should feel nauseous during administration of contrast media.

Contrast media may be administered intravenously or orally, and sometimes by both methods for some examinations. Intravenous contrast media used for CT are the same used for excretory urography. Almost all head (brain) scans and abdomen scans will use a common iodinated injectable. Usually these exams begin with slices made without contrast media; then the patient positioning couch is repositioned, the patient receives a drip-infusion and the scan is repeated. Some abdomen scans do not use an injectable agent. For example, some GI studies use a special barium solution that is weaker than the routine upper GI solution but is still administered orally. CT scans of the lumbar spine that are done to rule out herniated disks do not require contrast agents.

#### Exercises (452):

1. What patient preparation may be required for a brain scan with contrast media? Why?
2. A ward patient who just had a barium enema and IVP needs an abdomen scan. What patient preparation is required in this case? Why?
3. Why is contrast media used for various CT examinations?
4. What are two methods of administering contrast media for CT examinations?

#### 453. State determining factors and characteristics of patient positioning during CT procedures.

**Positioning the Patient.** When he or she arrives for the appointment, the patient gets gowned and, again, should be briefed on the examination. Then the patient is positioned for the scans.

Patient positioning is determined by the desired plane of anatomy that is to be imaged, the ability of the patient to cooperate, the limitation of the gantry angulation, and the diameter of the opening for the patient inside the gantry. In most CT examinations the gantry is positioned perpendicularly to the patient table; this helps simplify patient positioning. Sometimes the gantry should be angled. For example, brain scans are usually taken with the

gantry angled about 15° to 20° to the patient's OML (if the OML is perpendicular to the table). Body scans are usually done with the gantry perpendicular to the positioning table. An exception to this is a study of the spine for which slices through disk spaces are obtained at various angles.

You should pay close attention to two major concerns when you position the patient. First, make sure the patient is positioned as accurately as possible. Some CT exams call for specific positioning which will give optimum diagnostic information. This involves making sure the patient is not rotated or that certain positioning lines are angled. The second major concern is patient comfort. Any patient movement during the examination will lead to a loss of diagnostic information. Cushioning the head and placing pillows under the knees can help make the patient comfortable. Restraining straps may be used to immobilize some patients to reduce accidental movement.

#### Exercises (453):

1. List four factors that determine how the patient will be positioned for CT procedures.
2. How is the gantry positioned for a brain scan?
3. What are two major concerns you should consider when positioning a patient for CT?
4. What would result if the patient should move during an examination?
5. What should be done to prevent the patient from accidentally moving during the examination?

#### 454. Determine thickness, location, or number of slices for various CT examinations.

**Thickness, Location, and Number of Slices.** After positioning the patient, you can program the computer for scanning. During this step, you type in patient information, examination identification data, exposure technique, and scanning instructions. Two important factors you must specify are the thickness and location of each slice.

Generally, thin slices of 1.5 mm to 5 mm are used for fine detail on examinations of the posterior fossa, the pituitary gland, or the optic nerve. Sagittal and coronal reconstructed images from the cross-sectional scans also requires thin cuts.

In routine brain scans and most body scans a 1-cm thickness is generally acceptable, except for studies of the adrenal gland, for which thinner slices are usually taken.

The location of each slice is very important. As you operate the console, you can give instructions concerning where the scan slices will begin and end. In most studies, no anatomy separates two contiguous slices—where one slice leaves off the next one begins. In some studies, such as a generalized survey for lymphoma or metastasis, 1-cm slices are generally taken every other centimeter. You can overlap areas of each slice if extremely fine detail is needed.

The total number of slices depends on the size of the anatomic area to be examined and the preceding variables. As a general guideline, we can conclude the following number of slices for those particular exams:

- Brain scan—9 to 11 slices.
- Pancreas scan—about 11 slices.
- Liver or spleen scan—11 to 14 slices.
- Kidney scan—14 to 16 slices.

The number of slices taken will double if enhanced images with contrast media are added.

#### Exercises (454):

1. What slice thickness range should you use when scanning the pituitary gland? Why?

2. What slice thickness is generally acceptable for routine brain scans?

3. What two things can be done if extremely fine detail is needed?

4. What slice thickness and at what location interval should be done on a patient who needs a general survey of the abdomen for metastatic cancer?

5. How many slices should be done for a brain scan without contrast media?

6. A physician requests a kidney scan to be done with and without contrast enhancement. How many slices is involved in this examination?

## Scanography and Arthrography

YOU WILL RECALL that we have referred to magnification of a part several times in this CDC. As a rule, our studies have been concerned with reducing magnification to a minimum. The first section of this chapter, scanography, is basically more of the same—that is, reducing magnification of a part, although we go about it in a different manner. The second section deals with arthrography of the knee.

### 6-1. Scanography

Through the years, scanography has been done by either the *slit* or the *spot* method. The slit method involves movement of the tube during exposure. Moving the tube requires a technician to physically move it along the long axis of the bone either directly by hand or through a system of pulleys and cables. Both of these conditions present certain problems not encountered with spot scanography—and since you can produce any type of scanogram using the spot method, we will discuss only the spot method in this CDC.

**455. State the purposes of scanography and compare the CR-part-film alignment and part magnification of a conventional radiograph to a scanogram of a long bone.**

**Purposes of Scanography.** A scanogram is performed to determine the length of such long bones as the tibia, femur, or humerus. An examination to determine the longitudinal dimension provides the radiologist with a radiograph to measure the actual length of the bone. Depending on what specific information the orthopedist wants, the radiograph need not show the numerical dimension of the bone. It only has to demonstrate the length of one bone as compared with that of the opposite bone—for example, the length of the right femur as compared to the left.

**Principles of Scanography.** As we mentioned before, magnification is reduced to a minimum during scanography. Of course, you always keep magnification to a minimum during radiographic examinations, so reducing magnification is nothing new. However, since we want to produce a radiograph that shows the actual or relative length of a bone, we cannot demonstrate the length simply by “keeping the part-film-distance to a minimum” and “using the longest practical FFD.”

If you do a conventional radiograph of a long bone—the humerus, for example—the relationships between the CR and humerus and between the CR and film are like those shown in figure 6-1,A. Notice that the length of the image projected on the film is considerably larger than the actual length of the bone. The magnification is obviously caused

by the divergence of the primary beam. In general survey radiographs such as this, a certain amount of magnification is acceptable. When you perform a scanogram, however, unless you virtually eliminate the magnification, actual bone measurement is not possible, and relative bone measurements are difficult. If you make two exposures of the long bone diagrammed in figure 6-1,A, and direct the CR perpendicular to each *end* of the bone and the film, as shown in figure 6-1,B, the length of the projected image is the same as the actual bone length. Consequently, to eliminate the magnification resulting from the divergence of the primary beam, you simply use that portion of the primary beam with minimum divergence, the CR, and make separate exposures of each end of the bone.

### Exercises (455):

1. What are two specific purposes of scanography?
2. What is the difference, if any, between the CR-part-film alignment during a conventional and a scanographic projection of a long bone?
3. What is the relative difference between the magnification of a long bone radiographed by conventional means and by scanography?
4. Explain the reason(s) for the difference suggested in exercise 3 above.

### 456. Identify procedures for performing scanograms.

**Scanographic Procedures.** There are several ways to produce spot scanograms. The method you use depends on your radiologist and usually, the orthopedist. Also, the procedure depends upon whether the actual or relative length of the bone is desired.

**Actual length.** There are two ways to do a scanogram showing the actual numerical length of a bone. One requires the use of a ruler, scaled in centimeters and constructed so the scale marks and numerical values are demonstrated on the radiograph. Such a ruler, called the Bell-Thompson, is



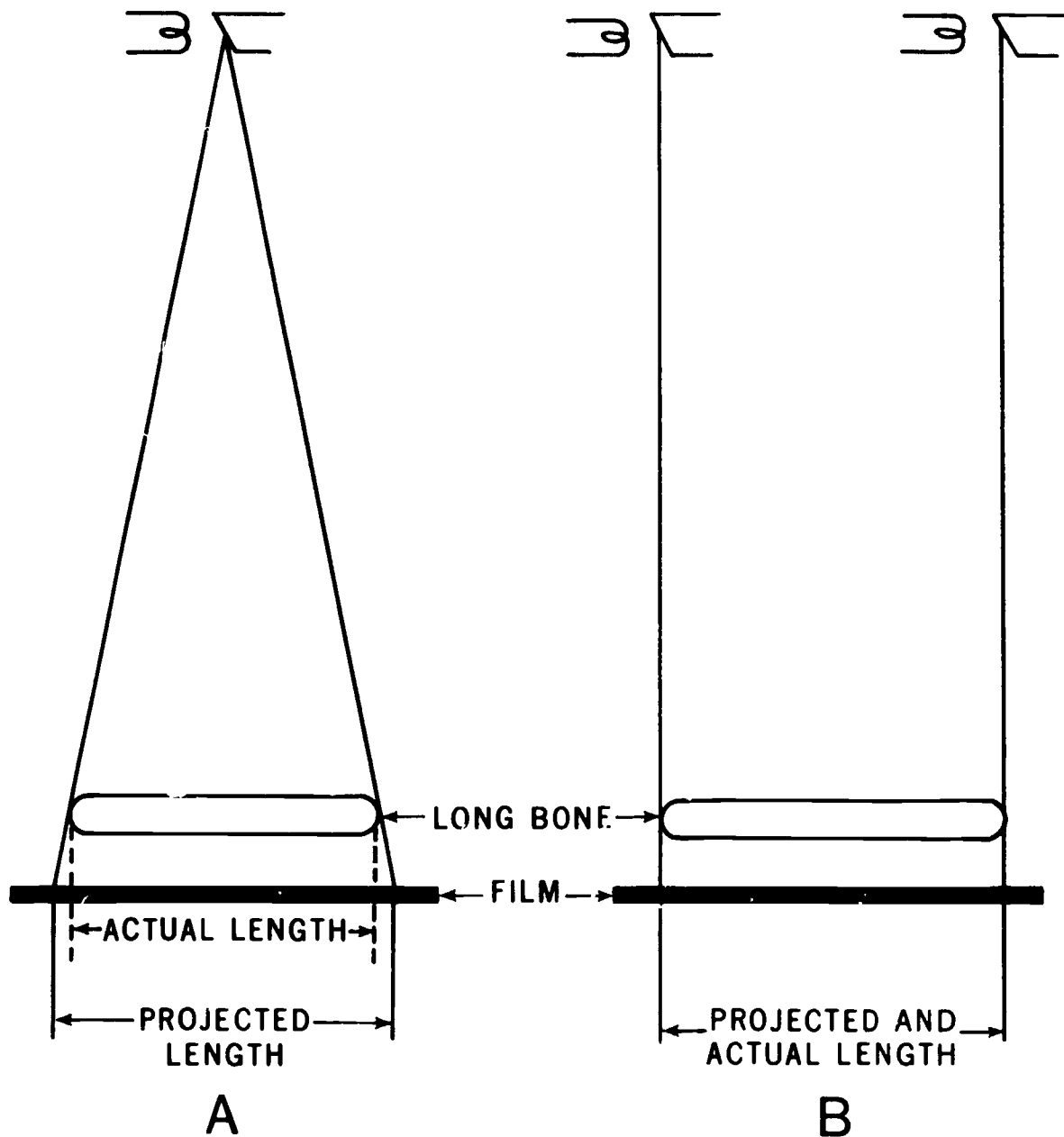


Figure 6-1.

available commercially. It has a 100-cm scale and requires an increase in technique—since it is radiopaque. Let's look at a scanogram of the femur and see how the ruler is used:

a. Suppose a scanogram showing the actual length of the femur is to be performed. Tape the ruler to the table on the centerline. Position the patient for an AP projection (all scanographic projections are AP) so the femur is directly over the ruler. Be sure the ruler markings extend to each end of the femur, as they should with all bones. Center the top half of the film to the hip joint. Collimate tightly and align the CR perpendicular to the center of the top half of the film. Make an exposure. Moving only the Bucky tray and tube, center the bottom half of the film to the knee joint

and align the CR perpendicular to the center of the bottom half of the film. Make another exposure. This radiograph will appear similar to the drawing in figure 6-2. Notice that only two sections of the ruler are seen on the film, but from the radiograph the radiologist can determine the actual length of the femur.

If the length of the entire leg is desired, use the same basic procedure. Project the hip joint on the top third of the film, the knee joint on the middle third, and the ankle joint on the bottom third.

You can also do a scanogram of both legs on the same film, using either three or six exposures. Using three exposures, tape the ruler to the centerline of the table as

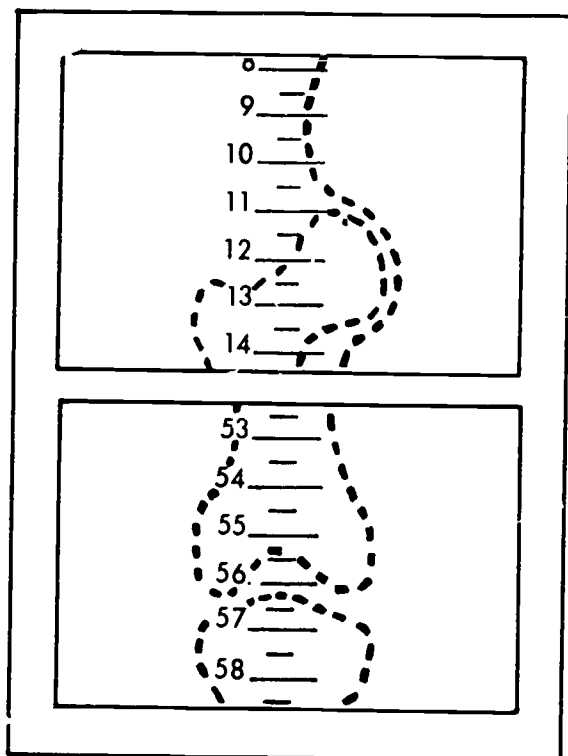


Figure 6-2 Drawing of a scanogram of a femur

before. Position the patient for AP projections of both legs on one film. Open the collimator wide enough to include both similar joints on each third of the film and direct the CR to the center of the table. Using six exposures, tape a ruler under each leg and use an X-ray field small enough to project the six joints individually on the film. As is true with all scanograms, do not move the ruler or patient between exposures. Naturally, when six exposures of the legs are made, the tube must be shifted off the grid center for each exposure, requiring consideration and/or compensation for grid cutoff.

b. You can demonstrate the length of certain long bones without using a ruler if the entire length of the bone or leg can be projected on a single film without moving the film. You can usually project the femur or tibia of most children on a 14- by 17-inch film. You can also project very small children's entire leg on a 14- by 17-inch film. Simply collimate to the joint and make an exposure of each joint, moving only the X-ray tube. No ruler is needed because the bone is not "shortened" by moving the film as is the case with the ruler. The length of the bone is determined by measuring directly with a centimeter ruler.

**Relative length.** The relative length of long bones (usually the legs) can be determined easily without a ruler. Simply follow the procedure for projecting both legs on one film, using three or six exposures. This procedure is usually done with the patient erect.

#### Exercises (456):

Indicate whether the following statements are true (T) or false (F). If you indicate false, explain your answer.

- 1. Because the Bell-Thompson ruler is radiolucent, it should be used with an increase in technique.
- 2. You can do a scanogram to determine the actual length of a long bone either with or without a Bell-Thompson ruler.
- 3. Neither the ruler, patient, film, nor tube should be moved between scanographic exposures.
- 4. Lateral scanographic projections are frequently made.
- 5. If the Bell-Thompson ruler is used for a scanogram, the markings should extend to each end of the bone.
- 6. A scanogram of both legs can be done using three or six tube positions.
- 7. The actual length of an adult femur can be determined on a scanogram using a film shorter than the femur.
- 8. The number of exposures for a scanogram depends upon the number of major joints present.
- 9. Two Bell-Thompson rulers are used to perform an actual length scanogram of adult legs on a single 14- by 17-inch film.
- 10. You can do an actual length scanogram of an adult femur on a 10- by 12-inch film without a Bell-Thompson ruler.

- 11. An actual length scanogram of a long bone taken without a Bell-Thompson ruler will show the two ends of the bone separated by an unexposed area.
- 12. A Bell-Thompson ruler need not be used for a relative length scanogram.

**457. Evaluate written descriptions of three scanograms and determine if either the CR alignment or the projected structure is correct.**

**Quality Control Considerations.** When you evaluate scanograms from a quality control point of view, pay special attention to where the CR was directed. Notice in figure 6-3 that we show a CR of a scanogram incorrectly directed to points away from the ends of the bone. The result is that the length of the image is smaller than that of the bone due to the divergence of the primary beam. If the CR were directed to points A and B in the figure, the image would be longer than the bone, for the same reason.

The best way to determine where the CR was directed is to find the center of each X-ray field on the film.

Obviously, you can locate the CR only if the X-ray field is smaller than that portion of the film on which the image is projected. If you cannot see the borders of the X-ray field, you cannot be sure where the CR was directed. Some technicians feel that as long as they mask off the unused portions of the film, the alignment of the CR is not important. Masking is important to reduce film fog due to scattered radiation; however, proper masking in combination with the correct CR alignment helps insure a diagnostic examination and reduces patient exposure.

**Exercises (457):**

Scanogram A is made of an adult tibia on an 8- by 10-inch film. Both the upper and lower halves of the film show X-ray fields completely visualized (all borders are seen). Both X-ray fields are 4 inches square. The proximal edge of the tibia is located one-half inch from the top border of the upper X-ray field. The distal edge of the tibia is located one-half inch from the bottom border of the lower X-ray field.

Scanogram B is made on an adult femur on a 10- by 12-inch film. Both the upper and lower halves of the film show X-ray fields completely visualized (all borders are seen). Both X-ray fields are 5 inches square. The proximal edge femur is located 2 1/2 inches from the top border and 2 1/2 inches

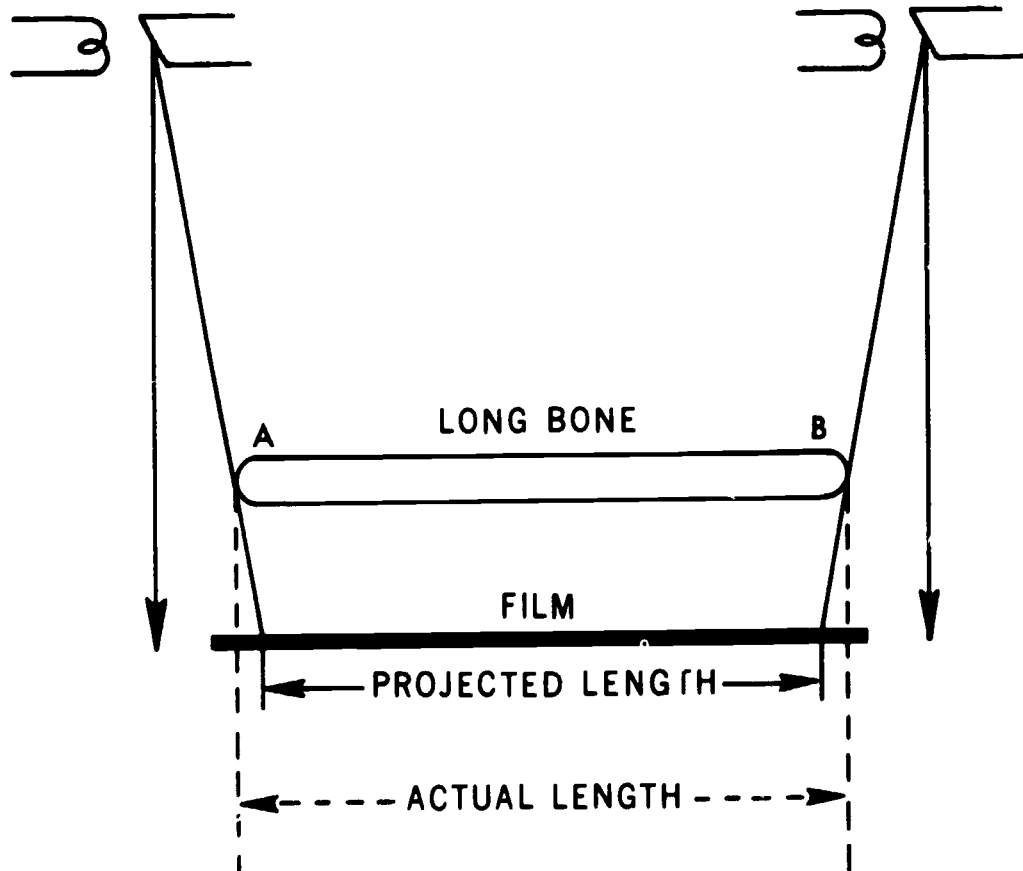


Figure 6-3.

from the bottom border of the upper X-ray field. The distal edge of the femur is located in the same relative location in the lower X-ray field.

Scanogram C is made of an adult femur on a 10- by 12-inch film. Only three borders of the X-ray field (which measures 7 inches across) on the upper half of the film are seen. The upper border is missing from the film. The proximal edge of the femur is located 4 inches from the center of the film. The lower X-ray field is completely visualized and measures 4 inches high by 7 inches across. The distal edge of the femur is located 2 inches from the bottom border of the X-ray field.

On the basis of the descriptions of scanograms A, B, and C above, answer the following questions concerning the CR alignment or projected length of the bone.

1. Which scanogram(s), if any, was (were) taken with the correct CR alignment?
2. Which scanogram(s), if any, projects (project) an image of the bone that is shorter than its actual length?
3. Which scanogram(s), if any, projects (project) an image of the bone that is longer than its actual length?
4. Briefly evaluate the correctness of CR alignment for each X-ray field on scanogram C.

## 6-2. Arthrography

Arthrography, as the name implies, is a radiographic examination of the soft tissue structures inside a joint space. The procedures for performing an arthrogram vary considerably from place to place. Consequently, some of the information presented here is general in nature. Arthrograms are done on several joints, including the ankle, knee, hip, elbow, and shoulder. Since most commonly arthrography is done on of the knee, our discussion in this section is limited to the knee. We begin with a review of the anatomy demonstrated by a knee arthrogram. After that, we explain the preparation and injection procedures and, finally, radiographic procedures.

**458. Given a list of structures located inside the knee joint, demonstrated by an arthrogram, identify each with either their location or function.**

**Anatomical Considerations of the Knee.** As you know, bony structures about the knee are normally well demonstrated on conventional knee radiographs. Certain soft tissue structures, however, are not. Let's discuss the soft tissue structures.

**Menisci.** The menisci are two cartilaginous pads, each of which is located between the medial or lateral femoral condyle and the medial or lateral superior articular surface of the tibia. Depending on their relative locations, the menisci are called the medial or lateral meniscus. The menisci act as shock absorbers in the knee joint.

**Collateral ligaments.** There are two collateral ligaments. The fibular collateral runs superoinferiorly along the fibular side of the knee. It attaches superiorly to the lateral femoral condyle and inferiorly to the head of the fibula. The tibial collateral ligament also runs superoinferiorly, but along the tibial side of the knee. It attaches superiorly to the medial femoral condyle and to the proximal, medial surface of the tibia inferiorly. Both collateral ligaments prevent medial or lateral movement of the joint.

**Cruciate ligaments.** The cruciate ligaments, anterior and posterior, stabilize the knee joint anteriorly or posteriorly. The anterior cruciate attaches anteriorly to the intercondylar eminence of the tibia, runs posteriorly and laterally through the femoral intercondylar fossa, and attaches to the posterior part of the medial surface of the lateral femoral condyle. The posterior cruciate ligament attaches to the posterior intercondylar fossa of the tibia, runs anteriorly and medially through the femoral intercondylar fossa, and attaches to the anterior part of the medial surface of the medial femoral condyle.

### Exercises (458):

1. Match the knee joint structures in column B with statements describing the location and function of the structures in column A by placing the letter of the column B structure in the space provided in column A. Each column B letter may be used once, or more than once.

<i>Column A</i> <i>Location</i>	<i>Column B</i> <i>Knee Joint Structure</i>
_____ (1) Extends from head of fibula to lateral femoral condyle.	a. Meniscus.
_____ (2) Runs through the femoral intercondylar fossa.	b. Collateral ligament
_____ (3) Extends superoinferiorly along the medial side of the knee.	c. Cruciate ligament
_____ (4) Located between the medial femoral condyle and medial superior articular surface of tibia.	
_____ (5) Attaches to intercondylar eminence of tibia.	
_____ (6) Attaches to posterior intercondylar fossa of tibia.	
<i>Function</i>	
_____ (7) Maintains anterior or posterior stability.	
_____ (8) Prevents medial or lateral movement of the knee joint.	
_____ (9) Acts as a shock absorber.	

**459. Explain patient preparation, types of contrast media which can be used, and injection procedures involved in an arthrogram of the knee.**

**Patient Preparation and Injection.** Since the patient preparation and injection procedures involved in an

arthrogram of the knee vary from one hospital to another, we will provide you with some general guidelines.

**Patient preparation.** Shave the lateral surface of the patient's knee joint and clean and prepare the skin. Surgical soap, alcohol, zephiran chloride, tincture of iodine, or a combination of these items may be used. Then drape the area with sterile towels or sheets.

**Injection procedures.** The radiologist usually injects a local anesthetic to numb the injection site, then injects a water-soluble contrast medium into the joint space. If a pneumoarthrogram is to be done, air, oxygen, or carbon dioxide may be injected. If a positive medium is used, the radiologist will probably inject about 10 to 15 cc of the solution. If joint effusion is present, more contrast medium is usually injected (up to twice the normal amount); otherwise, dilution will prevent a good study from being done. The radiologist also normally tries to aspirate as much fluid as possible when joint effusion is present to keep dilution of the medium to a minimum. Twenty cc or more of a negative medium may be injected if a pneumoarthrogram or double contrast study is to be done.

After covering the injection site with sterile gauze, the radiologist usually massages the knee to distribute the contrast medium throughout the joint space. He or she may also allow the patient to stand and walk to help distribute the medium. Some also wrap the knee tightly with an ace bandage to force the contrast medium out of the quadriceps pouch onto the surfaces of the menisci. The ace bandage should be removed before the lateral radiographs of the knee are made to permit visualization of the quadriceps pouch.

#### Exercises (459):

1. Briefly explain how the knee is prepared for injection during an arthrogram.
2. What type of positive contrast media is injected into the knee joint?
3.
  - a. How many centimeters of positive contrast medium would you normally need for an arthrogram?
  - b. How many centimeters would you need if joint effusion is present?
4. What type(s) of negative contrast medium may be injected into the knee joint?

5. Why is fluid aspirated when joint effusion is present?

6. Name three ways in which the contrast medium may be distributed throughout the knee joint after injection.

7. If the knee is wrapped in an ace bandage, when should it be removed? Why?

#### 460. State procedures for doing radiographs during an arthrogram of the knee.

**Radiographic Considerations.** Several different projections and type of radiographs of the knee are done during an arthrogram. Most radiologists request that the standard AP, PA, lateral, obliques, and stress views be done. Obliques may be done with various degrees of rotation—for example, 30, 45, 60, and 75. Usually, the CR is angled 5° cephalic for AP projections, including AP obliques, to better open the joint space. It is not necessary to angle the CR for the PA projection. Since the tibia and fibula are slightly inclined when the leg is PA, the CR will be parallel to the tibial plateau.

Some special projections are done with the patient's leg placed in a stress device to widen or "open up" the side of the joint space under investigation. This widening, or spreading, permits better distribution of the contrast medium around the meniscus. To visualize the medial side of the joint, the stress device is placed just above the knee and the lower leg is laterally stressed. The lower leg is medially stressed to widen the lateral aspect of the joint.

If a pneumoarthrogram or double contrast study is done, some or all of the projections are usually made with a horizontal CR to take advantage of the rising air.

**Necessity for speed.** The contrast medium injected into the joint capsule is eventually absorbed. Absorption begins within a short time after introduction, and the entire injection can disappear from the joint capsule within 30 minutes. It is obvious that you should work quickly to do the radiographs before this happens. You must also make sure that the positions, exposure factors, etc., are correct the first time since you may not have enough time to repeat the radiographs. If several radiographs are to be taken with various positions, you may need to use an assistant to reduce the examination time.

**Marking the joint space.** To properly demonstrate the necessary structures, you must direct the CR through the joint space when you do the radiographs. Since some sort of bandage is usually applied to the knee after the injection, it is difficult for you to determine the exact location of the joint. It is usually best to have the radiologist mark the joint space under fluoroscopy after the bandage has been applied. If various projections are to be made, a line drawn around the circumference of the knee is helpful.

**Exercises (460):**

Indicate whether the following statements are true (T) or false (F). If you indicate false, explain your answer.

- 1. The PA and AP projections are usually taken with a vertical CR to take advantage of the rising air.
- 2. Standard 45° obliques are always made.
- 3. Speed is important to prevent undue patient discomfort.
- 4. Perhaps you should use an assistant if many radiographs are to be made.
- 5. The CR must be directed through the joint space.
- 6. You can estimate the exact location of the joint space if the knee is wrapped in a bandage.

## Bedside and Surgical Radiography

SO FAR we have dealt primarily with patient care in the radiology department. This chapter deals with bedside and surgical radiography and with some conditions you may encounter when radiography is needed in other areas of the hospital.

### 7-1. Bedside Radiography

You have probably done many portable examinations in different areas of the hospital. No doubt you have learned to draw upon your knowledge of radiographic fundamentals to get good diagnostic films in the most difficult situations. In this section, we look at different patient care areas from a safety point of view by covering hazards and precautions that you may not come across each time you do a portable. Then we cover various ways to do a chest X-ray on a cardiac patient.

#### 461. Identify procedures for doing bedside radiography in special patient care areas.

**Patient Care Areas That Require Bedside Radiography.** Bedside radiography is requested when a patient's condition makes it difficult or hazardous to transport the patient to the radiology department—for example, orthopedic traction patients, neonatal nursery patients, and intensive care patients. Isolation patients also are frequently done bedside but since all three patient types just listed may also be isolation patients, and because of special precautions unique to isolation patients, we cover them separately.

**Orthopedic traction patients.** Orthopedic traction is a mechanical method that uses weights to provide a constant pull, or traction, on part of the body. The lumbar or cervical spine may be placed in traction to relieve muscle spasm or spinal stress, or a fractured long bone, such as a femur, may be placed in traction to keep the fragments aligned as the bone heals.

You must be careful when working around a traction device. An accidental bump against the bed or the traction weights may cause severe pain to the patient. Since patients know which motions are tolerable for them, let the patient assist as much as possible with any moving or lifting when you are positioning for the radiograph. If there is any doubt about the advisability of certain movements, check with nursing personnel who are familiar with the patient's condition. Sometimes the usual tube-part-film alignment may need to be adjusted because of the traction device.

The sudden release of traction may result in serious ill effects to the patient. You should never try to release, remove, or add any weights.

**Neonatal nursery patients.** Although most infants are born with good health, some problems with newborns are often monitored radiographically. For example, newborn atelectasis (failure of lungs to expand completely) may require chest films. Congenital hip dysplasia and possible fractures from birth trauma may need certain radiographs. Hydrocephalus (excess fluid in the ventricles of the brain) may cause a physician to request skull films. Since infants acquire immunity to certain infections gradually, neonates are often protected by means of reverse isolation. So you would need to go to the neonatal nursery to do the X-ray procedure.

When you arrive at the nursery, you will notice the infant will be enclosed in an incubator. This device provides extra warmth, moisture, and oxygen while reducing the possibility of airborne infection. Some infants may be safely removed from the incubator for brief periods to be radiographed; however, you should *never* remove the infant from the incubator without first checking with the nursing personnel. If the baby cannot be removed, you can radiograph the baby in the incubator by having the nursing personnel position the baby and cassette according to your instructions while you control the X-ray equipment.

Bedside radiography of neonates must always be done under strict radiation protection guidelines. Always show a collimated field of radiation and, whenever possible, shield vital organs on each radiograph. Use the least amount of radiation that is necessary and show marginal films to a radiologist before doing any repeats.

**Intensive care unit patients.** The intensive care unit (ICU) is especially designed for patients who are in critical condition or whose treatment requires frequent monitoring. The special problems faced in this environment may be two-fold: dealing with one's own anxiety at confronting near-death situations and dealing with a vast array of life-sustaining equipment, much of it connected to the patient or to other equipment by a network of cords, cables, and tubes. Since there is always adequate staff to provide nearly constant patient care, your duties are limited almost exclusively to technical considerations of the procedure you are doing. Therefore you need not overly concern yourself with the patient's condition; nursing personnel deal with that.

On the other hand, you will be confronted with much life-sustaining equipment. Some of it may include nasogastric tubes, closed-chest drainage tubes, or tracheotomy tubes that may be connected to a ventilator. Each type may pose a problem in positioning a patient and a cassette for an exposure. Avoid crimping or bending any tube. If you need to roll or lift a patient for cassette placement, always move the patient toward a tube. Moving

a patient away from a tube may dislodge it and jeopardize the patient's condition.

Other drainage devices may be situated near the patient or attached to the side of the bed. Always survey the immediate area around the patient before you bring in the mobile X-ray unit to avoid a serious accident.

The patient may be receiving oxygen to assist in respiration. While oxygen itself is not combustible, it supports combustion to the extent that pure oxygen can cause a flash fire if a source of ignition is present. For this reason, you must take special precautions when you do radiographic examinations on a patient receiving oxygen therapy.

In most cases, the oxygen can and should be turned off for a short time while you do the examination. Of course, you do not remove the oxygen supply or restart it—this is done by a nurse or other responsible ward personnel.

If the oxygen is to be turned off and the oxygen tent removed for the examination, be sure to make preparations such as setting the control panel, positioning the tube and film, and instructing the patient, in advance. You should also work quickly so that the patient can be returned to oxygen therapy as soon as possible.

If the patient's condition is so critical that the oxygen cannot be turned off at all, and if the examination to be done is a chest film—which it usually is—the oxygen tent can be draped only around the patient's head, leaving the chest area free.

#### Exercises (461):

Indicate whether the following statements are true (T) or false (F). If you indicate false, explain your answer.

- \_\_\_ 1. Never try to remove or add any weights to a traction device.
  
- \_\_\_ 2. Allow the patient to help with any moving or lifting when you are positioning for bedside radiography on a traction patient.
  
- \_\_\_ 3. Neonates are kept in reverse isolation to protect other patients from congenital diseases the infants may carry.
  
- \_\_\_ 4. An incubator is a device that maintains bone alignment or orthopedic traction patients.
  
- \_\_\_ 5. Never remove an infant from an incubator without first checking with the patient's parents.

\_\_\_ 6. Infants cannot be radiographed while they are inside an incubator.

\_\_\_ 7. If you need to roll or lift an ICU patient for cassette placement, always move the patient away from a tube to prevent crimping or bending that tube.

\_\_\_ 8. Oxygen is not combustible.

\_\_\_ 9. Pure oxygen can cause a flash fire if a source of ignition is present.

\_\_\_ 10. When doing bedside radiography, you should turn off an oxygen supply when taking the exposure.

#### 462. Explain bedside radiography procedures on isolation patients.

**Performing Bedside Radiography On Isolation Patients.** One major reason for doing bedside radiography is that a patient is in isolation. Isolation is a specialized method of medical asepsis that is used when the danger of transmitting disease is exceptionally great.

There are two major types of isolation: strict isolation and reverse isolation. Strict isolation confines the disease to the patient and immediate surroundings, which, in turn, protects other patients and personnel from contacting the disease. Reverse isolation, also called protective isolation, protects the especially susceptible patient from exposure to potential infection. Burn patients and neonatal infants are logical reverse isolation patients.

Doing bedside radiography on isolation patients calls for an awareness of the patient's condition, the type of isolation, and the established procedures you should follow. You can handle these situations more confidently and effectively if you are familiar with the requirements for each type of isolation. Strict isolation requires technicians to wear gowns, masks, and gloves. All equipment must be decontaminated or discarded before it is reused. Reverse isolation also requires gowns, masks, and gloves. Furthermore, any articles that come in direct contact with the patient must be sterile or disinfected and the mobile X-ray equipment must be disinfected before it enters the isolation room.

Radiography of an isolation patient should be done by two people, preferably two X-ray technicians. This enables one technician to position the patient and the other one to handle the equipment. Although both radiographers must follow all designated isolation procedures, one remains "clean" while the other is considered "contaminated."



These roles vary according to the situation. For example, when a patient in strict isolation is radiographed, the "clean" technician is the only one who touches the X-ray machine and cassettes; no direct contact with the patient, the bed, or any items that may have been touched by the patient should be made by this technician. The other technician would have direct patient contact and is responsible for film placement and positioning. This technician is considered contaminated after contact with the patient and should not touch the X-ray equipment or other personnel until he or she has cleaned up properly.

These roles change with a reverse isolation patient. Because you are trying to protect the patient from exposure to potential infection, the "clean" technician comes in contact with the patient while the "contaminated" technician operates the X-ray machine.

There are, of course, some general guidelines to follow when you do a portable besides the technical aspects of the job (use of grids, film holders, exposure factors, etc.). Perhaps one of the most important is being courteous. You should call the nursing station before you leave the radiology department to do a routine bedside radiograph. This will assure that the patient is available for the examination and that radiography will not interrupt a meal, a bath, or a much-needed nap. When you reach the ward, check with the nurse in charge and ask about the patient's condition. If the situation hasn't changed, you can go to the patient's room. Do not push your equipment in ahead of you. Park the machine outside and enter alone first. Introduce yourself, explain the procedure to the patient, and move any obstacles out of the way before you bring the X-ray machine to the bedside.

Patients in isolation often tend to feel rejected and "untouchable." You can help ease these feelings by expressing a friendly interest in the patient and by avoiding any display of fear or revulsion as you do your work.

#### Exercises (462):

1. What is "isolation"?
2. Define the two types of isolation.
3. What two types of patients are usually reverse isolation patients?
4. What requirements should be routine when doing bedside radiography on a strict isolation patient?
5. What is the difference in procedural requirements between strict isolation patients and reverse isolation patients?
6. Explain why two technicians should be used to do bedside radiography on an isolation patient.
7. Explain the duties of the "clean" technician when doing bedside radiography on a reverse isolation patient.
8. Explain the duties of the "contaminated" technician when doing bedside radiography on a reverse isolation patient.

#### 463. Identify the correct projection to use and the best patient positions for making beside chest projections of a cardiac patient.

**Radiographing a Cardiac Patient.** Numerous bedside radiographs are made of cardiac patients whose conditions are such that merely moving them to and from a stretcher might jeopardize their recovery. There are at least four ways to do a chest film on these patients. The procedure you use generally depends upon the amount of movement the patient is allowed or can tolerate.

**Erect PA, 72-inch chest.** When you must do a bedside chest radiograph on a cardiac patient, you should first consider a PA chest taken at a 72-inch FFD with the patient erect. This radiograph, of course, can be as diagnostic from a positional point of view as a routine PA chest done in the radiology department under ideal conditions.

The procedure for this chest radiograph is simple: the patient sits on the side of the bed holding the vertical cassette in front of his or her chest. Check with the nurse or physician whether it is permissible for the patient to assume this position. Use a horizontal CR.

**Erect or semierect AP chest.** If the patient cannot sit up, you should consider elevating the head of the hospital bed to bring the patient to a sitting position. Then place the film behind the patient and direct a horizontal CR at the vertical film from a distance of 72 inches.

At times it may not be possible, due to the patient's condition, to elevate the bed to bring the patient's chest to the erect position, but it may be permissible to elevate it, say 45°. Although this projection is not as good as the erect AP, it gives a semierect radiograph and is better than using the supine position. You may not be able to use a 72-inch FFD because the CR must be angled down from the horizontal so it is perpendicular to the tilted film.

**Supine AP chest.** If it is not possible to position the patient for any of the projections described above, then do a supine AP chest. Simply slide a cassette under the patient's back and use a vertical CR. Lower the hospital bed to provide the greatest FFD possible (which will be considerably less than 72 inches) so that magnification is kept to a minimum. This projection requires the least patient movement.

**Exercises (463):**

1. Match the bedside chest projection of a cardiac patient in column B with the correct statement in column A by placing the letter of the column B item in the space provided in column A. Each column B item may be used once or more than once. In addition, more than one column B item may match a single column A entry.

Column A	Column B
_____ (1) Lower the patient's bed to reduce magnification	a PA, erect.
_____ (2) Patient holds the cassette	b AP, erect
_____ (3) It's use depends upon the patient's condition	c AP, semierect
_____ (4) X-ray film is vertical.	d AP, supine.
_____ (5) CR is neither horizontal nor vertical	
_____ (6) Provides best radiograph.	
_____ (7) Performed when patient's condition precludes the other three projections	
_____ (8) Provides the least magnification of the chest	
_____ (9) If the patient's movement is not restricted, this projection should be performed	
_____ (10) Requires the least movement of the patient	

**464. Specify the minimum SSD you should use and the minimum lead equivalent of a protective apron worn when you do a mobile radiograph.**

**SSD and Protective Apron Requirements.** While these requirements are included under the heading of bedside radiography, they apply to all mobile radiography. At times, when you do mobile radiographs, it is not possible to achieve your normal FFD because of conditions beyond your control, such as the presence of casts, traction devices, and other patient-care apparatus. In these circumstances you may reduce the FFD to that necessary, as long as the SSD (source to skin distance) is not less than 12 inches. The SSD is, of course, the distance from the focal spot to the patient's skin. This minimum SSD is required by AFM 161-38, *Diagnostic X-Ray, Therapeutic X-Ray, and Gamma-Beam Protection for Energies up to 10 Million Electron Volts*. This manual also requires that you wear a protective apron of at least 0.25 mm lead equivalent.

**Exercises (464):**

1. What is the minimum SSD that you should use when you do a mobile radiograph?
2. What should be the minimum lead equivalent of a protective apron worn when you do a mobile radiograph?

**7-2. Surgical Radiography**

As was the case in the section on bedside radiography, we will not cover the specific exposure factors, grid use, etc., concerned with surgical radiography. We will focus our study on wearing surgical clothing, cleaning your mobile unit, and your general actions inside the operating room. Afterward, we will examine some general guidelines that apply to a radiographic examination.

**465. State the purpose and general requirements for operating room clothing and shoes and the conditions or circumstances that cause operating room clothing policies to vary.**

**Surgical Clothing.** To reduce the amount of bacteria introduced into the operating room and to prevent the buildup of static electricity, you must change into special surgical clothing.

**General clothing.** The special clothing includes a shirt and trousers or dress, cap, and mask. The shirt, trousers, and dress are usually made of cotton. The cap and mask

may be made of cotton, or they may be the disposable paper type. Since nylon or similar materials may cause static electricity, undergarments made of these materials should not be worn in the operating room.

**Shoe covers.** You also wear special shoe covers in the operating room. These shoe covers serve two purposes—they reduce the amount of bacteria introduced into the operating room, and they prevent the buildup of static electricity by grounding you. There are several types of covers, and all of them have a conductive sole to which is attached a conductive strap. The end of the strap is inserted inside your sock so it is in contact with your skin. Some operating rooms use a device that tests you to determine whether you are properly grounded.

**Operating room policies.** Due to the preference of the chief of surgery, the physical arrangement of the surgical suite, and other variables, clothing policies may vary from one hospital to another. For this reason, you, as a technician or supervisor, should ensure you and your personnel understand the procedures used in your hospital, and see that they are carried out properly.

### Exercises (465):

1. Why must special surgical clothing be worn in the operating room?
2. Why shouldn't you wear nylon or similar undergarments in the operating room?
3. How are you connected to ground by operating room shoe covers?
4. Give two specific factors that may cause clothing policies to vary from one hospital to another.

**466. Explain why and how components of your mobile unit should be cleaned before they are taken into an operating room.**

**Cleaning the Mobile Unit.** In keeping with our previous discussion of reducing the bacteria introduced into the operating room, you must clean your mobile unit before you take it inside. Thoroughly wipe down the entire unit with hand towels soaked in an antiseptic solution provided by operating room personnel.

The need to clean your portable unit is not too difficult to understand when you consider that the tubehead is usually positioned directly over the operative site. Even though the site is usually covered with sterile drapes when you do your radiographs, particles of dust falling from your tubehead might contaminate the sterile area. Some surgeons prefer you cover the tubehead with a sterile pillowcase or a sheet of clear plastic *after* the machine has been cleaned to reduce the danger of contamination. Clear plastic is preferred because it permits visualization of the light field from your collimator.

Other parts of your mobile unit that require special attention are the wheels and power cord. These, of course, are probably the dirtiest parts, since they are repeatedly in contact with the floor.

### Exercises (466):

1. Why should your mobile unit be cleaned before it is taken into an operating room?
2. How should your mobile unit be cleaned before it is taken into the operating room?

3. Name three components on your mobile unit that require special cleaning, and in each case state why.
4. After wiping your mobile unit down, how can you further prevent contamination of the operating site?

**467. List the usual composition or components of sterile and nonsterile areas of the operating room during "open" surgery, and state the chief concern of the radiology technician for these areas.**

**Operating Room Areas.** During "open" surgery, the operating room is considered to be divided into two areas: sterile and nonsterile.

**Sterile area.** The sterile area is concentrated about the operating site. Included in this area is a certain portion of the patient, the surgeon and his or her immediate assistants, the surgical instruments, and the tables, trays, and stands that hold the instruments.

**Nonsterile area.** The nonsterile area includes the anesthetist, you and your mobile unit, and various other components in the operating room. As you do the radiographic examination, you must keep from contaminating or contacting any part of the sterile area. It is usually good practice to extend the horizontal tube arm as far as possible so that when the tubehead is positioned over the patient, the remainder of the unit is remote from the table.

### Exercises (467):

1. Name five components (people or equipment) of the operating room in the sterile area.
2. Name three components of the operating room in the nonsterile area.
3. As the radiology technician, what is your main concern for these areas?

**468. Identify factors that affect radiographic examinations made in the operating room.**

**Performing the Examination.** Numerous surgical procedures require radiographic support. It would be impractical to cover all of them in this CDC. Instead, we look at some of the most common procedures, as well as some general considerations that apply.

**Speed.** Surgeons and anesthetists or anesthesiologists like to finish surgery as quickly as possible so the patient remains under the influence of the anesthetic for a minimum amount of time. During some surgical procedures, the surgeon cannot continue to work until the radiographs are examined. This means you should act quickly in performing the radiographic examination and return from your darkroom with the radiographs as quickly as possible.

You can, of course, reduce the delay caused by film processing by using Polaroid films and the accompanying processor. While you cannot use these films for all examinations, you can use them for many, especially open and closed reductions of the extremities.

**Accuracy.** Whenever you must repeat a radiograph made in the operating room due to the quality of the film, you are, in effect, increasing the length of the operation. Accordingly, the patient remains under the anesthetic for a longer time. Exposure and positioning are critical. Incorrect exposure is the most common reason that repeat radiographs must be made. Incorrect or incomplete technique charts contribute to the problem at times, so keep a correct, complete mobile-unit chart. Incorrectly estimating the thickness of the part also leads to incorrect exposure. Measure the patient, if possible, the surgery, if the operation is scheduled in advance.

**Scout film.** Since many radiographs are repeated because of incorrect exposure, a scout film should be made when possible. Naturally, a scout film need not be made for open or closed reductions of the extremities (excluding the hip). For a hip-nailing procedure, when a lateral projection (Danlius-Miller described in Volume 2) is required, you should always make a scout film and leave the mobile unit in place. For certain abdominal radiographs, such as an operative cholangiogram, you should always make a scout film.

**Aligning the X-ray tube to the grid.** At times, it may be difficult to align the X-ray tube to the grid to prevent cutoff due to lateral decentering. The reason for the difficulty is that, because of the extent to which the patient is draped, you may not be able to tell where the center of the grid is located. (NOTE: This discussion is based on the assumption that you make a properly aligned scout film for an operative cholangiogram, for example, and remove the unit from the immediate vicinity of the patient, thereby necessitating recentering the tube to the grid for the remaining radiographs.) One way to help prevent grid cutoff is to use a grid with a lower ratio, which, as discussed in Volume 1, increases the tolerable amount of lateral decentering.

Some technicians prefer to mark the location of the wheels on the floor when they make the scout film, so they can return the mobile unit to the same location. Naturally, the position of the X-ray tube with respect to the grid must be correct for the scout radiograph if this procedure is to be helpful.

#### Exercises (468):

1. Why is it important for you to complete a radiographic examination in the operating room quickly and accurately?
2. How can you reduce the delay caused by film processing when reductions of the extremities are done?
3. What is the most common cause of repeat radiographs in the operating room? What can you do to help prevent these repeats?
4. Name two surgical procedures that require a scout film.
5. Why is it sometimes difficult to align the X-ray tube to the grid when you do a radiograph in the operating room?
6. How can you increase the lateral decentering tolerance of the grid when you do a grid radiograph in the operating room?
7. Describe one way to properly align the tube to the grid for a later radiograph, assuming that proper alignment was originally made for the scout film.

## Film Duplication and Subtraction

BOTH FILM duplication and subtraction are simple procedures if you have one of the various commercial printers in your department. And if you have a continuous need to duplicate radiographs or do subtraction, you should have a printer on hand. However, if you only occasionally perform either of these procedures, you can do very well by understanding the principles involved and by using your own "homemade" device. In this chapter we cover the principles involved in film duplication and subtraction, and the construction and use of a special cassette to perform these two procedures.

### 8-1. Film Duplication

Our study of film duplication begins with a look at the principles of solarization. After that, we will examine specific procedures for duplicating radiographs.

#### 469. State how solarization applied to duplicating radiographs.

**Principles of Solarization.** Before we define solarization, let's look at a characteristic curve of typical X-ray film (see fig. 8-1). As you recall, the reaction of the film to exposure, either light photons or X-ray photons, begins at the toe of the curve and proceeds along the slope to the shoulder. Along the curve, the density of the film increases as the exposure increases.

When the density of the film reaches the maximum, shown by the leveling off of the shoulder of the curve, additional exposure *reduces* the density of the film. The phenomenon that causes this is called solarization. Notice in figure 8-2 that an extension of the characteristic curve shows the density to drop steadily as the exposure increases.

To see how solarization can be used to duplicate a radiograph, let's assume you place an unexposed standard X-ray film beneath a radiograph, and expose both of the films to white light for a very short time. After the X-ray film is processed, the information on the original radiograph appears, but the tones are reversed, as shown in figure 8-3,A. The black areas appear white, and the white areas appear black. This image reversal is due to the amount of exposure in the characteristic curve range where more exposure provides greater density. If both films are subjected to considerably more light, as shown in figure 8-3,B, the processed film shows the image of the original radiograph duplicated so that the black areas are black and the white areas are white. The reason for the exact tonal duplication is that the light exposure is now in the

solarization range, where greater exposure to the film causes less density. Consequently, solarization allows you to copy a radiograph showing exact tonal duplication.

You can copy a radiograph by following this general procedure, using either sunlight or artificial light. However, the duplicate would not provide good detail because a standard X-ray film does not reproduce detail sufficiently during solarization because of the composition of the film.

**Duplicating Film.** Most film manufacturers make a *duplicating film* to be used specifically for copying radiographs, and you should use this type of film. Duplicating film differs from standard X-ray film in that it has emulsion on one side only, and the emulsion is already solarized. The response of the emulsion to exposure can be compared to a standard X-ray film that has been preexposed to the maximum density or to the shoulder portion of its characteristic curve.

Most brands of duplicating film are designed to be exposed with ultraviolet light, but some are designed to be exposed by white light. In either case, use the recommended light source.

#### Exercises (469):

Indicate whether the following statements are true (T) or false (F). If you indicate false, explain your answer.

- \_\_\_ 1. An increase in exposure always increases film density.
- \_\_\_ 2. Solarization can cause a high exposure to produce low density.
- \_\_\_ 3. If a radiograph is duplicated using a standard X-ray film, the amount of exposure determines the tonal relationships.
- \_\_\_ 4. If a radiograph is duplicated using a standard X-ray film, and the reproduced tones are the same as those of the radiograph, solarization did not influence the outcome of the tones.

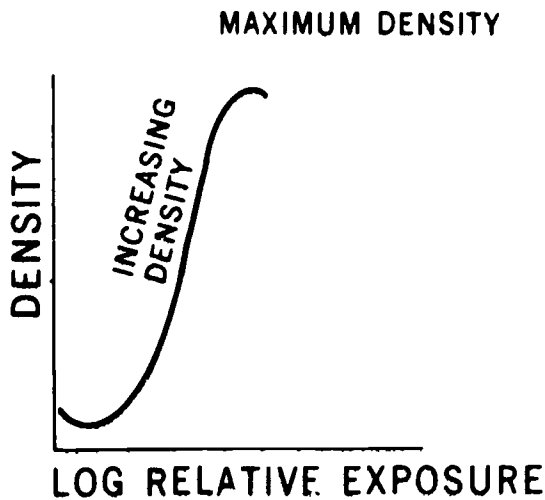


Figure 8-1 Characteristic curve of an X-ray film

- 5. Duplicating radiographs using standard X-ray film produce good detail on the duplicate.
- 6. Radiographs should be copied on duplicating film.
- 7. Duplicating film responds to exposure in the same way as conventional X-ray film does.
- 8. Solarized duplicating film should be used with the exposure source for which it is designed.

**470. Describe equipment and procedures for duplicating radiographs.**

**Duplicating a Radiograph.** Duplicating radiographs is a widely practiced function of radiology services. The easiest way to do this is to use a commercial printer; however, not every radiology department has one. Therefore, we explain the two ways to duplicate radiographs: with the use of a special cassette, and with the use of a commercial duplicator.

**Duplicating radiographs with a special cassette.** The first item you will need, other than a duplicating film, is a special cassette that you can easily build from a standard cassette. (A single 14 by 17 cassette will be sufficient, but you can make one for each size radiograph that you copy.) Simply remove the bakelite front of the cassette and replace it with a transparent sheet of regular glass or Plexiglas, and remove the intensifying screens. Keep the glass clean and do not let it get scratched, since glass that is soiled and scratched causes artifacts on the duplicate.

To load the cassette, place the radiograph to be copied in the cassette first so that it is in contact with the glass front. Place the duplicating film in the cassette with the emulsion against the radiograph—the emulsion is on the “dull” side of the film. The films must be in close, even contact when the cassette is closed to prevent loss of detail.

**Light source.** As mentioned before, you should use the type of light (ultraviolet or white) recommended by the manufacturer. Fluorescent or incandescent lamps may be used. An ordinary radiographic viewbox works well. You can use ultraviolet lamps in your viewbox, and, if you are using white light-sensitive films, the viewbox can be used with the standard fluorescent lamps. You can also use certain incandescent lamps that emit white light, as recommended by the film manufacturer.

**Exposure time and source-to-film distance.** These factors are closely related, since the intensity of the light diminishes as the source-to-film distance increases. Exposure time is usually in the neighborhood of a few seconds, while the source-to-film distance may reach to 40 inches. Each film manufacturer makes specific recommendations pertaining to these two factors—follow them.

**Evaluation of the duplicate.** Although you should initially follow the manufacturer’s recommended exposure time, do not hesitate to vary your exposure if the duplicates are not satisfactory. Certain factors such as line voltage and processing may necessitate different exposures. Keep in mind excessive exposure produces a light image and insufficient exposure produces a dark image. Obviously, this is due to the solarized duplicating film. Accordingly, you can also produce a duplicate with more or less density than the original by varying the exposure time.

**Duplicating a radiograph with a commercial duplicator.** Your department may have one of the various types of commercial duplicating machines. These are convenient because they eliminate the need for a special glass-front cassette.

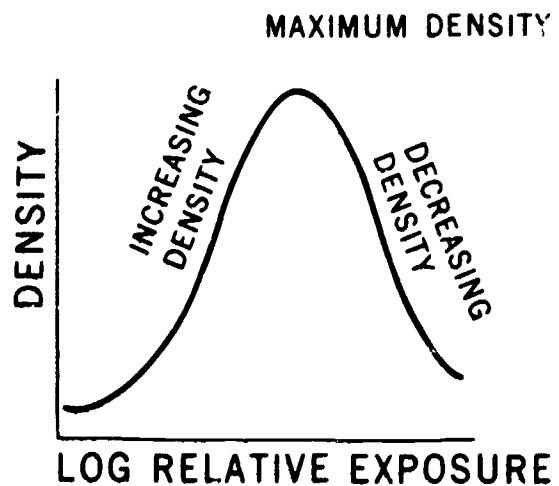


Figure 8-2. Extension of a characteristic curve showing the drop in density with increasing exposure caused by solarization.

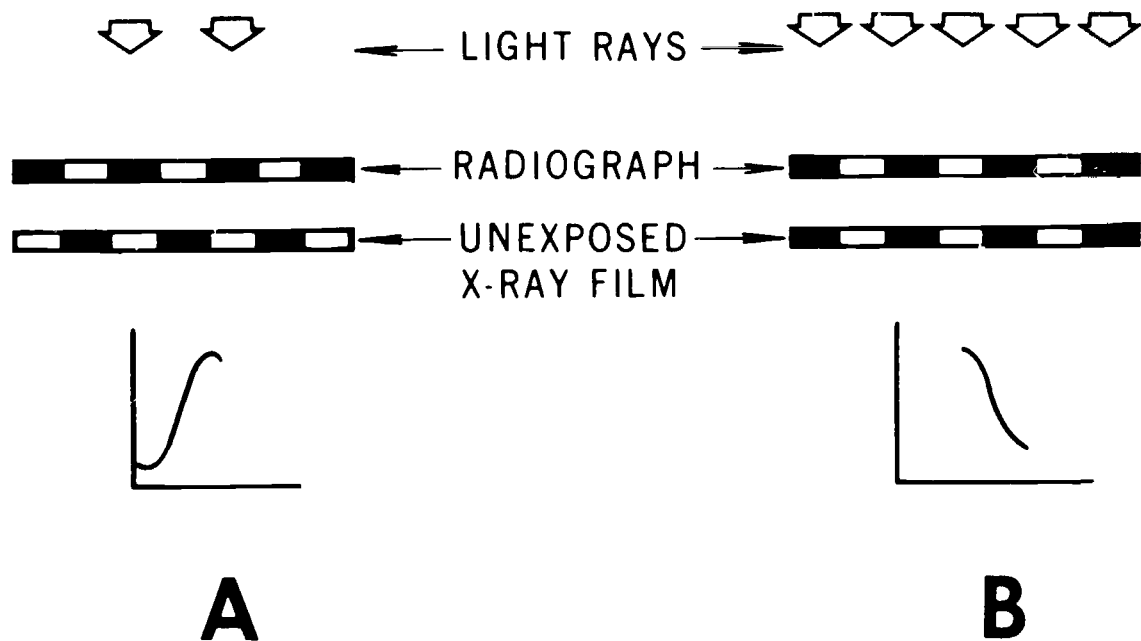


Figure 8-3

A typical duplicator can also perform subtraction procedures. The printer is kept in a darkroom so that copying film will not be accidentally exposed to white light. The unit has a pressure cover that must be raised so that film can be placed on a flat glass surface. Beneath the glass is an ultraviolet light source. A radiograph that is to be copied is placed on the glass and a sheet of duplicating film is placed on top of radiograph. Remember to place the emulsion side of the duplicating film in contact with the original film. The radiograph and copying film are arranged so that the exposing light passes through the radiograph to the emulsion of the duplicating film.

The cover is lowered and secured by latches to hold the two sheets of film firmly together. The copy film is now ready to be exposed.

The light exposure is controlled by a timer which is calibrated in seconds. The timer is activated by a "start" button and is usually set at about 4 seconds for an average radiograph. The initial exposure setting depends upon the density of the radiograph. For example, if the radiograph is light and you want the copy to be darker, then you can adjust the exposure timer differently for the initial copy. The timer can also be adjusted to correct a subsequent copy. Because copy film is a reversal film, increasing exposure reduces the density produced on a duplicating film. Thus a duplicate which is too low in density is corrected by decreasing the exposure. If the density of the copy is too high—that is, the copy is too dark—then the exposure should be increased to lower the density. After exposure, the film is processed routinely.

#### Exercises (470):

1. Explain how to make a special cassette for copying radiographs from a standard cassette.
2. Why should the front of a copying cassette be kept clean and free of scratch marks?
3. How should the two films (radiograph and duplicating film) be placed in a special cassette?
4. Why should there be close, even contact between the radiograph and duplicating film?
5. What type of light source should be used to expose the film in a copying cassette?

- 6 What specific exposure time and source-to-film distance should you use when copying a radiograph with a special cassette?
- 7 If a duplicate of a radiograph is too dark, how can the exposure be corrected on a subsequent duplicate?
- 8 If a radiograph is initially too light, can you produce a duplicate which is darker? How?
- 9 What is an advantage of copying radiographs with a commercial duplicator?
10. When using a commercial duplicator, what firmly holds the radiograph and copying film in contact with each other?
- 11 What device controls the exposure in a commercial duplicator?
12. What should you do to correct a copy that is too light that you made with a commercial duplicator?

## 8-2. Subtraction

Subtraction is a procedure that eliminates unwanted shadows from a radiograph. Specifically, the technique is usually used to eliminate all of the anatomical structures from an angiogram, leaving only an image of the contrast-filled vessels. Several methods of subtraction have been developed and used successfully, including electronic subtraction using television pickup tubes that display the vessels on a monitor. Subtraction fluoroscopy also is being performed with some success.

**471. State the principles involved in the subtraction process.**

**Principles of Subtraction.** Basically, subtraction removes the unwanted shadows from a radiograph by reducing or eliminating the contrast between those shadows. To illustrate how the contrast is affected, we have assembled some drawings in figure 8-4. Assume that drawing A represents a *base film* taken before the injection of the contrast medium during an angiogram. The figures in

the drawing would represent the bony structures (NOTE: In actuality, the bony structures would be represented by more than the two densities shown.) In drawing B we have added three more structures that represent the contrast-filled vessels on an angiogram.

Drawing C represents a negative of the base film and is called the *subtraction mask*. The tones of the mask are reversed from those of the base—that is, the dark areas on the base are light on the mask, and the light areas on the base are dark on the mask. The large circle, which was gray on the base film, is also gray on the mask.


Now if we superimpose films B and C, the appearance resembles drawing D in the figure—a dark background with the contrast-filled vessels appearing alone and light. Thus, the bony structures that may interfere with the interpretation of the vessels are canceled out or “subtracted” from the angiogram.

So we removed the unwanted shadows by reducing or eliminating the contrast. Think for a minute about what happens to the densities. The dark structures or areas become dark when superimposed over the light structures. Likewise, gray structures superimposed over gray structures become dark. The contrast-filled vessels that are included only on the angiogram remain visible. Consequently, except for the contrast between the vessels and the remaining dark background, the contrast on the angiogram is more or less eliminated.


### Exercises (471):

1. How does subtraction remove structures that may interfere with interpretation?
2. What is the subtraction mask?
3. Gray structures on the base film are what color on the mask?
4. How is a high contrast produced between the contrast-filled vessels and background?
5. What effect does the mask have on the background around the contrast-filled vessels?
6. What causes the structures to be subtracted?

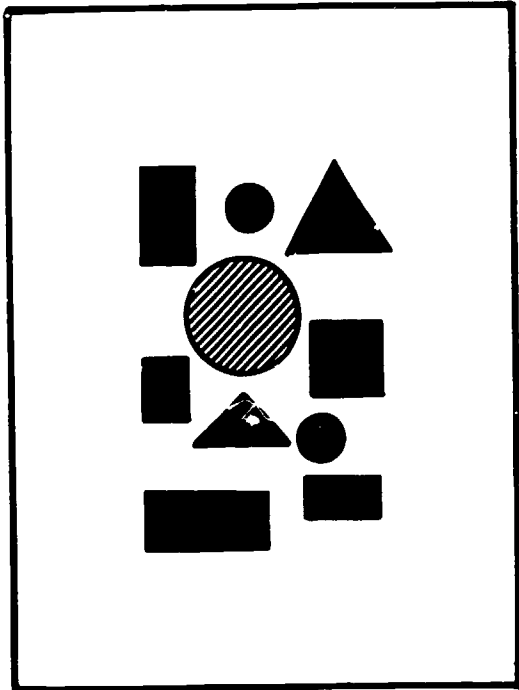




**A**



**B**



**C**



**D**

Figure 8-4

**472. State significant procedural details and requirements in performing subtraction.**

**Performing Subtraction.** Let us now look at a simple method for performing subtraction. The only equipment you will need is a supply of subtraction film, a 10- or 15-watt incandescent light bulb, and a glass-front cassette (the same as the one used to duplicate radiographs).

**Base film.** One of the key factors that influences the degree of subtraction achieved is whether there is part-motion between the base film and the angiogram. Good subtraction can be achieved only if the structures on the mask and angiogram (except for the vessels) are exactly superimposed. If the patient moves during the interval between the base film and angiogram, you will not be able to precisely superimpose the structures. For this reason, subtraction is usually done in conjunction with an examination performed with an automatic film changer, where the time lapse between the base film and the angiogram is minimal.

Obviously, sometimes the patient will move even when you use an automatic changer. Movement may be simply due to the patient's condition or it may be due to the feeling he or she experiences as the contrast material is injected. When movement occurs that keeps you from superimposing all of the structures, try to superimpose those in the area of greatest interest.

**Mask.** To make the subtraction mask, place the base film in the special cassette against the glass front, then put the subtraction mask film in the cassette with the emulsion (dull) side *away* from the base film. Expose the cassette to a 10- or 15-watt incandescent light bulb at a distance of 6 feet. Exposure time usually ranges from 2 to 30 seconds, depending upon the brand of film, the intensity of the light, and the density of the base film.

Another key factor in the subtraction process is whether the differences between the densities on the base are maintained on the mask. For example, if the densities of two bony structures on a base film are 1.5 and 0.5, the density ratio is 3 to 1. To eliminate the contrast between those structures, their respective densities on the mask must exist in a ratio of 1 to 3—for example, 0.5 and 1.5.

**Subtraction print.** So far we have only discussed superimposing the mask and the angiogram on a viewbox so that the radiologist can interpret the results directly. Some radiologists may wish to make a *subtraction print* of the results.

To make a print, place the superimposed mask and angiogram (taped together) in the special cassette with the mask against the glass. Place either a standard X-ray film or a subtraction print film on top of the angiogram. The standard film usually gives in higher contrast. If a subtraction print film is used, place its emulsion side *against* the angiogram. Expose the film to the same light source at the same distance as before. Exposure time is determined by trial and error, but you will need a longer exposure than when you made the mask because you now

have two films between it and the light source. The subtraction print will show the contrast-filled vessels to be dark against a light background.

These film placement steps are the same if you use a commercial subtraction unit.

**Exercises (472):**

1. Why is it important that there be no part motion between the base film and the angiogram?
2. Why is subtraction usually done for examinations performed with an automatic film changer?
3. If part motion occurs between the base film and the angiogram, what action should you take when you perform the subtraction?
4. How do you make the subtraction mask?
5. What relationship must exist between the densities of the structures on the base film and the densities of the structures on the mask (other than reverse tones)?
6. On what types of film can a subtraction print be made?
7. What films are placed inside the special cassette to make a subtraction print and in what order?
8. Why do you need more exposure when making the print than when making the mask?
9. How do the tones of the subtraction print compare with those seen when the mask and angiogram are viewed directly?

## Bibliography

### Books

- Ballinger, Phillip W , *Merrill's Atlas of Radiographic Positions and Radiologic Procedures*, 5th edition, St. Louis, Missouri: C.V. Mosby Company, 1982
- Bartrum, Royal J., Jr., and Harte C. Crow, *Gray-Scale Ultrasound*, Philadelphia, Pennsylvania: W.B. Saunders Company, 1977.
- Bushong, Stewart C., *Radiologic Science for Technologists*, 2nd edition, St. Louis, Missouri: C.V. Mosby Company, 1980.
- Eastman Kodak, *The Fundamentals of Radiography*, 12th edition, Rochester, New York: Eastman Kodak Company, 1980.
- Ehrlich, Ruth Ann, and Ellen McCloskey Givens, *Patient Care in Radiography*, St. Louis, Missouri: C.V. Mosby Company, 1981.
- General Electric, *Introduction to Computed Tomography*, General Electric, 1976.

### Department of Air Force Publication

AFM 160-30, *Radiologic Technology*

# ANSWERS FOR EXERCISES

## CHAPTER 1

### Reference:

- 400 - 1 (1) a, d  
(2) c  
(3) e  
(4) b  
(5) p  
(6) h  
(7) e
- 401 - 1 Fibrous and glandular (fibroglandular) tissue are about equal, fatty tissue is the least dense of the three types
- 401 - 2 Atrophic because it consists entirely of fatty tissue
- 401 - 3 Adolescent and lactating
- 402 - 1 F 0.5 mm is required
- 402 - 2 F While this statement is partially true, it is incomplete. Remember, the focal-spot must also be able to withstand the heat generated by the exposures
- 402 - 3 T
- 402 - 4 F The single exposure rating of the tube must also be considered
- 402 - 5 T
- 402 - 6 T
- 402 - 7 T
- 402 - 8 F It has a small aperture
- 402 - 9 T
- 403 - 1 The detail produced on the radiographs is inadequate
- 403 - 2 Standard films are coarse-grained, while industrial or mammographic films are fine-grained
- 403 - 3 Use commercial film packages, or combine films of various speeds in a direct exposure holder
- 403 - 4 It permits good visualization of both thick and thin portions of the breast from a single exposure
- 403 - 5 High-detail screens made especially for mammography
- 403 - 6 A disadvantage is loss of detail, advantages—reducing part motion and reducing the number of heat units
- 404 - 1 Twenty to thirty since the absorption properties of fibroglandular, fatty, and pathological tissue are nearly equal. The low kVp range is necessary to provide adequate contrast on the radiograph
- 404 - 2 Up to 50. A certain amount of muscle tissue must be penetrated
- 404 - 3 FFD, film speed, and whether intensifying screens are used
- 404 - 4 Part motion. By using the shortest exposure time possible
- 404 - 5 Twenty to forty inches
- 404 - 6 Advantages (1) increased detail and (2) lower patient skin dose, disadvantage requires more exposure
- 404 - 7 Advantage requires less exposure, disadvantages (1) detail loss due to increased magnification and (2) higher skin dose to the patient
- 405 - 1 F On the craniocaudal and the mediolateral projections
- 405 - 2 T
- 405 - 3 T
- 405 - 4 F Firm contact is important so that the posterior portion of the breast is included on the film
- 405 - 5 T
- 405 - 6 T
- 405 - 7 T
- 405 - 8 T

- 405 - 9 F It depends upon the relative position of the tail of the breast
- 405 - 10 i
- 406 - 1 Both use conventional X-ray equipment
- 406 - 2 In xeroradiography, image is recorded by photoelectric rather than photochemical process, special (selenium coated) plates are used, processing is dry. Conventional process uses photographic film, processing is wet
- 407 - 1 (1) c  
(2) e  
(3) a  
(4) b  
(5) d
- 408 - 1 Discharge is a reduction in the positive surface charge on the selenium plate
- 409 - 1 (1) c  
(2) e  
(3) g  
(4) f  
(5) a  
(6) b  
(7) d

## CHAPTER 2

- 410 - 1 Two types of tissue (gonadal and immature growing) are present in these patients, these types are highly susceptible to irreversible alteration from exposure to ionizing radiation
- 410 - 2 Improper positioning can prevent accurate evaluation of the radiographs
- 410 - 3 Repeat examinations due to improper positioning
- 410 - 4 (1) Ask the patient to tell you when there is no noticeable fetal motion, (2) have the patient breathe deeply several times and hold her breath before the exposure, and (3) use the shortest exposure time possible
- 410 - 5 Use high-speed screens and films, use high kVp and low mAs, and use reliable exposure techniques
- 411 - 1 T
- 411 - 2 F Visualization can occur as early as 12 weeks
- 411 - 3 F Exposure is more dangerous at 14 weeks
- 411 - 4 F Superimposition of the sacrum and fifth lumbar vertebra is important
- 411 - 5 T
- 411 - 6 T
- 411 - 7 T
- 411 - 8 F Demonstration of the fetal skull bones is important because overlapping of the bones can be a sign of fetal death
- 411 - 9 T
- 411 - 10 F Anencephaly is absence of the skull
- 412 - 1 The radiologist or the obstetrician
- 412 - 2 On the iliac crest
- 412 - 3 Symphysis pubis
- 412 - 4 On the AP projection
- 412 - 5 The patient can support herself on her knees and forearms, or you can place supports beneath her chest, extreme lower pelvis, and lower extremities
- 412 - 6 PA
- 412 - 7 Posterior
- 412 - 8 Information derived from the PA or AP projection

- 412 - 9 The position of comfort
- 413 - 1 (1) AP diameter—inlet, lateral projection  
(2) AP diameter—midpelvis, lateral projection  
(3) AP diameter—outlet, lateral projection  
(4) Transverse diameter inlet, AP projection  
(5) Transverse diameter midpelvis, AP projection  
(6) Transverse diameter outlet, AP projection
- 413 - 2 To determine the degree of magnification of the pelvic diameters
- 413 - 3 Between the gluteal folds, the level is the same as that of the AP pelvic diameters
- 413 - 4 At the same level as the ischial tuberosities, the level is the same as that of the transverse pelvic diameters
- 413 - 5 Palpate the upper margin of the symphysis pubis, and set the perforated ruler 10 cm below that margin
- 414 - 1 It would cause the AP pelvic diameters to measure longer than they actually are, consequently, the pelvis may be judged to be adequate for delivery, and may not actually be adequate, evaluation of the pelvis is inaccurate because the spaces between the ruler dots are magnified less than they should be
- 414 - 2 It would cause the AP diameters to measure shorter than they actually are, which could cause the pelvis to be judged inadequate, the mistaken diagnosis is caused by the spaces between the ruler dots being magnified more than they should be
- 414 - 3 Same answer as for exercise #1 (above) except that the transverse diameters, instead of the AP diameters, are affected
- 415 - 1 Mistakes are (1) failure to properly align the pelvis, (2) failure to include the ruler on the film, and (3) overexposure of the film  
Mistake No (1) obscures the ischial spines and prevents accurate measurement of the transverse diameter of the midpelvis, and makes other transverse measurements difficult. This mistake may be avoided by adjusting the median plane perpendicular to the table  
The effect of No. (2) is that magnification of the transverse diameters cannot be determined and the radiograph is of no use. It may be avoided by centering the film 1/2 inches above the symphysis pubis  
Mistake No (3) may prevent identification of bony landmarks between which transverse diameters are measured. It may be avoided by measuring through the CR
- 416 - 1 Errors are (1) positioning the patient so the pelvis is anteriorly rotated and (2) superimposing the femurs over the symphysis pubis  
Error No (1) shortens AP pelvic diameters and results in low measurements. It may be prevented by performing the lateral erect or elevating the anterior abdomen, superimposing the legs exactly, and placing supportive material between the knees and ankles.  
Error No (2) will result in the anterior ends of the AP diameters not being visualized. To avoid this error, extend the femurs
- CHAPTER 3
- 417 - 1 A series of repeating pressure disturbances of molecules, mechanical vibrations of particles.
- 417 - 2 Sound needs a medium through which to travel, a vacuum is void of particles
- 417 - 3 A measurement of peak pressure or strength of a sound wave.
- 417 - 4 The density or type of material it is passing through
- 417 - 5. The number of times a sound wave is repeated per second
- 417 - 6. A frequency of one million cycles per second.
- 417 - 7 Ultrasound frequency is much higher (1 to 20 MHz) than that of audible sound (20 to 20,000 Hz).
- 417 - 8 Ultrasound velocity is much faster in human soft tissue (1540 meters per second) than audible sound velocity is in air (331 meters per second).
- 417 - 9 Ultrasound wavelengths are much shorter (0.3 to 1.5 mm) than those of audible sound (2 to 200 cm)
- 417 - 10 Ultrasound amplitude is much lower than the amplitude of audible sound
- 418 - 1 A pulse of sound that strikes an object is reflected back to the source of the sound
- 418 - 2 When it is reflected by an object
- 418 - 3 To measure distances between the source of sound and the object that causes the reflection of the sound
- 419 - 1 To create a sound pulse and receive an echo
- 419 - 2 A surface that forms a common boundary between two tissues
- 419 - 3 An interface causes a sound pulse to be reflected, therefore, an interface produces echoes
- 419 - 4 Two tissues of different densities (acoustic impedance) coming in contact with each other
- 419 - 5 Acoustic impedance can be considered the same thing as the density of tissue
- 420 - 1 (1) b  
(2) c  
(3) a  
(4) a
- 421 - 1 (1) a  
(2) c  
(3) c  
(4) b
- 421 - 2 Watts per square centimeter ( $W/cm^2$ )
- 421 - 3  $100 mW/cm^2$
- 421 - 4 Yes. Because power levels presently used are far below the level needed to produce damaging effects
- 422 - 1 Creates a sound pulse and receives an echo
- 422 - 2 Piezoelectric effect
- 422 - 3 The ability of a crystal to change shape and convert an electrical signal into a sound wave and vice versa
- 422 - 4 The echo causes the crystal to oscillate which produces a weak electrical signal
- 422 - 5 To cushion or stop the vibration of the crystal
- 422 - 6 One percent
- 422 - 7 The case
- 422 - 8 The wavelength of the transducer
- 422 - 9 The face plate and the crystal
- 423 - 1 Resolution is greatly improved with a focused beam as compared to an unfocused beam
- 423 - 2 Fresnel (near) and Fraunhofer (far)
- 423 - 3 Fresnel
- 423 - 4 By the concave shaping of the crystal
- 423 - 5 Acoustic lenses
- 423 - 6 To visualize structures at various levels within the body
- 424 - 1 The ability of the ultrasound system to identify closely spaced interfaces that lie along the path of the beam
- 424 - 2 The length of the ultrasound pulse
- 424 - 3 An image is easily resolved when echoes clearly show distinct and separate interfaces.
- 424 - 4 They are separated by less than one-half pulse length
- 424 - 5. Because as the frequency increases, the wavelength and length of the pulse decreases
- 424 - 6 The ability to identify two closely spaced interfaces that are perpendicular to the long axis of the beam
- 424 - 7 The diameter or width of the beam
- 424 - 8 Poor lateral resolution, those two echoes will overlap and appear as one echo.
- 424 - 9 The smaller the beam width, the better the lateral resolution
- 425 - 1 Oscilloscope and television
- 425 - 2 The stronger the echo amplitude, the greater the intensity of the electron beam and the brighter the image
- 425 - 3. Intensity of an echo signal
- 425 - 4 As distance increases between a transducer and interfaces, echo signals become weaker
- 425 - 5 Adjusting a gain control, such as a TCG, to amplify low gain
- 425 - 6 It holds an entire image on the screen
- 425 - 7 It assigns a shade of gray to each echo to enable gray scale imaging

- 425 - 8. Television
- 426 - 1 (1) a  
(2) b  
(3) b  
(4) b  
(5) a  
(6) b  
(7) c  
(8) a
- 427 - 1 As spikes (vertical deflections) on the oscilloscope
- 427 - 2 Distances between interfaces
- 427 - 3 A-mode appears as spikes, B-mode appears as dots
- 427 - 4 Scanning
- 427 - 5 B-mode
- 427 - 6 Gray scale and real-time imaging
- 427 - 7 Real-time
- 427 - 8 Real-time
- 427 - 9 M-mode
- 427 - 10 Doppler
- 428 - 1 Transverse scanning produces an image of cross-sectional anatomy at a particular slice or level of the body from side to side, longitudinal scanning shows an image of cross-sectional anatomy as a longitudinal slice of the body along or parallel to the median plane
- 428 - 2 It helps you locate organs and ensures accurate scanning of structures you want to visualize
- 428 - 3 Xiphoid, umbilicus, symphysis pubis, and iliac crest
- 428 - 4 Longitudinal scanning is parallel to the median plane and visualizes anatomy in increments of usually 1 centimeter on both sides of the median plane
- 428 - 5 To identify the location of the scan to some reference point and, sometimes, to identify whether it is a transverse or longitudinal scan
- 428 - 6 As if you were looking at a supine patient with the head of the patient to your left and feet to your right
- 429 - 1 a Linear scanning involves moving the transducer in a straight line across the skin without angling the sound beam  
b Sector scanning requires an angular or pivoting movement of the transducer at one location on the body so that the sound beam is rotated about the transducer face.  
c Compound scanning, a combination of linear and sector scanning, requires repeated straight movements without angling the sound beam and pivotal movements where the sound beam is angled  
d Arc scanning calls for moving the transducer over the body with the beam directed to a central point within the patient
- 429 - 2 Compound
- 430 - 1 An increase or decrease in the number of interfaces due to a change in the acoustic impedance of the tissue being scanned
- 430 - 2 The ability to identify visual differences between normal and abnormal tissues.
- 430 - 3 An area of dense tissues with many interfaces and increased echoes
- 430 - 4 A structure that doesn't reflect echoes, few interfaces
- 430 - 5 An acoustic shadow
- 430 - 6 A structure of homogenous density, usually lighter in gray tones than adjacent tissues
- 430 - 7. A dense membrane of the placenta, produces a strong echo that shows up as a bold, black-line interface
- 431 - 1. Fasting helps to maximize dilation and prevent the physiologic contraction and emptying of the gallbladder.
- 431 - 2 Colas produce gas in the lower stomach and duodenum which can hinder visualization of the pancreas
- 431 - 3 Because the barium used in G.I. studies produces acoustic shadows that may obscure the pancreas.
- 431 - 4 Make sure all equipment is operational, all supplies are at hand, the room is clean and not too cool, and clean sheets are on the table or gurney
- 431 - 5 It serves as an acoustic coupling agent to eliminate an air gap between the transducer and patient, thereby ensuring proper transmission of the beam
- 432 - 1 Longitudinal scans, begin at the midline
- 432 - 2 To determine its entire length
- 432 - 3 Confirmation of gallstones and evaluation of gallbladder disease
- 432 - 4 Suspended deep inspiration Pushes the gallbladder caudally so that ribs don't interfere with the sound beam
- 432 - 5 To evaluate stone movement and eliminate gas shadows
- 432 - 6 Cirrhosis
- 432 - 7 Sector scanning To avoid interference of ribs with the sound beam
- 432 - 8 " produces very dark echoes that are similar to adjacent tissues
- 432 - 9 enlarges the pancreas and decreases its echo production
- 432 - 10 Splenic vein
- 433 - 1 Prone
- 433 - 2 Hold in a deep breath
- 433 - 3 15° cephalic
- 433 - 4 Central collecting system
- 433 - 5 Calculi.
- 433 - 6 Supine
- 434 - 1 Sector scanning
- 434 - 2 Fecal material and gas in the sigmoid colon or rectum
- 434 - 3. A fetus is not biologically damaged by ultrasound, and much information about a pregnancy is learned with the exam
- 435 - 1 Because it is filled with fluid
- 435 - 2 A-mode and B-mode
- 435 - 3 To determine whether the nodules are cystic or solid
- 435 - 4 Manubrium.
- 435 - 5 The contour of the breast is easily distorted
- 435 - 6 To identify and localize tissues that should be protected from damaging radiation.
- 435 - 7 Echoencephalography.
- 435 - 8 A transducer is placed on the temporal region of the skull and held stationary

#### CHAPTER 4

- 436 - 1 Radiography of sections of the body
- 436 - 2 Radiograph produced by tomography
- 436 - 3 A connecting rod which couples the tube and film carrier (cassette tray)
- 436 - 4 The point about which the lever pivots
- 436 - 5 Body layer which appears sharpest on the tomogram
- 436 - 6. Unsharp body area outside (above or below) the focal plane
- 436 - 7 Distance in inches the tube travels during exposure
- 436 - 8 Speed of the tube travel (usually expressed in inches per second).
- 436 - 9 Angle in degrees of the tube travel during exposure
- 436 - 10 Tomography with a small exposure angle—less than 10°
- 437 - 1 Sinusoidal
- 437 - 2 Elliptical
- 437 - 3 Circular.
- 437 - 4 Spiral
- 437 - 5 Hypocycloidal
- 437 - 6. Random
- 437 - 7. Linear
- 438 - 1 Its relative position on the film is the same throughout the exposure
- 438 - 2 Its relative position on the film shifts during the exposure.
- 438 - 3 Objects located in the focal plane are not blurred because their relative positions on the film do not change during the exposure
- 439 - 1 A layer or section of the body
- 439 - 2 How close the target is to the focal plane
- 439 - 3 Sharp, blurred
- 439 - 4 A large angle
- 439 - 5 A small angle
- 440 - 1. T
- 440 - 2 F A long amplitude produces a thin section
- 440 - 3 F There is (the longer the FFD at a given amplitude, the smaller the exposure angle)

- 440 - 4 F The structures are projected by different exposure angles. The farther a structure is from the focal plane, the greater the exposure angle
- 440 - 5 T
- 440 - 6 T
- 440 - 7 T
- 441 - 1 Three
- 441 - 2 Bottom (remote from tube) Top (nearest the tube)
- 441 - 3 Photons are absorbed as they pass through the films, screens, and interspace material, variable speed screens compensate for the absorption
- 441 - 4 0.5 mm
- 441 - 5 Each film has, in effect, its own fulcrum due to the space between the films
- 441 - 6 15 cm 11 cm
- 442 - 1 Because of the relatively low book exposure compared to the combined individual exposures
- 442 - 2 No Because the exposure required for the book is more than that required for a single exposure due to the speed of the top pair of intensifying screens
- 442 - 3 It reduces it because several cuts are done at the same time
- 442 - 4 (1) The lower films provide less good detail than the upper films because the lower intensifying screens are faster  
(2) Contrast is reduced on the lower films because more scattered photons are present
- 443 - 1 Approximately 150 mAs
- 443 - 2 Approximately 100 mAs
- 443 - 3 The tissue thickness is greater due to the angle of the tube
- 444 - 1 Sec = 3
- 444 - 2 Amplitude = 8 inches
- 444 - 3 Rate = 5 inches per second
- 445 - 1 T
- 445 - 2 T
- 445 - 3 T
- 445 - 4 T

#### CHAPTER 5

- 446 - 1 A computer reconstructs a cross-sectional tomographic plane of part of the body by collecting measurements at multiple points about the part's periphery
- 446 - 2 Remnant radiation is measured by detectors, which produces an electronic signal that is converted into a numerical value of density by the computer
- 446 - 3 CT has no image receptor, such as film, that is common to routine radiography
- 446 - 4 A detector
- 447 - 1 (1) b  
(2) a  
(3) b  
(4) b  
(5) a  
(6) a  
(7) a
- 448 - 1 The X-ray tube, the detector array, the high-voltage generator, and the patient support and positioning couch
- 448 - 2 Because its subsystems are used to produce and collect the X-ray attenuation information
- 448 - 3 CT must have an anode heating capacity of at least 400,000 heat units and high-speed rotors to dissipate heat
- 448 - 4 X-ray tube
- 448 - 5 Scintillation and gas-filled detectors.
- 448 - 6 Measure remnant radiation and transmit an electronic signal to the computer.
- 448 - 7 The crystal emits a flash of light when irradiated, the photomultiplier changes light flashes to electrical signals and finishes the transmission to the computer
- 448 - 8 a Supports the patient comfortably  
b Built of a low atomic number material  
c Smoothly and accurately motor driven  
d Indexes automatically
- 448 - 9 Automatic indexing, because the table automatically advances the patient for each consecutive slice without the operator entering the room between slices
- 449 - 1 a Receive data  
b Analyze data  
c Assign values for linear attenuation coefficients  
d Change data into a video image
- 449 - 2 A numerical value that indicates the degree that the X-ray beam is attenuated by a particular part of the body
- 449 - 3 The linear attenuation coefficient increases as the kVp decreases, and vice-versa
- 449 - 4 The higher the atomic number the higher the linear attenuation coefficient
- 449 - 5 A pixel (picture element) is a two-dimensional representation of a corresponding tissue volume, a small section of a CT image
- 449 - 6 A voxel (volume element) is the area of a pixel multiplied by the thickness of the slice
- 449 - 7 A CT number
- 449 - 8 A CT number indicates a particular level of optical density for the reconstruction process of a CT image
- 449 - 9 Blood has a higher CT number because its atomic density is higher than fat's
- 450 - 1 The kVp range is usually set above 100 up to about 120, mA ranges are 20-50 mA for continuous beam units up to several hundred mA (about 400) for pulsed beam units
- 450 - 2 1.5 mm, 5 mm, and 10 mm (1 cm).
- 450 - 3 Increase radiographic technique, because thinner slices are produced by collimation, which causes a reduction in exposure to the patient and a decrease in detectable remnant radiation
- 450 - 4 It allows a physician to review previous images and manipulate images without interfering with scanning procedures.
- 450 - 5 Contrast and density, region of interest, and magnification
- 450 - 6 The window
- 450 - 7 The level
- 450 - 8 As you increase the level, you increase the optical density, which makes the image darker
- 450 - 9 Floppy magnetic disks and magnetic tapes
- 450 - 10 The instant camera photograph or a multiformat camera system with X-ray film
- 451 - 1 (1) c, d  
(2) d  
(3) a  
(4) a, b  
(5) c  
(6) a  
(7) a  
(8) b  
(9) d  
(10) c
- 452 - 1 NPO at least 4 hours before the exam, to help prevent vomiting should the patient feel nauseous during administration of contrast media
- 452 - 2 NPO after midnight to prevent food from being in the digestive tract, and a standard bowel preparation to remove any residual barium.
- 452 - 3 To enhance specific areas to better show tissue differentiation
- 452 - 4 Orally and intravenously
- 453 - 1 a Desired plane of anatomy that is to be imaged  
b The ability of the patient to cooperate  
c The limitation of the gantry angulation  
d The diameter of the gantry opening
- 453 - 2 15° to 20° to the OML
- 453 - 3 Make sure the patient is positioned as accurately as possible and have the patient comfortable
- 453 - 4 A loss of diagnostic information
- 453 - 5 Cushioning the head and placing pillows under the knees, whenever possible, and use retraining straps if needed to immobilize the patient
- 454 - 1 1.5 mm to 5 mm; because a thinner cut produces finer detail
- 454 - 2 1 cm
- 454 - 3 Use a thin cut, such as 1.5 mm, and overlap continuous slices

- 454 - 4 1 cm slices taken at every other centimeter
- 454 - 5 9 to 11
- 454 - 6 28 to 32 (double the routine number without contrast media)

#### CHAPTER 6

- 455 - 1 (1) To determine the numerical length of a long bone  
(2) To determine the relative lengths of two opposite bones
- 455 - 2 The CR is perpendicular to the film in both cases. For a conventional radiograph, the CR is directed to the middle of the part and film. For a scanogram, the CR is directed to each end of the bone
- 455 - 3 The bone is magnified on the conventional radiograph; it is projected actual size on the scanogram
- 455 - 4 The ends of the bone are projected by divergent portions of the primary beam on the conventional radiograph and by the CR (nondiverging beam) on the scanogram
- 456 - 1 F Because it is radiopaque, the kVp should be raised by 10
- 456 - 2 T
- 456 - 3 F The ruler and patient should never be moved, but the film may be moved, depending upon the method employed and whether the tube is always shifted between exposures
- 456 - 4 F All scanograms are done by AP projections
- 456 - 5 T
- 456 - 6 T
- 456 - 7 T
- 456 - 8 T
- 456 - 9 T
- 456 - 10 F When you do an actual length scanogram without a ruler, the film must be long enough to project the entire length of the bone. The entire adult femur cannot be projected on a 10- by 12-inch film
- 456 - 11 T
- 456 - 12 T
- 457 - 1 B (C may also be correct, but you cannot tell from the information provided)
- 457 - 2 None (C may project a shorter image, but you cannot tell from the information provided)
- 457 - 3 A (C may also project a longer image, but you cannot tell from the information provided)
- 457 - 4 The CR for the lower X-ray field is aligned correctly. You cannot make any conclusions about the CR alignment for the upper field because you cannot see the entire X-ray field. For all you know, the field may measure 10 or 15 inches from top to bottom
- 458 - 1 (1) b  
(2) c  
(3) b  
(4) a  
(5) c  
(6) c  
(7) c  
(8) b  
(9) a
- 459 - 1 The lateral surface is shaved. The skin is cleaned and prepared, as directed by your radiologist. Surgical soap, alcohol, zephiran chloride, tincture of iodine, or a combination of these items may be used. The area is draped with sterile towels or sheets
- 459 - 2 Water soluble
- 459 - 3 a 10 to 15 cc  
b 20 or more cc
- 459 - 4 Air, oxygen, or carbon dioxide
- 459 - 5 To keep dilution of the contrast medium to a minimum
- 459 - 6 (1) By massaging the knee  
(2) By allowing the patient to stand and walk around  
(3) By wrapping the knee in an ace bandage
- 459 - 7 Before the lateral radiographs are made to permit visualization of the quadriceps pouch
- 460 - 1 F The PA projection is usually taken with a vertical CR but the AP is taken with the CR angled 5° cephalic, both are done this way to open the joint space

- 460 - 2 F Obliques of 30°, 45°, 60°, or 75° may be made
- 460 - 3 F Speed is important to accomplish the radiographs before the contrast medium disappears from the joint capsule
- 460 - 4 T
- 460 - 5 T
- 460 - 6 F It is difficult to determine the exact location of the joint space. You should have your radiologist mark the space under fluoroscopy

#### CHAPTER 7

- 461 - 1 T
- 461 - 2 T
- 461 - 3 F Neonates are kept in reverse isolation to protect themselves from outside infections
- 461 - 4 F An incubator is a device that provides extra warmth, moisture, and oxygen to an infant while reducing the possibility of airborne infections
- 461 - 5 F Never remove an infant from an incubator without first checking with the nursing personnel
- 461 - 6 F You can radiograph an infant in an incubator by having the nursing personnel position the baby and cassette while you control the X-ray machine
- 461 - 7 F Always move a patient towards a tube to prevent dislodging that tube
- 461 - 8 T
- 461 - 9 T
- 461 - 10 F Although an oxygen supply should be turned off during an exposure, you should never be the one to do it—only nursing personnel
- 462 - 1 A specialized method of medical asepsis that is used when the danger of transmitting disease is great.
- 462 - 2 *Strict isolation* confines the disease to the patient and immediate surroundings, *reverse isolation* protects the patient from potential infection
- 462 - 3 Neonatal nursery patients and burned patients.
- 462 - 4 You should wear a gown, mask, and gloves. All equipment must be decontaminated or discarded before reuse
- 462 - 5 The equipment is decontaminated or discarded after a strict isolation procedure and before reuse, whereas, it is disinfected before a reverse isolation procedure
- 462 - 6 This enables one technician to operate the equipment and the other to position the patient. One remains "clean" and the other "contaminated," depending upon the type of isolation
- 462 - 7 The clean technician comes in contact with the patient during positioning
- 462 - 8 The contaminated technician operates the X-ray equipment and avoids direct contact with the patient
- 463 - 1 (1) d  
(2) a  
(3) a, b, c, d  
(4) a, b  
(5) c  
(6) a  
(7) d  
(8) a, b  
(9) a  
(10) d
- 464 - 1 12 inches
- 464 - 2 0.25 mm
- 465 - 1 To reduce the amount of bacteria introduced into the operating room and to prevent the buildup of static electricity
- 465 - 2 They may produce static electricity
- 465 - 3 Through a conductive strap (which is in contact with your skin) attached to the conductive sole of the covers
- 465 - 4 The preference of the chief of surgery and the physical arrangement of the surgical suite
- 466 - 1 To reduce the bacteria introduced into the operating room
- 466 - 2 By thoroughly wiping it down with hand towels soaked in an antiseptic solution provided by operating room personnel



- 466 - 3 (1) Tube head—it is usually positioned directly over the operating site  
 (2) Wheels—they are especially dirty because of their repeated contact with the floor  
 (3) Power cord—it is especially dirty because of its repeated contact with the floor
- 466 - 4 Cover the tubehead with a sterile pillowcase or sheet of clear plastic
- 467 - 1 (1) Surgeon  
 (2) Surgeon's immediate assistants  
 (3) Part of patient  
 (4) Surgical instruments  
 (5) Tables, trays, and stands containing instruments
- 467 - 2 (1) Anesthetist  
 (2) You  
 (3) Your mobile unit
- 467 - 3 To work in the nonsterile area and, during open surgery, to keep from contaminating or contacting any part of the sterile area
- 468 - 1 To help reduce the overall operation time, and therefore, the amount of the time the patient is under the influence of the anesthetic
- 468 - 2 By using Polaroid films and the accompanying processor
- 468 - 3 Incorrect exposure Keep correct, complete, mobile-unit technique charts Measure the patient if possible beforehand Make a scout film if possible (except for most reduction radiographs of the extremities)
- 468 - 4 Hip nailing when a lateral projection is required and an operative cholangiogram The patient is draped to such an extent that you may not be able to tell exactly where the center of the grid is located
- 468 - 6 Use a grid with a lower ratio
- 468 - 7 Mark the locations of the wheels of the mobile unit on the floor when you make the scout film Later, return the wheels to the same marks

#### CHAPTER 8

- 469 - 1 F An increase in exposure increases film density only to the point (shoulder portion of the characteristic curve) where maximum density is reached After that, additional exposure decreases density
- 469 - 2 T
- 469 - 3 T
- 469 - 4 F Solarization did influence the outcome because the same tones were duplicated If opposite tones had occurred on the duplicate, solarization would have had no influence on the outcome
- 469 - 5 F Because of its composition, standard X-ray film does not produce a duplicate with good detail
- 469 - 6 T
- 469 - 7 F Duplicating film responds differently The more exposure, the less the density—because the emulsion is solarized
- 469 - 8 T
- 470 - 1 Remove the bakelite front and replace it with a sheet of transparent glass or Plexiglas Remove the intensifying screens Glass that is soiled and scratched causes artifacts on the duplicate
- 470 - 2 Place the radiograph in first so that it is against the glass front of the cassette Place the duplicating film in next with the "dull" side against the radiograph
- 470 - 4 To prevent loss of detail
- 470 - 5 Ultraviolet or white, depending upon the recommendation of the manufacturer
- 470 - 6 As recommended by the film manufacturer
- 470 - 7 By increasing the exposure
- 470 - 8 Yes Use less than the normal exposure
- 470 - 9 It eliminates the need for a special copying cassette.
- 470 - 10 The pressure cover when it is secured by latches
- 470 - 11 The timer
- 470 - 12 Adjust the timer to less exposure time, use another duplicating film, and repeat the procedure
- 471 - 1 By reducing or eliminating the contrast between those structures
- 471 - 2 The subtraction mask is a reverse tonal copy of the base film
- 471 - 3 Gray
- 471 - 4 By superimposing the angiogram and the mask
- 471 - 5 It causes them to appear dark
- 471 - 6 The density of the structures becomes equal
- 472 - 1 Motion prevents exact superimposition of the mask and angiogram Good subtraction of the structures occurs only if the structures on the mask and angiogram (except the vessels) are exactly superimposed
- 472 - 2 Part motion is least likely to occur because of the short lapse between the base film and the angiogram
- 472 - 3 Try to superimpose the structures in the area of greatest interest
- 472 - 4 (1) Place the base film in the special cassette against the glass front  
 (2) Place the subtraction mask film in the cassette with the emulsion away from the base film  
 (3) Expose the cassette to a 10- or 15-watt incandescent light bulb at a distance of 6 feet (Exposure time is usually 2 to 30 seconds, depending upon the brand of film, the intensity of the light, and the density of the base film )
- 472 - 5 The differences between the densities must be the same
- 472 - 6 A standard X-ray film or a subtraction film
- 472 - 7 (1) Mask—against glass front  
 (2) Angiogram—taped to the mask  
 (3) X-ray film or subtraction film
- 472 - 8 You now have two films in front of the unexposed film
- 472 - 9 They are reversed

STOP -

1. MATCH ANSWER SHEET TO THIS EXERCISE NUMBER.
2. USE NUMBER 2 PENCIL ONLY.

EXTENSION COURSE INSTITUTE  
VOLUME REVIEW EXERCISE

90370 03 23

SPECIAL TECHNIQUES

Carefully read the following:

**DO'S:**

- 1 Check the "course," "volume," and "form" numbers from the answer sheet address tab against the "VRE answer sheet identification number" in the righthand column of the shipping list. If numbers do not match, return the answer sheet and the shipping list to ECI immediately with a note of explanation.
- 2 Note that item numbers on answer sheet are sequential in each column.
- 3 Use a medium sharp #2 black lead pencil for marking answer sheet.
- 4 Write the correct answer in the margin at the left of the item. (When you review for the course examination, you can cover *your* answers with a strip of paper and then check your review answers against your original choices.) After you are sure of your answers, transfer them to the answer sheet. If you *have* to change an answer on the answer sheet, be sure that the erasure is complete. Use a clean eraser. But try to avoid any erasure on the answer sheet if at all possible.
- 5 Take action to return entire answer sheet to ECI.
- 6 Keep Volume Review Exercise booklet for review and reference.
- 7 If *mandatorily* enrolled student, process questions or comments through your unit trainer or OJI supervisor. If *voluntarily* enrolled student, send questions or comments to ECI on ECI Form 17.

**DON'Ts:**

- 1 Don't use answer sheets other than one furnished specifically for each review exercise.
- 2 Don't mark on the answer sheet except to fill in marking blocks. Double marks or excessive markings which overflow marking blocks will register as errors.
- 3 Don't fold, spindle, staple, tape, or mutilate the answer sheet.
- 4 Don't use ink or any marking other than a #2 black lead pencil.

**NOTE: NUMBERED LEARNING OBJECTIVE REFERENCES ARE USED ON THE VOLUME REVIEW EXERCISE.** In parenthesis after each item number on the VRE is the *Learning Objective Number* where the answer to that item can be located. When answering the items on the VRE, refer to the *Learning Objectives* indicated by these *Numbers*. The VRE results will be sent to you on a postcard which will list the *actual VRE items you missed*. Go to the VRE booklet and locate the *Learning Objective Numbers* for the items missed. Go to the text and carefully review the areas covered by these references. Review the entire VRE again before you take the closed-book Course Examination.

## MULTIPLE CHOICE

*Note to Student* - Consider all choices carefully and select the *best* answer to each question

- 1 (400) The fatty tissue that surrounds the female breast is distributed in the
  - a fatia
  - b fibrous tissues
  - c glandular tissue
  - d retromammary space
  
- 2 (400) The radiographically significant structure of the breast that lies between the posterior portion of the mammary gland and the pectoral muscle is the
  - a mamma
  - b lactiferous
  - c tail of the breast
  - d retromammary space
  
- 3 (401) With regard to exposure requirements during mammography, which type of breast is the least dense?
  - a Adolescent
  - b Atrophic
  - c Mature
  - d Lactating
  
- 4 (401) Concerning exposure requirements during mammography, which type of breast compares with the adolescent breast in terms of density?
  - a Lactating
  - b Menopausal
  - c Atrophic
  - d Mature.
  
- 5 (402) How much filtration should you use when performing a mammogram?
  - a Minimum
  - b 0.5 mm above minimum
  - c 1.5 above minimum
  - d Maximum
  
- 6 (402) When you are selecting the smallest possible focal spot for mammography, two factors to consider are
  - a type and amount of collimation used.
  - b mA and kVp selections available on the radiographic unit
  - c tube and anode storage capacities.
  - d heat units generated by a particular technique and the focal film distance (FFD) used.
  
- 7 (403) Fine-grained X-ray film should be used for conventional mammography because use of such film results in
  - a better detail
  - b lower subject contrast
  - c elimination of photoelectric absorption
  - d slow processing
  
- 8 (404) Why are low (20-30) kVp selections used for mammography?
  - a Low kVp lowers subject contrast
  - b Limited filtration is used
  - c Low kVp results in better subject contrast
  - d Low kVp techniques produce less heat
  
- 9 (404) If you must use a large focal spot for mammography, how can you improve the detail?
  - a Increase the focal film distance (FFD)
  - b Decrease the focal film distance (FFD)
  - c reduce the kVp by four
  - d Use the intensifying screens.

- 10 (404) Why do some radiologists prefer nearly 40 inches focal film distance (FFD) instead of 20 inches FFD for all mammograms with conventional radiography?
- To reduce the required technique.
  - To reduce the skin dose to the patient
  - To increase the amount of irradiated tissue
  - To increase subject contrast
- 11 (405) A patient should be instructed to sit straight and pull her shoulders back for the craniocaudal projection of the breast in order to
- place the nipple in profile
  - reduce the part film distance
  - demonstrate the tail of the breast
  - eliminate unwanted shadows on the radiographs
- 12 (405) Why should the nipple of the female breast be in profile when positioning for the craniocaudal projection?
- Retraction of a nipple on a radiograph could indicate pathology
  - To put lactiferous tubules parallel to the film
  - To put the retromammary space in profile
  - It determines the amount of collimation
- 13 (405) Select the projection of the breast that best visualizes the retromammary space
- |                |             |
|----------------|-------------|
| a Craniocaudal | c Axillary  |
| b Mediolateral | d Dependent |
- 14 (406) In what way is conventional radiography and xeroradiography similar?
- Film plate processing is essentially the same
  - Both use a similar recording medium.
  - Both use the same X-ray equipment.
  - Formation of the image on the recording medium is the same
- 15 (406) Which imaging procedure uses a photoelectric process instead of a photochemical process to record an image?
- Xeroradiography
  - Conventional radiography
  - Cineradiography.
  - Nuclear medicine
- 16 (407) In xeroradiography, relaxation is a process which
- regulates the charge on the selenium plate
  - places the initial charge on the plate
  - removes any previous charge remaining on the plate
  - applies toner to the plate, rendering the image visible.
17. (407) In xeroradiography, the conditioner is used to
- charge the selenium plate.
  - transfer the electrostatic image to paper
  - apply toner to the plate surface, making the image visible
  - discharge the selenium plate, thereby forming the electrostatic image

- 18 (407) The electrostatic charge of selenium plates used in xeroradiography is regulated by
- a a toner
  - b a ionization device
  - c a contrast selector
  - d a relaxation process
- 19 (408) What causes formation of a charge pattern on a selenium plate?
- a Exposure to X-rays
  - b Ionization device
  - c Contrast selector
  - d The conditioner
- 20 (409) The amount of toner attracted to the selenium plate of the xeroradiographic processor depends on the
- a initial charge placed on the plate
  - b temperature of the processor solution
  - c speed of the intensifying screens used in the cassette
  - d charge remaining after exposure, and the back bias voltage applied
- 21 (409) What step in the xeroradiography process causes the image to become permanent?
- a Applying back bias voltage
  - b Applying toner
  - c Fusing
  - d Relaxation
- 22 (410) Identify the most common cause of excessive radiation exposure to an obstetrical patient and fetus
- a High kvp
  - b Part thickness
  - c Faulty equipment
  - d Improper positioning
- 23 (411) What do overlapping skull bones of a fetus indicate during a fetogram?
- a Normal pregnancy
  - b Fetal death
  - c Hydrocephalus
  - d incorrect positioning of the patient
- 24 (411) Identify the first parts of a fetal skeleton that may be visible on a fetogram performed to determine whether or not a patient is pregnant
- a Ossification centers for the vertebral bodies
  - b Distal femoral and proximal tibial epiphyses
  - c Parietal bones of the skull
  - d Tarsal bones
- 25 (412) When optimum detail is of concern, a PA fetogram is preferred to an AP fetogram because the
- a patient's spine is magnified and does not obscure the fetus
  - b fetus is closer to the film
  - c compressed abdomen provides a homogeneous background
  - d diameter of the patient's pelvis can be more accurately measured
- 26 (412) Why would an oblique projection be requested in addition to a PA fetogram?
- a To place the fetal skeleton in profile
  - b To improve detail by reducing OFD
  - c Shifting the patient's abdomen to one side reduces discomfort and fetal motion
  - d To free fetal skeletal parts from superimposition with the patient's spine

- 27 (413) Measurements for a Colcher-Sussman pelvimetry are made at the
- inlet, midpelvis, and outlet
  - inlet, iliac crests, and symphysis pubis
  - midpelvis, symphysis pubis, and posterior superior iliac spine
  - midpelvis, iliac crests, and symphysis pubis
- 28 (413) The outlet measurement of pelvimetry in the AP position is measured at the level of the
- ischial spines
  - ischial tuberosities
  - superior border of the symphysis pubis
  - inferior border of the symphysis pubis
- 29 (413) Where is the Colcher-Sussman pelvimeter ruler placed for the AP projection?
- 10 cm below the level of the femoral heads
  - 10 cm below the level of the anterior margin of the symphysis pubis
  - At the level of the symphysis pubis
  - Between the gluteal folds
- 30 (414) If the ruler is *not* placed parallel with the film during a Colcher-Sussman projection, the measurements will be affected by
- a higher centimeter count
  - a lower centimeter count
  - a higher centimeter count on the AP and lower on the lateral.
  - a lower centimeter count on the AP and higher on the lateral
- 31 (415) Why should the film be centered about 1½ inches above the symphysis pubis for the AP Colcher-Sussman projection?
- To ensure the entire symphysis pubis is included
  - To allow space for the ruler on the lower margin of the film
  - To compensate for rotation of the pelvis
  - To include the iliac crests.
- 32 (416) What is perhaps the most common mistake made on the lateral projection for pelvimetry?
- Not including the ruler on the film
  - Overexposure.
  - Anterior rotation of the pelvis.
  - Positioning the film too high
- 33 (417) Which parameter of sound is a measure of the strength or loudness of the sound wave?
- Period
  - Velocity
  - Frequency.
  - Amplitude
- 34 (417) Select the parameter of sound that is recorded in cycles per second
- Period
  - Frequency
  - Amplitude
  - Wavelength
- 35 (417) Identify the frequency range of medical ultrasound
- 0.1 to 1.0 Hz
  - 1.0 to 20 Hz
  - 1.0 to 20 MHz.
  - 20 to 40 MHz.

- 36 (418) Select the principle upon which ultrasound applications are based
- a Sound - reflection principle
  - b Pulse - echo principle
  - c Sound - generation principle
  - d Echo - reflection principle
- 37 (418) What is the primary use of the pulse-echo principle in diagnostic ultrasound?
- a. Calibrating equipment
  - b Determining frequency
  - c Measuring amplitude
  - d Measuring distances
- 38 (419) What importance does an interface serve as it relates to ultrasound applications?
- a It indicates the presence of disease
  - b It indicates the absence of disease
  - c It causes a sound pulse to be reflected
  - d It causes a sound pulse to be absorbed
- 39 (419) In medical ultrasound, acoustic impedance relates to
- a density of tissue
  - b depth of tissue
  - c a focused beam
  - d an unfocused beam
- 40 (420) Select the method of ultrasound attenuation that is the basis for ultrasound diathermy
- a Generation
  - b Absorption
  - c Reflection
  - d Scattering
- 41 (420) Which type of ultrasound attenuation can be compared to the "all or nothing" phenomenon of the photoelectric effect of radiation?
- a Absorption
  - b Reflection
  - c Scattering
  - d Focusing
- 42 (421) What are the three biological effects of ultrasound?
- a Cavitation, thermal effects, and absorption.
  - b Cavitation, thermal effects, and viscous stresses
  - c Attenuation, cavitation, and viscous stresses
  - d Attenuation, thermal effects, and viscous stresses
- 43 (421) The manner in which a biological effect is produced by ultrasound is called
- a sound generation
  - b attenuation of sound
  - c refraction of sound
  - d. the mechanism of action
- 44 (422) The operation of a transducer in an ultrasound unit is based on the
- a pulse-echo principle
  - b photoelectric effect
  - c piezoelectric effect
  - d reflection of sound effect
- 45 (422) What is the purpose of the backing material in a transducer?
- a It cushions the motion of the crystal
  - b It insulates the crystal from electrical interference
  - c It conducts electrical charges from the crystal
  - d It provides stability for the face plate

- 46 (423) Which field or zone of an ultrasound beam will produce the best resolution?
- a Far
  - b Fresnel
  - c Fraunhofer
  - d Unfocused
- 47 (424) The two types of ultrasound resolution are
- a axial and lateral
  - b axial and anterior
  - c lateral and azimuthal
  - d anterior and azimuthal
- 48 (424) Which ultrasonic factor affects axial resolution?
- a Diameter of the crystal
  - b Thickness of the backing material
  - c Width of the ultrasound beam
  - d Length of the ultrasound pulse
- 49 (424) The ability to identify two closely spaced interfaces that are perpendicular to the long axis of the ultrasound beam is defined as
- a refraction
  - b reflection
  - c lateral resolution
  - d axial resolution
- 50 (424) What will result on an ultrasound image if two interfaces are separated by less distance than the width of the ultrasound beam?
- a Good lateral resolution
  - b Poor lateral resolution
  - c Scattering of the beam
  - d Two echoes show on the screen
- 51 (425) What should you use to assign shades of gray in ultrasound imaging?
- a A color coordinator
  - b A scan converter
  - c An oscilloscope
  - d A storage oscilloscope
- 52 (425) What is "gain" in ultrasonography?
- a Increasing one's knowledge of ultrasound exams.
  - b Increasing the amplitude of the sound beam
  - c The intensity of an echo signal
  - d The length of the focused zone
- 53 (426) Which ultrasound image recording system uses X-ray film?
- a Cine-recording system
  - b Digital display system
  - c Multi-imaging system
  - d Instant photograph camera system.
- 54 (427) Ultrasound operational modes are various
- a types of transducers.
  - b scanning motions
  - c recording systems
  - d ways to visualize echoes.
- 55 (427) Which ultrasound operational mode has its main uses with abdominal and pelvic ultrasonography?
- a A-mode
  - b B-mode
  - c M-mode.
  - d Real time



- 56 (427) The primary purpose of A-mode in ultrasonography is to
- measure depth of interfaces
  - measure volume flow of vessels
  - detect sounds from moving parts
  - produce gray-scale images
- 57 (428) Identify the type of ultrasound scanning that runs parallel to the level of the iliac crests
- Transverse
  - Sagittal
  - Longitudinal
  - Bilateral
- 58 (428) Which of the following scan descriptions would be identified as "L + 1"?
- A transverse scan of the left side that is one centimeter above the iliac crests
  - A transverse scan of the left lung that is one centimeter above the xiphoid
  - A longitudinal scan one centimeter along the left border of the liver.
  - A longitudinal scan one centimeter to the left of the median plane
- 59 (429) Which ultrasound scanning motion has the sound beam pass over some interfaces more than once?
- Arc
  - Compound
  - Linear
  - Sector.
- 60 (430) What is "differential diagnosis" in ultrasound?
- The ability to identify cross-sectional anatomy
  - The ability to prescribe treatment for diseases.
  - The ability to differentiate between longitudinal and transverse scans.
  - The ability to see visual differences between normal and abnormal tissues
- 61 (430) A cystic mass on an ultrasound image differs in appearance from adjacent tissues in that it
- contains many interfaces
  - shows an absence of echoes
  - produces more echoes
  - produces a chorionic plate
- 62 (430) What is a characteristic of a fluid cyst as it appears on an ultrasound image?
- It shows a strong back interface
  - It shows a strong front interface
  - It shows many echoes
  - Its interfaces do not produce echoes
- 63 (430) Identifying the location of the chorionic plate would be helpful when you are providing ultrasound scans for
- placenta praevia
  - gallstones
  - hepatitis
  - pancreatitis.
- 64 (431) Why should mineral oil be rubbed on the patient's skin prior to ultrasonography?
- To increase the dissipation of the sound beam.
  - To reduce friction between the transducer and skin.
  - To prevent the dissipation of the sound beam.
  - To prevent an increase of skin temperature.

- 65 (432) What should you do to determine the entire length of the aorta when performing ultrasonography for an aorta aneurysm?
- Perform transverse scans
  - Perform longitudinal scans
  - Perform decubitus scans
  - Perform valsalva maneuver
- 66 (432) Why should the patient suspend deep inspiration during ultrasound scanning of the gallbladder?
- To provide an acoustic window
  - To raise the gallbladder higher in the abdomen
  - To cause the gallbladder to contract
  - To force the gallbladder lower in the abdomen
- 67 (432) Why is the pancreas difficult to visualize with ultrasound?
- A normal pancreas produces echoes similar to adjacent tissues
  - An abnormal pancreas produces echoes similar to adjacent tissues
  - A pancreas is superimposed by the splenic vein
  - A pancreas is superimposed by lower ribs
- 68 (433) How should the patient be positioned for ultrasonography of the kidneys?
- Erect
  - Lateral Decubitus
  - Prone
  - Supine.
- 69 (433) How should the sound beam be directed when performing transverse ultrasound scans of a kidney?
- 15° caudad
  - 15° cephalic
  - Parallel to the long axis of the kidney
  - Parallel to the patient's sagittal plane
- 70 (434) Why are sector scanning motions with a transducer recommended when doing longitudinal scans of the pelvis?
- To use the bladder as an acoustic window
  - To prevent false readings of fecal material
  - Because the pelvis is a small scanning area
  - To eliminate acoustic shadows of intestinal gas
- 71 (435) When doing transverse ultrasound scans of the thyroid gland, coordinates should be referenced to the
- clavicle
  - manubrium
  - mandible
  - xiphoid.
- 72 (435) When scanning thyroid nodules with ultrasound, a primary concern is
- whether they are cystic or solid
  - what coordinates are used.
  - how many nodules are present
  - the location of nodules

- 73 (436) In tomography, the term amplitude refers to the
- speed of tube travel during exposure
  - layer of the body which appears sharpest
  - point at which a lever rotates
  - amount of tube travel during exposure
- 74 (436) What is zonography?
- Tomography with an exposure angle of less than  $10^\circ$
  - Tomography with an exposure angle of more than  $10^\circ$
  - A method of measuring heat production by pathologic conditions within the body
  - Ultrasonic scanning of individual layers of the body
- 75 (437) Which of the following describes an *elliptical* tomographic tube movement?
- The spiral path
  - The linear path
  - The pretzel-like path
  - The oblong circular path.
- 76 (437) Identify the polytomographic movement that is the simplest and offers complete blurring of unwanted structures
- The linear
  - The circular
  - The spiral
  - The random
- 77 (437) Which of the following is the most complex polytomographic movement?
- Rectilinear
  - Elliptical
  - Hypocycloidal
  - Sinusoidal
- 78 (438) Which statement is correct concerning a tomogram?
- Structures located in the focal plane are blurred
  - Structures located in the focal plane are sharp.
  - Structures located in the vertical plane are sharp
  - Structures projected by a large exposure angle are blurred
- 79 (439) Which of the following statements about conventional tomography is correct?
- A large exposure angle produces a thin section.
  - A small exposure angle produces a thin section
  - A 5-degree change in exposure angle produces a 0.5-mm change in section thickness
  - Exposure angle and section thickness are not related
- 80 (440) Increasing the FFD while leaving the amplitude constant during a rectilinear tomography will result in
- a thicker section being produced.
  - a thinner section being produced.
  - an increase in radiation exposure to the patient.
  - an increase in the exposure angle
- 81 (441) Which pair of intensifying screens in a book cassette are the fastest speed?
- The top pair.
  - The middle pair.
  - The bottom pair
  - The pair at the focal plane level

- 82 (442) Why does a three-film book cassette need a greater exposure than that needed for a single film tomogram taken under the same conditions?
- The three films of the book cassette demonstrate deeper structures
  - Book cassette exposure is determined by the speed of the bottom screens
  - Book cassette exposure is determined by the speed of the top screens
  - The book cassette front (bakelite material) is thicker than a conventional cassette
- 83 (443) If 100 mAs is used for a conventional radiograph, what mAs should be used to tomograph the same part using a 30° exposure angle?
- 50 mAs
  - 100 mAs
  - 150 mAs
  - 200 mAs
- 84 (444) If the amplitude is 15 inches and the rate is 10 inches per second, what is the tomographic exposure time?
- 1.5 seconds
  - 10 seconds
  - 15 seconds
  - 30 seconds
- 85 (445) How should a patient be positioned relative to tube movement in linear tomography?
- So the longitudinal axis of the patient is 45° to the tube movement.
  - So the longitudinal axis of the parts to be blurred are parallel to the tube movement.
  - So the longitudinal axis of the parts to be blurred are at right angles to the tube movement
  - So the longitudinal axis of the patient is parallel to the tube movement
- 86 (446) In what way does a computed tomography (CT) scanner differ from routine radiography?
- It does not record an image in the conventional way
  - Patient motion does not affect image quality
  - High voltage generators are not used.
  - Less radiation exposure to the patient.
- 87 (447) Identify an advantage of CT over conventional radiography
- It is preferred for dynamic studies.
  - It can resolve objects as small as 0.1 mm.
  - Reduces radiation exposure to the patient.
  - Superimposition of structures is not a factor
- 88 (448) What are the four main subsystems of a CT gantry assembly?
- The X-ray tube, the detector array, the high-voltage generator, and the patient positioning couch
  - The X-ray tube, the computer, the high-voltage generator, and the patient positioning couch
  - The X-ray tube, the detector array, the console, and the computer.
  - The X-ray tube, the console, the computer, and the patient positioning couch
- 89 (448) What is the purpose of a photomultiplier in a CT unit?
- It changes light flashes into electrical impulses
  - It changes electrical impulses into light flashes
  - It amplifies light flashes from a crystal.
  - It amplifies electrical impulses from a computer

- 90 (449) What role do CT numbers have in the imaging process?
- They determine the linear attenuation coefficient values
  - They indicate a particular shade of gray for each pixel
  - They determine the thickness of each voxel
  - They indicate how many images can be stored on a disk
- 91 (450) What is the purpose of the cathode ray tube in CT units?
- Changes CT data into a video form for viewing
  - Source of radiation for imaging procedures
  - Initiates algorithms for computer analysis
  - Measures remnant radiation to determine attenuation
- 92 (450) What results on a CT image when the window number is lowered?
- Greater density
  - Lesser density
  - Greater contrast
  - Lesser contrast
- 93 (451) Identify the generations of CT scanners that use a translation-rotation tube movement
- First and second
  - First and third
  - Second and third
  - Third and fourth
- 94 (451) Which generation of CT scanners was the first to use a 1 second scan time?
- First
  - Second
  - Third
  - Fourth
- 95 (452) Why should a patient be NPO prior to all CT examination that use a contrast medium?
- To increase the absorption rate of the contrast medium
  - To reduce artifacts on the image of a scan
  - To prevent the dilution of the contrast medium
  - To reduce the possibility of vomiting
- 96 (453) CT scans of the abdomen are usually done with the
- patient prone after the administration of a contrast medium
  - gantry parallel to the positioning table
  - kVp in the low range to improve subject contrast
  - gantry perpendicular to the positioning table
- 97 (454) Identify the slice thickness and frequency of interval for a CT survey for lymphoma or metastasis
- 1 cm thickness, contiguous slice interval
  - 1 cm thickness, every other centimeter interval
  - 1.5 cm thickness, contiguous slice interval
  - 1.5 mm thickness, every other centimeter interval
- 98 (455) A scanogram is performed to determine the
- length of a fracture
  - length of the spine.
  - actual and relative lengths of long bones
  - depth of a foreign body and biparietal diameter

- 99 (455) While performing a scanogram, you should align the X-ray tube to which of the following portions of the part to be examined?
- a The ends
  - b The middle
  - c The lateral borders
  - d The proximal portion only
- 100 (456) What device is projected on most scanograms?
- a Colcher-Sussman ruler
  - b Bell-Thompson ruler
  - c Sweet's localizer
  - d Caliper
- 101 (457) What is the *best* way to determine where the CR was directed on scanograms?
- a Measure from the film borders to each joint.
  - b Ask the technician who did the procedure
  - c Ask the patient
  - d Find the center of each X-ray field on the film
- 102 (458) Which of the following structures prevents medial or lateral movement of the knee joint?
- a Collateral ligaments
  - b Cruciate ligaments
  - c Menisci.
  - d Synovial capsules
- 103 (459) Why is a knee wrapped tightly with an ace bandage during arthrography?
- a To increase dilution of the contrast medium
  - b To force contrast medium into the quadriceps pouch
  - c To permit visualization of the quadriceps pouch.
  - d To force contrast medium out of the quadriceps pouch.
- 104 (460) Why should you work rapidly when performing an arthrogram?
- a Because it is difficult to maintain a sterile field for any length of time
  - b Because absorption of the media begins shortly after introduction.
  - c Because the patient is in considerable pain due to the various positions of the knee
  - d Because the longer the contrast material stay, in the joint capsule, the greater the chance of simulated pathology
- 105 (460) To widen the medial aspect of the knee joint and better visualize the medial meniscus, the lower leg is
- a flexed 20°.
  - b hyperextended
  - c laterally stressed
  - d medially stressed
- 106 (461) Which of the following is most important when performing bedside radiography on orthopedic traction patients?
- a Using a vertical CR that is perpendicular to the film
  - b Maintaining at least an 18 inch FFD.
  - c Shielding other patients in the room
  - d Being careful not to bump the bed or traction weights
- 107 (461) What precaution should you take while performing a portable examination on an infant in the newborn nursery?
- a Repeat marginal films for optimum radiographic quality.
  - b Follow guidelines for radiographing patients in strict isolation.
  - c Never remove an infant from an incubator without first checking with the nursing personnel
  - d Never allow nursing personnel to handle the infant during positioning.

- 108 (462) Why should two X-ray technicians do a bedside procedure on an isolation patient?
- To reduce the time it takes for one technician to do the exam
  - In the event both are needed to position the patient
  - One stays with the patient while the other develops the radiograph
  - One must position the patient while the other handles the X-ray equipment
- 109 (462) When two X-ray technicians are performing bedside radiography on a reverse isolation patient, which technician is considered "contaminated"?
- The one who operates the X-ray equipment
  - The one who positions the patient
  - The one who operates the patient's oxygen supply
  - The one who doesn't put on a gown, a mask, and gloves
- 110 (463) Identify the bedside chest radiograph in which you should lower the patient's bed to reduce magnification
- PA erect
  - AP erect
  - AP supine
  - AP semierect
- 111 (464) What is the minimum source-to-skin distance that you should use when accomplishing a portable radiograph?
- 10 inches
  - 12 inches
  - 15 inches
  - 18 inches
- 112 (465) Identify the type of clothing or material that should *not* be worn in the operating room when you are doing surgical radiography
- Cotton
  - Nylon
  - Rubber-soled shoes
  - Paper-type disposable masks
- 113 (466) Which part of a mobile X-ray unit should be covered with a sterile pillow case or a sheet of clear plastic?
- The controls
  - The power supply cord
  - The tube head
  - The wheels
- 114 (467) Of those involved with "open" surgery, who is considered nonsterile and therefore should *not* come in contact with a sterile area?
- Surgeon.
  - Scrub Nurse
  - Scrub Technician
  - Radiologic Technologist
- 115 (468) What is the *most* common cause of repeat radiographs in the operating room?
- Incorrect tube-part-film alignment
  - Grid cutoff
  - Incorrect exposure technique
  - Patient's breathing motion.
- 116 (469) Which statement *best* describes the solarization process of duplicating radiographs?
- Exposure is not logarithmic.
  - Density is unrelated to exposure
  - Increasing exposure increases film density
  - Increasing exposure decreases film density

- 117 (469) Duplicating film differs from standard X-ray film in that
- a it cannot be developed in an automatic processor
  - b it is more sensitive to X-rays
  - c it is not sensitive to light
  - d it has emulsion on only one side
- 118 (469) Most brands of duplicating film are designed to be exposed with
- a intensifying screens
  - b ultraviolet light
  - c white light
  - d X-rays
- 119 (470) To convert a conventional cassette into one that can be used to duplicate radiographs, you need
- a two sheets of clear glass
  - b a sheet of clear glass or Plexiglass
  - c a pair of slow-speed intensifying screens
  - d a sheet of clear glass, and a pair of light-sensitive intensifying screens
- 120 (470) If a duplicate of a radiograph is too dark, what should you do to improve a subsequent duplicate?
- a Increase the distance
  - b Decrease the exposure time
  - c Use a larger bulb
  - d Increase the exposure time
- 121 (470) An advantage of copying radiographs with a commercial duplicator is that it eliminates the need of
- a single emulsion film
  - b chemical processing of the copy
  - c a special cassette
  - d timing an exposure
- 122 (471) The subtraction process removes unwanted shadows from an angiogram by reducing the
- a overall density of the shadows.
  - b contrast between the shadows
  - c densities of the contrast-filled vessels
  - d contrast between the vessels and the background
- 123 (472) To produce a subtraction mask, how should the subtraction mask film be placed into the special cassette?
- a Emulsion side against the base film
  - b Glossy side against the base film
  - c Emulsion side against the angiogram
  - d Glossy side against the subtraction print
- 124 (472) What sequence of film production occurs during the subtraction process?
- a Mask, print, base
  - b Base, print, mask
  - c Base, mask, print
  - d Mask, base, print

**END OF EXERCISE**



## STUDENT REQUEST FOR ASSISTANCE

### PRIVACY ACT STATEMENT

**AUTHORITY** 10 USC 8012 and EO 9397 **PRINCIPAL PURPOSES** To provide student assistance as requested by individual students **ROUTINE USES** This form is shipped with ECI course package. It is utilized by the student, as needed, to place an inquiry with ECI **DISCLOSURE** Voluntary The information requested on this form is needed for expeditious handling of the student's need Failure to provide all information would result in slower action or inability to provide assistance to the student

### SECTION I: CORRECTED OR LATEST ENROLLMENT DATA (Mail to ECI, Gunter AFS AI 36118)

1 THIS REQUEST CONCERNS COURSE (1 - 6)	2 TODAY'S DATE	3 ENROLLMENT DATE	4 AUTOVON NUMBER
5 SOCIAL SECURITY NUMBER (7 - 15)	6 GRADE/RANK	7 NAME (First initial second initial last name) (17) (18) (19-32)	
8 ADDRESS <i>(OJT Enrollees -- Address of unit training office with zip code All others -- current mailing address with zip code)</i>		(33-53)	(54-75)
9 NAME OF BASE OR INSTALLATION IF NOT SHOWN ABOVE		10 TEST CONTROL OFFICE ZIP CODE/SHRED (33 - 39)	

### SECTION II: REQUEST FOR MATERIALS, RECORDS, OR SERVICE

*(Place an 'X' through number in box to left of service requested)*

#### FOR ECI USE ONLY

1	Request address change as indicated in Section I.	16	
2	Request Test Control Office change as indicated in Section I	33	
3	Request name change/correction (Provide Old or Incorrect data)	G	
4	Request Grade/Rank change/correction.	K	Vol 33 - 35 GR 36 38
5	Correct SSAN. (List incorrect SSAN here) (Correct SSAN should be shown in Section I)	M	33 34 35 40
6	Extend course completion date. (Justify in REMARKS)	N	33 - 38
7	Request enrollment cancellation.	P	Vol 33 - 35 TC 36 37
8	Send VRE answer sheets for Vol(s): 1 2 3 4 5 6 7 8 9 Originals were: <input type="checkbox"/> Not received <input type="checkbox"/> Lost <input type="checkbox"/> Misused	2	33 34 Volume 35 17
9	Send course materials. (Specify in REMARKS) <input type="checkbox"/> Not received <input type="checkbox"/> Lost <input type="checkbox"/> Damaged	38	39 - 42
10	Course exam not yet received. Final VRE submitted for grading on _____ (date).	1	39 42
11	Results for VRE Vol(s) 1 2 3 4 5 6 7 8 9 not yet received. Answer sheet(s) submitted _____ (date)	2	39 - 42
12	Results for CE not yet received. Answer sheet submitted to ECI on _____ (date)	3	39 - 42
13	Previous inquiry ( <input type="checkbox"/> ECI Fm 17, <input type="checkbox"/> Ltr, <input type="checkbox"/> Msg) sent to ECI on _____ (date).	16	
14	Give instructional assistance as requested on reverse		
15	Other (Explain fully in REMARKS)		

REMARKS (Continue on Reverse)

DJT STUDENTS must have their DJT Administrator certify this request

I certify that the information on this form is accurate and that this request cannot be answered at this station. *(Signature)*

ALL OTHER STUDENTS may certify their own requests.

**SECTION III: REQUEST FOR INSTRUCTOR ASSISTANCE**

**NOTE:** Questions or comments relating to the accuracy or currency of subject matter should be forwarded directly to preparing agency. For an immediate response to these questions, call or write the course author directly, using the AUTOVON number or address in the preface of each volume. All other inquiries concerning the course should be forwarded to ECI.

**VRE Item Questioned.**

Course No \_\_\_\_\_

Volume No \_\_\_\_\_

VRE Form No \_\_\_\_\_

VRE Item No \_\_\_\_\_

Answer You Chose \_\_\_\_\_  
(Letter)

Has VRE Answer Sheet  
been submitted for grading?

Yes  No

**REFERENCE**

(Textual reference for the  
answer I chose can be  
found as shown below)

In Volume No \_\_\_\_\_

On Page No \_\_\_\_\_

In  left  right column

Lines \_\_\_\_\_ Through \_\_\_\_\_

**MY QUESTION IS**

**REMARKS**

ADDITIONAL FORMS 17 available from trainers, OJT and Education Offices, and ECI. Course workbooks have a Form 17 printed on the last page.

90370 04 8401

CDC 90370

# RADIOLOGY TECHNICIAN

(AFSC 90370)

Volume 4

*Special Procedures*



Extension Course Institute

Air University

412

Prepared by  
MSgt Steven G Hayes  
(AUTOVON 736-2809/2647)

Reviewed by.  
Pamela G. Brown and Richard B Taylor

Edited by.  
Julia F Woodard



SCHOOL OF HEALTH CARE SCIENCES USAF (ATC)  
SHEPPARD AIR FORCE BASE TEXAS 76311

EXTENSION COURSE INSTITUTE (AU)  
GUNTER AIR FORCE STATION, ALABAMA 36118

413

## Preface

EXAMINATIONS of body systems have historically been referred to as special procedures. As we point out repeatedly in this volume, the exact procedures carried out during these examinations depend a great deal upon your radiologist's preference. Each radiologist has a particular method of performing the examination. This does not imply that some procedures are superior to other. It merely means that each radiologist has a particular way to arrive at an accurate diagnosis of a patient's condition. Accordingly, this volume deals mostly with procedures that are general in nature. Hopefully, this information will allow you to adapt quickly to the examination, regardless of the circumstances involved.

This volume contains anatomy and physiology of various systems of the body. Some of these systems—the digestive, the urinary, the female reproductive, the respiratory, the cardiovascular, and the nervous—have special contrast studies that pertain to specific anatomy. The remaining body systems of the muscular, the integumentary, and the endocrine have no special contrast studies, but we include a section on them to make our anatomy and physiology review complete. We also specify any equipment that is unique to a special procedure (e.g., rapid film changers and automatic pressure injectors).

The inclusion of names of any specific commercial product, commodity, or service in this publication is for information purposes only and does not imply indorsement by the Air Force.

This volume is valued at 27 hours (9 points).

Material in this volume is technically accurate, adequate, and current as of August 1983.

## Contents

	<i>Page</i>
<i>Preface</i>	<i>iii</i>
<i>Chapter</i>	
1 Contrast Studies of the Digestive System . . . . .	1
2 Contrast Studies of the Urogenital System . . . . .	30
3 Contrast Studies of the Respiratory System . . . . .	47
4 Contrast Studies of the Cardiovascular and Lymphatic Systems . . . . .	55
5 Contrast Studies of the Nervous System . . . . .	75
6 Muscular, Integumentary, and Endocrine Systems . . . . .	86
<i>Answers for Exercises</i>	<i>94</i>

## Contrast Studies of the Digestive System

CONVERSION of food to chemical nutrients, usable by the body, occurs in the digestive system. Consequently, malfunction of any of the system components results in impairment of the digestive process. When the degree of impairment is sufficient, medical and/or surgical intervention is necessary. Generally, the first step in such professional treatment requires radiographic examination of the affected system component. Since you are involved in preparing the equipment for and will assist with such procedures, you must have at least a basic knowledge of the organs in the digestive system, how they function, the materials used to make them radiopaque, the radiographic equipment, and how the equipment is generally used. Therefore, this chapter is a discussion of these factors as they apply to representative parts of the digestive system.

### 1-1. Anatomy and Physiology of the Digestive System

The digestive system consists of the alimentary tract or canal and the accessory organs of digestion. The alimentary tract is 28 to 32 feet long and consists of the mouth, the pharynx, the esophagus, the stomach, the small bowel, the large bowel, the rectum, and the anus. The accessory digestive organs are the salivary glands, the liver, the gallbladder, and the pancreas. We begin our study of the digestive system with the mouth.

**600. Name the structures and the bones comprising the roof of the mouth and state the role of the posterior roof of the mouth during the swallowing process.**

Although the mouth or oral cavity is made up of various structures, including the teeth, mandible, cheeks, lips, and tongue, our discussion is primarily directed toward the roof of the mouth and the salivary glands.

**Roof of the Mouth.** The roof of the mouth is formed by the hard and the soft palates. The stationary hard palate, forming the anterior portion of the roof of the mouth, is made of the maxillae and palatine bones, which are covered by mucous membranes. The hard palate joins posteriorly with the soft palate—a fold of mucous membrane which encloses muscular fibers, vessels, mucous glands, and nerves. The soft palate, normally pendant, elevates during the process of swallowing to separate the nasal cavity and nasopharynx from the oral cavity and oropharynx. (See fig. 1-1.)

### Exercises (600):

1. What two structures (other than bones) make up the roof of the mouth?
2. What two pairs of bones comprise the anterior portion of the roof of the mouth?
3. What effect does the elevation of the soft palate during the swallowing process have on the nasal and oral cavities and the pharynx?

**601. Identify the location, size, number, ductal system, and function of salivary glands.**

**Salivary Glands.** Three pairs of salivary glands are located about the oral cavity. (See fig. 1-2.) They are the parotid, submaxillary, and sublingual glands. Each of these glands secretes saliva into the mouth. The *parotids*, which are the largest of the salivary glands, are located in the superior-posterior aspect of each cheek, below and in front of each ear. By means of *Stenson's* (parotid duct in fig. 1-2) *duct*, parotid secretions are channeled through the muscles of each cheek into the mouth through a small opening adjacent to each upper second molar. The *submaxillary* (also called submandibular) glands are located near the anteromedial aspect of each mandibular angle. Submaxillary gland secretions reach the mouth by way of *Wharton's duct*, which opens into the mouth on each side of the frenulum of the tongue. The *sublingual* glands, smallest of the three, are located beneath the mucous membrane of the floor of the mouth on each side of the midline. Saliva from each sublingual gland empties into several small excretory ducts called the ducts of *Rivinus*. Some of the ducts of Rivinus join to form the duct of *Bartholin*, which empties into Wharton's duct. Some empty directly into Wharton's duct, while others empty directly into the mouth on either side of the frenulum of the tongue.

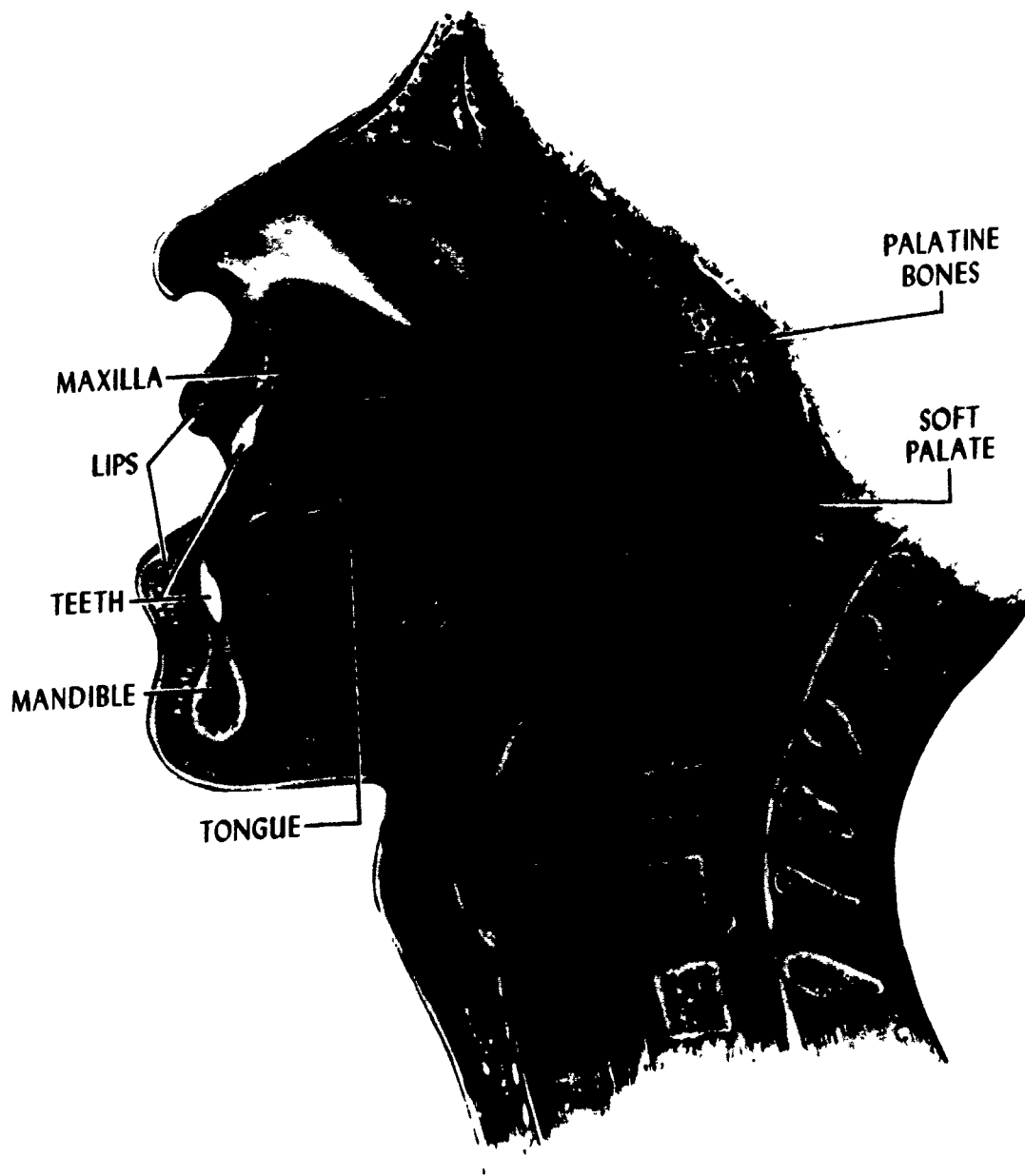


Figure 1-1 The oral cavity and adjoining areas



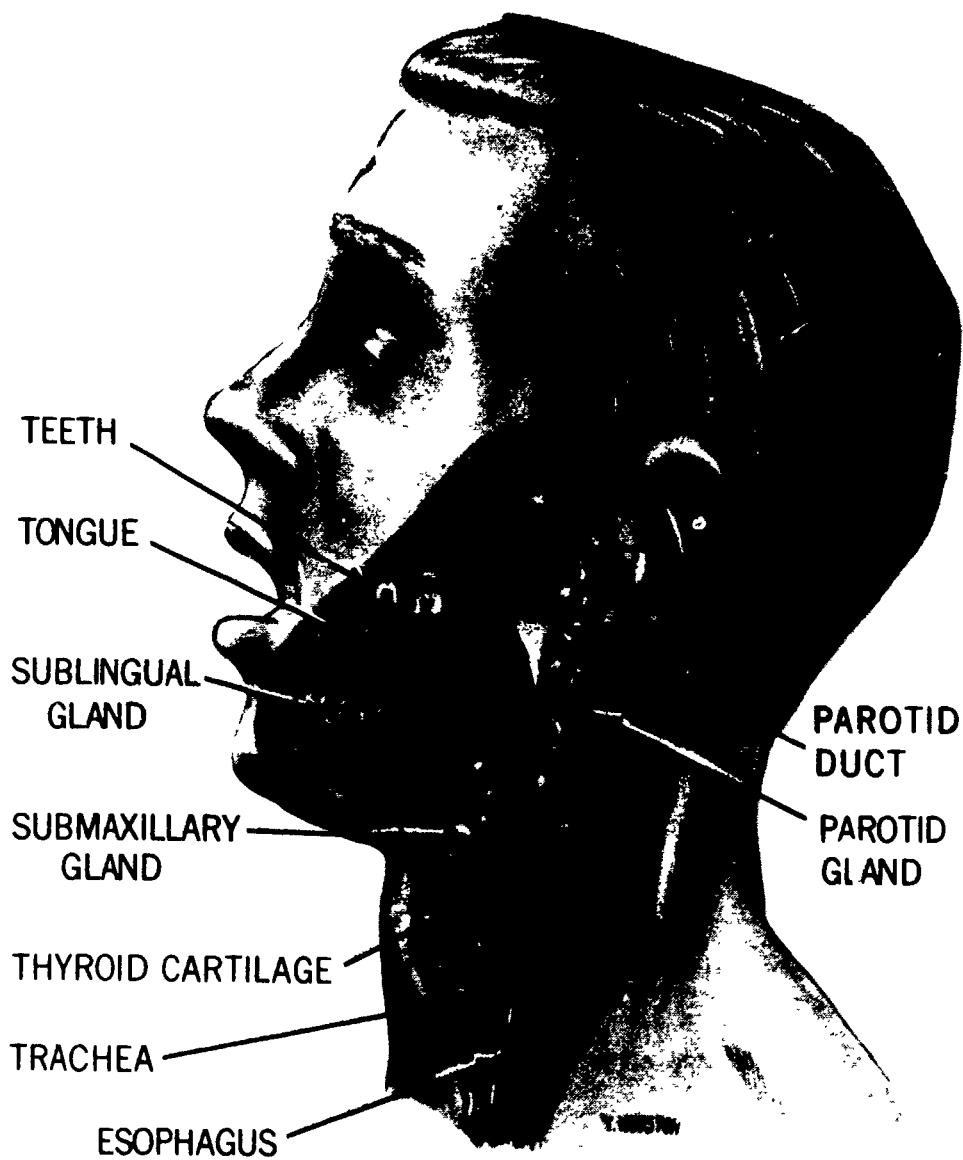


Figure 1-2 Salivary glands and related structures

**Exercises (601):**

1. Match the salivary gland in column B with the appropriate statement or phrase in column A. Each column B item may be used once or more than once. Also, more than one column B item may match a single column A entry.

Column A	Column B
_____ (1) Smallest salivary gland	a. Submaxillary
_____ (2) Empties via Stenson's duct	b. Parotid
_____ (3) Located anteroinferior to the ear	c. Sublingual
_____ (4) Secretes saliva	
_____ (5) Communicates with Wharton's duct	
_____ (6) Located most inferiorly.	
_____ (7) Empties into the mouth on either side of the frenulum of the tongue.	
_____ (8) Empties into the mouth near the upper second molar.	
_____ (9) Empties via the duct of Bartholin	
_____ (10) Empties via the ducts of Rivinus	
_____ (11) Located beneath the mucous membrane of the floor of the mouth	
_____ (12) Largest salivary gland	

**602. Identify the structure, function, and radiographic significance of the pharynx and esophagus.**

**The Pharynx.** The pharynx is a tubelike structure, approximately 12 cm long, extending from the inferior portion of the skull to the level of the sixth cervical vertebra. (See fig. 1-3.) It is continuous with the nasal cavity anteriorly and the esophagus inferiorly. The pharynx is divided into three parts: (1) the *nasopharynx*, (2) the *oropharynx*, and (3) the *laryngopharynx*.

**Nasopharynx.** The curved nasopharynx is the proximal portion of the pharynx which serves as an air passage from the nasal cavity to the oropharynx. It extends distally to the inferior margin of the soft palate.

**Oropharynx.** The oropharynx extends from the soft palate to the hyoid bone. It is common to both the digestive and respiratory systems because it serves as an air passage from the nasopharynx to the larynx and as a food passage from the oral cavity to the laryngopharynx.

**Laryngopharynx.** The laryngopharynx extends from the oropharynx to the level of the sixth cervical vertebra and the cricoid cartilage, where it becomes the esophagus.

**Radiographic considerations.** Generally speaking, the nasopharynx and oropharynx can be adequately

demonstrated on a soft-tissue lateral projection because they are normally filled with air. The laryngopharynx, however, is usually visualized radiographically after the introduction of a contrast medium because it is not a normal air passage.

**The Esophagus.** The *esophagus* is the portion of the digestive system where peristalsis begins; it connects the pharynx to the stomach. It is approximately 25 cm long and from 10 to 30 mm in diameter. (See fig. 1-4.) As seen from the front, it appears as a "lazy S." It begins in the midline and inclines slightly to the left, back to the right, and then to the left again where it enters the stomach at the level of the eleventh thoracic vertebra. As seen from the side, it follows the curvatures of the lower cervical and thoracic spines. Notice that the esophagus is in close proximity to the aorta. The esophagus is also located along the posterior border of the heart. You can see how the location of the esophagus with respect to the aorta and heart can be used to advantage to radiographically demonstrate certain abnormalities of those two structures. If the esophagus is filled with a contrast medium, an enlarged heart or an aortic aneurysm may show a portion of the esophagus displaced from its normal location.

**Exercises (602):**

Identify each true statement and explain why the others are false.

- \_\_\_\_\_ 1. The pharynx is approximately 12 cm long.
- \_\_\_\_\_ 2. The nasopharynx is the middle portion of the pharynx.
- \_\_\_\_\_ 3. Food and air pass through the laryngopharynx.
- \_\_\_\_\_ 4. The most distal portion of the pharynx is the laryngopharynx.
- \_\_\_\_\_ 5. The nasopharynx and oropharynx can be demonstrated on a lateral radiograph because of the presence of air.
- \_\_\_\_\_ 6. The laryngopharynx is usually demonstrated on a radiograph after introduction of a contrast medium.

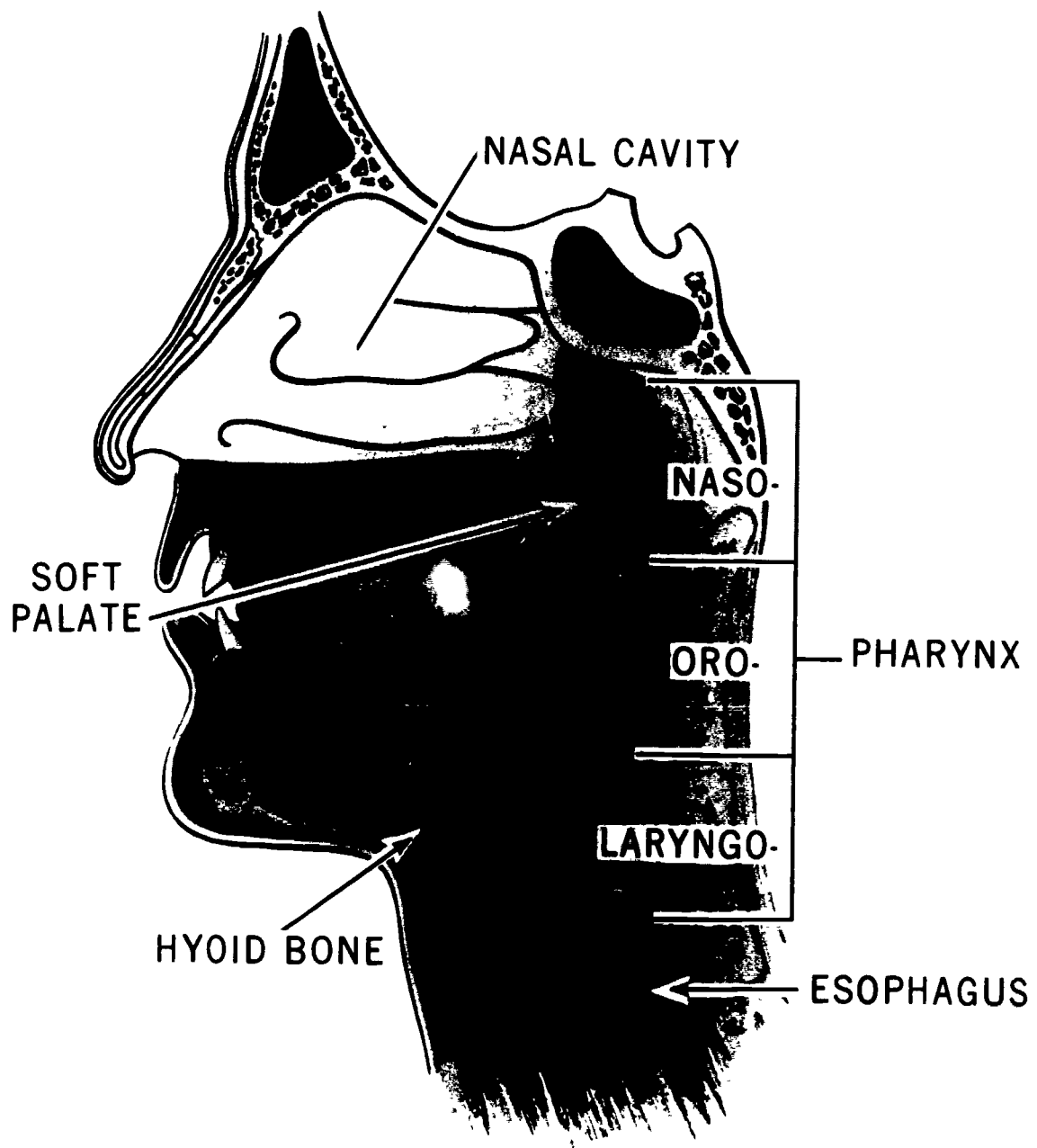


Figure 1-3. The pharynx

- \_\_\_ 7. The laryngopharynx is continuous with the proximal esophagus.
- \_\_\_ 8. The esophagus is approximately 30 cm long.
- \_\_\_ 9. The esophagus, after beginning in the midline, curves first to the left, back to the right, and back again to the left.
- \_\_\_ 10. The esophagus is located anterior to the heart.
- \_\_\_ 11. Abnormalities of the heart and aorta may displace the normal course of the esophagus.

603. State the names or locations of key stomach structures and the shapes and locations of the stomach according to body habitus.

**The Stomach.** The stomach is the most dilated portion of the digestive system and extends from the esophagus to the small intestine.

**General structure.** The stomach has two main borders or curvatures: (1) the *greater* curvature, and (2) the *lesser* curvature. (See fig. 1-5 ) The greater curvature is the larger of the two and contains a slight groove called the *sulcus intermedius*. The lesser curvature, the smaller, is located on the right side of the stomach and contains a well-defined notch, the *incisura angularis*.

There are two openings in the stomach, as shown in figure 1-6. The proximal opening at the junction of the esophagus is the *cardiac orifice*, which normally lies at the level of the eleventh thoracic vertebra about 1 inch to the left of the lateral sternal border. The lower opening, which communicates with the small intestine, is the *pyloric orifice*. It normally lies about 1 to 2 inches to the right of the midline at the level of the upper border of the first lumbar vertebra.

The stomach proper is divided into three parts: (1) the *fundus*, (2) the *pylorus*, and (3) the *body*. The fundus is the

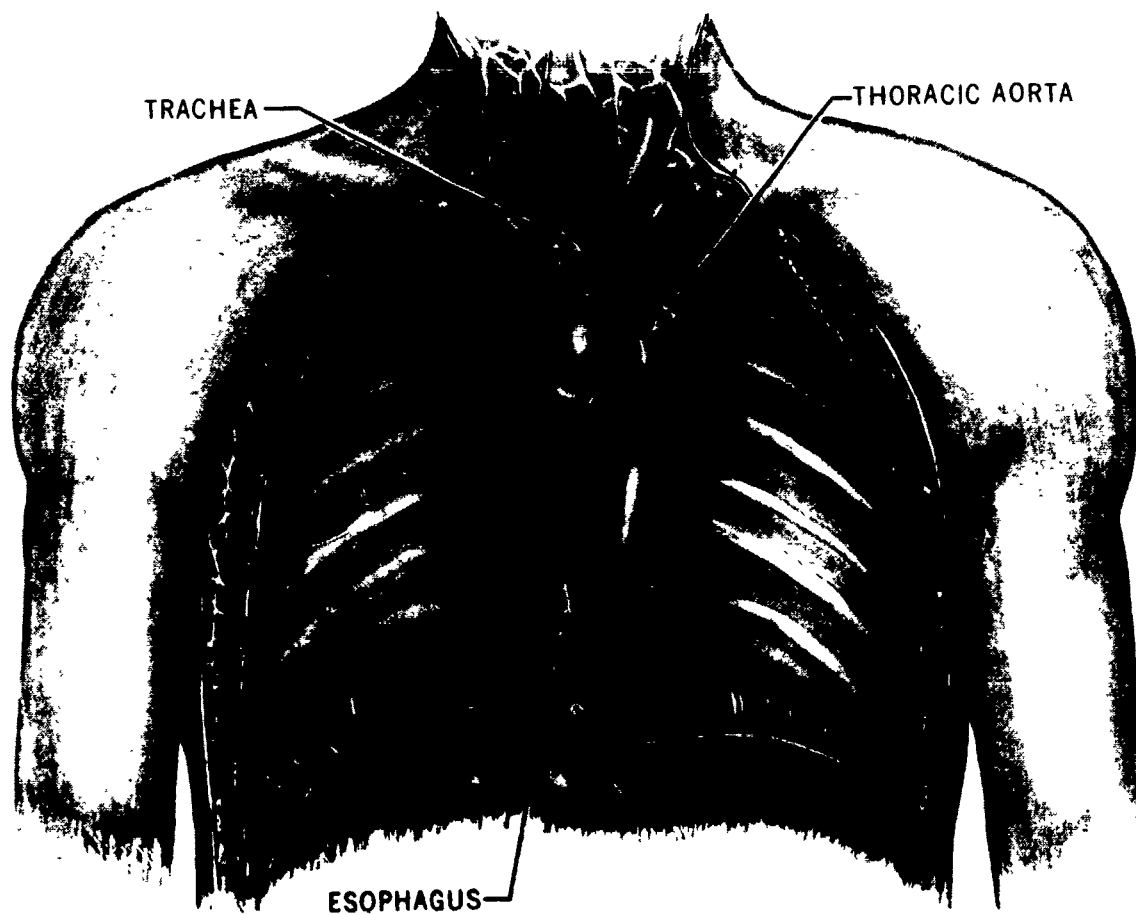


Figure 1-4. The esophagus and related structures

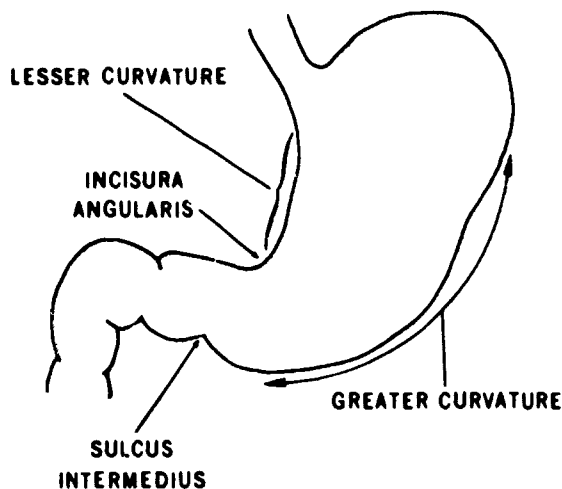


Figure 1-5 Curvatures of the stomach

dome-shaped portion lying directly beneath the left hemidiaphragm. It extends inferiorly to a transverse plane passing through the cardiac orifice. The pylorus is the distal portion of the stomach, and the term "body" identifies the remainder. Thick folds, called *rugae*, are located throughout the internal surface of the stomach. The rugae are most prominent when the stomach is empty and tend to flatten out when it is distended. The relationship of the stomach to surrounding abdominal structures can be seen in figure 1-7.

**Locations and shapes of the stomach.** One of the problems technicians face when radiographing the stomach is to include the entire structure on a 10- x 12-inch film. The problem is due to the various locations of the stomach. We cannot teach you precisely where to center your film and patient to consistently "hit" the stomach with a 10- x 12-inch—that comes only with experience. We will, however, review the relative location of the stomach to provide you with the basic information needed to radiograph the stomach. The location and shape of the stomach vary, depending upon the body habitus of the patient. (See fig. 1-8.)

a. Detail A in the figure shows an individual with the *sthenic* of average build. The esophagus of this individual joins the stomach at the level of the xyphoid process, while the most inferior portion of the greater curvature is at the level of the iliac crest.

b. The *hypersthenic* or obese individual is shown in figure 1-8,B. This person's stomach is almost horizontally situated and lies highest in the abdomen. Usually, the heavier the individual is, the more horizontal the position of the stomach.

c. The *hyposthenic* (fig. 1-8,C) individual is more slender than the sthenic individual. This person's stomach is "J-" or "fishhook-shaped" and lies low in the abdomen. The most inferior portion of the greater curvature extends 2 to 4 inches below the level of the iliac crest.

d. The *asthenic* individual is shown in figure 1-8,D. The "J-shaped" stomach is lower in the abdomen than in the hyposthenic individual. This stomach location is normally found in thin elderly patients who have lost their normal muscle tone

#### Exercises (603):

1. Which stomach curvature is (a) the largest, and which is (b) the smallest?
2. Where is the sulcus intermedius located?
3. What notch is located on the lesser curvature?
4. What are the names and locations of the two stomach openings?
5. Name the three subdivisions of the stomach and indicate which is the proximal, the middle, and the distal portion.
6. To what body landmark does the lowest portion of the stomach of an individual with an average build extend?
7. In what type of individual is the stomach located highest in the abdomen?
8. In what type of individual is the stomach located lowest in the abdomen?
9. In the hyposthenic individual, where is the most inferior portion of the stomach located?

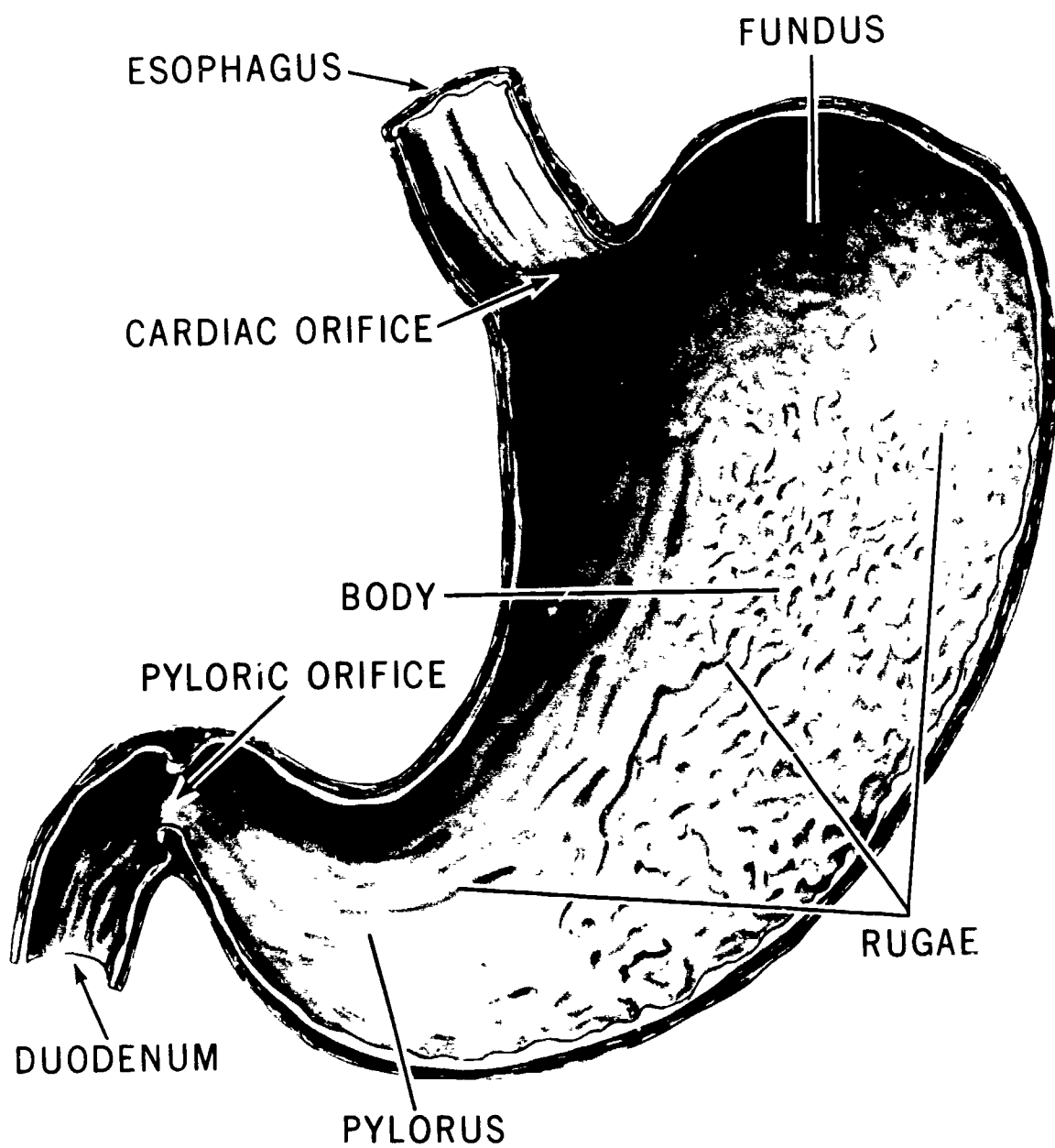


Figure 1-6 The stomach

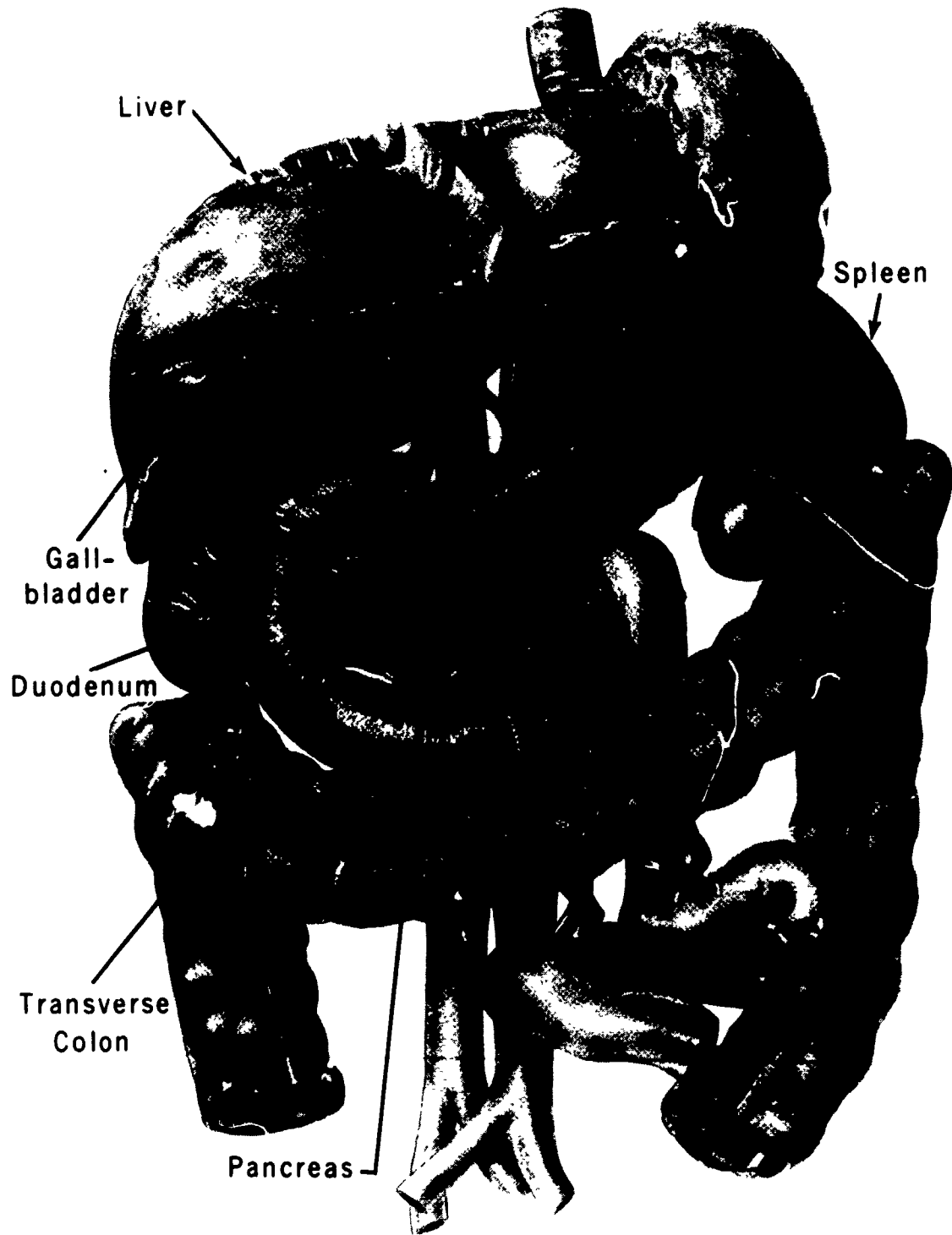
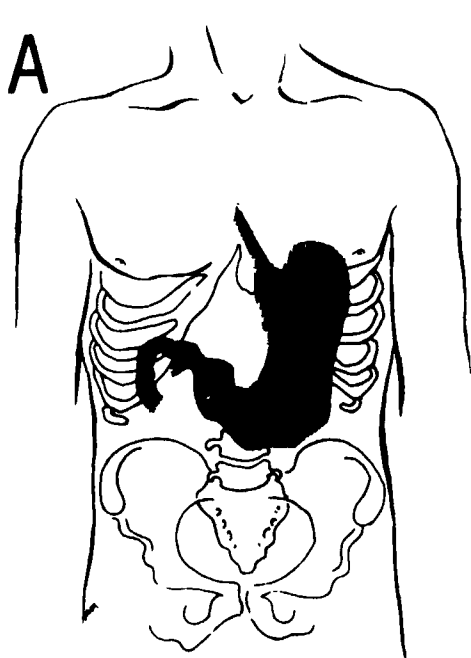
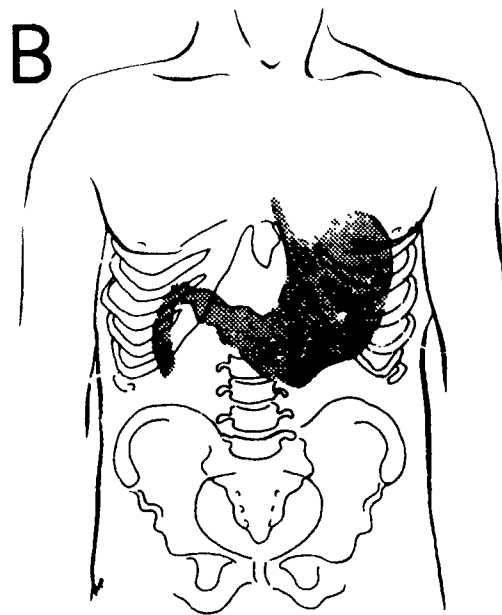


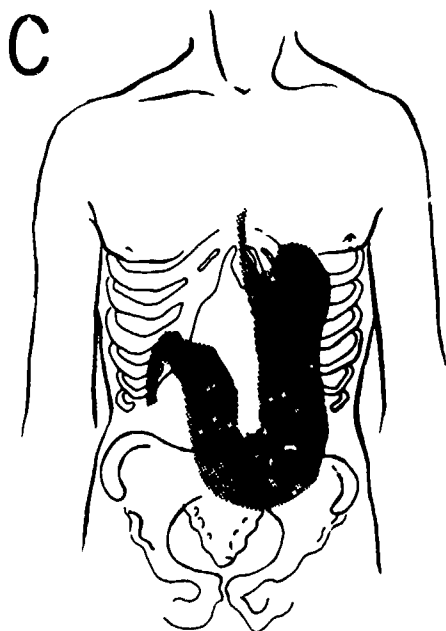
Figure 1-7 Location of the stomach in relation to other abdominal structures



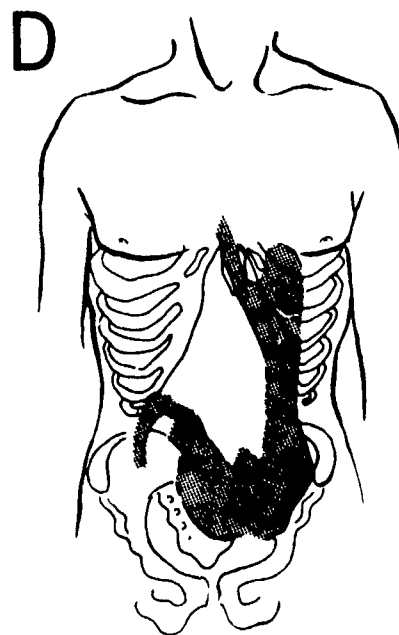
STHENIC



HYPERSTHENIC



HYPOSTHENIC



ASTHENIC

Figure 1-8 Variations in stomach location and shape



10. In the hyposthenic or asthenic individual, how is the stomach shaped?

604. Cite the names, dimensions, and radiographic significance of the major small bowel structures.

**The Small Bowel.** The small bowel connects the stomach to the large bowel and is divided into three portions: (1) the *duodenum*, (2) the *jejunum*, and (3) the *ileum*.

**Duodenum.** The proximal portion of the small bowel, the duodenum, shown in figures 1-7 and 1-9, is about 25 cm long. It is the widest segment of the small bowel. The first part of the duodenum, the *duodenal bulb*, normally extends posterolaterally from the pylorus—thus oblique projections are required to view the bulb in profile. Occasionally, it lies in an anteroposterior direction which requires a right lateral for profile demonstration.

From the bulb, the duodenum curves downward, descending over the head of the pancreas, then curves medially and upward behind the stomach, and finally

curves sharply downward. Part of its course roughly resembles a "C"; thus, the proximal half of the duodenum is sometimes referred to as the C-loop.

**Jejunum.** The duodenum joins the *jejunum* over the left margin of the second lumbar vertebra. The jejunum, approximately 7 to 8 feet long, follows a random course.

**Ileum.** The third portion of the small bowel, the *ileum*, is about 16 feet long and terminates at the *ileocecal valve*, which connects the ileum to the large bowel. The ileocecal valve, shown in figure 1-10, is especially significant to you because when visualized on a small bowel series, it generally marks the completion of the series.

#### Exercises (604):

1. What are the names and approximate lengths of the three parts of the small bowel?




Figure 1-9. The duodenum.

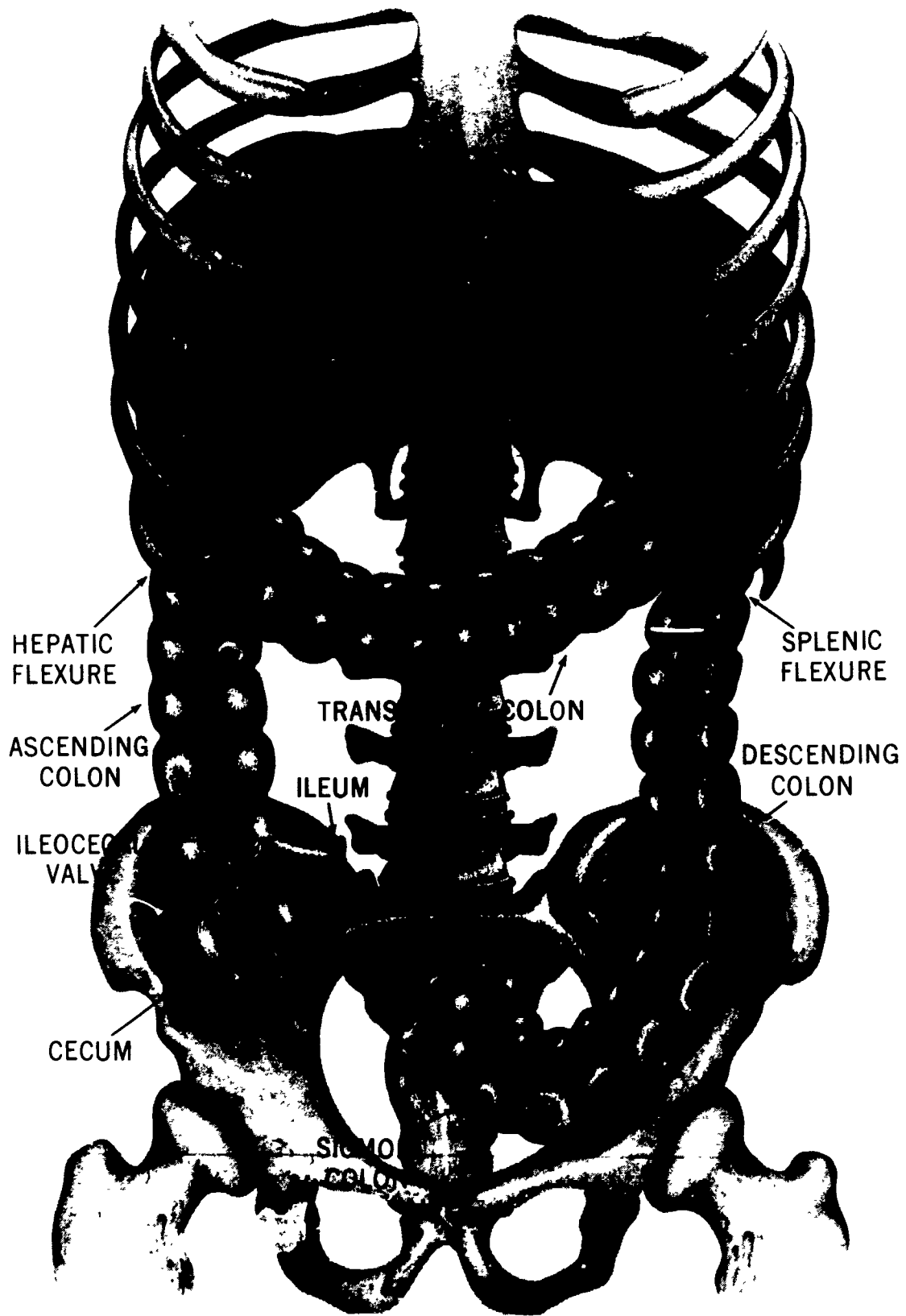


Figure 1-10. The large bowel

2. What projection is normally required to view the duodenal bulb in profile?
3. When does a lateral projection show a profile view of the duodenal bulb?
4. What is the radiographic significance of the ileocecal valve?
5. What section of the small bowel follows a definite course? Describe its course.
6. What is the "C-loop"?

**605. Beginning at the proximal end, name each portion of the large bowel in the order of appearance.**

**The Large Bowel.** The large bowel or *colon* is roughly horseshoe-shaped and extends from the ileocecal valve to the anus. (See figs. 1-10 and 1-11.) The proximal portion of the large bowel is the *cecum*, which is located below the ileocecal valve. The cecum is about 7 cm long, about 7.5 cm in diameter, and terminates in the appendix.

**Ascending colon.** The *ascending colon* is that portion of the colon above the level of the ileocecal valve. It extends upward from the junction of the ileum and cecum, along the right side of the abdomen, and to the inferior surface of the liver. At this point it curves forward and medially to form the *hepatic flexure*.

**Transverse colon.** The *transverse colon* extends across the abdomen from the hepatic flexure to the spleen. It passes over the descending segment of the duodenum, the pancreas, and the inferior margin of the stomach. At the level of the spleen it curves forward and inferiorly to form the *splenic flexure*.

**Descending colon.** The *descending colon* extends downward from the splenic flexure to the iliac fossa. From this point, it usually follows the inferomedial curvature of the ileum and joins with the *sigmoid colon*.

**Sigmoid colon.** The *sigmoid colon* is S-shaped, and dips into the pelvis, curving gently downward and toward the midline. Then it curves sharply upward and is slightly inclined toward the sacrum. At about the level of the first sacral segment, it curves posteriorly and joins with the *rectum*.

**Rectum and anus.** The rectum extends downward, lies between the bladder and the coccyx, and joins with the *anal canal*, which terminates in the *anus*.

**Exercises (605):**

1. Name each portion of the large bowel in order, from the most proximal to the most distal portion.

**606. Identify the composition, location, and function of major structures of the liver, gallbladder, biliary system, and pancreas.**

**The Liver.** The *liver* lies directly under the right hemidiaphragm and is divided into left and right lobes. (See fig. 1-12.) The larger right lobe houses the smaller right lobe proper, plus the *quadrate* and *caudate* lobes located on its inferior surface. The left lobe is small and wedge-shaped and is separated from the right lobe by the falciform ligament.

**The Gallbladder and Biliary System.** The *gallbladder* (see fig. 1-13) is situated on the inferior surface of the right and quadrate lobes of the liver. It usually is located between the ninth rib and the iliac crest, depending upon the patient's body habitus.

The biliary ductal system, illustrated in figure 1-14, is made up of the bile ducts found in the liver (called the *intrahepatic radicals*), the *right and left hepatic ducts*, the *common hepatic duct*, the *cystic duct*, the *common bile duct*, and the *duodenal papilla*. The small intrahepatic ducts emanate from all lobules of the liver. They pass downward and inward following the blood vessels and empty into the larger right and left hepatic ducts. These larger ducts join to form the common hepatic duct. This duct descends to join the cystic duct from the gallbladder. The combined ducts then form the common bile duct. The common bile duct is about 10 cm in length. It descends on a slightly lateral course where it usually joins with the *pancreatic duct* to empty into the posterior wall of the duodenum through a common orifice at the *duodenal papilla*, a protrusion into the duodenal lumen. The pancreatic and the common bile ducts occasionally enter the duodenum separately. A sphincter muscle, the *sphincter of Oddi*, normally prevents reflux into the common bile and the pancreatic ducts.

**The Pancreas.** The pancreas extends from the spleen across the abdomen to the "C-loop" of the duodenum. (See fig. 1-7.) It is comprised of a tail, which lies against the spleen, a long, flat body, and an irregularly shaped head, which lies against the C-loop. The pancreatic duct extends from the tail through the midportion of the pancreas, through the head of the duodenum. The *islets of Langerhans* are scattered throughout the pancreas and produce insulin. The pancreatic duct often bifurcates in the region of the head of the pancreas and gives rise to an accessory pancreatic duct, or *duct of Santorini*, which empties into the duodenum about 2.5 cm above the duodenal papilla.

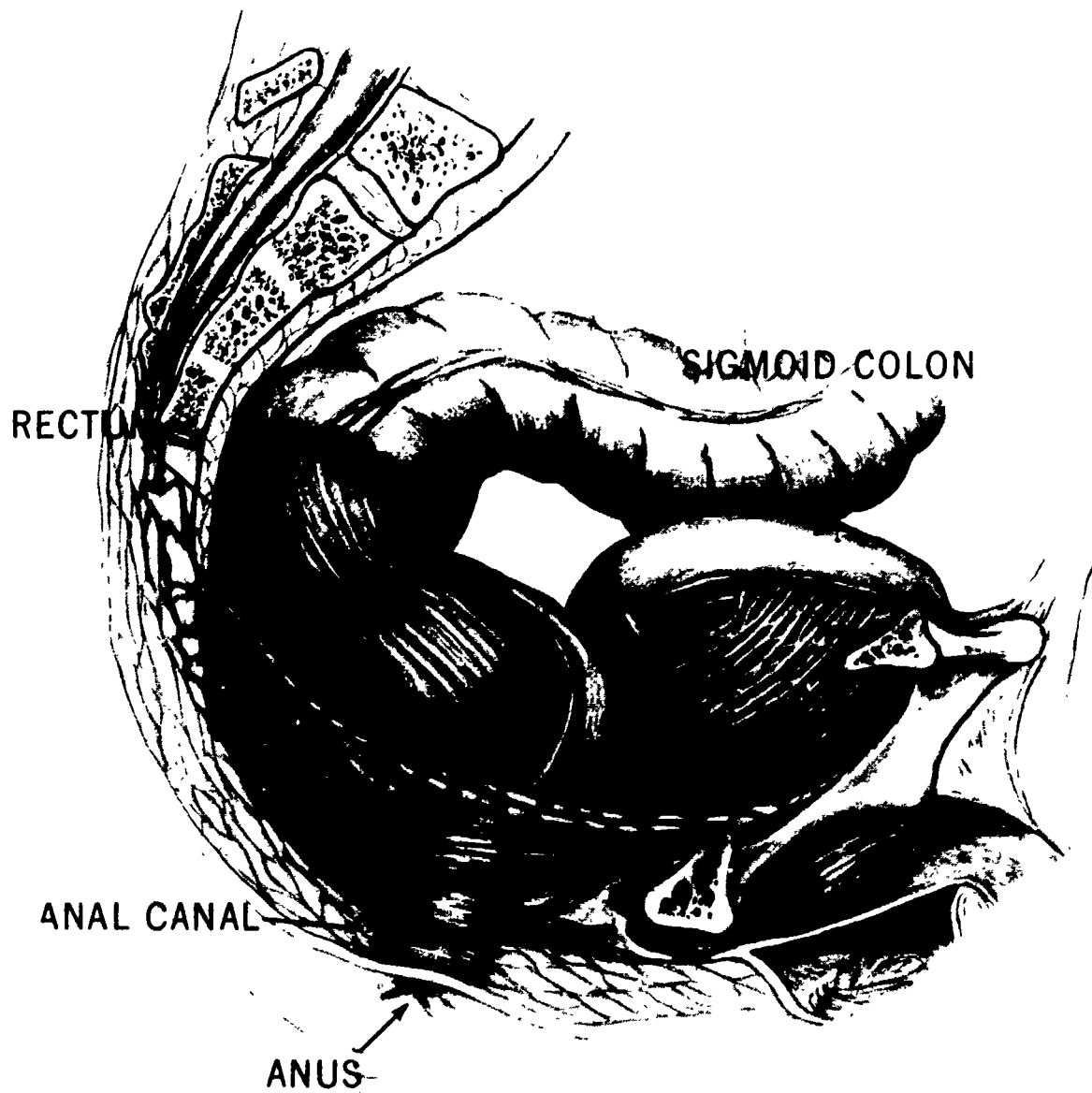


Figure I-11 The rectum and anus

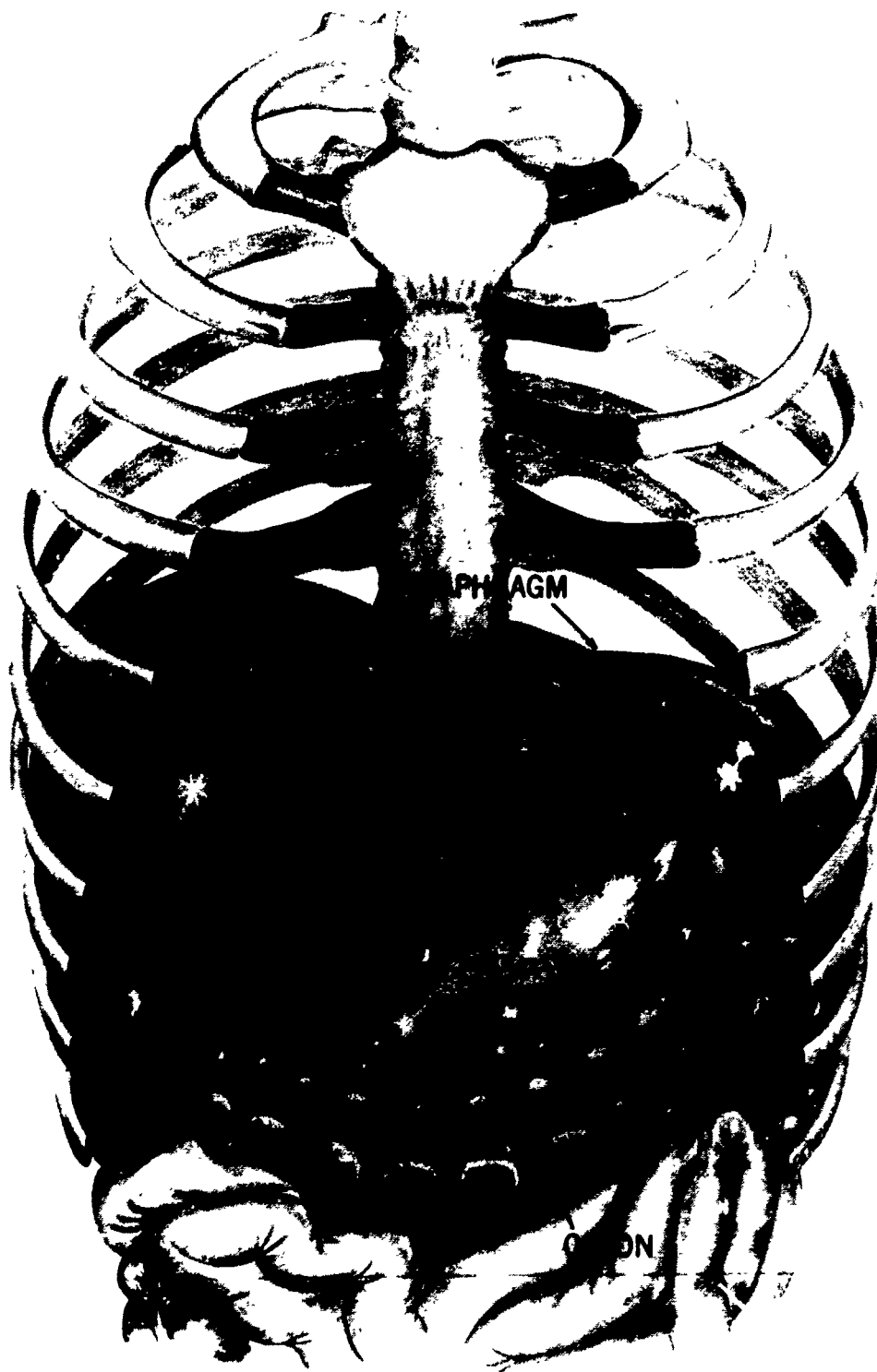


Figure 1-12 The liver

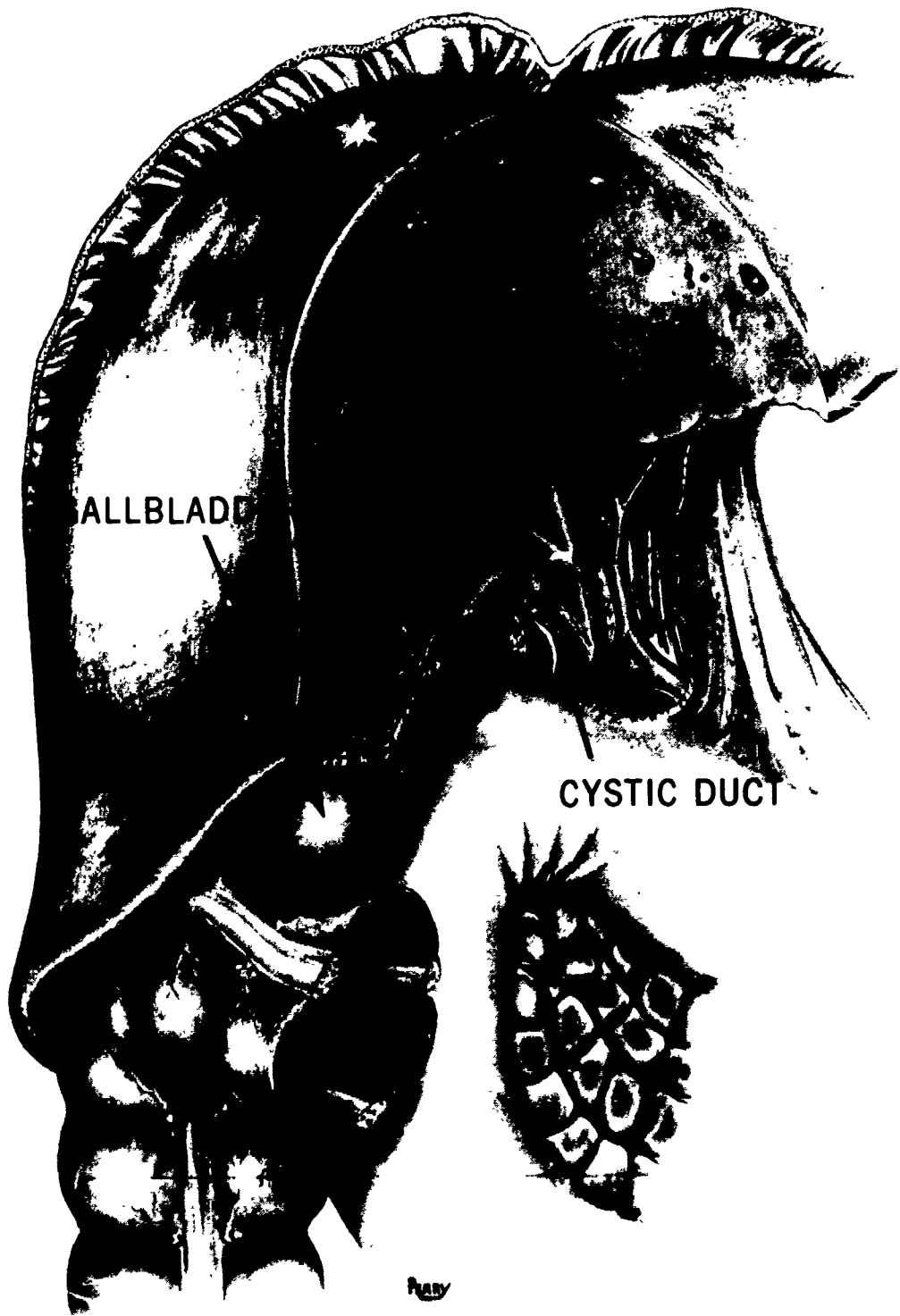


Figure 1-13 The gallbladder

431

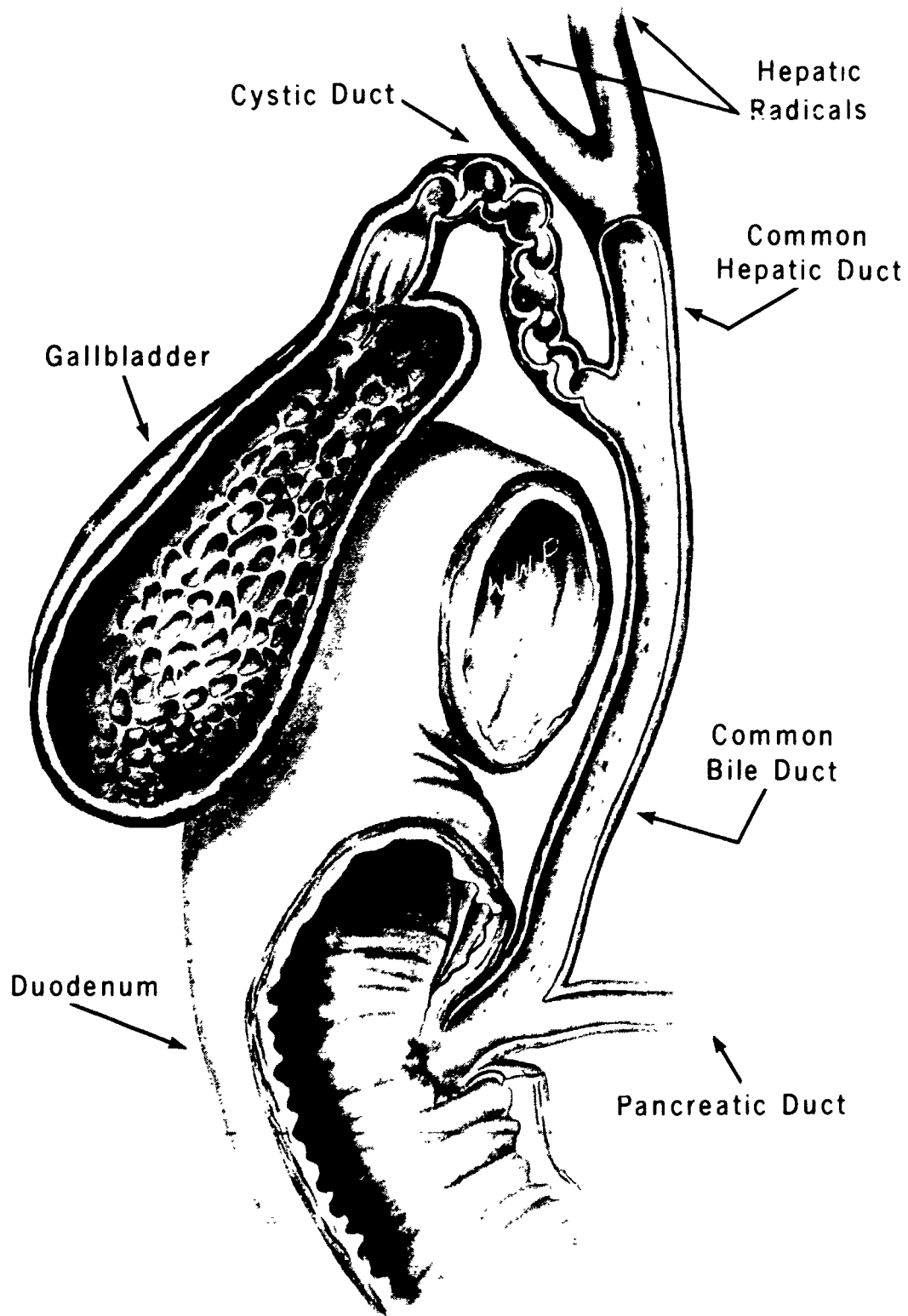


Figure 1-14 The biliary ductal system

### Exercises (606):

Select the terms that complete the following statements  
Some answer sets may be used more than once.

Common bile; pancreatic  
Duct of Santorini  
Intrahepatic radicals  
Inferior  
Right; quadrate; caudate  
Tail, body, head  
Hemidiaphragm  
Cystic  
Islets of Langerhans  
Posterior; duodenum  
Falciform ligament  
Common hepatic  
Duodenal papilla

- 1 The liver lies directly under the right \_\_\_\_\_.
- 2 The large right lobe of the liver is comprised of the \_\_\_\_\_, \_\_\_\_\_ and \_\_\_\_\_ lobes.
- 3 The left and right lobes of the liver are separated by the \_\_\_\_\_.
4. The gallbladder is located on the \_\_\_\_\_ surface of the liver
- 5 The right and left hepatic ducts unite to form the \_\_\_\_\_ duct.
6. The common bile duct empties into the \_\_\_\_\_ wall of the \_\_\_\_\_.
7. The small bile ducts distributed throughout the liver are called the \_\_\_\_\_.
8. The bile duct leading from the gallbladder is called the \_\_\_\_\_ duct
- 9 The \_\_\_\_\_ and \_\_\_\_\_ ducts usually join to empty by way of a common orifice
- 10 The sphincter of Oddi prevents reflux from the duodenum into the \_\_\_\_\_ and \_\_\_\_\_ ducts.
- 11 A protrusion inside the duodenal lumen where the two main ducts empty is called the \_\_\_\_\_.
- 12 The three major portions of the pancreas are the \_\_\_\_\_, \_\_\_\_\_ and \_\_\_\_\_
- 13 Insulin is produced in the pancreas by the \_\_\_\_\_.
- 14 An accessory pancreatic duct emptying into the duodenum is called the \_\_\_\_\_.

### 1-2. Patient and Contrast Media Preparation

Two very important aspects that lead to satisfactorily completing a contrast study of the digestive system are patient preparation and using the right contrast media. Your failure to adhere to departmental guidelines with these topics may cause the patient to repeat and examination.

**607. State the importance of patient preparation and specify how instructions are administered.**

**Patient Preparation.** The specific preparatory instructions you give to your patients scheduled for a contrast study of some part of the digestive system depend upon your radiologist. The important feature of the instructions is that it should result in the part under study or of related structures being free from food, liquids, gas, or fecal material. The obvious reason for the preparation is that pres-



ence of the materials mentioned may result in difficulties in interpretation due to "confusing" shadows seen during fluoroscopy or on the radiographs.

Your role in preparing the patient is usually limited to providing detailed, written instructions. Prepare the instruction forms and necessary supplies (such as pills, suppositories, etc.) in advance, so all patients receiving the same examination receive the same instructions, regardless of who schedules the patient. Make sure the instructions are clear so the patient understands exactly what to do and when to do it. If you provide a laxative, include in the instructions the nature of its action. If the examination calls for ingestion of selected foods, specify the foods allowed. Do not simply state in the instructions for the patient to remain on a low-residue diet for 3 days. Also, be sure to include the phone number of your department on the instruction form so that the patient can contact you if questions arise.

When the patient arrives for the examination, it is usually a good idea to ask if instructions were followed. For example, the patient may forget and eat breakfast on the morning of the scheduled upper gastrointestinal (GI) series. If you can identify this situation before the radiologist begins fluoroscopy, you can save time for everyone concerned, because the examination is usually cancelled. Also, if the pills you gave the barium enema (BE) patient "didn't work," the radiologist may request a flat plate of the abdomen before fluoroscopy to check for gas and fecal material in the colon.

#### Exercises (607):

1. Why is it important for the patient to be properly prepared before an examination of certain parts of the digestive system?
2. List five key points to remember when you prepare patient instructions.
3. How and why should you follow up on the patient's preparation?

#### 608. State the types, uses, radiographic significance, and preparation procedures pertaining to the contrast media used for the digestive system.

**Contrast Media.** There are several types and brands of contrast media used during contrast examination of the digestive system. Like many other aspects of radiology, your radiologist uses the contrast medium that provides the diagnostic information consistent with the requirements of the examination. The specific contrast medium used depends

upon your radiologist. However, we will provide you with some general information about the types of media.

**Barium sulfate preparations.** Barium sulfate preparations are available under many different brand names. Some examples are Barospense, Barotrast, Colonatrast, Oratrast, Esophotrast, Micropaque, E-Z-Paque, and Sol-O-Pak. Depending upon how supplied, they are used for visualization of the pharynx, esophagus, stomach, small bowel, and colon. Commercial paste or cream preparations are used for examination of the pharynx and esophagus. This and other barium sulfate pastes characteristically adhere to the mucosa for a long period of time and help you to "catch" the medium in the right area. Other barium sulfate preparations usually are supplied in powder form and are mixed with water before use. Some are prepackaged in disposable kits. Obviously, when mixing these preparations follow established procedures.

**Alternate digestive system media.** Oral Hypaque and Gastrografin are examples of contrast media that are sometimes used for examinations of parts of the digestive system when a barium sulfate preparation is contraindicated. They are supplied in powder or liquid form. The powder is simply mixed with water before use. These types of contrast media usually are selected for use by your radiologist if a perforation is suspected.

**Cholecystopaques.** Contrast media normally used to examine the gallbladder and biliary tree are sometimes called cholecystopaques. Some examples of oral cholecystopaques used to examine the gallbladder are Bilopaque, Oragrafin, and Telepaque. They are supplied in tablet, capsule, or powder (to be mixed with water). An example of an injectable cholecystopaque used for intravenous cholecystography or intravenous cholangiography is Cholografin. Operative, T-tube, and transhepatic cholangiograms usually are performed using a water-soluble injectable medium, such as Hypaque or Renografin.

**Other types of media.** Two other types of contrast media are frequently used to examine portions of the digestive system. Air is used for a double-contrast study of the colon. Air (carbon dioxide) is also introduced into the stomach by means of a carbonated beverage to provide an air-contrast study of the fundus. An oily contrast medium, such as Pantopaque, or a water-soluble injectable, such as Hypaque, is normally used to visualize the salivary ducts during a sialogram.

As mentioned previously, your radiologist determines the contrast medium used in your department. One example of why this decision is made is you may have a patient with a suspected tracheoesophageal fistula; if a contrast medium is introduced into the esophagus, it may end up in the lungs. Certain types of contrast material may be dangerous to the patient if introduced into the lungs. Consequently, in case of a tracheoesophageal fistula, a contrast medium introduced into the esophagus must be safe with respect to the lungs. In recent years, studies have shown that contrast materials other than those normally used in the past may be better suited for this examination. Therefore, we cannot overemphasize the importance of reviewing current literature when deciding on a contrast medium.

### Exercises (608):

1. What is the radiographic significance of commercial barium sulfate cream or paste preparations?
2. What action should you take immediately before using a barium sulfate preparation if it has been allowed to stand for a few minutes? Why?
3. If barium sulfate is contraindicated for use in the digestive system of a patient, what type of media might be used?
4. Why might a patient be given a carbonated beverage during an upper GI series?
5. A patient is suspected of having a tracheoesophageal fistula. What does this tell you about the contrast medium used to demonstrate the abnormality?

### 1-3. Contrast Studies of the Digestive System

In the final section of this chapter, we cover various radiographic aspects of the different contrast studies of the digestive system. We begin with sialography.

#### 609. State the equipment, procedures, and projections used for a sialogram.

**Sialography.** The salivary ductal systems are demonstrated by injecting a contrast medium into the main duct of each gland that opens into the mouth. As a general rule, the procedure is a simple one—your radiologist injects the contrast medium and you perform the necessary radiographs. Some radiologists prefer to fluoroscope the gland under examination and make spot films.

**Special Supplies.** While the supplies used for a sialogram vary from one radiologist to another, the following are frequently used:

- a. A small probe to locate and explore the main duct.
- b. A small bore polyethylene catheter or blunt needle through which to inject the contrast material.
- c. A small syringe (2.5 or 5 cc capacity) with which to inject the contrast material.
- d. A local anesthetic, injectable or viscous, to anesthetize the area about the main duct opening.
- e. A lemon, cut in quarters. The lemon sometimes serves two purposes: (1) to stimulate the gland so that the duct

opening can be easily located due to the discharge of saliva and (2) to evacuate the contrast material after the initial "filled" radiographs are obtained. (NOTE: A postevacuation radiograph is usually made to check the degree of evacuation.) If the contrast material is not completely evacuated before the patient leaves the department, the radiologist may ask the patient to continue stimulating the gland for 1 to 3 days using lemon slices, lemon juice, or chewing gum.

**Sialographic projections.** As a general rule, the specific projections used for a sialogram depend upon the particular gland under examination.

a. A tangential projection, either anteroposterior (AP) or posteroanterior (PA), is usually made if the parotid gland is being examined. The gland is located approximately halfway between the anterior and posterior surfaces of the patient so part-film distance is the same for each projection. Adjust the head until the infraorbitomeatal line is perpendicular to the film. Rotate the patient's face 25° to 35° toward the side being examined or until the parotid area is perpendicular to the film. Direct the C.R. perpendicular to the film.

b. A "straight" lateral projection can be made to visualize either of the three salivary glands. Extend the head slightly and position the skull in the true lateral position with the gland under examination nearest the film. Direct the C.R. perpendicular through the appropriate gland. Various other lateral projections are sometimes made, depending upon your radiologist. The radiologist may prefer a lateral with the patient's face rotated 15° downward (toward the tabletop) to visualize the parotid gland. Also, true lateral positions of the skull with the C.R. directed 10° to 30° cephalic are sometimes made to demonstrate either salivary gland.

c. The entire sublingual gland is usually demonstrated by using an inferosuperior or intraoral projection. Simply place an occlusal film as far into the patient's mouth as possible without causing undue discomfort and direct a horizontal C.R. to the center of the portion of the film in the patient's mouth. (See fig. 1-15.) A portion of the submaxillary gland can also be demonstrated by this projection.

### Exercises (609):

1. Why is a small probe used when performing a sialogram?
2. In place of a small bore polyethylene catheter, what can be used to introduce the contrast material?
3. Why is a lemon necessary in performing a sialogram?

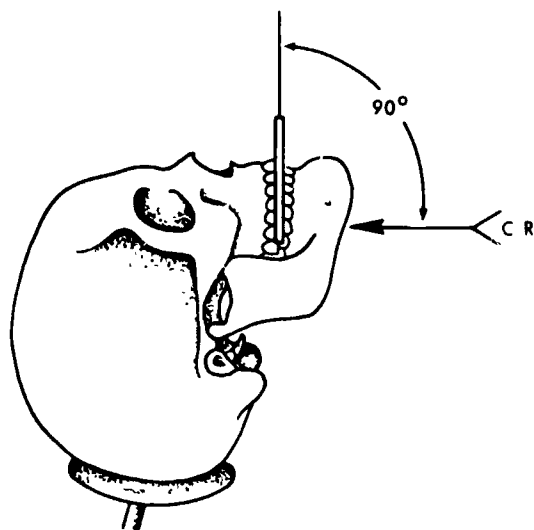


Figure 1-15 Inferosuperior projection of the sublingual gland

4. What salivary glands are demonstrated on the straight lateral projection?
5. Should a tangential PA or a tangential AP projection be made of the parotid gland?
6. What approximate degree of rotation should be used for a tangential projection of the parotid gland?
7. What gland is probably being demonstrated if a lateral projection is made with the patient's face rotated 15 downward?
8. What gland is entirely demonstrated with the intraoral projection?
9. If an AP tangential projection of the right parotid gland is being performed, in what direction is the patient's face rotated?

10. What range and direction of C.R. angulation is used for lateral projections of the salivary glands?

**610. State major procedures and various influential factors pertaining to contrast radiography of the pharynx and esophagus.**

**The Pharynx and Esophagus.** Contrast studies of the pharynx and esophagus, with the exception of a cardiac series, are usually made after fluoroscopy. In many cases, the radiologist makes spot films or records the parts using cine. Our discussion is directed toward ways to "catch" the contrast media during postfluoro radiography and the projections that are usually made.

**Pharynx.** Examinations of the pharynx (oropharynx and laryngopharynx) using barium sulfate are somewhat difficult to make because the bolus quickly descends through the area during deglutition (the act of swallowing). This causes many technicians to be "late" with their exposure. Also, the patient may not respond promptly to your instruction to swallow, which can cause you to make the exposure too early. One of the best ways to time the exposure to coincide with the barium-filled pharynx is to watch the patient's thyroid cartilage (Adam's apple). During deglutition the thyroid cartilage moves up and forward and then relaxes back to its normal position when the process is completed. Make your exposure immediately when the cartilage reaches its most anterosuperior position. At that instant, the oropharynx and laryngopharynx are usually filled with barium. The posterior portion of the oral cavity is also well visualized at the peak of the swallowing process.

**Esophagus.** Most radiographic examinations of the esophagus are made after the fluoroscopic phase of an upper GI series and to demonstrate enlargement of the heart.

Some radiologists have included in the routine of postfluoro upper GI films a radiograph of the entire esophagus. Usually, the projection is made with the patient recumbent in the right anterior oblique (RAO) position because the position presents a larger space between the heart and spine and, consequently, permits a more unobstructed view of the lower esophagus. The entire esophagus can usually be demonstrated filled with barium if the patient is allowed to drink the liquid barium through a straw continuously (drinking esophagram), beginning 4 or 5 seconds before the exposure. Of course, the exposure can be made after the patient swallows a single mouthful of liquid or paste barium, but demonstration of the entire esophagus filled with barium is difficult. A commercially prepared barium paste usually shows the outline of the entire esophagus due to the special coating characteristics of the medium, but the entire esophagus is usually not filled.

Radiographic projections of the esophagus to demonstrate enlargement of the heart should be made with the patient erect, at a 72-inch distance, and after full inspiration. One reason for these conditions is that the visible size of the heart is evaluated on the radiographs in

addition to possible displacement of the esophagus as a result of heart enlargement. Also, the pulmonary structures are evaluated because pulmonary changes may occur with heart enlargement.

Four projections of the chest with the esophagus outlined with the contrast medium are usually made—posteroanterior (PA), left anterior oblique (LAO), RAO, and left lateral. The left lateral is made as opposed to the right to minimize the part- (heart) film distance and the resulting magnification. The degree of rotation for the obliques varies slightly among radiologists; however, the RAO is usually 45°, while the LAO is normally 55° to 65°. The reason the obliquity is different for each oblique is that since the heart is located somewhat to the left of the midline, the LAO requires more rotation to project the heart clear of the spine.

You can obtain better results if you use barium paste for the cardiac series—specifically a commercial paste with special coating properties. Most radiologists can evaluate the esophagus as long as it is outlined by the paste rather than being filled by the liquid barium. The exact timing of the exposure is largely a matter of personal preference on the part of the technician. It also depends on the thickness of the paste and cooperation of the patient. Some technicians ask the patient to swallow a mouthful of paste and immediately take a breath—the exposure is then made immediately after the breath or after a delay of 1 to 4 seconds. The time lapse depends upon the thickness of the paste. Other technicians have the patient swallow one mouthful of paste, give another to hold, and then repeat the above procedure. The first mouthful increases the possibility for good esophageal coating.

There are two other factors you should keep in mind while performing this examination. First, the exposure factors should be increased slightly over normal chest techniques to permit visualization of the lower esophagus. Second, displacement of the esophagus by the great vessels is usually evaluated so it is important to outline the middle third of the esophagus as well as the distal third. Some radiologists do not care about the demonstration of the proximal third when a cardiac series is performed.

#### Exercises (610):

1. Why is it difficult to produce barium-filled radiographs of the pharynx?
2. Explain one way to synchronize your exposure with the act of swallowing to radiograph the contrast-filled pharynx.
3. Why is the esophagram made in conjunction with an upper GI series usually performed with the patient in the RAO position?
4. Describe the drinking esophagram.
5. How does the drinking esophagram radiograph differ from the "single-swallow" or "paste" radiographs in the visualization of the esophagus?
6. Why should esophagrams for heart evaluation be made with the patient erect, at a 72-inch FFD, and on full inspiration?
7. Why is a left lateral esophagram performed instead of a right lateral for a cardiac series?
8. Why is the LAO rotated more than the RAO?
9. What type of barium sulfate preparation produces the best results for a cardiac series?
10. What three factors influence timing of the exposure during a cardiac series?
11. Why should the exposure factors be increased slightly over "normal" chest techniques?
12. Why is it important to visualize the middle third of the esophagus during a cardiac series?

#### 611. Identify procedures used in hypotonic duodenography and the nature of projections performed for an upper GI series.

**The Stomach and Duodenum.** Examination of the stomach and duodenum, as you know, is made by a combination of fluoroscopy with cine or spot filming and "followup" or "overhead" films.

**Delay in gastric evacuation.** At times during the fluoroscopic phase of the examination, the contrast medium is slow to empty into the duodenum, preventing

visualization of the all-important duodenal bulb and the remainder of the duodenum. If the radiologist elects to have the patient wait outside the exposure room so that the next patient may be examined, the radiologist may ask you to have the patient lie down to speed up the evacuation of the stomach. When this situation arises, have the patient lie in either the right anterior oblique or right lateral position. It is in these positions that peristalsis is maximal due to the influence of gravity.

**Hypotonic duodenography.** Hypotonic duodenography is examination of the duodenum without interference from peristalsis. It enables the radiologist to more effectively evaluate the mucosa of the duodenum. The examination may be done in conjunction with a standard upper GI series. The patient is given an injection of propanthine or a similar drug that temporarily decreases the tone of the walls and dilates the duodenum.

The examination may also be scheduled separately, in which case the barium may be introduced by means of a tube or by oral ingestion. Propanthine is administered after the contrast medium. The radiologist may or may not require followup films. However, the radiologist almost always records the duodenum by using spot films or cine.

A side effect stemming from the injection of propanthine is loss of control of the voluntary muscles, including control of the respiratory muscles. If this condition occurs, artificial respiration must be administered until the effects of the drug have subsided. Consequently, your emergency tray containing resuscitation equipment should be readily available.

**Projections.** The specific followup projections you done during an upper GI series vary from one hospital to another. Five such projections are commonly performed. We discuss them from the aspect of the anatomy demonstrated. The duodenum is demonstrated fairly well in most of the projections with the exception of the bulb, as will be noted.

a. The PA projection shows the general contour of the stomach and duodenal bulb. If taken erect, it also reveals the shape and relative position of the stomach.

b. The left posterior oblique (LPO) shows an air-contrast view of the body, pylorus, and duodenal bulb. The fundus is shown filled with barium.

c. The RAO, on all patients except the hypersthenic individual, provides the best demonstration of the pylorus and duodenal bulb. The degree of obliquity required to present the pylorus and bulb in profile (which shows them best) depends upon the size, shape, and position of the stomach. Some radiologists request a standard 45° oblique while others want two or more obliques with varying degrees of rotation. Your radiologist may also request two radiographs made with the patient in the same oblique position to take advantage of the maximal peristalsis in that position.

d. The right lateral projection provides a profile view of the pylorus and duodenal bulb in a hypersthenic individual because those parts usually are aligned in an anteroposterior direction. The patient is sometimes referred to as having a "posterior bulb."

e. The erect left lateral is the best projection to show the relationship between the stomach and retrogastric structures.

## Exercises (611):

In the following exercise pertaining to an upper GI series and hypotonic duodenography, select the terms that complete the statements. Each answer set is used only once.

LPO

Walls

Maximum peristalsis

Mucosa

Right lateral

Retrogastric structures

Pylorus; duodenal bulb

Respiratory muscles; artificial respiration

Contrast medium; drug

Right anterior; right lateral; peristalsis

1. The \_\_\_\_\_ oblique and \_\_\_\_\_ positions should be used to promote gastric evacuation because \_\_\_\_\_ is maximum.
2. A hypotonic duodenal examination permits better evaluation of the duodenal \_\_\_\_\_.
3. The drug used in hypotonic duodenography decreases the tone of the \_\_\_\_\_ of the duodenum.
4. In hypotonic duodenography, the introduction of the \_\_\_\_\_ always precedes the introduction of the \_\_\_\_\_.
5. The drug used in hypotonic duodenography may cause loss of control of the \_\_\_\_\_, necessitating \_\_\_\_\_ until the drug effect subsides.
6. The \_\_\_\_\_ projection of the stomach and duodenum reveals an air-contrast view of the stomach (except for the fundus) and duodenal bulb.
7. The RAO presents the best view of the \_\_\_\_\_ and \_\_\_\_\_ on most individuals.

- 8 Two identical right anterior oblique projections may be made to take advantage of \_\_\_\_\_
- 9 For a patient with a posterior bulb, a profile view of the bulb is obtained with a \_\_\_\_\_ projection
10. The erect left lateral projection is best to demonstrate the relationship between the stomach and \_\_\_\_\_.

**612. Differentiate among the four methods of contrast examinations of the small bowel.**

**Contrast Examinations of the Small Bowel.** There are four methods by which contrast examination of the small bowel is performed. They are: (1) frequent interval method, (2) cold isotonic saline method, (3) intubation method, and (4) retrograde method.

**Frequent interval method.** The frequent interval method is often done in conjunction with an upper GI series. The barium is simply followed on 14- x 17-inch PA or AP radiographs taken at specific intervals—usually 30 minutes. Some radiologists inspect each film immediately so that they can examine the patient under fluoroscopy if a suspicious area is present. The last 14- x 17-inch radiograph taken is the first one that shows the head of the column of barium in the large bowel. At that time, the radiologist usually examines the patient fluoroscopically to evaluate and perhaps make spot films of the ileocecal valve.

In addition to demonstrating structural variations of the small bowel, the frequent interval method is also used to evaluate the *motility* of the small bowel. The radiologist determines the time it takes for the stomach to empty and the time required for the barium to reach the colon. Consequently, you should include time markers on the radiographs. In addition, include the stomach on the radiographs, at least until it is empty.

**Cold isotonic saline method.** The cold isotonic saline method involves mixing the barium with cold isotonic saline instead of plain water. The saline hastens stomach evacuation and motility through the small intestine. The barium may be mixed with saline as described above, or it may be mixed in the conventional manner, in which case the saline is given later. If this examination is performed in conjunction with an upper GI series, the latter procedure should be followed with the saline given to the patient after completion of the standard upper GI followup films. In place of saline, plain cold water may also be used to shorten stomach evacuation and small bowel transit time. The water may be given at various intervals throughout the examination, or it may be given only after completion of the followup films.

If a considerable amount of saline or water is given, the contrast medium tends to become diluted; consequently, some contrast and details are lost. However, this method does reduce the transit time considerably, allowing the barium to reach the colon quicker—thus reducing the overall time for the examination. Also, the radiologist can more readily follow the head of the column of barium fluoroscopically. The reason for this is that the barium moves fast enough to make it practical to monitor most or all of the barium movement to the colon. Naturally, with this method, normal stomach evacuation and transit time are not evaluated.

**Intubation method.** If the contrast medium cannot be administered orally as in the two previously described methods, it may be given through a tube introduced into the small bowel. The intubation has a definite advantage over all other types of small bowel examinations in that the contrast medium can be introduced directly into a small bowel segment. This allows visualization of the segment under study without interference from other portions of the small bowel because of superimposition.

**Retrograde method.** Most rarely performed is the retrograde method, also called reflux method, of small bowel examination. The contrast medium is introduced by a barium enema. The reflux of the contrast medium through the ileocecal valve enables the small bowel to be demonstrated. This method is usually used to detect organic filling defects.

**Exercises (612):**

1. Match the method of small bowel examination in column B with the appropriate statement or phrase in column A. Each column B item may be used once or more than once.

Column A	Column B
_____ (1) Evaluates small bowel motility	a Frequent interval method
_____ (2) Depends upon reflux	b Cold isotonic saline method
_____ (3) Medium is introduced directly into a small bowel segment	c Intubation method
_____ (4) Medium passes rapidly through the small bowel	d Retrograde method
_____ (5) Requires time markers	
_____ (6) Used to detect organic filling defects	
_____ (7) Permits study of a small bowel segment without interference from superimposition	
_____ (8) Uses barium enema	
_____ (9) Makes use of cold water	
_____ (10) Hastens stomach evacuation	
_____ (11) Include stomach on radiographs until it is empty	

### 613. State fundamental procedures involved in air-contrast studies of the colon.

**Examinations of the Large Bowel.** Basically, two types of radiographic examinations are performed on the large bowel—the barium enema and the double-contrast or air-contrast study. As a general rule, the air-contrast study is performed by one of two methods—direct or two-stage.

**Direct air-contrast studies.** The direct air-contrast study is performed simultaneously with the barium enema. A relatively small amount of barium sulfate is introduced into the colon, followed by air. The major difference between the direct and two-stage methods is that with the direct method the barium is not evacuated before the air is introduced. Naturally, the direct method requires equipment that allows you to switch immediately from barium to air during fluoroscopy. If your department uses certain disposable enema kits, you will have to rig a Y-connector to the tubing so that air or barium can be introduced into the colon. Some disposable kits are especially designed for direct air-contrast studies—eliminating the requirement for a special connector.

Because a patient does *not* evacuate the barium prior to the injection of air in this study, it is most important that the patient's colon be exceptionally clean. Residual fecal material can often obscure small polyps or tumor masses.

**Two-stage air-contrast studies.** The two-stage method of air-contrast examinations is performed as follows: After a standard barium enema, the patient evacuates the contrast medium and is returned to the table. Air is then introduced into the colon, usually by means of a single tube to which is attached an enema tip and air bulb.

#### Exercises (613):

1. What is the major difference between the direct and two-stage methods of air-contrast studies of the colon?
2. The equipment for introducing the contrast media during a direct air-contrast study must differ from that of a two-stage study in what way?
3. Why is it important that a patient's colon be exceptionally clean for a direct air-contrast BE?

### 614. Determine whether statements pertaining to the preparation of the barium liquid for colon examinations are correct.

**Barium solution preparation for barium enemas.** You should prepare the barium sulfate for a colon examination according to established procedures. Most radiologists like

the temperature of the liquid to be about 85° F, while others like it slightly warmer. A few of them want the temperature to be considerably colder, about 41° F. Naturally, if this low temperature is desired, you will either have to mix the preparation in advance and refrigerate it, or mix the barium sulfate with refrigerated water. In either case, to ensure the correct temperature, use a thermometer rather than estimate the temperature. Also keep in mind that the temperature of a solution allowed to stand at room temperatures for a long period of time will either increase, if it is around 41° F, or decrease, if around 85° F. In view of the changing temperature, it is usually best to mix the solution immediately before each examination. However, if this procedure is not possible, maintain the correct temperature by allowing the solution container to remain in water of the corresponding temperature.

The thickness of the barium sulfate solution for a colon examination also varies. The ratio of barium sulfate to water ranges from 1 part barium to 4 to 8 parts water by volume. The important factor is *consistency from one batch to another*. This means you should have a reliable means of measuring both parts of the mixture so that the thickness can be repeated day after day. The usual procedure calls for adding a certain amount of water to a disposable BE bag and then agitate the solution well until the barium sulfate is in solution. The bag should be shaken again just prior to the start of the exam procedure.

Some radiologists prefer using premixed, high-density barium sulfate for air-contrast BEs. Premixed liquid barium products are more consistently mixed by the manufacturer, generally more uniform for radiographic use than most barium suspensions mixed in a radiology department, and are better for air-contrast BEs because the premix liquid is thicker and provides excellent coating of colon walls.

Whether a premix liquid or a regular disposable barium bag is used, the most important criterion of the barium is that it flow sufficiently to coat the walls of the colon. You can use a hydrometer to spot check the specific gravity and, therefore, the thickness of the preparation. Some hydrometers cannot be used for this purpose since they are not scaled in the appropriate range. Special hydrometers are available to test the specific gravity of barium sulfate preparations. Of course, the specific gravity you use depends upon local policy.

Another important point to keep in mind is to "bleed" the tubing immediately before you insert the rectal tip to remove the air. This step serves two purposes: (1) it tells you whether or not the solution runs freely through the tube, and (2) it prevents the air in the tube from being introduced into the colon ahead of the barium. Air introduced in this manner can interfere with good visualization of the colon.

#### Exercises (614):

Indicate whether the following statements pertaining to preparation of the barium liquid for colon examinations are true or false. If you indicate false, explain your answer.

- \_\_\_\_\_ 1. The temperature of the liquid should always be 85° F.
- \_\_\_\_\_ 2. You should use a thermometer to check the temperature of the liquid rather than estimate it.
- \_\_\_\_\_ 3. To help ensure the correct liquid temperature, you mix it immediately before use.
- \_\_\_\_\_ 4. The barium sulfate preparation is usually mixed at a ratio of 1 part barium to 4 to 8 parts water by volume.
- \_\_\_\_\_ 5. You should use a hydrometer to spotcheck the thickness of your barium preparation.
- \_\_\_\_\_ 6. The most important criterion for the barium sulfate is its ease in dissolving
- \_\_\_\_\_ 7. "Bleeding the tube" prevents airlock.

**615. Specify procedures for followup projections taken in conjunction with contrast colon examinations.**

Followup projections. The followup projections taken in conjunction with a colon examination may consist of a standard "routine," or the radiologist may vary them according to the fluoroscopic findings. In either case, there are several that are performed. As a general rule, the 14- x 17-inch film should be centered to the iliac crest for all projections, except those indicated below. Also, when a large patient is examined, it is difficult and sometimes impossible to include the entire colon on a single film. When such is the case, use two films crosswise instead of one lengthwise for the AP or PA. Oftentimes, you can include the entire colon on the obliques when it is not possible to do so on the PA or AP.

When performing air-contrast radiographs, you should rotate the patient 360° before performing each radiograph to recoat the walls of the colon with the barium. For example, if the patient is supine and you wish to perform a right lateral decubitus, rotate the patient 360° to the supine position before turning the patient on the right side for the decubitus projection.

PA, AP, and 45° anterior or posterior oblique projections are frequently made on the colon. On the PA and AP

radiographs, the hepatic and splenic flexures and the sigmoid colon usually are not seen well because the loops are overlapped. The LPO or RAO usually provides an unobstructed view of the hepatic flexure, while the RPO or LAO does the same for the splenic flexure.

A lateral projection of the rectum is also frequently performed. For this projection, align the patient so that a coronal plane, 2 inches posterior to the midaxillary line, is centered to the midline of the table. Direct the C.R. perpendicularly through a point on the coronal plane 2 inches superior to the symphysis pubis.

The sigmoid colon and rectum are also demonstrated by placing the patient in the LPO position and directing the C.R. 2 inches medial to the right (elevated) anterior-superior iliac spine at an angle of 30° to 35° toward the head. Also, the supine position is used with the same C.R. angulation and direction, or the prone position with a caudally angled C.R. (also 30° to 35°).

The *Chassard-Lapine* projection also demonstrates the sigmoid colon and rectum. (See fig. 1-16.) Seat the patient on the side of the table and have him or her abduct the femurs so they will not interfere with the flexion of the patient's body. Have the patient lean forward as far as possible and hold the ankles for support. Direct the C.R. perpendicularly through the midline of the lumbosacral region at the level of the greater trochanters to the center of the film. The exposure for this projection should be approximately the same as that required for a lateral projection of the rectum.

As a rule, some projections of the air-contrast study are performed with a horizontal C.R. to demonstrate the air/fluid levels. Both lateral decubitus projections are almost always included. Also, erect AP or PA projections are usually performed. Keep in mind that even though the thickness of an abdomen is the same, you should reduce your exposure slightly from normal when performing air-contrast projections because of the radiolucency of the air.

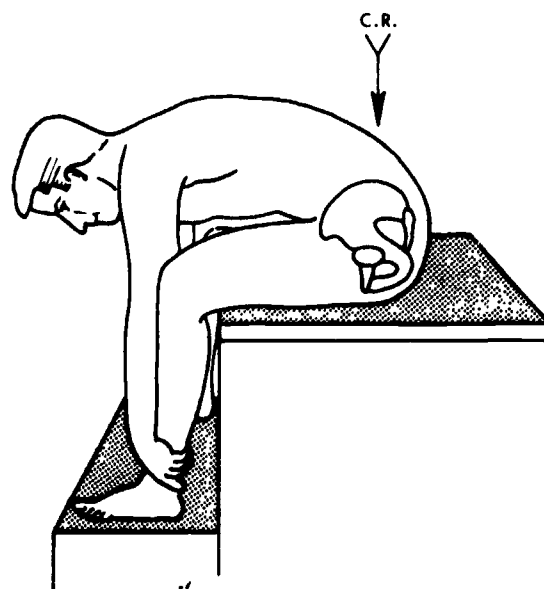


Figure 1-16 Chassard-Lapine projection.



### Exercises (615):

1. Where should 14- x 17-inch cassettes be centered for most colon radiographs?
2. What action should you take with regard to the AP or PA projection of the colon on a large patient that is being examined?
3. Why should the patient be rotated 360° before performing each radiograph of the colon during an air-contrast examination?
4. What parts of the colon are not visualized on the AP or PA projection?
5. (a) What oblique projection(s) provide(s) an unobstructed view of the splenic flexure? (b) The hepatic flexure?
6. How should the patient and C.R. be aligned for a lateral rectum?
7. List three positions in which the C.R. is angled that demonstrate the sigmoid colon and rectum. Give the angle and direction of the C.R. for each.
8. What part(s) of the colon is/are demonstrated on the Chassard-Lapine projection?
9. What relative exposure should be used for the Chassard-Lapine projection?
10. Why are some air-contrast radiographs of the colon taken with a horizontal C.R.?

11. What relative exposure should be used for air-contrast projections of the colon? Why?

### 616. Specify fundamental procedures involved in the performance of an oral cholecystogram.

**Gallbladder and Biliary System Studies.** Examination of the gallbladder is usually done by an oral cholecystogram, although occasionally it can be demonstrated by the intravenous injection of contrast medium. The biliary ductal system is examined either by intravenous, T-tube, transhepatic, or operative cholangiography.

**Oral cholecystography.** The gallbladder is located anywhere from the level of the right eighth rib to well below the iliac crest on the right side. Also, with regard to its medial/lateral location, it is superimposed over the spine, located near the lateral wall of the abdomen or anywhere in between. The precise location depends for the most part on the patient's body habitus. In a hypersthenic individual, it is usually located high in the abdomen toward the lateral wall; in the asthenic or hyposthenic individual, it is usually located lower and nearer the spine. In addition, the gallbladder "moves" from one location to another as you change the patient's position to perform the various radiographs.

With the exception of the scout film, radiographs of the gallbladder should be made with tight collimation. Consequently, you can see it is important for you to properly locate the gallbladder with the scout film so that you can perform the remainder of the radiographs with the gallbladder properly centered in the small cone field.

Most radiologists require an initial PA 10- x 12-inch scout film of the gallbladder area. The PA projection is better than the AP because the gallbladder is located more toward the anterior surface of the abdomen. Center a sagittal plane midway between the midline and the lateral abdominal wall to the center of the table. Adjust the center of the film to the level of the 10th posterior rib. Some technicians like to leave the patient and tube in position while the scout film is being processed. After inspection of the scout, they make a mark on the patient's back directly over the gallbladder, using the lighted cone field as a reference. Other technicians prefer to tape a line of lead numbers or letters over the patient's spine and determine the location of the gallbladder with respect to the lead markers. It doesn't matter how you locate the gallbladder as long as you can accurately project it in a small cone field when performing the remaining radiographs.

If the gallbladder is not seen on the 10- x 12-inch scout film, the most probable cause is that it did not visualize. However, rarely is it located outside the area covered by the film. It can be located on the patient's left side and, while this possibility is remote, some radiologists require a 14- x 17-inch film of the entire abdomen before terminating the examination to evaluate that possibility. Also, the radiologist sometimes likes to see, in case of a nonvisualized gallbladder, whether or not contrast medium

is in the stomach, small bowel, or large bowel. Occasionally, patients do not take pills at the prescribed time. If a patient took them just before coming to the radiology department, the concentration of medium in the bowel can provide the radiologist with additional information about the nature of contrast medium absorption into the bloodstream.

Various projections are performed of the gallbladder after the scout film is taken. At least one projection, erect or right lateral decubitus, is made with a horizontal C.R. for two reasons: (1) small stones heavier than bile may gravitate to the dependent portion of the gallbladder and therefore be visualized more readily due to concentration, and (2) small stones lighter than bile have a tendency to stratify, also increasing the possibility of their visualization. The stratification is due to the fact that bile layers out according to the specific gravity. Small radiolucent stones float at the surface of a specific bile layer, depending upon the relative specific gravity. Keep in mind that with both the erect and decubitus projections, the gallbladder will "drop" slightly, requiring you to adjust your centering point. On the erect, it usually moves inferiorly 2 to 4 inches, while on the decubitus it moves laterally 1 to 2 inches.

Other projections of the gallbladder are supine LAO and RPO. (NOTE: The erect projection mentioned before may be taken with the patient in the LAO or RPO position. In fact, because the gallbladder normally shifts closer to the spine in the erect position, some radiologists prefer an oblique erect projection be made to avoid superimposition over the spine.) The oblique projections are usually made routinely with 45° of obliquity.

One of the problems you must overcome when performing a gallbladder series is the superimposition of gas over the gallbladder. Radiologists usually require at least one projection with the gallbladder free of overlying gas. If the routine projections reveal overlying gas, PA or oblique projections made with patient in the Trendelenburg position may be the answer. Also, recumbent or erect obliques made with the patient rotated more or less than 45° may project a gallbladder free of gas.

To check the function of the gallbladder, a fatty meal is given to the patient and radiographs are made afterwards. If the original radiographs reveal stones in the gallbladder, some radiologists do not want a fatty meal given to the patient. Since ingestion of fatty foods precipitates the flow of bile to the duodenum, one or more of the gallbladder stones may also leave the gallbladder and become lodged in the cystic or common bile duct. This condition can be dangerous to the patient and may require immediate corrective surgery.

#### Exercises (616):

1. The gallbladder is usually located within what mediolateral and superoinferior boundaries?
2. Why should you withhold the fatty meal from a patient whose films demonstrate gallstones?

2. Where is the gallbladder located in a hypersthenic individual? In a hyposthenic individual?
3. To increase subject contrast of a gallbladder, what type of collimation should be used?
4. Where should you center for a gallbladder scout film?
5. Although there are several ways to locate and mark the gallbladder, what is your most important concern?
6. What is the most probable cause of a "missing" gallbladder on a 10- x 12-inch scout film?
7. Why might you perform a 14- x 17-inch radiograph of a patient with a suspected nonvisualized gallbladder?
8. Why should at least one projection of the gallbladder be made with a horizontal C.R.?
9. Approximately how far does the gallbladder "drop" for a decubitus projection? For an erect projection?
10. Why should the erect gallbladder radiograph be made with the patient in the oblique position?
11. Give two ways to rid the gallbladder of overlying gas shadows.
12. Why should you withhold the fatty meal from a patient whose films demonstrate gallstones?

**617. Differentiate among the various methods of cholangiography.**

***Intravenous cholecystography and cholangiography.***

The gallbladder and biliary ductal system can be examined by intravenous introduction of a contrast medium, such as Cholografin, especially designed to be secreted by the liver. The contrast medium usually appears in the bile within 10 to 15 minutes after injection, and maximum filling of the gallbladder is reached in 2 to 2 1/2 hours. The intravenous examination may be performed to visualize the gallbladder, ductal system, or both. If the gallbladder is to be examined, it is done by using the oral cholecystographic projections previously described after maximum filling has been reached. If the gallbladder fails to visualize in a reasonable period of time, it sometimes can be demonstrated on a film taken 24 hours later.

If the examination is primarily a cholangiogram, a series of radiographs usually are made with the patient in the RPO position rotated 15°. This oblique position is used because it clears the distal end of the common bile duct from superimposition over the spine, which occurs if the patient is in the "straight" AP position.

After a scout film is made to determine whether or not gas and fecal material may preclude visualization of the bile ducts, a radiograph usually is made 10 to 15 minutes after injection and every 10 or 15 minutes or so thereafter. Actually, the radiologist usually inspects each radiograph and tells you when to make the next radiograph. When it is determined that the ducts are adequately visualized, you may be asked to do tomograms, which usually demonstrate the ducts better than the plain radiographs. Since the major ducts are located approximately midway between the anterior and posterior surfaces of the abdomen, the cuts should be in that vicinity. The specific cuts, of course, depend upon your radiologist, but usually they cover an area from 1 to 2 cm above to 1 to 2 cm below the level of the biliar ducts.

***Transhepatic, operative, and T-tube cholangiography.***

These three types of cholangiograms are made by introducing the contrast medium directly into the biliary

ducts. All of them demonstrate the ducts more clearly than the intravenous method because the contrast medium is not significantly diluted. Specific procedures for these three vary from place to place.

The contrast medium for the transhepatic examination is introduced into the ducts by means of a needle about 11 or 12 cm in length. The needle is passed from the anterior surface of the abdomen through the liver into the appropriate viliary duct. While this examination is sometimes performed in the radiology department, it is frequently performed in the operating room just prior to surgery.

An operative cholangiogram is performed during a cholecystectomy. It may be done before or after the gallbladder is removed (usually after). The contrast medium is injected directly into the biliary ducts.

A T-tube cholangiogram is performed by introducing the contrast medium directly into the biliary ducts by means of a T-tube left in place after a cholecystectomy.

**Exercises (617):**

1. 1. Match the type of cholangiogram in column B with the appropriate statement or phrase in column A. Each column B item may be used once or more than once. In addition, more than one column B item may match a single column A item.

Column A	Column B
_____ (1) Medium is injected directly into ducts.	a Intravenous.
_____ (2) Performed during surgery	b T-tube
_____ (3) Performed after cholecystectomy	c Operative.
_____ (4) Performed in the operating room	d Transhepatic
_____ (5) May also demonstrate the gallbladder	
_____ (6) Usually requires RPO radiographs	

## Contrast Studies of the Urogenital System

THE UROGENITAL system consists of the urinary and reproductive organs. Malfunction of any component of this complex system may result in permanent damage or, in the case of the urinary organs, even death. Consequently, early and accurate diagnosis of such maladies is essential for surgical or medical correction. As a rule, such diagnosis involves radiological examination of the affected component. Since you are required to assist with these examinations, you must be familiar with the structure and function of the organs involved and also versed in the procedural steps employed to radiologically demonstrate them. We begin this chapter with a look at the anatomy and physiology of the urinary system. After that, we discuss the all-important contrast media reactions and some emergency equipment, followed by the IVP, cystogram, and cystourethrogram. Finally, we discuss the anatomy and radiographic considerations of the female reproductive system.

### 2-1. Anatomy and Physiology of the Urinary System

The urinary system is vital to life in that it provides a means for collecting waste products from the bloodstream, filtering and storing these products, and excreting the waste. Major portions of the urinary system are the kidneys, ureters, bladder, and urethra.

**618. Indicate whether statements pertaining to the anatomy and physiology of the kidneys are correct.**

**The Kidneys.** The bean-shaped kidneys are the principal organs of the urinary system. They are situated in the retroperitoneal space on each side of the vertebral column. Each kidney is about 11 cm long, 5 to 7 cm wide, and 2.5 to 3 cm thick.

**Surrounding structures.** The superior margins of the kidneys are approximately at a level with the 12th thoracic vertebra. Their inferior margins are usually aligned with the third lumbar vertebra. The top of the left kidney is situated slightly higher than the organ on the right. (NOTE: This is the usual location of the kidneys when the patient is supine. When the patient is erect, these organs descend a bit.) Figure 2-1 illustrates the relationship between the urinary system, the spine, the pelvis, and the rib cage.

Since the kidneys are retroperitoneal structures, they are posterior to most other abdominal organs. The liver, for example, covers the greater portion of the anterior surface

of the right kidney, and the descending portion of the duodenum covers a small segment of the medial aspect of this surface. The hepatic flexure and a portion of the transverse colon cover the remaining inferior portion. The spleen covers most of the anterior surface of the left kidney, while the posterior gastric wall covers a portion of the superior aspect of this surface. The posterior pancreatic surface overlies the medial midsection. The jejunum covers the inferomedial surface of this kidney, and the inferolateral tip is covered by the transverse colon.

Not all of the abdominal structures lie anterior to the kidneys. For instance, the adrenal glands are situated on the medial and superior aspects of the upper portions of both organs. These glands are part of the endocrine system and serve no urinary function.

The diaphragm covers the superior renal surfaces and a portion of the posterior surfaces. The 12th rib usually overlies both kidneys. Occasionally, the 11th rib also overlies the upper aspect of each kidney. The remainder of both organs is covered by musculature and fatty tissue. The medial portions are close to the psoas major muscles, the central sections are just anterior to the quadratus lumborum muscle, and the inferolateral aspects are covered by the sacrospinalis muscles. Laterally, the renal organs are cushioned by layers of fatty tissue, which lie between them and the lateral walls of the abdomen.

**Kidney structure.** The medial surfaces of the kidneys are concave. This portion of each kidney houses the renal hilum, through which the renal arteries enter the kidneys and where the renal veins and renal pelves exit. All other surfaces of the renal organs are completely covered by a layer of fatty tissue referred to as the *perirenal-fat pad*. This fatty tissue serves as a shock absorber and a temperature-control device for the kidneys. It also serves to separate the adrenal glands from the renal organs, a significant fact when a differential diagnosis of adrenal or renal cortical tumor masses is sought. Figures 2-2 and 2-3 illustrate the structures of the kidney. Refer to these figures as we cover the renal components.

The *cortex* or outer layer contains the *glomeruli* and *convoluted tubules* which form the *nephron* or functional unit of the kidney. There are about one million nephron units in each kidney. The *medullary* layer of renal tissue is inside the cortex and contains the *collecting tubules*, which begin the passage for urine. The collecting tubules converge to form a series of conical masses, the renal *pyramids*, which number from 8 to 18.

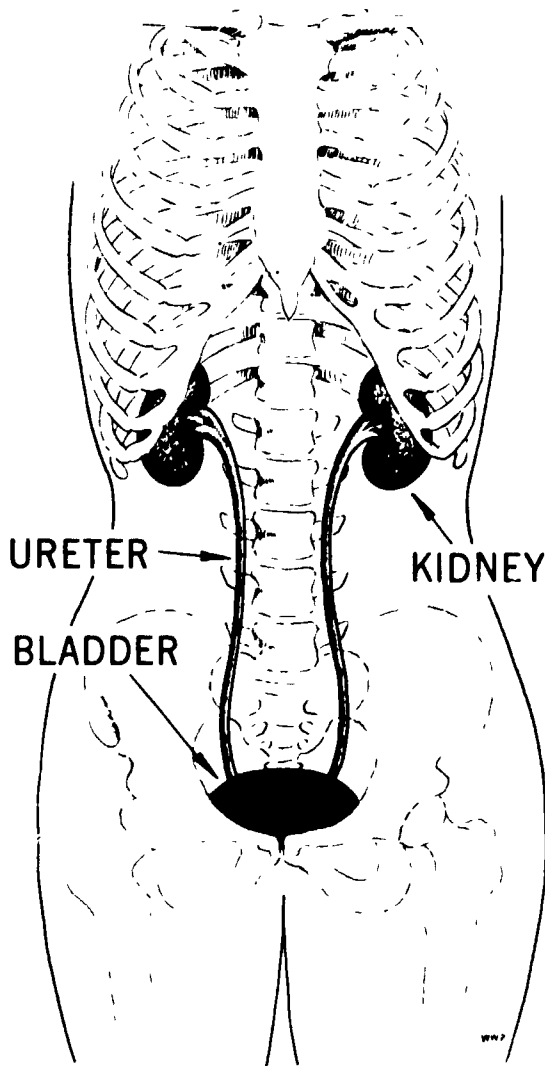


Figure 2-1 The kidneys, ureters, and bladder

The renal *sinus* is an expanded extension of the hilum. It forms the central cavity of the kidney and houses the minor calyces, major calyces, and the renal pelvis.

The *minor calyces* are a group of small, cup-shaped tubes numbering from 4 to 13. They are situated along the outer curvature of the sinus and are in close contact with the apices of the pyramids. (NOTE: The minor calyces actually surround one or more of the papillae extending through the surface of the apices.) The minor calyces, after receiving the urine from the apices of the pyramids, extend into the central portion of the renal sinus for a short distance and then join to form the *major calyces*. These major structures are two or three short, wide tubes which extend further into the renal sinus and then join to form the funnel-shaped *renal pelvis*. This structure leaves the kidney through the hilum, curves downward, and joins with the ureter. The minor calyces, major calyces, and renal pelvis are continuous with each other.

### Exercises (618):

Indicate which of the following statements are true and which are false. If you indicate false, explain your answer

- \_\_\_ 1. The kidneys are located in the retroperitoneal space
- \_\_\_ 2. The kidneys are approximately 11 cm long, 5 to 7 cm wide, and 2.5 to 5 cm thick
- \_\_\_ 3. The left kidney is located more superiorly than the right.
- \_\_\_ 4. The tops of the kidneys are approximately level with the 12th thoracic vertebra.
- \_\_\_ 5. Portions of the stomach, the small bowel, and the large bowel overlie the kidneys.
- \_\_\_ 6. The adrenal glands are located on the inferior surface of each kidney.
- \_\_\_ 7. The 11th and 12th ribs overlie the kidneys in all individuals

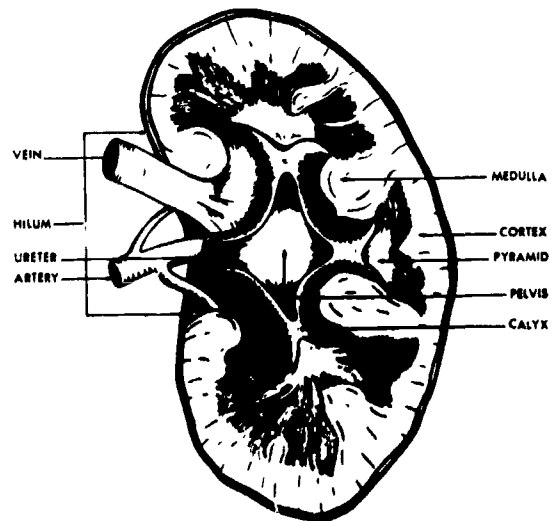


Figure 2-2 Structures of a kidney

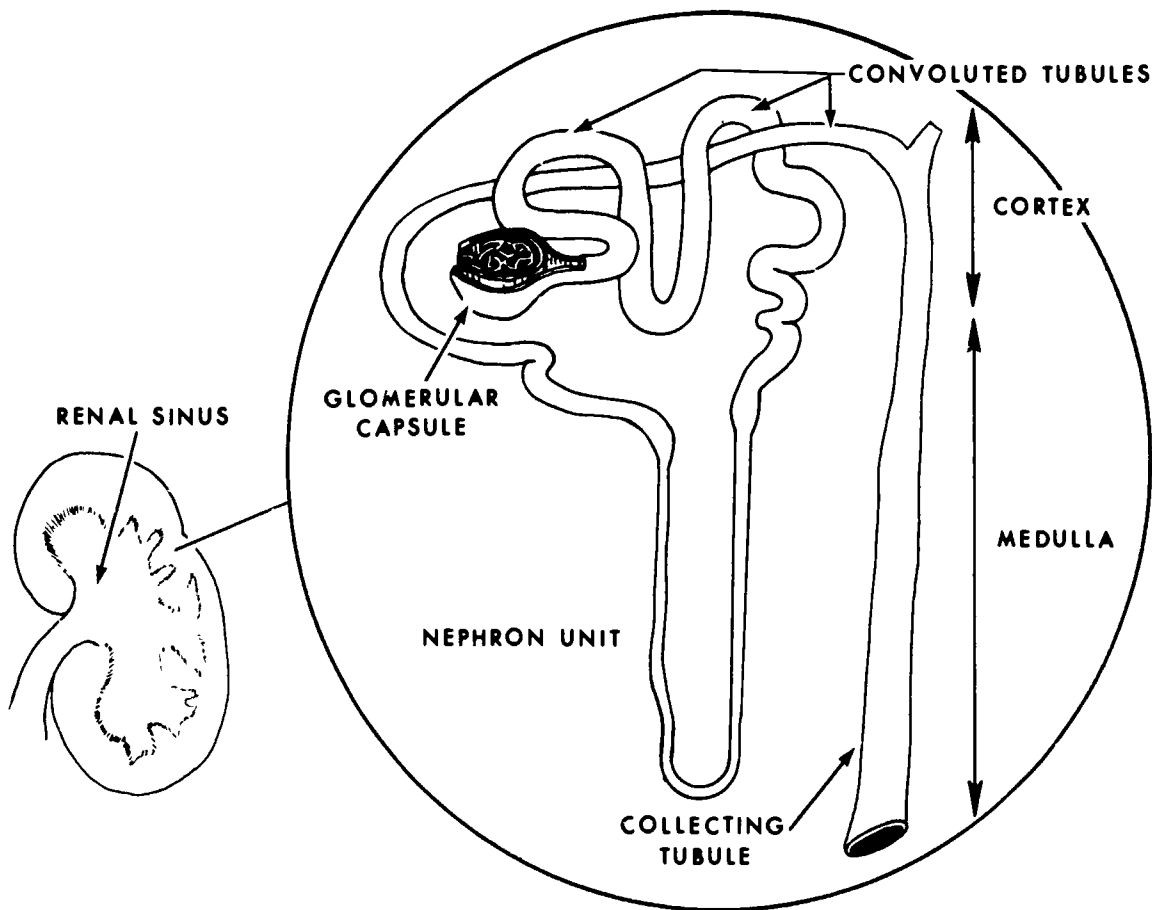


Figure 2-3 Renal sinus and nephron unit

- \_\_\_\_\_ 8. The medial portion of the kidney, through which various structures enter and exit the kidneys, is the renal pelvis
- \_\_\_\_\_ 9. The perirenal-fat pad separates the adrenal glands from the kidneys
- \_\_\_\_\_ 10. The outer layer of the kidney containing nephron units is the cortex.
- \_\_\_\_\_ 11. The collecting tubules converge to form the renal pyramids.
- \_\_\_\_\_ 12. The minor calyces receive urine from the apices of the pyramids.
- \_\_\_\_\_ 13. Immediately after leaving the minor calyces, urine flows into the renal pelvis.
- \_\_\_\_\_ 14. The renal pelvis conveys urine outside the kidney proper.
- 619. Specify significant features of the ureters.**

**The Ureters.** The ureters are two hollow, musculomembranous tubes which join with the renal pelvis and extend to the posteroinferior surface of the urinary bladder. These structures are 28 to 34 cm long, are of variable diameter, and are comprised of abdominal and pelvic portions.

Juncture of the distal renal pelves and the proximal ureters occurs in the region between and just anterior to the transverse processes of the first and second lumbar vertebrae. The *abdominal* portions pass downward, over the medial surfaces of the psoas major muscles, and behind the peritoneum, to the pelvic brim, and cross the wings of the sacrum just medial to the sacroiliac joints.

The *pelvic* portions of the ureters proper follow the general curvature of the pelvis. They curve forward and medially at about the level of the ischial spines, pass through the peritoneum, and join the urinary bladder in the region of the trigone. Figure 2-1 illustrates the ureters proper in relation to the kidneys, vertebral column, pelvis, and urinary bladder.

Each ureter is comprised of three layers or coats: (1) a fibrous coat, (2) a muscular middle coat, and (3) an inner mucous coat. The fibrous layer is continuous with the renal membrane, which forms the floor of the renal sinus. The muscular middle coat is formed by three layers of muscle tissue. The outer muscle layer is made up of longitudinal fibers, the middle layer of circular fibers, and the inner layers of fibers that are generally longitudinal in direction. This muscular structure is similar to that found in the alimentary tract and is responsible for ureteral peristalsis. The mucosal inner coat extends from the renal papillae, which it surrounds, to the mucous membrane lining of the urinary bladder with which it is continuous.

#### Exercises (619):

1. Each ureter is about how many centimeters long?
2. What are the names of the two portions of the ureters?
3. Where do the renal pelves join with the ureters?
4. What ureteral portion passes through the peritoneum?
5. Which ureteral layer is responsible for ureteral peristalsis?
6. What type(s) and arrangements of tissue comprise the layer or coat suggested in exercise number 5 above?

#### 620. Cite structural and functional details, including locations, of the bladder and urethra.

**The Bladder.** The "storage area" of the urinary system is formed by the urinary bladder. This structure is a hollow, musculomembranous sac located in the lower anterior portion of the true pelvis.

Naturally, the precise location of the bladder will vary in accordance with the amount of fluid it contains. Generally speaking, the inferior portion is situated behind the symphysis pubis, while the entire bladder is anterior to the rectum and underneath the peritoneum.

The urinary bladder wall is comprised of an external serous coat, three layers of muscle tissue, a submucous coat, and a mucous membrane lining. The outer layer of muscle tissue is comprised of longitudinal fibers, the middle layer of circular fibers, and the inner layer of still more longitudinal fibers. This muscular arrangement allows for free expansion of the bladder during the filling process. As the bladder fills, the superior surface rises into the abdominal cavity rounding off the posterior and lateral borders. As a rule, the bladder is considered moderately full when it contains 500 cc of urine. (However, in certain cases 2,000 cc and more have been removed from the bladder. This experience illustrates the expansive abilities of the urinary bladder.) The mucosa consists of loose folds (similar to the rugal folds of the stomach), which allow this membrane to stretch as the muscular walls expand. The urinary bladder and its component structures are depicted in figure 2-4.

The trigone is a triangular area in the posteroinferior bladder wall. Its structure is basically the same as that described for the remainder of the bladder, but the musculature is not as expansive as is that of other segments of the bladder wall, and the mucosal lining is always smooth. The distal ends of the ureters pierce the wall of the trigone in the upper outer regions, pass through the tissue on an inferomedial course for about 2 cm, and terminate in the *ureteral orifices*. When the bladder is empty, these openings are about 2.5 cm apart, but when the sac is full, they are about 5 cm apart. This fact illustrates the degree and direction of trigonal expansion. As the trigone stretches with the remainder of the bladder during filling, its musculature tightens on the distal ureteral ends, thus clamping them off and preventing regurgitation, or reflux, or urine into the ureters. The trigone also houses the internal urethral orifice. This crescent-shaped aperture is located in the apex of the trigone, which forms the most inferior portion of the bladder. The circular muscle fibers of the floor of the bladder are concentrated around the internal urethral orifice, thus forming the *internal urinary sphincter*. This layer of concentrically arranged muscle fibers contracts to close the urethral orifice, and on relaxation opens it.

**The Urethra.** The urethra is a hollow, narrow tube which extends from the bladder to the external surface of the body. The male urethra is about 20 cm (8 inches) long and is comprised of *prostatic*, *membranous*, and *cavernous portions*. The prostatic urethra is the widest and most dilatable portion of the tube. It extends downward for about 3 cm and passes through the prostate gland. This gland lies

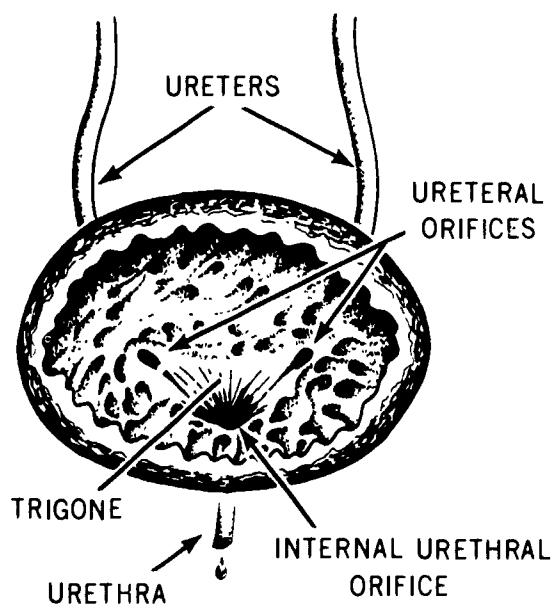


Figure 2-4 The urinary bladder

directly below and close to the external surface of the bladder floor. The membranous portion of the urethra is the shortest and least dilatable segment of the tube. It extends anteroinferiorly from the under surface of the prostate to the bulb of the urethra, a distance of about 1.25 cm. The cavernous portion of the urethra, usually about 15 cm in length, extends from its juncture with the membranous segment, through the penis to the external urethral orifice. It first passes upward to the front of the symphysis pubis and then downward through the penis.

The female urethra is much shorter and straighter than that of the male. It extends from the internal urethral orifice downward and forward for a distance of about 4 cm (1 1/2 inches). As a rule, the female urethra is of uniform diameter and, since it is imbedded in the anterior vaginal wall, is relatively immovable.

#### Exercises (620):

1. What relationship exists between the location of the bladder and the symphysis pubis and rectum?
2. What four components or coats comprise the wall of the bladder?
3. How does the bladder accommodate increases in volume?

4. What is the trigone?
5. What is the difference between the musculature of the trigone and other bladder walls?
6. Where do the ureters enter the bladder?
7. Explain what occurs and when to prevent reflux of urine into the ureters.
8. What function does the internal urinary sphincter serve?
9. Name the three portions of the male urethra.
10. What gland lies directly below the male bladder floor?
11. What is the longest portion of the male urethra called?
12. About how long is the female urethra?

#### 2-2. Reactions to Contrast Media

As you know, there is danger of a reaction to the contrast media injected into your patient's bloodstream. The reaction may be mild with little or no consequences, or it may be severe and result in death. We include our discussion of reactions in this portion of the CDC because in most radiology departments, the intravenous pyelogram (IVP) is the examination most commonly performed in which reaction is possible. Keep in mind, however, that a reaction may occur anytime contrast media is injected into the patient.

Our study of reactions begins with a look at the signs and symptoms of different types of reactions. After that, we will discuss the emergency tray and some specific emergency items.



**621. State important signs, symptoms, or other factors associated with the detection and evaluation of reactions to injections of contrast media.**

**Detection and Evaluation of Reactions.** The signs and symptoms that may be exhibited by the patient during or after the injection of a contrast medium vary, depending upon the type and severity of the reaction. Your primary concern is to be able to recognize a possible serious reaction and advise a physician immediately so treatment can begin.

**Technique reactions.** Local signs and symptoms—that is, those located at or near the injection site—are sometimes referred to as *technique* reactions. For example, pain at the injection site is sometimes caused by infiltration of the contrast material into the tissues adjacent to the blood vessel. The infiltration, or extravasation as it is sometimes called, is quite painful and can last for 10 to 15 minutes until the contrast material is absorbed and removed from the area. Infiltration of blood can also cause pain at the site, but usually it is not as painful as the infiltration of the contrast material. Either type of infiltration can cause a noticeable elevation of the skin or "hematoma." Burning and numbness at the site of injection or along the upper arm are also considered technique reactions and disappear within a few minutes. Technique reactions, such as these described, usually are not serious in nature.

**Hemodynamic reactions.** A reaction is said to be *hemodynamic* if it is precipitated by the movement involved in circulation of the blood. Some of the hemodynamic reactions may be temporary in nature, subsiding after a few seconds or a few minutes, and others may be severe enough to endanger the patient's life. The important point to remember is that the mild reactions may be initial manifestations of more severe reactions. Therefore, just because you have seen these mild reactions subside in the past, do not assume that they are not important. Two mild reactions are a feeling of warmth and flushing (redness of the face and neck). These *usually* disappear quickly. More severe cardiovascular hemodynamic reactions include an increase in blood pressure (hypertension), a drop in blood pressure (hypotension), weak rapid pulse, irregular pulse, or in case of cardiac arrest, no pulse at all. Others are cyanosis and unconsciousness.

**Anaphylactic reactions.** Anaphylactic reactions result when the patient is allergic to the contrast medium. As with hemodynamic reactions, they can be mild or severe. Also, mild reactions are initial manifestations of the more severe reactions. Signs and symptoms of anaphylactic reactions include urticaria (hives), which are elevated patches on the skin that are redder or paler than the surrounding skin. Generalized itching also may occur, which may or may not be accomplished urticaria. Tightness in the chest, sneezing, and wheezing (audible breathing) also may be present.

Breathing difficulties or irregularities may be present—such as labored breathing and high or low respiratory rates. Also, breathing may cease altogether. Watery or redened eyes are two other signs of anaphylactic reactions.

**Other reactions.** Nausea with or without vomiting may occur after injection of the contrast medium. Anxiety, headache, dizziness, and trembling may also be present.

**Evaluation of reactions.** As mentioned before, a radiologist initiates treatment if it becomes necessary during a reaction. However, the radiologist may not be in the room when a reaction occurs. In this case, you must decide when (or if) the radiologist should be notified. Remember, as mentioned before, some of the reactions are of brief duration. Unfortunately, there are no concrete answers to these questions. We can say that if such signs and symptoms as urticaria, hypotension, hypertension, difficulty in breathing, abnormal pulse, cyanosis, or equally severe reactions occur, you should notify the radiologist immediately. But whether you should notify the radiologist the instant your patient sneezes or has a mild technique reaction is something you should work out with him or her. The patient's radiologist may want to be called if the patient exhibits *any* sign or symptom of a reaction. In any event, an initial mild sign or symptom should alert you to the fact that a more severe reaction may be imminent, and you should observe the patient more closely for following events

**Exercises (621):**

1. What is your primary concern associated with reactions to contrast media?
2. What type of reaction is caused by infiltration of contrast material or blood into the surrounding tissues?
3. Name four signs or symptoms that are shown by the patient during a reaction of the type indicated by exercise number 2 above.
4. (a) Is a hemodynamic reaction always serious in nature? (b) Is it always mild in nature?
5. Warmth and flushing are two mild hemodynamic reactions. Give their possible relationship to more severe reactions
6. List seven serious hemodynamic reactions.
7. List ten anaphylactic reactions.

8. Briefly discuss the question of whether, and when, you should notify your radiologist (or other physician) of the patient's condition if there is a reaction to the contrast medium.

### 622. Give the important guidelines for establishing and maintaining an emergency tray.

**Emergency Equipment.** Every radiology department using injectable contrast media must have on hand the appropriate equipment to treat a severe reaction. Usually called an *emergency tray*, the specific items of equipment are decided by your radiologist, and we discuss some of them later; however, there are significant features of the tray itself that we should cover.

**The emergency tray.** First of all the equipment should be assembled on a single cart with rollers. The reason for having everything together is so that it is readily available. Remember, you cannot afford to waste time looking for a drug or laryngoscope when the need arises. (NOTE: If your radiologist elects to use some of the larger items, such as a large oxygen cylinder or a portable suction apparatus (also on rollers), obviously you cannot assemble these items on a single cart. The important issue is that you should assemble everything *possible* together.) The cart should have rollers so that it can be easily moved from one room to another, depending upon where the injection takes place.

The equipment should be placed neatly and orderly on the cart so that each item can be located quickly. One good way to do this is to secure a piece of some type of foam rubber, at least 2 inches thick, on the top shelf of the cart. Then cut out depressions in the material to correspond with the sizes of your small items, such as syringes, needles, drugs, etc. Thus, these small items remain in the same location on the cart, permitting quicker location when needed. Also, you can quickly spot a missing item during your *daily* inventory. Large items of equipment, such as the AMBU and intravenous fluids, can be placed on the bottom shelf of the cart.

As previously suggested, you should inventory emergency equipment daily to ensure that the necessary items are available. Conduct the inventory preferably in the morning before any examinations are started. At the time of inventory, check the expiration date on such items as locally assembled packs, drugs, etc. Also, you should test such items as the laryngoscope light (batteries don't last forever), the suction apparatus (plug it in and check for suction at the end of the hose), and the amount of oxygen remaining in the bottle.

You should attach to the cart a list of the items available. This list will enable someone unfamiliar with the contents to quickly determine if a particular item is available. The list can also serve as a checklist for inventory or inspection procedures.

One final word about the emergency cart—make sure everyone involved knows (1) what items are available and

- (2) where they are located. Remember, *speed* in locating the proper item is essential to a severe reaction.

### Exercises (622):

1. Why should your emergency items be assembled together in one specific location?
2. Why should your emergency items be assembled on a cart with rollers?
3. Why should specific items be arranged neatly and orderly on your emergency tray?
4. How often should your emergency items be inventoried?
5. In addition to checking on the availability of items, what other checks should the inventory include?
6. Why is it important that all personnel be familiar with the specific emergency items available and their precise location?

### 623. State the purpose and uses of the AMBU and laryngoscope.

**Specific equipment.** As previously mentioned, your radiologist decides what items of equipment are included in your emergency setup. However, some items are typically required in most departments.

a. The AMBU resuscitator, shown in figure 2-5, is commonly included in an emergency tray. The resuscitator is available in both pediatric and adult sizes. It is used to provide air or oxygen to patients if spontaneous breathing stops or if breathing is difficult. The steps for using the AMBU are as follows:

- (1) Tilt the patient's head back and lift the jaw forward.
- (2) Hold the mask firmly against the face with your thumb and index finger, keeping the chin and head back with your other three fingers.
- (3) Inflate the lungs by squeezing the bag with your other hand. Watch the chest rise.



Figure 2-5 Pediatric and adult AMBU resuscitators

(4) Release the bag and let the patient exhale. The bag will automatically fill for the next inflation. Repeat every 3 seconds—1 second for inhalation and 2 seconds for exhalation

NOTE: You should not attempt to use equipment, such as the AMBU, until you have received sufficient on-the-job training and then only as part of a preconceived plan with your radiologist.

The patient can receive oxygen through the AMBU as well as room air. Simply connect an oxygen hose to the input nipple located at the end of the bag. Obviously, you must ensure beforehand that you have an oxygen hose that will fit the nipple. The AMBU suction pump, shown in figure 2-6, is supplied with the resuscitator. It is used to remove blood, mucus, or other similar material from the air passage. Operation of the pump itself is relatively simple. You will need a catheter (not supplied with the pump) to attach to the adapter end of the hose that leads to the collection bottle. *You* do not insert the catheter into the patient, but you can operate the pump simply by depressing the bellows one-third to one-half the way down with your foot. Maintain a constant rhythm with your foot.

*b.* Sometimes during a severe reaction the patient's larynx closes, and the patient cannot breathe. In this case, an anesthetist or physician must insert an endotracheal tube through the mouth into the trachea. The endotracheal tube is inserted with the use of a laryngoscope. The laryngoscope is a device consisting of a detachable blade mounted on a battery-contained handle. Also included is a small bulb which permits the physician to see the laryngeal area. As a rule, once the endotracheal tube is inserted, resuscitation is performed with the AMBU. The mouthpiece of the AMBU slips off so that the opening can be fitted to an adapter that connects the AMBU to the endotracheal tube. Be sure to have such an adapter available, along with various sizes of laryngoscope blades and endotracheal tubes.

### Exercises (623):

1. What is the purpose of an AMBU?
2. Under what conditions should you use an AMBU?
3. Explain the procedures for using an AMBU.
4. How is oxygen administered through an AMBU?
5. What item of equipment (not supplied) is needed to use the AMBU suction pump?
6. How should the bellows of the AMBU suction pump be operated?
7. Give one purpose or use of a laryngoscope.



Figure 2-6 AMBU foot-operated suction pump.

- 8 Why should your laryngoscope kit contain an adapter?
- 9 Should your laryngoscope kit have more than one blade and tube?

### 2-3. Contrast Studies of the Urinary System

We now turn our attention to radiographic examinations of the urinary system. We include the following contrast studies: intravenous pyelography, retrograde pyelography, nephrotomography, cystography, and cystourethrography.

#### 624. Specify significant procedures associated with intravenous pyelography.

**Intravenous Pyelography.** Intravenous pyelography (IVP), also called *excretory urography*, involves the intravenous injection and subsequent renal processing of a suitable contrast medium, followed by abdominal radiography. This procedure demonstrates the calyces, renal pelves, ureters, and, to some extent, the urinary bladder. Even though an IVP visualizes the anatomic configuration of these structures, it also serves as a renal-function test. Perhaps the key to the success of this procedure deals with the proper preparation of the patient.

**Patient preparation for an IVP.** As with other contrast medium examinations, excretory urography calls for a certain amount of patient preparation. Although these preparatory instructions vary with radiologists, they generally direct IVP patients to dehydrate themselves for a specified period of time prior to the exam, to fast or be on a restricted diet 8 to 12 hours just prior to the exam, and to cleanse the bowel in a specified manner and at a particular time.

**Dehydration.** Dehydration reduces the amount of fluid in the kidneys at the time of injection. This will increase the concentration level of the medium excreted by the kidneys and, thus, enhance the radiopacity produced in the calyces, renal pelves, ureters, and bladder. Dehydration is done by limiting the patient's fluid intake for a particular period of time—the longer the period of total restriction, the greater the degree of dehydration. Usually, though, patients are allowed a specified number of ounces of clear fluids the day before the exam, but they must be NPO the last 8 to 12 hours just prior to the examination.

**Fasting.** Fasting reduces the amount of feces and gas produced in the bowel. It also serves to reduce the possibility of vomitus aspiration should a medium reaction occur. If the stomach is empty at the time of reaction, the quantity of vomitus is dramatically reduced. Thus, the possibility of aspiration is greatly reduced. Consequently, the patient is usually asked to eat only a light supper at about 6 p.m. the evening before the exam and nothing thereafter.

**Cleansing the bowel.** Cleansing the bowel is quite necessary since the colon covers the urinary system on a

radiograph. If the colon is full of feces and gas, the calyces, renal pelves, and ureters will be obscured. If the sigmoid colon (which lies behind the bladder) is filled, the urinary bladder will be obscured. Accurate radiologic diagnosis of uropathy is difficult, if not impossible, under these circumstances. Therefore, certain steps need to be taken to ensure that the bowel is free from gas and feces prior to contrast medium injection.

Some radiologists ask that the patient take 2 ounces of castor oil the evening prior to the examination and a cleansing enema the next morning; others feel that castor oil is too harsh and that enemas introduce air into the colon, thus defeating their purpose. These radiologists instead prefer a mild, commercially prepared laxative, such as Ducolax, in the evening and a suppository comprised of similar chemicals in the morning. However, if some gas is still present and the exam must be conducted, the problem of obscuring gas shadows in a majority of patients can be resolved by placing the patient in a prone position. By exerting pressure on the abdomen, the prone position shifts the gas laterally away from the renal structures.

Regardless of the means used, bowel cleansing is an absolute prerequisite for an IVP. If it is not done or is incomplete, the exam may well be cancelled and rescheduled. More IVPs are cancelled because of incomplete bowel evacuation than for any other reason.

#### Exercises (624):

- 1 Describe an IVP study by defining it and listing the anatomic structures that are demonstrated.
2. Why is an IVP considered both an anatomical and functional study?
3. What are the three specific areas of patient instructions that prepare a patient for an IVP?
4. What effect does dehydration have on the kidneys and why should a patient undergo this preparation?
5. Why is fasting included in the patient preparation for an IVP?
6. Why is it important that the sigmoid colon be free of feces and gas during an IVP?

7. Why don't some radiologists approve of a cleansing enema just prior to the IVP?
8. If a patient has abdominal gas and cannot be rescheduled, how can this patient be positioned to remedy this situation and why?
9. What reason causes more cancellations of scheduled IVPs than any other reason?

**625. State the purposes and procedures for performing the IVP scout film.**

*Scout film.* A scout film of the abdomen is performed before the contrast medium is injected for an IVP. Patients should empty their bladder before you perform the scout film. This reduces dilution of the contrast material in the bladder, allowing better demonstration.

The scout film serves several purposes. First of all, it allows the radiologist to determine whether or not the patient is adequately "cleaned out." If the patient has considerable gas and fecal material in the bowel, the examination may not be diagnostic because the contrast medium in the urinary tract may be obscured. Secondly, it allows the radiologist to see a urinary tract stone or other abnormality that can be obscured by the contrast medium. The scout film also enables you to check your exposure and positioning and make the necessary adjustments on the subsequent radiographs. Centering the film is especially important during an IVP because you must include the superior portion of the symphysis pubis and the upper margins of the kidneys. This is usually not a problem with an average-sized individual. Simply center the 14- x 17-inch cassette to the iliac crest. However, on a large patient you may not be able to include the necessary anatomy on a single radiograph. This is where you can use the scout film to advantage. It may be necessary for you to center the 14 x 17 3 or 4 inches higher than normal and use a 10- x 12-inch cassette centered 2 inches above the symphysis pubis to include the lower pelvis. Since this procedure obviously increases the patient's radiation dose considerably, be sure to check it out with your radiologist.

When performing the scout film and all other AP projections of the kidneys during an IVP, some radiologists prefer that you flex the patient's knees to place the lower back in contact with the table as you would for an AP lumbar spine. Also, the radiologist may want you to elevate the head and shoulders slightly on one or two pillows. By doing so, you place the long axes of the kidneys as near as possible parallel with the plane of the film and reduce their distortion on the radiograph.

**Exercises (625):**

- 1 Why should the bladder be emptied before performing an IVP scout film?
- 2 Briefly explain the purposes of the IVP scout film.
- 3 What two upper and lower anatomical areas must you include on the IVP scout film?
- 4 How can you minimize distortion of the kidneys on the IVP scout film?

**626. State why and how compression, obliques, and postvoiding radiographs are done in conjunction with an IVP.**

*Other projections and procedures.* Once the contrast medium is injected, various projections and procedures can be performed. Usually radiographs are made at timed intervals, beginning 5 minutes after the completion of the injection. Posterior obliques of the kidneys are sometimes performed 10 or 15 minutes from injection, in which case you should use a 10- x 12-inch cassette crosswise. For the obliques, rotate the patient 25° to 30° and center the lower margin of the film 2 to 4 inches above the iliac crest. Obliques are also taken of the entire system, which of course indicates a 14- x 17-inch film instead of a 10 x 12. A postvoiding erect film is usually taken to check for gravitational emptying of the renal calyces and pelves and to evaluate the mobility of the kidneys. Also, a postvoiding AP projection of the bladder area is sometimes performed on males to reveal enlargement of the prostate gland and to check bladder retention of both sexes. Before voiding, provide the patient with a container covered with gauze if a urinary stone is suspected. The urine always should be strained in this case and if, after inspecting the gauze, you find a stone, report it to your radiologist.

Some radiologists feel they can better outline the renal pelves and calyces by compressing the ureters and thus restricting the flow of contrast material into the bladder. This purpose is achieved by using compression across the upper pelvis at the level of the anterosuperior iliac spines. This is the level where the ureters cross the sacrum. Compression compresses the ureters against a prominent portion of the sacrum temporarily cutting off the flow. Compression placed above or below this level is not effective. Compression is usually applied after completion of the injection and released at a specified time after one or more radiographs are made. A radiograph can also be made

a few seconds after release of the compression to visualize the contrast-filled ureters. Compression can be applied in a number of ways, although you usually use the compression band supplied with your X-ray unit. Some radiologists like to use a blood pressure cuff underneath the compression band. After the band is tightened until it is "snug," the cuff is inflated a specified amount, usually from 90 to 110 mm of mercury. Using a device such as this is advantageous because the amount of pressure on the ureters can be repeated from one examination to another. You can also place a foam rubber pad or other positioning aid under the compression band and tighten the band to compress the ureters.

If the patient cannot tolerate the compression, and some cannot, the purpose of the compression can be partially satisfied by using the Trendelenburg position ( $10^{\circ}$  to  $20^{\circ}$ ). This position retards the flow of the contrast medium into the bladder due to the countereffects of gravity. When performing radiographs with the patient so positioned, be sure to angle the tube caudally the same degree to which the table is tilted to prevent distortion.

#### Exercises (626):

- 1 If you perform obliques of the kidneys, how many degrees should you rotate the patient?
- 2 Give two reasons for performing a postvoiding erect radiograph
3. Why should a postvoiding radiograph be made of the bladder?
- 4 What patients should be instructed to strain their urine?
- 5 What advantages are realized by using compression before performing radiographs of the bladder area?
6. Where should the compression be applied?
7. Why is it advantageous to apply compression with a blood pressure cuff?

- 8 If a blood pressure cuff is used to apply compression, to what extent should the cuff be inflated?
- 9 If the patient cannot tolerate compression, what alternate procedure may be used to achieve the desired effect?

**627. State the purpose of administering a carbonated beverage to a child receiving an IVP and the amount of beverage to be administered.**

**Pediatric Intravenous Pyelography.** One of the problems associated with an IVP on a pediatric patient 8 years of age and under is that preparation of the gastrointestinal tract is difficult or clinically contraindicated. As a result, gas and fecal shadows can overlie the kidneys and obscure the contrast medium. This problem is easily solved by giving the patient a carbonated beverage which distends the stomach with gas. Distention of the stomach displaces the bowel downward so that it no longer overlies the kidneys. Also, the excellent contrast produced between the resulting gas bubbles in the stomach and the medium-filled kidneys provides even better demonstration of the kidneys than if the patient was properly prepared in the first place. Usually, 2 ounces of beverage is given to an infant and 12 ounces to a child 8 years old, with proportionate amounts for ages in between.

#### Exercises (627):

- 1 How does the ingestion of a carbonated beverage improve visualization of the kidneys during an IVP on a child?
2. How many ounces of carbonated beverage are given to children undergoing IVPs?

**628. Cite the purpose and general procedures used during a hypertensive IVP.**

**Hypertensive Intravenous Pyelography.** A hypertensive IVP is performed to determine whether or not hypertension is caused by stenosis (narrowing) of a renal artery. If stenosis is present in a renal artery, excretion of the contrast material by the kidney of the affected artery can be delayed when compared with the opposite kidney. To evaluate the difference between the appearance and concentration of contrast material in the kidneys, the medium is injected rapidly into the vascular system, after

which radiographs are taken at 30-second to 1-minute intervals for about 5 minutes.

Following the prescribed number of films, a "urea washout" study may also be performed. The study is done by the infusion of a mixture of saline and urea, a substance which promotes the secretion of urine. Radiographs are made at 5- or 10-minute intervals to determine if the contrast material "washes out" of one kidney faster than the other.

#### Exercises (628):

1. What specific vascular abnormality may be indicated by a hypertensive IVP?
2. If the condition indicated in exercise number 1 is present how could it be suggested on a hypertensive IVP?
3. At what relative speed is the contrast medium injected for a hypertensive IVP, and at what intervals are radiographs made?
4. What is a "urea washout"?

#### 629. Indicate whether statements pertaining to the performance of retrograde pyelography and nephrotomography are correct.

**Retrograde Pyelography.** Retrograde pyelography is a technique for demonstrating the major structures of the kidney via retrograde introduction of a contrast medium. Retrograde means against the normal flow. Therefore, since the contrast medium is introduced through a catheter, a functional study is not obtained. Patient preparation for a retrograde study is similar to one for an IVP with one exception—the patient should be instructed to drink large amounts of fluid. This is done to reduce the possibility of excessive dehydration which would be caused by the contrast material. The chemical composition, amount, and concentration of the contrast material used have a diuretic effect. A diuretic is an agent that affects the secretion of urine. One of the functions of the renal system is to maintain a fluid balance for the body. The contrast material used increases the secretion of urine. In some patients this increase in secretion can cause dehydration, which could be dangerous. A retrograde pyelogram is done under sterile conditions, either in your department, or the urographic suite, or in surgery. One of your major responsibilities is preparing the contrast medium to be used. Either injectable

or noninjectable urographic media may be used. Generally, a noninjectable such as Retrografin or Cystokon is used because it contains an antibiotic to reduce the possibility of infection. Either contrast media may be used as is; however, most physicians prefer to dilute the contrast material to a certain weight by volume concentration. This is usually done to reduce irritation to the renal structures. When you are instructed to dilute the contrast material, use either sterile water or saline and mix the contents under sterile conditions. As a footnote, information pertaining to any contrast material, how it is used, mixed, contraindications, etc., is obtained from the accompanying literature. If this happens to get misplaced, the *Physicians' Desk Reference* (current edition) can be used to obtain the same information.

Intravenous and retrograde pyelography are not competitive studies; they are complimentary. Their relationship is best explained by the fact that a suspicious area seen on an IVP can be specifically studied in a retrograde pyelogram. The major advantage of a retrograde study is that optimum demonstration of the renal pelvis and calyces can be obtained by controlling the amount and concentration of the contrast material.

**Nephrotomography.** IVPs and retrograde pyelograms are studies of the hollow, internal structures of the urinary system. When it is necessary to examine the soft tissue structure of the kidneys, nephrotomography is used. Patient preparation is the same as for a retrograde study and for the same reason. The contrast material is intravenously introduced; therefore, an injectable medium is used. If you do not use commercially prepared drip-infusion media, you will have to mix your own. Generally, the medium is mixed to a 25- to 30-percent weight by volume concentration in normal saline. Depending on the patient's weight, 300 to 400 cc of the solution is used. The introduction of the contrast material is different from an IVP. The contrast medium IV fluid solution is drip-infused over a period of time, usually 6 to 10 minutes. The effect of the introduction of this large volume of fluid is to flood the kidneys. A condition similar to urinary stasis is produced because so much filtrate is processed by the glomeruli that the total volume is greater than the volume it can handle. Consequently, the contrast material backflows into the collecting tubules and dilates them. Some excretory function does occur, but it is relatively slow. Since the media is in the collecting tubules, the entire kidney is opacified. This effect is called a nephrogram and can last as long as 45 minutes. A series of tomograms is normally begun as soon as the contrast material has been introduced. This study provides a detailed study of both kidneys, particularly the soft tissue enabling differentiation of tumors or cysts from normal renal tissue.

#### Exercises (629):

Indicate whether the following statements are true or false. If you indicate false, explain your answer.

- \_\_\_\_\_ 1. The patient preparation for retrograde pyelography is the same as for an A.P.
- \_\_\_\_\_ 2. Retrograde pyelography is a functional study of the urinary system.
- \_\_\_\_\_ 3. Aseptic or sterile technique is used for retrograde pyelography.
- \_\_\_\_\_ 4. A diuretic is an agent that affects the secretion of urine.
- \_\_\_\_\_ 5. In nephrotomography, tomograms are used to demonstrate the ureters.
- \_\_\_\_\_ 6. The effect of the drip infusion is to flood the kidneys.
- \_\_\_\_\_ 7. Patient preparation for nephrotomography is the same as for a retrograde pyelogram.
- \_\_\_\_\_ 8. 30 to 60 cc of contrast material is used for a nephrotomogram.

**630. Indicate whether statements pertaining to the performance of a cystogram and cystourethrogram are correct.**

**Cystography and Cystourethrography.** Cystograms and cystourethrograms are made by the retrograde introduction of a negative or positive contrast medium into the bladder. (An incidental cystogram is obtained when an intravenous pyelogram is performed, but the amount and concentration of the contrast material is insufficient for a complete study.) The positive contrast medium used is either a diluted, injectable urographic medium or a noninjectable medium made specifically for these studies. Oxygen, carbon dioxide, or air is used for the negative medium during a cystogram.

**General considerations.** The exact procedures for performing a cystogram or cystourethrogram vary. Most radiologists, however, monitor the filling phase to ensure that the bladder is sufficiently filled but not overfilled. Some radiologists perform all films during fluoroscopy with

spot films, cine, etc., while others film only the urethra in that manner and include "overhead" radiographs for the bladder. In either case, voiding films of the urethra are almost always performed under fluoroscopy.

**Projections.** Usually, you are required to perform several projections of the bladder during a cystogram. In all cases, center the film to the level of the soft tissue depression immediately above the most prominent point of the greater trochanter.

*a.* When performing the AP projection, extend the patient's legs to arch the lumbosacral spine. In this position the lumbosacral spine is arched and the pubic bones are tilted downward, which helps to project the symphysis pubis caudally and away from superimposition over the neck of the bladder. Also, for the same reason, angle the C.R. 5° caudally. If there is a loss of the normal lumbar lordosis when the patient's legs are extended, angle the C.R. 15° to 20° caudally. An additional AP projection is sometimes made to examine the distal ureters in case of reflux. Tilt the table so that the patient is in the Trendelenburg position—15° to 20°—and use a vertical C.R. In this position, the filled bladder moves superiorly and usually permits an unobstructed view of the distal ureters.

*b.* For the oblique projections, rotate the patient 40° to 60°. These projections are taken to provide oblique views of the bladder proper and also to reveal reflux of the contrast medium into the distal ureters.

*c.* A PA projection of the bladder is sometimes made to project the prostate gland above the symphysis pubis. Angle the C.R. 20° to 25° toward the head. It should enter the patient about 1 inch distal to the tip of the coccyx and exit slightly above the symphysis pubis.

*d.* Lateral projections of the bladder are taken to demonstrate the anterior and posterior bladder walls.

*e.* The Chassard-Lapine projection described in Chapter 1 of this volume is also occasionally used to demonstrate the posterior bladder wall and the distal ureters in case of reflux.

**Chain Cystourethrography.** A chain cystourethrogram is sometimes performed on females to evaluate the anatomical relationships between the bladder, urethrovesical junction, urethra, and urethral orifice. One end of a metallic bead chain is introduced into the bladder, while the other end remains outside taped to the patient's thigh. The bladder is also filled with a positive contrast medium. Usually, you will be required to make two radiographs—an AP and a lateral—while the patient is performing Valsalva's maneuver and the same projections repeated without the maneuver. Most commonly, the radiographs are taken with the patient erect.

#### **Exercises (630):**

Indicate whether the following statements pertaining to the performance of cystography and chain cystourethrography are true or false. If you indicate false, explain your answer.



- \_\_\_\_\_ 1. The contrast medium may be negative or positive.
- \_\_\_\_\_ 2. Fluoroscopy is almost always used when making voiding films.
- \_\_\_\_\_ 3. Radiographs of the bladder should be centered to the level of the greater trochanter.
- \_\_\_\_\_ 4. Extension of the legs for an AP cystogram removes unwanted shadows from the area under examination.
- \_\_\_\_\_ 5. The C.R. should always be angled 15° to 20° caudally for an AP cystogram.
- \_\_\_\_\_ 6. An AP projection of the bladder with the patient in the Trendelenburg position—15° to 20°—may demonstrate the distal ureters.
- \_\_\_\_\_ 7. The C.R. for the projection in exercise number 6 above is perpendicular to the film.
- \_\_\_\_\_ 8. AP and obliques and Chassard-Lapine projections may reveal reflux into the distal ureters.
- \_\_\_\_\_ 9. If a PA prostate projection is made, the C.R. is angled 20° to 25° cephalic.
- \_\_\_\_\_ 10. Lateral and Chassard-Lapine projections demonstrate the posterior bladder wall.
- \_\_\_\_\_ 11. A chain cystourethrogram is performed to evaluate the anatomical relationships between the bladder and urethral structures.
- \_\_\_\_\_ 12. During a chain cystourethrogram, supine AP and lateral radiographs are usually made.
- \_\_\_\_\_ 13. Chain cystourethrographic projections usually are made with and without Valsalva's maneuver.

## 2-4. Anatomic and Radiographic Considerations of the Female Reproductive System

The last portion of the urogenital system we discuss is the female reproductive system. We begin with a look at the anatomy and then study hysterosalpingography.

### 631. Identify characteristics and locations of anatomical structures (organs, tissues, etc.) of the female reproductive system.

**Anatomic Considerations.** The female reproductive system consists of two groups of structures—internal and external—connected by the vaginal canal. Our discussion is mostly centered around the internal structures, including the vagina, uterus, fallopian tubes, and ovaries. Refer to figures 2-7 and 2-8 as we discuss them.

**Vagina.** The vagina is a musculomembranous tube that connects the external structures to the uterus. It extends superiorly and posteriorly to a point where it meets the inferior portion of the uterus. The vagina lies between the rectum and the urinary bladder.

**Uterus.** The pear-shaped uterus is a hollow, thick-walled structure situated in the pelvis cavity between the rectum and the urinary bladder. It consists of the cervix, which is its narrow, anterior end; the corpus or body, which comprises the major bulk of the organ; and the fundus, which is its curved superior position. The uterus is usually tipped anteriorly, with its anterior surface close to the posterior and superior aspects of the bladder. The cervix extends into the vagina and contains the external cervical os in its distal surface. The small opening communicates with the endocervical canal, which passes through the muscular cervix and joins with the uterine cavity by means of the internal cervical os. Two small orifices represent the uterine openings of the fallopian tubes. They are housed in the upper lateral aspects of the body. The fundus forms an oval roof and is situated above the level of the orifices.

**The fallopian tubes.** The fallopian tubes, also called the uterine tubes or oviducts, are hollow, musculomembranous structures which extend laterally from the uterus to the ovaries. They are about 12 cm long and lie along the leading edge of the broad ligament that supports the uterus. Their lateral ends consist of several irregular projections called fimbria, which surround the ovaries.

**The ovaries.** The ovaries are the primary reproductive organs of the female system. These almond-shaped organs are located on either side of the uterus below the fallopian tubes. They are about 4 cm long, 2 cm wide, and 8 mm thick. The ovaries are comprised of a central framework of

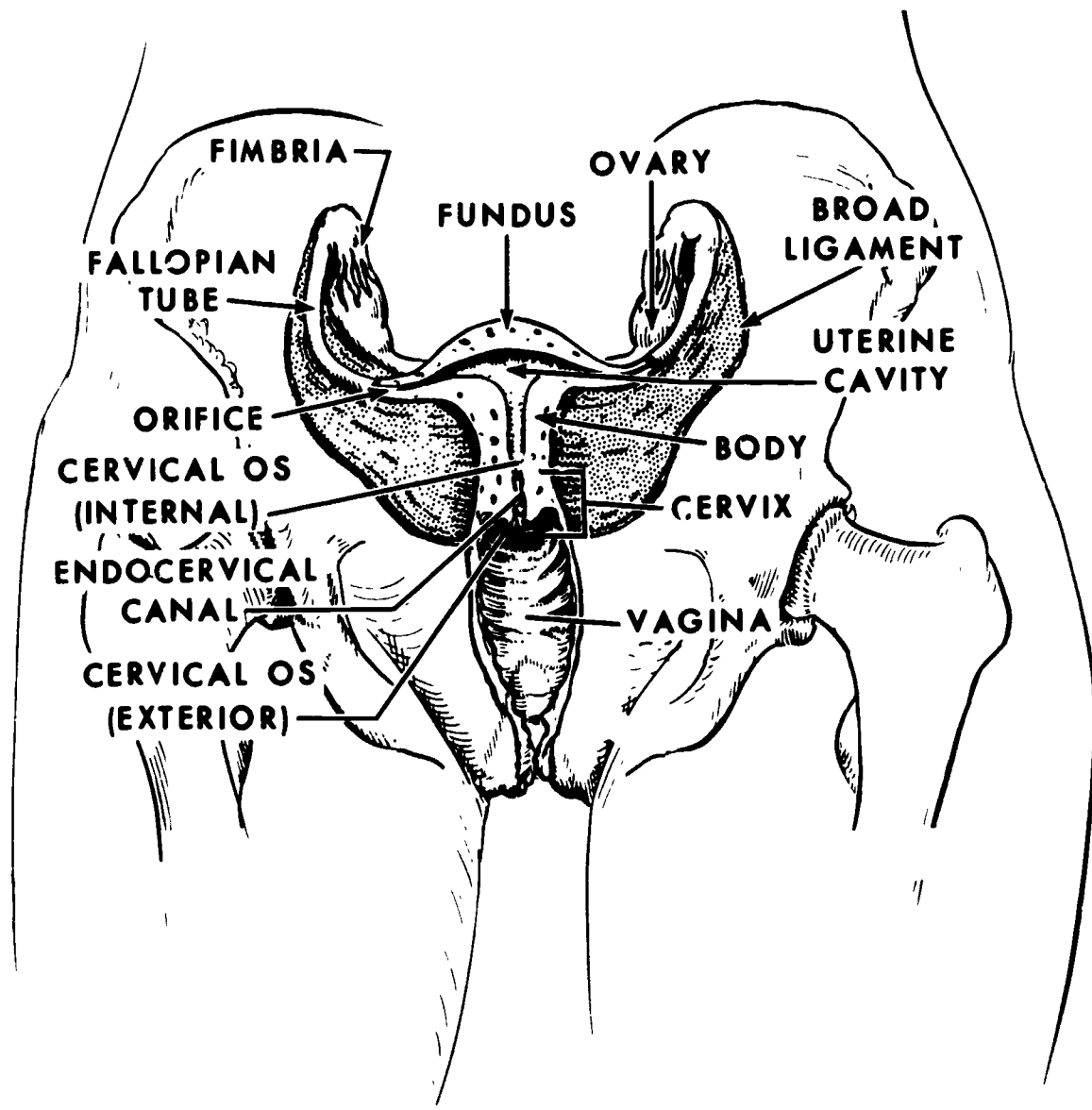


Figure 2-7 Female reproductive system

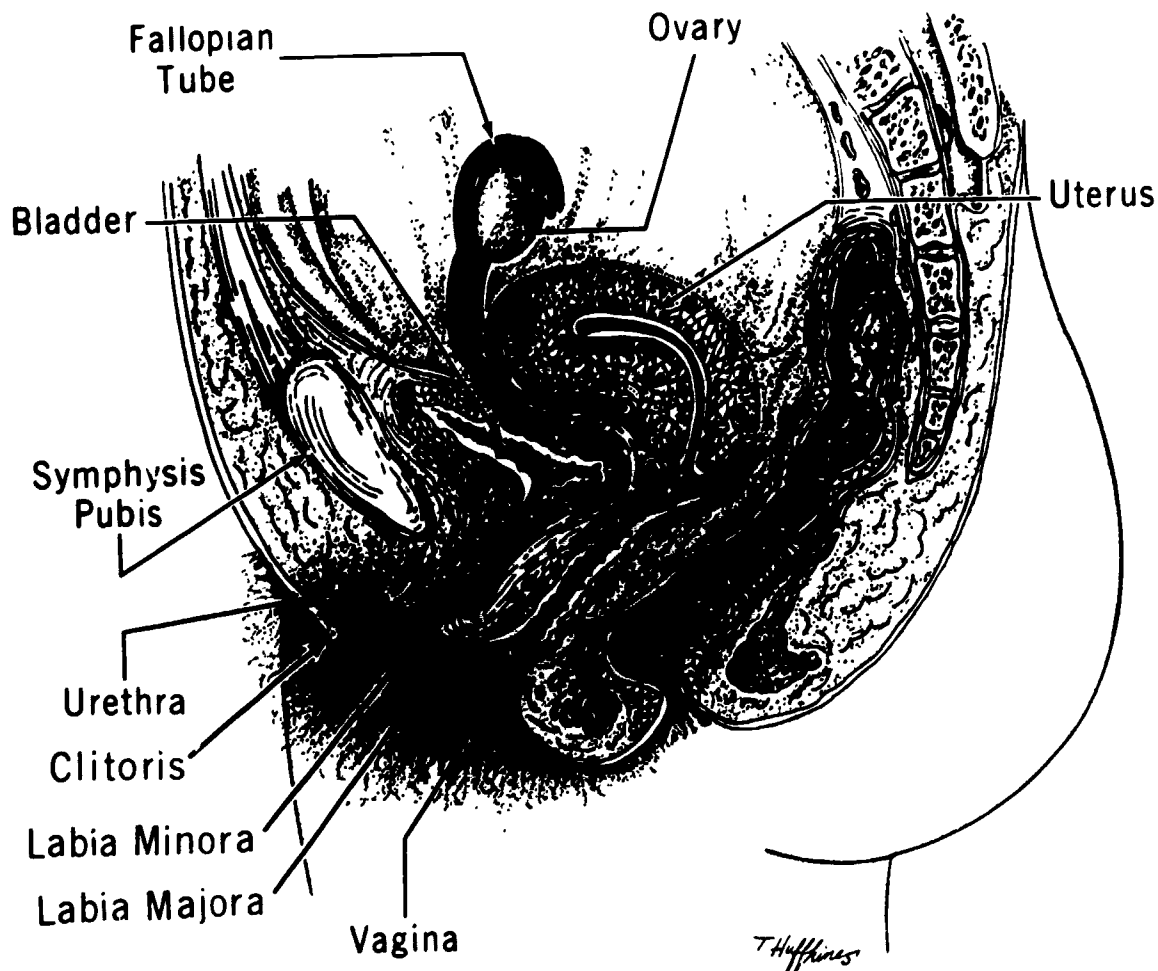


Figure 2-8 Internal structure of the femal reproductive system

vascular tissue that houses numerous ovarian follicles. These follicles serve as containers for the ova, or eggs, and appear in varying stages of maturity.

**Exercises (631):**

Select the terms which complete the following statements. Each answer set is used only once.

Fundus	Rectum
Lateral; body	Laterally; 12
Fimbria; ovaries	4; 2; 8

1. The vagina and uterus are located between the urinary bladder and \_\_\_\_\_.

2. The upper curved portion of the uterus is the \_\_\_\_\_.

3. The opening of the fallopian tubes into the uterus occurs in the upper \_\_\_\_\_ aspects of the \_\_\_\_\_.

4. The fallopian tubes extend \_\_\_\_\_ from the uterus and are about \_\_\_\_\_ cm long.

5. Several \_\_\_\_\_ make up the distal ends of the fallopian tubes and surround the \_\_\_\_\_.
6. The almond-shaped ovaries are approximately \_\_\_\_\_ cm long, \_\_\_\_\_ cm wide, and \_\_\_\_\_ mm thick.

632. State the purpose and procedures used for a hysterosalpingogram and Rubin's test.

**Radiographic Considerations.** While hysterosalpingography is performed for other reasons, it is usually done to determine whether or not the fallopian tubes are patent (open or unobstructed). Patency of the tubes is evaluated as part of a sterility "workup." If the tubes are patent, the positive contrast medium passes through them and "spills" into the peritoneal cavity and visualizes as such on the radiographs.

Aside from a hysterosalpingogram, a Rubin's test is sometimes conducted by the gynecologist to determine patency of the fallopian tubes. Usually performed in the gynecology department, carbon dioxide is introduced into the tubes under pressure, and patency is determined by the amount of resistance. If the tubes are open, the carbon dioxide, like the positive contrast medium, spills into the peritoneal cavity. Sometimes the gynecologist elects to document the presence of air in the peritoneal cavity with a radiograph. You should perform a routine erect PA chest or erect AP abdomen to include the diaphragm just as you would to demonstrate "free air" under any other circumstances. Since the carbon dioxide is absorbed rather quickly, you should perform the radiograph as soon as possible.

**Patient preparation.** A hysterosalpingogram is usually performed 7 to 8 days after completion of menstruation. The patient is instructed to void before she assumes her position on the X-ray table to reduce the possibility of a filled bladder impinging upon the fallopian tubes. The filled bladder may also present an extraneous dense shadow which might interfere with visualization of the contrast medium.

**Preparing for the examination.** If an oily contrast medium is used for the examination, it should be warmed to body temperature to make it flow more freely. One major consideration to keep in mind is that when the contrast medium is injected into the uterus and fallopian tubes, it is done so under considerable pressure, which causes the patient a lot of pain. After you perform the radiographs, the gynecologist removes the pressure, which relieves the pain. It follows that you should perform your radiographs as quickly as possible. For this reason, we recommend that two technicians perform the radiographs to save time. Precisely which technician does what during the examination is something you should decide as long as you minimize the time required to perform the radiographs.

For the same reason mentioned above, you should assemble the necessary cassettes with the identification markers (R, L, CCs, etc.) already taped on the cassette. Changing these markers between radiographs is inexcusable in this case because you are prolonging the patient's discomfort.

**Performing the radiographs.** As a rule, only AP and posterior oblique projections are performed during a hysterosalpingogram. Use 10- x 12-inch cassettes crosswise, centered to a point 2 inches superior to the symphysis pubis. A delayed AP projection (up to 24 hours) is sometimes made to check for spillage if it is not present immediately.

#### Exercises (632):

1. Why is a hysterosalpingogram usually performed?
2. Why is a Rubin's test performed?
3. If a patient arrives in the radiology department for a radiograph immediately after a Rubin's test, what is the likely reason for the film and what radiograph should you make?
4. Why should the patient void before a hysterosalpingogram?
5. Why should an oily contrast medium be warmed to body temperature before a hysterosalpingogram?
6. How can you minimize the period of time during which the contrast medium is injected (by the gynecologist) into the uterus and fallopian tubes and, therefore, also minimize the patient's discomfort?
7. Where should you center the film for the hysterosalpingographic projections?

## Contrast Studies of the Respiratory System

AS YOU KNOW, the chest is perhaps more frequently X-rayed than any other portion of the body. While most abnormalities of the chest are evaluated by standard radiography, it is necessary at times to introduce a contrast medium into the lungs to better visualize the structures via bronchography.

We begin our study of the respiratory system with a close look at the anatomy involved. After that, we examine the various methods used to introduce the contrast medium and, finally, the procedures involved in the bronchogram itself.

### 3-1. Anatomy and Physiology of the Respiratory System

In this section, we examine the anatomy and physiology of the respiratory system, from the larynx to the alveolar sacs.

#### 633. State anatomical characteristics and physiological functions of the larynx, trachea, and primary bronchi.

**Larynx.** The *larynx* (fig. 3-1), sometimes called the voice box, is located in the upper anterior portion of the neck, extending from the fourth to the sixth cervical vertebrae. It serves as a passage of air between the oropharynx and the trachea and is located immediately anterior to the laryngeal pharynx. The larynx is suspended from the hyoid bone and is made up of various structures, including the *thyroid* and *cricoid* cartilages. The *epiglottis* guards the entrance of the larynx, preventing food from entering the trachea during the act of swallowing.

**Trachea.** The trachea (fig. 3-2) is often called the windpipe. It is a rounded cartilaginous tube about 4 1/2 inches long and is located in front of the esophagus. It extends from the larynx to the level of the superior border of the fifth thoracic vertebra, where it bifurcates into the right and left main bronchi. The internal walls of the trachea are lined with mucosa. The innermost surface of this mucosa is composed of stratified, ciliated epithelium, while its deeper portion is composed of a looser meshwork of connective tissue containing the mucous glands, nerves, and blood vessels. The mucosal cilia, along with the mucous secretions filter any inhaled dust particles and move them upward to the pharynx. The external surface consists of partial, C-shaped cartilaginous rings embedded in fibrous tissue to give the trachea its rigidity. The C-shaped rings

open posteriorly, leaving gaps that are covered by strips of muscular tissue to form a flat posterior surface where the trachea overlies the esophagus.

**Primary Bronchi.** At its inferior aspect, the trachea branches into two smaller tubes—the right and the left primary bronchi—which are similar in construction to the trachea. One bronchus goes to the right lung, the other to the left.

**Right bronchus.** The right bronchus consists of six to eight cartilaginous rings that are smaller than, but otherwise identical to, those of the trachea. It enters the right lung at the level of the fifth thoracic vertebra. It is shorter, wider, and more vertical in position than the left bronchus.

**Left bronchus.** The left bronchus is smaller in diameter and longer than the right bronchus. It has from 9 to 12 cartilaginous rings and enters the left lung at about the level of the sixth thoracic vertebra. Figure 3-2 illustrates the primary bronchi.

#### Exercises (633):

Select the terms to complete the following statements. Each answer set is used only once.

Fifth  
Anterior  
Trachea  
Cricoid; thyroid  
Rings; posteriorly  
Left; left; right  
Epiglottis  
Right; left  
Cilia; secretions

1. The larynx serves as an air passage between the oropharynx and the \_\_\_\_\_.
2. Two major cartilages that make up the larynx are the \_\_\_\_\_ and the \_\_\_\_\_.

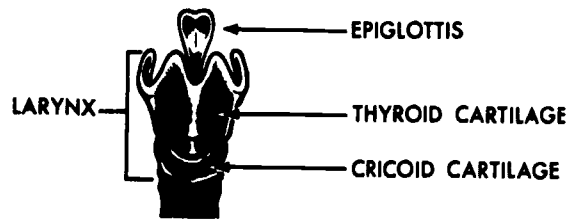


Figure 3-1 The larynx

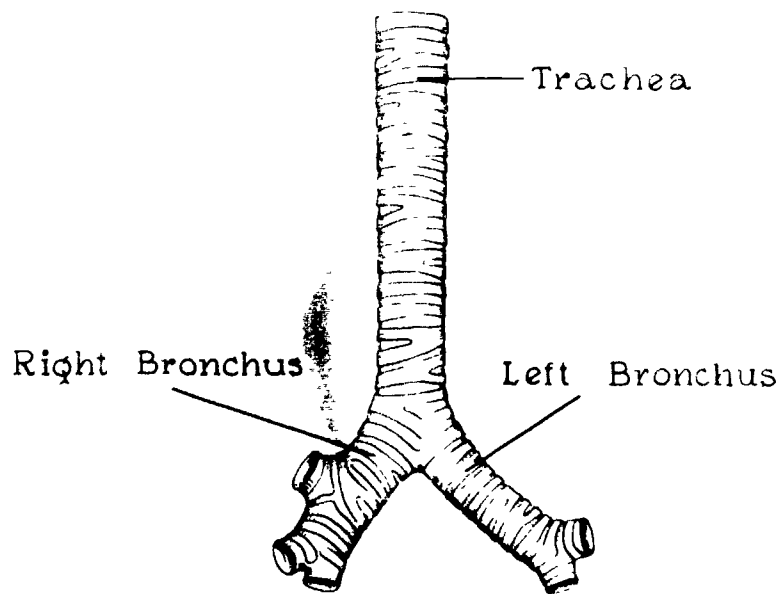


Figure 3-2 The trachea and main bronchi

- 3 The entrance to the larynx is guarded by the \_\_\_\_\_.
4. The trachea is located \_\_\_\_\_ to the esophagus.
- 5 The trachea bifurcates at the level of the \_\_\_\_\_ thoracic vertebra.
6. Inhaled dust particles are filtered in the trachea by the mucosal \_\_\_\_\_ and mucous \_\_\_\_\_.
- 7 The rigidity of the trachea is provided by C-shaped \_\_\_\_\_ which open \_\_\_\_\_.
8. The trachea divides into the \_\_\_\_\_ and \_\_\_\_\_ primary bronchi.
9. The \_\_\_\_\_ primary bronchus enters the \_\_\_\_\_ lung at a slightly lower thoracic level than does the \_\_\_\_\_ bronchus.

**634. Specify the anatomical structures and physiological features of the bronchial tree.**

**The Bronchial Tree.** The main bronchi bifurcate within the lungs to form the bronchial tree, as shown in figure 3-3.

**Secondary bronchi.** The first branch from the primary bronchi is the *secondary*, or lobar, bronchi. The right lung has three secondary bronchi; the left has two. There is one secondary bronchus for each lobe.

**Tertiary bronchi.** The secondary bronchi are further divided into *tertiary*, or segmental, bronchi. The right lung usually contains 10 tertiary bronchi, one for each bronchopulmonary segment. The left lung has eight tertiary bronchi and eight bronchopulmonary segments.

**Bronchioles.** Next in order of subdivision are the *bronchioles* (little bronchi), which enter the lung tissues. To this point, the bronchi and their subdivisions are composed of fibrous tissue and resemble the C-shaped cartilaginous rings of the trachea and the primary bronchi. But when the bronchi becomes bronchioles, their diameter is decreased to

1 mm or less, and the cartilage is no longer seen. Each bronchiole penetrates deeper into the lung tissue, where it divides into several ducts called the *alveolar ducts*.

**Atria.** Next in the subdivision are the *atria*, which are irregularly shaped, elongated air sacs continuous with the alveolar ducts. From the atria, the alveolar sacs continue the subdivisions.

**Alveoli.** Finally, the *alveoli* are reached. These are minute, cup-shaped air cells that project from the walls of the bronchioles, alveolar ducts, atria, and alveolar sacs, and which become more numerous at the terminal portion of the respiratory system. They consist of a very delicate, thin layer of epithelial tissue and are surrounded by a network of capillaries. It is here, where the alveoli are close to the bloodstream, that the gases are exchanged through diffusion.

**Exercises (634):**

1. How many secondary branches are in the left lung? In the right lung?
2. What is another name for the secondary bronchi?
3. What is the next subdivision after the secondary bronchi?
4. At what point do the C-shaped cartilaginous rings of the bronchi disappear?
5. What ducts appear immediately after the bronchioles?
6. From what pulmonary structures does the exchange of gases occur in the lungs?

**635. Define and locate significant features or structures of the lungs.**

**The Lungs.** The lungs, shown in figure 3-4, are located on both sides of the *mediastinum*, where they occupy the right and left portions of the thoracic cavity. Each extends from about 1 to 1 1/2 inches above the clavicle to the superior border of the diaphragm. They are separated from each other by the *mediastinum*, which contains the heart, esophagus, part of the trachea, the great vessels, primary

**LEGEND:**

- Secondary bronchi of right lung
- Secondary bronchi of left lung
- Tertiary bronchi of right lung
- Tertiary bronchi of left lung
- ✶ Bronchioles

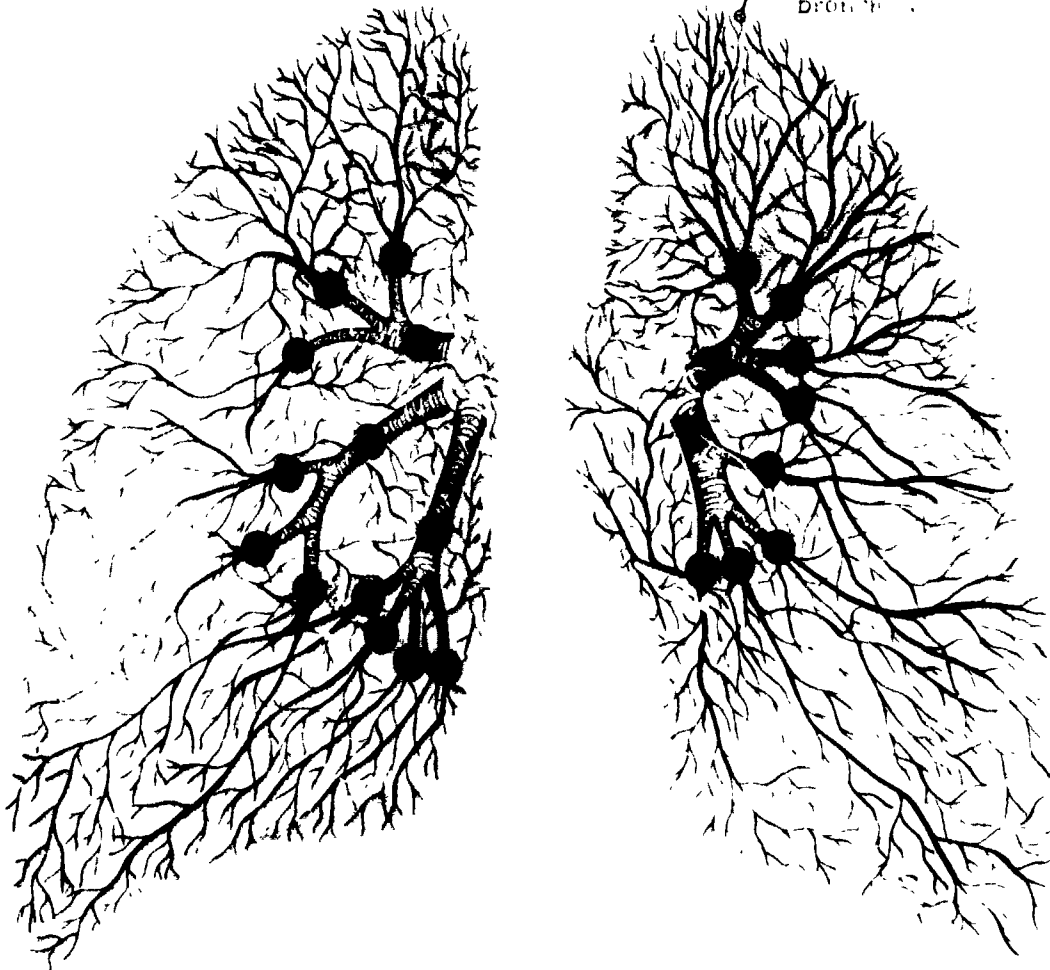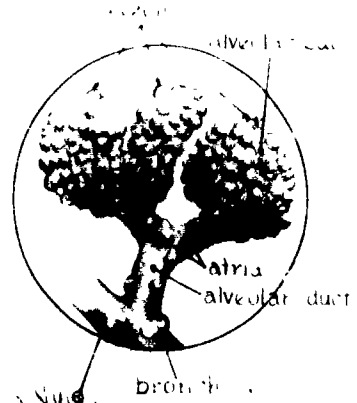


Figure 3-3 The bronchial tree



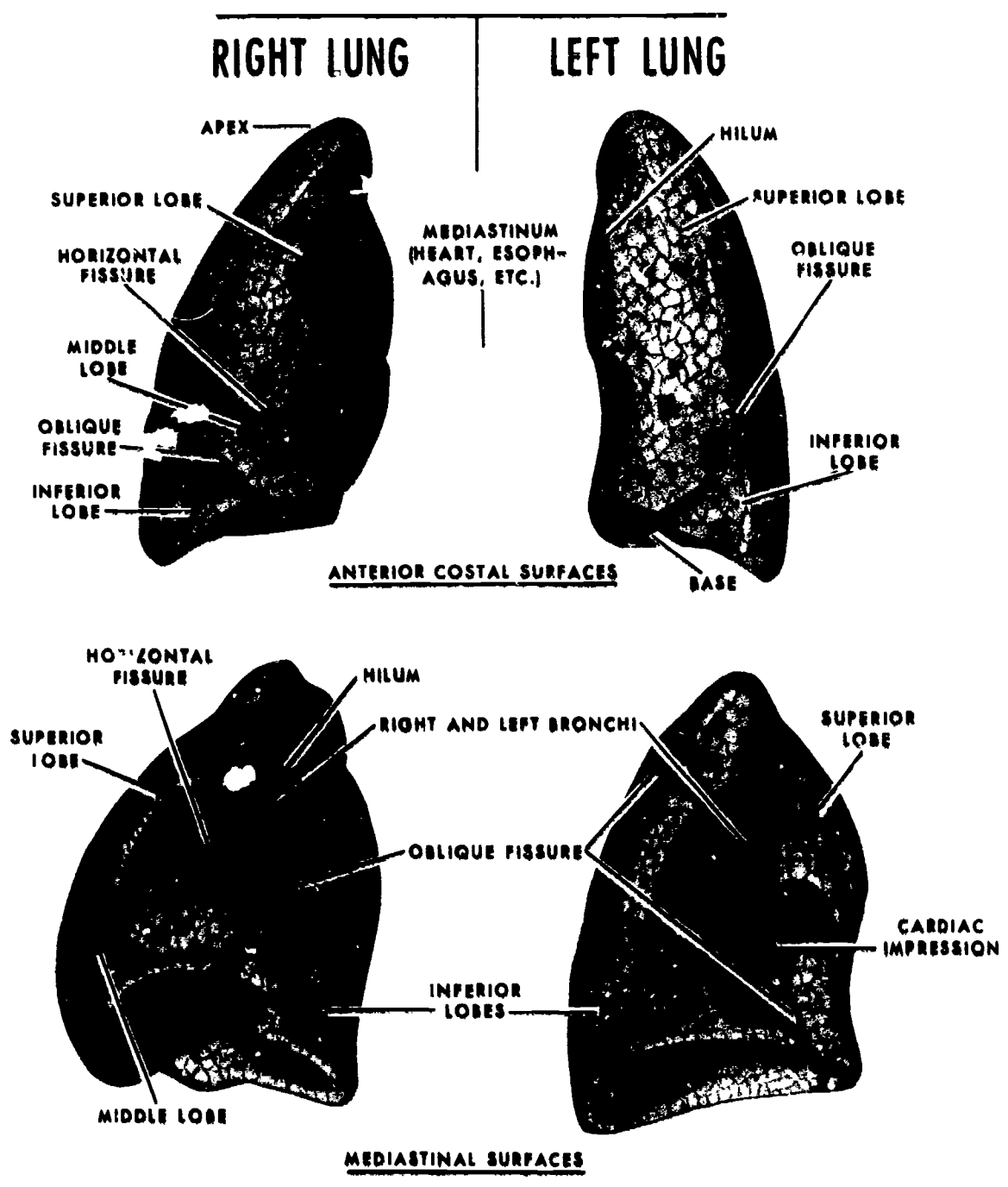


Figure 3-4. The lungs

bronchi, and many other smaller structures. The root of each lung connects the lung, trachea, and heart and contains the pulmonary artery and vein, bronchus, bronchial arteries and veins, nerves, lymphatics, and lymph nodes. The arteries, veins, and nerves enter and leave the lung at a point called the *hilum*, a triangular depression on the inner medial surface of each lung.

The lungs are composed of a light, porous and spongy, elastic tissue. Each resembles an inverted cone in shape and consists of an apex, a base, costal and mediastinal surfaces, lobes and fissures, and a bronchial tree. The apex is rounded and extends to about 1 to 1 1/2 inches above the level of the sternoclavicular joints, bilaterally.

The lung base, or diaphragmatic surface, consists of a broad, concaved, inferior part that rests on the convex superior surface of the diaphragm. Because it covers the right lobe of the liver, the base of the right lung has a deeper concavity than the left.

The interlobar (oblique) fissure divides the left lung into two parts—a superior (upper) lobe and an inferior (lower) lobe; the latter is the larger of the two. The right lung has three lobes. An interlobar fissure, similar to that of the left lung, separates the inferior lobe from the middle and superior lobes. A horizontal fissure at the level of the fourth costal cartilage makes a wedge-shaped middle lobe between the inferior and superior lobes.

#### Exercises (635):

1. What is the name of the area between the lungs?
2. What is the hilum?
3. Where is the apex of a lung located?
4. On what structure does the base of the lung rest?
5. How many lobes has the right lung? The left?
6. What structures mark the divisions of the lobes of the lungs?

### 3-2. Bronchography Procedures

There are at least four methods of introducing the contrast medium into the lungs for a bronchogram. They are: (1) *intratracheal intubation*, (2) *supraglottic*, (3) *intraglottic*, and (4) *cricothyroid*.

#### 636. Differentiate among the four methods of introducing the contrast medium during a bronchogram.

**Intratracheal Intubation Method.** The intratracheal intubation method is perhaps the most commonly used method for introducing the contrast medium into the lungs. The tube or catheter is inserted either through the mouth or, most commonly, through the nasal cavity into the trachea during the first stage in the procedure. Then, under fluoroscopic control, the radiologist directs the tube into the specific area to be examined. A syringe filled with contrast medium is then connected to the tube and the medium is introduced under fluoroscopic control. One advantage of this method is that it offers selective visualization of a particular portion of the bronchial tree.

**Supraglottic Method.** The supraglottic method, also called the *drip* method, is the oldest and sometimes considered to be the least effective. The contrast medium is dripped from a syringe fitted with a cannula onto the back of the tongue where it flows into the trachea and lung fields. One disadvantage is that some of the contrast medium is swallowed and appears in the esophagus, possibly causing confusing shadows on the radiographs.

**Intraglottic Method.** The intraglottic method is similar to the supraglottic method. Instead of dripping the contrast medium onto the back of the tongue, the radiologist introduces it directly into the glottis using a syringe fitted with a long, curved laryngeal cannula.

**Cricothyroid Method.** In the cricothyroid method, a needle is inserted directly into the trachea between the cricoid and thyroid cartilages. The contrast medium can be introduced through the needle or into a catheter that has replaced the needle. In case of the catheter, selective visualization of a portion of the bronchial tree is also possible. One major advantage with this method is that since the upper larynx is bypassed, the patient may not be as likely to cough, which can interfere with the examination. This method also seems to be the most popular with patients.

#### Exercises (636):

1. Match the bronchographic method of contrast media introduction in column B with the appropriate statement in column A. Each column B item may be used once or more than once. Also, more than one column B item may match a single column A entry.

## Column A

- \_\_\_\_\_ (1) Requires the insertion of a needle
- \_\_\_\_\_ (2) Used most often
- \_\_\_\_\_ (3) Requires a catheter
- \_\_\_\_\_ (4) Permits selective visualization of a specific part
- \_\_\_\_\_ (5) May be least effective
- \_\_\_\_\_ (6) Uses a long, curved laryngeal cannula
- \_\_\_\_\_ (7) May provide confusing shadows of a contrast-filled esophagus
- \_\_\_\_\_ (8) Reduces the patient's urge to cough
- \_\_\_\_\_ (9) Most popular with patients

## Column B

- a Intratracheal intubation
- b Supraglottic
- c Intraglottic
- d Cricothyroid

## Exercises (637):

1. What is the overall effect that excessive coughing by a patient during bronchography could have on the examination?
2. Give two reasons for your answer to exercise number 1.
3. How can you, by instructing or informing the patient, possibly help prevent the patient from coughing excessively?
4. What action should you take while performing the postfluoro radiographs to help ensure that the examination is not unsuccessful due to the coughing?

**637. Relate coughing by the patient to the success of a bronchogram and state how coughing affects your role during a bronchogram.**

**Coughing.** When the contrast medium is introduced into the patient's bronchial tree, it causes a strong urge to cough—the more contrast medium, the stronger the urge. This is a natural reflex action caused by irritation of air passages by the medium. If the patient coughs excessively during the examination, the examination may not be successful for two reasons. First, the patient may cough up the contrast medium. Second, coughing may create a condition known as peripheral flood, in which the contrast material fills the minute air passages in the periphery, resulting in some difficulty in interpretation.

What can you do to help prevent the patient from coughing? In the first place, you should carefully explain the entire examination. Tell the patient exactly what is going to happen and when it will occur. Stress that the patient should try to refrain from coughing. If the urge to cough becomes strong, have the patient begin rapid, shallow breathing or "pant," which sometimes suppresses the urge to cough.

As mentioned before, the more contrast material in the patient's lungs, the stronger is the urge to cough. This means that when the examination nears completion and the entire amount of contrast material has been introduced, the patient's urge to cough is strongest. This is the time during which you will be performing the postfluoro radiographs. Consequently, you must act quickly. It is best if two technicians perform the radiographs to further minimize the time.

**638. Explain procedures for performing postfluoro bronchographic radiographs.**

**Projections and Exposure.** When the radiologist finishes the fluoroscopic phase of the examination, you perform the postfluoro radiographs. Depending upon local policy, the radiographs are made with the patient recumbent on the X-ray table or erect in front of an upright cassette holder.

Both sides of the chest can be examined simultaneously, but more often only one side is examined on a given day. The projections you perform depend upon the side examined. Usually, a minimum of three radiographs are made—PA or AP, oblique, and lateral; however, this depends upon local policy. Anterior or posterior oblique projections can be made. If the right lung is examined and your radiologist wants posterior obliques, take an RPO. Take the opposite posterior oblique if the left side is examined. If your radiologist wants anterior obliques and the left side is examined, take an RAO—take the opposite anterior oblique if the right side is examined. All of these obliques demonstrate the lung field in question, free of superimposition by the spine.

If only one side is examined, the correct lateral, of course, is the one that places the part under examination closer to the film. If both sides are being examined, a lateral projection after both sides are filled normally is not done because superimposition of the two sides obscures structural details. However, a lateral of the first side filled with contrast material is usually done before the opposite side is filled.

The exposure for the projections described should be increased slightly over that normally used for the lungs. The

reason for the increase is to demonstrate those portions of the lung fields superimposed by the heart and to demonstrate the trachea and primary bronchi, which are superimposed over the spine. Generally, a 5- to 10-percent increase in kVp is sufficient.

#### Exercises (638):

Answer the following exercises pertaining to the projections made after fluoroscopy during a bronchogram.

1. What minimum number of projections are usually made? What are they?
2. If only the right lung is being examined, what oblique projection should you make?
3. If only the left lung is being examined, what oblique projection should you make?
4. Why is a particular oblique necessary?
5. If both lungs are being examined (right lung first), how many laterals will you probably make and why?
6. If your answer to the first part of exercise number 5 was *one*, which lateral would you make? If your answer was *two*, which lateral would you make first?

7. Why is it necessary to increase the exposure over that normally required for lung radiographs?

**639. Briefly explain the care of the bronchographic patient after the examination is finished, in terms of coughing up the contrast material and ingestion of food or water.**

**Aftercare of the Patient.** Once the examination is terminated, provide the patient with an emesis basin. Give instructions to cough *gently* to remove the contrast material from the lungs, keeping the patient under observation until the patient leaves the radiology department. Be sure to stress that the patient is to cough *gently* because to cough harshly forces the contrast medium into the alveoli, in which case it can only be eliminated by absorption.

Also, of major importance is the fact that the patient's throat remains anesthetized for a number of hours following the examination. Because of this condition, the patient must not have *anything* to eat or drink until the anesthesia has worn off because, instead of the material being swallowed, it can be aspirated into the lungs.

#### Exercises (639):

1. Explain how the patient should be instructed to cough up the contrast material after the bronchogram and why.
2. How long after the examination should the bronchographic patient be refused water or food and why?

## Contrast Studies of the Cardiovascular and Lymphatic Systems

BLOOD OR LYMPH is circulated throughout the body by the circulatory or cardiovascular system. Occlusion, perforation, or disease of these organs and tissues can produce serious and often permanent damage. Not only are the components of the cardiovascular system affected but so are the organs or structures dependent upon them for blood supply. Prompt medical or surgical intervention is often required to correct a malfunction. However, for some conditions, treatment is not initiated until accurate, comprehensive diagnostic tests have been completed. These tests include complete radiographic examination of the heart or of the affected vessel. The procedure involved in this type of examination is called angiography and is the subject of this chapter. Our study is conducted in three parts. The first portion concerns the physical structures of the cardiovascular and lymphatic system. The second deals with various angiographic considerations including contrast media and techniques for introducing the contrast media. Thirdly, we will take a brief look at some of the special equipment items and devices.

### 4-1. Anatomy and Physiology of the Cardiovascular System

The circulatory system includes the lymphatic system, the blood, and the blood-vascular system. We begin our discussion with the lymphatic system.

**640. Define, locate, and give the function of major structures of the lymphatic system.**

**Lymphatic System.** The lymphatic system (fig. 4-1) is composed of lymphatic vessels, glands, and nodes. It promotes the return of body fluids toward the heart; as such, it is an adjunct to the cardiovascular system.

**Lymph.** Lymph comprises the bulk of intercellular fluid. It functions as a transfer medium for supplying the cell with nutrients, oxygen, and fighting off bacteria. It contains lymphocytes, proteins, and waste by-products. Lymphocytes are a type of white blood cell that carries off waste and initiates formation of scar tissue. The proteins are a source of energy for the cells. The waste materials are a result of cellular metabolism.

**Lymph vessels, nodes, and ducts.** Lymph vessels comprise a network of tubes that begin in the intercellular spaces. Here tiny lymph capillaries collect lymph and

transport it to lymph nodes that are located throughout the body. The lymph nodes filter out the waste by-products and fight bacteria. Lymph nodes or glands are small oval or bean-shaped bodies, varying from a pin head to a lima bean in size. They are distributed along the course of the lymph vessels, sometimes singly, but usually in groups or clusters. There are superficial and deep nodes. They are found in close contact with an artery and vein. Lymph nodes are especially numerous in the neck (cervical), the armpit (axillary), the groin (inguinal), and in the thorax and abdomen. Lymph vessels enter these nodes, and a larger trunk leaves the nodes. Eventually vessels from the nodes carry lymph to a large duct in the thorax where the lymph is returned to the bloodstream into the left subclavian vein. Valves located in the vessels prevent backflow.

**Spleen.** The spleen is the largest collection of lymphoid tissue in the body. It is a large, glandlike, ductless organ directly beneath the diaphragm, behind and to the left of the stomach. Two of its functions are to produce lymphocytes for fighting infection and, since it has many sinusoids, to store red blood cells.

### Exercises (640):

1. (a) What is lymph? (b) Name two of its functions.
2. Where are lymph nodes or glands located?
3. Where does the thoracic duct empty into the venous system?
4. Where is the spleen located?

Tone indicates body area from which Right Lymphatic Duct receives lymph.

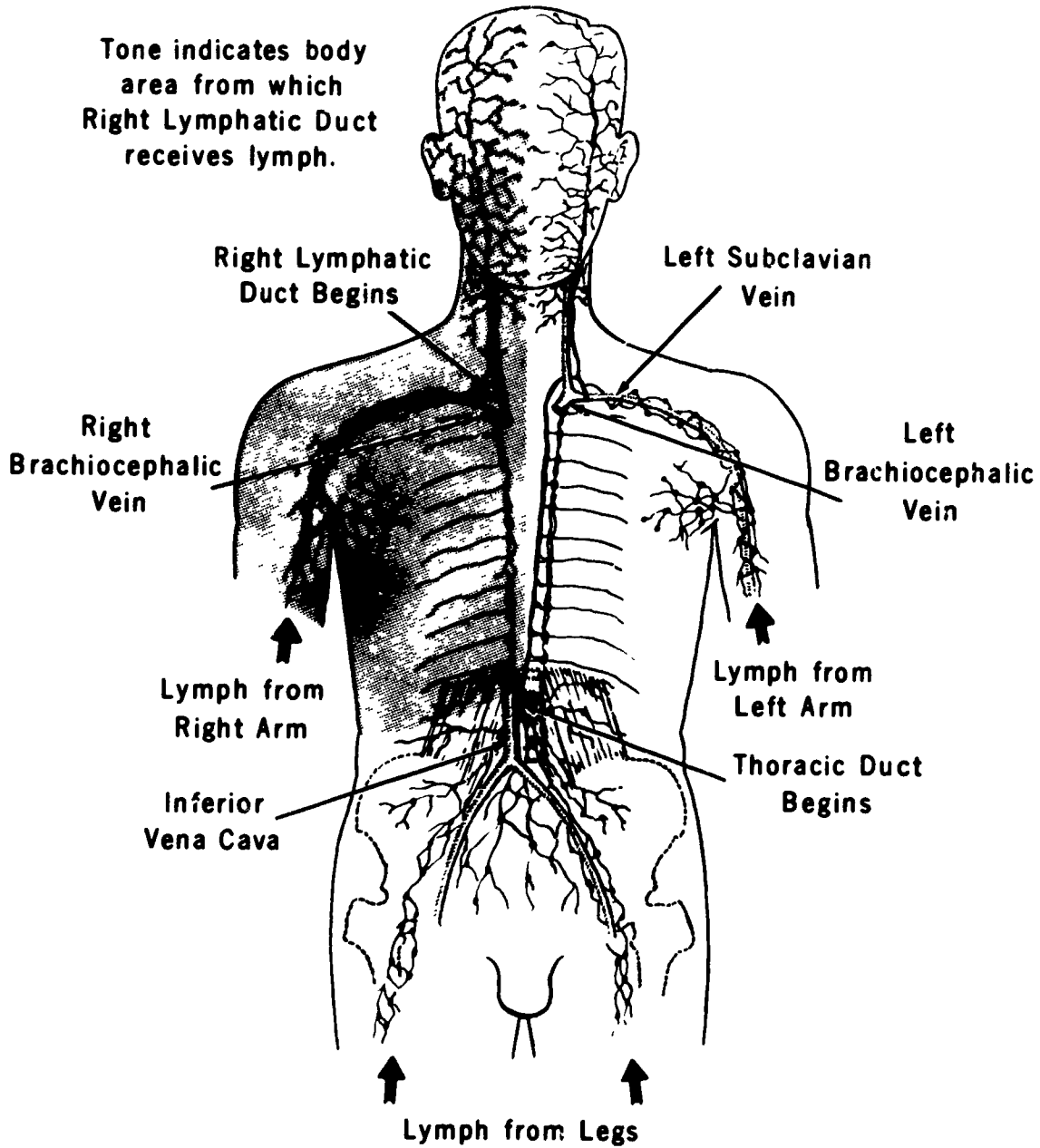


Figure 4-1 The lymphatic system

5. What are two functions of the spleen?

**641. Name the major structures of the heart, trace the circulation of blood through the heart, and define systole and diastole.**

**The Heart.** The heart (fig. 4-2) is the major organ of the circulatory system. It is hollow, muscular, somewhat cone-shaped, and slightly larger than the closed fist. The heart lies obliquely in the lower two-thirds of the thoracic cavity, with the apex directed downward and the bulk of its mass to the left of the midsagittal line.

**Structure.** Located in the mediastinum, the heart is enclosed in a dual-layered, loose-fitting sac called the pericardium. Between the outer fibrous layer and the inner serous layer is a serous liquid, the pericardial fluid, which lubricates the smooth outer surface of the heart. The superior portion or base of the heart consists of two receiving chambers, the atria. The main body extends into the apex and consists of two larger chambers, the ventricles.

**Blood circulation.** Deoxygenated blood from the body tissues enters the right atrium through the superior and inferior vanae cavae (see fig. 4-2). It then passes through the tricuspid valve into the right ventricle. The blood leaves this chamber through the pulmonary semilunar valve and passes by the right and left pulmonary arteries to the lungs, where it receives a fresh supply of oxygen and releases carbon dioxide. The oxygenated blood returns to the heart in the right and left pulmonary veins, which open into the left atrium. From the left atrium the blood passes through the bicuspid (or mitral) valve into the left ventricle. This ventricle is the largest and strongest chamber of the heart and from it the oxygenated blood passes through the aortic semilunar valve into the aorta from which it is distributed to all parts of the body except the lungs.

**Heart action.** As the heart pumps, backflow of blood is prevented by the action of valves: the tricuspid valve between the right atrium and ventricle; the mitral valve (bicuspid valve) between the left atrium and ventricle; and the semilunar valves, which guard the outlets of the ventricles

Although variations in the individual heart rate depend on sex, age, and physical activity as well as on other factors, the heart normally beats about 70 times per minute.

Each heartbeat or cardiac cycle consists of a wave of contraction called *systole*, followed by a wave of relaxation called *diastole*. Each wave starts at the atria and moves across the ventricles. When a chamber is in systole, blood is being forced out; and when it is in diastole, blood is entering. The systolic pressure is the pressure during the contraction phase, the diastolic pressure is the pressure during relaxation, and the pressure between the two pulses is the pulse pressure.

#### Exercises (641):

1. What is the name of the dual-layered sac enclosing the heart?
2. Name the two chambers in the superior portion (base) of the heart.
3. Name the two chambers in the inferior portion of the heart.
4. Trace the circulation of blood through the major chambers and vessels of the heart
5. What function do the various valves located in the heart serve?
6. Define systole and diastole.

**642. State the four regions of the aorta and identify major vessels of the body with areas drained.**

Systemic circulation follows an orderly pattern in which blood from the heart courses through the major arteries and its branches to body tissues and returns to the heart through major veins and their tributaries.

**Major Arteries.** The aorta is the primary arterial trunkline in the systemic circulation. It arises from the left ventricle, ascends superiorly, arches over the left lung, and descends through the thoracic and abdominal cavities along the spinal column to the level of the fourth lumbar vertebra. Here it bifurcates into the right and left common iliac arteries that supply the lower extremities. Major arteries supplying other parts of the body branch out from the aorta at specific locations. For descriptive purposes the aorta may be divided into four regions: the ascending aorta, the arch of the aorta, the descending aorta, and the abdominal aorta. The major arteries are shown in figure 4-3.

**Major Veins.** In general, the major veins course through the body in proximity to the arteries and, in most cases, have the same name. Blood from the veins of the heart drains through the coronary sinus into the right atrium. Blood from the head and neck drains into the jugular veins; that from the upper extremities drains into the subclavian veins. On each side these veins join to form the right and

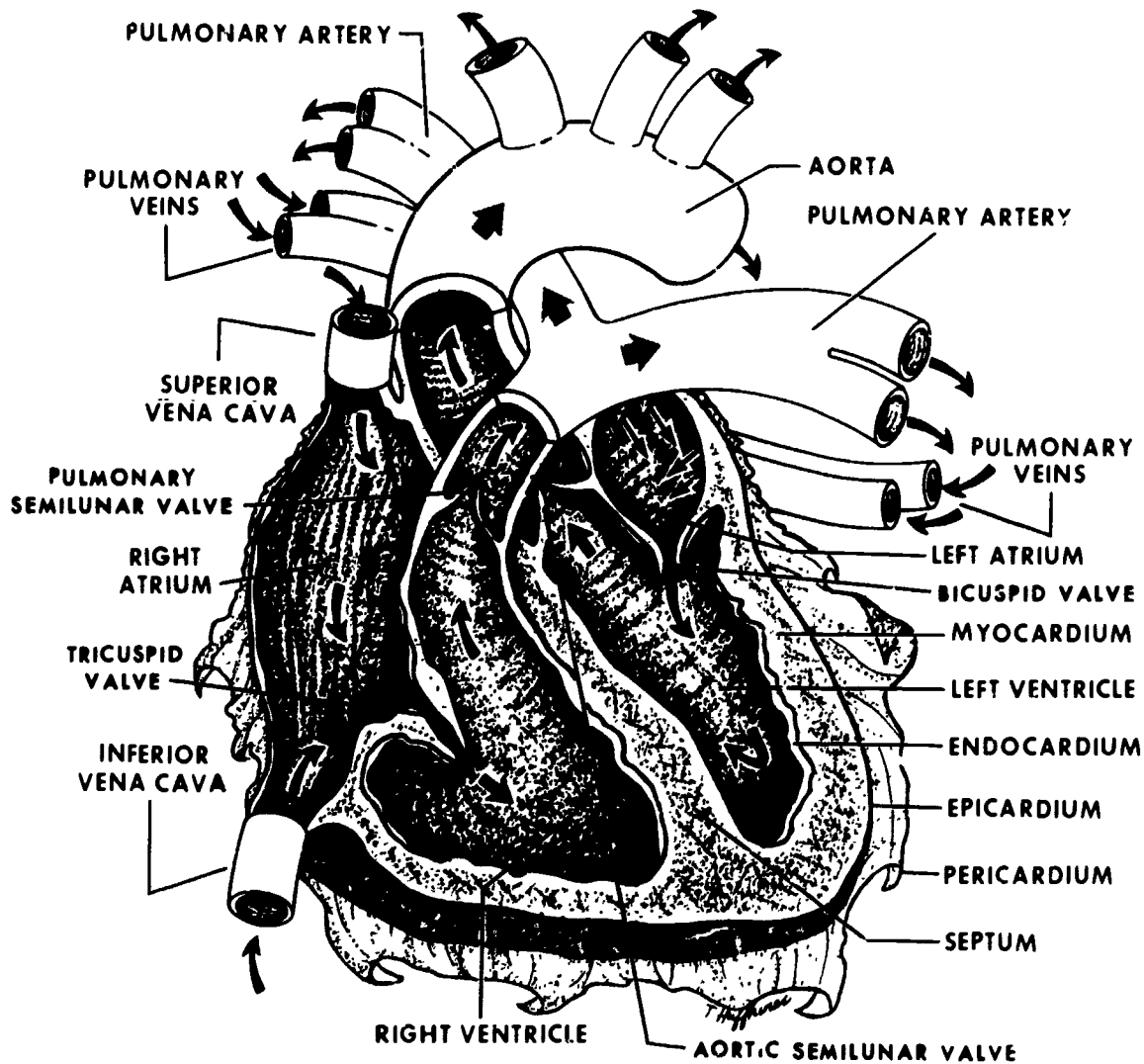


Figure 4-2 The heart

left innominate veins, which, in turn, unite into the superior vena cava that opens into the right atrium. The superior vena cava also receives the azygos vein, which, with its tributaries, returns blood from the thorax to the superior vena cava. The azygos vein begins in the abdomen as an extension of one of the tributaries of the inferior vena cava and serves as a connection between the superior and inferior venae cavae in the return of blood to the heart. The major veins are shown in figure 4-4.

From the lower extremities and abdomen, two venous routes lead to the heart. In the direct route, blood from the lower extremities moves through the right and left common iliac veins, which join at the level of the fifth lumbar vertebra to form the inferior vena cava. This major vein courses through the abdominal cavity in proximity to the aorta along the posterior abdominal wall. It receives the lumbar, genital, renal, adrenal, hepatic, and inferior phrenic veins as it ascends through the abdominal cavity, before it enters the right atrium of the heart.

Blood from the spleen and the abdominal organs of the gastrointestinal tract is not returned directly to the heart by way of the inferior venae cavae. Instead, the veins draining the small intestine, stomach, lower esophagus, and spleen join to form the portal vein, which enters the liver. Blood from the tissues of the liver enters the hepatic vein, which then drains into the inferior venae cavae en route to the right atrium.

#### Exercises (642):

1. Name the four regions of the aorta.



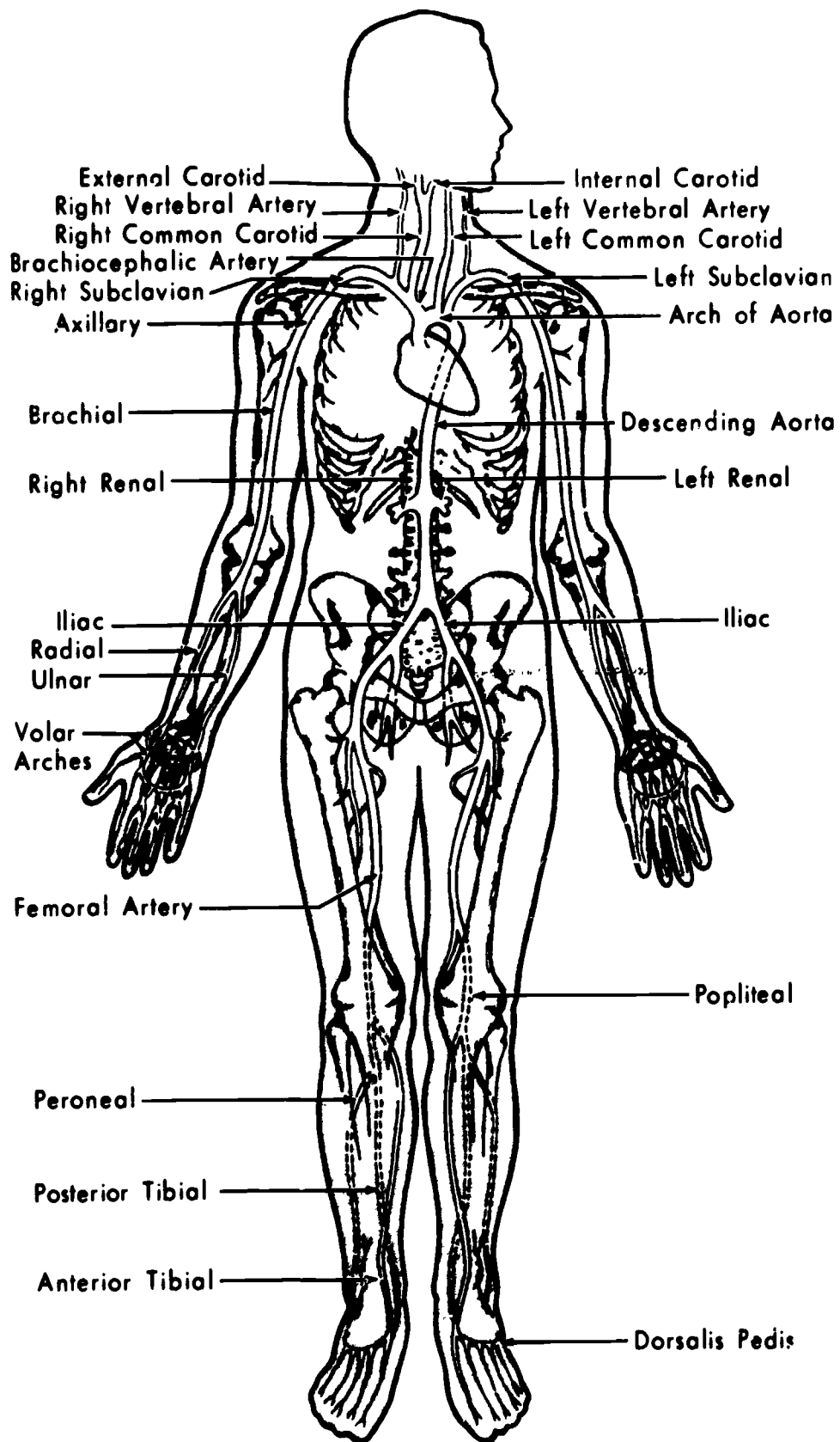


Figure 4-3. Major arteries.

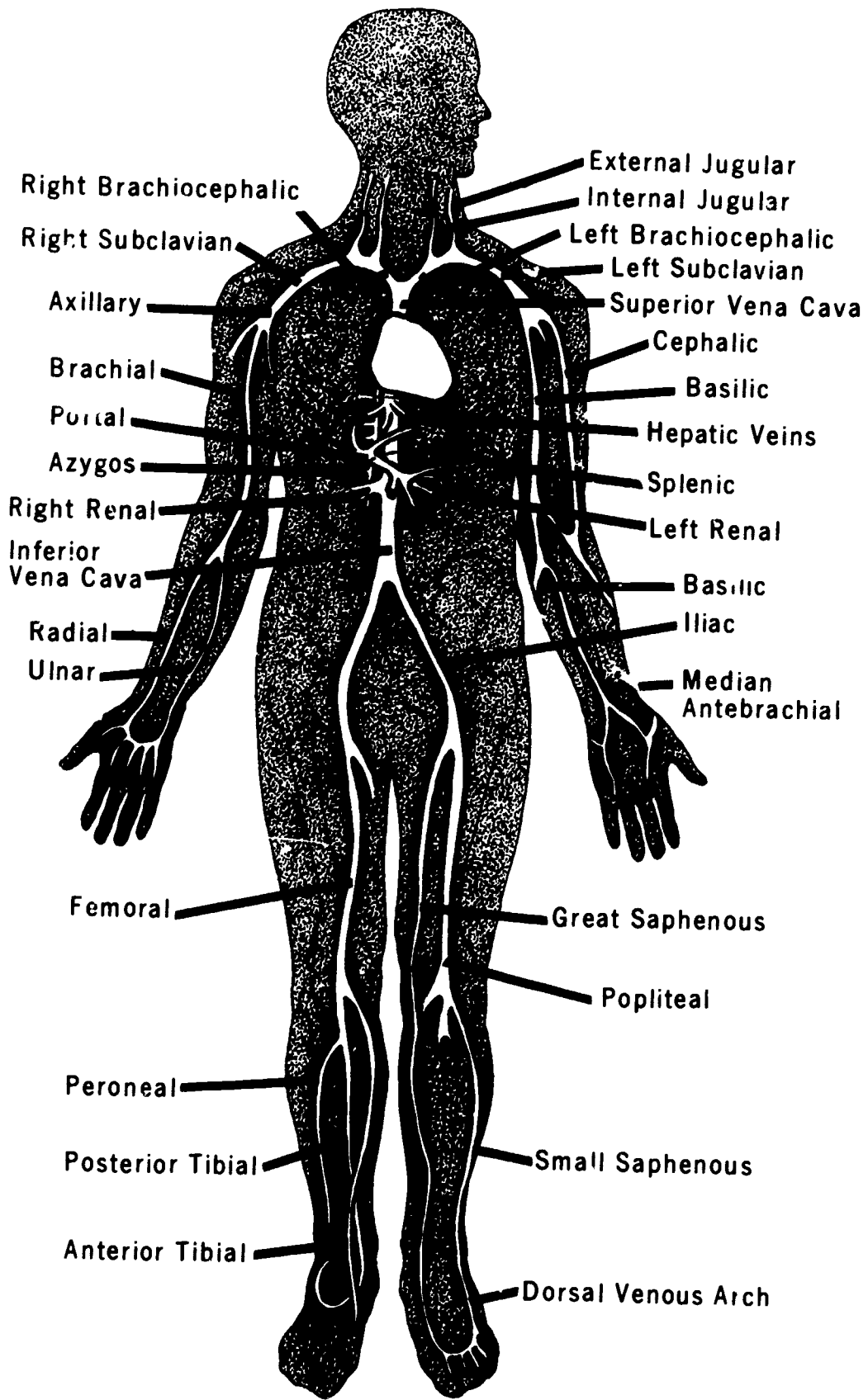


Figure 4-4 Major veins.

2. Match the major vein from column B with the area of the body it drains in column A. Each vein in column B is used only once.

Column A	Column B
_____ (1) Thorax	a Portal
_____ (2) Liver	b Iliac
_____ (3) Head and neck	c Hepatic
_____ (4) Upper extremities	d Azygos
_____ (5) Lower extremities	e Jugular
_____ (6) Small intestine, stomach, lower esophagus, and spleen	f Subclavian

**643. Name, locate, and state relationships of key arteries about the head and neck.**

**Arteries of the Head and Neck.** The arteries that carry blood to the cervical and cranial regions arise from the aortic arch, the innominate, and the subclavians. As seen in figure 4-5, the ascending vessels include the left and right common carotids and the vertebral arteries. The left common carotid arises from the highest point of the aortic arch and ascends through the superior portion of the mediastinum into the neck. The right common carotid passes directly into the neck from its point of origin at the bifurcation of the innominate artery. Once into the cervical region, the appearance and configuration of the carotid arteries and their ramifications are essentially identical. Therefore, we consider only those vessels supplying one side of the neck, face, and head. The same is true of the vertebral arteries.

**Carotid artery.** The cervical portion of the carotid artery ascends obliquely through the neck to a point just about level with the superior aspect of the thyroid cartilage. Here it separates, forming internal and external branches.

The external carotid artery curves laterally and then ascends along the side of the neck. It gives off numerous branches that supply the upper neck, the face, and the scalp.

The internal carotid artery ascends almost vertically from the junction to the floor of the skull. It then follows a tortuous path through the petrous portion of the temporal bone. The vessel then passes medially along the surface of the sphenoid bone and gives off the ophthalmic artery, which supplies the eye and the orbit. The internal carotid then curves upwards and perforates the dura mater in the region of the sella turcica. It then bends upon itself and gives off the anterior cerebral, middle cerebral, posterior communicating, and choroidal arteries. These vessels supply the deep midportion of the cerebral hemisphere. Figure 4-6 illustrates the internal carotid system and shows the vessels as seen from the right side.

**Vertebral artery.** The vertebral artery arises from the subclavian and, as illustrated in figure 4-6, ascends through the foramina of the transverse processes of the cervical spine to the base of the skull. It then passes through the foramen magnum and joins with its counterpart on the

opposite side to form the basilar artery. Before they join, however, each vertebral artery gives off one inferior cerebellar artery. These vessels pass through the foramen magnum and serve to nourish the lower portion of the hind brain. The basilar artery, usually a midline structure, ascends on an anteriorly angled course to a point about 1 cm posterior to the dorsum sellae. Here it gives off several branches that supply the cerebellum and the posterior aspects of the cerebral hemispheres. The basilar artery terminates in the posterior cerebral arteries.

**Circle of Willis.** The carotid and vertebral systems are joined at the base of the brain by the circle of Willis. Figure 4-7 illustrates the appearance and structural arrangement of this juncture. Notice that the majority of the circle is formed by branches from the carotid system. The anterior cerebral arteries are joined by the anterior communicating arteries to form the anterior portion of the circle; while the internal carotid and the middle cerebral arteries form the majority of its lateral aspects. The posterior portion of the circle is formed by the posterior communicating and posterior cerebral arteries and is the terminal end of the basilar artery.

**Exercises (643):**

Select the terms to complete the following statements. Each answer set is used only once.

- Transverse processes
- Inferior cerebellar
- Left subclavian
- Circle of Willis
- Internal carotid; external carotid
- Anterior cerebral; anterior communicating
- Posterior communicating; posterior cerebral
- Basilar
- Left
- Internal carotid
- Right subclavian

1. The \_\_\_\_\_ common carotid artery arises directly from the aorta.
2. Of the three large arteries existing from the aortic arch, the \_\_\_\_\_ exits nearest the descending aorta.
3. The right vertebral artery arises from the \_\_\_\_\_ artery.
4. The common carotid branches into the \_\_\_\_\_ and \_\_\_\_\_.

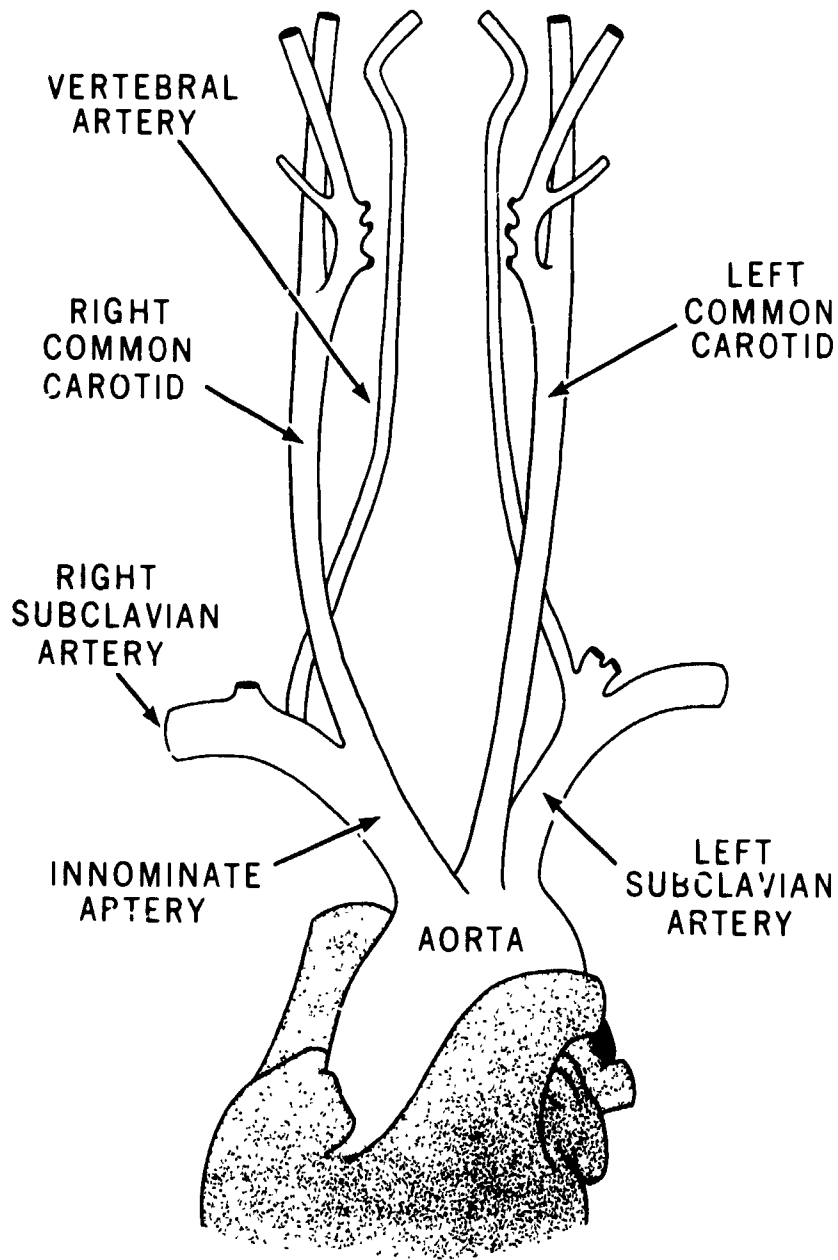


Figure 4-5 The aorta and its major branches

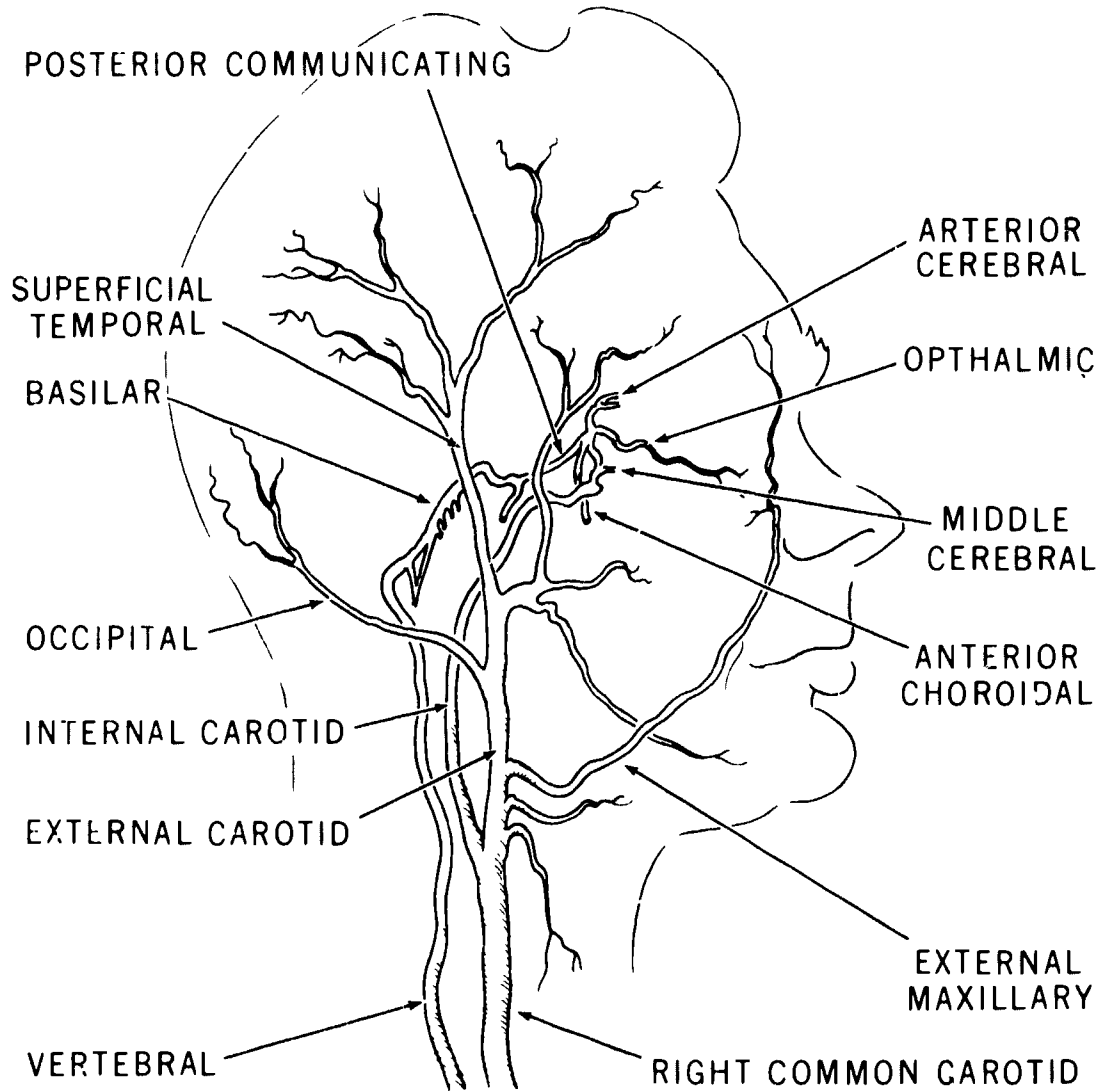


Figure 4-6 The arterial system of the head and neck

5. The ophthalmic artery is a branch off the \_\_\_\_\_.
6. The vertebral artery ascends through the \_\_\_\_\_ of the cervical spine.
7. The lower portion of the hind brain is supplied by the \_\_\_\_\_ arteries.
8. The \_\_\_\_\_ artery terminates in the posterior cerebral arteries.
9. The \_\_\_\_\_ joins the carotid and vertebral arterial systems.
10. The anterior portion of the circle of Willis is formed by the \_\_\_\_\_ and \_\_\_\_\_ arteries.
11. The posterior portion of the circle of Willis is formed by the \_\_\_\_\_ and \_\_\_\_\_ arteries.
644. Name, locate, and specify relationships of key veins about the neck and head.

**Veins of the Head and Neck.** The vessels that comprise the venous network of the head and neck are divided into deep and superficial groups. The deep vessels of the head, those which drain blood from the brain, are comprised of the internal and external cerebral veins, the superior and inferior cerebellar veins, and the dural sinuses. Refer to figure 4-8 as we discuss these vessels.

**Deep vessels.** The internal cerebral vessels, which empty the deep midportion of the cerebral hemispheres, are the striothalamic (terminal) vein, the internal cerebral vein, and the great cerebral vein of Galen. The external cerebral vessels include the superior, middle, and inferior cerebral veins and the anastomotic veins of Trolard and Labbe. These veins empty the upper, mid, and basilar surfaces of

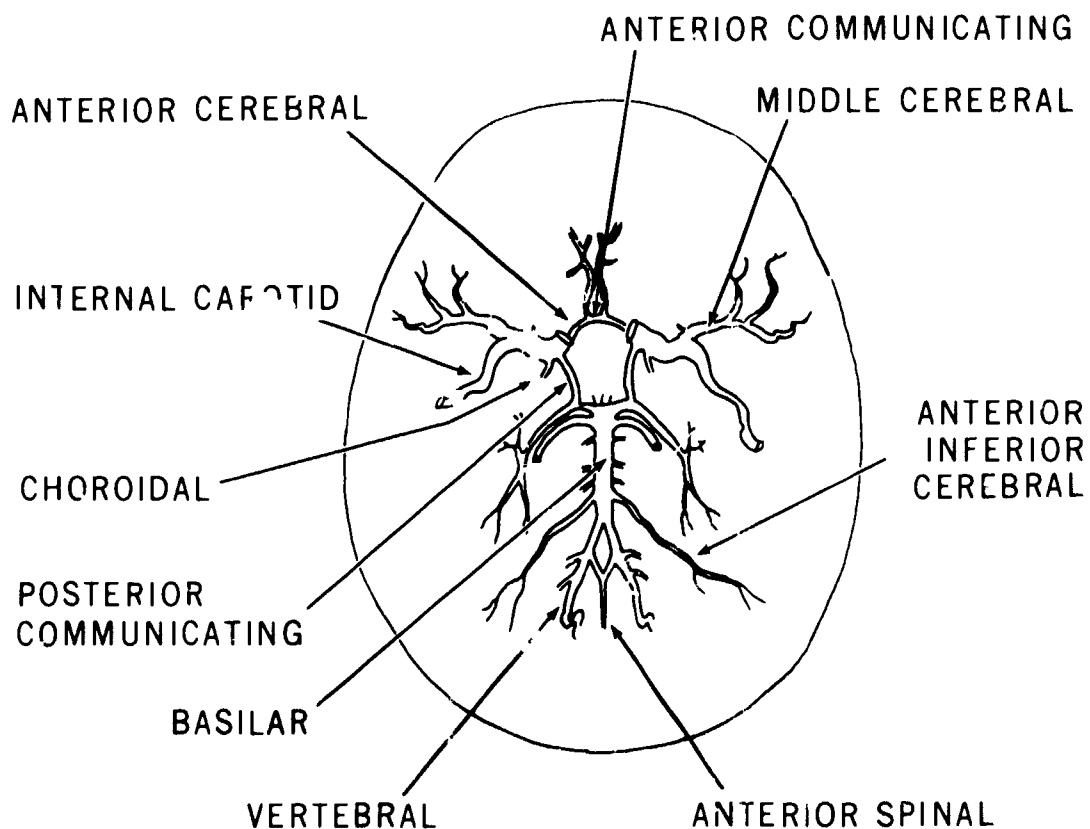


Figure 4-7 Circle of Willis.

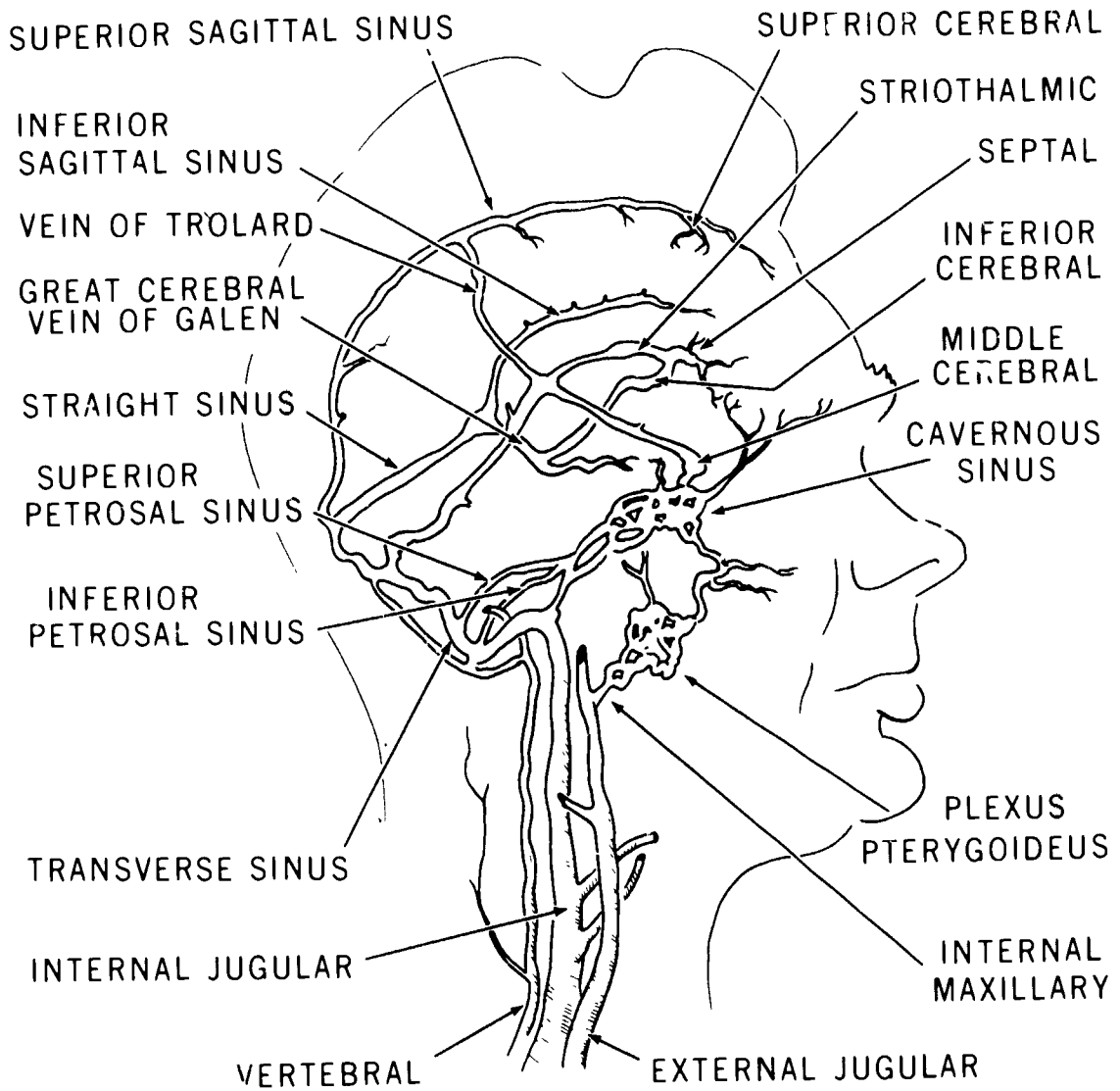


Figure 4-3 The venous system of the neck and head

the hemispheres. The cerebellar veins drain blood from the hind brain. All of these vessels empty into the dural sinuses. As you can see, these large vessels completely surround the brain. The superior and inferior sagittal sinuses lie along the margins of the falx cerebri (a fibrous, curtainlike structure which separates the superior aspects of the cerebral hemispheres). They are joined by the straight sinuses, into which the great vein of Galen empties. These sinuses join in the region of the internal occipital protuberance and form the confluens of the sinuses. The right and left transverse sinuses extend inferolaterally from this junction. They pass along the inner surface of the occiput and give rise to the inferior and superior petrosal and basilar sinuses. The latter gives rise to the sigmoid sinuses which empty into the internal jugular veins. There are no valves in these thin-walled, venous structures or sinuses.

**Superficial vessels.** The superficial veins of the head, illustrated in figure 4-9, arise from the scalp and face. They describe a pattern similar to that of the external carotid

arterial system and, for the most part, empty into the external jugular veins. As you can see, the occipital vein does not empty into either of the jugular vessels but passes down the posterior aspect of the neck to join with the deep cervical and vertebral vessels. The anterior facial vein empties into both of the large neck veins.

The venous vessels of the neck consist of the internal jugular veins (which are the largest), the external jugulars (and their ramifications), the vertebral veins, and the deep cervical vessels. As illustrated in figure 4-8, the vertebral vein originates at the base of the skull and passes downward through the foramina in the transverse processes of the cervical spine. Thus, it follows a course closely approximating that of the vertebral artery. This vein empties into the subclavian vein.

The deep cervical vein arises from the suboccipital region and passes downward and forward to join with the vertebral vein in its distal reaches. The deep cervical

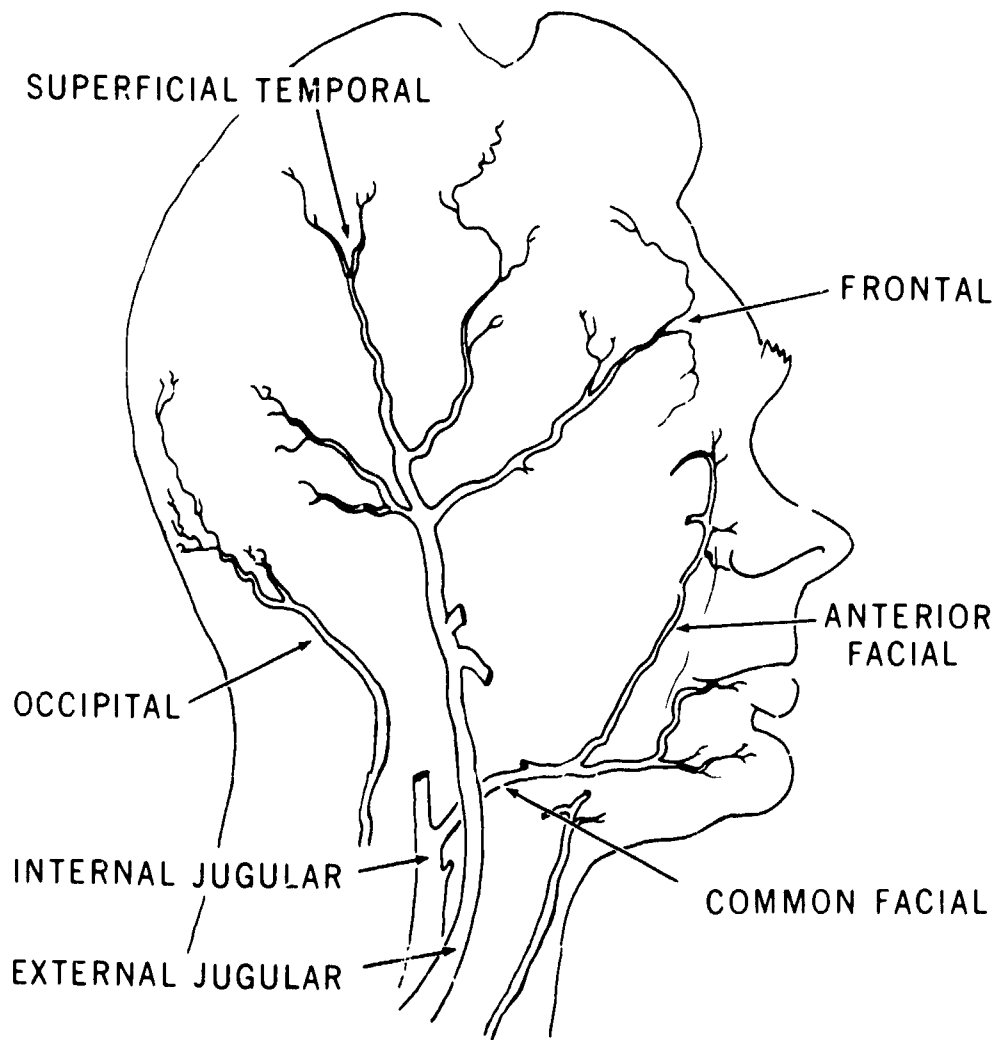


Figure 4-9 Veins of the neck and head



receives the occipital vein and tributaries from the venous plexuses surrounding the cervical vertebrae.

The external jugular veins, as shown in figure 4-9, commence near the angles of the mandible. They descend along the lateral aspects of the neck to about the level of the clavicles where they empty into the subclavian veins. The external jugulars receive tributaries from the smaller anterior and posterior external jugular veins, from the superior veins of the base of the neck and scapula, and also from large communicating branch from the internal jugulars.

The internal jugular veins arise from the sigmoid sinuses, pass through the jugular foramina in the floor of the skull, and descend (almost vertically) to join with the subclavian veins. These large vessels receive branches from the common facial, lingual, pharyngeal, and the superior and middle thyroid veins. Although their primary function is to drain blood from the brain, they also receive and carry off blood from the face and the structures of the neck.

The subclavian vein extends medially from the first rib to the sternal end of the clavicle. It lies anterior and inferior to the subclavian artery and receives several tributaries, including the external jugular vein. The subclavian joins with the internal jugular to form the innominate vein.

#### Exercises (644):

1. Name three veins that empty the deep midportion of the cerebral hemispheres.
2. What portions of the cerebral hemispheres are emptied by the cerebral and anastomotic veins of Trolard and Labbe?
3. What large vessels completely surround the brain?
4. Where are the superior and inferior sagittal sinuses located?
5. Into what vein does the sigmoid sinus empty?
6. Are the transverse and basilar sinuses considered deep or superficial drainage channels?

7. Does the occipital vein empty into the external jugular vein?
8. Where does the vertebral vein originate?
9. Where does the vertebral vein empty?
10. With what vein does the deep cervical vein join distally?
11. Where does the external jugular vein originate?
12. Into what vein does the external jugular empty?
13. The subclavian and internal jugular veins unite to form what vein?

#### 4-2. General Angiographic Considerations

Radiography of the vascular system is performed in many different ways. A simple procedure can be performed using a "needle and syringe" injection into a vessel after which a single radiograph is made. Or, the examination can be performed after a catheter is passed into a specific vessel or chamber of the heart. This type examination generally requires the use of sophisticated equipment to automatically start the injection, make the exposure, and change the film.

Due to the dissimilarity of specific procedures and techniques, we will present you with information that is basic and general in nature. Keep in mind that many technical aspects of radiography, such as FFD, target angles, tube rating charts, etc., have been discussed in Volume 1 of this CDC. These factors obviously apply to angiographic procedures.

In this section we will discuss angiographic contrast media, methods of introducing the contrast media, and how to form catheters.

#### 645. Specify requirements for and adverse effects of angiographic contrast media.

**Contrast Media.** Angiographic contrast media are similar to those used for intravenous urography—that is,

they are injectable organic iodides. The major difference is their weight-by-volume concentration.

**Concentration.** Weight-by-volume concentration does not refer to the iodine content of a particular medium, but to the concentration of the iodine compound in solution. For example, in 100 cc of Renografin-60, approximately 60 percent of the weight of the 100 cc in the compound is diatrizoate meglumine and 40 percent of the weight is in sterile water and other agents used in its manufacture. Generally contrast media such as Hypaque-50 percent, Conray-60 percent, and Renografin-60 percent are used for urographic and small vessel studies. However, for angiography, higher weight-by-volume concentrated solutions are used. Hypaque-75 percent or -90 percent, Renografin-76 percent, Isopaque 440, and Angioconray are examples of contrast media used for angiography. (NOTE: These are only examples and do not constitute an indorsement of products by the United States Air Force Medical Service.) For up-to-date information, consult supply catalogs and the *Physicians' Desk Reference* (PDR), current edition.

These highly concentrated media are used to prevent excessive dilution due to the high volume of blood found in the heart and large vessels.

**Adverse effects.** Contrast media administered during angiography can cause reactions similar to those discussed in Chapter 2 of this volume. Also, due to the higher concentration of some angiographic media and the rapid rate in which they are injected, the chance of a serious reaction is greater.

Another increased hazard associated with the injection of angiographic contrast media is that certain sensitive areas are more susceptible to reaction when the contrast medium is introduced directly into them. For example, during a renal arteriogram, the medium is either introduced directly into the renal artery or it is introduced into the aorta just proximal to the renal artery. Consequently, this medium reaches the kidneys in a more concentrated form than if it were injected into the arm for an IVP. Thus, the danger of damage to the kidney tissue is greater. The heart and the brain are other areas where direct introduction of the medium poses potential dangers.

#### Exercises (645):

1. What does the term "weight-by-volume concentration" indicate?
2. How is excessive dilution of a contrast medium overcome for angiographic studies?
3. Give three reasons why injection of angiographic contrast media increases the chance of a serious reaction.

#### 646. Associate techniques with the three methods for introducing the contrast medium during an arteriogram.

**Introductory Techniques and Devices.** Refined methods and, in certain instances, sophisticated injection devices are used to introduce contrast material into the vasculature. The techniques include *percutaneous injection*, *selective catheterization*, and a combination of these called *percutaneous-selective catheterization* or Seldinger's technique.

**Percutaneous injection.** Percutaneous simply means "through the skin." This technique is performed by passing a spinal, abdominal, or hypodermic needle through the skin, the subcutaneous and muscle tissue, and into the vessel to be demonstrated. The two-part spinal needle is more often used. One part consists of a hub and cannula, and the other is a trocar. The slender trocar has a very sharp point, while the cannula is usually blunted. The trocar is passed through the cannula and does the cutting. Once into the vessel, it is removed and the dull cannula is left in place. Thus, the arterial or venous walls are not subjected to any more damage than is absolutely necessary. A syringe filled with physiological saline is then attached to the hub of the needle, either directly or by means of tubing and an adapter. This salt water solution is injected by hand in the standard manner. It serves to clear the cannula and the area around its tip of debris resulting from passage through the vessel wall. Following the injection of saline, another syringe filled with a moderately concentrated contrast material is attached to the needle in the same manner. Again, injection is made by hand in the standard manner. Percutaneous injection is usually restricted to procedures that require only small amounts of contrast material. Thus, it is generally employed for carotid, femoral, peripheral angiography, and vena cavography.

**Selective catheterization.** Selective catheterization involves the passage of a long, thin-walled catheter through an artery or vein into the heart or aorta. A surgical cutdown is performed to expose the vessel through which the catheter is to be threaded. As a rule, the femoral artery (below the inguinal ring), the antecubital vein, or the brachial artery are the vessels exposed. The vessel is incised and the catheter inserted and threaded to the desired position under fluoroscopic control. When it is in place, the catheter is sutured to the vessel and the surrounding tissue. The incision is then closed and dressed. A contrast medium-filled syringe is attached to the exposed end of the catheter by an adapter, and injection can be made by hand. However, the procedures for which this technique is employed usually require large amounts of highly concentrated material. Consequently, automatic pressure injectors are more often used to force the medium through the catheter and into the structures to be visualized. Selective catheterization can be used for angiocardiology, thoracic aortography, coronary arteriography, lumbar aortography, and selected abdominal arteriography.

**Percutaneous-selective catheterization.** Percutaneous-selective catheterization (Seldinger's technique) is a combination of the techniques just described. This technique involves percutaneous insertion of a special

needle into the lumen of a particular vessel (usually the femoral artery, just below the inguinal ring), followed by selective catheterization. The needle, rather than a surgically exposed vessel, serves as the introduction site for the catheter. The needle consists of either two or three parts. It is inserted into the vessel, and physiological saline is injected in the same manner and for the same reasons as described for the standard percutaneous injection. A special, flexible guide wire is then passed through the needle and into the lumen of the vessel. The wire is threaded under fluoroscopic control to the desired position. When it is in place, the needle is removed and a long, thin-walled catheter is passed over the guide wire through the puncture site and into the lumen of the vessel. From there it is threaded again under fluoroscopic control to the desired position. The guide wire is then removed, and the position of the catheter is fluoroscopically rechecked. Heparinized saline (a solution of heparin, an anticoagulant, and physiological saline) is usually injected by hand to preclude obstruction of the catheter tip because of the blood clotting. Injection of contrast material is made either by hand or by automatic pressure injector. Percutaneous-selective catheterization is widely used for abdominal arteriography and aortography.

#### Exercises (646):

- 1 Match the method for introducing angiographic contrast media in column B with the appropriate statement in column A. Each column B item may be used once or more than once. Also, more than one column B item may match a single column A item.

<i>Column A</i>	<i>Column B</i>
_____ (1) Uses a catheter	a Percutaneous injection
_____ (2) Catheter is passed over a guide wire	b Selective catheterization
_____ (3) Injection is usually by hand	c Percutaneous-selective catheterization
_____ (4) Automatic injection is more often used	
_____ (5) The catheter may be sutured in position	
_____ (6) Contrast medium is injected through a needle	
_____ (7) A needle is introduced into a blood vessel	
_____ (8) Injection can be by hand or by an automatic injection	
_____ (9) Generally used for peripheral angiography	
_____ (10) Includes a surgical cutdown	
_____ (11) Guide wire is removed from within the catheter	

### 4-3. Angiographic Equipment

Automatic film changers and pressure injectors are two special equipment items that are used in angiographic studies. In this section we will look at characteristics of these units.

#### 647. Compare advantages and disadvantages of the three types of automatic film changers.

**Automatic Film Changers.** Most angiographic examinations require radiographs made with an automatic film changer. Conceivably, cine or video tape systems could perform the same function of recording several "pictures" per second of contrast-filled vessels, but neither of these systems reproduces the fine detail needed for these studies.

Several types of automatic film changers are on the commercial market and found in Air Force hospitals. Basically, they can be broken down into three categories: (1) the cassette changer, (2) the roll-film changer, and (3) the cut-film changer.

**Cassette changer.** Historically, the cassette changer was the first automatic changer to receive extended use in angiography, and it is still used for some angiograms with excellent results. One of the problems encountered with a cassette changer is that it is not as reliable mechanically as the other two types. There is a tendency for the unit to jam, especially after the cassettes are used repeatedly and have become worn or damaged. Another problem is that it cannot achieve the rapid change rate that can be achieved by others. The relatively slow rate limits the use of this type of changer to angiograms that do not require several film exposures or pictures per second.

Another significant problem encountered with a cassette changer, as opposed to roll- or cut-film changers, is that due to the weight of the cassettes as they are transferred from one point to another, the unit has a tendency to vibrate. Obviously, this vibration can cause slight movement of the patient and result in motion on the radiographs. As a rule, the motion is most striking on a projection, such as the AP skull, where the part is relatively unstable. If vibration of your cassette changer results in part motion, you should use an extension hand on the X-ray table to support the head instead of resting the head directly on the changer.

**Roll-film changer.** The roll-film changer is somewhat of an improvement over the cassette changer in that more radiographs can be made per unit of time. This improvement results from the fact that mechanical movement of film on a roll is easier to do than that of cassettes. This type of changer is more reliable mechanically than other types. The fact that the film is rolled, however, does not lend itself to the economical use of film. Between examinations, a new leader must be inserted into the receiving magazine, which results in wasted film. Also, the end of a roll may have to be discarded if it is not long enough to accommodate the next examination, resulting in a further waste of film. The roll film changer does not experience the vibration of a cassette changer.

**Cut-film changer.** The cut-film changer solves some of the problems of both the other types of changers. Single sheets of film are advanced instead of cassettes or a roll. This type of changer can produce more films per unit of time. It can also reduce film waste and vibration, the latter caused by the movement of heavy cassettes.

fluoroscopically monitored simultaneously with the filming. Not only does this allow the physician to monitor the area with television but it also allows the injection to be recorded on video tape. The advantage of the video tape recording is that the tape can be played back immediately, enabling the radiologist to quickly determine whether or not the examination is successful. Otherwise, the radiologist must wait until the "changer" radiographs are processed.

**Exercises (647):**

1. Match the type of film changer in column B with the appropriate description in column A. Each column B item may be used once or more than once. Also, more than one column B item may match a single column A item.

**Exercises (648):**

1. What are the advantages of a see-through film changer?

Column A	Column B
_____ (1) Has a tendency to vibrate	a Cassette changer
_____ (2) Has slowest filming rate	b Roll-film changer
_____ (3) Wastes film	c Cut-film changer
_____ (4) Least reliable mechanically	
_____ (5) Has high filming rate with little film waste	
_____ (6) Little vibration	

**649. Identify characteristics of the major parts of a film changer.**

**Film-Changer Parts.** Film changers, either roll or cut film (figs. 4-10 and 4-11), are generally considered to have four major parts: (1) changer and mounting stand assembly, (2) supply magazine, (3) receiving magazine, and (4) program selector.

**Changer and mounting stand assembly.** The mounting stand assembly is the support for the changer. Some are simple with manual adjustments to raise or lower the unit, while others use electrical drives for adjustment. Also, some can be used in only one axis, either vertical or horizontal, while others can be used in either axis. There is also some sort of floor-anchoring device to reduce vibration

**648. State the advantages of a see-through film changer.**

One recent improvement in automatic film changers is the see-through changer. This improvement allows the use of an image tube positioned so the area can be

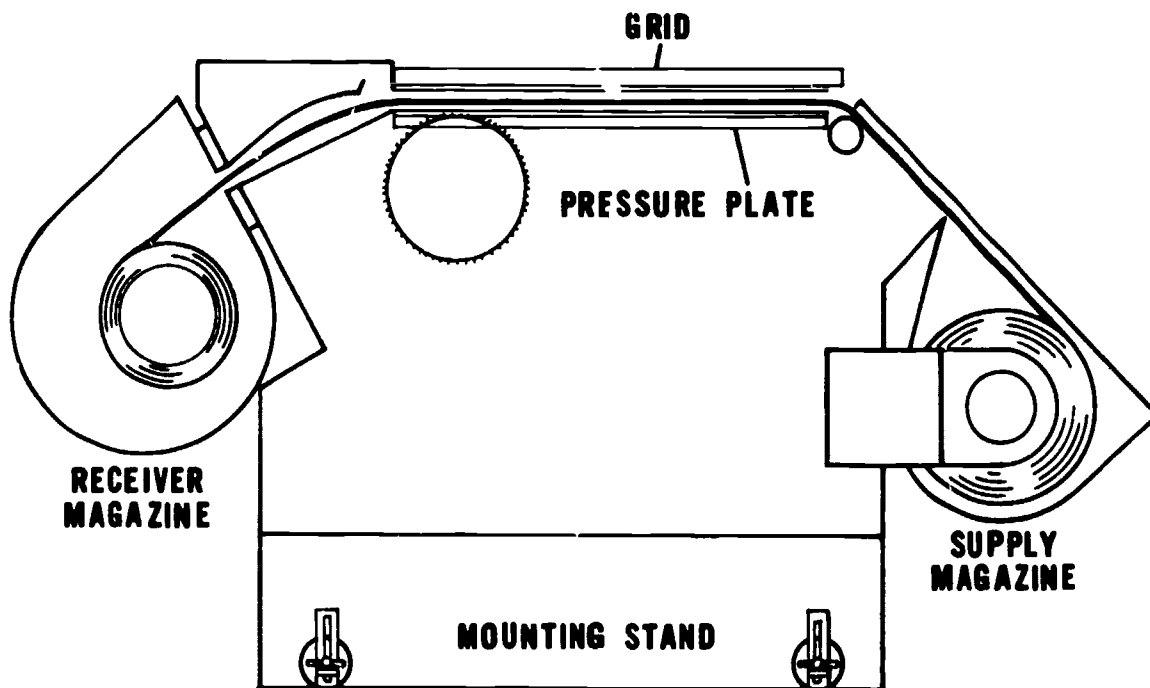


Figure 4-10 Roll-film changer depicting major parts

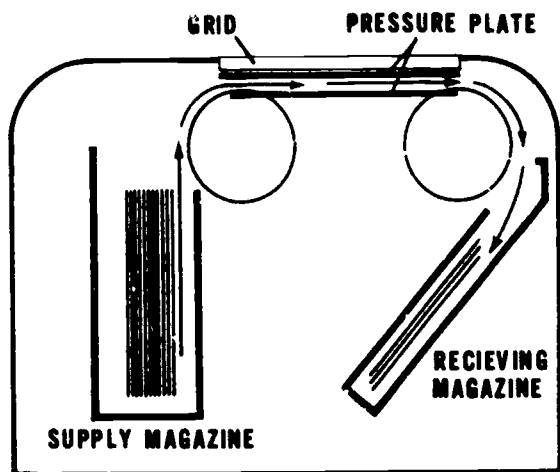


Figure 4-11 Cut-film changer depicting major parts

during exposure. The changer consists of a series of gears and chains to advance the film. Some changers are limited to the size film produced or accommodated. Roll film changers usually advance the film in 11-inch increments. Cut film changers can transport single sheets from 5 x 7 inches to 14 x 14 inches. Film changers are supplied with two intensifying screens. They can be slow-, par-, or hi-speed screens. As with the screens mounted in regular cassettes, they should be cleaned periodically. Grids of varying ratios are available with each type changer. Usually the grid mount is considered to be universal, which means any standard grid can be used. The pressure plate provides the screen-film contact necessary for quality radiographs.

**Supply magazine.** The supply magazine is a light-tight container that holds the unexposed film. It is detachable so it can be taken to the darkroom for loading.

**Receiving magazine.** The receiving magazine receives the exposed film. It is also detachable so it can be taken to the darkroom. Be careful in handling either the supply or receiving magazine as light leaks can develop.

**Program selector.** The program selector can be considered the heart of a film changer. It establishes the number of films per second (or per unit of time) along with the duration of each phase. The programmer can be linked to a pressure injector and X-ray generator. When connected in such a manner, it can initiate the injection, film changer, and exposure. Programmers can also be programmed to control single-plane or biplane changers.

#### Exercises (649):

Answer the following true or false. If you indicate false, explain your answer.

- \_\_\_\_\_ 1 Only par-speed screens are used with film changers

- \_\_\_\_\_ 2 Grids of varying ratios are available with film changers

- \_\_\_\_\_ 3 Mounting stands can only be used in the horizontal position

- \_\_\_\_\_ 4 The pressure plate provides the screen-film contact necessary for quality radiographs

- \_\_\_\_\_ 5 Some film changers are limited to the size film they can accommodate

- \_\_\_\_\_ 6 Supply and receiving magazines should be handled carefully

- \_\_\_\_\_ 7 Programmers can be used to start an injection.

- \_\_\_\_\_ 8 Programmers can only control single-plane studies

#### 650. State advantages and problems pertaining to biplane film changer operation and indicate corrective measures necessary to overcome the problems.

**Biplane Changer Operation.** If two X-ray tubes are used to simultaneously make AP or PA and lateral radiographs, the examination is a biplane study. One obvious advantage of biplane studies is the reduction in the dosage of contrast medium—the patient receives one dose for a biplane study but receives two doses for separate studies. Another advantage, the most significant one, is that the physician can study the structures more accurately if right-angle studies are made simultaneously.

One of the major problems you will encounter during a biplane examination is the presence of scatter radiation causing film fog. Since you have two X-ray beams exposing the patient, scatter radiation is approximately twice normal. One solution to this problem of excessive scatter is to use two crossed grids (described in Volume 1). At times, however, you cannot use two crossed grids. For example, if one of the two projections, such as the AP cerebral angiogram, requires an angled C.R., you cannot use a crossed grid due to the absorption of primary radiation.

Even though you use two crossed grids and collimate properly, film fog will be slightly more evident than during single-plane operation. Consequently, the exposure you use for a biplane projection should be slightly less than that used for the same projection during a single-plane study. The reduced exposure is necessary to maintain the same film density from one examination to the next. Consequently, you will have to use a linear grid for the AP. You can use a crossed grid for the lateral in this case because the C.R. is perpendicular to the grid. Precise collimation of both beams to the parts under study is absolutely necessary during biplane operation to reduce the scatter radiation.

Another problem sometimes encountered with a biplane cerebral angiogram is the loss of detail due to the large part-film distance on the lateral. Depending on the type of changer you have, you may not be able to achieve close contact between the side of the patient's head and the changer. This condition results in some detail loss—the amount depending upon the part-film distance present. To compensate for the increase in part-film distance, increase the FFD—perhaps to 72 inches—if the part-film distance is considerable.

#### Exercises (650):

1. What are two advantages of biplane film changer operation?
2. List two problems encountered during biplane filming. In each case, indicate how the problems can be overcome.

#### 651. Identify major parts and operating characteristics of a pressure injector.

**Features and Operation of Pressure Injectors.** Pressure injectors are devices that introduce large amounts (up to 150 cc) of contrast material into the circulatory system under pressure. While several different models are available, all have certain components in common. Each has a syringe, a heating device, and a pressure mechanism. The syringes are available in different sizes, ranging from 20 cc to 150 cc. Some units use syringes that can be disassembled and sterilized, while others use disposable syringes. (NOTE: the disposable syringes you use daily for IVPs, IVCs, etc., are not to be used in a pressure injector. Assuming the syringe would fit the unit (which is improbable), it would probably burst under the pressure used for a particular study.)

The heating system heats and maintains the contrast material at or near body temperature. This reduces the viscosity of the material, facilitating the setting of certain flowrates. The heating device is normally located on the injector head, and the syringe fits into it. The temperature is

thermostatically controlled and is usually preset by the manufacturer.

The two types of pressure mechanisms used for pressure injectors are electromechanical and compressed air. An electromechanical injector consists of an electric drive motor connected to a shaft that drives the piston of the syringe either in or out. Compressed-air injectors usually use carbon dioxide (CO<sub>2</sub>) to drive the piston. Pressure is regulated through a series of valves and the settings read from a gauge. Prior to the injection, the reading should be double-checked. After the procedure is complete, release the pressure to avoid damaging the injector.

#### Exercises (651):

Answer the following either true (T) or false (F). If you indicate false, explain your answer.

1. Components common to all pressure injectors are a syringe, a heating device, and a pressure mechanism.
2. Disposable syringes commonly found in the hospital can be used in pressure injectors.
3. The heating system is designed to maintain contrast material at or near body temperature.
4. Compressed-air injectors usually use carbon dioxide to drive a piston.
5. Double-checking the pressure settings prior to injection is recommended to avoid damaging the injector.

#### 652. Explain the terms "flowrate," "constant flowrate," and "constant pressure" as they apply to the operation of a pressure injector.

**Types of Pressure Injectors—Based on Flowrate.** There are basically two types of pressure injectors: constant-flowrate and constant-pressure injectors. Before discussing them, we will define flowrate. Flowrate is the amount of contrast material delivered per unit of time. It depends on the viscosity of the contrast material, injection pressure, and length and diameter of the catheter. Flowrate for a given procedure is dependent on the vessel entered, the patient, and the nature of the disease. Flowrates are given in so many cubic centimeters per second—for example, 10 cc.

**Constant-flowrate injector.** A constant-flowrate injector maintains a selected flowrate regardless of the variables (catheter length, diameter, etc.) and automatically adjusts the applied pressure. For example, if a flowrate of 25 cc and a volume of 100 cc is required, you program the injector to deliver the 100 cc in 4 seconds. When using this type injector, care must be taken to avoid excessive flowrates that can injure the patient or burst the catheter. There are several charts available that give safe parameters. These charts essentially instruct you on what flowrate you can safely set (for a new catheter), taking into account the variables such as catheter length, diameter, and the viscosity of the contrast material.

**Constant-pressure injector.** A constant-pressure injector will maintain a selected pressure; however, the flowrate will vary. The flowrate is affected by catheter length, diameter, contrast material viscosity, and catheter side holes. Shorter catheters have a higher flowrate. A large-diameter catheter will have a higher flowrate. A relatively thick contrast material will reduce the flowrate. Placing side holes in the catheter to reduce back pressure will result in a higher flowrate. Again, charts are to be consulted for these various parameters.

#### Exercises (652):

1. Define the term "flowrate"
2. How does a constant-flowrate injector maintain a selected flowrate?
3. What precaution should be taken when using a constant-flowrate injector?
4. How does a constant-pressure injector maintain a selected pressure?

#### 653. State the significance of the R-wave as it pertains to a pressure injector.

Some circulatory studies require phased injections. In such cases ECG triggering is used. Some pressure injectors are available with an electrocardiogram (ECG) triggering device that can be synchronized with the impulses of the heart. A detailed explanation of electrocardiograms is beyond the scope of this CDC. However, there are some terms you should be familiar with.

The electrocardiogram (ECG, German spelling: EKG) is a recording of the changing electrical fields in the tissues of the heart. It is not a recording of heart strength or sound.

Specifically, the ECG records the amount of voltage generated by the heart and the time it takes for the voltage to travel through the heart. When this voltage, represented on a vertical scale (fig. 4-12), is compared with time on the horizontal scale, the result is the peak-and-valley pattern of an ECG. This pattern is described with letters and as a combination of these letters. The letters are not abbreviations but were arbitrarily chosen by the medical profession.

The heart is in millisecond phases of systole or diastole during this period. The R-wave, since it is the strongest wave, is easily detected by the ECG of the injector and is used as a reference point. Certain studies are injected at different phases of the heart. For example, in coronary arteriography, the injection is made during a period of relative stillness of the heart, which is diastole. Were the injection made during systole, the blood being pumped out of the heart would excessively dilute the contrast material being injected. Therefore, for optimum visualization, the heart would be monitored to determine the diastolic period, and the ECG triggering device would be adjusted to coincide with this period.

#### Exercises (653):

1. What is the significance of the R-wave as it pertains to a pressure injector?

#### 654. Point out hazards, precautions, and safety devices incorporated in pressure injectors.

Pressure injectors incorporate several safety features, depending on the unit. Two of primary concern are pressure-limiting devices and electric-monitoring alarms.

As we discussed earlier, flowrate is dependent on several variables. We also mentioned using various charts for selecting flowrates or pressures that take these variables into account. Even so, during the course of study, unexpected problems with the equipment, a catheter, the

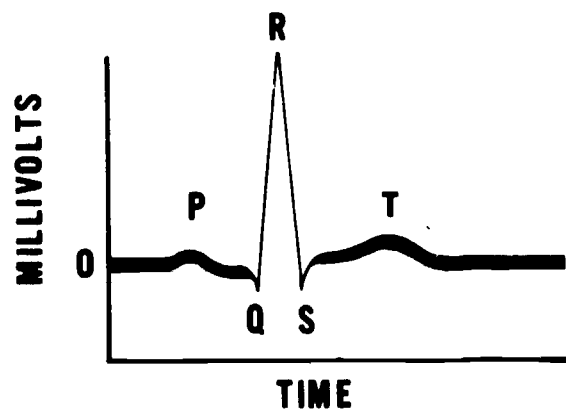


Figure 4-12 Basic electrocardiogram

injector itself, or the patient can arise. Therefore, injectors have built-in, pressure-limiting devices. These devices set a maximum on the pressure or flowrate that can be generated in case a problem occurs. Their proper use depends on your being completely familiar with the operating instructions of your unit.

In Volume 1 we discussed electrical hazards common to a radiology department. In particular, we discussed problems that may arise when a patient is connected to a pressure injector. Because of its importance, we review the particulars here. When an injector is connected to a catheter, which is inserted into the blood stream, it only takes approximately 1/1000th of the lethal skin current to produce ventricular fibrillation. Most injectors today use isolated electrical transformers, nonconductive syringes, and drive pistons to eliminate an electrical current path. Even so, problems can still arise. Therefore, many units incorporate sensing circuitry to detect if an unsafe ground condition exists. If an unsafe condition does exist, either an alarm will go off or the unit will not operate. Rather than relying on an alarm system, all manufacturers stress the

importance of proper grounding. You must ensure that the injector, X-ray table, and any other electrical appliances in the room are grounded to the same ground potential, as illustrated in figure 4-13. This reduces the possibility of the patient being electrocuted and other dangers of an electrical nature.

**Exercises (654):**

1. What is the purpose of a pressure-limiting device on a pressure injector?
2. Describe the electrical hazard present when a pressure injector is used and give the necessary precaution.

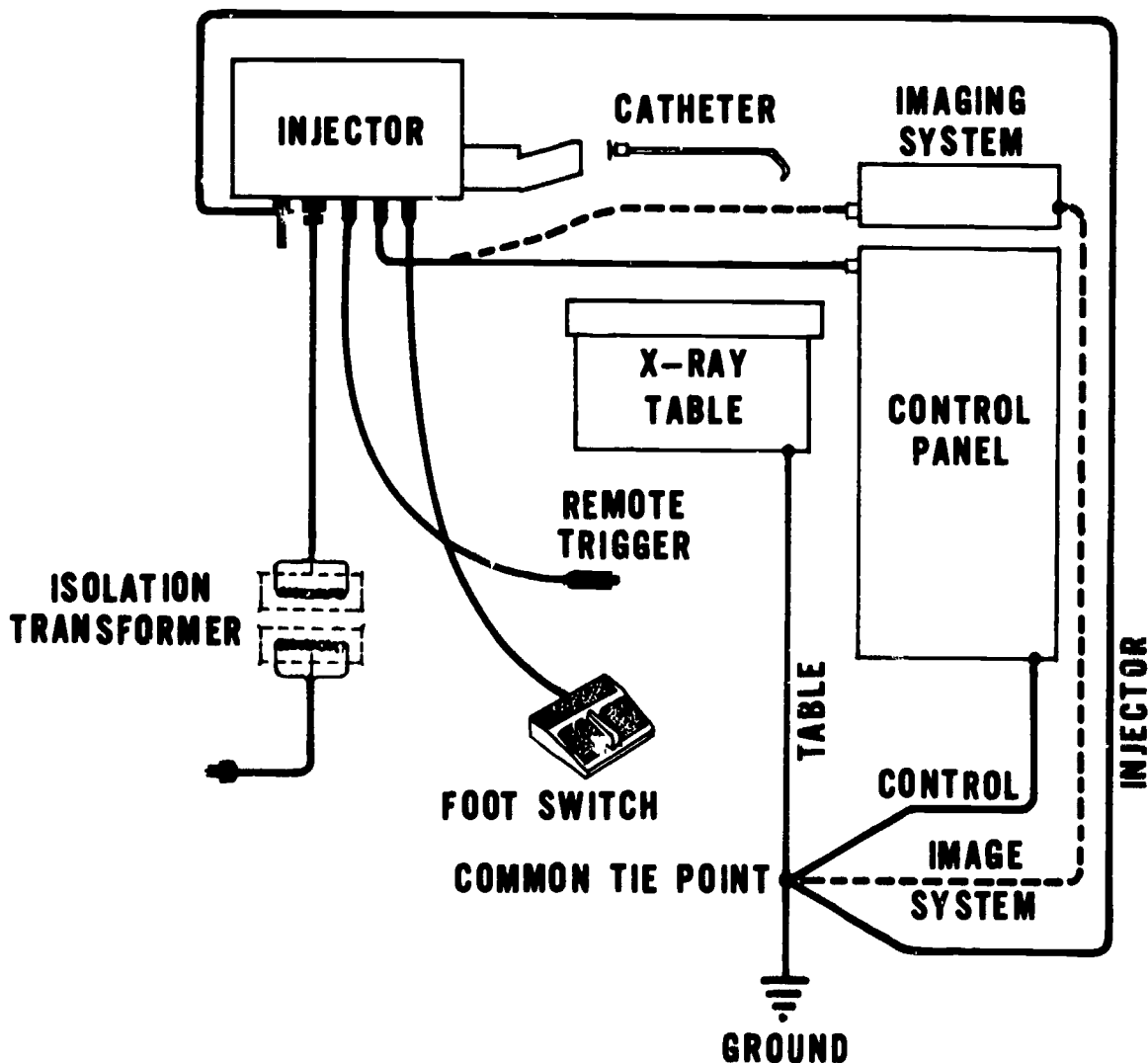


Figure 4-13 Common ground connection



## Contrast Studies of the Nervous System

ALL OF OUR specialized senses (sight, hearing, smell, taste, and touch), as well as our organic functions (respiration, circulation, digestion, etc.), are governed by a complex neural network which is referred to as the nervous system. Actually, this network is comprised of two major components, the central and the peripheral nervous systems. The latter is further divided to include the autonomic nervous systems. However, since we are concerned only with the central system, this portion of our discussion is limited to central nervous system (CNS) structures; for example, the brain, spinal cord, meninges, and the ventricular system. The brain is encased by the cranial bones, and the spinal cord is surrounded by the bony structures of the vertebral column. Further protection is afforded by three layers of membranous tissue—the meninges—which completely invest both the brain and the cord. The cerebrospinal fluid flows through this closed and continuous system to cushion the brain in its solid vault. In order to examine each section of the system in more detail, we consider them separately and in conjunction with the radiographic procedures used to visualize them. We begin with a study of the myelogram.

### 5-1. Anatomic and Radiographic Considerations of the Spinal Cord

As you know, the special radiographic procedure employed to demonstrate abnormalities of the spinal cord is referred to as a myelogram. Essentially, the procedure involves introduction of a contrast material into the spinal portion of the subarachnoid space. This injection is followed by fluoroscopic observation and radiographic recording of the contrast media flow around the spinal cord.

#### 655. Identify anatomical characteristics of the human spinal cord.

**Anatomic Considerations.** The spinal cord is the longest and most inferiorly situated portion of the CNS. Essentially, it provides a means of communication between the brain and the nerve fibers connecting to the various parts of the body.

**External structure of the spinal cord.** As you can see in figure 5-1, the spinal cord is an extension of the brain stem. It joins the medulla oblongata in the region of the first cervical vertebra and then descends through the spinal canal to about the level of the first or second lumbar vertebra. The

cord is approximately 42 to 45 centimeters long, is about 1 centimeter in diameter, and is roughly cylindrical. It terminates in a sharply constricted cone called the *conus medullaris*. The *filum terminale*, a slender filament, extends from the apex of the conus to the first coccygeal segment where it is attached to the osseous tissue of the vertebral column.

The anterior, or ventral surface of the cord, is scored by a relatively deep fissure. This centrally situated depression is called the *ventral median fissure*. The posterior, or dorsal surface, is scored by a similar but much shallower depression called the *dorsal median sulcus*. These major depressions divide the cord into lateral halves. Each half is further scored by two shallow furrows referred to as the *dorsal lateral sulcus* and *ventral lateral sulcus* respectively. Figure 5-2 illustrates the location of these grooves. The dorsal nerve roots pass through the dorsal lateral sulci and provide the posterior connection between the spinal nerve and the central portion of the cord. The ventral nerve roots pass through the ventral lateral sulci and serve to connect the anterior portion of the central part of the cord with the spinal nerve. Figure 5-3 illustrates the appearance of the nerve roots emanating from their respective sulci and joining to form the spinal nerves.

The spinal cord gives off 31 pairs of spinal nerves. As you can see in figure 5-1, the cervical and thoracic nerves exit transversely from the cord, and those on the lumbar region descend almost vertically from the conus medullaris. Thus, the lumbar and sacral nerves descend individually from the conus to their respective points. This region, which extends from about the second lumbar vertebra to the second sacral segment, is referred to as the *cauda equina*, which means "horses tail." It is so named because the vertically situated lumbar and sacral nerves resemble the coarse hair in the tail of a horse. The spinal cord and cauda equina are completely invested by three layers of membranous tissue that we will discuss later in this chapter.

**Internal structure of the spinal cord.** Generally speaking, the inner portion of the spinal cord is comprised of an H-shaped column of gray matter and fiber tracts of white matter shown by the dark-shaded H and the lighter shaded material in figure 5-2. The gray matter forms the core of the cord and is surrounded by the white matter. Both types of tissue are continuous with that of the medulla oblongata. The cross section through the cord shows the structural relationship between the core and its surrounding tissue.

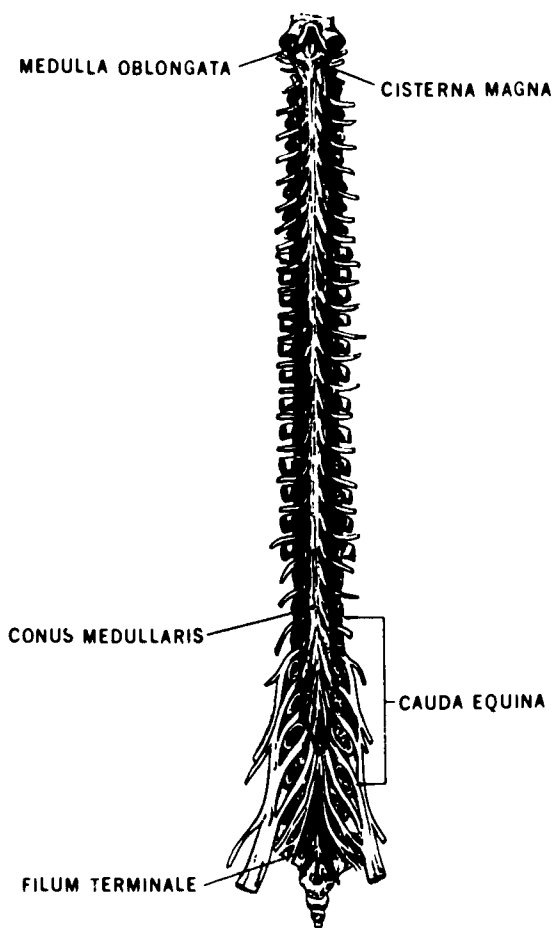


Figure 5-1 The spinal cord

- 2 The spinal cord is about \_\_\_\_\_ to \_\_\_\_\_ cm long and about \_\_\_\_\_ cm in diameter
- 3 The end of the spinal cord is called the conus \_\_\_\_\_
- 4 The spinal cord is divided into lateral halves by the \_\_\_\_\_ fissure and the \_\_\_\_\_ sulcus.
- 5 A dorsal nerve root connects the \_\_\_\_\_ to the center of the spinal cord
- 6 The \_\_\_\_\_ root connects the spinal nerve to the anterior portion of the spinal cord
- 7 There are \_\_\_\_\_ of spinal nerves given off by the spinal cord.
- 8 The \_\_\_\_\_ is the region extending from about the second lumbar to the second sacral vertebra containing the vertically situated nerves.

**Exercises (655):**

Select the terms which complete the following statements. Each answer set is used only once.

- 31 pairs
- Spinal nerve
- Medullaris
- Cauda equina
- Ventral nerve
- First cervical
- 42; 45; 1
- Ventral median; dorsal medial
- Gray matter; white matter

1. The spinal cord connects with the medulla oblongata near the \_\_\_\_\_ vertebra.

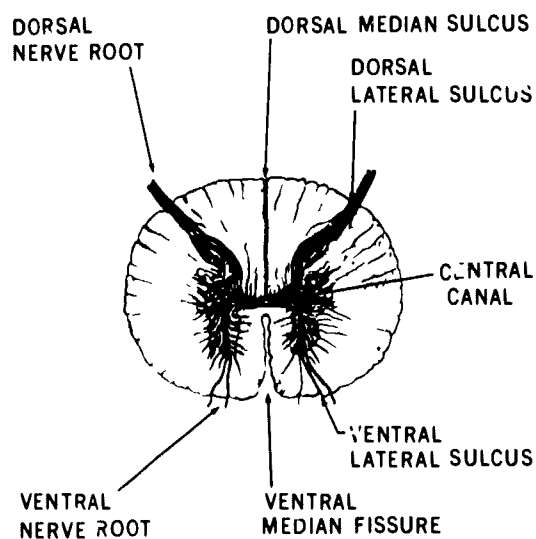


Figure 5-2 The dorsal and ventral sulci (cross section of spinal cord)

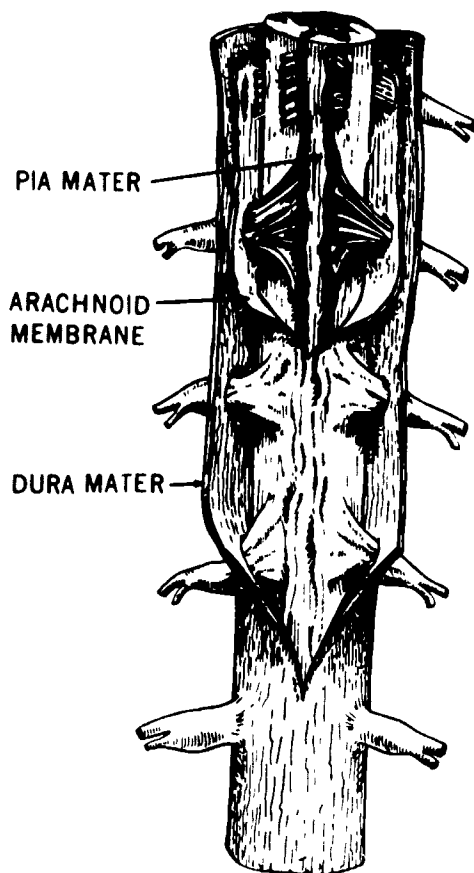


Figure 5-3 The nerve roots emanating from their sulci:

9. Two types of tissue found in the spinal cord continuous with that of the medulla oblongata are the inner \_\_\_\_\_ and the outer \_\_\_\_\_.

**656. Specify procedures pertaining to the patient's position while contrast medium is introduced into the subarachnoid space of the spinal cord.**

**Radiographic Considerations.** Basically, the myelogram consists of the radiologist introducing the contrast medium into the subarachnoid space, followed by fluoroscopy and spot films. After that you usually will be required to take some postfluoro radiographs, after which time the radiologist removes as much of the contrast material as possible. Your role generally consists of assisting the radiologist as needed and, as we mentioned, making some radiographs.

**Positioning the patient for lumbar puncture.** The contrast medium is usually injected into the subarachnoid space of the spinal cord by means of a lumbar puncture. (Another injection site, which we discuss later, is occasionally used. Position the patient for the lumbar

puncture on the X-ray table in the prone or lateral recumbent position. Attach the headboard and footrest to the table because the table is tilted in both directions throughout the examination to allow the contrast material to gravitate to specific areas.

If the injection is to be done with the patient prone, place a rolled pillow under the patient's lower abdomen to straighten the lumbar lordosis. This widens the space between the spinous processes, making the puncture easier. If the injection is to be made in the lateral recumbent position, place enough suitable material under the patient's lower thoracic and upper lumbar spines to place the spine parallel with the table. Also, have the patient flex his or her spine by drawing the knees up toward the chin and drawing the head and shoulders forward (the fetal position). These actions aid in locating the injection site for making the lumbar puncture.

**Positioning the patient for the cisternal puncture.** The contrast medium is rarely injected into the cisternal magna, the widest portion of the subarachnoid space, located in the upper cervical region between the base of the cerebellum and the medulla oblongata. Called a cisternal or cervical puncture, the procedure is somewhat dangerous and only used when the subarachnoid space is obstructed, preventing flow of the lumbar-injected medium to the upper spine. For the cisternal puncture, place the patient in the lateral recumbent position. Elevate the patient's head to place the cervical spine parallel with the table. Initially, until the injection is completed and the needle withdrawn, the patient's head is flexed and the head end of the table is elevated. Immediately after injection, the head is hyperextended and usually held in place by another physician to prevent the contrast medium from entering into the ventricular system of the brain. Contrast material in the ventricles can lead to severe complications, and, in rare instances, they can be fatal. However, two of the more common reasons for hyperextending the patient's head are: (1) to reduce the chance of a severe headache and (2) to make removal of the contrast material easier.

#### Exercises (656):

1. What two basic body positions are used for a lumbar puncture?
2. With which of the positions indicated in exercise number 1 should you attach the footrest and headboard?
3. Why should you elevate the patient's lower abdomen for a prone lumbar puncture?

4. Why should the lower thoracic and upper lumbar vertebrae be elevated for a lateral lumbar puncture?

5. Describe the fetal position

6. When is the cisternal puncture used in place of the lumbar puncture?

7. What basic body position is used for the cisternal puncture?

8. What is the position of the patient's head and the table during a cisternal puncture injection?

9. Why is the patient's head hyperextended immediately after the cisternal injection is completed?

**657. Describe the intraspinal pressure test using a manometer and the Queckenstedt sign.**

**Spinal tests.** At times, the radiologist elects to check the amount of fluid pressure within the subarachnoid space before injecting the contrast material. Consequently, you should always have a Rubin's manometer available. The radiologist simply connects this device to the stopcock and allows cerebrospinal fluid (CSF) to flow into the calibrated glass tube. The height to which the fluid rises indicates the amount of pressure within the subarachnoid space.

Also, the radiologist can look for the Queckenstedt sign that indicates whether or not there is an obstruction or block in the vertebral canal. For this procedure the radiologist needs your assistance. He or she will ask you to compress the jugular veins of the neck on one or both sides and release the pressure upon a signal. Your radiologist will demonstrate the exact compression site and procedure. Sometimes when the veins are compressed, the pressure of the cerebrospinal fluid rises quickly if there is no obstruction. When the pressure is released, the pressure also drops quickly. If an obstruction is present, the pressure usually is not affected by the compression or release of the compression.

**Exercises (657):**

1. Briefly describe the test for intraspinal pressure using a Rubin's manometer.

2. Explain the Queckenstedt sign

**658. Explain precautions pertaining to myelography and how procedures differ depending upon the type of medium used.**

**Injection of the Contrast Medium and Fluoroscopy.**

Once the preliminary procedures are over, the radiologist injects the contrast medium into the subarachnoid space. Recent advancements with myelographic contrast media have introduced a water-soluble radiopaque, Amipaque, that can be used instead of the oily and viscous medium, Pantopaque, which has been used in myelography for many years. The major advantage of using a myelographic water-soluble medium is that the injection needle can be immediately withdrawn from the subarachnoid space after the medium is introduced. This new medium is quickly absorbed and does not need to be removed, as is the case with the oily, viscous medium. Depending upon the type of contrast medium used, there are minor differences in the postinjection procedures.

**Procedures when using an oily, viscous medium.**

Immediately after the introduction of the oily, viscous medium, the radiologist replaces the stylette in the needle and covers the needle with a sterile dressing. The needle is left in place so that the contrast material can be removed when the examination is over. As indicated before, during a cisternal puncture the needle is removed after injection of the medium. In this case, the medium is removed through a second puncture.

If the upper thoracic or cervical spinal canals are examined, an additional technician may be required to maintain the patient's head in an elevated and hyperextended position during fluoroscopy and until the medium is removed. Also, the patient's head must not be permitted to drop below the level of the spine. As indicated earlier, this is to prevent the contrast medium from entering the ventricles of the brain.

The patient is usually placed in the prone position for fluoroscopy, leaving the protruding needle between the patient's spine and the fluoroscopic apparatus. At this time, you must lock the vertical adjustment of the fluoroscopic unit in place so that it cannot be accidentally lowered to contact the needle. This event could result in the needle being driven into the spinal nerves, causing permanent paralysis of a portion of the patient's lower anatomy. Of course, your radiologist is also aware of the dangers involved with the protruding needle. However, because of the possible consequence, if both you and your radiologist

double-check each other, the chance of farther insertion of the needle is minimized.

The fluoroscopic apparatus can be positively secured to prevent accidental contact with the needle by means of a commercial myelographic stop made especially to be used with certain X-ray machines. It is simply a metal bar which attaches to the fluoroscopic unit and maintains a certain amount of space between the unit and tabletop. This is the best method to use because it does not rely on a "lock" that can become defective.

*Postfluoro projections.* When the radiologist terminates the fluoroscopy, he or she will more than likely require you to perform certain radiographs. There are two important factors to keep in mind while performing the radiographs. The first is that the needle is still present in the patient's back and must be prevented from contacting anything. The second is that the patient's head must not be permitted to drop below the level of the spine. If the contrast medium is in the thoracic or cervical spines, the hyperextension of the head must also be maintained.

The specific projection you make will depend upon your radiologist's fluoroscopic findings. However, PA, anterior oblique, and standard or cross-table lateral radiographs can be made. Obviously, you will not perform AP and posterior obliques due to the presence of the needle.

*Procedures when using a water-soluble medium.* A myelographic water-soluble medium, such as Amipaque, has a distinct advantage when compared to an oily, viscous medium. Although its use is rapidly spreading, Amipaque has not completely replaced Pantopaque because, at the time of this writing, Amipaque is not recommended for patients under 12 years old. However, it is often used on adult patients.

Basic preparation and injection procedures are still similar; it is immediately after completion of the injection that some steps differ. First, as you noted earlier, the injection needle is removed. The needle is not needed to aspirate the medium back into a syringe upon completion of filming procedures because, as we stated before, the medium is quickly diffused within the CSF and absorbed into the bloodstream. Following the injection, conventional radiography will continue to provide good diagnostic contrast for at least 30 minutes. At about 1 hour, diagnostic contrast usually will not be available except by computed tomography.

The second major procedural change deals with postfluoro projections. Since the needle is not in the patient's back after injection, AP and posterior obliques may be included if the radiologist desires them. Some radiologists prefer a cross-table lateral and a full routine lumbar series during myelography with Amipaque. Any other particular variations, such as preparation of the solution, are dependent upon the radiologist's preference; thus, you should always follow standard operating procedures of your department when performing this procedure or preparing contrast media.

## Exercises (658):

1. With respect to the patient's head, what precautions may have to be taken throughout the myelogram and why?
2. With respect to the protruding needle when doing a myelogram with an oily, viscous medium, what precautions should be taken and why?
3. What is the major advantage of using a water-soluble medium instead of an oily, viscous medium in myelography?
4. Why is the injection needle removed immediately after the introduction of a water-soluble medium?
5. How do postfluoro projections differ when doing a myelogram with a water-soluble medium as compared to projections during a myelogram injected with an oily, viscous medium?

## 5-2. Anatomic and Radiographic Considerations of the Brain

The brain is the largest and most complex part of the central nervous system. It is encased by the cranial bones and is divided into lobes for anatomical purposes. In this section, we discuss the characteristics of the brain and then consider the applicable radiographic procedures.

### 659. Specify relationships of significant parts of the cerebrum and ventricular system of the brain.

**Anatomic Considerations:** As you can see in figure 5-4, the brain consists of the cerebrum, or forebrain; the midbrain; the cerebellum, or hind brain; and the brain stem. Let's look at them.

*The cerebrum.* The egg-shaped cerebrum is the largest component of the brain. In figure 5-5, it is divided longitudinally by a deep cleft called the *longitudinal fissure*. The two parts are referred to as *hemispheres*. Notice that the surfaces of these hemispheres are comprised of folded ridges (convolutions) called *gyri*. The gyri are separated from each other by shallow furrows called *sulci*. Six of the sulci, three in each hemisphere, are deeper than the others and serve to segment the cerebrum. These segments are referred to as *lobes*. Four of the lobes are

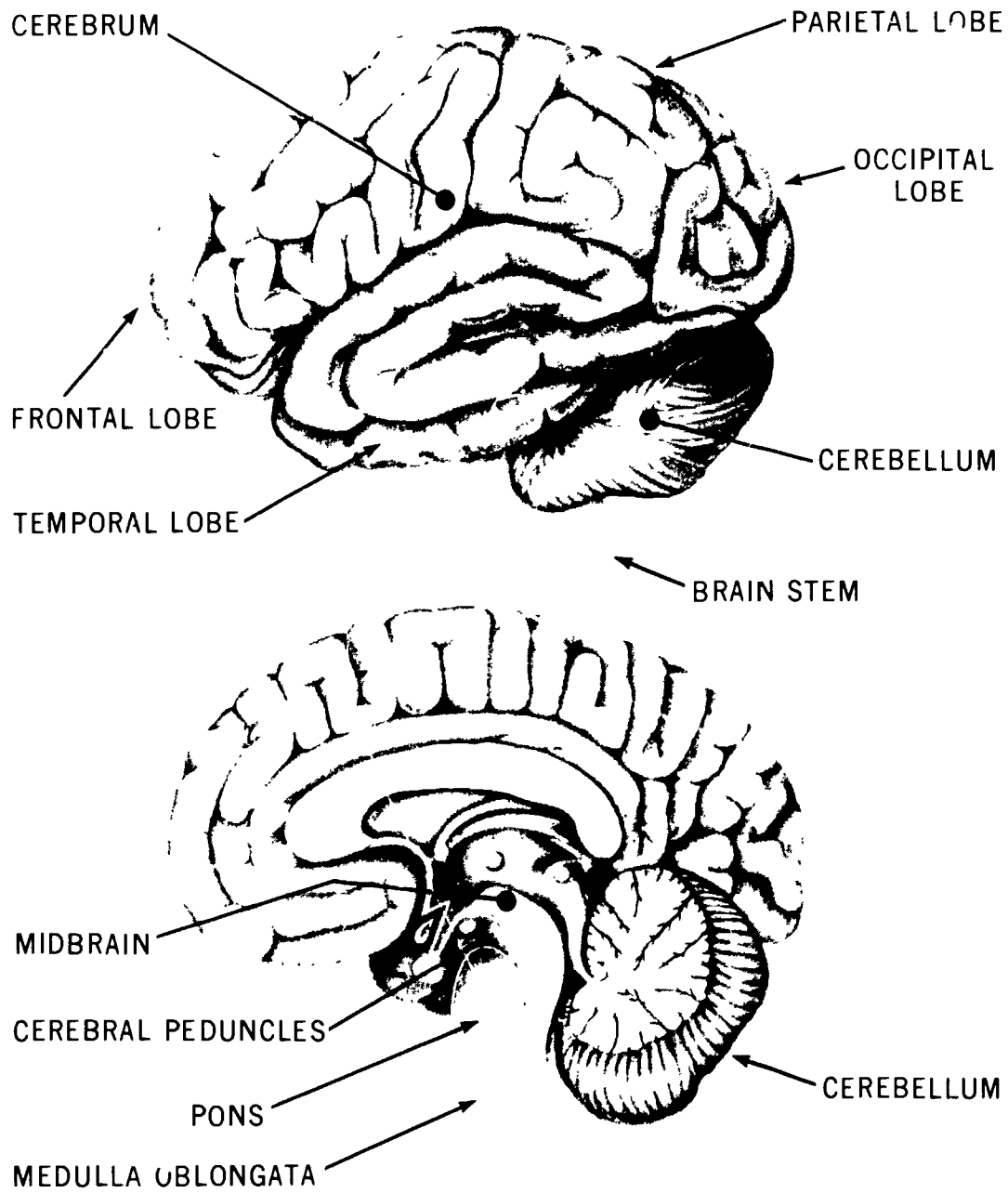


Figure 5-4 The brain

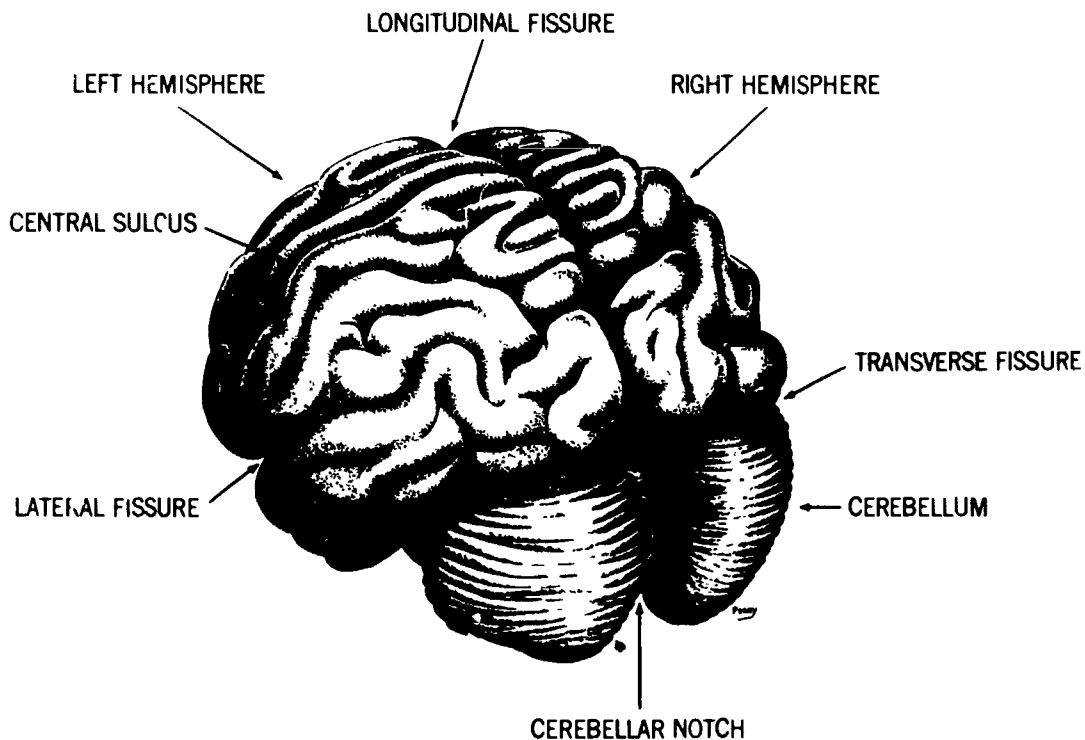


Figure 5-5 Relative positions of brain structures

named for the cranial bones which cover them, while the fifth is called the *insula*.

The convoluted surface of the hemispheres is comprised of gray matter (so-called because of its color). This gray matter spreads over an inner mass of specialized fibrous tissue called white matter (once again, after its color).

**Ventricular system.** The midportion of the cerebrum houses four irregularly shaped, interconnected cavities referred to as ventricles (fig. 5-6). The ventricles are lined with delicate tissues that secrete the lymphlike cerebrospinal fluid that fills the ventricles and the intracranial and spinal portions of the subarachnoid space. Each lateral ventricle (there are two) is comprised of a central portion, or body, and three appendages referred to as the *anterior*, *posterior*, and *inferior horns*. The majority of the body, including the anterior and posterior horns, is situated directly below the corpus callosum. The anterior horn extends into the frontal lobe and the posterior horn into the occipital lobe. Each lateral ventricle communicates with the third ventricle by a channel called the *foramen of Monro*.

The third ventricle is situated in the midline, directly below the medial aspects of the lateral ventricles. It is housed between the masses of the thalamus, and its anterior-inferior portion extends downward through the hypothalamus. The third ventricle consists of a central portion from which irregularly shaped projections extend posteriorly and anteroinferiorly. The posterior portion is situated above the pineal body and, thus, is referred to as

the *suprapineal recess*. The third ventricle communicates with the fourth ventricle through the aqueduct of Sylvius.

The rhomboid, or diamond-shaped fourth ventricle, is a midline structure situated in the space between the cerebellum and the brain stem. Its posterior aspect is formed by the concavity between cerebellar hemispheres. The fourth ventricle is continuous with the central canal of the spinal cord, which is the constricted inferior portion of the cavity. Other than the aqueduct of Sylvius, there are three openings into the fourth ventricle—the *foramen of Magendie* and two *foramina of Luschka*. The ventricle communicates with the cisterna magna through the foramen of Magendie and with the subarachnoid cisterns through the two foramina of Luschka.

**Exercises (659):**

Complete the following statements with the proper term or terms:

1. The largest component of the brain is the \_\_\_\_\_.
2. The cerebrum is divided into \_\_\_\_\_ and \_\_\_\_\_ hemispheres by the \_\_\_\_\_.

3. The folded ridges on the surfaces of the cerebrum are called \_\_\_\_\_
4. The names of the five cerebral lobes are \_\_\_\_\_, \_\_\_\_\_, \_\_\_\_\_, \_\_\_\_\_, and \_\_\_\_\_
5. The outer layer of cerebral tissue is referred to as \_\_\_\_\_
6. Cerebrospinal fluid is secreted by the four \_\_\_\_\_
7. The two large wishbone-shaped ventricles are the \_\_\_\_\_
8. The foramen of Monro connects the \_\_\_\_\_ ventricles to the \_\_\_\_\_ ventricle
9. The posterior portion of the third ventricle is known as the \_\_\_\_\_
10. The fourth ventricle communicates with the third ventricle by the way of the \_\_\_\_\_
11. The fourth ventricle communicates with the cisternal magna by way of the \_\_\_\_\_

**660. Name, locate, and cite functions of significant structures of the cerebellum and brain stem.**

**The cerebellum.** The cerebellum, second largest component of the brain, is situated beneath the posterior aspect of the cerebrum (the occipital lobe). The cerebellum is comprised of a central stalk, called the *vermis*, and two hemispheres. The hemispheres are separated from the cerebrum by a deep cleft, called the *transverse fissure*. Their superior aspects are also separated from each other by a shallower vertical cleft referred to as the cerebellar notch.

**The brain stem.** The midbrain, pons, and medulla oblongata are referred to as the brain stem. In figure 5-4, these structures are united and are situated anterior to the cerebellum (The medulla oblongata is actually continuous with the spinal cord, but for our purposes, we consider these structures as separate entities.)

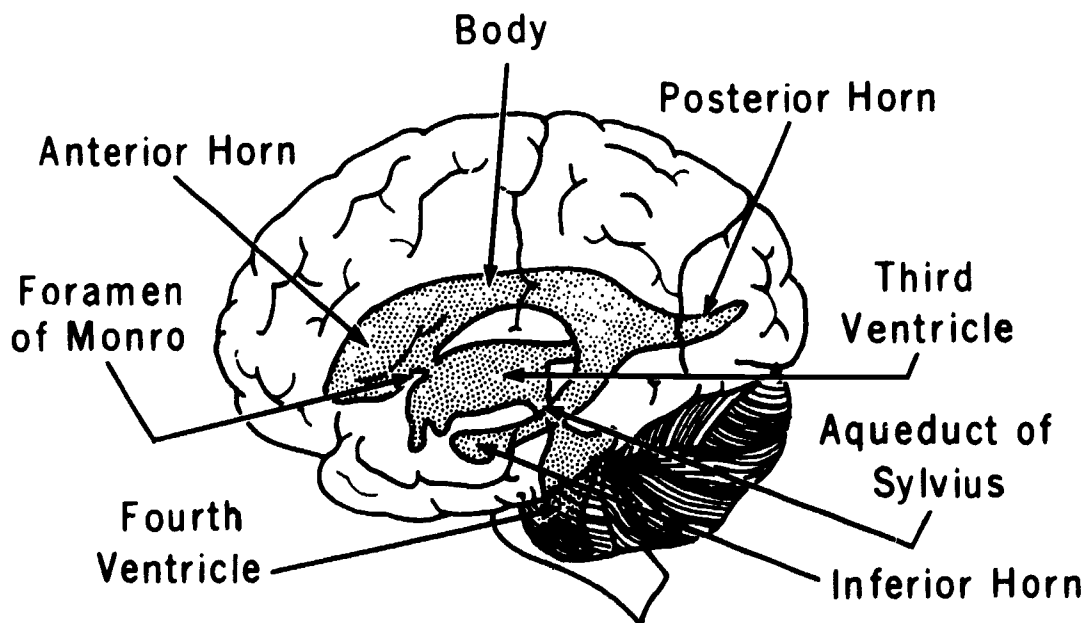


Figure 5-6 Ventricles of the brain



The midbrain is a short, constricted segment connecting the pons and cerebellum with the cerebrum. The *cerebral peduncles* carry impulses between the cerebrum and spinal cord.

The pons (see fig. 5-4) is a large bulbous mass of fiber tracts situated below the midbrain, anterior to the cerebellum, and superior to the medulla oblongata. It is comprised primarily of white matter, although it does house the nuclei of four cranial nerves in its central portion.

The medulla oblongata (see fig. 5-4), often referred to as the bulb, is actually an enlarged area of the spinal cord. It is situated below the pons and just above the foramen magnum. The anterior surface of the medulla oblongata is comprised of two bundles of fibers called the *pyramids*. The posterior aspects of the medulla houses two major nuclei that receive the fibers from the white columns of the spinal cord below and the thalamus and cerebellum above.

#### Exercises (660):

1. Where is the cerebellum located with respect to the cerebrum?
2. What are the names of the three basic parts of the cerebellum?
3. What are the three parts of the brain stem?
4. What parts of the midbrain carry impulses between the spinal cord and cerebrum?
5. Where is the medulla oblongata located?
6. What are the pyramids?

#### 661. Identify and locate the anatomical structures or parts of the meninges and subarachnoid space.

**The meninges.** The brain and spinal cord are completely covered by three layers of membranous tissue that are referred to collectively as the meninges. They are comprised of the pia mater, arachnoid membrane, and the dura mater.

The *pia mater* is the innermost portion of the meninges. It is a highly vascular membrane that very closely covers

the brain and spinal cord. The intracranial portion of the pia covers the gyri of the cerebrum and cerebellum. This portion dips down into sulci of both structures; it extends into the transverse cerebral fissure, it forms the tela choroidea of the third ventricle and, in part, the choroid plexuses of the lateral and fourth ventricles, and it covers the outer surfaces of the corpus callosum, hypothalamus, mamillary bodies, pons, and medulla oblongata. The spinal portion of the pia mater is somewhat thicker than the intracranial portion. It completely encircles the cord and is closely adherent to it. The tissues of the pia completely fill the median fissure and form a sturdy band along its ventral margins. The pia extends into the filum terminate and blends with the dura mater (outer meningeal membrane) in the region of the second sacral segment, where it joins the peritoneum.

The term "arachnoid" literally means spiderlike. Its use in connection with the meninges refers to the similarity between a spider's web and the delicate structure of the middle meningeal membrane. In figure 5-3, the arachnoid is situated between the pia mater and the dura mater. It loosely envelopes both brain and spinal cord. The arachnoid, unlike the pia, does not dip down into the sulci of the cerebrum and cerebellum. The arachnoid membrane is not closely adherent to the pia mater but is separated from it by the subarachnoid space. Cerebrospinal fluid produced by the ventricular system is circulated through this space. The subarachnoid space is not uniform in depth; the wide deep regions are referred to as *cisterns*. The three principal cisterns are located in the vicinity of the cerebral peduncles, the junction of the pons and the medulla oblongata, and the inferior surface of the cerebellum and the brain stem. The spinal portion of the arachnoid loosely invests the cord and terminates in the distal reaches of the cauda equina.

The *dura mater* is the outermost meningeal membrane. Comprised of tough, fibrous tissue, the dura completely covers the outer surfaces of the brain and spinal cord. Its intracranial portion is comprised of two layers. The outer, periosteal, layer is in direct contact with the inner surfaces of the cranial bones. The smooth inner, or meningeal, layer overlies the arachnoid membrane. Both layers of the dura are joined except in the places where the dural sinuses pass between them. The meningeal layer of the dura is separated from the arachnoid membrane by the shallow subdural space. This space is similar to that found between the visceral and parietal layers of the pleura. It contains a small amount of fluid to prevent adhesion and friction.

**The subarachnoid space.** As previously described, the subarachnoid space is continuous around the brain and spinal cord and is divided into intracranial and spinal portions. It is not uniform in depth. The deep spaces in the intracranial portion are referred to as cisterns and surround the base and stem of the brain. The largest of these is the cisterna magna. It actually forms a funnel around the base of the cerebellum and the medulla oblongata.

#### Exercises (661):

Complete the following statements with the correct term or terms:

- 1 The three layers of tissue surrounding the brain and spinal cord are called the \_\_\_\_\_
- 2 The inner meningeal layer is the \_\_\_\_\_
- 3 The thicker portion of the inner meningeal layer is in the \_\_\_\_\_ area
- 4 The inner meningeal layer blends with the outer layer near the \_\_\_\_\_ vertebra.
- 5 The middle meningeal layer is the \_\_\_\_\_ membrane
- 6 The space between the middle and inner meningeal layers is called the \_\_\_\_\_ space.
- 7 The space indicated in exercise number 6 contains \_\_\_\_\_
- 8 Wide, deep portions of the subarachnoid space are called \_\_\_\_\_.
- 9 The subarachnoid space ends in the distal portion of the \_\_\_\_\_.
- 10 The outer meningeal layer is called the \_\_\_\_\_.
- 11 The two layers of the outer meningeal membrane are joined everywhere except in the locations of the \_\_\_\_\_
12. The space between the middle and outer meningeal layers is called the \_\_\_\_\_ space
- 13 The largest cistern is the \_\_\_\_\_

**662. Differentiate among methods of radiographic demonstration of intracranial structures.**

**Radiographic Considerations.** Intracranial structures (the brain and ventricles) are demonstrated primarily by two radiographic modes: cerebral pneumography and computed tomography (CT).

**Cerebral pneumography.** Cerebral pneumography is a general term applied to the radiographic examination of the brain and ventricles by means of the introduction of a negative (gaseous) contrast medium into the ventricular system. Because of the radiographic homogeneity of brain matter and fluid-containing channels, noncalcified lesions of those structures cannot be satisfactorily demonstrated by conventional radiography without the use of a contrast medium. A gaseous medium—air, oxygen, or carbon dioxide—is generally used for this purpose in preference to positive contrast media because gases produce less irritation in the ventricular system and are more readily absorbed in the subarachnoid space.

Cerebral pneumography is employed to demonstrate space-occupying lesions or masses as shown by filling defects or deformations in the shadow outline of gas-filled ventricles. The two procedures of cerebral pneumography are *pneumoencephalography* and *pneumoventriculography* (also called *ventriculography*). Basically, the examinations are similar with respect to projections made after the medium is introduced. However, there is a considerable difference between the two concerning other aspects. Since these procedures are rapidly being replaced by CT, we cover them in general steps rather than in detail.

**Pneumoencephalography.** The entire pneumoencephalographic procedure is done in the radiology department. The examination usually begins with the patient seated with the forehead resting against an upright filming device, such as a head unit, upright X-ray table, or other upright bucky. The patient can be strapped into a special pneumoencephalographic chair, or if one is not available, he or she can be seated astride a standard straight-back chair. The physician usually makes a lumbar puncture (rarely a cisternal puncture) and, after removing a small amount of spinal fluid, replaces it with air, carbon dioxide, or oxygen. Since air rises, the negative contrast medium ascends the spinal cord and, for the most part, enters the ventricular system of the brain. (A small amount of medium also enters the subarachnoid spaces of the brain.)

The surgeon then asks for an AP or lateral projection or both to determine whether or not the contrast medium does, in fact, reach the ventricular system. Make these initial

projections without moving the patient except to turn his or her head for the lateral, if it is necessary to do so. After inspecting the radiographs, the surgeon usually administers more contrast medium and asks for additional scout films. When satisfied that the ventricles are sufficiently filled, the surgeon will ask you to perform the standard projections

**Ventriculography.** The contrast medium for the ventriculogram is introduced in the operating room; consequently, you may be required to perform scout films there with a portable unit. After a patient is anesthetized, the surgeon, using a special trephine saw which is used to remove a circular disc of bone, makes a small hole on each side of the skull (usually called trephine openings). If the patient is an infant, the holes may not be necessary due to the open sutures or anterior fontanel. The surgeon then inserts a needle through each opening into the lateral ventricles and replaces a certain amount of the spinal fluid with the same type of contrast media used for pneumoencephalography. If the surgeon wants scout films, an AP or PA and cross-table lateral projections are usually made. After inspecting the radiographs, the surgeon can introduce more of the contrast medium or remove the needles, dress the wounds, and have the patient transferred to the radiology department for the radiographs.

**CT of the brain and ventricles.** As CT units become more commonplace, physicians are turning to this method for studies of the brain. Some reasons for this include its excellent tissue differentiation and precise localization of pathologic structures. Because CT can distinguish between tissues that have very small differences in atomic density, it may not be necessary to include a contrast enhancement series. Therefore, CT may not need to be an invasive exam in each situation, whereas cerebral pneumography is always an invasive study. And because CT slices are accurately measured, the precise size and location of pathologic structures—tumors, masses, aneurysms, etc.—can be easily seen.

Perhaps the most common reason for doing CT brain scans is because the patient complains of headaches. Often a physician is looking for masses or tumors, hydrocephalus, or an increase in ventricular size. Regardless of the reason, procedures are very similar.

The patient is positioned supine so that the OML is perpendicular to the positioning table. If the patient's body habitus causes the OML to be tilted, then the gantry may be angled to place the C.R. in line with the OML. Either way is satisfactory to get an AP positioning. The skull is usually restrained and held motionless by a head holder that becomes attached to the table. A scout film is obtained after the patient's position is secured.

The first scan usually is made at the base of the skull; contiguous scans are made until the vertex is reached. The first series of scans is always done without any contrast medium. Some pathology, such as soft tissue masses or

checking on ventricular size, may not need a second series of scans made after the introduction of a contrast medium. Contrast enhancement scans are included whenever pathology may affect the cranial vascular system, such as hypervascular tumors

If contrast enhancement scans are needed, they are always done *after* the first scans are done without a contrast medium. Generally, the patient is given a drip infusion of 120 - 150 cc of a water-soluble contrast medium. The injection is usually in the antecubital region of the arm, although other veins may be used. About 7 to 10 minutes after the drip infusion began, scans may be obtained again

#### Exercises (662):

- Match the radiographic examination in column B with the appropriate statement in column A. Each column B item may be used once or more than once. Also, all column B items may match a single column A entry.

#### Column A

- First radiographs are made with the patient upright
- Can be a noninvasive study
- The contrast medium is introduced through trephine openings
- The contrast medium is usually introduced by drip infusion
- The contrast medium, during introduction, rises into the ventricles
- Visualizes the ventricles of the brain
- Patient is seated for the introduction of the contrast medium
- Contrast medium is introduced directly into the lateral ventricles
- Provides excellent tissue differentiation
- Becoming more preferred instead of the other two methods

#### Column B

- Pneumoencephalography
- Ventriculography
- Computed tomography

## Muscular, Integumentary, and Endocrine Systems

IN THE PRECEDING chapters of this volume, we have covered the five basic body systems related to special procedures. This chapter concludes our study of anatomy and physiology. It includes three sections covering the muscular, the integumentary, and the endocrine systems. No study of anatomy and physiology is complete without a look at these three systems. Even though there are no special contrast studies of these systems routinely done in diagnostic radiology, you will see that they are as vital to life as any of the major organs previously studied. We begin with the muscular system.

### 6-1. Muscular System

Most physiological activities of the body can be related to movement produced by the muscles. Generally, we can exercise voluntary control over some movements, such as the act of walking, while other movements, such as the heartbeat, are precipitated by conditions not under our voluntary control. Our discussion of the muscular system includes a look at the three types of muscular tissue, some skeletal muscle characteristics, and finally a study of some specific skeletal muscles.

**663. Differentiate among the three types of muscle tissue in terms of location, function, and appearance of each type.**

**Types of Muscular Tissues.** All of the muscles found in the human body can be classified into one of three types: (1) *skeletal*, (2) *smooth*, or (3) *cardiac*.

**Skeletal.** By far, most of the muscles in the body are classified as *skeletal*. In fact, they alone constitute about 40 percent of the body weight. Skeletal muscles are so designated because they are attached to bones. They are also sometimes referred to as voluntary muscles because we exercise conscious control over them. As stated in the introduction to this section, the act of walking results from voluntary control over our muscles. In this case, we regulate the movements of our legs by consciously and voluntarily influencing the actions of certain leg muscles. Skeletal muscles are also sometimes called *striated muscles* due to their microscopic appearance. When magnified, a skeletal muscle fiber appears to be composed of alternate light and dark parallel stripes.

**Smooth.** The second type of muscle tissue is classified as *smooth*. This type of tissue is composed of spindle-

shaped fibers that do not appear to have striations or stripes when examined microscopically. Smooth muscles are sometimes termed "visceral muscles" because they are located primarily in the walls of various body organs, such as the stomach and the bowel. These muscles are stimulated by impulses from the autonomic nervous system, which, in case of the structures mentioned, conduct the peristaltic action. The walls of blood vessels also contain smooth muscle fibers that account for the dilatation and constriction of the vessels. Since smooth muscles are stimulated by self-controlling impulses, they are sometimes called *involuntary muscles*.

**Cardiac.** *Cardiac* muscle tissue, as the name implies, makes up only the walls of the heart. Heart muscles microscopically appear similar to the skeletal muscles in that they are striated. Their actions—contraction and relaxation—are responsible for the "pumping" action of the heart that circulates blood throughout the body. Naturally, cardiac muscle fibers are involuntarily controlled.

### Exercises (663):

- 1 Match the type of muscle tissue in column B with the appropriate statement or word in column A. Each column B item may be used once or more than once. Also, more than one column B item may match a single column A entry.

Column A	Column B
_____ (1) Responsible for pumping blood to the lungs	a Skeletal
_____ (2) Cannot be consciously activated.	b Smooth
_____ (3) Microscopically controlled	c Cardiac
_____ (4) Voluntarily controlled	
_____ (5) Visceral	
_____ (6) Peristalsis.	
_____ (7) Responsible for arm movement	
_____ (8) Comprises the heart muscle	
_____ (9) Attaches to the humerus	
_____ (10) Comprises almost half of the body weight	

**664. Identify by name, location, and attachment the parts of skeletal muscles in general and the biceps brachii in particular.**

**Parts of Skeletal Muscles.** Skeletal muscles are composed of three basic parts. (1) the *body*. (2) the *origin*, and (3) the *insertion*. See figure 6-1. The body or belly is the large middle portion of the muscle. The origin is the proximal point of attachment, located on the relatively more fixed anatomical structure. The insertion is the distal point of attachment, located on the more movable structure. The biceps brachii, illustrated in figure 6-1, among other functions, flexes the elbow. The distal portion of that muscle is attached to the forearm, which is more movable during elbow flexion than the proximal structure of origin—in this case, the scapula. Notice that the biceps brachii has two points of origin, since the proximal portion is split into two divisions. When such is the case, each division is sometimes referred to as a *head*. Also, notice that the muscle tissue itself terminates in a tendon that connects the muscle to the points of origin and insertion. (NOTE: In actuality, the origin and insertion of a skeletal muscle is functionally interchangeable.) For example, if you chin yourself on a horizontal bar, the act includes flexion of the elbows, but your forearms are relatively stationary while the remainder of your body moves. This situation would reverse the origin and insertion of the biceps brachii. For general descriptive purposes, however, the origin is the proximal portion and the insertion is the distal portion.

**Exercises (664):**

1. What are the names of the three basic parts of a skeletal muscle?
2. What is the origin of (a) a skeletal muscle? (b) The insertion?
3. Where, specifically, is the origin of the biceps brachii?
4. If a skeletal muscle is divided into two or more proximal portions, what are the portions called?

**665. Identify actions of the skeletal muscles in general and certain arm muscles in particular.**

**Skeletal Muscle Actions.** The human body has more than 400 skeletal muscles; they function in groups to provide varying degrees of movements. Groups arranged so they oppose each other are called *antagonistic* muscle

groups. Their antagonistic actions are done, for example, by flexors in opposition to extensors. An example of such action is the flexion and extension of the elbow. As the biceps brachii contracts, the triceps brachii relaxes and flexion of the elbow occurs; reversely, as the triceps brachii contracts, the biceps brachii relaxes and extension of the elbow occurs. During elbow flexion, the triceps brachii is the antagonist of the biceps brachii. These combined actions of antagonistic muscles provide smooth, coordinated movements and help to regulate and stop the movements.

In most instances more than one muscle crosses and regulates the movement of a particular joint. However, certain muscles are primarily responsible for the movement and are called *prime movers*. A single muscle or group of muscles may be primarily responsible for the movement. In case of flexion of the elbow, the biceps brachii, the brachialis, and the brachioradialis all contribute to the movement. The biceps brachii and the brachialis are primarily responsible for the movement, while the brachioradialis is considered an *agonist*. An agonistic muscle, then, is one which aids a prime mover. We can also say that an antagonistic muscle is one that opposes a prime mover.

In addition to prime movers, agonists and antagonists, there are also *synergistic muscles*. These muscles stabilize joints so that the prime mover and the agonist function efficiently. Referring once again to elbow flexion, as the appropriate muscles act to flex the joint, certain muscles about the shoulder must contract to stabilize the arm so that flexion occurs in the desired direction or plane. Such stabilizing muscles are said to be synergistic.

**Exercises (665):**

Indicate whether the following statements are true or false. If you indicate false, explain your answer.

- \_\_\_\_\_ 1. A group of muscles that flexes or extends a particular part is called an agonistic muscle group.
- \_\_\_\_\_ 2. Although antagonistic muscles work against each other, their combined efforts effect desirable muscle movements.
- \_\_\_\_\_ 3. A particular muscle may be classified as both an antagonist and a prime mover.
- \_\_\_\_\_ 4. An agonistic muscle is a prime mover.

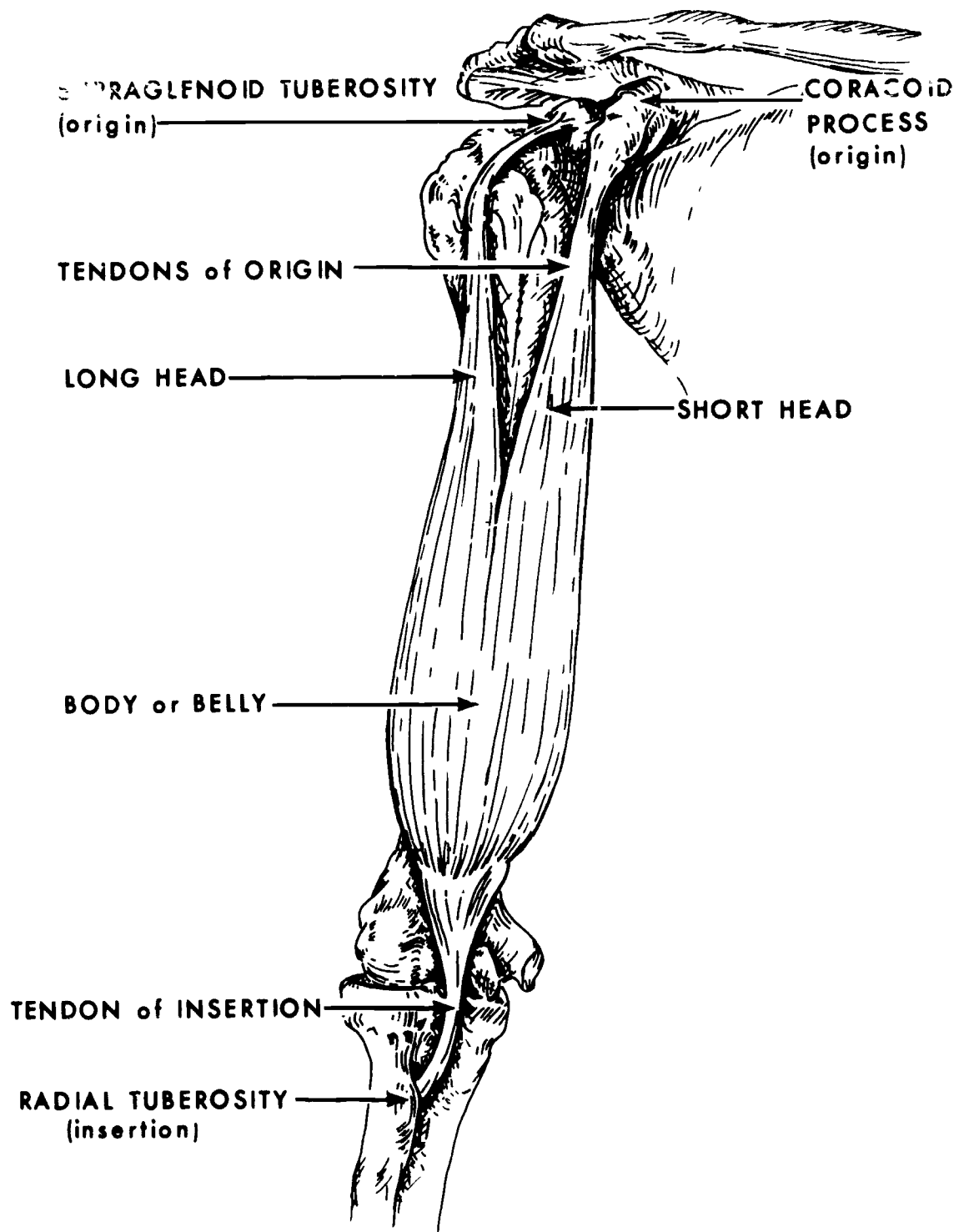


Figure 6-1 Majors parts of a typical skeletal muscle—the biceps brachi

- \_\_\_\_\_ 5 Prime movers and agonistic muscles may provide identical movements
- \_\_\_\_\_ 6 The brachioradialis muscle is considered a prime mover
- \_\_\_\_\_ 7 Synergistic muscles are those that stabilize a part during movement.

**666. Differentiate among skeletal muscles in terms of their origin, insertion, and action.**

**Origin, Insertion, and Action of Specific Skeletal Muscles.** At this point, we conclude our discussion of the muscular system with a close look at some of the skeletal muscles. We examine seven such muscles in terms of their origin, insertion, and action.

**Serratus anterior.** The *serratus anterior* is a thin muscle situated between the ribs and the scapula. It originates on the lateral aspects of the first eight ribs and inserts into the vertebral border of the scapula. Its major function is to rotate the scapula.

**Trapezius.** The *trapezius* is the large posterior muscle of the neck and shoulder. Anatomically, it is broken down into the upper middle and lower portions. The origins of the trapezius extend from the external occipital protuberance, down the nuchal ligament, and along the spinous processes of the thoracic vertebrae. The insertions include the lateral one-third of the clavicle, the vertebral border of the scapula, and the base of the scapula spine. Actions of the trapezius include rotation and adduction of the scapula.

**Deltoid.** The *deltoid* is the large fan-shaped muscle on the apex of the shoulder. It originates from the lateral portion of the clavicle, the acromion process of the scapula, and the spine of the scapula. The deltoid muscle inserts into the deltoid tuberosity, located approximately in the middle of the shaft of the humerus. Actions of the deltoid are flexion, extension, and abduction of the arm.

**Pectoralis major.** The *pectoralis major* (commonly called the breast muscle) originates from the medial portion of the clavicle and the first six costal cartilages. It inserts into the edge of the bicipital groove of the humerus and contributes to adduction, medial rotation, and extension of the arm.

**Psoas major.** The *psoas major* muscle, often seen on abdominal radiographs, originates from the transverse processes and bodies of the lumbar vertebrae and inserts into the lesser trochanter of the femur. It flexes the thigh and the lumbar vertebral column and bends the column laterally.

**Quadriceps femoris.** The *quadriceps femoris* are considered to be the largest and most powerful group of muscles in the body. Located on the anterior thigh, the muscle group originates from the anterior-superior iliac

spine and from the lateral surface, the lower medial surface, and the upper two-thirds of the anterolateral surfaces of the femur. They insert into the tibial tuberosity. The actions of the quadriceps femoris include elevating the femur and leg extension.

**Gastrocnemius.** The *gastrocnemius* is located on the posterior portion of the lower leg and originates from the posterior portion of each femoral condyle. It inserts into the posterior surface of the calcaneus by way of the Achilles tendon. Actions include plantar flexion of the foot, extension of the knee joint, and flexion of the knee joint.

**Exercises (656):**

1. Match the skeletal muscles in column B with the appropriate insertion, origin, or action in column A. Each column B item may be used once, more than once, or not at all. Also, more than one column B item may match a single column A entry.

Column A	Column B
<i>Origin</i>	
_____ (1) Femoral condyles	a Serratus anterior
_____ (2) First six costal cartilages	b Trapezius
_____ (3) Clavicle	c Deltoid
_____ (4) Lumbar vertebrae	d Pectoralis major
_____ (5) Thoracic vertebrae	e Psoas major
_____ (6) Anterior-superior iliac spine	f Quadriceps femoris
	g Gastrocnemius
<i>Insertion</i>	
_____ (7) Midportion of humerus	
_____ (8) Proximal portion of humerus	
_____ (9) Posterior calcaneus	
_____ (10) Tibial tuberosity	
_____ (11) Lesser trochanter	
<i>Action</i>	
_____ (12) Plantar flexion of foot	
_____ (13) Knee extension	
_____ (14) Thigh flexion	
_____ (15) Rotation of the scapula	
_____ (16) Flexion or extension of arm	

**6-2. Integumentary System**

The integumentary system, or skin, not only covers most visible parts of the body but is associated with several body functions. It protects the deeper tissues from injury and dehydration, and, unless the skin is broken, it prevents the entrance of bacteria-producing microorganisms. The skin, along with some of its appendages, helps to regulate body

temperature through the dilatation and constriction of its blood vessels. Another important function is the elimination of certain waste products. In this section, we will discuss the structure of the skin as well as its appendages.

**667. Differentiate among layers of the skin in terms of location, function, name, and characteristic.**

**Structure of the Skin.** The skin is composed of two principal layers: the outer layer, or *epidermis*, and the inner layer, or *dermis*. Each principal layer is subdivided into structural sublayers.

**The epidermis.** The epidermis contains no blood vessels or lymph vessels and consists of five structural sublayers. From external to internal they are: (1) *stratum corneum* (2) *stratum lucidum* (3) *stratum granulosum* (4) *stratum spinosum* and (5) *stratum basale*.

The external layer of the epidermis, or *stratum corneum*, varies in thickness, depending upon the amount of trauma to which it is subjected. Accordingly, it is thickest over the palms and soles and thinnest over well-protected areas of the body. The *stratum corneum* is composed of cells that are continuously dying and sloughing off.

The second layer of the epidermis is called the *stratum lucidum*, so named because of its clearness or translucence. This layer acts as a medium for new cells passing to the *stratum corneum*.

The third or middle layer of the epidermis, or *stratum granulosum*, consists of two or three rows of flattened cells.

The *stratum spinosum*, or fourth layer of the epidermis, is composed of several layers of polygonal cells.

The deepest layer of the epidermis is called the *stratum basale*. It is sometimes called the *stratum cylindricum* because its cells are cylindrically shaped. This layer is responsible for the growth of the epidermis, since it is the only epidermal layer that reproduces new cells. As the new cells are formed, they gradually pass to the *stratum corneum* where, after dying, they eventually slough off the external surface. Skin pigmentation is determined by the amount and activity of melanin found in this layer.

**The dermis.** The dermis is composed of two structural sublayers: (1) the *papillary layer* and (2) the *reticular layer*. The *papillary layer* is located directly beneath the deepest layer of the epidermis. It derives its name from the many nipplelike projections located on the outer surface. The outer surface of the *reticular layer* joins the inner surface of the *papillary layer* and extends to the subcutaneous tissue.

**Exercises (667):**

- Match the skin layer in column B with the appropriate statement or phrase in column A. Each column B item may be used once or more than once. Also, more than one column B item may match a single column A entry.

*Column A*

*Column B*

- |  |                      |
|--|----------------------|
| _____ (1) Deepest epidermal layer                            | a Stratum corneum    |
| _____ (2) Deepest dermal layer                               | b Stratum granulosum |
| _____ (3) Joins subcutaneous tissue                          | c Stratum basale     |
| _____ (4) Responsible for skin color                         | d Papillary layer    |
| _____ (5) Its cells continuously slough off                  | e Stratum lucidum    |
| _____ (6) Middle epidermal layer                             | f Reticular layer    |
| _____ (7) Located between stratum basale and reticular layer | g Stratum spinosum   |
| _____ (8) Produces new epidermal cells                       |                      |
| _____ (9) Epidermal layers                                   |                      |
| _____ (10) Dermal layers                                     |                      |
| _____ (11) Thickness depends upon exposure to trauma         |                      |
| _____ (12) Contains melanin                                  |                      |

**668. Specify the structure, location, and functions of nails, hairs, sweat glands, and sebaceous glands.**

**Appendages of the Skin.** The appendages of the skin are the *nails*, *hairs*, *sweat glands*, and *sebaceous glands*.

**Nails.** The nails are flat, hard structures that contain a root, the proximal portion of which is hidden by the skin, and a body, which is visible. The external surface of the nail proper consists of the *stratum lucidum*, which is greatly thickened. The deeper (internal) surface of the nail consists of the deepest layer of the epidermis.

**Hairs.** A hair consists of a root that is below the surface of the skin and a shaft that is visible above the skin. The root is situated inside the follicle, which is an indentation of the epidermis extending into the subcutaneous layer of tissue. See figure 6-2. Minute muscles called arrector muscles originate from the dermis and insert into the hair follicle. They insert onto the side of the follicle toward which the shaft slopes, as seen in figure 6-2.

**Sweat glands.** Sweat glands consist of (1) a body or secretory portion that may lie in the dermis or subcutaneous tissue and (2) a duct that opens into the external surface of the skin (see fig. 6-2).

**Sebaceous glands.** Sebaceous glands, as seen in figure 6-2, are located on the lateral surfaces of the hair follicles. They secrete *sebum*, an oil substance, into the follicle. The sebum protects the hair from excessive dryness and brittleness and lubricates the skin surface.

**Exercises (668):**

Fill in the blank spaces with the appropriate word(s).

- The outer portion of a nail is composed of the stratum \_\_\_\_\_.



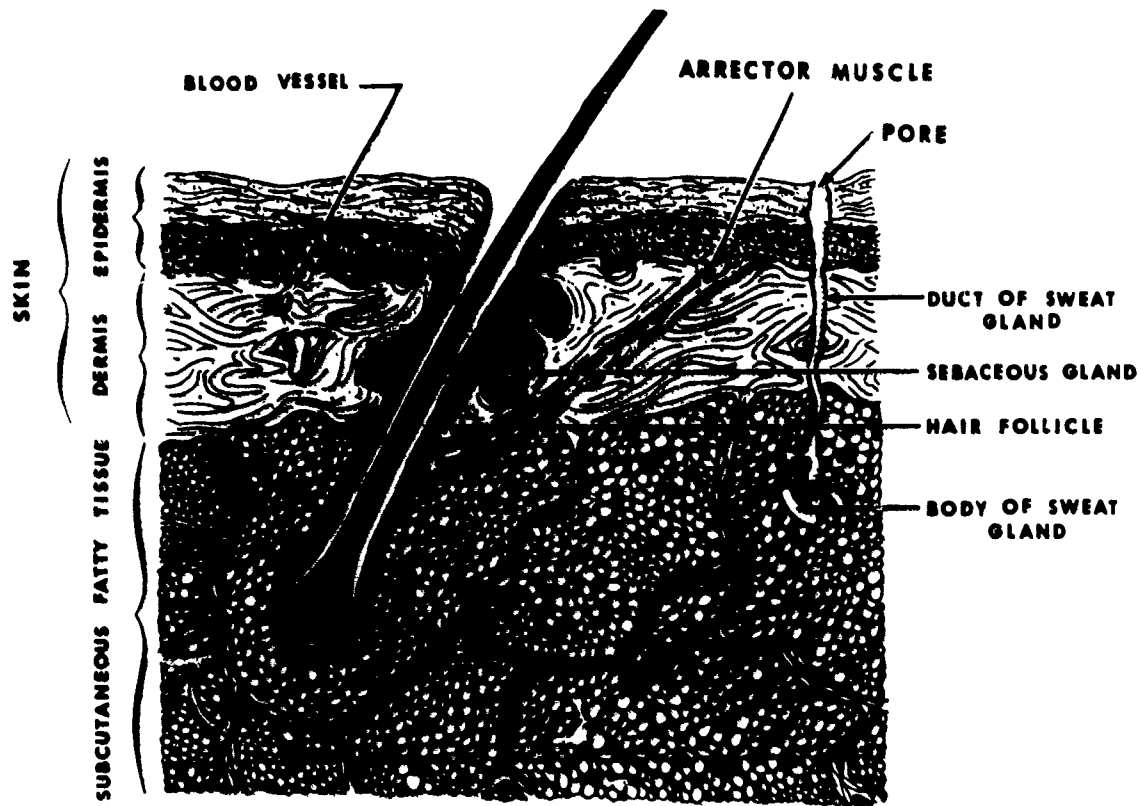


Figure 6-2 The epidermis, dermis, subcutaneous tissue, and appendages of the skin

2. The \_\_\_\_\_ surface of a nail is composed of the stratum basale.
3. The hair \_\_\_\_\_ is not normally visible.
4. A hair root is located inside the hair \_\_\_\_\_.
5. The secretory portion of a sweat gland may lie in the \_\_\_\_\_ or \_\_\_\_\_ tissue.
6. A sebaceous gland secretes \_\_\_\_\_ which \_\_\_\_\_ the skin surface.

### 6-3. The Endocrine System

The glands of internal secretion are commonly called ductless or endocrine glands because they secrete their hormones directly into the blood stream. (Other glands that secrete their products onto the body surface or into a body cavity are sometimes referred to as duct or exocrine glands.) The hormones secreted by the endocrine glands are important because they control many of our life processes.

In this section, we discuss the location and functions of the following endocrine glands: the *thyroid*, the *parathyroid*, the *thymus*, the *adrenal*, the *pituitary*, the *pineal*, the *pancreas*, and the *gonads*. Refer to figure 6-3 as we discuss their locations.

#### 669. Identify functions and characteristics of the endocrine glands.

**Thyroid Gland.** The thyroid gland is located in the anterior portion of the neck just below the level of the thyroid cartilage. It contains two lobes, the left and right, which are connected by a strip of tissue called the *isthmus*. The upper portions of each lobe follow the general contour of the lateral portions of the thyroid cartilage, which together with the thin isthmus give the thyroid a "butterfly" appearance. The hormone thyroxin is secreted by the thyroid gland. Thyroxin controls growth and development of the body by regulating the body metabolism.

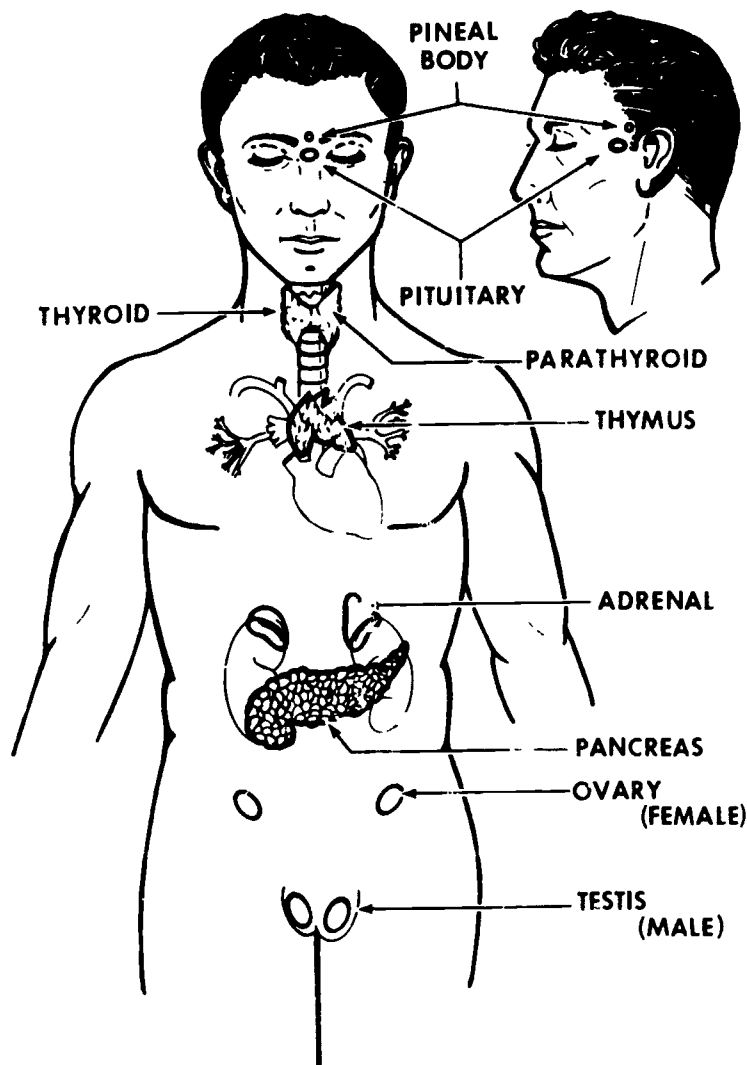


Figure 6-3 Location of the endocrine glands

**Parathyroid Glands.** The four parathyroid glands are located two on each lateral thyroid lobe—although their composition and function are completely independent of the thyroid gland. They appear as small oval discs averaging about 6 mm in length and 3.5 mm in width. The parathyroids secrete parathormone, which regulates the calcium content in the blood and the general calcific metabolic state in the body.

**Thymus.** The thymus is located in the anterior portion of the upper mediastinum, overlying the trachea and the major blood vessels arising from the heart. The thymus is larger in small children and undergoes a gradual reduction in size with age. It is thought that the gland secretes a substance that directs the production of antibodies that fight infections in the body.

**Adrenal.** The two adrenal glands located on the medial and superior aspects of the upper portions of each kidney

consist of an outer section, the cortex, and an inner section, the medulla. The cortex produces several different corticosteroids that regulate salt, water, carbohydrate, protein, and fat metabolism. The medulla secretes adrenaline (epinephrine) and norepinephrine, which enable us to mobilize our body resources in times of emergency or stress.

**Pituitary.** The pituitary gland, sometimes called the master gland because it controls the secretions of various other glands, is located in the sella turcica. It is about the size of a "pea" and is comprised of an anterior and a posterior lobe. The anterior lobe dominates the functions of the pituitary by secreting hormones that affect many body processes. The following are examples of some of these hormones and their actions:

- Somatotropin—Influences growth of body tissues.
- Thyrotropin—Influences the thyroid gland, causing it to secrete its hormone.
- Gonadotropin—Stimulates the gonads.
- Adrenotropin—Stimulates the adrenal glands.

An extract obtained from the posterior pituitary lobe acts upon certain muscle fibers, causing them to contract.

**Pineal.** The pineal body is located just posterior and superior to the pituitary, as seen in figure 6-3. The secretions and functions of the pineal are still somewhat uncertain.

**Pancreas.** The pancreas is considered to be both an exocrine and endocrine gland. Its exocrine function is the production of pancreatic juices for the chemical digestion of fats, carbohydrates, and proteins, which it empties into the duodenum. Its endocrine function is the secretion of insulin in the tiny islandlike cells called the islets of Langerhans. Insulin regulates the sugar metabolism of the body.

**Gonads.** The gonads are the female ovaries and male testes.

**Ovaries.** The ovaries produce several estrogens, which are hormones affecting development of the secondary sex characteristics. Estrogens also affect the reproductive functions of the female. One estrogen, progesterone, primarily functions to prepare the uterus for implantation of a fertilized ovum.

**Testes.** The testes produce androgens (hormones) that affect development of the secondary sex characteristics and maintenance of the reproductive functions. Two such hormones are androsterone and testosterone.

### Exercises (669):

1. Match the endocrine glands in column B with the appropriate statement or phrases in column A. Each column B item may be used once, more than once, or not at all

<i>Column A</i>	<i>Column B</i>
_____ (1) Produce testosterone	a Thyroid
_____ (2) Secretes insulin	b Parathyroid
_____ (3) Master gland	c Thymus
_____ (4) Secretes adrenaline	d Adrenal
_____ (5) Controls body development	e Pituitary
_____ (6) Shaped like a butterfly	f Pineal
_____ (7) Larger in small children	g Pancreas
_____ (8) Secretes adrenotropin	h Ovaries
_____ (9) Functions both as endocrine and exocrine gland	i Testes
_____ (10) Produce progesterone.	
_____ (11) Produces corticosteroids	
_____ (12) Four in number	
_____ (13) Produces androsterone	
_____ (14) Regulates calcific metabolism	

## Answers for Exercises

### CHAPTER I

#### Reference:

- 600 - 1 Hard and soft palates  
 600 - 2 Maxillae and palatines  
 600 - 3 It separates the nasal cavity and nasopharynx from the oral cavity and oropharynx
- 601 - 1 (1) c  
 (2) b  
 (3) b  
 (4) a, b, c  
 (5) a, c  
 (6) a  
 (7) a, c  
 (8) b  
 (9) c  
 (10) c  
 (11) c  
 (12) b
- 602 - 1 T  
 602 - 2 F It is the proximal portion  
 602 - 3 F Food and air pass through the oropharynx  
 602 - 4 T  
 602 - 5 T  
 602 - 6 T  
 602 - 7 T  
 602 - 8 F It is approximately 25 cm long  
 602 - 9 F  
 602 - 10 F It is posterior to the heart  
 602 - 11 T
- 603 - 1 (a) Greater curvature, (b) lesser curvature  
 603 - 2 On the greater curvature  
 603 - 3 Incisura angularis  
 603 - 4 (1) Cardiac orifice—lies at the level of the eleventh thoracic vertebra 1 inch to the left of the lateral sternal border (2) Pyloric orifice—1 to 2 inches to the right of the midline at the level of the upper border of the first lumbar vertebra.
- 603 - 5 (1) Fundus—proximal, (2) body—middle, (3) pylorus—distal.  
 603 - 6 The iliac crest.  
 603 - 7 Hypersthenic or obese  
 603 - 8 Asthenic  
 603 - 9 Two to 4 inches below the level of the iliac crest  
 603 - 10 Like a "J" or "fishhook."
- 604 - 1 Duodenum, 25 cm, jejunum, 7 to 8 feet, and ileum, 16 feet  
 604 - 2 Oblique  
 604 - 3 When the bulb lies in an anteroposterior direction  
 604 - 4 It marks the end of a small bowel series when it is visualized on a radiograph.  
 604 - 5 Duodenum Posterolaterally from the pylorus. Curves downward and descends over the head of the pancreas, curves medially and upward behind the stomach, and finally curves sharply downward.  
 604 - 6 The proximal half of the duodenum.  
 605 - 1 Cecum, ascending colon, hepatic flexure, transverse colon, splenic flexure, descending colon, sigmoid colon, rectum, anal canal, and anus.
- 606 - 1 Hemidiaphragm  
 606 - 2 Right, quadrate caudate  
 606 - 3 Falciform ligament  
 606 - 4 Inferior.  
 606 - 5 Common hepatic  
 606 - 6 Posterior, duodenum  
 606 - 7 Intrahepatic radicals  
 606 - 8 Cystic  
 606 - 9 Common bile, pancreatic  
 606 - 10 Common bile, pancreatic  
 606 - 11 Duodenal papilla.  
 606 - 12 Tail, body, head  
 606 - 13 Islets of Langerhans  
 606 - 14 Duct of Santorini
- 607 - 1 The presence of food, liquids, gas, or fecal material may result in difficulties in interpretation due to confusing shadows  
 607 - 2 (1) Keep them consistent for the same examination (2) Make them clear and easy to understand (3) If a laxative is included, provide the nature of its action (4) Specify foods allowed. (5) Include the phone number of your department.  
 607 - 3 Ask the patient if he followed the instructions before he or she is readied for the examination. You can save all persons concerned a lot of time
- 608 - 1 They adhere to the mucosa of the pharynx and esophagus for a longer time period, allowing you to better "catch" the medium in the right area  
 608 - 2 Restrict the preparation because some settling occurs in most preparations  
 608 - 3 Alternate digestive media such as Oral Hypaque and Gastrografin  
 608 - 4 To provide an air-contrast study of the fundus of the stomach  
 608 - 5 It must be safe with respect to the lungs.
- 609 - 1 To locate and explore the main salivary duct.  
 609 - 2 Blunt needle  
 609 - 3. (1) To stimulate the gland, permitting the duct opening to be located due to the discharge of saliva (2) To evacuate the contrast material after the "filled" radiographs are made
- 609 - 4. All of them.  
 609 - 5 Either PA or AP  
 609 - 6 From 25° to 30° or until the area is perpendicular to the film.  
 609 - 7 The parotid  
 609 - 8 Sublingual.  
 609 - 9 To the right.  
 609 - 10 From 10° to 30° cephalic.
- 610 - 1 The barium descends very quickly during the act of swallowing, and the patient cannot respond promptly to your instruction to "swallow."  
 610 - 2. Observe the patient's thyroid cartilage during the act of swallowing. When it reaches its most anterosuperior position, make your exposure  
 610 - 3 It permits a more unobstructed view of the distal esophagus  
 610 - 4 The patient continuously drinks liquid barium from a straw. The exposure is made after 4 to 5 seconds of drinking  
 610 - 5 The drinking esophagram usually shows the entire esophagus filled with barium. The others do not

- 610 - 6 So that the visible size of the heart and pulmonary structures may also be evaluated
- 610 - 7 To minimize magnification of the heart
- 610 - 8 It requires more rotation to project the heart clear of the spine because the heart is slightly to the left of the midline
- 610 - 9 Commercial barium paste with special coating characteristics
- 610 - 10 (1) Personal preference, (2) thickness of the medium, and (3) cooperation of the patient
- 610 - 11 To permit better visualization of the lower esophagus
- 610 - 12 To evaluate displacement of the esophagus by the great vessels of the heart
- 611 - 1 Right anterior, right lateral, peristalsis
- 611 - 2 Mucosa
- 611 - 3 Walls
- 611 - 4 Contrast medium, drug
- 611 - 5 Respiratory muscles, artificial respiration
- 611 - 6 LPO
- 611 - 7 Pylorus, duodenal bulb
- 611 - 8 Maximum peristalsis
- 611 - 9 Right lateral
- 611 - 10 Retrogastric structures
- 612 - 1 (1) a  
(2) d  
(3) c  
(4) b  
(5) a  
(6) d  
(7) c  
(8) d  
(9) b  
(10) b  
(11) a
- 613 - 1 During the direct method, barium is introduced followed by air. During the two-stage method, the barium is partially evacuated before air is introduced
- 613 - 2 It must allow you to switch immediately from barium to air
- 613 - 3 Because residual fecal material can often obscure small polyps or tumor masses
- 614 - 1 F The temperature is as specified by established procedures and may be 41° F, about 85° F, or warmer
- 614 - 2 T
- 614 - 3 F You should mix it immediately before use whenever possible, but you may not be able to do so always. The important factor to remember is that you must maintain the liquid at the correct temperature until use
- 614 - 4 T
- 614 - 5 T
- 614 - 6 F The most important criterion of the barium is its ability to flow sufficiently to coat the walls of the colon
- 614 - 7 F It tells you whether or not the solution runs freely and prevents air from being introduced into the colon ahead of the barium
- 615 - 1 To the iliac crest
- 615 - 2 Take two films crosswise instead of a single film lengthwise
- 615 - 3 To recoat the walls of the colon with barium
- 615 - 4 Splenic flexure, hepatic flexure, and sigmoid colon.
- 615 - 5 (a) RPO or LAO (b) LPO or RAO
- 615 - 6 Center a coronal plane 2 inches posterior to the midaxillary line to the center of the table. Direct the C.R. perpendicularly through a point on the coronal plane 2 inches superior to the symphysis pubis
- 615 - 7 (1) LPO—C R 30° to 35° cephalic  
(2) AP—C R 30° to 35° cephalic  
(3) PA—C R 30° to 35° caudad
- 615 - 8. Sigmoid colon and rectum
- 615 - 9 Approximately the same as that for a lateral rectum
- 615 - 10 To demonstrate air/fluid levels
- 615 - 11 Less than normal because of the radiolucency of the air
- 616 - 1 From the spine to the lateral abdominal wall and from the right eighth rib to the iliac crest
- 616 - 2 High in the abdomen near the lateral wall. Low in the abdomen near the spine
- 616 - 3 Tight
- 616 - 4 At the level of the 10th posterior rib, midway between the spine and lateral abdominal wall
- 616 - 5 To be able to accurately project the gallbladder in a small cone field
- 616 - 6 Nonvisualization
- 616 - 7 To make sure the gallbladder is not on the opposite side and to check the stomach, small bowel, and large bowel for the contrast medium
- 616 - 8 To visualize concentrated stones heavier than bile that gravitate to the dependent portion of the gallbladder and to visualize layered stones that are lighter than bile
- 616 - 9 One to 2 inches, 2 to 4 inches
- 616 - 10 To prevent its superimposition over the spine
- 616 - 11 Use PA or oblique Trendelenburg positions and obliques with more or less than 45° of rotation
- 616 - 12 The stones may leave the gallbladder, becoming lodged in the cystic or common bile duct
- 617 - 1 (1) b, c, d  
(2) c  
(3) b  
(4) c, d  
(5) a  
(6) a

## CHAPTER 2

- 618 - 1 T
- 618 - 2 F 2.5 to 3 cm thick
- 618 - 3 T
- 618 - 4 T
- 618 - 5 T
- 618 - 6 F They are located on the superior and medial aspects of the upper portions of the kidneys
- 618 - 7 F The 12th usually does so, the 11th only occasionally
- 618 - 8 F The renal hilum
- 618 - 9. T
- 618 - 10 T
- 618 - 11 T
- 618 - 12 T
- 618 - 13 F After leaving the minor calyces, it flows into the major calyces
- 618 - 14 T
- 619 - 1 28 to 34
- 619 - 2 Abdominal and pelvic
- 619 - 3 Anterior to the transverse processes of the first and second lumbar vertebrae
- 619 - 4 Pelvic
- 619 - 5 Muscular middle coat
- 619 - 6 (1) Outer layer—longitudinal fibers, (2) middle layer—circular fibers, and (3) inner layer—fibers, generally longitudinal in direction.
- 620 - 1. The inferior portion of the bladder is posterior to the symphysis pubis. The entire bladder is anterior to the rectum
- 620 - 2 (1) External serous coat, (2) muscle tissue, (3) submucous coat, and (4) mucous membrane lining.
- 620 - 3 By expansion of the muscular walls
- 620 - 4. A triangular area in the posteroinferior bladder wall
- 620 - 5 The trigone is not as expansive
- 620 - 6 In the upper outer regions of the trigone
- 620 - 7 As the bladder fills and stretches, the trigone stretches and clamps the distal ends of the ureters.
- 620 - 8 It opens and closes the urethral orifice
- 620 - 9. Prostatic, membranous, and cavernous
- 620 - 10. Prostate
- 620 - 11 Cavernous
- 620 - 12 4 cm
- 621 - 1 To be able to recognize a possible serious reaction and advise your radiologist or physician immediately
- 621 - 2 Technique reaction

- 621 - 3 (1) Pain at the injection site, (2) hematoma, (3) burning at the injection site or along the upper arm, and (4) numbness at the injection site or along the upper arm.
- 621 - 4 (a) No; (b) No
- 621 - 5 They may be initial manifestations of more severe reactions.
- 621 - 6 (1) Hypertension, (2) hypotension, (3) weak, rapid pulse, (4) irregular pulse; (5) cardiac arrest, (6) cyanosis, and (7) unconsciousness
- 621 - 7 (1) Urticaria (hives), (2) tightness of the chest, (3) sneezing, (4) wheezing, (5) itching, (6) watery or reddened eyes, (7) labored breathing, (8) high respiration rate, (9) low respiration rate, and (10) absence of respiration.
- 621 - 8 To begin with, keep in mind that we are only referring to the "mild" reactions with this question. You should always notify your radiologist (or other physician) immediately if the patient is experiencing a severe reaction. Whether or when you call your radiologist for other than severe conditions is something you should discuss with him or her. The radiologist may or may not want to be notified of any reaction
- 622 - 1 So they will be readily available
- 622 - 2. So the equipment can be easily and quickly transported from one room to another
- 622 - 3 So they can be quickly located. It also helps you to spot a "missing" item during inventory
- 622 - 4 Daily
- 622 - 5 (1) Expiration dates, (2) laryngoscope light, (3) proper operation of the suction apparatus, and (4) oxygen supply
- 622 - 6 So they can locate them quickly.
- 623 - 1 To provide air or oxygen to patients if breathing stops or is difficult
- 623 - 2 After proper OJT and as part of a preconceived plan with your radiologist.
- 623 - 3 (1) Tilt the patient's head back and lift his or her jaw forward; (2) hold the mask firmly against the face with your thumb and index fingers, keeping the chin and head back with your other three fingers, (3) squeeze the bag with your other hand, (4) release the bag and let the patient exhale. Repeat every 3 seconds—1 second for inhalation and 2 seconds for exhalation
- 623 - 4 By connecting an oxygen hose to the input nipple of the AMBU.
- 623 - 5 A catheter.
- 623 - 6. Depress it with your foot one-third to one-half down—maintain a constant rhythm with your foot
- 623 - 7 To insert an endotracheal tube
- 623 - 8 To connect the AMBU to the endotracheal tube
- 623 - 9 Yes
- 624 - 1 An IVP is a radiographic examination of selected renal structures (calyces, renal pelvis, ureters, and bladder) after the intravenous injection of a suitable contrast medium
- 624 - 2 Anatomically, it shows the configuration of renal structures, functionally, it demonstrates renal processing of the contrast medium and its transportation to the bladder.
- 624 - 3 (1) Withhold fluids to dehydrate the urinary system  
(2) Fast for a required period of time.  
(3) Cleanse the bowel.
- 624 - 4. Dehydration reduces the amount of fluid in the kidneys which, therefore, increases the concentration level of the excreted contrast medium so that the radiopacity of renal structures is enhanced
- 624 - 5 Fasting reduces the amount of feces and gas in the colon, which can obscure urinary structures. It also reduces the possibility of vomitus aspiration because the stomach is relatively empty.
- 624 - 6. A filled sigmoid colon can obscure the urinary bladder.
- 624 - 7. Because enemas can introduce air into the colon
- 624 - 8 Take the radiographs with the patient in the prone position because pressure on the abdomen shifts the gas laterally away from renal structures
- 624 - 9. Incomplete bowel evacuation of feces and gas.
- 625 - 1 It prevents dilution of the contrast medium, allowing better visualization of the bladder
- 625 - 2 (1) It allows the radiologist to check for gas and fecal material, which may interfere with the examination, (2) it provides the radiologist the chance to see a stone or other abnormality that may be obscured later by the contrast medium, and (3) it enables you to check your exposure and positioning
- 625 - 3 The upper margins of the kidneys and superior portion of the symphysis pubis
- 625 - 4 (1) Have the patient flex his or her knees to place the lower back in contact with the table, and (2) elevate the patient's head and shoulders slightly
- 626 - 1 25° to 30°
- 626 - 2 To evaluate gravitational emptying of the calyces and pelvis and to evaluate the mobility of the kidneys
- 626 - 3 To check bladder retention in males and females and to reveal prostate enlargement in males
- 626 - 4 Those suspected of having a urinary stone
- 626 - 5 Better outlining of the renal calyces and pelvis and better demonstration of the ureters
- 626 - 6. Across the upper pelvis at the level of the anterosuperior iliac spines
- 626 - 7 So that the pressure is consistent from one examination to the next
- 626 - 8 From 90 to 110 mm of mercury
- 626 - 9 Place the patient in the Trendelenburg position—10° to 20°
- 627 - 1 (1) It distends the stomach with gas, displacing the bowel downward and away from the kidneys, and (2) it provides excellent contrast between the kidneys and gas bubbles in the stomach
- 627 - 2 Two ounces to an infant, 12 ounces to an 8-year old, and proportionate amounts for ages in between
- 628 - 1. Narrowing of a renal artery
- 628 - 2 Visualization of the contrast material may be delayed when compared to that of the opposite kidney
- 628 - 3 Rapid injection—radiographs are made at 30-second to 1-minute intervals
- 628 - 4 Part of a hypertensive IVP performed to determine if the contrast medium washes out of one kidney faster than the other
- 629 - 1 F The major exception is that the patient is instructed to drink large amounts of fluid
- 629 - 2 F It is an anatomical, not a functional study
- 629 - 3 T
- 629 - 4 T
- 629 - 5. F. Tomograms are used to demonstrate the soft tissue structures of the kidneys
- 629 - 6 T
- 629 - 7. T
- 629 - 8 F Depending on the patient's weight, 300 to 400 cc of contrast material is used
- 630 - 1 T
- 630 - 2 T
- 630 - 3 F They should be centered to the level of the depression above the greater trochanter
- 630 - 4 T.
- 630 - 5 F Only when there is a loss of the normal lumbar lordosis. Otherwise, angle the tube 5° caudally
- 630 - 6 T
- 630 - 7 F. It is vertical and strikes the film at a 15° to 20° angle
- 630 - 8 T
- 630 - 9 T
- 630 - 10 T
- 630 - 11 T
- 630 - 12 F. The radiographs are usually made erect
- 630 - 13 T
- 631 - 1 Rectum
- 631 - 2 Fundus
- 631 - 3. Lateral, body
- 631 - 4 Laterally, 12
- 631 - 5. Fimbria, ovaries
- 631 - 6 4, 2, 8
- 632 - 1 To evaluate patency of the fallopian tubes in cases of sterility
- 632 - 2. Same answer as in exercise number 1 above

- 632 - 3 The reason is most likely to document the presence of air (carbon dioxide) in the peritoneal cavity. Do an erect chest or abdomen to include the diaphragms.
- 632 - 4 To reduce the possibility of a filled bladder impinging upon the fallopian tubes and to prevent the bladder shadow from interfering with visualization of the contrast medium.
- 632 - 5 So that it flows more freely.
- 632 - 6 (1) Use two technicians. (2) prepare the cassettes with markers in advance, and (3) work quickly.
- 632 - 7 Two inches superior to the symphysis pubis.

### CHAPTER 3

- 633 - 1 Trachea
- 633 - 2 Cricoid, thyroid
- 633 - 3 Epiglottis
- 633 - 4 Anterior
- 633 - 5 Fifth
- 633 - 6 Cilia, secretions
- 633 - 7 Rings, posteriorly
- 633 - 8 Right, left
- 633 - 9 Left, left, right
- 634 - 1 Two, three
- 634 - 2 Lobar bronchi
- 634 - 3 Tertiary or segmental bronchi
- 634 - 4 After the tertiary bronchi
- 634 - 5 Alveolar ducts
- 634 - 6 Alveoli
- 635 - 1 Mediastinum
- 635 - 2 A triangular depression on the inner medial surfaces of each lung where the blood vessels and nerves enter and leave the lung.
- 635 - 3 One to 1 1/2 inches above the level of the sternoclavicular joints, bilaterally.
- 635 - 4 The diaphragm
- 635 - 5 Three, two
- 635 - 6 Fissures
- 636 - 1 (1) d  
(2) a  
(3) a  
(4) a d  
(5) b  
(6) c  
(7) b  
(8) d  
(9) d
- 637 - 1 The examination may not be successful.
- 637 - 2 (1) The patient may cough up the contrast material. (2) Coughing may create peripheral flooding, which results in difficulty in interpretations.
- 637 - 3 (1) Explain the examination. (2) Stress the importance of not coughing. (3) Instruct the patient to pant if there is the urge to cough.
- 637 - 4 Use two technicians and work quickly.
- 638 - 1 Three. PA or AP, lateral, and oblique.
- 638 - 2 RPO or LAO
- 638 - 3 LPO or RAO
- 638 - 4 To project the lung free from superimposition by the spine.
- 638 - 5 One. Because a lateral with both sides filled is not diagnostic due to superimposition.
- 638 - 6. The right lateral. (Your answer should have been one.)
- 638 - 7 To demonstrate: (1) those portions of the lung superimposed by the heart and (2) the trachea and primary bronchi superimposed by the spine.
- 639 - 1 The patient should be instructed to cough gently. Harsh coughing can cause the contrast material to go into the alveoli. Once there, it can only be eliminated by absorption.
- 639 - 2 Until the throat anesthesia has worn off because the material can be aspirated into the lungs rather than swallowed.

### CHAPTER 4

- 640 - 1 (a) Interstitial fluid containing lymphocytes, proteins, and waste by-products. (b) Functions as a transfer medium to supply cells with nutrients and oxygen and also fights off bacteria.
- 640 - 2 Throughout the body, in close contact with arteries and veins.
- 640 - 3 Into the left subclavian vein.
- 640 - 4 On the left side, beneath the diaphragm and behind the stomach.
- 640 - 5 To produce lymphocytes and store red blood cells.
- 641 - 1 Pericardium
- 641 - 2 Right and left atria
- 641 - 3 Right and left ventricles
- 641 - 4 (1) Superior and inferior venae cavae. (2) right atrium. (3) right ventricle. (4) right and left pulmonary arteries. (5) right and left pulmonary veins. (6) left atrium. (7) left ventricle. (8) aorta
- 641 - 5 Prevent backflow of blood.
- 641 - 6 Systole—blood being forced out of a chamber. diastole—blood entering a chamber.
- 642 - 1 Ascending aorta, arch of the aorta, descending aorta, and abdominal aorta.
- 642 - 2 (1) d  
(2) c  
(3) e  
(4) f  
(5) b  
(6) a
- 643 - 1. Left
- 643 - 2. Left subclavian
- 643 - 3 Right subclavian
- 643 - 4 Internal carotid, external carotid
- 643 - 5 Internal carotid
- 643 - 6 Transverse processes
- 643 - 7 Inferior cerebellar
- 643 - 8 Basilar
- 643 - 9 Circle of Willis
- 643 - 10 Anterior cerebral, anterior communicating
- 643 - 11 Posterior communicating, posterior cerebral
- 644 - 1. Striothalamic, internal cerebral, and great cerebral vein of Galen
- 644 - 2. Upper, mid, and basilar portions
- 644 - 3 Dural sinuses.
- 644 - 4 Along the margins of the falx cerebri
- 644 - 5 Internal jugular
- 644 - 6 Deep
- 644 - 7 No
- 644 - 8 At the base of the skull
- 644 - 9 Into the subclavian vein
- 644 - 10 Vertebral
- 644 - 11 Near the angle of the mandible
- 644 - 12. Subclavian
- 644 - 13. Innominate.
- 645 - 1 Concentration of iodine compound in solution
- 645 - 2 By using highly concentrated media
- 645 - 3 (1) The medium is of higher concentration. (2) the medium is injected at a more rapid rate. (3) the medium is introduced directly into areas containing susceptible tissue
- 646 - 1. (1) b, c  
(2) c.  
(3) a  
(4) b  
(5) b  
(6) a  
(7) a, c  
(8) b, c  
(9) a  
(10) b  
(11) c

- 647 - 1 (1) a  
(2) a  
(3) b  
(4) a  
(5) c  
(6) b, c
- 648 - 1 (1) Provides simultaneous fluoroscopic monitoring and filming, and (2) allows video tape recording of the injection, permitting immediate evaluation of the examination
- 649 - 1 F Any speed screen can be used with a film changer  
649 - 2 T  
649 - 3 F Depending on the unit, they can be used either vertically or horizontally  
649 - 4 T  
649 - 5 T  
649 - 6 T  
649 - 7 T  
649 - 8 F They can control either single-plane or biplane studies
- 650 - 1 (1) Reduced dosage of contrast medium, and (2) more accurate interpretation  
650 - 2 (1) Film fog, because of scatter radiation Use crossed grids except for projections using an angled C R Collimate the beams to the parts under study Reduce the exposure from that normally used for single-plane operation (2) Loss of detail, because of the large part-film distance on a lateral cerebral angiogram Increase the FFD up to 72 inches
- 651 - 1 T  
651 - 2 F Pressure injectors use specially designed disposable syringes that can withstand the pressure used for a particular study  
651 - 3 T  
651 - 4 T  
651 - 5 F The pressure settings are double-checked to avoid injuring the patient
- 652 - 1 The amount of contrast material delivered per unit of time  
652 - 2 By increasing the applied pressure  
652 - 3 To avoid excessive flowrate which could burst a catheter  
652 - 4 By varying the flowrate
- 653 - 1 It serves as a reference point from which adjustments can be made for phased injections
- 654 - 1 Sets maximum pressure or flowrate that can be generated  
654 - 2 The contrast medium in the catheter bypasses the patient's normal skin resistance and can cause the patient to be electrocuted from a small amount of leakage current from an electrical device Make sure all electrical appliances are grounded to a common ground
- 656 - 9 To prevent the contrast medium from entering the ventricles of the brain
- 657 - 1 The manometer is connected to the spinal fluid through a stopcock, allowing the fluid to flow into the calibrated tube. The height of the fluid in the tubes indicates the pressure.  
657 - 2 It is a means to indicate whether or not an obstruction is present in the vertebral canal The veins on one or both sides of the neck are compressed and released If an obstruction is present, the intraspinal pressure is not affected If an obstruction is not present, the pressure rises quickly during compression and drops quickly during release
- 658 - 1 It may be necessary for a technician to maintain the patient's head in a hyperextended position Also, the patient's head must not be allowed to drop below the level of the spine. This is to prevent the contrast medium from entering the ventricles and is usually done only when the upper thoracic or cervical spinal canals are being demonstrated  
658 - 2 You must lock the vertical fluoroscopic adjustment in place or, better still, use a myelographic stop to prevent contact between the fluoroscopic unit and needle Throughout the examination keep the needle in mind so that it is not accidentally touched Do not perform AP or posterior oblique projections If the needle is driven into the spinal nerves, permanent paralysis of a portion of the patient's lower anatomy could result  
658 - 3 The injection needle can immediately be withdrawn from the patient upon completion of the injection of medium  
658 - 4 Because the water-soluble medium can be absorbed by the body and does not need to be aspirated from the subarachnoid space when the exam is finished.  
658 - 5 Since the needle is removed from the patient, AP and posterior obliques may be included
- 659 - 1 Cerebrum  
659 - 2 Left, right, longitudinal fissure  
659 - 3 Gyri  
659 - 4 Frontal, parietal, temporal, occipital, insula  
659 - 5 Gray matter  
659 - 6 Ventricles  
659 - 7 Laterals  
659 - 8 Lateral, third  
659 - 9 Suprapineal recess  
659 - 10 Aqueduct of Sylvius  
659 - 11 Foramen of Magendie
- 660 - 1 Beneath the occipital lobe  
660 - 2 Vermis and two hemispheres (right and left)  
660 - 3 (1) Midbrain, (2) pons, and (3) medulla oblongata  
660 - 4 Cerebral peduncles  
660 - 5 Below the pons and above the foramen magnum  
660 - 6 Two bundles of fibers located on the anterior surface of the medulla oblongata
- 661 - 1 Meninges  
661 - 2 Pia mater  
661 - 3 Spinal  
661 - 4 Second sacral  
661 - 5 Arachnoid  
661 - 6 Subarachnoid  
661 - 7 Cerebrospinal fluid  
661 - 8 Cisterns  
661 - 9 Cauda equina  
661 - 10 Dura mater  
661 - 11 Dural sinuses  
661 - 12 Subdural  
661 - 13 Cisterna magna
- 662 - 1 (1) a  
(2) c  
(3) b  
(4) c  
(5) a  
(6) a, b, c  
(7) a  
(8) b  
(9) c  
(10) c

## CHAPTER 5

- 655 - 1 First cervical  
655 - 2 42, 45, 1  
655 - 3 Medullaris  
655 - 4 Ventral median, dorsal medial  
655 - 5 Spinal nerve  
655 - 6 Ventral nerve  
655 - 7 31 pairs  
655 - 8 Cauda equina  
655 - 9 Gray matter, white matter
- 656 - 1 Prone and lateral recumbent  
656 - 2 Both  
656 - 3 To straighten the lumbar lordosis, which helps the radiologist to more accurately locate the injection site and perform a more accurate puncture  
656 - 4 To place the spine parallel with the table for the same reasons as indicated in the answer to exercise number 3  
656 - 5 The patient is lateral recumbent with knees drawn up toward chin and shoulders drawn forward  
656 - 6 When there is an obstruction in the subarachnoid space.  
656 - 7 Lateral recumbent  
656 - 8 The head is flexed and the head end of the table is elevated



CHAPTER 6

- 663 - 1 (1) c
- (2) b, c
- (3) a, c
- (4) a
- (5) b
- (6) b
- (7) a
- (8) c
- (9) a
- (10) a

664 - 1 Body, origin, and insertion

- 664 - 2 (a) The proximal point of attachment, located on the more fixed structure
- (b) The distal point of attachment, located on the more movable structure

664 - 3 It has two—the supraglenoid tuberosity and the coracoid process

664 - 4 Heads

665 - 1 F It is called an antagonistic muscle group

665 - 2 T

665 - 3 T

665 - 4 F It supports a prime mover

665 - 5 T

665 - 6 F It is an agonistic muscle

665 - 7 T

- 666 - 1 (1) g
- (2) d
- (3) c, d
- (4) e
- (5) b
- (6) f
- (7) c
- (8) d
- (9) g
- (10) f

- (11) e
- (12) g
- (13) f, g
- (14) e
- (15) b
- (16) c, d

- 667 - 1 (1) c
- (2) f
- (3) f
- (4) c
- (5) a
- (6) b
- (7) d
- (8) c
- (9) a, b, c, e, g
- (10) d, f
- (11) a
- (12) c

668 - 1 Lucidum

668 - 2 Deeper (internal)

668 - 3 Root

668 - 4 Follicle

668 - 5 Dermis, subcutaneous

668 - 6 Sebum, lubricates

- 669 - 1 (1) i
- (2) g
- (3) e
- (4) d
- (5) a
- (6) a
- (7) c
- (8) e
- (9) g
- (10) n
- (11) d
- (12) b
- (13) i
- (14) b

**STOP -**

- 1. MATCH ANSWER SHEET TO THIS EXERCISE NUMBER.**
- 2. USE NUMBER 2 PENCIL ONLY.**

**EXTENSION COURSE INSTITUTE  
VOLUME REVIEW EXERCISE**

**90370 04 23**

**SPECIAL PROCEDURES**

**Carefully read the following:**

**DO's:**

1. Check the "course," "volume," and "form" numbers from the answer sheet address tab against the "VRE answer sheet identification number" in the righthand column of the shipping list. If numbers do not match, return the answer sheet and the shipping list to ECI immediately with a note of explanation.
2. Note that item numbers on answer sheet are sequential in each column.
3. Use a medium sharp #2 black lead pencil for marking answer sheet.
4. Write the correct answer in the margin at the left of the item. (When you review for the course examination, you can cover *your* answers with a strip of paper and then check your review answers against your original choices.) After you are sure of your answers, transfer them to the answer sheet. If you *have* to change an answer on the answer sheet, be sure that the erasure is complete. Use a clean eraser. But try to avoid any erasure on the answer sheet if at all possible.
5. Take action to return entire answer sheet to ECI.
6. Keep Volume Review Exercise booklet for review and reference.
7. If *mandatorily* enrolled student, process questions or comments through your unit trainer or OJT supervisor. If *voluntarily* enrolled student, send questions or comments to ECI on ECI Form 17.

**DON'Ts:**

1. Don't use answer sheets other than one furnished specifically for each review exercise.
2. Don't mark on the answer sheet except to fill in marking blocks. Double marks or excessive markings which overflow marking blocks will register as errors.
3. Don't fold, spindle, staple, tape, or mutilate the answer sheet.
4. Don't use ink or any marking other than a #2 black lead pencil.

**NOTE: NUMBERED LEARNING OBJECTIVE REFERENCES ARE USED ON THE VOLUME REVIEW EXERCISE.** In parenthesis after each item number on the VRE is the *Learning Objective Number* where the answer to that item can be located. When answering the items on the VRE, refer to the *Learning Objectives* indicated by these *Numbers*. The VRE results will be sent to you on a postcard which will list the *actual VRE items you missed*. Go to the VRE booklet and locate the *Learning Objective Numbers* for the items missed. Go to the text and carefully review the areas covered by these references. Review the entire VRE again before you take the closed-book Course Examination.

## MULTIPLE CHOICE

*Note to Student* Consider all choices carefully and select the *best* answer to each question

1. (600) Which structure of the mouth elevates during the process of swallowing?
  - a. Hard palate
  - b. Soft palate
  - c. Maxillae
  - d. Palatine bones
  
2. (601) Which salivary glands are the largest?
  - a. Submandibulars.
  - b. Submaxillaries.
  - c. Parotids
  - d. Sublinguals
  
3. (602) Which of the following structures serves as a passage for both food and air?
  - a. Oropharynx.
  - b. Nasopharynx
  - c. Laryngopharynx.
  - d. Proximal esophagus.
  
4. (602) The portion of the digestive system where peristalsis begins is
  - a. the pharynx
  - b. the esophagus
  - c. the stomach
  - d. the duodenum.
  
5. (603) Where would the location of the most inferior portion of the greater curvature of the stomach be in a patient of average build?
  - a. At the level of the iliac crests
  - b. 2 to 4 inches before the level of the iliac crests
  - c. At the level of the cardiac orifice.
  - d. At the level of the 8th rib.
  
6. (603) Which body habitus type is associated with the thin elderly patient?
  - a. Stenic.
  - b. Astenic.
  - c. Hypostenic
  - d. Hyperstenic
  
7. (604) The portion of the small bowel commonly referred to as the C-loop is the
  - a. distal third of the jejunum.
  - b. proximal half of the duodenum.
  - c. proximal portion of the duodenum bulb.
  - d. distal half of the duodenum and proximal jejunum.
  
8. (604) Which structure, when visualized on a small bowel series, generally marks the completion of the series?
  - a. Duodenum.
  - b. Jejunum.
  - c. Ileum.
  - d. Ileocecal valve.
  
9. (604) Which of the following structures is the longest portion of the small bowel?
  - a. Duodenum.
  - b. Jejunum.
  - c. Ileum.
  - d. Colon.
  
10. (605) Which portion of the large bowel is situated between the cecum and the hepatic flexure?
  - a. Sigmoid.
  - b. Descending.
  - c. Transverse.
  - d. Ascending.

11. (606) Which of the following structures normally prevents reflux into the common bile and pancreatic ducts?
- Duodenal papilla.
  - Sphincter of Oddi.
  - Sulcus intermedius
  - Pancreatic valve.
12. (606) Which duct is created if the pancreatic duct bifurcates?
- Common bile duct.
  - Cystic duct.
  - Duct of Santorini.
  - Duct of Bartholin.
13. (607) The main purpose of written preparation instructions given to a patient when that patient is scheduled for any contrast study of the digestive system is
- to indicate the appointment time.
  - to explain the examination to the patient.
  - to ensure that the structures under study are free of food, liquids, gas, or fecal materials.
  - to inform the patient of the type of laxative given and the nature of its action.
14. (607) If the laxative pills you gave the barium enema (BE) patient "didn't work," the radiologist will *first*
- reschedule the examination.
  - have the patient consume a tumbler of barotrast before the examination.
  - request a flat plate of the abdomen before fluoroscopy.
  - request adominal ultrasound scans be performed.
15. (608) Barium sulfate paste or creme preparations are used as a contrast medium for examination of the pharynx and esophagus because they
- adhere to the mucosa.
  - adhere to the bone.
  - neutralize acidity.
  - settle out of suspension
16. (608) Why might a patient be given a carbonated beverage during an upper GI series?
- To force barium from the stomach.
  - To distend the duodenum.
  - To visualize a suspected hiatal hernia.
  - To provide an air contrast study of the fundus.
17. (609) What size of syringe should be available to inject a contrast medium for sialography?
- 2.5 to 5cc.
  - 10 cc.
  - 20 cc.
  - 30 cc
18. (609) The entire sublingual salivary gland is usually demonstrated by using
- a PA tangential projection.
  - an AP tangential projection.
  - an inferosuperior or intraoral projection.
  - a lateral projection with the patient's face rotated 15° downward.
19. (610) Examinations of the pharynx using barium sulfate are best revealed, if the exposure is made at the instant that the
- patient is instructed to swallow.
  - patient begins to drink barium through a straw.
  - patient's Adam's apple begins to move anteriorly.
  - patient's Adam's apple reaches its most anterosuperior position.

20. (610) When radiographing a barium-filled esophagus, why should exposure factors be increased slightly over a regular chest technique?
- To permit visualization of the proximal esophagus.
  - To permit visualization of the lower esophagus.
  - Because barium obscures suspected fistulas.
  - Because barium reduces image contrast.
21. (611) Resuscitation equipment should be readily available during hypotonic duodenography to administer artificial respiration in case
- control of the voluntary muscles is lost.
  - the patient faints because of hyperoxygenation.
  - the mucosa of the duodenum becomes oversaturated.
  - the contrast medium does not pass into the duodenum, causing obstructive anoxia.
22. (611) An erect PA projection accomplished during an upper GI series would specifically reveal the
- profile view of the pylorus and the duodenal bulb.
  - stomach's relative position and shape.
  - relationship between the stomach and the retrogastric structures.
  - air-contrast view of the stomach's body, the pylorus, and the duodenal bulb.
23. (611) Which followup projection of an upper GI series shows an air-contrast view of body, pylorus, and duodenal bulb?
- RAO.
  - LAO.
  - RPO.
  - LPO.
24. (612) What method of contrast examination employs a substitute for the water with which the barium powder is mixed, thereby hastening stomach evacuation and motility?
- Intubation.
  - Retrograde.
  - Frequent interval.
  - Cold isotonic saline.
25. (612) What is the major advantage of performing a small bowel series by the intubation method?
- It evaluates the motility of the small bowel.
  - It hastens stomach evacuation and motility.
  - It is usually used to detect filling defects.
  - It allows visualization of a segment of small bowel without superimposition by other small bowel segments.
26. (613) What is the major difference between the direct and the two-stage methods of air-contrast studies of the large bowel?
- In the direct method, the barium is not evacuated before the air is introduced.
  - In the direct method, the barium is evacuated before the air is introduced.
  - In the two-stage method, the barium is not evacuated before the air is introduced.
  - In the two-stage method, a cleansing enema prior to the examination is not required.
27. (614) A correct step in the preparation of the barium liquid for colon examination is
- to use hot water about 180° F for mixing.
  - to pour water onto the barium sulfate, except when using prepackaged kits.
  - to use a single container for the preparation, except when using prepackaged kits.
  - to use a hydrometer to spot check the specific gravity and therefore thickness of the barium preparation.

28. (615) Which of the following projections to a barium enema best demonstrates an unobstructed view of the hepatic flexure?
- RAO.
  - LAO.
  - RPO.
  - PA.
29. (616) The gallbladder in a hypersthenic individual is usually
- superimposed over the spine.
  - located low in the abdomen near the spine.
  - located at the level of the right eighth rib.
  - located high in the abdomen, toward the lateral wall.
30. (616) Why is a fatty meal given to a patient during cholecystography?
- To stimulate bile production of the liver.
  - To check the function of the gallbladder.
  - To force out stones from the gallbladder.
  - To check for the patency of the biliary ductal system.
31. (617) Which method of performing cholangiography may also visualize the gallbladder?
- T-tube.
  - Operative.
  - Intravenous.
  - Transhepatic.
32. (617) What method of cholangiography is performed during a cholecystectomy, usually after the gallbladder has been removed, by having direct injection of contrast medium inserted into the biliary ducts?
- T-tube.
  - Operative.
  - Intravenous.
  - Transhepatic.
33. (618) The superior margins of the kidneys are located at approximately what level?
- Both kidneys at the level of the umbilicus.
  - Right kidney, 12th thoracic vertebra; left kidney, slightly higher.
  - Right kidney, third lumbar vertebra; left kidney, slightly lower.
  - Right kidney, third lumbar vertebra; left kidney; slightly higher.
34. (619) The juncture of the distal renal pelvis and proximal ureters occurs in the region between and just anterior to
- the trigone.
  - the sacro-iliac joints.
  - the first and second lumbar vertebra.
  - the 11th and 12th thoracic vertebra.
35. (620) From the bladder to the external urethra orifice, in what order are the three portions of the male urethra?
- Cavernous, prostatic, membranous.
  - Prostatic, cavernous, membranous.
  - Prostatic, membranous, cavernous.
  - Membranous, prostatic, cavernous.
36. (621) What symptom is associated with a technique reaction during the injection of a contrast medium?
- Burning and numbness at the injection site.
  - Feeling of warmth and flushing of the face.
  - Breathing difficulties or urticaria.
  - An increase or decrease in blood pressure.

37. (621) Which of the following conditions may indicate that a patient is having an anaphylactic reaction to contrast medium?
- a. Hypertension.
  - b. Hematoxinas.
  - c. Urticaria.
  - d. Hypotension.
38. (622) All statements that follow concern the importance of establishing and maintaining an emergency tray. Which statement is of *prime* importance?
- a. A checklist is essential.
  - b. The cart should be on rollers.
  - c. All possible equipment must be assembled on one cart and inventoried.
  - d. Necessary items must be readily available when and where needed.
39. (622) How often is it necessary to inventory items included in the emergency tray that is used for contrast media reactions?
- a. Daily.
  - b. Weekly.
  - c. Monthly.
  - d. Bimonthly.
40. (623) The laryngoscope is used by the physician to
- a. administer oxygen to a patient.
  - b. inflate and deflate the patient's lungs.
  - c. aid in the insertion of an endotracheal tube.
  - d. remove blood, mucus, or other material from the air passage.
41. (624) Concerning the patient preparation for an IVP, which procedure reduces the possibility of vomitus aspiration should a contrast medium reaction occur?
- a. Dehydration.
  - b. Fasting.
  - c. Cleansing the bowel.
  - d. Drinking carbonated beverages.
42. (624) What causes most cancellations of scheduled IVPs?
- a. Incomplete bowel evacuation.
  - b. Excessive dehydration.
  - c. Excessive fluid in the kidneys.
  - d. Presence of food or gas in the stomach.
43. (625) Before an injection of contrast medium for an IVP, you perform a scout film for several purposes. Which of the following is *not* one of these purposes?
- a. To discover the abnormalities that might later become obscured by the contrast media.
  - b. To make necessary preadjustments concerning exposure and positioning.
  - c. To determine whether the patient is radiologically "clean."
  - d. To decrease radiation exposure.
44. (626) Under what circumstances would a patient be provided with a gauze-covered container as a part of the postvoiding projection?
- a. In case a urinary stone is suspected.
  - b. To evaluate the mobility of the kidneys.
  - c. To measure the capacity of the bladder.
  - d. To check for gravitational emptying of the renal calyces.
45. (626) Which type and angulation of obliques are usually included with IVP radiographs?
- a. Anterior obliques; 10 to 15 degrees rotation.
  - b. Anterior obliques; 25 to 30 degrees rotation.
  - c. Posterior obliques; 10 to 15 degrees rotation.
  - d. Posterior obliques; 25 to 30 degrees rotation.

580

46. (626) Concerning IVP radiographs, how can the purpose of compression be partially satisfied for those patients who cannot tolerate compression of the ureters?
- Substitute a firm rubber pad.
  - Substitute a blood pressure cuff
  - Use the Trendelenburg position ( $10^{\circ}$  to  $20^{\circ}$ )
  - Angle the tube cephalically
47. (627) How much carbonated water is normally given to an 8-year old child to provide a better demonstration on an IVP?
- 2 grams.
  - 2 ounces.
  - 12 grams.
  - 12 ounces
48. (628) During a hypertensive IVP, the infusion of a mixture of saline and urea is administered
- to retard the secretion of urine.
  - to retain contrast medium in renal structures.
  - to evaluate filling deficiencies of the urinary bladder.
  - to compare contrast medium secretion rate of kidneys.
49. (629) The major advantage of a retrograde pyelogram is that an optimum demonstration of the renal pelvis and calyces can be obtained by
- using a non-injectable urographic medium.
  - using an injectable urographic medium.
  - introducing the contrast material through a catheter
  - controlling the amount and concentration of the contrast material.
50. (629) Which examination is accomplished when it is necessary to examine the soft tissue structures of kidneys?
- Nephrotomography.
  - Routine IVP.
  - Hypertensive IVP.
  - Retrograde pyelogram.
51. (630) Which of the following cystogram projections best demonstrates the posterior wall of the bladder?
- AP and Chassard-Lapine.
  - AP and Lateral.
  - Lateral and Chassard-Lapine.
  - Oblique and Chassard-Lapine.
52. (631) Which structures join the uterus with the ovaries?
- Fallopian tubes.
  - Cystic ducts.
  - Ducts of Rivinus.
  - Ducts of Bartholin.
53. (632) When possible, two technicians should perform radiographs that require contrast material to be injected into the uterus and fallopian tubes to
- lessen the patient's discomfort.
  - provide more accurate radiographs.
  - assist the examiner with the injection.
  - reduce scatter exposure.
54. (633) The trachea extends from the larynx to the level of the superior border of which thoracic vertebra?
- Third.
  - Fourth.
  - Fifth.
  - Sixth.
55. (633) The left bronchus differs structurally from the right bronchus in that the left bronchus
- is shorter.
  - is smaller in diameter.
  - contains six to eight cartilaginous rings.
  - enters the lung at the fifth thoracic vertebra level.



56. (634) What is another name for that part of the bronchial tree called the secondary bronchi?
- Lobar bronchi.
  - Tertiary bronchi.
  - Segmental bronchi.
  - Bronchioles, alveoli, or artria.
57. (635) Vessels enter and leave the lung at a point called
- the apex.
  - the hilum.
  - the mediastinum.
  - the inferior lobe.
58. (636) Select the bronchography method or methods most commonly used for introducing contrast medium into the lungs and offering selective visualization of a desired portion of the bronchial tree.
- Cricothyroid.
  - Supraglottic.
  - Intratracheal intubation.
  - Supraglottic and intraglottic.
59. (637) Beforehand, what should you tell a patient to do if an urge to cough is felt during a bronchogram procedure?
- Pant (take rapid, shallow breaths).
  - Perform the Valsalva maneuver.
  - Take long, deep breaths.
  - Relax completely.
60. (638) If both lungs are being examined during bronchography, which post-fluoro radiographs are usually *not* accomplished?
- PA and AP.
  - Anterior obliques.
  - Posterior obliques.
  - Laterals.
61. (639) For what period of time and why should food and liquids be withheld from a patient who has received a bronchogram?
- Four hours to prevent aspiration into the lungs.
  - Eight hours to prevent dilution of the contrast.
  - Until the patient coughs up the medium to prevent flocculation.
  - Until the anesthesia has worn off to prevent aspiration into the lungs.
62. (640) The spleen is located directly beneath the diaphragm and
- behind and to the left of the liver.
  - behind and to the left of the stomach.
  - in front and to the right of the duodenum.
  - in front and to the left of the gallbladder.
63. (641) The wave of relaxation of the heartbeat is called the
- systole.
  - diastole.
  - pulse.
  - pulse pressure.
64. (642) The arteries that supply the lower extremities are the
- tibial and peroneal.
  - arch and ascending portion of the aorta.
  - right and left common iliac.
  - popliteal and femoral.
65. (643) At the base of the brain, the carotid and vertebral systems join and form a juncture commonly known as
- Robinson's circle.
  - the circle of Weber.
  - the circle of Willis.
  - the circle of Haller.

66. (644) The part of the venous network of the head and neck that empties the upper, mid, and basilar surfaces of the hemispheres includes the anastomotic
- veins of Trolard and Labbe.
  - veins of Willis and Galen.
  - external and internal jugulars.
  - cerebellar veins.
67. (644) Which veins join to form the innominate vein?
- Vertebral and internal jugular.
  - Subclavian and external jugular.
  - Subclavian and internal jugular.
  - Vertebral and external jugular.
68. (645) "Weight-by-volume concentration" in angiographic contrast media refers to the
- iodine content of a particular medium.
  - concentration of iodine compound in a solution.
  - amount of contrast material used for a particular study.
  - amount of contrast material used, dependent on the patient's weight, for a particular study.
69. (646) Which of the three listed methods, if any, for introducing angiographic contrast media employs all of the following techniques at different times: (1) a catheter, sutured into position, may be used; (2) injection may be made by hand or automatically; and (3) a surgical cutdown may be performed?
- Percutaneous injection.
  - Selective catheterization.
  - Percutaneous-selective catheterization.
  - None of the above.
70. (646) What purpose does a heparinized saline serve during angiographic procedures?
- It prevents blood clotting of the catheter tip.
  - It reduces the possibility of contrast medium reactions.
  - It elevates the blood pressure to prevent shock.
  - It anesthetizes the injection site.
71. (647) Which of the following film changers, if any, has a high-filming rate along with little film waste?
- Cassette changer.
  - Roll film changer.
  - Cut film changer.
  - None of the above.
72. (648) What important benefit does a see-through film changer provide?
- It permits more film per second as compared to any other film changer.
  - Pressure injectors can be connected.
  - It contains ECG monitoring devices.
  - The area under study can be fluoroscopically monitored during filming.
73. (649) If angiographs show isolated areas of blurred images, where will the problem most likely originate?
- The pressure plate.
  - The floor anchoring device.
  - The program selector.
  - The receiver magazine.
74. (650) When using biplane filming during cerebral angiography, what should you increase to compensate for the problem associated with the later. action?
- Part-film distance.
  - Focal film distance.
  - Radiographic exposure.
  - Rate of injection.

75. (650) What problem is sometimes encountered when performing the lateral biplane cerebral angiogram?
- An increase in exposure.
  - The necessity for making right angle studies simultaneously.
  - A reduction in scatter radiation.
  - The loss of detail due to the increased part-film distance
76. (651) The purpose of the heating system in a pressure injector is
- to maintain a catheter at or near body temperature.
  - to allow the use of special disposable syringes.
  - to maintain the contrast material at or near the body temperature.
  - to thermostatically turn the injector off if leakage current is detected
77. (652) In reference to pressure injections, flowrate is
- the amount of contrast material delivered per unit of time.
  - the amount of pressure applied to deliver the contrast material.
  - the maximum delivery rate of a pressure injector.
  - a parameter to consider when selecting a catheter.
78. (653) When applied to a pressure injector, the R-wave is used
- as a reference point.
  - to determine the systolic period.
  - to determine the diastolic period.
  - as an alarm system to detect potential electrical hazards.
79. (654) What is the purpose of the electrical monitoring alarm circuit found in pressure injectors?
- It gives an alarm if the wrong voltage is being used.
  - It detects an unsafe ground condition.
  - It functions as a voltage compensator.
  - It indicates a voltage decrease in the incoming line.
80. (655) The spinal cord terminates in a sharply constricted cone known as the
- |                       |                     |
|-----------------------|---------------------|
| a. medulla oblongata. | c. filum terminale. |
| b. conus medullaris.  | d. cauda equina.    |
81. (656) What action should be taken to prevent the contrast material from entering the ventricular system of the brain during a cisternal puncture?
- Elevate the foot end of the table 15°.
  - Immediately after injection hyperflex the head.
  - Immediately after injection hyperextend the head and hold it in place.
  - Maintain hyperextension and placement of the head during and after injection.
82. (656) Contrast material is introduced into the subarachnoid space using a spinal puncture with the patient prone. A rolled pillow or similar object is placed under the patient's lower abdomen to
- straighten the lumbar lordosis.
  - make the patient more comfortable.
  - reduce the spaces between the spinous processes.
  - allow the medium to gravitate to the presacral area.

83. (657) The radiologist may ask you to compress the blood vessels along the side of the patient's neck during a lumbar puncture to
- locate the cisternal magna.
  - test for the normal circulation time.
  - test for an obstruction in the vertebral canal.
  - measure the exact amount of cerebrospinal fluid.
84. (658) What is the major advantage of using a special water-soluble contrast medium instead of an oily-viscous medium when performing myelography?
- The examination time is greatly reduced.
  - The post-fluoro projections can include AP and posterior obliques.
  - The patient does not require hospitalization after the examination.
  - The needle can be immediately withdrawn after the injection of medium
85. (658) How do postfluoro projections differ from a myelogram injected with a special water-soluble contrast media as compared to a myelogram injected with an oily-viscous medium?
- The patient remains prone during projections.
  - The patient is placed in a head-down Trendelenburg position
  - The patient's head and neck should be hyperflexed.
  - AP and posterior obliques may be included.
86. (659) What structure divides the cerebrum into two hemispheres?
- Gyrus.
  - Major sulcus.
  - Transverse fissure
  - Longitudinal fissure.
87. (659) Which of the following secretes cerebrospinal fluids?
- Ventricles.
  - Spinal canal.
  - Hypothalamus.
  - Corpus callosum.
88. (660) What three structures comprise the brain stem?
- Medulla oblongata, pons, and vermis.
  - Midbrain, pons, and medulla oblongata.
  - Midbrain, cerebrum, and spinal canal.
  - Cerebellum, cerebrum, and occipital lobe.
89. (661) Which of the following statements best describes the pia mater?
- It contains a periosteal layer.
  - It is the outermost meningeal layer.
  - It closely covers the brain and spinal cord.
  - It lies between the arachnoid membrane and the dura mater.
90. (661) What are the wide, deep regions of the subarachnoid space called?
- Cisterns.
  - Dura cavities.
  - Dural sinuses.
  - Subarachnoid cavities.
91. (662) One way that cerebral pneumography differs from computed tomography of the brain is that cerebral pneumography
- is a non-invasive procedure.
  - is always an invasive procedure.
  - uses a positive contrast medium.
  - best demonstrates small differences in tissue densities.

92. (663) Visceral muscles are classified as being what type of muscle?
- Voluntary.
  - Skeletal.
  - Cardiac.
  - Smooth.
93. (664) An insertion is that part of a skeletal muscle that is
- the proximal point of attachment.
  - the distal point of attachment.
  - the bulk of tissue found in the muscle body.
  - the tendon that connects the muscle origin to bone.
94. (665) Which muscles, at some time during the extension and flexion of the elbow, perform antagonistic actions and thereby provide coordinated movements?
- Brachialis and the brachioradialis.
  - Triceps brachii and the brachialis.
  - Biceps brachii and the triceps brachii.
  - Brachioradialis and the triceps brachii.
95. (666) Which skeletal muscle has its origin in the anterior superior iliac spine?
- Gastrocnemius.
  - Pectoralis major.
  - Serratus anterior.
  - Quadriceps femoris.
96. (667) The stratum granulosum is composed of two or three rows of flattened cells and is located, in relation to other structural sublayers of the skin, between the
- epidermis and the dermis.
  - second and third layers of the epidermis.
  - stratum lucidum and the stratum spinosum of the epidermis.
  - deepest layer of the epidermis and the papillary layer of the dermis.
97. (668) What is the name of the small muscles which insert into the hair follicles, and where do they originate?
- Erector from the dermis.
  - Arrector from the dermis.
  - Arrector from the epidermis.
  - Erector from the sebaceous gland.
98. (669) Which gland has a butterfly appearance, regulates the metabolism, and has two lobes connected by an isthmus?
- Thyroid.
  - Exocrine.
  - Endocrine.
  - Parathyroid.
99. (669) Which of the endocrine-type glands reaches its maximum development during the early years of childhood and is responsible, in part, for the production of antibodies?
- Pituitary.
  - Adrenal.
  - Gonad.
  - Thymus.
100. (669) Which estrogen prepares the uterus for implantation of a fertilized ovum?
- Androgens.
  - Testosterone.
  - Progesterone.
  - Andosterone.

END OF EXERCISE

## STUDENT REQUEST FOR ASSISTANCE

### PRIVACY ACT STATEMENT

**AUTHORITY:** 10 USC 2012 and EO 9367. **PRINCIPAL PURPOSES:** To provide student assistance as requested by individual students. **ROUTINE USES:** This form is shipped with ECI course package. It is utilized by the student, as needed, to place an inquiry with ECI. **DISCLOSURE:** Voluntary. The information requested on this form is needed for expeditious handling of the student's need. Failure to provide all information would result in slower action or inability to provide assistance to the student.

### SECTION I: CORRECTED OR LATEST ENROLLMENT DATA: (Mail to ECI, Gunter AFS AL 36118)

1 THIS REQUEST CONCERNS COURSE (1 - 6)	2 TODAY'S DATE	3 ENROLLMENT DATE	4 AUTOVON NUMBER
5 SOCIAL SECURITY NUMBER (7 - 15)	6 GRADE/RANK	7 NAME (First initial, second initial, last name)	
-		(17)	(18) (19-32)
8 ADDRESS <i>(OJT Enrollees - Address of unit training office with zip code. All others - current mailing address with zip code)</i>		(33-53)	
		(54-75)	
9 NAME OF BASE OR INSTALLATION IF NOT SHOWN ABOVE			10 TEST CONTROL OFFICE ZIP CODE/SHRED (33 - 38)

### SECTION II: REQUEST FOR MATERIALS, RECORDS, OR SERVICE

*(Place an 'X' through number in box to left of service requested)*

### FOR ECI USE ONLY

1 Request address change as indicated in Section I.	16	
2 Request Test Control Office change as indicated in Section I.	33	
3 Request name change/correction (Provide Old or Incorrect data)	G	
4 Request Grade/Rank change/correction.	K	Vol 33 - 35 GR 36 - 38
5 Correct SSAN. (List incorrect SSAN here) (Correct SSAN should be shown in Section I)	M	33 - 34 35 - 40
6 Extend course completion date. (Justify in REMARKS)	N	33 - 38
7 Request enrollment cancellation.	P	Vol 33 - 35 TC 36 - 37
8 Send VRE answer sheets for Vol(s): 1 2 3 4 5 6 7 8 9 Originals were: <input type="checkbox"/> Not received <input type="checkbox"/> Lost <input type="checkbox"/> Misused	Q	33 - 34 Volume 35 37
9 Send course materials. (Specify in REMARKS) <input type="checkbox"/> Not received <input type="checkbox"/> Lost <input type="checkbox"/> Damaged	Q	Q Q
10 Course exam not yet received. Final VRE submitted for grading on _____ (date).	38	39 - 42
11 Results for VRE Vol(s) 1 2 3 4 5 6 7 8 9 not yet received. Answer sheet(s) submitted _____ (date).	1	
12 Results for CE not yet received. Answer sheet submitted to ECI on _____ (date).	2	
13 Previous inquiry ( <input type="checkbox"/> ECI Fm 17, <input type="checkbox"/> Ltr, <input type="checkbox"/> Msg) sent to ECI on _____ (date).	3	39 - 42
14 Give instructional assistance as requested on reverse.	16	
15 Other (Explain fully in REMARKS)		

REMARKS (Continue on Reverse)

OJT STUDENTS must have their OJT Administrator certify this request

I certify that the information on this form is accurate and that this request cannot be answered at this station (Signature)

ALL OTHER STUDENTS may certify their own requests.

**SECTION III REQUEST FOR INSTRUCTOR ASSISTANCE**

**NOTE.** Questions or comments relating to the accuracy or currency of subject matter should be forwarded directly to preparing agency. For an immediate response to these questions, call or write the course author directly, using the AUTOVON number or address in the preface of each volume. All other inquiries concerning the course should be forwarded to ECI.

**VRE Item Questioned**

Course No. \_\_\_\_\_

Volume No. \_\_\_\_\_

VRE Form No. \_\_\_\_\_

VRE Item No. \_\_\_\_\_

Answer You Chose \_\_\_\_\_  
(Letter)

Has VRE Answer Sheet  
been submitted for grading?

Yes  No

**REFERENCE**

(Textual reference for the  
answer I chose can be  
found as shown below)

In Volume No. \_\_\_\_\_

On Page No. \_\_\_\_\_

In  left  right column

Lines \_\_\_\_\_ Through \_\_\_\_\_

**MY QUESTION IS**

**REMARKS**

ADDITIONAL FORMS 17 available from trainers, OJT and Education Offices, and ECI. Course workbooks have a Form 17 printed on the last page.

90370 05 8402


CDC 90370

# RADIOLOGY TECHNICIAN

(AFSC 90370)

Volume 5

*General Information and Radiation Therapy*



Extension Course Institute  
Air University 529



Prepared by  
MSgt Steven G. Hayes  
(AUTOVON 736-2809/2647)

Reviewed by  
Maxine J. Robinson

Edited by  
Virginia J Fisher



SCHOOL OF HEALTH CARE SCIENCES USAF (ATC)  
SHEPPARD AIR FORCE BASE TEXAS 76311

EXTENSION COURSE INSTITUTE (AU)  
GUNTER AIR FORCE STATION, ALABAMA 36118

530

## Preface

IF WE WERE to attempt to briefly describe a radiologic technologist, we would say that a radiologic technologist has the technical and the supervisory know-how to manage a radiology department. The first four volumes of this CDC have mostly been oriented toward technical aspects. However, as you progress in this career field you will be rewarded with promotions and increased responsibilities. More often, those responsibilities mean that you will supervise personnel of various radiology functions. This volume is designed to help you manage those areas by explaining duties and procedures. In Chapter 1, we cover five areas you will come in contact with through either direct performance or supervision. They include (1) supply procedures, (2) administration procedures, (3) quality assurance, (4) career field progression, and (5) the Air Force Occupational Safety and Health (AFOSH) Program. All these sections of Chapter 1 are vital to the overall success of a radiology department and to the performance of your personnel.

Chapter 2 deals with a branch of radiology—radiation therapy. We include this chapter for two very good reasons. First, if you are going to be assigned to a radiotherapy section, the information we provide gives you an understanding of its purpose, methods of treatment, and your responsibilities while performing radiotherapy duties. Second, if you become the NCOIC or superintendent of a department that has a radiotherapy treatment facility, you will be assigning personnel to that section and you may have direct supervisory responsibilities over them. Regardless of the reason, you will need to know about radiation therapy.

The inclusion of names of any specific commercial product, commodity, or service in this publication is for information purposes only and does not imply indorsement by the Air Force.

This volume is valued at 12 hours (4 points).

Material in this volume is technically accurate, adequate, and current as of November 1983.

# Contents

	<i>Page</i>
<i>Preface</i> . . . . .	<i>iii</i>
<i>Chapter</i>	
1 <b>Managing Department Functions</b> . . . . .	1
2 <b>Radiation Therapy</b> . . . . .	32
 <i>Bibliography</i> . . . . .	 38
<i>Answers for Exercises</i> . . . . .	39

## Managing Department Functions

AS YOU advance in the radiology career field, you will assume additional duties and responsibilities in managing and supervising. This chapter is designed to help you with those responsibilities. We have included sections of supply procedures, administration procedures, quality assurance, career field progression, and safety. We begin with supply procedures.

### 1-1. Supply Procedures

No matter how proficient you and other radiology personnel are, you cannot effectively function as a department without the proper supplies and equipment. This materiel must be budgeted for, ordered, and accounted for until it is either consumed or turned in. This section is designed to assist you with these procedures.

**800. Define property responsibility and differentiate among the three levels of property responsibility.**

**Property Responsibility.** Property responsibility is the obligation of Air Force members to care for Air Force property with which they are associated. The obligation to care for a particular property item is not limited to the individual who has signed for the item. It includes anyone who uses, supervises the use of, or otherwise comes in contact with the item. For example, the fact that you have not signed for the X-ray machines in your department does not relieve you from the responsibility of properly caring for the units. By "property caring for property," we mean that you should take positive action to prevent the loss, damage, or destruction of the equipment. Of course, it is difficult to "lose" an X-ray machine, but many smaller items of equipment can easily become lost.

**Levels of Responsibility.** There are three levels of property management responsibility: command, supervisory, and custodial. It is possible for one individual to carry more than one of these types of responsibility at the same time.

**Command responsibility.** Commanders at all echelons are charged with the responsibility of insuring that only qualified personnel are selected and assigned as accountable officers. They are responsible for seeing that there is space for proper storage of medical supplies and equipment, that prescribed records are kept, and that supply discipline is understood and exercised.

**Supervisory responsibility.** This applies to anyone who exercises supervision over property received, in use, in transit, in storage, or undergoing modification or repair.

The supervisor must select qualified personnel to do the work under his or her control and must train them in supply procedures to insure compliance with Air Force regulations governing property. Supervisors must also indoctrinate workers in the principles of supply discipline.

**Custodial responsibility.** Anyone who has acquired possession of Government property has custodial responsibility for it. This person is personally responsible for such property if it is issued for official use, whether or not she or he has signed a receipt for it and is personally responsible for the storage, use, custody, or safeguarding of any property under his or her direct control.

"Finders keepers" may apply in some circumstances but not to Government property. If you find Government property that apparently has been lost, stolen, or abandoned, you must assume custodial responsibility for it and protect or care for it until it can be returned to the proper authorities.

### Exercises (800):

1. What is property responsibility?
2. What responsibility do you have regarding all equipment within the X-ray department, even though you may not have signed for it?
3. Match the responsibility in column B with the appropriate statement in column A by placing the letter of the column B item in the space provided in column A. Each column B item may be used once or more than once.

Column A	Column B
— (1) Responsibility for property that is undergoing modification	a Command responsibility
— (2) Responsibility for property that has been abandoned	b Supervisory responsibility
— (3) Responsibility for training personnel about supply discipline	c Custodial responsibility
— (4) Responsibility for all base property	d Responsibility of all personnel
— (5) Responsibility for stocking supplies	

**801. Explain some procedures of the responsibilities of a property custodian.**

**Property Custodian.** Every radiology department has a *property custodian* who is responsible for requesting and accounting for all *equipment* within the department. This person is designated by the director of base medical services (DBMS) upon the recommendation of the person's supervisor. Although the individual appointed need not necessarily be the senior in grade in the department, he or she must be a mature person and well aware of the responsibilities of the position.

**Responsibility of the Property Custodian.** Each new property custodian must sign a custody receipt for all equipment currently used by that department. This receipt is called the custody receipt/locator list. All medical and nonmedical equipment on hand and due-in for the department is listed in stock number sequence. The item description is also included, as well as a locally-assigned item location code for some items. Several items also have index numbers and serial numbers to help in medical equipment repairs and in maintenance and control of the equipment. The transfer of property should not be taken lightly. The new custodian should personally count each and every item for which he or she is signing. He or she also should check closely the serial numbers and index numbers. By signing and dating the listing, the custodian assumes responsibility for all in-use items in the quantities indicated and verifies the requirement for all items due-in on the listing. The property custodian must insure, by spot check and periodic inventory, that all property is physically on hand or otherwise accounted for. Physical inventories of equipment are done once each year or more often if determined necessary by the medical materiel manager or higher authority. These inventories may be done by the property custodian or by an inventory team. Before a property custodian is relieved from duty, transferred, separated from service, or absent from the department for over 45 days, an authorized successor must be appointed. A custodian cannot be relieved of custodial responsibilities until he or she is officially cleared by the medical equipment management office (MEMO).

**Requesting equipment.** Every item of equipment, be it a replacement item or increased authorization, must be requested on an AF Form 601, Equipment Action Request (fig. 1-1) This form may be used for the following reasons.

- a. Initial issue or replacement of nonexpendable equipment.
- b. Turn-in of excess or unserviceable equipment.
- c. Request for allowance or authorization change.
- d. Transfer of equipment between property custodians.

Written instructions for the preparation of this form are found on the back of the form. It may be a good idea to coordinate your preparation of the form with the MEMO to insure compliance with local policy. Also bear in mind that equipment items must be budgeted individually. Therefore, you should plan well in advance to request equipment, to insure that the item(s) are included in the annual budget, and to be sure that funds are available. Requests for new equipment or increased authorizations for existing

equipment must be fully justified. Do not use long, flowery sentences in the justification. Get to the point and be specific. The justification should include answers to these questions.

- Why do you need the equipment?
- How have you done without the equipment before?
- How will the mission of the medical facility be affected if you do not receive the equipment?
- Will the cost of the new equipment be offset by a reduction in other resources? If so, by how much?

Additional information may be found in AFR 167-11, *Serving Medical Material Customers*. Submit the completed 601 to MEMO for further action. If the item costs less than \$3000, the DBMS has final approval authority. If the cost is above \$3000, the request must be approved by DBMS, the major command (MAJCOM), and the Surgeon General's Office (SGO).

**Exercises (801):**

1. Who requests and accounts for all equipment within a radiology department?
2. Generally, how is a property custodian selected?
3. When a new property custodian is assigned, who should personally perform an inventory of all assigned equipment?
4. What is the usual interval for a routine physical inventory of equipment?
5. What office officially relieves a property custodian of his or her custodial responsibilities?
6. What form is required for all equipment requests?
7. When preparing an AF Form 601, why should you coordinate with MEMO?

**802. Define pecuniary liability and explain procedures associated with it.**

**Pecuniary Liability.** We in the Air Force also have "pecuniary liability" when it comes to caring for property.

TO	FROM	SIGNATURE	DATE	ACTION TAKEN																																			
				APPROVED <input type="checkbox"/> DISAPPROVED <input type="checkbox"/>																																			
				APPROVED <input type="checkbox"/> DISAPPROVED <input type="checkbox"/>																																			
				APPROVED <input type="checkbox"/> DISAPPROVED <input type="checkbox"/>																																			
				APPROVED <input type="checkbox"/> DISAPPROVED <input type="checkbox"/>																																			
				APPROVED <input type="checkbox"/> DISAPPROVED <input type="checkbox"/>																																			
				APPROVED <input type="checkbox"/> DISAPPROVED <input type="checkbox"/>																																			
1 CUSTODIAN REQUEST NO		8 IN-USE DOC NO		9 NATIONAL STOCK NO OR PART NO																																			
				18 ACTION REQUESTED																																			
				A. AUTHORIZATION INCREASE <input type="checkbox"/> ADD NEW <input type="checkbox"/> REDUCE <input type="checkbox"/> DELETE <input type="checkbox"/>																																			
2 CMO	3 FAD	4 LJC	5 BUD	10 USE CODE																																			
				11 PRICE																																			
				12 U/I																																			
				13 ENRCD																																			
8. CUSTODIAN SIGNATURE				14 EQUIP CODE																																			
				15 NOMENCLATURE																																			
				8 ISSUE/DUE OUT																																			
				ADVICE CODE ( )																																			
				INITIAL ISSUE <input type="checkbox"/> REPLACEMENT <input type="checkbox"/> CANCEL DUE OUT <input type="checkbox"/>																																			
				C TURN-IN (Complete all applicable blocks)																																			
				CONDITION																																			
				STATUS																																			
				YES																																			
				NO																																			
				18 ALLOWANCE IDENTIFICATION																																			
				17 QUANTITY																																			
				SERVICEABLE																																			
				COMPLETE (List missing parts in Block 19)																																			
				REPARABLE																																			
				CALIBRATION REQUIRED																																			
				CONDEMNED																																			
				CLEAN, PAINT ETC																																			
				UNKNOWN																																			
				DISASSEMBLY REQUIRED																																			
				DATE AVAILABLE FOR PICKUP																																			
7 I certify that I have evaluated this request and the action herein is required																																							
19 JUSTIFICATION AND ITEM DESCRIPTION																																							
20 REVIEWING AUTHORITY COMMENTS																																							
21 ORGN																																							
22 UKC																																							
23 LEVEL																																							
24 DET																																							
25 WPM																																							
26 EMOLC																																							
27 SUPPLY CONTROL NO																																							
28 CEMO CONTROL NO																																							
29 AFLC CONTROL NO																																							
1	2	3	4	5	6	7	8	9	10	11	12	13	14	15	16	17	18	19	20	21	22	23	24	25	26	27	28	29	30	31	32	33	34	35	36	37	38	39	40
41	42	43	44	45	46	47	48	49	50	51	52	53	54	55	56	57	58	59	60	61	62	63	64	65	66	67	68	69	70	71	72	73	74	75	76	77	78	79	80

AF FORM 601 NOV 81

REPLACES AF FORMS 601A, APR 66 AND 601B, APR 70 WHICH WILL BE USED

EQUIPMENT ACTION REQUEST  
(See Instructions on Reverse)

Figure 1-1 AF Form 601

This means that an individual may have to pay for an item of equipment if the item is lost, damaged, or destroyed as a result of maladministration or negligence in the use, care, custody, or safekeeping of the item. In Air Force language, the "admission of pecuniary liability" by an individual implies that he or she is willing to pay the Air Force for the lost, damaged, or destroyed property.

**Relief from property responsibility.** You may be relieved of the responsibility for a particular piece of property in a number of ways. For example, you may turn the property in to supply as excess; or you may transfer it to another person. However, if the property becomes destroyed, damaged, or lost, the procedure is not quite so simple. If you admit pecuniary liability, the least troublesome way to settle a monetary obligation is to pay in cash. The procedure is very simple—DD Form 1131, Cash Collection Voucher, is filled out, and you pay the Government in cash for the property. This collection method can be used only if the amount involved is less than \$500.

If you admit pecuniary liability but do not have the money to pay in cash, DD Form 362, Statement of Charges for Government Property Lost, Damaged or Destroyed, is used. The form simply authorizes the Government to deduct the amount from your paycheck. DD Form 362 is used only if the amount involved is less than \$500.

When an individual does not admit pecuniary liability or when the amount is \$500 or more, an AF Form 198, Report of Survey for Air Force Property, must be prepared. Two commissioned officers conduct the report of survey. They are the *appointing authority* and the *investigating officer*. The appointing authority is a commander or other officer having jurisdiction over the individual who has custodial responsibility for the property in question. The appointing authority usually appoints an investigating officer, whose duty it is to make a detailed and impartial investigation (survey) of the circumstances connected with the loss, damage, or destruction of property described on AF Form 198.

A survey officer is not necessarily appointed in every instance. When circumstances do not appear to warrant such a step, the appointing authority may make her or his own recommendations and forward the report of survey to the base commander for review and approval. As a result of the findings, the person responsible for the custody of the property in question may or may not be required to pay for it.

**DD Form 2090, Government Property Loss or Damage Survey Certificate.** This certificate may be used when there is no evidence of gross negligence, willful misconduct, or deliberate unauthorized use of equipment on the part of known or unknown persons resulting in loss of damage to Air Force property. DD Form 2090 may only be used for items costing less than \$500 and when no apparent willful illegalities have occurred that resulted in the loss or damage to the property.

#### Exercises (802):

1. What is pecuniary liability?

2. If you admit pecuniary liability for an Air Force property item costing \$490 that you lose, how may you settle your monetary obligation?
3. When must an AF Form 198, Report of Survey of Air Force Property, be prepared?
4. When an AF Form 198 is prepared, what action does the investigating officer take?
5. When could you use a DD Form 2090?

#### 803. Differentiate among categories of medical materiel.

**Classification of Medical Materiel.** Medical materiel may be in the form of equipment or supplies. Equipment items are *nonexpendable* and must be authorized. Supplies are *expendable* and need no authorization. Materiel with which you should be familiar is classified into one of the three equipment and two supply categories described below.

**Investment medical equipment.** Investment medical equipment denotes those items with a unit cost of \$3,000 or more and a life expectancy of 5 years or longer. Some examples are an X-ray machine and an automatic processor.

**Expense medical equipment.** An item classified as expense medical equipment is one with a unit cost of at least \$300, but less than \$3,000, and a life expectancy of at least 5 years.

**Nonmedical equipment.** Nonmedical equipment is those items that meet the criteria established in AFM 67-1, *USAF Supply Manual*, Volume IV, Part 1, *Air Force Equipment Management Systems*. Further, equipment management codes (EMC) assigned nonmedical equipment in Table of Allowances (TA) 001 and guidance are provided in AFM 67-1, Volume II, Part 2, *USAF Standard Base Supply System*, Chapter 22. The appropriate codes must be used to determine which items require accountable records. Both volumes are normally maintained at Base Supply. Thus, nonmedical equipment cannot be classified on the basis of an assigned dollar value. Examples of nonmedical equipment are a typewriter, a desk, and other office equipment.

**Expendable medical supplies.** Expendable medical supplies are *consumable* and *durable*. A consumable supply item loses its identity when used, cannot be reused for the same purpose, or is not durable enough to last 1 year. Drugs, X-ray film, adhesive tape, processing solutions, and contrast media are examples. A durable supply item maintains its identity when used, usually has a life expectancy of at least 1 year, but does not qualify as an

equipment item Instruments, such as scissors and hemostats are examples of durable supplies.

**Nonmedical supplies.** These supplies are items that are nonmedical in nature. Some examples are pencils, ballpoint pens, paper towels, typing paper, and typewriter ribbons

**Exercises (803):**

- Match the materiel category in column B with the appropriate statement or term in column A by placing the letter of the column B item in the space provided in column A. Each column B item may be used once, more than once, or not at all. In addition, two or more column B items may match a single column A entry.

Column A	Column B
___ (1) A \$40 000 portable X-ray machine	a Investment medical equipment
___ (2) A \$45 box of contrast media	b Expense medical equipment
___ (3) Box of 8 x 10 film	c Nonmedical equipment
___ (4) Box of paper clips	d Expendable medical supplies (consumable)
___ (5) Loses its identity when used	e Expendable medical supplies (durable)
___ (6) Life expectancy of at least 5 years	f Nonmedical supplies
___ (7) Must be authorized	
___ (8) 90-second automatic processor	
___ (9) Cannot be classified on the basis of an assigned dollar value	

**804. Differentiate among the parts of a Federal Supply Catalog and a national stock number (NSN).**

**The Federal Supply Catalog.** The Federal Supply Catalog consists of a series of publications listing items of medical and nonmedical material which are used by the Army, Navy, and Air Force and are supplied by the Defense Personnel Support Center (DPSC). These publications are divided into subsections called identification list (IL) and management data lists (ML).

**Identification list.** A separate identification list is published for each Federal Supply Group (FSG) or Federal Supply Class (FSC). It is identified by the letters IL. The "6525" series, illustrated in figure 1-2, lists X-ray equipment and supplies. Contained in the IL is an alphabetical index (fig. 1-3) by Federal item names, a national stock number index (fig. 1-4) cross-referenced with IL index numbers, and descriptive data on each item (fig. 1-5). The index numbers are used solely as a locator device; they are not to be used instead of the national stock number or to requisition items.

Each IL is supplemented by a consolidated alphabetical index that facilitates the location of an item when its

national stock number is not known. This index includes Federal item names, synonyms, and trade names that are referenced to the FSG or FSC of the IL in which the item is listed

**Management data list.** A separate management data list, identified by the letters ML, is published for each IL. Contained in this publication are the national stock number, unit of issue, unit cost, packaging information, and weight and cubage for all items listed in the IL. It also contains a mandatory substitution list for items that have been deleted from the Federal supply list. Figure 1-6 shows a page from the ML for X-ray.

**National Stock Number.** The national stock number (NSN) is a 13-digit number assigned to each item of supply. It is arranged in groups of 4, 2, 3, and 4 digits separated by hyphens, e.g., 6525-00-721-9814. Each group of digits has a specific meaning (fig. 1-7).

**Federal Supply Group.** The first two digits of the NSN represent the FSG. Using the example shown in figure 1-7, the 65 designates the item as being in the medical supply group.

**Federal Supply Class.** The first four digits of the NSN further identify the FSC. Using the example again, 6525 designates the item as X-ray equipment or supplies for medical, dental, or veterinary use.

**North Atlantic Treaty Organization (NATO) code.** The next two digits represent the NATO code numbers.

**National Item Identification Number (NIIN).** The last seven digits of the NSN represent the NIIN which uniquely identifies the individual stock item. In our example, the number is represented by the digits 721-9814, which is the numerical designation of a 10- by 12-inch radiographic film cassette

**Exercises (804):**

- Listed in column A are specific sections or information that are found in one of the Federal Supply Catalog publications in Column B. Indicate which publication of column B you should research to find the section or information of column A by placing the letter from column B in the space it relates to in column A. Each column B item may be used more than once

Column A	Column B
___ (1) Unit cost of an item	a Identification List (IL)
___ (2) Unit of issue	b Management Data List (ML)
___ (3) Alphabetical index by Federal item names	
___ (4) NSN index	
___ (5) Weight and cubage	
___ (6) Descriptive data of each item	
___ (7) Mandatory substitutions	



C-6525-IL



# FEDERAL SUPPLY CATALOG

# IDENTIFICATION LIST

FSC 6525

**X-RAY EQUIPMENT and  
SUPPLIES: MEDICAL,  
DENTAL, VETERINARY**

**C  
O  
N  
S  
O  
L  
I  
D  
A  
T  
E  
D**

## IMPORTANT NOTICE

SUPERSEDES C-6525-IL, DATED 1 FEBRUARY 1979  
SEE PAGE 1 FOR SPECIAL NOTE ON NATIONAL STOCK NUMBERS

**1 JUNE 1981**

Figure 1-2 Cover page for the 6525 Identification List

## ALPHABETICAL INDEX

*Item names in capital letters are approved Federal item names.*

Name	A-B	Index No.	Name	G-H	Index No.
ADAPTER, DENTAL X-RAY FILM.....		5	Graph-O-Mat Developer Starter-Liquid.....		4695
Adjustable Mobile Vinalead Screen.....		4635	GRID, RADIOGRAPHIC.....		4090,4095
Auveloper.....		4400	HANGER, X-RAY FILM.....		4110-4140
Bin, Film.....		245-255	Hanger Rack, X-Ray Film.....		4485
Bite Block Adapter Film Holder.....		4175	High Voltage Bleeder.....		20
Bitewing Film Adapter, Dental.....		5	HOLDER, RADIOGRAPHIC FILM CASSETTE.....		4150
Bitewing Mistory Mount.....		4300	HOLDER, RADIOGRAPHIC FILM EXPOSURE.....		4160,4165
BLEEDER, HIGH VOLTAGE, X-RAY GENERATOR SERVICING.....		20	HOLDER SET, DENTAL RADIOGRAPHIC FILM EXPOSURE.....		4175,4180
BLOCKER SET, X-RAY FILM IDENTIFICATION.....		30			
<b>C</b>					
CABINET, CASSETTE-FILM TRANSFER.....		45	ILLUMINATOR, X-RAY FILM.....		4195-4225
CASSETTE STORAGE, DARKROOM EQUIPMENT SET.....		55	Illuminator (See also Viewers)		
CASSETTE TRANSFER.....		65	Image Intensifier Test Pattern.....		4795
RADIOGRAPHIC ACCESSORIES, DARKROOM EQUIPMENT SET.....		75	Insert, Developing Tank.....		4730-4740
CABINET AND ILLUMINATOR, RADIOGRAPHIC.....		85	Intensifying Screen.....		4585-4620
CABLE ASSEMBLY AND RADIOGRAPHIC CONE SET, MEDICAL X-RAY APPARATUS.....		85			
CALIPER, X-RAY TECHNIQUE.....		105	<b>K-L</b>		
CASSETTE, RADIOGRAPHIC FILM.....		115-300	Kodak PP X-OMAT Processor.....		4375,4380
RADIOGRAPHIC PAPER AND DEVELOPER ASSEMBLY.....		210	Kodak RP X-OMAT Processor.....		4375,4380
X-RAY TUBE CALIBRATION TEST.....		220,225	LABEL, X-RAY FILM IDENTIFICATION.....		4240
CASSETTE CHANGER.....		235	LETTER SET, X-RAY FILM MARKING.....		4250,4255
Cassette Holder, Radiographic Film.....		4150	LF Microline.....		115,120
Pass Box, Radiographic Film.....		65			
Transfer Cabinet.....		45	<b>M-N</b>		
CHEST, X-RAY FILM PROTECTIVE.....		245-255	MARKER SET, X-RAY FILM IDENTIFICATION.....		4270
COLLIMATOR, RADIOGRAPHIC AND FLUOROSCOPIC X-RAY APPARATUS.....		265	Master Tank, X-Ray Film Processing.....		4750-4770
CONTROL UNIT, X-RAY APPARATUS.....		275,280	Medical X-Ray Apparatus.....		4940-4955
CONTROL UNIT AND TUBE-TRANSFORMER HEAD, X-RAY APPARATUS.....		280	MIXER-DISTRIBUTOR, RADIOGRAPHIC CHEMICAL SOLUTIONS.....		4280,4285
COOLER, X-RAY FILM PROCESSING UNIT.....		300	MOUNT, RADIOGRAPHIC FILM, DENTAL.....		4295-4310
			NUMERAL SET, X-RAY FILM MARKING.....		4325
<b>D</b>					
DENSITOMETER.....		315,320			
Dental Radiographic Film.....		3875-3985	<b>P</b>		
Dental X-Ray Apparatus.....		4915-4930,4955	Pakarol-XU.....		4385
DEVELOPER, X-RAY FILM PROCESSING.....		330-410	Pako Processing Machine.....		4385
Developing Tank (See also PROCESSING UNIT, X-RAY FILM and TANK, MASTER, X-RAY FILM PROCESSING)		300	Pass Box, Radiographic Film Cassette.....		65
Developing Tank Cooling Unit.....		300	PHANTOM, MAMMOGRAPHIC.....		4340
Developing Tank Insert.....		4730-4740	PHANTOM, TOMOGRAPHIC.....		4350
DISPENSER, DENTAL X-RAY FILM.....		420	Polaroid Film.....		4495,4500
DRIER, PHOTOGRAPHIC FILM.....		430	Powjer, Developing, X-Ray.....		395-410
DRIER, X-RAY FILM.....		440,445	PROCESSING MACHINE, PHOTOGRAPHIC FILM.....		4380
			RADIOGRAPHIC FILM, AUTOMATIC.....		4370-4430
<b>F</b>					
FILM, CINEFLUOROGRAPHIC.....		480-590	RADIOGRAPHIC PAPER AND DEVELOPER ASSEMBLY.....		4440-4450
PHOTOFLUOROGRAPHIC.....		600-680	PROCESSING SET, RADIOGRAPHIC FILM, DAYLIGHT SYSTEM.....		4460
RADIOGRAPHIC.....		700-3865	PROCESSING UNIT, X-RAY FILM.....		4470
RADIOGRAPHIC, DENTAL.....		3875-3985	Profexray Processing Machine.....		4380
Film Holder.....		4135	Protective Screen, X-Ray.....		4630-4640
Film Transfer Cabinet.....		45			
FILTER, PHOTOGRAPHIC DARKROOM SAFELIGHT.....		3975-3985	<b>R</b>		
FILTER SET, X-RAY, HALF- VALUE LAYER DETERMINATION.....		3995	RACK, X-RAY FILM HANGER.....		4485
FIXER, X-RAY FILM PROCESSING.....		4005-4075	RADIOGRAPHIC PAPER AND DEVELOPER ASSEMBLY.....		4495,4500
Fixing Bath, X-Ray Film Processing.....		4005-4055	RECTIFIER ASSEMBLY, RADIOGRAPHIC AND FLUOROSCOPIC X-RAY APPARATUS.....		4510
Fluoroscopic and Radiographic Unit.....		4965-4985, 5005-5025	RP X-OMAT Starter Developer.....		4680
			RULE, ANATOMICAL.....		4520
			Ruler, X-Ray.....		4530
			RULER, X-RAY BEAM MEASURING.....		4530
			<b>S</b>		
			SAFE, DENTAL X-RAY FILM PROTECTIVE.....		4545
			SAFELIGHT, DARKROOM, PHOTOGRAPHIC.....		4555-4575
			SCREEN, X-RAY INTENSIFYING.....		4585-4620
			SCREEN, X-RAY PROTECTIVE.....		4630-4640
			SENSITOMETER, RADIOGRAPHIC FILM.....		4650

Figure 1-3 A page from the Alphabetical Index of the Identification List

NATIONAL STOCK NUMBER INDEX

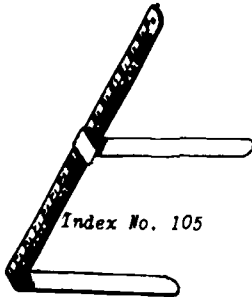
NATIONAL STOCK NO	INDEX NO	NATIONAL STOCK NO	INDEX NO	NATIONAL STOCK NO	INDEX NO	NATIONAL STOCK NO	INDEX NO
CLASS 6325		6525-00-612-4770	4720	6525-01-003-9326	3730	6525-01-045-0035	1020
6525-00-023-4594	4500	6525-00-612-4775	4815	6525-01-003-9327	3685	6525-C1-045-0036	1015
6525-00-054-7208	4945	6525-00-612-4790	4850	6525-01-003-9329	3725	6525-01-045-0037	1010
6525-00-074-4542	4125	6525-00-612-4795	4870	6525-01-003-9333	3530	6525-G1-045-1356	3635
6525-00-075-3294	65	6525-00-612-5200	4995	6525-01-004-1038	3500	6525-C1-045-1357	3625
6525-00-082-2492	4970	6525-00-612-7500	4520	6525-01-004-1039	3545	6525-01-045-1358	3620
6525-00-089-8186	4740	6525-00-612-7650	4545	6525-01-004-1040	3675	6525-01-045-1359	3615
6525-00-113-8333	4215	6525-00-612-7775	4555	6525-01-004-1041	2500	6525-C1-045-1360	3610
6525-00-138-9515	55	6525-00-612-7785	3985	6525-01-004-3984	3690	6525-01-045-1361	3240
6525-00-138-9517	75	6525-00-612-7825	4545	6525-01-004-6688	3185	6525-C1-045-1362	3360
6525-00-138-9749	4495	6525-00-612-7840	4540	6525-01-004-8589	3715	6525-C1-045-1363	1005
6525-00-142-8732	4300	6525-00-612-8032	4430	6525-01-004-8590	3525	6525-01-045-1364	1750
6525-00-149-1598	4805	6525-00-612-8300	4605	6525-01-005-7536	3710	6525-G1-045-1365	1045
6525-00-181-7104	3920	6525-00-612-9300	4410	6525-01-006-1689	3570	6525-01-045-1366	1040
6525-00-208-6569	3585	6525-00-612-9500	4415	6525-01-006-1690	3575	6525-C1-045-2243	3325
6525-00-209-7216	4195	6525-00-613-0300	4620	6525-01-007-6058	4920	6525-C1-045-2244	3180
6525-00-222-1340	4915	6525-00-615-8100	4710	6525-01-009-8004	3145	6525-01-045-2245	3170
6525-00-222-1341	130	6525-00-616-2762	430	6525-01-010-8496	4460	6525-01-045-2246	3155
6525-00-222-1347	4840	6525-00-616-7400	4770	6525-01-012-9686	200	6525-01-045-2247	3135
6525-00-226-0918	115	6525-00-616-7691	4470	6525-01-012-9687	185	6525-01-045-2248	2885
6525-00-226-0919	120	6525-00-616-7679	4730	6525-01-012-9688	175	6525-C1-045-2249	2925
6525-00-242-0611	4685	6525-00-616-9250	4845	6525-01-012-9689	170	6525-01-045-3447	3480
6525-00-264-3953	4745	6525-00-663-1695	45	6525-01-012-9690	155	6525-01-045-3448	3260
6525-00-293-8905	680	6525-00-664-0858	445	6525-01-015-4671	3515	6525-01-045-3449	775
6525-00-299-8269	300	6525-00-680-0808	245	6525-01-015-4672	3510	6525-01-045-3450	1545
6525-00-299-8300	4150	6525-00-680-0891	4820	6525-01-015-4673	3505	6525-G1-045-3451	1550
6525-00-299-8495	4570	6525-00-680-0892	4840	6525-01-015-4674	3495	6525-C1-045-3452	1545
6525-00-299-9538	4750	6525-00-680-0893	280	6525-01-015-4685	1385	6525-C1-045-3453	1540
6525-00-356-9172	3045	6525-00-680-0894	4875	6525-01-015-4688	1375	6525-01-045-3454	805
6525-00-389-9288	4420	6525-00-684-8524	4510	6525-01-015-4690	1365	6525-01-045-3455	800
6525-00-420-9588	4430	6525-00-684-8745	5010	6525-01-015-4692	1355	6525-C1-045-3456	795
6525-00-421-7830	4135	6525-00-684-8780	5005	6525-01-015-4695	1350	6525-01-045-5668	2810
6525-00-433-9036	20	6525-00-685-5169	5025	6525-01-015-6109	3235	6525-C1-045-5766	3840
6525-00-442-4753	4390	6525-00-689-3678	4490	6525-01-023-1132	3560	6525-G1-045-6410	1485
6525-00-455-9947	4890	6525-00-690-3214	4925	6525-01-023-5247	3255	6525-01-045-6411	1460
6525-00-462-4082	4900	6525-00-721-9813	135	6525-01-024-8877	410	6525-C1-045-6412	1450
6525-00-464-2514	4385	6525-00-721-9814	140	6525-01-024-8878	4075	6525-01-045-6413	1420
6525-00-464-3796	3795	6525-00-721-9815	145	6525-01-028-1272	2910	6525-C1-045-6414	1335
6525-00-477-6717	4380	6525-00-721-9816	150	6525-01-028-3984	2915	6525-01-045-6415	1490
6525-00-484-9490	4400	6525-00-721-9827	4585	6525-01-028-3985	2865	6525-C1-045-6416	1465
6525-00-492-6306	4795	6525-00-721-9828	4590	6525-01-028-4654	3270	6525-01-045-6417	1455
6525-00-539-7442	3535	6525-00-721-9829	4595	6525-01-028-4655	2870	6525-01-045-6418	1425
6525-00-550-8820	4830	6525-00-721-9830	4400	6525-01-028-4656	2875	6525-G1-045-6419	1585
6525-00-562-2494	85	6525-00-753-9598	4435	6525-01-028-4657	3160	6525-G1-045-6420	1750
6525-00-571-9582	4755	6525-00-763-4615	405	6525-01-028-4658	2895	6525-01-045-6421	1725
6525-00-571-9585	4945	6525-00-792-2079	4980	6525-01-028-9770	2955	6525-C1-045-6422	1715
6525-00-573-9366	4575	6525-00-817-2363	4305	6525-01-029-5576	2900	6525-01-045-6423	1705
6525-00-579-9112	4070	6525-00-817-2364	4295	6525-01-030-6391	3735	6525-C1-045-6424	1675
6525-00-600-7900	105	6525-00-823-8127	4445	6525-01-030-9011	4310	6525-G1-045-6425	1635
6525-00-601-0600	210	6525-00-823-8144	4450	6525-01-037-5182	4660	6525-01-045-6426	1840
6525-00-601-1700	235	6525-00-853-8121	4985	6525-01-038-0546	755	6525-C1-045-6427	1820
6525-00-601-2120	250	6525-00-880-7257	4240	6525-01-038-0547	760	6525-C1-045-6428	1800
6525-00-601-2124	245	6525-00-880-7261	30	6525-01-038-0548	765	6525-G1-045-6429	1795
6525-00-601-3680	290	6525-00-890-2194	4175	6525-01-038-0549	770	6525-01-045-6430	1815
6525-00-601-4500	440	6525-00-903-8168	4160	6525-01-038-0550	780	6525-C1-045-6720	2800
6525-00-601-5015	5	6525-00-903-8172	4145	6525-01-039-4019	225	6525-C1-045-7085	3865
6525-00-603-1230	4090	6525-00-926-9164	4895	6525-01-039-4436	2805	6525-01-045-8536	3330
6525-00-603-1310	4095	6525-00-930-0575	4495	6525-01-039-4775	2890	6525-G1-045-8537	1000
6525-00-603-1760	4110	6525-00-930-3274	4640	6525-01-041-6898	565	6525-01-046-0075	3350
6525-00-603-1765	4115	6525-00-935-1006	4375	6525-01-041-4100	1625	6525-G1-046-1130	3345
6525-00-603-1775	4120	6525-00-935-1129	350	6525-01-043-6303	3285	6525-G1-046-1937	3695
6525-00-603-1795	4130	6525-00-935-1131	6015	6525-01-044-7101	900	6525-C1-046-2948	2015
6525-00-604-0000	4220	6525-00-935-4049	4060	6525-01-044-7102	895	6525-01-046-2949	2005
6525-00-604-0125	4205	6525-00-935-4050	4065	6525-01-044-8312	890	6525-01-046-2950	1980
6525-00-604-2160	4735	6525-00-935-4051	395	6525-01-044-8313	885	6525-C1-046-2951	1970
6525-00-604-2165	4740	6525-00-935-4052	400	6525-01-044-8314	880	6525-01-046-2952	1960
6525-00-604-7825	4250	6525-00-935-4097	390	6525-01-044-8315	875	6525-C1-046-2953	1930
6525-00-604-7925	4255	6525-00-935-4098	385	6525-01-044-8316	925	6525-G1-046-2954	1890
6525-00-608-0620	4270	6525-00-935-4099	380	6525-01-044-8317	920	6525-01-046-2955	1880
6525-00-611-1225	4325	6525-00-935-4103	4050	6525-01-044-8318	915	6525-01-046-5646	3110

Figure 1-4 A page from the National Stock Number Index of the 6525 Identification List

**CALIPER, X-RAY TECHNIQUE**

One fixed and one sliding jaw. Graduated at 1-40 cm at 1 cm intervals and 1/2-16 in. at 1/2 in. intervals. For measuring thickness of body parts.

Action	Index No.	National Stock No.	Descriptive Data
—	105	6525-00-600-7900	—



**CASSETTE, RADIOGRAPHIC FILM**



With two high-speed intensifying screens, except Index No. 160, 165, 180, 190, and 195, with two medium-speed intensifying screens.

Index No. 130—Replacement cassette for X-ray apparatus, Index No. 4915. For use with 5 by 10 or 5 by 12 in. radiographic film in full mouth radiography. Requisition should specify the X-ray apparatus serial no. when ordering.

Index No. 155, 170, 175, 185, and 200—Consists of two vinyl-covered aluminum covers mounted in plastic frames. flush-mounted lift-up latch, and a daylight inspection window on the back cover.

Index No. 160, 165, 180, 190, and 195—Consists of two vinyl-covered aluminum covers mounted in aluminum frames with two flush-mounted slide latches.

Action	Index No.	National Stock No.	Descriptive Data	For Replacement Intensifying Screens, order Index No.
<b>WITH GRID. 80-line, 5:1 ratio (focal range 28 to 72 in.) microline grid front.</b>				
—	115	6525-00-226-0918	10 by 12 inches	4590
—	120	6525-00-226-0919	10 by 17 inches	4600
<b>WITHOUT GRID</b>				
—	130	6525-00-222-1341	5 by 12 inches	—
—	135	6525-00-721-9819	8 by 10 inches	4585
—	140	6525-00-721-9814	10 by 12 inches	4590
—	145	6525-00-721-9815	11 by 14 inches	4595
—	150	6525-00-721-9816	14 by 17 inches	4600
—	155	6525-01-012-9690	Lightweight, 8 by 18 inches	—
—	160	6525-01-070-1504	Lightweight, 8 by 10 inches	—
—	165	6525-01-070-2699	Lightweight, 10 by 12 inches	—
—	170	6525-01-012-9689	Lightweight, 18 by 24 cm	—
—	175	6525-01-012-9688	Lightweight, 24 by 30 cm	—
—	180	6525-01-070-1503	Lightweight, 24 by 30 cm	—
—	185	6525-01-012-9687	Lightweight, 30 by 35 cm	—
—	190	6525-01-070-1502	Lightweight, 30 by 35 cm	—
—	195	6525-01-070-1501	Lightweight, 35 by 43 cm	—
—	200	6525-01-012-9686	Lightweight, 35 by 48 cm	—



**CASSETTE, RADIOGRAPHIC PAPER AND DEVELOPER ASSEMBLY**

With one high-speed intensifying screen. Accommodates radiographic paper and developer assembly, Index No. 4495 and 4500. Replacement cassette for processing machine, Index No. 4445. For use with processing machine, Index No. 4450.

Action	Index No.	National Stock No.	Descriptive Data
—	210	6525-00-601-0600	9-3/8 by 10 inches




Figure 1-5 A descriptive data page from the 6525 Identification List

AC-TION	ACQUIS ADVISE CODE	NATIONAL STOCK NR	PRICE	UNIT OF ISSUE	INTERMED PACKAGE CTY	EXTERICP CONTAINER CTY	UNIT OF ISSUE	CF ISSUE	EXTERICP CONTAINER WEIGHT	LAIT OF ISSUE	CUBE	EXTERIOR CONTAINER CUBE
C	D	6525-00-457-6854	6.080	EA				2.0000			.2220	
C	O	6525-00-457-6855	7.860	EA				2.0000			.2220	
C	V	6525-00-462-40E2	87.570	EA		1		8.0000	E		1.8374	1.837
L		6525-00-464-2514		EA		1		500.0000	900		51.1500	51.156
C	H	6525-00-466-3756	60.180	RD		1		5.0000	5		.2500	.250
C	O	6525-00-467-0053	11.380	EA				.2500			.0011	
L		6525-00-477-6717		EA		1		510.0000	510		57.4055	57.409
Y		6525-00-484-9450		EA		1		150.0000	150		70.0000	20.000
L		6525-00-492-6306		EA	1	4		16.6666	6E		.4482	1.792
C	V	6525-00-494-6732	2.280	EA				.7800			.0070	
C	H	6525-00-539-7462	54.280	PG	1	5		8.4000	42		.2300	1.150
C	V	6525-00-550-8820	895.030	EA		1		245.0000	245		8.0000	8.000
C	C	6525-00-561-074E	241.060	EA				3.5000			.1500	
C	V	6525-00-561-0745	1.350	EA				.0300			.0010	
C	D	6525-00-561-087E	6.250	EA				2.0000			.0208	
C	V	6525-00-561-05E2	1.180	EA				.1000			.0006	
C	O	6525-00-562-2456	727.580	EA		1		90.0000	50		7.5167	7.916
C	H	6525-00-569-0716	32.080	RD		1		10.0000	10		1.0000	1.000
C	O	6525-00-571-9502	2,702.420	EA		1						
C	C	6525-00-571-9503	32,428.590	EA		1						
C	D	6525-00-573-947E	21.650	EA				.5000			.0006	
C	D	6525-00-575-447E	5.000	EA				.1000			.0006	
C	V	6525-00-579-9112	1.080	PG	1	12		2.7500			.0020	
C	D	6525-00-582-0445	6.190	EA				.0100			.0010	
C	V	6525-00-600-7710	166.470	EA				22.0000			4.0000	
C	D	6525-00-600-7900	14.820	EA	1	36		1.8333	66		.1111	4.000
C	D	6525-00-601-0400	420.070	EA	1	6		7.5000	45		.2333	1.400
C	H	6525-00-601-1700	2,110.210	EA		1		631.0000	631		61.0000	61.000
C	D	6525-00-601-2120	340.580	EA		1		112.0000	113		5.5000	5.500
C	D	6525-00-601-2124	249.900	EA		1		80.0000	80		6.5000	6.500
C	V	6525-00-601-3600	1,315.530	EA		1		215.0000	215		8.7000	8.700
C	V	6525-00-601-4500	242.440	EA		1		385.0000	385		44.5000	44.500
C	V	6525-00-601-5015	.750	DX	12	200		.1771	51		.0090	2.600
C	D	6525-00-603-1250	474.810	EA		1		13.0000	13		.5000	.500
C	O	6525-00-603-125E	5.000	EA				.2000			.0006	
C	O	6525-00-603-1300	2.220	EA				.2000			.0006	
C	D	6525-00-603-1310	683.420	EA		1		21.0000	21		.7000	.700
C	D	6525-00-603-1700	16.660	EA	6	24		1.7500	42		.1750	4.200
C	D	6525-00-603-1705	16.660	EA	6	24		2.0000	48		.2083	5.000
C	D	6525-00-603-1770	16.660	EA	6	24		1.2917	21		.1125	2.700
C	O	6525-00-603-1755	9.400	EA	12	216		.2565	77		.0325	7.100
C	D	6525-00-604-0000	100.360	EA		1		27.0000	27		3.1500	3.150
C	D	6525-00-604-0125	1,402.610	EA		1		229.0000	225		15.5000	19.500
C	V	6525-00-604-2140	67.020	EA		1		48.0000	48		4.7000	4.700
C	C	6525-00-604-2145	67.020	EA		1		40.0000	40		5.0000	5.000
C	D	6525-00-604-7825	13.810	SE	12	576		.1250	72		.0048	2.760
C	D	6525-00-604-7925	.830	SE	144	3456		.0175	60		.0008	2.760
C	C	6525-00-608-0620	487.690	SE	1	12		5.0000	60		.1667	2.600
C	D	6525-00-611-1225	5.230	SE	12	576		.0174	10		.0017	1.000
C	V	6525-00-612-4400	329.700	EA		1		28.0000	28		2.0000	2.000
C	C	6525-00-612-4700	22.620	EA	1	24		1.3750	32		.0E33	2.000
C	H	6525-00-612-4720	20,376.200	SE		1		4000.0000	4000		160.0000	160.000
C	V	6525-00-612-4725	1,443.130	SE		1		156.0000	156		6.4000	6.400
C	V	6525-00-612-4755	4,331.430	EA		1		562.0000	562		47.3000	47.300
C	V	6525-00-612-4770	7,351.640	EA		1		2000.0000	2000		84.0000	84.000
C	V	6525-00-612-4775	2,702.420	EA		1		474.0000	424		24.0000	24.000
C	H	6525-00-612-4780	1,342.800	EA				10.0000			3.1200	
C	V	6525-00-612-4750	2,406.220	EA		1		1140.0000	1140		68.1000	68.100
C	V	6525-00-612-4755	1,250.670	EA		1		127.0000	127		8.0000	8.000
C	H	6525-00-612-5200	2,030.050	SE		1		275.0000	375		16.3000	16.300
C	O	6525-00-612-7500	.590	EA	12	432		.1825	75		.0029	1.200
C	V	6525-00-612-7600	42.020	EA	1	12		5.0000	60		.2083	2.500
C	V	6525-00-612-7775	84.850	EA	1	4		7.2500	25		.4500	1.800
C	V	6525-00-612-7785	3.890	EA	6	144		.5000	72		.0208	3.000
C	D	6525-00-612-7825	41.720	EA	1	12		4.1667	50		.4167	5.000
C	D	6525-00-612-7840	67.830	EA	1	6		7.5000	45		.4500	2.700
C	V	6525-00-612-8030	1,037.120	EA		1		100.0000	100		6.0000	6.000
C	D	6525-00-612-8300	27.660	PR	1	48		1.2917	62		.0833	4.000
C	Y	6525-00-612-9300	37.920	PR	1	36		2.1389	77		.1722	6.200
C	D	6525-00-612-9500	33.450	PR	1	12		2.1667	26		.1750	2.100
C	D	6525-00-613-0300	44.490	PR	1	12		2.1667	36		.1500	1.800
C	V	6525-00-613-8100	2,090.590	EA		1		525.0000	525		22.7000	22.700
C	V	6525-00-616-2740	469.140	EA		1		80.0000	80		6.2000	6.200
C	V	6525-00-616-7400	1,771.650	EA		1		343.0000	343		21.0000	21.000
C	V	6525-00-616-7651	7,104.280	EA		1		880.0000	880		85.0000	85.000

Figure 1-6 A page from the 6525 Management Data List



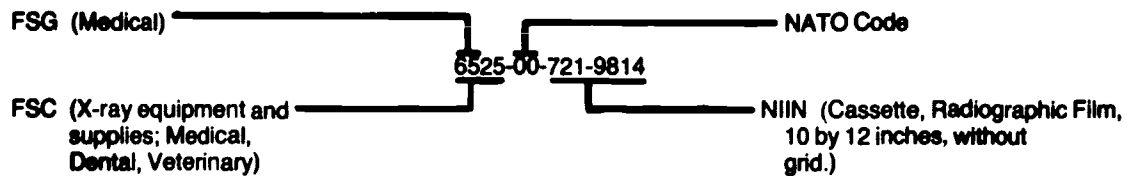


Figure 1-7 The breakdown of a national stock number

2. The following questions refer to NSN 6525-00-299-8300.

- (1) Which numbers refer to the Federal Supply Class?
- (2) Which numbers refer to the Federal Supply Group?
- (3) Which numbers refer to the National Item Identification Number?
- (4) Which numbers identify the item as X-ray equipment or supplies for medical, dental, or veterinary use?

**805. Assess the importance of reviewing your issue list and describe the two methods of ordering supplies.**

**Ordering Supplies.** We will now examine the two methods for ordering supplies. Keep in mind that—regardless of the method used—if you order an item, it must appear on the issue list that you receive when the supplies are delivered. This is especially important in case an item is back-ordered. The back-ordered item must appear on the issue list, or you will never receive the item from supply when they receive it from the depot. In case an item you ordered does not appear on the issue list, report the omission to the medical materiel section.

**Telephone orders.** This the preferred method of requesting supplies because of its speed and simplicity. The medical supply account provides you with a *shopping guide*. This is a computer-produced listing that shows all the expendable items that you order on a recurring basis. The items are listed in stock number sequence, with each item having a line number. The unit of issue, item nomenclature, and unit price are also shown for each item. The medical supply account maintains a shopping-guide card for each item listed on your shopping guide.

When it's time for you to order, call the medical supply section and, using your shopping guide, place your order by

line number. For example: line 4, six bottles; line 6, two boxes; line 9, one can. As you order, the medical supply clerk pulls the appropriate card from the file and annotates the quantity requested on the card. You can see why this is the preferred method: it saves time at both ends of the supply line.

**DD Form 1348-6, Non-NSN Requisition (Manual).** The name of this form is misleading because it is not restricted to nonstock numbered items only. It can also be used to order these types of supplies. (1) Nonstock numbered items—Medical, nonmedical, and local purchase; (2) stock numbered items—medical and nonmedical.

When you need an expendable item that is not listed on your shopping guide, you must submit your order on a DD Form 1348-6 (fig. 1-8). If you wish to have the item added to your shopping guide, write in boldface letters on the face of the DD Form 1348-6: **ADD TO SHOPPING GUIDE**.

When using a DD Form 1348-6, you may order multiple quantities of each item that have the same stock number. However, each different stock number or part number item you need to order must have its own 1348-6.

Figure 1-8 shows how to prepare the form. On the top row of spaces, you need to write the NSN, if available (or the manufacturer's part number); the unit of issue (e.g., BX or EA); and the quantity (e.g., 00001, 00002, etc.). The name of the item is entered into block number 6 (Name of Item Requested). In block 9 (Requisitioner) at the bottom of the form, three things are entered: your name (or the name of who is doing the ordering), the account number of your supply account, and the date.

**Exercises (805):**

1. Why should you review the issue list?
2. Briefly describe the two methods for ordering supplies.

**806. Given two reasons for using stock levels, and show how stock levels are established and maintained.**

**Stock Levels.** Supplies are usually ordered every week or as directed by local supply policies. Let's assume that you are the supply person in your section and that you must



do just that. Now you have a stockpile of 10 x 12 film in your department and the medical supply section also has a stockpile of the film sitting in the warehouse.

The computer may also react differently if you do not order an item for a long period of time. Assume again that you have stockpiled 10 x 12 film and do not order for some time. During this time, you are actually using the film daily from your stockpile and the computer is reducing the medical supply level because there is no recorded consumption of the item. Finally, you use all your stockpile and submit an order to the medical supply section for more 10 x 12 film. However, the computer has reduced the stock level to zero; and the medical supply section has no 10 x 12 films.

If you extend these examples to each item in your section, the need to establish and adhere to realistic levels should be obvious. Always remember to order what you need, but be sure that you need what you order. If you order supplies once a week and use four boxes of 10 x 12 film each week, order four. The system works better that way.

Your requirement for an item may change. If it does, immediately advise medical supply personnel so that their level on the item can be adjusted accordingly. Medical supply personnel cannot function effectively without your complete cooperation. They can give you only the quality of service you give them. It's a two-way street.

Regardless of your position, keep one thought in mind when working with Government supplies. Consider each supply item as being paid for you "out of your pocket." If you adopt this attitude, maintaining good supply discipline will be a simple task.

#### Exercises (806):

1. What are two good reasons for using stock levels?
2. What maximum stock level are you authorized to maintain?
3. Upon what factor is the medical supply stock level based?
4. If you stockpile a particular supply item, how might this condition affect medical supply's stock of the item?
5. What action should you take if you want to change a stock level?

#### 807. Specify turn-in procedures for excess or unserviceable materiel and explain how credit is given for items which are turned in.

**Materiel Turn-in Procedures.** From time to time you may have to return supplies or equipment to the medical supply section. This may take place because the items become excess to the need of your department or because they become unserviceable. Certain items may be transferred to another activity which may need them.

The turn in of materiel is a separate and distinct transaction from that of obtaining a replacement item. Only serviceable materiel may be stocked in your department. Unserviceable items must be turned in to the medical supply section when identified as other than serviceable. The property custodian ensures that unserviceable or excess items are not kept in your department. Requests for issue of items to replace unserviceable or reparable materiel turned in should be cross-referenced to the turn-in request and the two actions coordinated for timely replacement.

AF Form 601 is used to turn-in equipment and requisition new or replacement equipment. All materiel to be turned in is made available to the medical supply section through MEMO. The materiel manager or designated inspector determines the condition and identity of the property being turned in. The price reflected on all documentation is the standard price for the item as of the turn-in date if credit is granted.

**Turn-in credit.** The medical supply section allows the customer full credit for serviceable supplies turned in *up to* the operating inventory requirements (the difference between the stock control level in normal operating stock and the total of on-hand and due-in assets). Since turn-ins often indicate reduced demand caused by factors such as changes in professional staff, missions, or usage of related items, the medical supply section checks to see that the stock control level realistically reflects all known future demand factors before they give you credit.

Materiel to be destroyed by the medical supply section or the medical destruction officer or to be turned in to a defense property disposal office (DPDO), can only be turned in without credit. Materiel suspended from issue and use is unserviceable, so no credit is given. If the medical supply section gets credit for the materiel or if the materiel is released from suspension as suitable for issue and use, the medical supply section may allow credit to the department. The decision will be based on the value of the credit, the length of time the item was suspended, and the administrative cost of making the adjustment. Credit adjustments are not considered appropriate if the dollar value is \$25 or less per using activity or if the suspension time is greater than one year.

NOTE: Suspended materiel turned in to the medical supply account becomes the property of the medical supply account and will not be returned to the activity turning in the materiel, except by formal issue procedures.



### Exercises (807):

1. What are two main reasons why items are turned-in to the medical supply section?
2. Who should ensure that unserviceable equipment items are not kept in the X-ray department?
3. Briefly explain how an unserviceable item is turned in to the medical supply section
4. How is the price determined for items turned in to the medical supply section?
5. If you turn in four bottles of an item for credit and it makes supply two bottles over their normal operating level, how many will you receive credit for?
6. What credit action is taken on materiel turned in for destruction by the medical supply section?
7. What normal dollar value must be met on turn-in materiel before credit will be considered?

### 808. Specify procedures for budgeting of supplies and equipment.

**Budgeting for Supplies and Equipment.** Sooner or later, you will become involved in budgeting for the supplies and equipment you use in your department. There is nothing difficult about budgeting, although it does require a certain amount of planning. We will consider the supply budget requirements first and then discuss the equipment budget requirements.

**Supply budgeting.** The resource management officer in your medical facility is responsible for preparation and submission of the annual budget for the entire facility. Around the first of February, he or she will request that your department prepare fund requirements for the coming fiscal year. The first action you should take when you receive this request is to study your previous supply expenditures. This is a simple matter, since your monthly issue list shows a total dollar amount on the last page of each list. You should determine how much you spent on supplies for the preceding fiscal year and how much you have spent in the first half of the current fiscal year. From this information

you should be able to predict approximately how much you will need based on previous expenditures.

At this point, you should consider any upcoming changes in the workload and types of examinations that might affect your requirements. A forecasted increase or decrease in the base population may affect your workload.

After you consider everything including inflation, you have a projected-costs figure you can submit to the resource management officer. You need to have your estimate ready for submission by early August for the following fiscal year.

**Equipment budgeting.** Equipment budgeting is also accomplished at the same time before the start of a fiscal year. Some of the items you may need are a new radiographic unit, an additional processor, or an automatic injector.

Equipment budgeting is slightly different from supply budgeting in that you must have an authorization for the item. It must be authorized by the table of allowances (TA), a special document showing items of equipment authorized for medical facilities, or it must be authorized in writing from the major command. Usually, the request for an item requiring special authorization must be approved by a local Medical Equipment Review Board. Submit the request on AF Form 601.

Before you attempt to budget for a replacement item of equipment, make sure that you can fully justify your need for the item. Talk it over with your radiologist and the medical equipment repair technicians. Sometimes factory alterations to existing equipment may solve your problem. Keep in mind that you must justify on AF Form 601 your need for any item. Also remember that equipment funds, as well as any other funds, are limited.

### Exercises (808):

1. Approximately how many months before the start of a fiscal year should you be notified to prepare your supply budget estimate?
2. To which office should you submit your projected supply budget?
3. Where can you find your total dollar amount you spent for supplies during the last fiscal year?
4. During which month should you submit your projected supply budget?
5. What should you reference to determine if a certain equipment item is authorized?

6. Who must approve a request for an equipment item that requires special authorization?

7. What form is used to request equipment items?

## 1-2. Administration Procedures

Nothing can impair the function of a radiology department more than poorly kept records. One of the big problems with any records system is the inability to find a document when it is needed. In a radiology department, this problem takes on added significance. Consider the following example: A patient's routine annual chest film shows a small lesion in his right lung. The lesion appears to be benign, but the radiologist needs to compare the appearance of the lesion with that from a previous film if it was indeed visible before. Sometimes, if a lesion has not increased in size in a reasonable length of time, the radiologist can rule out malignancy. The patient had a chest film made in your department 3 years ago, but you cannot find the previous film in the files. As a result of the missing film, correct diagnosis of the patient's condition may be delayed considerably and more difficult to establish.

It goes without saying that we must maintain a reliable records system in our radiology departments. This section is designed to help you do just that.

809. Explain procedures for annotation and disposing of SF 519A.

**SF 519A, Radiographic Report.** SF 519A (fig. 1-9) is a three-part, snap-out form used to request radiographic examinations and to record the radiologist's findings. This form is prepared by or at the direction of the physician, dentist or authorized practitioner desiring the diagnostic procedure.

**Clinical history.** It is important for the person who is requesting the radiographs to specify both the examination requested and the pathology suspected. For example, many radiologists like to include an additional PA chest made with forced expiration on a patient suspected of having a pneumothorax. By noting the appropriate pathology suspected on the form, a technician is alerted to the suspected condition and performs the desired radiographs. There are many more examinations requiring the technician to alter his or her approach to the technical aspects of the examination based upon the suspected pathology.

The suspected pathology, or history as we sometimes say, is also important to the radiologist's interpretation of the radiographs. The history alerts the radiologist to give special attention to certain findings that may either rule out or support the requesting physician's preliminary diagnosis.

**Identification data.** When a patient arrives for a radiographic examination, check the SF 519A to be sure all necessary information is included. This includes the patient's full name, SSAN (if a dependent, SSAN of sponsor) rank or status, and a phone number where the patient can be reached in the event further radiographs are required. Other information should include the patient's

PATIENT'S IDENTIFICATION (For typed or written entries give Name—last, first, middle; residential facility)		AGE	SEX	REGISTER NO.	WARD NO.	FILM NO.
		EXAMINATION REQUESTED				
		REQUESTED BY			DATE OF REQUEST	
PERTINENT CLINICAL HISTORY, OPERATIONS, PHYSICAL FINDINGS, AND PROVISIONAL DIAGNOSIS						
DATE OF EXAMINATION (include year)		DATE OF REPORT		DATE TRANSMITTED		
RADIOGRAPHIC REPORT						
SIGNATURE: (Specify location of X-ray facility if not part of requesting facility) NOTE: For additional space use SF-607, Continuation Sheet    NBR 7549-02-004-4102 * U.S. GOVERNMENT PRINTING OFFICE: 1962 O - 381 - 531 (2625)						
				RADIOGRAPHIC REPORT STANDARD FORM 519-A (REV. 6-77) PREPARED BY 200-0201 PAPER 101-11 650-0 510-010		

Figure 1-9 SF Form 519A

age, sex, and applicable data such as bedside, wheelchair, etc. Enter the ward number if the patient is an inpatient. If the patient is an outpatient, ensure the particular outpatient clinic is indicated in the block designated "Ward No."

**Film number.** The SF 519A is checked against the nominal index. If the patient has had previous radiographs, these need to be pulled so the new radiographs can be added to the folder. You need to indicate in the upper left corner of a SF 519A whether or not the patient has a film file in your department. For instance, if a patient was last X-rayed in your department in a previous year, such as 1982, then you need to write "F," indicating "file," and the patient's last-four SSAN, such as F-2345. Some departments prefer to include the year that the patient's film envelope is filed; e.g., F82-2345 Use "N," which stands for "new," for patients who have never been X-rayed in your department and have no transferred films in you file; e.g., N-2345. Remember, it is possible that a patient has a film envelope in your file even though your department has never X-rayed that person; the films may have been sent or hand-carried from another treatment facility. This is common for patients sent to your facility for special treatment and vice versa.

**Immediate disposition.** After the films are read by your radiologist, the findings (diagnosis) and the date of the report are entered in the spaces provided. The radiologist signs the form and releases it for distribution.

Routine distribution, as outlined in AFR 168-4, *Administration of Medical Activities*, calls for the original copy (the top page) to be sent to the ward unit for inpatients or to the medical records section for outpatients. The middle page (first carbon copy) should be sent to the requesting physician. The last copy (the bottom page) is to be filed in the patient's radiographic film envelope, preferably in chronological sequence with the most recent SF 519A on top. These film file copies are best kept inside a smaller envelope within the film file envelope. Many departments reverse the distribution for the two carbon copies for good reason: the middle copy is easier to read than the final copy. For example, the copy sent to the requesting physician is usually only read once and thrown away. The copy placed in the patient's radiographic film envelope is permanently kept and is read by a radiologist during followup films or is copied for other physicians. Thus, the film file copy should be clearly legible; and since the middle page is somewhat easier to read than the last page, the middle copy is usually the choice for the film file envelope.

The radiologist's findings are usually typed on the form. When early interpretation is desired, the requesting physician enters the notation "Wet Reading" in the top border of the form. Requests from the emergency room and critically-ill inpatients fall into this category. These requests are promptly read by the radiologist who relays the findings to the requesting physician by telephone, in person, or by handwritten memorandum.

#### Exercises (809):

1. Why should SF 519A contain an appropriate patient history?

2. Where is it determined on a SF 519A where to send the doctor's copy of a request for an outpatient?
3. What is the SF 519A cross-referenced with to see if the patient has a film envelope on file?
4. Explain how you should indicate whether or not a patient has previous films in file
5. How can a patient have films on file if that patient has never been X-rayed in you department?
6. Where and how are the X-ray department's copies of SF 519As maintained?
7. Where does the original, or top, copy of a SF 519A go after it is signed by a radiologist?

#### 810. Explain procedures for the use and disposition of the nominal index file.

**Nominal Index File.** Each radiology facility must maintain an alphabetical index of patients by name. This index, the nominal index file, is usually maintained on 3 x 5 inch cards but may be kept on a motorized access system or a computerized information system. The nominal index file, commonly called the card file, serves more than one purpose. First, it indicates whether or not a patient has a film envelope on file and, if so, in what year it is filed. By cross-referencing each SF 519A to the card file, you can readily locate a patient's previous films; thus, this prevents you from making unnecessary and duplicate folders. Second, it provides a list of exams the patient has had in your department. This is useful when a clinic or ward calls to inquire what exams a patient has had; sometimes this may prevent a duplicate exam if the original exam was done recently and the results are pertinent.

Information in the index file should include the patient's full name, rank or dependency status, SSAN of the patient (or sponsor), age, sex, and a chronological listing (by date performed and type) of each radiologic exam that was performed on the exam. It is a good idea to list on the card the receipt of films performed in another treatment facility. This can easily be done by writing "FFR," which stands for "foreign films received" because they are "foreign" to your facility, and the date you received the films and placed them in file.

Nominal index cards may be used as "flash cards" for the identification of patient's films if your department uses a particular type of film flashers (identifiers).

Disposition of the nominal index file is directed in AFR 12-50, *Disposition of Air Force Documentation*, table 160-4. Rule 21 states that "nominal index cards are to be retired or destroyed concurrently with the X-rays to which they relate." For example, suppose a patient came into your department for a routine exam and informs you that previous films were taken 2 years earlier but none since then. You must locate the previous nominal index card for that patient and update it to the current year's index file. Don't forget to annotate on the SF 519A that the patient has previous films in file so that the file room personnel can update that film envelope also to this current year's files. On the other hand, if a patient's films have not been updated over the last few years, chances are they have been salvaged or destroyed if they have been held in storage for 5 calendar years after the cutoff date (31 December of the year they were filed). When that particular year's films are destroyed, then the nominal index file which corresponds to that year is also destroyed. For example, the 1978 nominal index card file could be destroyed no earlier than 1 January 1984.

#### Exercises (810):

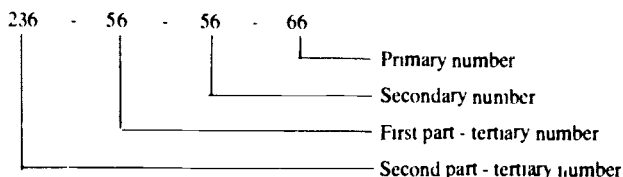
1. List five uses of the nominal index file
2. How does the nominal index file prevent duplicate film envelopes?
3. What procedure should you take if a physician inquires whether or not a patient has previous mammography films, and why?
4. How should you annotate on a nominal index file card that another medical facility mailed films pertaining to MSgt Smith to your department?
5. What directive outlines the disposition of the nominal index file?
6. When should a nominal index file be destroyed?
7. What is the earliest date that the 1980 nominal index file may be destroyed?

### 811. Specify procedures for filing and loaning radiographs.

**Filing X-ray Films.** Patients' radiographs and their reports (SF 519A) are stored in a film file envelope, sometimes called film folders. Film envelopes are filed according to a system using the patient's (or sponsor's) SSAN, which is referred to as the "terminal digit filing system." Film folders are color-coded with the color determined by the primary number and designed to correspond to the color of the patient's health records folder. The film file is cutoff on the last day of the calendar year (31 December), and a new file is established on 1 January of each year. Since these envelopes serve to hold patients' films, disposition is covered by AFR 12-50, table 160-4, which prescribes that diagnostic radiographs (and their film envelopes) be destroyed or salvaged after the end of the fifth calendar year after their cutoff.

**Envelope data.** A film file envelope is prepared for each patient on their first visit to the department. Each film file must show the patient's full name, rank (or status), SSAN (or sponsor's for dependents), and a chronological listing of each radiographic (or imaging) procedure contained within the folder.

**Terminal digit filing.** Terminal digit filing has become the preferred system for filing records, including film file envelopes. And, as we said before, the system is based on the SSAN of the patient (or sponsor if the patient is a dependent). Each SSAN is broken down into the numbers that follow:



Let's assume that you want to establish the terminal digit filing system in your department on the first day of January. The first thing to do is determine from the previous year's files and projected changes how much filing space you will need for the coming year's files. Divide the filing space into 100 sections of equal sizes. Each section represents one of the 100 possible combinations of the primary number. The primary numbers begin with 00 and progress to 01, 02, 03, and end with 99. Use a file guide in each of the 100 sections. Now you have 100 sections of filing space each of which is labeled with a file guide (from 00 to 99). If the SSAN of the first patient X-rayed on 1 January is 236-56-56-66, the folder is filed in the section labeled 66, since the primary number in that SSAN is 66.

The secondary number, 56 in the above example, is the next number to consider when filing folders within one of the 100 sections. For example, suppose you have four SSANs such as:

806-94-54-66  
723-10-55-66  
236-56-56-66  
301-31-60-66

All four folders are filed in the 66 section because each primary number is 66. In addition, the four folders are aligned according to their secondary numbers which, as you can see, are 54, 55, 56, and 60. The four numbers listed above are correctly aligned. Notice that the first and second parts of the tertiary numbers in the four SSANs listed have no pattern whatsoever. The reason is that under the terminal digit system you only align the secondary numbers if the primary numbers are the same, the first part of the tertiary numbers if the secondary numbers are the same, etc.

Let's add some other numbers to our section labeled 66 and consider them with our original four numbers.

<i>Original Numbers</i>	<i>Added Numbers</i>
806-94-54-66	(723-11-55-66)
723-10-55-66	(236-57-56-66)
236-56-56-66	(235-57-56-66)
301-31-60-66	

If we correctly order the seven numbers or folders, the arrangement would be like this.

- a. 806-94-54-66.
- b. 723-10-55-66.
- c. (723-11-55-66).
- d. 236-56-56-66.
- e. (235-57-56-66).
- f. (236-57-56-66).
- g. 301-31-60-66.

Now let's take a closer look at those seven folders. First of all, the primary numbers are all 66, so they would be filed in the section labeled 66. Of the seven secondary numbers *b* and *c* are identical (55), so we must look to the first parts of the tertiary numbers, which are 10 and 11. Obviously, 10 comes before 11. Three other secondary numbers *d*, *e*, and *f* are also identical (56), so we once again must look to the first parts of the tertiary numbers. In this case, *d* is 56 and *e* and *f* are 57. Obviously, 56 comes first. Now since we have two identical first-part tertiary numbers that are identical (57), we must look to the second parts of the tertiary numbers. As you can see those numbers are 235 and 236 and are correctly aligned.

**Film Loaning Procedures.** There are two methods by which you may loan films to other intrahospital services or to other medical facilities. The first method requires you to remove the desired films from the regular film file envelope and put them in a "loan envelope" which shows the patient's name and SSAN. Keep the carbon copies of the SF 519A in the regular film file envelope; these file copies are not suppose to leave the department. Annotate the loan record section on the front of the patient's regular film file envelope; this section provides an audit trail of when the films were loaned, which films were loaned, and to whom or where they were delivered. The regular film folder may then be put back into its routine storage location. When the loaned films are returned, replace them in the patient's film file envelope; and enter the date returned in the loan record section of the envelope.

The second method of loaning films allows the original film file envelope to be signed out instead of using a loan envelope. In this method you need to fill out an AF Form 614, Charge Out Record, and insert it into the normal

location for that particular film folder it relates to or in a designated area for folders that are signed out. Again, the file copies of SF 519A are kept in the file room, preferably attached to the AF Form 614. When the loaned folder is returned, put the file copies of the SF 519A back in it and put the folder back in its proper file space. Remove the AF Form 614; it may be used again for other loans.

#### Exercises (811):

1. When is the film file cut off and a new file established?
2. What information must appear on the film file envelope?
3. What part of a SSAN determines the color of a film envelope?
4. What year may the 1983 film files be destroyed or salvaged?
5. Name the four parts of SSAN 456-46-2703 that are used in the terminal digit filing system.
6. Reorder the following numbers from the smallest to the largest according to the terminal digit filing system.
 

189-39-79-22	408-01-00-99
101-00-32-77	376-18-19-92
591-37-11-80	106-00-32-72
623-40-09-83	620-49-09-83
370-99-69-77	865-49-87-31
407-00-01-99	374-99-68-77
972-41-86-31	375-17-20-92
873-40-86-31	973-40-86-31
7. Briefly describe the two methods of loaning films.
8. What happens to the file copies of SF 519A when films are loaned?

#### 812. Specify the publication and procedures for disposition of radiology records.

**Disposition of Radiology Records.** Like all records accumulated in the Air Force, those in your radiology

department must be disposed of according to current directives. Table 160-4, AFR 12-50, *Disposition of Air Force Documentation*, provides you with specific guidelines.

We have included table 160-4 in this section (fig. 1-10) so that you may be more familiar with its contents and use. Notice in figure 1-10 how easily it is to locate desired information. For example, suppose you are unsure of the proper disposition for radiographs which are unidentifiable as to the patient they relate. By reading down column A you find rule 20, "unidentified exposed X-ray film." Notice that these consist of X-rays which cannot be identified with the individuals to whom they pertain (column B). Column D, which states the disposition instructions, directs that these films must be destroyed when encountered. In other words, you have no use for those films in your department; thus, they are turned in for salvaging their silver content.

Be sure to refer to table 160-4 and follow the procedures indicated as required.

#### Exercises (812):

1. Where do you find the instructions (publication number, title, and table) by which to dispose of radiology records?
2. Using rule 10 of table 160-4, what is the disposition for diagnostic radiographs which are used for teaching purposes?
3. What rule number of table 160-4 covers the disposition of the nominal index file?
4. Using table 160-4 of AFR 12-50, what is the maximum length of time you may hold radiographs that relate to the separation of personnel?

#### 813. Specify procedures for providing information for inclusion on AF Form 235 and AF Form 235e.

**Radiology Reports.** The purpose of monthly reports is to provide data on strength served, workload performed during the month, and miscellaneous statistical information. These data provide the Surgeon General, command Surgeons, and medical facilities with information needed to manage medical service programs, plan for construction, budget material and manpower, and to determine the general health of the population served.

**AF Form 235, Report of Patients.** You submit the information that follows to the resource management office for inclusion on AF Form 235.

a. The total number of X-ray films actually exposed (not number of exposures per film) for inpatients and outpatients. The number of films exposed should be the difference between the number of films on hand at the beginning of the month and the number on hand at the end of the month, after making appropriate adjustments for receipts from medical materiel, spoilage, and so forth. Do not include cine film exposed.

b. The number of fluoroscopic examinations accomplished on inpatients and outpatients.

c. The number of radiographs interpreted by your radiologist but actually performed at another facility.

**AF Form 235e, Report of Patients—Manpower Standards Supplement.** You submit the following information to the resources management office for inclusion on AF Form 235e.

a. The number of specific procedures accomplished each month. For example, the number of chest radiographs requiring one film, the number requiring two films, how many UGIs, BEs, etc. Each one of these and other examinations listed in AFM 168-695, Volume 2, *MAMS—Medical Administrative Management System—Command*, are assigned workload equivalent point values. From these point values, manning for radiology, nuclear medicine, and ultrasound is determined.

b. Further information includes nuclear medicine procedures.

c. Ultrasound visits.

d. Number of students formally enrolled in Course SAZO90350-1, Phase II.

For specific instructions and point values assigned to the various procedures refer to AFM 168-695, Volume 1, *Medical Administration Management System—Base*.

#### Exercises (813):

1. What information do you provide to the resource management office for inclusion on AF Form 235, Report of Patients?
2. What information do you provide to the resource management office for inclusion on AF Form 235e, Report of Patients—Manpower Standards?
3. What are four reasons why the above information is needed?
4. To whom and how often should you submit the above information?

TABLE 160-4

## RADIOLOGY DOCUMENTATION

R U L E	A	B	C	D
	If documents are or pertain to	consisting of	which are on	then
1	entrance and separation examination X-ray film	chest X-rays exposed in conducting the medical examination preliminary to an individual's entry into, reenlistment for, or release or discharge from extended active military service in either an officer or enlisted status	applicants accepted for induction, and Reserve or Regular enlistment for extended active duty or active duty for training, including applicants for aviation cadet training, officer candidate school, and flying service on enlisted status	forward on a current basis to NPRC (CPR) (note 1); film files may be forwarded weekly or monthly, depending on the rate of accumulation but will not be held longer than three months in addition to the accumulating month; shipments will be in weekly or monthly increments with the oldest week or month forwarded first; (exception: separation and retirement X-rays may be retained until the individual has been separated or retired, then forward in accordance with procedures outlined above).
2			applicants accepted for appointments as officers, warrant officers, flight officers and Air Force cadets	
3			members of the Reserve and National Guard ordered to 6 months active duty for training or extended active duty under the Reserve Forces Act	
4			current or former members who reenlist for additional periods of extended active duty	
5			students and graduates of officer candidate schools	
6			chest and other X-rays made as a part of the medical examination for release or discharge from extended active military service	

TABLE 160-4 (Continued)

R U L E	A	B	C	D
	If documents are or pertain to	consisting of	which are	then
7		X-rays of applicants for US Service Academies made at the time of qualifying examinations	at the examining center	file with diagnostic X-rays and dispose of as in rule 10, column D, unless sooner requested to be forwarded to one of the US Service Academies.
8			(RESERVED)	
9	periodic flight and other physical examinations X-ray film			see rule 10.
10	diagnostic X-ray film	X-rays made in connection with diagnosis and treatment of patients at medical facilities, including US Coast Guard personnel and dependents (except those covered in table 162-1 and AFR 168-4)	maintained numerically on an annual basis	hold 5 years after cutoff in staging area or in any other manner consistent with prescribed procedures for adequate storage and servicing; salvage or destroy (note 2).
11		X-rays of unusual interest or those selected for teaching purposes		salvage or destroy when of no further value.
12		negative pathological findings and positive pathological findings that are static in nature (except as indicated in rule 13)	Federal Civil Service employees maintained at Industrial Medicine Facilities	destroy after 5 years.
13		positive pathological findings that are not static in nature, and one representative X-ray of those that are static in nature		retire as permanent to NPRC (CPR) at the end of the calendar year in which an employee retires or otherwise terminates employment.
14		(RESERVED)		

21



15	rejected applicant and registrant chest X-ray film		applicants rejected because of pulmonary tuberculosis	offer to official state public health agency of rejected person's home state; salvage or destroy if state health officer considers the report, indicating existence of disease, is sufficient and does not desire the film.
16			applicants rejected for physical reasons other than disease of the chest	salvage or destroy after findings have been entered on the physical examination form.
17			unacceptable registrants for induction	package and return to registrant's local board (label package: EXPOSED X-RAY FILM, and indicate name of induction station making shipment).
18	chest X-rays for tuberculosis care finding purposes	film accumulated by mobile X-ray service units	negatives indicating pathology	include in patient's medical record.
19			negatives indicating a normal chest	destroy after 30 days.
20	unidentified exposed X-ray film	X-rays which cannot be identified with the individuals to whom they pertain		destroy when encountered.
21	nominal index file	cards filed alphabetically as index to X-ray films		retire or destroy concurrently with the X-rays to which they relate.
22	radiation and radium therapy	copies of the following clinical record forms: Radiation Therapy, Radiation Therapy Summary, Radium Therapy, and Doctor's Progress Notes, filed in the Radiology Department (except those in the individual's medical record)		retire as permanent to WNRC on inactivation of the medical treatment facility.

Figure I-10 Table 160-4. AFR 12-50 (Contd)

### 1-3. Quality Assurance

Within the private business world, a quality assurance program is successful when the end product is delivered to customers with consistent high quality at the lowest possible price. That principle is not limited to just the private business world. In fact, every operation that produces an end product, including within the military and medical professions, should have a quality assurance program that is specially designed to best meet the prevailing conditions.

In this section we examine quality assurance as it relates to a radiology department. We explore the needs and benefits of such a program and what is included to make a program successful.

#### 814. Define terms pertaining to a quality assurance program.

**Quality Assurance Terms.** You need to be familiar with certain terms and their definitions used throughout this section.

**Quality assurance.** Quality assurance (QA) is planned and systematic actions that provide adequate confidence that a diagnostic X-ray facility will produce consistently high quality images with minimum exposure to patients and medical personnel. The determination of what constitutes "high quality" will be made by the facility producing the images. The radiologist in charge is usually the one that establishes quality guidelines that determine what is acceptable and what is not acceptable. Quality assurance actions include quality control techniques and quality administration procedures.

**Quality assurance program.** This is an organized methodology designed to provide quality assurance for a diagnostic radiology facility. The nature and extent of a program will vary with the size and type of facility, the type of examinations conducted, available personnel, and resources.

**Quality control techniques.** Quality control (QC) techniques are specified, documented procedures used in monitoring or testing the operation and maintenance of the components of an X-ray system. Thus, QC techniques are concerned directly with the equipment.

**Quality administration procedures.** These are management actions intended to ensure that monitoring techniques are properly performed and evaluated and that necessary corrective measures are taken in response to monitoring results. Administration procedures provide the organizational framework for the QA program.

**X-ray system.** An X-ray system is an assemblage of components for the controlled production of diagnostic images with X-rays. It includes minimally an X-ray high-voltage generator, an X-ray control, a tube-housing assembly, a beam-limiting device, and the necessary supporting structure. Other components that function with the system, such as image receptors, image processors, view boxes and darkrooms, are also part of the system.

### Exercises (814):

1. Define quality assurance as it pertains to radiologic services
2. Who establishes the quality standard for radiographs?
3. Define a radiologic quality assurance program
4. Define quality control techniques
5. Define quality administration procedures.
6. What provides the organizational framework for a QA program?

#### 815. Explain why quality assurance is needed and list the benefits of a quality assurance program.

**Need for Quality Assurance.** Too often radiology departments that don't have an active QA program experience a high percentage of rejected or repeated radiographs. While these films have no diagnostic value, they do serve as an excellent tool to indicate problem areas within the department. More often than not, an analysis of rejected films indicates that poor equipment performance is a significant cause of repeated films. Problems may arise in any part of an X-ray system.

The effect of poor quality images is twofold. If the image is not of optimum quality, the radiologist may not have all the diagnostic information that could be available. Although one might be able to draw useful conclusions from a poor film, it is obvious that a radiologist would prefer to read an optimal quality film. In addition, if the quality of the radiograph is so poor that it cannot be used, then the patient will have received unproductive radiation exposure. In this same line of thought, we can also state that poor quality films that are repeated add significantly to operating expenses of the department.

A quality assurance program should eliminate as many of those problems as possible and detect subtle changes in equipment operation so that they can be corrected before they affect the radiographic quality of the film. A QA program does not consist of just making measurements, recording the data, and filing the results. If the results are not periodically evaluated and corrective action taken when unacceptable areas are found, then all the efforts expended have been wasted.

The Department of the Air Force (DAF) has also recognized the importance of a radiology quality assurance program. Recent directives from DAF Headquarters provide guidelines for QA. A major point of interest to note is that Air Force policy states that all medical and dental treatment facilities must develop and maintain a QA program.

**Benefits of Quality Assurance.** Now that you can see the need for QA, it doesn't take long after the establishment of a QA program before you see its benefits. The impact of quality assurance programs is usually expressed in terms of a reduction in retake rate. Reducing the retake rate is a direct indication that unnecessary radiation exposure and medical costs have been reduced. Such reductions also indirectly indicate an overall improvement in image quality.

#### Exercises (815):

1. Explain briefly how poor quality images justify the need for quality assurance by explaining the effect these films have on diagnostic interpretation, patient protection, and operating expenses.
2. How can a QA program aid a department concerning image quality?
3. What is the Air Force policy concerning QA?
4. List three direct benefits of a good QA program.
5. What is an indirect benefit of a QA program?

#### 816. State responsibilities that various radiology personnel have concerning quality assurance.

**Responsibilities for Quality Assurance.** Virtually everyone connected with a radiology department has some degree of responsibility with quality assurance.

**Responsibilities of the radiologist.** The radiologist in charge has primary responsibility for quality administration. Since these actions guarantee that the QA program is operated properly, they are usually delegated to the NCOIC (or superintendent).

**Responsibilities of the NCOIC.** A clear assignment of responsibility, with the authority to carry out the responsibility assigned, is essential to the success of a QA program. The success of a program usually lies with the NCOIC because of the numerous responsibilities, some of which include the following:

- (1) Ensure that the QA program is carried out.
- (2) Ensure that proper documentation is recorded and maintained.
- (3) Ensure that equipment malfunctions are reported to medical equipment repair (MER) or other authorized equipment maintenance personnel.
- (4) Work closely with equipment maintenance personnel to develop new equipment requirements as needed.

**Responsibilities of technicians.** Staff technologists play a major role in the actual execution of the program. Some facilities may have technicians responsible for all the monitoring and testing procedures. Of course your responsibilities are at the discretion of your NCOIC but regardless of specific assigned functions that may be placed on you, you always have one important role: bringing possible problems to the attention of the specialized personnel (either the QA technician or the NCOIC). Sometimes problems can be spotted through preventive maintenance.

**Preventive maintenance.** Preventive maintenance is an inherent responsibility assigned to anyone that operates an X-ray system. This should be performed on a regularly scheduled basis with the goal of preventing breakdowns due to equipment failing without warning signs detectable by monitoring. Possible preventive maintenance procedures include visual inspection of the mechanical and electrical characteristics of the X-ray system. This covers such things as:

- Checking condition of cables.
- Watching the tomographic unit for smoothness of motion.
- Assuring cleanliness with respect to spilling of contaminants in the X-ray room or darkroom.
- Listening for unusual noises in the moving parts of the system.

Furthermore, preventive maintenance includes following the manufacturer's recommended procedures for cleaning and maintenance of the equipment and regular inspection and replacement of switches and parts that routinely wear out or fail. (NOTE: Equipment maintenance is usually performed by medical equipment repair center (MERC).)

#### Exercises (816):

1. What QA responsibility does the chief radiologist have?
2. What are four responsibilities of the NCOIC?
3. Who assigns monitoring duties to a staff technologist?

4. What major role do technicians have in QA?
5. Who has preventive maintenance responsibilities?
6. Explain how preventive maintenance aids a QA program

**817. Specify procedures associated with the monitoring of X-ray system components.**

**Parameters to be Monitored.** A routine quality control monitoring and maintenance program using state-of-the-art procedures should be established and conducted on a regular schedule. The purpose of monitoring is to permit evaluation of the performance of the facility's X-ray systems in terms of the standards for image quality established by the radiologist in charge and compliance with applicable regulatory requirements.

The parameters to be monitored should be determined by each facility on the basis of an analysis of expected costs and benefits. Such factors as the size and resources of the facility, the types of examinations conducted, and the quality assurance problems that have occurred in that or a similar facility should be taken into account in establishing the QA program. The monitoring frequency should also be based upon need and can be different for different parameters. Upon the identification of a problem area, you should temporarily increase the monitoring frequency to ensure that the corrective measures taken were effective.

It is not within the scope of this course to list or describe step-by-step procedures for each QC technique. The monitoring tests for the components of an X-ray system are too numerous, they have various specifications, and there are different procedures according to the type of equipment your department uses. Therefore, you need to refer to the manufacturer's publications for that equipment, as well as some publications that provide general guidelines for QC techniques. The National Technical Information Service (NTIS), a division of the US Department of Commerce, has some publications that may be ordered through your medical library. The publications that follow are some of those available from NTIS.

- a. PB80-101405, *Quality Assurance for Radiographic X-Ray Units and Associated Equipment*.
- b. PB80-129778, *Quality Assurance for Fluoroscopic X-Ray Units and Associated Equipment*.
- c. PB80-13338, *Radiation Recommendations Quality Assurance Programs for Diagnostic Radiology Facilities*.

Those publications, as well as other references you may use from additional sources, offer guidelines for performing monitoring tests. Regardless of which reference you have, you should consider monitoring the five key components of the X-ray system: (1) film processing, (2) cassettes and

grids, (3) view boxes, (4) darkrooms, and (5) basic performance characteristics of an X-ray unit

**Film processing.** Film processing problems are often the cause of poor quality films and are perhaps the most commonly monitored parameter. QC techniques for film processing could include tests for:

- a. An index of film speed.
- b. An index of contrast
- c. Base plus fog.
- d. Solution temperatures.
- e. Film artifact identification.

Some film processing tests require special test equipment, such as a densitometer and a sensitometer. If your department doesn't have test equipment for different parameters, your QA program can have serious deficiencies which can prevent your department from realizing the full benefits of a well-run program. You recall that we explained some film processing tests in Volume I of this course.

**Cassettes and grids.** Problems with these devices lead to retakes or, at the very least, a poor quality image. These tests are not difficult to master and can be done without special equipment. Tests on cassettes include:

- a. Film/screen contact.
- b. Screen condition
- c. Light leaks.
- d. Artifact identification.

(NOTE: Volume I also includes some QC checks for cassettes and screens.)

QC techniques for grids include

- a. Alignment of grid
- b. Focal distance.
- c. Artifact identification.

**View boxes.** This parameter is often neglected even though it affects image quality when films are being viewed. The following items can be evaluated.

- a. Consistency of light output with time.
- b. Consistency of light output from one box to another.
- c. View box surface conditions.

The uniformity of illuminators should be evaluated periodically and whenever a light bulb is changed. For this evaluation, only an optical light meter and viewing mask are needed.

**Darkrooms.** A darkroom should be just as its name implies—a "dark" room. QC techniques for the darkroom are concerned with the amount of light inside the darkroom during its use. This light should never be enough to affect the film by causing film fog. Therefore, you should test for *darkroom integrity and safelight conditions*.

When checking for the integrity of the darkroom, make sure light does not leak into the room. Light leaks can develop around pass boxes, doors, and film processors. You can check for light leaks by holding a film against these areas while inside a darkroom, process the film, and compare it (film fog with a base film (one not held up to suspected light leaks)). If film fog is present, then that area must be sealed against light leaks.

Safelight tests can be conducted in a similar manner. A common problem with safelights is film fogging due to small cracks in the light cover or an excessive bulb wattage.

**Basic performance characteristics of an X-ray unit.** Monitoring tests for X-ray units are numerous, and the type of procedure to be performed is dependent upon the type of X-ray unit you are testing. In other words, there are different QC techniques for fluoroscopic X-ray units, image-intensified units, automatic exposure control units (photo-timing), computed tomography units, and regular radiographic X-ray units. For example, some checks for a radiographic unit include:

- a. Reproducibility of X-ray output.
- b. Linearity and reproducibility of milliamperage (mA) stations.
- c. Reproducibility and accuracy of timer stations.
- d. Reproducibility and accuracy of kilovolt peak (kVp) stations.
- e. Accuracy of source-to-film distance indicators.
- f. Light/X-ray field congruence.
- g. Focal spot size consistency.

Some of those tests may apply to other X-ray units even though each type of unit may also have specific tests unique to that system. Special test equipment devices are often necessary to perform QA checks with X-ray units.

#### Exercises (S17):

1. Briefly explain how the parameters that are to be monitored are determined and what factors are taken into consideration?
2. Assume that you have conducted a performance check on an automatic film processor, found a problem, and took corrective actions on the unit. How is the monitoring frequency affected for that processor? Why?
3. Generally speaking, what are two sources that provide technical guidelines for performing QC techniques?
4. What are the five key components of an X-ray system that should be monitored?
5. List five quality checks that can be done for film processing.

6. What are two parameters you should monitor within the darkroom and what does each consist of?

#### 1-4. Radiology Personnel—Career Progression Field

Every radiology supervisor must be fully aware of the skill levels, AFSCs, and job titles (table 1-1) for our career field, which aid in managing our most important resource—our personnel. Furthermore, as technicians, we have an inherent responsibility to help train radiology personnel for upgrading. Often our new personnel are eager to advance through our career ladder but are unaware of certain requirements, such as those shown in figure 1-11. We have included this section to help you better understand the capabilities of your personnel and to assist them as they progress in radiologic technology.

#### 818. Specify how an airman basic gains entry into the radiology career field.

**Classification into the Radiology Career Field.** Entry into the radiology career field begins before enlistment into the Air Force with the administration of the Airman Qualifying Examination (AQE). This examination is administered by an Air Force recruiter and consists of test items pertaining to four areas of aptitude clusters. The areas are *mechanical, administrative, general, and electronics*. It has been proven that a minimum or better score in one or more of the four areas must be obtained in order for you to have a reasonable chance for success in a particular field. For example, in certain Air Force career fields related to electronics, the examinee must obtain a relatively high score in the electronics area. In the case of our career field, you must obtain a minimum of 45 in the general area.

**Classification interview.** As an airman basic (AFSC 99000) undergoing basic military training (BMT) at Lackland AFB, you probably took your first direct step toward entry into this field when you were interviewed by a career advisor. During this interview, four factors were considered: (1) AQE minimums, (2) biographical data, (3) Air Force requirements, and (4) the airman's preference. The AQE minimum was mentioned in the last paragraph. Biographical data include such factors as your education and occupational experience. High school courses in biology and chemistry are desirable for entry into radiology. Air Force requirements and airman's preference are self-explanatory although, obviously, the two must be considered in the order given. If the above factors permit entry into this field, the next step is completion of Course 3ABR90330 at Sheppard AFB, Texas.

**Bypassed specialist.** When an airman is qualified by virtue of prior civilian or military occupational experience or training, as determined by the career interview at Lackland AFB, then that person may be administered the apprentice knowledge test (AKT). The AKT for the radiology field is written by a panel of subject matter specialists (SMS) from the field who are master sergeants,

TABLE I-1  
RADIOLOGY SKILL LEVELS,  
AFSCs, AND JOB TITLES

SKILL LEVELS	AFSC	JOB TITLE
Superintendent	90399	Radiology Superintendent
Advanced	90370	Radiology Technician
Skilled	90350	Radiology Specialist
Semiskilled	90330	Apprentice Radiology Specialist
Helper	90310	Radiology Helper

senior master sergeants, or chief master sergeants. An airman who receives a favorable score on the AKT is considered a *bypassed specialist* and is awarded AFSC 90330. The airman is then required to complete Course 5AZO90350-1, Phase II training.

**Exercises (818):**

1. What is the Airman Qualifying Examination?
2. What is the purpose of the Airman Qualifying Examination?
3. What Airman Qualifying Examination score in what area is a mandatory requirement for entry into the radiology field?
4. What four factors are considered during the classification interview to determine into what career field an airman is placed?

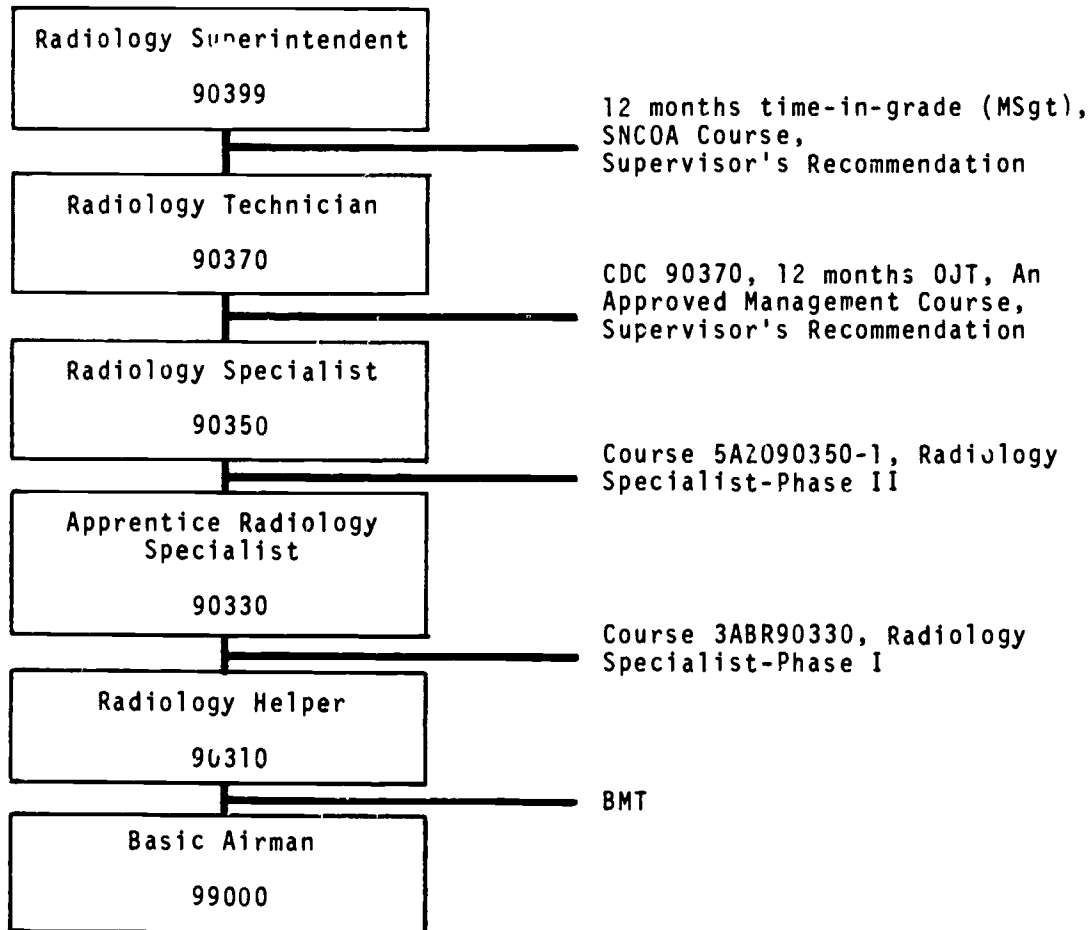


Figure I-11. Progression in the radiology career field.

- 5 How may an airman undergoing basic military training be awarded AFSC 90330 without attending Course 3ABR90330?

### 819. Specify requirements for career progression from AFSC 90310 to AFSC 90350.

**AFSC 90330.** Upon completion of basic training, airmen who are not bypassed specialists are assigned to Sheppard AFB to attend Course 3ABR90330. Course 3ABR90330 consists of approximately 14 weeks of instruction in the science of radiologic technology. The curriculum includes courses that enable students to meet the knowledge and performance levels required by the 3-level codes on the specialty training standard (STS). After successful completion of this course, students are awarded AFSC 90330.

**AFSC 90350.** The next step in progression up the radiology career field is completion of Course 5AZO90350-1. All airmen who are awarded AFSC 90330 must complete this course, which is taught at USAF medical centers, regional hospitals, and at other selected USAF hospitals. Students receive classroom as well as clinical training that meets the requirements of the knowledge and task levels as stipulated for a 5 level in the STS. Upon successful completion of this course, AFSC 90350 is awarded.

#### Exercises (819):

1. What AFSC and duty title are awarded after successful completion of Course 3ABR90330?
2. Where is Course 5AZO90350-1 taught?
3. What AFSC and duty title are awarded after successful completion of Course 5AZO90350-1?

### 820. Specify requirements for obtaining AFSC 90370.

**AFSC 90370.** The next step up the radiology career ladder is training to the "advance" skill level. Training to this skill level is a bit more involved than the others, so let's look at the requirements necessary to begin training.

**Initial requirements.** Before training is started to the 7 level, possession of AFSC 90330 is an obvious requirement. Also, each radiology specialist selected for upgrade training to the 7 level must be either a staff sergeant selectee or promoted to that grade. For example, SSgt selectees can voluntarily enter upgrade on the first month of the promotion cycle even though they haven't received the new stripe yet. If a selectee declines to begin

7-level training early in the promotion cycle, he or she must enter no later than the month of promotion to SSgt.

**Training requirements.** There are several requirements that must be met before you are awarded AFSC 90370. One requirement is successful completion of the CDC. You must complete this CDC within 1 year from the date of enrollment, or your enrollment is cancelled. You may request your OJT supervisor to ask ECI for an extension if, due to unusual circumstances, you are unable to complete the course in 1 year. The request must be made to ECI before the end of the 12th month (NOTE: If you are completing this course during your Phase III training as a prerequisite for certification, then you are not required to complete it again for upgrade training.)

Another requirement is at least 12 months of OJT for all routine trainees. If the trainee is a cross-trainee and possesses a 7 level in another AFSC, then 6 months of OJT may be waived. This job-experience training, along with the CDC, enables you to meet the 7-level coding requirements of the STS.

Before you obtain your 7 level, you also must have completed one of the following management courses.

- (1) NCO PME II, III, IV, or V—by correspondence or in-residence.
- (2) A base-level accredited management course, such as the Management Course for Air Force Supervisors (Management I)
- (3) ECI 0006 or 7B, Management for Air Force Supervisors. (This course is no longer available for enrollment but if an NCO has taken this course in the past, it still meets the requirement for the completion of a management course.)

(4) Squadron Officers School for NCOs who previously were officers.

(5) ECI Course 9 or 11, Management for Supervisors.

After the completion of at least 12 months OJT, CDC 90370, and a management course, you still need to satisfy two more requirements. First, you must meet the requirements of AFSC 90370 job description as found in AFR 39-1, *Airman Classification Regulation*. And, finally, all trainees must have their supervisor's recommendation for upgrading to the 7 skill level.

Once you begin your 7-level training, you have a maximum of 2 years in which to meet all requirements. During your 18th month of training, your commander will conduct an evaluation of your progress. You will receive a second commander's evaluation during the 24th month of training. Unless you are the victim of some unusual circumstances, such as incapacitating illness, chances are you will not be allowed to continue training after the 24th month. Consequently, you will remain at the 5 level and not be eligible for promotion to technical sergeant. Except for cross-trainees, the highest rank permitted with AFSC 90370 is master sergeant.

#### Exercises (820):

1. When may a radiology specialist begin training for the 7 level?

- 2 How long do you normally have to complete this CDC?
- 3 How may you receive an extension to complete this CDC?
4. What minimum time in training status is necessary before a routine trainee may be awarded AFSC 90370? For a cross-trainee with a prior 7 level?
- 5 What are the initial requirements a trainee must have before 7-level training can begin?
- 6 In general terms, what are the training requirements to obtain AFSC 90370?
7. What is the maximum time you have to complete your 7-level training?
8. When should you expect your commander's evaluations of your training progress?
9. Generally, what is the highest rank you may hold with AFSC 90350? With AFSC 90370?

**821. Specify requirements for progression to AFSC 90399.**

**AFSC 90399.** AFSC 90399, radiologic superintendent, is the highest skill level that you can attain in the radiology career field. Nuclear medicine technicians also use AFSC 90399 as their top skill level; therefore, a radiologic superintendent could previously have been either a radiology technician or a nuclear medicine technician. Naturally, preliminary requirements in both cases call for an appropriate 7 level and the rank of MSgt.

Training requirements for AFSC 90399 are:

- (1) At least 12 months time-in-grade as a MSgt.
- (2) Senior NCO Academy (SNCOA) correspondence course. For upgrading purposes, the SNCOA course is completed by correspondence only.
- (3) Supervisor's recommendation.

When a MSgt who has not completed all training requirements for the 9 level is selected for promotion to senior master sergeant, then that person is awarded AFSC 90399 at the time of selection for promotion. The 9 level is required for promotion to chief master sergeant.

**Exercises (821):**

- 1 What are the three training requirements for AFSC 90399?
- 2 When can completion of the SNCOA course be waived as a requirement for upgrade training?

**822. Specify requirements for becoming certified as a registered radiologic technologist in the USAF program.**

**Certification Training.** To qualify for certification testing by the American Registry of Radiologic Technologists (ARRT), you must complete a 24-month American Medical Association (AMA) accredited training program in radiologic technology. In addition, the school from which you graduate must certify to the ARRT that you have completed all phases of the training program.

**Structure of the USAF program.** The USAF AMA accredited training program is structured in the following manner. The School of Health Care Sciences (SHCS) is the accredited school that sponsors the program and is, therefore, responsible for the curriculum during the entire 24-month period. The Phase II training facilities are approved as clinical affiliates and provide the clinical education as outlined in the SHCS Phase II training plan. All USAF hospitals that have a full-time board-qualified radiologist on their staff are approved to provide the second year of training (Phase III). To satisfy the didactic portion of the curriculum during this second year, each student must complete CDC 90370. The SHCS must certify to the ARRT that each USAF applicant has satisfactorily completed all phases of the AMA accredited curriculum.

**Training requirements.** The training requirements that follow are necessary to apply for quality control testing, as well as certification testing by the ARRT.

- a. Be a graduate of Course 3ABR90330, Radiology Specialist (Phase I), or equivalent.
- b. Be a graduate of Course 5AZO90350-1, Radiology Specialist (Phase II).
- c. After graduation from Phase II, complete 12 months of clinical education in an Air Force medical facility under the direct supervision of a board-qualified radiologist. A consultant who is physically present for 16 or more hours per week would be considered as full time.
- d. Complete CDC 90370, *Radiology Technician*, during the clinical education period (Phase III). The CDC must be completed before quality control testing.
- e. Achieve a satisfactory score on the USAF quality control test for 903X0 personnel. This test is administered



three times a year (March, June, and September). Questions for the QC test are referenced from CDC 90370, AFR 160-30, *Radiologic Technology*, and the most recent edition of *Merrill's Atlas of Radiographic Positions*.

It is important for you to realize that the above is a summary of the requirements. Specific details pertaining to eligibility, dates, testing, and other requirements have been purposely left out. For specific details, questions should be directed to:

Phase II, Program Director  
School of Health Care Sciences, USAF  
Radiology Course MSDM/114  
Sheppard AFB, Texas 76311  
AUTOVON 736-2650

The commercial phone number, including the area code, is (817) 851-2650 (collect calls cannot be accepted).

### Exercises (822):

1. State five basic requirements for becoming certified as a registered radiologic technologist (ARRT) in the USAF program.
2. If you have questions pertaining to the registry program, to whom should you contact?

### 1-5. Air Force Occupational Safety and Health (AFOSH) Program

The Air Force supplies its people with the best quality equipment, supplies, and weapons systems which are needed to accomplish the mission. However, all that is useless without people to maintain and operate them. Since people are our most important resource, it is imperative that we keep them healthy, injury free, and able to perform their assigned duties. The Air Force Occupational Safety and Health Program is designed to do just that.

#### 823. Explain aspects of the AFOSH program that pertain to radiology services.

**Air Force Occupational Safety and Health (AFOSH) Program.** The Air Force conducts an intensive program to protect all Air Force personnel from work-related deaths, injuries, and occupational illness. As outlined in AFR 127-12, *Air Force Occupational Safety and Health Program*, it includes all safety, fire prevention, and health activities that affect the safety and health of Air Force personnel at their work stations.

**AFOSH Standard 127-8.** This standard applies to all Air Force military and civilian personnel working in medical facilities. This standard is used to assist the managers of USAF medical organizations in maintaining a safe environment and to administer a safety program compatible with Air Force directives, National Fire

Protection Association (NFPA) codes, standards of the Joint Commission on Accreditation of Hospitals (JCAH), pertinent Federal regulations and national consensus standards. Information provided in this standard highlights hazards peculiar to health care and health care related institutions and activities.

**General safety practices.** The responsibility to provide an environment free from unsafe acts or unsafe conditions requires that all levels of the hospital staff, functional managers, supervisors, and employees must be vigilant in the performance of their jobs to eliminate practices or conditions that could result in patient, visitor, and employee injury.

To make the hospital facility as safe as possible, employees should:

- a. Report to their supervisor any unsafe act or condition observed.
- b. Remove or wipe up any foreign material or liquid observed on floors.
- c. Know relevant work procedures and safe work practices.
- d. Not use any damaged or defective equipment.
- e. Learn correct lifting and handling procedures, especially to prevent back, muscle, or hernia-type injuries which frequently result from incorrect lifting techniques.
- f. Not participate in horseplay or practical jokes which often result in injuries.
- g. Report all injuries, however slight, to their supervisor and get immediate first aid.
- h. Insure that used needles, syringes, and sharp instruments are properly disposed in approved containers and never in wastebaskets, trash bags, or linen carts.
- i. Wear appropriate protective clothing and equipment when using cleaning solutions, solvents, caustics, etc., or whenever the job requires it, such as in laboratories, shops, etc.

As you can see, these general safety practices apply to everyone who works in the hospital. AFOSH Standard 127-8 also list safety practices and standards which are specific to radiology.

**AFOSH standards for AFSC 903X0.** You must be familiar with the section of AFOSH Standard 127-8 which covers radiology. Excerpts from the AFOSH standard read as follows.

(1) All X-ray equipment and facilities (including dental) will be surveyed by a qualified person according to the requirements of AFM 161-38, *Diagnostic X-Ray, Therapeutic X-Ray, and Gamma-Beam Protection for Energies Up To 10 Million Electron Volts*.

(2) Collimation of the useful beam to the smallest size necessary for the diagnostic procedure will be enforced by the person in charge. Collimators will be checked for accurate beam size control and alignment during routine safety inspections. X-ray technicians can easily accomplish this check by exposing a single film with the beam size limited to less than the film size and centered. A simple comparison of the image produced against that which was desired will indicate accuracy. Tolerances are presented in AFM 161-38. Facilities utilizing collimators with beam-defining lights should have the capability to dim the

overhead lighting to allow accurate alignment of the light field.

(3) Lead aprons and gloves will be in good condition. Racks will be provided to hang aprons when not in use. Aprons should not be folded as sharp creases result in cracks.

(4) Film badges will be worn by all physicians and technicians (including medical maintenance and bioenvironmental engineering personnel) when working with X-ray equipment.

(5) Positioning locks and motion limiters for X-ray equipment will be maintained in good working condition. Malfunctioning locks and limiters will be reported to medical maintenance immediately.

(6) Counter balance systems (weights, pulleys, cables, springs, locks, and brakes) should be checked on semiannual basis by medical maintenance personnel.

(7) Overhead movable X-ray equipment and cables will be positioned out of the way when not in use.

(8) Doors leading to X-ray exposure rooms will be labeled "X-ray exposure room, knock before entering." Doors will be kept closed during exposures.

(9) Lead drapes and the bucky slot shield on fluoroscopy units will be maintained in good condition. Lead drapes should be easily positioned and the bucky shield should effectively cover the entire slot.

(10) Good housekeeping is essential especially since a considerable amount of work is done under low levels of illumination.

(11) Portable X-ray equipment will be stored to prevent unauthorized use. A lead apron for the operator should be kept with the machine. When the machine is transported, the tube head should be in a lowered position.

(12) Use of radioactive materials will be strictly in accordance with Nuclear Regulatory Commission license and/or USAF permit conditions. The radiation protection officer specified on the license/permit will monitor this program.

**Hazards of AFSC 903X0.** Did you notice that in the list of standards for AFSC 903X0 that most of those standards

relate to radiation or to radiation equipment? Radiation is our most serious hazard in our career field. Other hazards include equipment, electricity, and chemicals. Volume I of this course deals more in detail with these hazards; therefore, we won't cover it again at this time.

#### Exercises (823):

1. What regulation covers the AFOSH program?
2. What is the purpose of the AFOSH program?
3. To whom does AFOSH Standard 127-8 apply?
4. What is the purpose of AFOSH Standard 127-8?
5. What publication lists safety hazards and standards for the radiology services?
6. What checks must be done on collimators during routine safety inspections?
7. Why is good housekeeping essential within an exposure room or while processing film?
8. List four general hazards of AFSC 903X0.

## Radiation Therapy

NOT LONG after Roentgen's accidental discovery of X-rays in 1895 scientists began to learn that ionizing radiation affected living tissue. Within months experiments began using radiation for the treatment of disease; thus, radiation therapy was in its infancy stage. The close of that century saw the first record of a cancer cure in 1899.

Today's radiation therapy (also called radiotherapy or, simply, therapy among radiation workers) has grown into a complex science with its own doctors (radiotherapists, therapists, health physicists), nurses, radiotherapy technicians, and dosimetry/accelerator technicians who are trained in therapeutic procedures from special schools. It is obvious that we cannot present all the information found in a 1 or 2 year radiotherapy school in this course. Instead, it is our intention to provide you with the general facts you need to better understand radiation therapy. Therefore, this chapter is generally oriented toward principles rather than specific procedures of radiotherapy.

### 2-1. Introduction to Radiation Therapy

The first section of this chapter deals with the basis and purpose of radiotherapy, then we cover oncology (the study of tumors) to see how it relates to radiotherapy.

#### 824. Specify the basis and purpose of radiation therapy.

**Basis and Purpose of Radiation Therapy.** Penetration and ionization are two important characteristics of radiation that make it useful in the treatment of disease. Since radiation can penetrate body tissues, it obviously has the capability to reach into areas where pathological processes may exist. When radiation is directed toward an area of the body containing cancer, ionizations occur in the normal, as well as the abnormal, tissues. The ionizations produce biological changes in both normal and abnormal cells. These biological changes, in part, damage or control the growth of both types of cells; however, the response to the radiation is not entirely the same. As a rule, abnormal cells are more sensitive to radiation than normal cells.

All cells are more radiosensitive during mitosis, the stage of cell division. Malignant tumors are more likely to have a greater proportion of dividing cells than the adjacent normal tissues and are more likely to show a greater response to irradiation. Radiation therapy is based on this differential response of cells to radiation.

The ideal in radiotherapy would be to kill off all tumor cells without causing any damage to normal cells; however, this is not possible; and we have to compromise by causing as little damage as possible to normal cells. By carefully subjecting cells to radiation, therapists aim to damage or

control the growth of abnormal cells, while, at the same time, they try to spare the surrounding normal or healthy cells as much as possible.

#### Exercises (824):

1. What is the basis of radiation therapy?
2. What is the purpose of radiation therapy?

#### 825. Differentiate between benign and malignant tumors.

**Tumors.** The word "tumor" covers a broad spectrum of growths. We can define tumor as a new growth of tissue (neoplasm) which is abnormal or diseased. Generally, we can group all tumors as either *benign* or *malignant*.

**Benign tumors.** A benign tumor is one that exists only in its immediate site of growth. It is usually enclosed in a capsule that prevents it from spreading to a remote site. Benign tumors are, for the most part, less dangerous because they can be totally removed by surgery. In some cases, however, they can become dangerous. An example, of a dangerous benign tumor is one growing and spreading in the region of the brain. Having no room to expand, it damages the surrounding brain tissues as it grows. Benign tumors are usually not treated with radiation, but they may be if they are not surgically removed.

**Malignant tumors.** A malignant tumor, like a benign tumor, is a growth that may cause damage at the place where it first appears. The key difference between a malignant tumor and a benign tumor is that only a malignant tumor may spread to other locations within the body and cause damage to remote sites. This spreading of a malignant tumor is called *metastasis*. The initial growth is called a *primary* tumor, while a growth resulting from metastasis is called a *secondary* or *metastatic* tumor. Most radiation therapy is directed toward malignant tumors.

Tumors may spread by one of three methods: (1) direct local spread, (2) by way of the lymphatic system, or (3) by way of the circulatory system. Direct local spread implies that the tumor grows directly from its original site and invades surrounding organs or tissues. When a tumor spreads by way of the lymphatic system, tumor cells enter the lymphatic system and are carried along the lymphatic ducts and either become lodged in a duct or in a lymph node

where a secondary tumor is formed. Tumor cells may also move from the secondary tumor and form other secondary tumors. Malignant tumors spreading by way of the circulatory system do so in a manner similar to those spreading through the lymphatic system. In this case, secondary tumors may form in virtually any of the body tissues, although certain metastatic sites are more common than others.

**Exercises (825):**

- Match the type of tumor in column B with the appropriate statement or phrase in column A by placing the letter of the column B item in the space provided in column A. Each column B item may be used once or more than once. In addition, both column B items may match a single column A entry.

Column A	Column B
___ (1) Growth	a Benign.
___ (2) May cause damage at remote location	b Malignant
___ (3) More dangerous	
___ (4) Enclosed in a retarding capsule	
___ (5) Secondary lesion	
___ (6) Moves via the circulatory system	
___ (7) Radiation therapy is usually directed toward this type	
___ (8) Causes damage by direct local spread	

**826. Classify benign and malignant tumors as to epithelial or connective.**

**Further Classifications of Tumors.** We can further classify benign and malignant tumors according to their tissue origins or the type of tissue each tumor attacks. Basically, neoplasms originate in two types of tissue: *epithelium* (glandular or nonglandular) and *connective tissue*.

**Epithelial tumors.** Epithelial tumors can be either benign or malignant and are either glandular or nonglandular. Some benign epithelial tumors are *adenoma* (such as breast or thyroid) and *papilloma* (bladder wall).

Epithelial tumors that are malignant are called, collectively, *carcinomas*. These are the most numerous of all cancers (or malignancies). Glandular epithelial tumors that are malignant are called *adenocarcinomas*, such as for the breast or thyroid glands. Nonglandular epithelial tumors that are malignant are *squamous cell carcinoma*, which arises from squamous epithelium, and *basal cell carcinoma*, which arises from the basal layer of the skin.

**Connective tissue tumors.** These tumors can be either benign or malignant. Connective tissue tumors that are benign are named after the type of tissue from which they arise. Some common ones are:

- *Fibroma*: fibrous tissue.
- *Chondroma*: cartilage.
- *Lipoma*: fat.
- *Osteoma*: bone.

Connective tissue tumors that are malignant are called *sarcomas*. Because these may metastasize, they are named after the tissue of origin. Some of these are:

- *Fibrosarcoma*: fibrous tissue
- *Chondrosarcoma*: cartilage
- *Liposarcoma*: fat
- *Osteosarcoma*: bone.

Although there are many other types of benign and malignant tumors, those that we list are the more common forms. No doubt you will become familiar with other types of tumors should you work for some time in a radiation therapy section.

**Exercises (826):**

- Match the type of tumor in column B with the appropriate statement or phrase in column A by placing the letter of the column B item in the space provided in column A. Each column B item may be used once or more than once.

Column A	Column B
___ (1) Adenocarcinoma	a Benign epithelial tumor
___ (2) Chondroma	b Benign connective tissue tumor
___ (3) Osteoma	c Malignant epithelial tumor
___ (4) Liposarcoma	d Malignant connective tissue tumor
___ (5) Papilloma	
___ (6) Squamous cell carcinoma	
___ (7) Basal cell carcinoma	
___ (8) Adenoma	

**827. Name and briefly assess two factors influencing the success of tumor treatment by radiation and identify the two types of radiation treatment.**

**Types of Tumor Treatment.** Not all malignant tumors can be successfully treated with radiation therapy. The success of the treatment depends upon several factors. One of the influential factors is the sensitivity of the tumor tissue to radiation—some tissues are more sensitive or *radiosensitive*; others are less sensitive or *radioresistant*. The more sensitive the tumor, the greater the chance for successful treatment. Another factor influencing the outcome of the treatment is the stage of development in which treatment is initiated. Early treatment increases the chance for success. Generally, treatment of tumors can be classified as radical (curative) or palliative.

**Radical.** Radical treatment of a tumor means that an attempt is made to cure the patient. By cure, we mean that for 5 years from the time of treatment the patient remains alive and well with no sign of the disease.

**Palliative.** Palliative treatment is reserved for those patients whose condition has deteriorated to the point where a cure is not possible. The treatment is usually oriented toward the patient's symptoms and may be of significance in reducing pain or enhancing some basic function, such as breathing or swallowing, if a tumor interferes with that function.

### Exercises (827):

1. Name two factors influencing the success of radiation treatment. In each case, briefly discuss how the treatment is affected.
2. What is radical treatment?
3. When is the patient considered to be cured?
4. What is palliative treatment?

### 2-2. Radiotherapy Equipment

A well-equipped radiotherapy department will have different units for tumor treatment and various equipment associated with treating patients. Some associate equipment includes simulators, computers, and computerized tomography. Radiotherapy simulators are fluoroscopic and radiographic units which will exactly duplicate the treatment geometry allowing the therapist and treatment planning team to produce the optimum treatment plan. Computers are used to collect and display data used in treatment planning in the form of isodose distributions conforming to the body. Computerized tomography scans are frequently used to localize tumors and help in treatment planning.

In addition to that equipment associated with treatment planning, a radiotherapy department may have a variety of equipment used to administer radiotherapy treatments. In this section we explain differences in radiotherapy

equipment which you may become associated with sometime during your radiology career.

### 828. Differentiate among types of external beam therapy machines.

**External Beam Therapy Machines.** There are basically two types of therapy units used for external irradiation: (1) the X-ray machine and (2) the teletherapy apparatus. The X-ray unit produces X-rays only when the current is switched on. The teletherapy unit has a source of radioactive material which is giving out gamma rays continuously. Therefore, the source must be housed in a compartment within the machine head that prevents radiation leakage. Notice in figure 2-1, a cross-sectional representation of a head of a teletherapy machine, that when the machine is in the OFF position, the radioactive material (such as cobalt 60) is completely surrounded by a protective covering (usually lead). When the machine is in the ON position, the chamber containing the cobalt is moved to allow radiation to emit through the aperture opening of the machine head.

Other than its method of radiation production, external beam units also differ because of their energy levels and beam characteristics. Differences in energy levels are needed because of various locations where malignancies are found. A tumor in the pelvis requires deeper penetration of the beam when compared to malignant lesions near the skin. Different equipment has different characteristics which can be used to enhance the therapeutic effect of treatment. Thus, a radiotherapy department should have a range of equipment to be able to treat all lesions.

Some common energy ranges of equipment still widely used are *superficial*, *orthovoltage*, and *megavoltage* (or *supervoltage*).

**Superficial X-ray machines.** These units are capable of producing X-rays within the range of 60 to 140 kilovolts. As the name implies, this is used for treating superficial malignant lesions of the skin or just below the skin. Energy levels below this range are rarely, if ever, used.

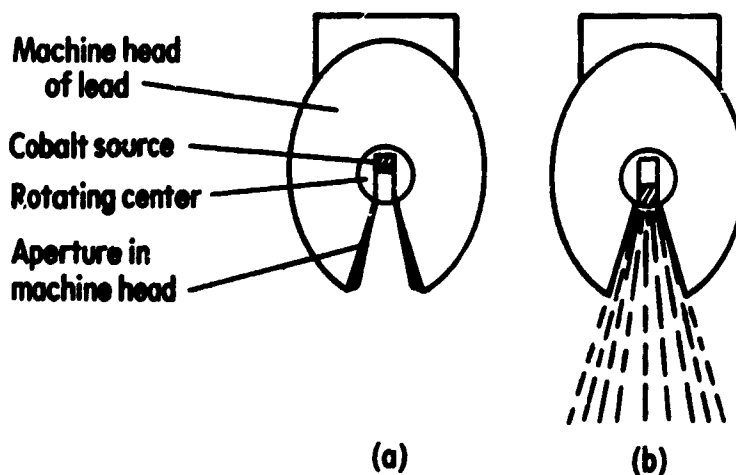


Figure 2-1. Cross-sectional representation of a teletherapy machine head

**Orthovoltage machines.** Since various references conflict on an exact range and since it is our purpose to show how types of external beam therapy units differ by energy levels, we will consider orthovoltage consisting of that energy range between 140 kiloelectronvolts (KeV) to 300 KeV.

This is also called deep X-ray therapy because the radiation allows treatment of tumors that are further away from the skin. They have now been replaced in many departments by megavoltage (MeV) units, but orthovoltage units are still being used for malignancies lying relatively close to the skin.

**Megavoltage machines.** These machines produce radiation above 1 MeV and are mainly of two types: the cobalt 60 teletherapy unit and the linear accelerator.

**Radioactive cobalt.** Perhaps the most widely used source for teletherapy units is radioactive cobalt ( $^{60}\text{Co}$ ) which produces gamma rays that are approximately equivalent to X-rays produced with an energy of about 1.2 MeV.

Cobalt 60 is continuously decaying; and the output of such a machine decreases by 10 percent each year; thus, you need to maintain output charts as time goes on to calculate daily doses and to determine when to replace the source. The advantage of this equipment is that there are no complicated electronics to go wrong and the replacement of cobalt is practically the only servicing needed.

**Linear accelerators.** These machines produce X-rays at very high energies—in clinical practice most linear accelerators operate at between 4 and 10 MeV for the low energy linear accelerators or between 18 and 25 MeV for those in the high energy range.

These machines are complex masses of sophisticated electronics and need expert attention from therapists and technicians.

Linear accelerators are so called because they accelerate a stream of electrons down an evacuated tube to hit a target and produce high energy X-rays. High energy (15 to 45 MeV) linear accelerators also have the capability to treat directly with electrons of various energy selections. Electrons have the distinct advantage of depositing most of their energy within a few centimeters of the skin surface. This allows treatment of tumors which are relatively close to the skin while sparing the exit portion of the treatment field from radiation.

**Betatrions.** A betatron is a machine similar to a linear accelerator in that both are designed to produce high energy X-rays. Betatrions, however, are capable of producing extremely high energy photons usually operating in the range of 20 to 50 MeV, even though some models can go much higher. These machines are also capable of producing electron beams.

#### Exercises (828):

1. Explain briefly how the two basic types of therapy units differ because of their method of radiation production.

2. What are the three energy levels that are used in radiotherapy?
3. Why are differences in energy levels needed with various therapy units?
4. Which energy range of therapy is also called deep X-ray therapy?
5. What radioactive source is commonly found in teletherapy units?

#### 829. Define brachytherapy, and identify the three methods of brachytherapy.

**Brachytherapy.** Brachytherapy is a method of radiation therapy in which sealed gamma or beta sources are utilized to irradiate tumors at distances of up to a few centimeters. It does this by one of three methods: interstitial, intracavitary, or surface application.

**Interstitial therapy.** In this method, the radiation source is positioned directly into the tissues to be treated. Special tubes, needles, and seeds (cells) containing radioactive substances are used to deliver radiation into a tumor. Sources commonly used may be radium 226, iodine 125, cobalt 60, gold 198, or iridium 192, although any radioactive material with appropriate radiation energy, half-life, and physical properties could be used.

**Intracavitary therapy.** Intracavitary therapy introduces a radioactive source into a body cavity to reach a tumor site. The same containers and source materials that are used in interstitial therapy can be used with this method.

**Surface application.** This method is the least used method; it is virtually obsolete. Special applicators, plaques, or molds are filled with a radioactive source and placed in contact with the patient's skin. This was useful for treating malignancies of the skin but is now being replaced by external beam therapy. Strontium 90 applicators are still widely used for treating pterygiums, a benign lesion of the eye.

#### Exercises (829):

1. Define brachytherapy.
2. What are the three methods of brachytherapy?

3. Which method positions a radiation source directly into the tissues to be treated?
4. Which method is virtually obsolete?

### 2-3. Responsibilities and Safety Procedures

A therapy technician administers prescribed treatment under the direct supervision of a qualified therapist. In this situation, you serve as an assistant to the therapist who is responsible for the patient treatment. Additionally, you are responsible for the safety and welfare of patients who are undergoing the treatment you are administering. You must fully understand your responsibilities and limitations in all matters of radiotherapy patient care and treatment. In this section, we cover general responsibilities and safety procedures you need to know to help you administer therapy treatment.

**830. Specify responsibilities that a radiotherapy technician has to the patient and explain the correct procedure for various situations.**

**Your Responsibilities to the Patient.** Without the patient's cooperation, successful radiotherapy cannot be done. There are certain things you can do to gain the confidence of the patient.

**Practice the "Golden Rule."** You should always be considerate and sympathetic. The patient, particularly during the initial treatment experience, may understandably be apprehensive and require reassurance. Often the radiotherapy administered is palliative for seriously ill patients in the terminal stages of cancer; frequently, these patients are emotionally disturbed. These patients need your understanding and "tender-loving care."

**Prepare the patient.** Before therapy is initiated, there are certain things you should explain to the patient. For example, the patient should be informed of the body areas to be treated and for how long. Any symptoms that may develop because of the treatment should be explained.

The patient should be told a little about the type of equipment to be used and how the patient will be positioned in relation to the equipment. For example, you can show the patient automatic timers and other safety devices so that he or she understands that they are fully protected. The purpose of lead shields, treatment cones, and collimators should also be explained from the standpoint of the protection which they afford.

**Protect the patient's privacy.** Under no circumstances should you ask personal questions to patients about their disease. Also, don't discuss details about one patient to another patient. All information available to you should be kept in strict confidence. If patients should ask you questions about their condition, you should answer only questions you are qualified to answer and refer others to the therapist. You should always remember the serious nature of the patient's condition and how important the correct answers might be to them.

Ulcerated areas on exposed parts should be covered with a dressing to conceal their unsightliness. If odor from such wounds cannot be controlled, allow the patient to wait in a separate room away from others.

**Provide encouragement.** Many patients associate malignant disease with a hopeless prognosis; sometimes, more than death they fear the possibility of suffering or the likelihood that they will live only to suffer later or to end up useless—a vegetable—unloved and unwanted. In other words, they may fear dying more than death. Where there is a good hope of cure, this must be stressed and the patient supported even when he or she thinks there is no cure. You can provide encouragement by being cheerful and responsive to the patient's needs. This includes arranging appointments for followup examinations and blood counts, filling out appointment forms, and encouraging the patient to return for followup examinations.

#### Exercises (830):

1. In general, what are the four main responsibilities that a radiotherapy technician has to a patient?
2. When preparing a patient for treatment, what may you tell him or her about the treatment?
3. Explain what you should do if a patient questions you about his or her condition.

**831. Specify responsibilities that a radiotherapy technician has to a radiotherapist, and explain the correct procedure for various situations.**

**Your Responsibilities to the Therapist.** These duties primarily consist of assisting the therapist and performing administrative functions.

**Assisting the therapist.** We think of these tasks as those that primarily deal with treating patients, such as positioning, immobilization, beam centering, radiation protection, and practicing safe operating procedures.

You should exercise extreme care in positioning patients to insure that they are placed in a restful position and under no physical strain to hold themselves still. This may be done by judicious use of sandbags and other restraining devices. With child patients, proper restraint may also be necessary.

If possible, shield all areas of the body exposed to the radiation field but not incident to the treatment. A visual localizer on the therapy unit indicates the area under treatment. Shielding may be done by using lead blocks, custom blocks, or various-size cones which restrict the field of treatment. It is especially important to protect certain sensitive tissues, such as the eyes, larynx, earlobes and hairline. Flexural surfaces, such as the neck, groin, and popliteal areas, should be protected to ensure these areas do not exceed the radiation tolerance prescribed by the radiotherapist.

To avoid injury to the patient, exercise extreme care when moving the treatment unit or treatment couch. One of the most significant dangers is that of dropping a lead shielding block weighing from 1/2 to 20 pounds on a patient. Moving of shielding blocks over a patient requires extreme care to prevent a patient from being injured by a falling block.

You must constantly observe the patient on a television monitor or mirror and the controls of the therapy unit. If the patient should move, terminate treatment immediately and reposition.

Since there is considerable variation among different machines used for radiation therapy, it is extremely important that only a fully qualified technologist operates any unit used. Compromise of a patient's treatment by unqualified technicians could cause serious injury, complicate the treatment efforts of the radiotherapist, or even cause the death of a patient.

Carefully study the proper operating procedures for the particular unit to be used for the treatment, and carry them out meticulously. You should never operate a radiation therapy unit unless you are fully trained in its use, know the effects to the patient, and are aware of the hazards to the staff and general public.

When giving a treatment, you must constantly monitor the control console. If any unusual variation occurs, immediately call it to the attention of the therapist.

Another major responsibility you have to the therapist is recordkeeping. Certain data must be kept current in the patient's records. This should include (1) the nature of the beam, such as the type (cobalt 60 or X-ray) used, its energy level, and the filtration used; (2) technique or dosage, such as information on ports, source-skin distance, number of treatments, dose rates, etc. Other data may be included as necessary. Some forms presently used are SF 524, Clinical Record—Radiation Therapy, SF 525, Medical Record—Radiation Therapy Summary, and SF 526, Clinical Record—Radium Therapy. (AFR 168-4, *Administration of Medical Activities*, explains these forms).

Lists that deal with responsibilities are by no means conclusive; you can probably think of some more. Use these ideas in your job and build on them as you strive to be the best.

#### Exercises (831):

1. In general, what two main areas of responsibility do you have to the therapist?
2. Explain what you can do to ensure that only a specific area of the patient is irradiated.
3. Explain what you should do if a patient moves during a treatment.

#### 832. Specify safety procedures used in radiotherapy.

**Safety Procedures for Radiotherapy.** Many safety procedures that are applicable for diagnostic radiology should also be followed carefully when doing radiotherapy. Most of these deal with radiation protection for you and your patient; some deal with the equipment to prevent its damage or injury to a patient. We covered some of these commonsense items in the section about your responsibilities to the therapist. There are a few more guidelines we want you to be aware of when you do radiotherapy

a. Both the control panel and patient should be kept under observation during exposure. This point is so important we wanted to bring it to your attention again. If any unusual variation of the controls occurs, immediately terminate treatment and call it to the attention of the therapist. If the patient should move, stop treatment immediately and reposition the patient.

b. Use mechanical supporting or restraining devices when a patient must be held in position.

c. Emergency procedures to be followed in the event of failure of the beam control mechanism should be established and posted at the control panel. If the light signals indicate that the beam control mechanism has failed to terminate the exposure at the end of the preset time (for example, if the red light stays on and/or the green signal does not light up) the source may still be in the ON position. You should carry out the following steps in a calm manner.

- (1) Open the door to the treatment room.
- (2) If the patient is ambulatory, direct that person to get off the table and leave the room.
- (3) If the patient is not ambulatory:
  - (a) Enter the treatment room, but avoid exposure to the useful beam.
  - (b) Pull the treatment table as far away from the useful beam as possible.
  - (c) Transfer the patient to a gurney, and remove the patient from the room.
- (4) Close the door.
- (5) Turn off the main switch at the control panel.
- (6) Notify the radiation therapist and radiation protection officer at once.

Emergency procedures at your medical facility may vary somewhat from those we just listed. Regardless, the principle remains the same: Immediately remove the patient from the room. Emergency procedures are usually practiced as a realistic drill under the guidance of a health physicist.

#### Exercises (832):

1. What should you do if any unusual variation of the controls occurs?
2. If the beam control mechanism fails to terminate an exposure, what steps should be taken to remove from the treatment room a patient who is unable to walk?



## Bibliography

### Books

- Deeley, Thomas J., *Principles of Radiation Therapy*, First Edition, Woburn, Massachusetts: Butterworths (Publishers) Inc., 1976.
- Howl, Barbara, *Simplified Radiotherapy for Technicians*, First Edition, Springfield, Illinois: Charles C. Thomas Publisher, 1972.

### Department of the Air Force Publications

- AFR 12-50, *Disposition of Air Force Documentation*, Table 160-4, Radiology.
- AFM 67-1, Volume 5, *Air Force Medical Materiel Management System—General*.
- AFOOSH Standard 127-8, *Medical Facilities*.
- AFR 127-12, *Air Force Occupational Safety and Health Program*.
- AFR 168-4, *Administration of Medical Activities*.

### Commercial Manual

- PB-183338, *Radiation Recommendations Quality Assurance Programs for Diagnostic Radiology Facilities*, First Edition, Springfield, Virginia. U.S. Department of Commerce, National Technical Information Service, 1980.

## Answers for Exercises

### CHAPTER I

**Reference:**

- 800 - 1 The obligation to care for Air Force property with which you are associated
- 800 - 2 Proper care
- 800 - 3 (1) b  
(2) c  
(3) b  
(4) a  
(5) d
- 801 - 1 Property custodian
- 801 - 2 The person is recommended by his or her supervisor and designated by the DBMS
- 801 - 3 The new property custodian
- 801 - 4 Once a year
- 801 - 5 MEMO
- 801 - 6 AF Form 601
- 801 - 7 To insure compliance with local policies
- 802 - 1 The obligation to pay for an item if it is lost, damaged, or destroyed as a result of maladministration or negligence
- 802 - 2 (1) Pay in cash through the use of DD Form 1131 or (2) authorize the Government to deduct the amount from your paycheck through the use of DD Form 362
- 802 - 3 When a person does not admit liability or when the amount is \$500 or more.
- 802 - 4 Makes a detailed and impartial investigation of the circumstances connected with the loss, damage, or destruction of Air Force property
- 802 - 5 When there is no evidence of negligence, willful misconduct, or deliberate use of equipment resulting in damage or loss
- 803 - 1 (1) a  
(2) d  
(3) d  
(4) f  
(5) d  
(6) a, b  
(7) a, b, c  
(8) a  
(9) c
- 804 - 1 (1) b  
(2) b  
(3) a  
(4) a  
(5) b  
(6) a  
(7) b
- 804 - 2 (1) 6525  
(2) 65  
(3) 299-8300  
(4) 6525.
- 805 - 1. To make sure back-ordered items appear, if they do not, supply will not issue you the item when it is available.
- 805 - 2. (1) Telephone orders; use your shopping list and provide the supply clerk with the line number and number of items needed.  
(2) DD Form 1348-6; submit your order on this form
- 806 - 1. (1) To ensure that the items are available when needed  
(2) To prevent the accumulation of excess items
- 806 - 2 2 weeks
- 806 - 3 Your ordering rate (which should correspond to your consumption rate)
- 806 - 4 The medical supply section may end up overstocked or without the item altogether
- 806 - 5 Advise medical supply personnel of the change
- 807 - 1 Items become excess to the needs of the department or they become unserviceable.
- 807 - 2 Property custodian
- 807 - 3 The property custodian prepares an AF Form 601 for the item and submits it and the item to MEMO
- 807 - 4 The price as of the turn-in date
- 807 - 5. If none are due-in, you may receive credit for two if the dollar value is over \$25
- 807 - 6 There is no credit received for materiel turned in for destruction.
- 807 - 7 \$25
- 808 - 1 8 months
- 808 - 2 Resource management
- 808 - 3 On the last page of your monthly issue lists
- 808 - 4 August
- 808 - 5 Table of allowances
- 808 - 6 A local Medical Equipment Review Board
- 808 - 7 AF Form 601
- 809 - 1 It allows the technician to make the proper technical adjustments and alerts the radiologist to certain findings that may rule out or support the preliminary diagnosis
- 809 - 2 The block titled "Ward No " should have the name of the outpatient clinic
- 809 - 3 The nominal index file
- 809 - 4. After cross-referencing the SF 519A with the nominal index file, write in the upper-left corner of the 519A either "F" (for file) and the last-four SSAN or "N" (for new) and the last-four of the patient's SSAN; you may also indicate the year that previous films are filed
- 809 - 5 The patient could have been X-rayed in another facility and the films transferred to your department.
- 809 - 6 In the patient's film file envelope maintained in chronological order (most recent report on top)
- 809 - 7 To the ward for inpatients, or to the medical records section for outpatients
- 810 - 1 (1) To indicate whether or not a patient has a film envelope on file, (2) in what year's files the previous film envelope is located, (3) to provide a chronological listing of exams the patient received in the department, (4) to indicate if films from another facility have been received, and (5) to use as a flash card for identification of a patient's films
- 810 - 2. It indicates if a previous film envelope is in file.
- 810 - 3 Check the nominal index file to determine if the patient's index card has that particular exam listed. If so, bring this fact to the attention of the requesting physician, who will decide if a repeat study is necessary. If a particular exam had recently been accomplished, it may not be necessary to perform it again
- 810 - 4 Write on the index card "FFR" and the date the films were received and filed.
- 810 - 5 AFR 12-50, *Disposition of Air Force Documentation*.
- 810 - 6. Concurrently with the X-ray films to which they relate
- 810 - 7 1 January 1986.
- 811 - 1 Cutoff date is 31 December of each year and new files are established on 1 January of each year

- 811 - 2 Full name, rank or dependency status, SSAN, and a chronological listing of each procedure contained within the folder
- 811 - 3 The primary number
- 811 - 4 1989
- 811 - 5 03—Primary number  
72—Secondary number  
46—First part-tertiary number  
456—Second part-tertiary number
- 811 - 6 189-39-79-22  
873-40-86-31  
973-40-86-31  
972-41-86-31  
865-49-87-31  
106-00-32-72  
101-00-32-77  
374-99-68-77  
370-99-69-77  
591-37-11-80  
623-40-09-83  
620-49-09-83  
376-18-19-92  
375-17-20-92  
408-01-00-99  
407-00-01-99
- 811 - 7 (1) Place the films in a loan envelope which contains the patient's name and SSAN. Keep the file copies of the SF 519A in the original folder, annotate the loan record section, and put the original folder back in file  
(2) Complete AF Form 614 and attach file copies of SF 519A to it and place it in the file where the original folder was kept  
Loan out the films in the regular film folder
- 811 - 8 They are kept in the file room
- 812 - 1 AFR 12-50, *Disposition of Air Force Documentation*, table 160-4
- 812 - 2 Salvage or destroy when of no further value
- 812 - 3 21
- 812 - 4 3 months
- 813 - 1 The total number of X-ray films exposed on inpatients and outpatients, number of fluoroscopic examinations accomplished on the inpatients and outpatients, and number of radiographs interpreted by your radiologist but actually performed at another facility
- 813 - 2 Number of specific radiographic procedures accomplished each month, nuclear medicare procedures, ultrasound visits, students formally enrolled in course 5AZ090350-1, Phase II
- 813 - 3 (1) To aid in managing medical service programs, (2) for planning construction, (3) for budgeting, and (4) to determine the general health of the population s
- 813 - 4 Resource management office, monthly
- 814 - 1 Planned and systematic actions designed to ensure that consistently high quality images are produced while at the same time keeping radiation exposure to the patient and medical personnel to a minimum
- 814 - 2 The radiologist
- 814 - 3 An organized program designed to provide quality assurance
- 814 - 4 Specific procedures for monitoring and testing the operation and maintenance of X-ray system components
- 814 - 5 Management actions that ensure monitoring techniques are properly performed and evaluated and necessary corrective measures are taken in response to those results
- 814 - 6 Quality assurance procedures.
- 815 - 1 They may reduce the amount of diagnostic information that could be available to the radiologist, indicate that the patient received unnecessary radiation if the films are worthless, and increase operating expenses if the films are repeated
- 815 - 2 It can prevent many of the problems that can cause poor image quality by detecting small changes in equipment operation so that corrections can be made before image quality is affected
- 815 - 3 All medical and dental facilities must develop and maintain a QA program.
- 815 - 4 (1) Reduction in retake rate, (2) reduction in radiation exposure to the patient, and (3) reduction in operating costs
- 815 - 5 An overall improvement in image quality
- 816 - 1 Primary responsibility for quality administration
- 816 - 2 (1) Ensure that the QA program is carried out, (2) ensure that proper documentation is recorded and maintained, (3) ensure that equipment malfunctions are reported to maintenance personnel, and (4) work with equipment maintenance personnel to develop new equipment requirements as needed
- 816 - 3 The department NCOIC
- 816 - 4 Bringing possible problems to the attention of the NCOIC or QA monitor
- 816 - 5 Anyone that operates an X-ray system
- 816 - 6 It helps prevent breakdowns due to equipment failures
- 817 - 1 Each radiology department decides which parameters that will be monitored in its QA program. The decision is based on an analysis of expected costs and benefits after considering the size and resources of the facility, the types of exams done, and QA problems that have previously occurred in the department
- 817 - 2 The monitoring frequency for any X-ray system component that had corrective actions taken on it should be temporarily increased. To ensure that the corrective actions were effective
- 817 - 3 Manufacturer's publications for your equipment and the National Technical Information Service
- 817 - 4 (1) Film processing, (2) cassettes and grids, (3) View boxes, (4) darkrooms, and (5) basic performance characteristics of an X-ray unit
- 817 - 5 (1) Film speed, (2) film image contrast, (3) base plus fog, (4) solution temperatures, and (5) film artifact identification
- 817 - 6 (1) Darkroom integrity—checking for light leaks around pass boxes, doors, and film processors and (2) safelight conditions—making sure film fog does not occur because of cracked safelight covers or an excessive bulb wattage
- 818 - 1 An examination administered by Air Force recruiters consisting of test items pertaining to four aptitude clusters, (1) mechanical, (2) administrative, (3) general, and (4) electronics
- 818 - 2 To predict success in a particular career field
- 818 - 3 45, general
- 818 - 4 (1) AQE minimum, (2) biographical data, (3) Air Force requirements, (4) airman's preference
- 818 - 5 Py receiving a favorable score on the apprentice knowledge test
- 819 - 1 90330, Apprentice Radiology Specialist
- 819 - 2 At USAF medical centers, USAF regional hospitals, and selected USAF hospitals
- 819 - 3 90350, Radiology Specialist
- 820 - 1 During the promotion cycle of a SSgt selectee or NLT the month of promotion to SSgt
- 820 - 2 1 year
- 820 - 3 Request your OJT supervisor to ask ECI for the extension before your year is up
- 820 - 4 1 year 6 months
- 820 - 5 Possession of AFSC 90350 and be either a SSgt selectee or promoted to SSgt
- 820 - 6 (1) Completion of CDC 90370, (2) at least 12 months OJT (6 months for cross-trainees with a prior 7 level), (3) completion of an approved management course, (4) meet the requirements of AFSC 90370 job description, and (5) have supervisor's recommendation
- 820 - 7 2 years.
- 820 - 8 During the 18th and 24th months of training
- 820 - 9 Staff sergeant Master sergeant
- 821 - 1 (1) At least 12 months time-in-grade as a MSgt, (2) Completion of SNCOA correspondence course, (3) Supervisor's recommendation
- 821 - 2 When a trainee is selected for promotion to senior master sergeant
- 822 - 1 a Be a graduate of course 3ABR90330, *Radiology Specialist* (Phase I), or its equivalent

- b Be a graduate of course SAZO90350-1 *Radiology Specialist* (Phase II)
  - c After graduation from Phase II work under the direct supervision of a board-qualified radiologist for 12 months
  - d Complete CDC 90370 during Phase III
  - e Pass the USAF quality control test for 903X0 personnel
- 822 - 2 The School of Health Care Sciences
- 823 - 1 AFR 127-12
- 823 - 2 To protect all Air Force personnel from work-related deaths, injuries, and occupational illness
- 823 - 3 All personnel working in medical facilities
- 823 - 4 To assist managers of USAF medical organizations in maintaining a safe environment
- 823 - 5 AFOSH Standard 127-8
- 823 - 6 Accurate beam size control and alignment
- 823 - 7 A considerable amount of work done in these areas is accomplished under low levels of lighting
- 823 - 8 Radiation, equipment, electricity, and chemicals

### CHAPTER 2

- 824 - 1 The differential response in cells to radiation—abnormal cells are more sensitive to radiation than normal cells
- 824 - 2 To damage or control the growth of abnormal cells and to spare the surrounding normal cells
- 825 - 1 (1) a b  
(2) b  
(3) b  
(4) a  
(5) b  
(6) b  
(7) b  
(8) a b
- 826 - 1 (1)c (2)b (3)b (4)d (5)a (6)c (7)c (8)a
- 827 - 1 (1) Sensitivity of the tumor tissue. Treatment of radiosensitive tumors is more successful than treatment of radioresistant tumors. (2) Stage of tumor development when treatment is initiated. Early treatment improves that chance for success.
- 827 - 2 Treatment aimed at curing the patient

- 827 - 3 When the patient remains alive for 5 years after treatment with no evidence of the disease
- 827 - 4 Symptomatic treatment of a patient whose condition cannot be cured
- 828 - 1 The X-ray unit produces therapeutic radiation only when current is applied; the teletherapy unit has a source of radioactive material which is giving out gamma rays continuously
- 828 - 2 Superficial, orthovoltage, and megavoltage
- 828 - 3 Because of the depth (or location) of tumors found within the body
- 828 - 4 Orthovoltage
- 828 - 5 Cobalt 60
- 829 - 1 A method of radiotherapy which uses sealed gamma or beta sources to irradiate tumors
- 829 - 2 Interstitial, intracavitary, and surface application
- 829 - 3 Interstitial
- 829 - 4 Surface application
- 830 - 1 (1) Practice the "Golden Rule." (2) prepare the patient for each procedure. (3) protect the patient's privacy, and (4) provide encouragement to the patient
- 830 - 2 Technical aspects of the therapy treatment, such as the part of the body to be treated and for how long, the position of the patient in relation to the equipment, safety mechanisms, and possible side effects or discomforts which may be experienced as a result of the treatment
- 830 - 3 Do not answer personal questions about the patient's condition, refer them to the therapist
- 831 - 1 Assisting the therapist and recordkeeping
- 831 - 2 Use exact positioning, immobilization devices, proper beam centering, and shield all areas of the body exposed to the X-ray field but not incident to the treatment
- 831 - 3 Terminate treatment immediately and reposition the patient
- 832 - 1 Immediately stop treatment and notify the therapist
- 832 - 2 Open the door to the treatment room, direct an ambulatory patient from the room or physically remove a nonambulatory patient from the room, close the door, turn off the main switch at the control panel, and notify the therapist and radiation protection officer immediately

576

STOP -

1. MATCH ANSWER SHEET TO THIS EXERCISE NUMBER.
2. USE NUMBER 2 PENCIL ONLY.

EXTENSION COURSE INSTITUTE  
VOLUME REVIEW EXERCISE

90370 05 23

GENERAL INFORMATION AND RADIATION THERAPY

Carefully read the following:

**DO's:**

1. Check the "course," "volume," and "form" numbers from the answer sheet address tab against the "VRE answer sheet identification number" in the righthand column of the shipping list. If numbers do not match, return the answer sheet and the shipping list to ECI immediately with a note of explanation.
2. Note that item numbers on answer sheet are sequential in each column.
3. Use a medium sharp #2 black lead pencil for marking answer sheet.
4. Write the correct answer in the margin at the left of the item. (When you review for the course examination, you can cover *your* answers with a strip of paper and then check your review answers against your original choices.) After you are sure of your answers, transfer them to the answer sheet. If you *have* to change an answer on the answer sheet, be sure that the erasure is complete. Use a clean eraser. But try to avoid any erasure on the answer sheet if at all possible.
5. Take action to return entire answer sheet to ECI.
6. Keep Volume Review Exercise booklet for review and reference.
7. If *mandatorily* enrolled student, process questions or comments through your unit trainer or OJT supervisor. If *voluntarily* enrolled student, send questions or comments to ECI on ECI Form 17.

**DON'Ts:**

1. Don't use answer sheets other than one furnished specifically for each review exercise.
2. Don't mark on the answer sheet except to fill in marking blocks. Double marks or excessive markings which overflow marking blocks will register as errors.
3. Don't fold, spindle, staple, tape, or mutilate the answer sheet.
4. Don't use ink or any marking other than a #2 black lead pencil.

**NOTE: NUMBERED LEARNING OBJECTIVE REFERENCES ARE USED ON THE VOLUME REVIEW EXERCISE.** In parenthesis after each item number on the VRE is the *Learning Objective Number* where the answer to that item can be located. When answering the items on the VRE, refer to the *Learning Objectives* indicated by these *Numbers*. The VRE results will be sent to you on a postcard which will list the *actual VRE items you missed*. Go to the VRE booklet and locate the *Learning Objective Numbers* for the items missed. Go to the text and carefully review the areas covered by these references. Review the entire VRE again before you take the closed-book Course Examination.

577

## MULTIPLE CHOICE

*Note to Student* Consider all choices carefully and select the best answer to each question

- 1 (800) What type of responsibility is exercised when you have Air Force equipment in your possession?
  - a Custodial
  - b Supervisory.
  - c Command.
  - d Personal
  
2. (800) Who is charged with the responsibility of training new radiology specialists in the principles of supply discipline?
  - a Radiologist in charge
  - b Medical Supply
  - c Supervisor
  - d Orderly Room personnel
  
- 3 (801) What procedure *must* take place if a property custodian is going TDY for 60 days?
  - a An authorized successor must be appointed.
  - b. The NCOIC conducts a property inventory
  - c. Excess supplies are turned-in to Medical Supply.
  - d. New equipment deliveries are stopped for 60 days
  
- 4 (801) What form does a property custodian use to request new equipment?
  - a. AF Form 198.
  - b AF Form 601.
  - c DD Form 1131.
  - d. DD Form 1348-6.
  
- 5 (801) Which of the following has the final approval authority for a request of new equipment which costs less than \$3,000?
  - a. Director of Base Medical Services.
  - b Medical Equipment Management Office.
  - c. Radiology Superintendent
  - d Chief Radiologist
  
6. (802) When must a Report of Survey of Air Force Property be prepared?
  - a When property damage causes personal injury.
  - b. When there is no evidence of gross negligence
  - c When lost property values are more than \$100.
  - d. When a person does not admit pecuniary liability
  
- 7 (802) A person admits pecuniary liability for loss of property valued at \$400. What form should be used to authorize payroll deductions?
  - a. DD Form 362.
  - b. DD Form 1131.
  - c DD Form 2090.
  - d. AF Form 198.
  
- 8 (803) What is the medical materiel category for a \$12,000 film processor with a life expectancy of 7.5 years?
  - a. Medical Supply Item.
  - b. Nonmedical Material.
  - c. Expense Medical Equipment Item.
  - d. Investment Medical Equipment Item
  
- 9 (803) What is the medical materiel category for 4 boxes of X-ray film costing \$125 for each box?
  - a. Durable Medical Supplies.
  - b. Consumable Medical Supplies.
  - c. Investment Medical Equipment
  - d. Expense Medical Equipment.
  
- 10 (804) Which of the following sections of the Federal Supply Catalog contains authorized substitute items?
  - a. Alphabetical Index.
  - b. Identification List.
  - c. Management Data List.
  - d. National Stock Number Index.

11. (804) Which section of the Federal Supply Catalog contains information that describes an item in detail?
- a. Alphabetical Index.
  - b. Management Data List.
  - c. Identification List
  - d. National Stock Number Index.
12. (804) Refer to text figure 1-7 Which digits of National Stock Number 6525-00-721-9814 refer to the National Item Identification Number?
- a. 65
  - b. 6525.
  - c. 00
  - d. 721-9814.
13. (804) The digits 65 of National Stock Number 6525-00-721-9814 refer to the
- a. Federal supply class.
  - b. Federal supply group.
  - c. Nato number.
  - d. National Item Identification Number.
14. (805) To correctly order medical supplies by telephone, you should
- a. also submit a DD Form 1348-6.
  - b. verify the order in writing.
  - c. use a unit shopping guide.
  - d. use Federal Supply Catalogs.
15. (805) When should you use a DD Form 1348-6?
- a. To order an expendable item that is not listed on your shopping guide.
  - b. To order equipment items that have a life expectancy of more than 5 years.
  - c. To turn-in equipment items to Medical Equipment Management Office.
  - d. To request an allowance or authorization change in your supply budget
16. (805) What should you do if an item that is "back ordered" does not appear on your issue list?
- a. Submit a DD Form 1348-6.
  - b. Submit a local purchase request.
  - c. Telephone MEMO and reorder the item.
  - d. Report the omission to Medical Materiel.
17. (806) What stock level should you establish if your department uses 3 boxes of 14- by 17-inch X-ray film a week?
- a. 3 boxes.
  - b. 6 boxes.
  - c. 9 boxes.
  - d. 12 boxes
18. (806) What *maximum* stock level are you authorized for recurring-demand expendable supplies?
- a. One week's normal usage.
  - b. Two week's normal usage.
  - c. Three week's normal usage.
  - d. Four week's normal usage
19. (807) AF Form 601, Equipment Action Request, is used to
- a. turn-in unserviceable equipment.
  - b. request local purchase supplies.
  - c. request equipment modifications or repairs.
  - d. submit equipment budget estimate.
20. (807) Who determines the condition of the items turned-in to Medical Supply?
- a. Radiologist.
  - b. Supply custodian.
  - c. NCOIC.
  - d. Materiel manager.

21. (807) What is the *minimum* amount for which credit will be allowed for items turned-in to supply?
- \$25.
  - \$50.
  - \$75.
  - \$100.
22. (808) What is the *first* action you should take when planning next year's supplies budget?
- Conduct an inventory of stock items on hand.
  - Compute any expected workload changes for the next fiscal year.
  - Analyze previous supply expenditures by using monthly issue lists.
  - Request due-out and back-ordered listings from Medical Supply.
23. (808) To whom should the projected supplies budget for a radiology department be submitted?
- Chief of Radiology.
  - Resource Management Officer.
  - Medical Equipment Review Board.
  - Commander of Base Supply.
24. (808) What must you do before attempting to budget for a replacement item of equipment?
- Deduct from the budget any credit values for turned-in equipment.
  - Determine if MER is able to service the item.
  - Make sure you can fully justify your need for the item.
  - Turn-in an unserviceable item that is similar to the requested item.
25. (809) When a patient comes to the X-ray department for a procedure, with what should you cross-reference the SF 519A to and why?
- Nominal index file; to determine if this is a follow-up exam.
  - Nominal index file; to determine if a film envelope is in file.
  - Daily log sheets; to determine the patient's eligibility.
  - Daily log sheets; to determine the patient's rank and status.
26. (807) Which one of the following statements best indicates the significance of the heading "Wet Reading" on a SF 519A?
- The patient is critically ill and near death.
  - Radiographs must be returned with the patient.
  - An immediate report of the radiologist's findings must be relayed to the requesting physician.
  - The patient has priority and must be taken into the exposure room before other patients.
27. (809) Where can you find the procedures for the routine distribution of a SF 519A?
- Base Publication Office.
  - AFR 12-50, *Disposition of Air Force Documentation*.
  - AFR 160-30, *Radiologic Technology*.
  - AFR 168-4, *Administration of Medical Facilities*.
28. (810) What is the earliest date that the 1984 nominal index file may be destroyed?
- 1 Jan 89.
  - 31 Dec 89.
  - 1 Jan 90.
  - 31 Dec 90.
29. (810) If a film envelope that was stored in 2-year old files is brought forward and placed into this year's film files, what should be done with the nominal index file card that relates to the film envelope?
- Destroy it at the end of the calendar year.
  - Update it into the current year's nominal index file.
  - Destroy it and type a new nominal index file card.
  - Retain it in the old file and type a new card for the current year's file.



- 30 (811) Which numbers of SSAN 520-40-1234 determine the color of the film file envelope for filing that patient's radiographs?
- a. 520.
  - b. 40.
  - c. 12
  - d. 34
- 31 (811) In the terminal digit filing system, which part of a patient's social security account number determines the general location of the film envelope?
- a. First part - tertiary number.
  - b. Second part - tertiary number.
  - c. Secondary number
  - d. Primary number
- 32 (811) When should you use the first part of the tertiary number to align a film folder in the terminal digit filing system?
- a. Only after the primary numbers are the same.
  - b. Only after the primary numbers and the secondary numbers are the same.
  - c. Only after the second part of the tertiary numbers are the same
  - d. Only after the secondary numbers and the second part of the tertiary numbers are the same.
- 33 (812) Which of the following publications provides guidelines pertinent to the disposal of radiology records?
- a. Hospital Operating Instructions (HOI).
  - b. AFR 168-4, *Administration of Medical Facilities*.
  - c. AFR 12-50, *Disposition of Air Force Documentation*
  - d. AFR 168-695, *Medical Administration Management System Base (PA)*.
34. (812) What should you do with radiographs that cannot be identified with the individuals to whom they pertain?
- a. Destroy when encountered.
  - b. Hold in the file room for 30 days.
  - c. Forward monthly to the National Personnel Records Center
  - d. Return films to Medical Material for turn-in credit
- 35 (813) Which of the following information must you submit to the Resource Management Office for inclusion on AF Form 235?
- a. Total number of x-ray film exposed for in-patients and out-patients.
  - b. The number of fluoroscopic examinations accomplished on in-patients and out-patients.
  - c. The number of radiographs interpreted by your radiologist but accomplished at another facility
  - d. All of the above.
36. (813) How often should you submit information for inclusion of AF Form 235?
- a. Weekly.
  - b. Monthly.
  - c. Quarterly
  - d. Annually.
37. (813) To which office should you submit a monthly report of workload equivalent point values for procedures accomplished?
- a. Resource Management Office
  - b. Air Force Surgeon General's Office.
  - c. Director of Base Medical Services.
  - d. Medical Services Orderly Room.
38. (814) Who sets the quality guidelines that determine whether a radiograph is acceptable or unacceptable?
- a. Quality assurance technician.
  - b. Department NCOIC.
  - c. Radiology specialist
  - d. Radiologist.

39. (814) What actions provide the organizational framework for a quality assurance (QA) program and ensure that corrective measures are taken in response to equipment tests?
- a. Quality administration procedures.
  - b. Equipment maintenance procedures
  - c. Quality assurance techniques
  - d. Quality assurance standards
40. (815) The impact of a successful quality assurance program is *first* seen as a (an)
- a. reduction in operating costs
  - b. reduction in the retake rate.
  - c. reduction of radiation exposure.
  - d. improvement in departmental morale.
41. (815) What is the Air Force policy concerning quality assurance programs?
- a. The chief radiologist determines whether a QA program is necessary.
  - b. All medical facilities must develop and maintain a QA program.
  - c. QA programs are optional for facilities that have a film repeat rate of less than 15 percent
  - d. All medical facilities will monitor all five key components of an X-ray system.
42. (816) Concerning a QA program, who has primary responsibility for quality administration?
- a. Medical facility commander.
  - b. NCOIC of Radiology.
  - c. Chief radiologist.
  - d. Individual room technicians.
43. (816) All X-ray room technicians always have a QA responsibility to
- a. ensure that proper documentation is maintained.
  - b. perform quality control techniques on key components of an X-ray system.
  - c. perform corrective maintenance when problems are detected.
  - d. bring possible problems to the attention of medical equipment repair or the NCOIC.
44. (817) Assume that you have performed a quality test on a radiographic unit, found a problem, and requested corrective actions on the unit. How does this temporarily affect the QA program for that unit?
- a. Decreases monitoring frequency because the unit was just repaired.
  - b. Decreases preventive maintenance because MER assumes responsibility for repaired equipment
  - c. Increases monitoring frequency to ensure that corrective actions taken were effective.
  - d. Increases preventive maintenance to prevent a repeat of equipment failure.
45. (817) When performing QA checks on X-ray system components, an optical light meter is used to monitor
- a. darkrooms.
  - b. view boxes.
  - c. film processing.
  - d. cassettes and grids.
46. (818) What must an airman do to bypass Course 3ABR90330?
- a. Receive a favorable score on the Apprentice Knowledge Test.
  - b. Receive favorable scores in all four areas of the Airman Qualification Examination
  - c. Be a registered radiologic technologist.
  - d. Be awarded AFSC 90350 through OJT.
47. (819) When is an airman considered to be a skilled radiology specialist?
- a. Immediately after completing Course 3ABR90330.
  - b. Immediately after completing Course 5AZ090350-1.
  - c. Immediately after completing Phase III Training.
  - d. Immediately after becoming a registered radiologic technologist.

48. (819) What *must* a bypassed specialist do after being awarded AFSC 90330 to become a radiology specialist?
- Complete Course 3ABR90330
  - Complete Course 5AZ090350-1.
  - Receive a favorable score on the USAF Quality Control Test for 903X0 personnel
  - Receive a favorable score on the Airman Qualifying Examination
49. (820) Unless a person is a victim of unusual circumstances, what is the maximum time allowed for upgrade training to the 7-level?
- 12 months
  - 18 months
  - 24 months
  - 36 months
50. (820) Normally, what is the highest rank permitted with AFSC 90370?
- SSgt
  - TSgt
  - MSgt
  - CMSgt
51. (821) If a master sergeant has *not* completed all routine upgrade training requirements for AFSC 90399, how can the person be awarded AFSC 90399?
- Complete 36 months time-in-grade.
  - Be selected for senior master sergeant.
  - Have a recommendation from the Chief of Radiology
  - Complete 36 months OJT.
52. (821) What are the training requirements for AFSC 90399?
- 12 months time-in-grade as a MSgt, completion of USAF Senior NCO Academy, and supervisor's recommendation.
  - 12 months time-in-grade as a MSgt, completion of Command NCO Academy, and supervisor's recommendation.
  - 24 months time-in-grade as a MSgt, completion of USAF Senior NCO Academy, and the Hospital Commander's recommendation.
  - 24 months time-in-grade as a MSgt, completion on Command NCO Academy, and the Hospital Commander's recommendation.
53. (822) What is the *minimum* requirement needed to qualify for certification testing by the American Registry of Radiologic Technologists?
- Completion of the Air Force's Phase I and Phase II courses.
  - Completion of a 24-month American Medical Association accredited training program in Radiologic Technology.
  - Working in a medical center or regional hospital, under direct supervision of a board-qualified radiologist for 2 years.
  - Completion of this CDC and OJT or possession of AFSC 90370, and a favorable score on the USAF Quality Control Test.
54. (822) Which organization conducts the testing for *certification* of X-ray technicians?
- American Medical Association (AMA).
  - American Society of Radiologic Technologists (ASRT).
  - American Registry of Radiologic Technologists (ARRT).
  - American College of Radiology (ACR).

55. (823) What is the purpose of AFOSH Standard 127-8?
- To assist in maintaining safe working conditions.
  - To ensure structural upkeep of the facility
  - To ensure mechanical upkeep of equipment items
  - To conform with civilian hospital standards.
56. (823) What is the primary occupational hazard of AFSC 903X0?
- Chemical hazards.
  - Equipment hazards.
  - Electrical hazards
  - Radiation hazards
57. (824) Why is radiation used to treat tumors?
- It produces minimum strain on the patient.
  - It affects only abnormal cells.
  - It produces biological changes in tissues
  - It is easier and cheaper to use than surgical procedures
58. (824) Why are malignant tumors more likely to show a greater response to irradiation than surrounding normal tissues?
- Normal tissue cells do not have adult cells.
  - Normal tissue cells do not have a mitosis stage.
  - Malignant tumors usually have less dividing cells.
  - Malignant tumors usually have more dividing cells
59. (825) Select the *true* statements concerning tumors?
- Benign tumors metastasize into secondary tumors.
  - Benign tumors metastasize through the circulatory system.
  - Malignant tumors form primary and metastatic tumors.
  - Malignant tumors are enclosed in a capsule.
60. (825) Which statement concerning benign tumors is *not* true?
- They can become dangerous.
  - They usually are enclosed in capsules.
  - They usually are treated with radiation.
  - They exist only in the immediate site of growth and can usually be removed.
61. (826) Which one of the following is a benign epithelial tumor?
- Adenoma.
  - Fibrosarcoma.
  - Osteoma.
  - Squamous cell carcinoma
62. (826) Which one of the following is a malignant epithelial tumor?
- Papilloma.
  - Chondroma.
  - Fibrosarcoma.
  - Basal cell carcinoma.
63. (826) What are sarcomas?
- Benign epithelial tumors.
  - Benign connective tissue tumors.
  - Malignant epithelial tumors.
  - Malignant connective tissue tumors

64. (827) What does "radical treatment of a tumor" mean?
- The tumor is radioresistant.
  - An attempt is made to cure the patient
  - The patient's cure is considered improbable.
  - The patient will experience 10 years of no further trouble
65. (827) Which one of the following statements concerning the treatment of tumors by radiation therapy is correct?
- Malignant tumors are best treated by radiation therapy
  - Palliative treatment produces a cure for the patient.
  - The more radioresistant the tumor, the greater the chance for successful treatment.
  - The more radiosensitive the tumor, the greater the chance for successful treatment
66. (828) What energy range is considered orthovoltage therapy?
- 0 to 140 KeV
  - 140 to 300 KeV.
  - 1 to 3 MeV
  - 4 to 10 MeV.
67. (828) Which type of radiotherapy is used to treat lesions of the dermis?
- Superficial.
  - Orthovoltage.
  - Megavoltage
  - Betatron dischargers
68. (828) What determines which class of radiotherapy is to be used for tumor treatment?
- The size of the tumor.
  - The energy level needed to treat a disease.
  - Whether or not the tumor is benign or malignant.
  - The type of radioactive nuclides that are available.
69. (829) What is brachytherapy?
- A method of radiation therapy which uses low-voltage X-ray units to treat surface tumors.
  - A method of radiation therapy which uses high-voltage external-beam units to irradiate deep-seated tumors.
  - A method of radiation therapy which uses linear accelerators to irradiate tumors.
  - A method of radiation therapy which uses sealed gamma or beta radiation sources to irradiate tumors.
70. (829) Which method of brachytherapy positions a radiation source directly within the tissues which are to be treated?
- Interstitial.
  - Intracavitary.
  - Surface applicators.
  - Linear accelerators
71. (830) What should you do when therapy patients ask you personal questions about their condition?
- Tactfully answer all questions honestly.
  - Tell them you don't know anything about their condition
  - Refer them to the therapist.
  - Tell them there is nothing for them to worry about.
72. (830) Which one of the following actions should you avoid when helping a therapy patient who is apprehensive about radiotherapy?
- Ask personal questions to reduce patient's apprehension.
  - Provide a dressing to conceal exposed ulcerations.
  - Arrange appointments for follow-up examinations.
  - Explain symptoms the patient may experience as a result of treatment.

73. (831) What should you do if any unusual variation occurs to the control console while monitoring a radiotherapy treatment?
- Notify the therapist immediately
  - Notify Medical Equipment Repair immediately
  - Reset the controls and begin the procedure over.
  - Increase or decrease the settings of the autotransformer while the X-ray tube is in operation
74. (831) If a patient moves during a radiotherapy treatment you should
- continue the treatment and notify the therapist.
  - continue the treatment and increase the time the patient is exposed to radiation
  - stop treatment immediately and reposition the patient
  - stop treatment immediately and reschedule the appointment
75. (832) What should be your *primary* concern if the beam control mechanism fails to stop the exposure during a radiotherapy treatment?
- To remove the patient from the exposure room.
  - To prevent overheating or damage to the X-ray tube head.
  - To prevent electrical damage to the control console.
  - To include the patient's additional radiation exposure on the treatment record
76. (832) Where should emergency procedures that indicate what you should do if a beam control mechanism fails to stop an exposure be posted?
- At the control panel.
  - In the patient treatment exposure room.
  - In the patient waiting room so they can read them
  - Filed in the NCOIC's office

### END OF EXERCISE

99 01

### ATC/ECI SURVEY

The remaining questions are not part of the Volume Review Exercise (VRE) *You must complete and return the answer sheet marked "Student Survey" to receive your end of course examination (CE).* This survey will not affect your score. We need your opinions of how well the CDC supports skill progression for the entire AFSC and how well you view course content and/or service. Your name and SSAN will be disassociated from your responses to the survey prior to tabulation. (See Privacy Act statement).

Using a number 2 pencil, indicate what you consider to be the appropriate response to each survey question on your answer sheet labeled "Student Survey." Do not respond to questions that do not apply to you. Your cooperation will help both ATC and ECI improve the quality of our service and courses and you'll have an active part in the management of Air Force Career Development Education and Training.

Please keep your student survey answer sheet 99 01. All VREs plus the answer sheet for 99 01 must be submitted before you will receive your course examination.

10 586

90370 05 23

## PRIVACY ACT STATEMENT

- A. Authority. 5 U.S.C. 301, *Departmental Regulations*
- B. Principal Purpose: To obtain student input concerning ECI course materials, examinations, administration, and student study methods and support educational research.
- C. Routine Uses. Group data will be used for routine course evaluation and improvement

1 Which of the following best describes your current Department of Defense status

- a USAF active duty.
- b Civilian.
- c USAF Reserve/ANG
- d Other.

2 Mark the item that best describes the counseling you received prior to enrolling into this course

- a I was counseled by Base Education Services Personnel
- b My OJT Trainer/Manager counseled me
- c My supervisor and/or friend told me all I needed to know before I enrolled.
- d I received no counseling.

3 If you contacted ECI for any reason during your enrollment, how would you describe the service provided?

- a Excellent
- b Satisfactory
- c Unsatisfactory
- d Did not contact ECI.

4. I enrolled in this course.

- a. As a mandatory enrollment for upgrade purposes
- b. To obtain WAPS study material.
- c. To increase my chances of cross-training.
- d. For my own personal benefit

5. (USAFE only) How long did it take to receive your course materials *after* you received notification of enrollment?

- a. 1-9 days.
- b. 10-19 days.
- c. 20-29 days.
- d. 30 or more days

6 (PACAF only) How long did it take to receive your course materials *after* you received notification of enrollment?

- a. 1-9 days.
- b. 10-19 days.
- c. 20-29 days.
- d. 30 or more days

7. (ALL EXCEPT USAFE AND PACAF) How long did it take to receive your course materials *after* you received notification of enrollment?

- a. 1-9 days
- b. 10-19 days.
- c. 20-29 days.
- d. 30 or more days

8 What was the condition of the course materials you received from ECI?

- a. A complete set of well-packaged materials.
- b. An incomplete set of well-packaged materials.
- c. A complete set of poorly-packaged materials.
- d. An incomplete set of poorly-packaged materials.

9. The amount of time I spent posting changes to this CDC was.
- Less than 30 minutes.
  - Between 30 minutes and 1 hour
  - More than 1 hour.
  - None, as there were no changes to post.
10. The overall reading level of the material in this course is:
- Much too high
  - Slightly high.
  - About right
  - Too low.
11. If you had difficulty understanding any of the course materials, did you experience difficulty with.
- The technical information relevant to your AFSC.
  - The non-technical information related to your AFSC (e.g. security)
  - All of the materials
  - None of the material.
12. The illustrations in the course materials.
- Were of high quality and aided learning.
  - Were of poor quality and were still useful to some degree
  - Were of no value.
  - There were no illustrations.
13. The format of the text (objective followed by narrative and exercises) helped me study
- Strongly agree.
  - Agree.
  - Disagree
  - Strongly disagree.
14. The volume review exercises were helpful in reviewing course information
- Strongly agree
  - Agree.
  - Disagree
  - Strongly disagree
15. The learning objective exercises in my CDC helped me learn the material presented by the texts
- Strongly agree.
  - Agree.
  - Disagree
  - Strongly disagree.
16. How much of the information in this course is covered adequately by other sources (e.g. PME)?
- Less than 10%
  - 10-19%.
  - 20-30%.
  - I do not know
17. The CDC does *not* refer to people in terms relating gender, race, or ethnic background
- Strongly agree.
  - Agree.
  - Disagree.
  - Strongly disagree
18. (MANDATORY ENROLLMENTS ONLY) Which rating best describes the usefulness of the information in this course in your upgrade program?
- Excellent.
  - Satisfactory.
  - Marginal.
  - Unsatisfactory.
19. The technical information in this course is.
- 90-100% current.
  - 80-89% current.
  - 70-79% current
  - Less than 70% current



- 20 The CDC was too long and complex
- |                    |                       |
|--------------------|-----------------------|
| a. Strongly agree. | c. Disagree.          |
| b. Agree.          | d. Strongly disagree. |
21. The CDC material reviewed but did not excessively repeat what I learned in technical school or through a previous CDC.
- |                    |                      |
|--------------------|----------------------|
| a. Strongly agree. | c. Disagree          |
| b. Agree           | d. Strongly disagree |
- 22 The material presented by the CDC helped to prepare me for work in any job within my Air Force Specialty.
- |                    |                      |
|--------------------|----------------------|
| a. Strongly agree. | c. Disagree.         |
| b. Agree.          | d. Strongly disagree |
23. The CDC material increased my career knowledge
- |                    |                      |
|--------------------|----------------------|
| a. Strongly agree. | c. Disagree          |
| b. Agree.          | d. Strongly disagree |
- 24 The CDC material gave me a satisfactory knowledge of the technical areas of my AFSC
- |                    |                      |
|--------------------|----------------------|
| a. Strongly agree. | c. Disagree.         |
| b. Agree.          | d. Strongly disagree |
- 25 The technical material in the course was written such that I could understand it.
- |                    |                       |
|--------------------|-----------------------|
| a. Strongly agree. | c. Disagree.          |
| b. Agree.          | d. Strongly disagree. |
- 26 Procedures described in the CDC were general and did not require actual work experience to understand.
- |                   |                      |
|-------------------|----------------------|
| a. Strongly agree | c. Disagree.         |
| b. Agree.         | d. Strongly disagree |

**NOTE:** If you know this CDC contains outdated information or does not provide the knowledge that the current specialty training standard (STS) requires you to have for upgrade training, contact your unit OJT advisor and fill out an AF Form 1284, Training Quality Report.

## STUDENT REQUEST FOR ASSISTANCE

### PRIVACY ACT STATEMENT

**AUTHORITY** 10 USC 8012 and EO 9397 **PRINCIPAL PURPOSES** To provide student assistance as requested by individual students **ROUTINE USES** This form is shipped with ECI course package It is utilized by the student, as needed, to place an inquiry with ECI **DISCLOSURE** Voluntary The information requested on this form is needed for expeditious handling of the student's need Failure to provide all information would result in slower action or inability to provide assistance to the student

### SECTION I CORRECTED OR LATEST ENROLLMENT DATA *(Mail to ECI Gunter AFS 41 36118)*

1 THIS REQUEST CONCERNS COURSE (1-6)	2 TODAY'S DATE	3 ENROLLMENT DATE	4 AUTOVON NUMBER
5 SOCIAL SECURITY NUMBER (7-15)	6 GRADE/RANK	7 NAME (First initial second initial last name)	
		(17)	(18) (19-32)
8 ADDRESS <i>(OJT Enrollees -- Address of unit training office with zip code All others current mailing address with zip code)</i>		[33-53]	[54-75]
9 NAME OF BASE OR INSTALLATION IF NOT SHOWN ABOVE		10 TEST CONTROL OFFICE ZIP CODE/SHRED (33-39)	

### SECTION II. REQUEST FOR MATERIALS, RECORDS, OR SERVICE

*(Place an X through number in box to left of service requested)*

### FOR ECI USE ONLY

1 Request address change as indicated in Section I.	16	
2 Request Test Control Office change as indicated in Section I.	G	33
3 Request name change/correction (Provide Old or Incorrect data)	K	Vol 33-35 GR 36-38
4 Request Grade/Rank change/correction.	M	33-34 35-40
5 Correct SSAN. (List incorrect SSAN here) (Correct SSAN should be shown in Section I)	N	33-38
6 Extend course completion date. (Justify in REMARKS)	P	Vol 33-35 TC 36-37
7 Request enrollment cancellation.	Q	33-34 Volume 35-37
8 Send VRE answer sheet for Vol(s): 1 2 3 4 5 6 7 8 9 Originals were: <input type="checkbox"/> Not received <input type="checkbox"/> Lost <input type="checkbox"/> Misused	38	39-42
9 Send course materials. (Specify in REMARKS) <input type="checkbox"/> Not received <input type="checkbox"/> Lost <input type="checkbox"/> Damaged	1	39-42
10 Course exam not yet received Final VRE submitted for grading on _____ (date).	2	39-42
11 Results for VRE Vol(s) 1 2 3 4 5 6 7 8 9 not yet received. Answer sheet(s) submitted _____ (date)	3	39-42
12 Results for CE not yet received. Answer sheet submitted to ECI on _____ (date)	16	
13 Previous inquiry ( <input type="checkbox"/> ECI Fm 17, <input type="checkbox"/> Ltr, <input type="checkbox"/> Msg) sent to ECI on _____ (date).		
14 Give instructional assistance as requested on reverse.		
15 Other (Explain fully in REMARKS)		

REMARKS *(Continue on Reverse)*

OJT STUDENTS must have their OJT Administrator certify this request	I certify that the information on this form is accurate and that this request cannot be answered at this station. <i>(Signature)</i>
ALL OTHER STUDENTS may certify their own requests.	

**SECTION III REQUEST FOR INSTRUCTOR ASSISTANCE**

**NOTE:** Questions or comments relating to the accuracy or currency of subject matter should be forwarded directly to preparing agency. For an immediate response to these questions, call or write the course author directly, using the AUTOVON number or address in the preface of each volume. All other inquiries concerning the course should be forwarded to ECI.

**VRE Item Questioned**

Course No \_\_\_\_\_

Volume No \_\_\_\_\_

VRE Form No \_\_\_\_\_

VRE Item No \_\_\_\_\_

Answer You Chose \_\_\_\_\_  
(Letter)

Has VRE Answer Sheet  
been submitted for grading?

Yes  No

**REFERENCE**

(Textual reference for the  
answer I chose can be  
found as shown below)

In Volume No \_\_\_\_\_

On Page No \_\_\_\_\_

In  left  right column

Lines \_\_\_\_\_ Through \_\_\_\_\_

**MY QUESTION IS**

**REMARKS**

ADDITIONAL FORMS 17 available from trainers, OJT and  
Education Offices, and ECI. Course workbooks have a Form 17  
printed on the last page.