

DOCUMENT RESUME

ED 213 965

CE 031 771

TITLE

The Musculoskeletal System [and] Instructor's Guide:
The Musculoskeletal System. Health Occupations
Education Module: Instructional Materials in Anatomy
and Physiology for Pennsylvania Health Occupations
Programs.

INSTITUTION
SPONS AGENCY

National Evaluation Systems, Inc., Amherst, Mass.
Pennsylvania State Dept. of Education, Harrisburg.
Bureau of Vocational and Technical Education.

PUB DATE

Jun 79

NOTE

64p.; For related documents see listing in note of CE
031 758.

EDRS PRICE
DESCRIPTORS

MF01/PC03 Plus Postage.

*Allied Health Occupations Education; *Anatomy;
Behavioral Objectives; *Individualized Instruction;
*Learning Activities; Learning Modules; Medical
Vocabulary; *Physiology; Postsecondary Education;
Pretests Posttests; Programed Instructional
Materials; Secondary Education; Self Evaluation
(Individuals); Teaching Methods

IDENTIFIERS

*Muscular System; Pennsylvania; *Skeletal Systems

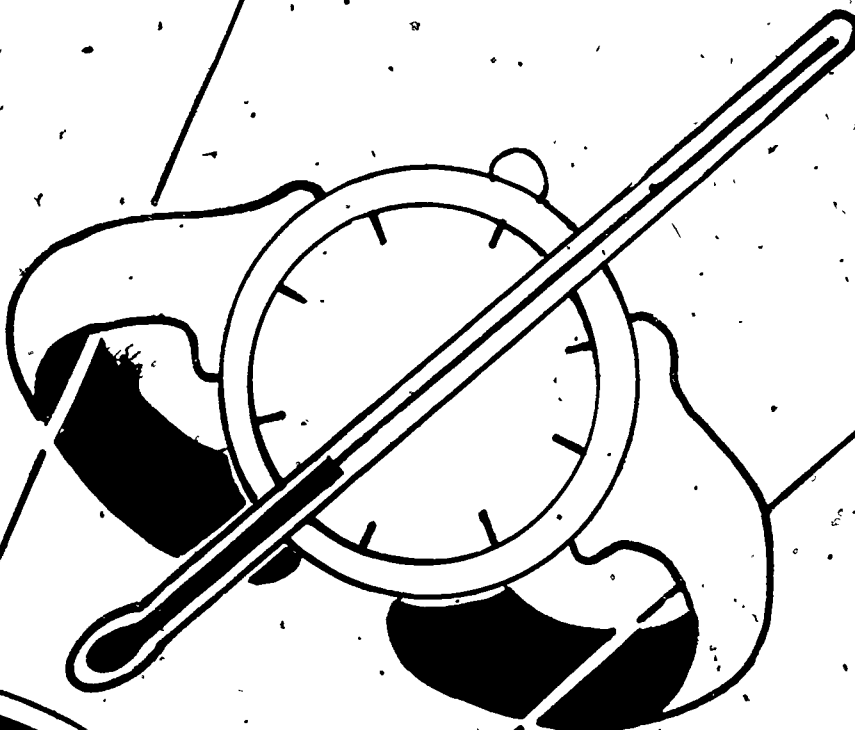
ABSTRACT

This module on the musculoskeletal system is one of 17 modules designed for individualized instruction in health occupations education programs at both the secondary and postsecondary levels. It is part of an eight-unit miniseries on anatomy and physiology within the series of 17 modules. Following a preface which explains to the student how to use the module, the unit consists of a pretest with answers, seven sections (information sheets) with their goals (e.g., classify different types of bone), optional activities (e.g., on diagrams of the skeleton, draw the major muscles of the body), and posttests, and a glossary of terms. Topics covered in the unit are introduction to the skeletal system, axial skeleton, appendicular skeleton, introduction to the muscular system, major muscles of the body, supporting structures of the musculoskeletal system, and movements. An accompanying instructor's guide contains suggestions for using the module and answers to the posttest. (KC)

* Reproductions supplied by EDRS are the best that can be made *
* from the original document. *

ED213965

HEALTH OCCUPATIONS EDUCATION MODULE



U.S. DEPARTMENT OF EDUCATION
NATIONAL INSTITUTE OF EDUCATION

PERMISSION TO REPRODUCE THIS
MATERIAL HAS BEEN GRANTED BY

B. Ford

TO THE EDUCATIONAL RESOURCES
INFORMATION CENTER (ERIC)

THE MUSCULOSKELETAL SYSTEM

Instructional Materials in Anatomy and Physiology
for Pennsylvania Health Occupations Programs

THE MUSCULOSKELETAL SYSTEM

Prepared for:

Research Coordinating Unit for Vocational Education
Pennsylvania Department of Education
Box 911
Harrisburg, Pennsylvania 17126

Prepared by:

National Evaluation Systems, Inc.
30 Gatehouse Road
Amherst, Massachusetts 01002

June, 1979

PREFACE

An understanding of basic human anatomy and physiology is essential to any person preparing to enter a health occupation. This instructional unit is designed to introduce you to the structures and functions of the human musculoskeletal system--and the interrelationships of the two--and to familiarize you with some of the terms and concepts necessary for an understanding of the musculoskeletal system.

This unit consists of a pretest; seven modules with their optional activities and post-tests; and a glossary of terms.

Begin this modular unit by taking the brief pretest at the front of the booklet. The pretest is for your use only, to give you an idea of what is included in this unit, and to give you an indication of the areas within the unit to which you should pay special attention (perhaps by working on the optional activities). When you have completed the pretest, turn to the answers in the back (page 52) to check your own score. You will not be graded on the pretest.

Next, read through each of the modules (Introduction to the Skeletal System, Axial Skeleton, Appendicular Skeleton, Introduction to the Muscular System, Major Muscles of the Body, Supporting Structures of the Musculoskeletal System, and Movements) and investigate any of the optional activities that may be helpful or interesting to you. The optional activities will help you learn more about some of the material presented.

At the end of this unit (page 49) is a glossary which provides you with brief definitions of many of the terms used in the modules.

Upon completion of each module, you should be able to demonstrate an understanding of the material presented, by your performance on the post-test. When you have finished a module and feel that you understand the information in that module, take the post-test that follows it. Write down your answers on ONE piece of paper and pass it in to your instructor, who will give you your grade.

PRETEST

1. Which of the following is a part of the skeletal system?

- A. blood
- B. nerves
- C. muscles
- D. bones

2. One of the major functions of the skeletal system is to:

- A. transport oxygen.
- B. protect body organs.
- C. process food.
- D. regulate body temperature.

3. Another name for the breastbone is the

_____.

4. The forearm contains which of the following pairs of bones?

- A. clavicle and sternum
- B. tibia and fibula
- C. radius and ulna
- D. ilium and ischium

5. All of the movements of the body are produced by what type of tissue?

6. Which of the following is another name for skeletal muscle?

- A. smooth
- B. cardiac
- C. involuntary
- D. striated

7. On the arm, the antagonist to the biceps is the:

- A. rectus femoris.
- B. masseter.
- C. pectoralis.
- D. triceps.

8. Muscles are attached to bones by what type of structure?

9. A joint which allows no motion is also called a:

- A. synovial joint.
- B. hinge joint.
- C. gliding joint.
- D. fibrous joint.

10. What is the opposite motion of abduction?

INTRODUCTION TO THE SKELETAL SYSTEM

Goals

Upon completion of this module, you should be able to:

1. Identify the major components and functions of the skeletal system.
2. Classify different types of bone.

THE FUNCTION OF THE SKELETON

The adult human skeleton is composed of 206 bones, each serving its own distinct function. As a whole, the skeleton is like the framework of a building; it supports and gives shape to the structures around and within it. Individual parts of the skeleton provide the support that maintains the functional shape of certain organs. For instance, the thin tissue of the lungs would collapse on itself and lose the shape necessary for adequate respiration were it not for the attachment of the lungs to the bony ribcage that holds them open.

The structure of bones and of the skeletal system helps the skeleton to provide protection for many of the body's organs. For example, the hard skull houses the vulnerable brain; the vertebral column protects the spinal cord; and the ribcage shields the heart and lungs from injury.

Body movements also depend on the framework of bone. Skeletal muscles use the bones as supports and levers to produce movement. Its rigid nature, and the arrangement of bones, makes the skeletal system's function as a structural support rather obvious. Less obvious are its other functions, such as the production of erythrocytes (red blood cells) and the storage of minerals. Most bones have a living core called bone marrow, which is classified as either "red" or "yellow." Red bone marrow is found in the thoracic (ribs and sternum) and pelvic bones, and in the ends of long bones; it is the site of red blood cell formation. Yellow bone marrow, found in the shafts of long bones and elsewhere, can in emergencies convert to red blood cell producing marrow. Bones also provide the body with minerals. Substances such as magnesium, calcium, and phosphorus, which are part of the bone material, are stored until the body needs them.

CLASSIFICATION OF BONES

The many bones of the skeleton range in size and shape from the tiny bones of the middle ear to the large heavy bones of the leg. Different kinds of bones are classified by their shapes as long, short, irregular, or flat. Long bones are longer than they are wide; examples of long bones include the femur of the thigh, the bones of the arm, and even the phalanges of the fingers. The long part of the bone is the shaft or diaphysis; the ends of the shaft, called epiphyses, are broader than the shaft. Figure 1 shows the structure of long bones.

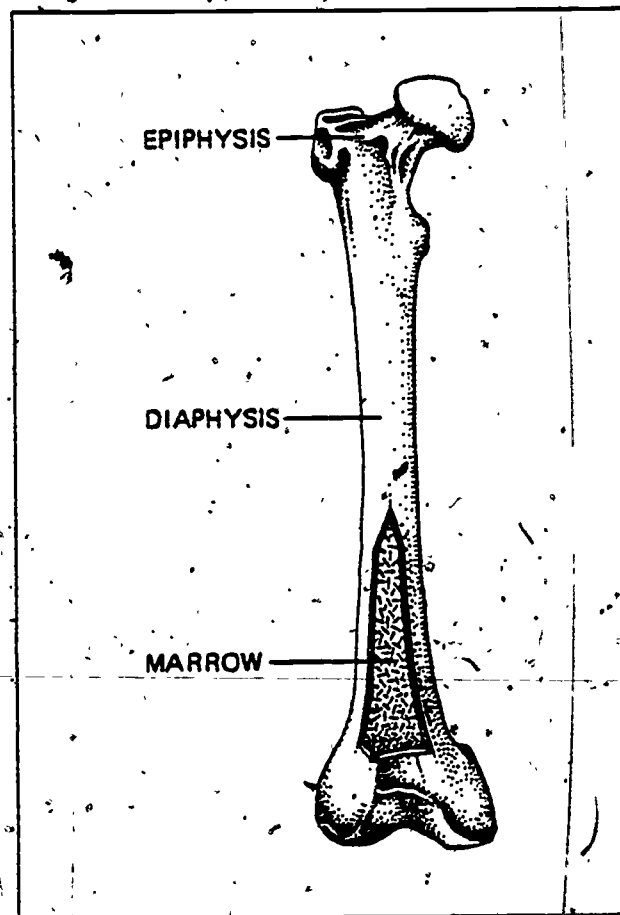


Figure 1. The Structure of Long Bone

Short bones are uniformly as broad as they are wide; an example of a short bone is one of the carpals of the wrist. Irregular bones, such as the vertebrae, have odd or complex shapes. Flat bones, such as those found in the skull, are broad plates of bone.

ARRANGEMENT OF THE SKELETON

The human skeleton is a configuration or arrangement of these different types of bones, held together by ligaments, tendons, muscles, and cartilage; and joined together in junctions called articulations, or joints.

Two different systems make up the entire skeleton: the axial skeleton and the appendicular skeleton. The axial skeleton consists of the skull, vertebral column, and ribcage; and the appendicular skeleton is composed of the bones of the appendages, or extremities (arms and legs).

Figure 2 shows a frontal view of the human skeleton.

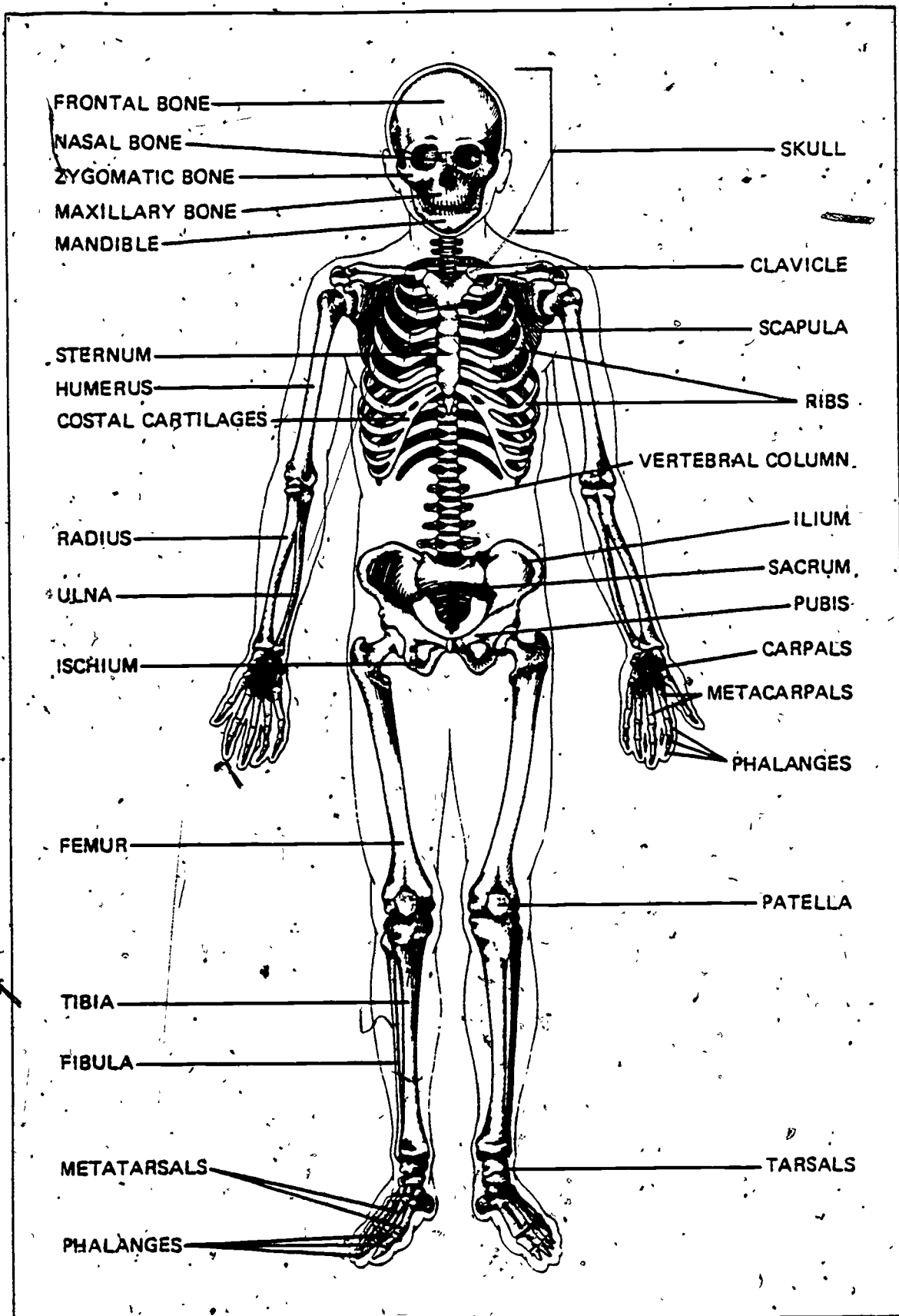


Figure 2. The Human Skeleton

INTRODUCTION TO THE SKELETAL SYSTEM

Post-Test

1. How many bones are there in the normal adult human body?

2. What are the two major divisions of the skeletal system?

3. Joints between bones are also called:

- A. tendons.
- B. cartilage.
- C. articulations.
- D. epiphyses.

4. Red blood cells are formed in the:

- A. bone marrow.
- B. heart.
- C. brain.
- D. cartilage.

5. One function of bones is to:

- A. produce mucus.
- B. transmit impulses.
- C. store minerals.
- D. initiate movement.

6. All of the organs and structures of the body are supported by the:

- A. nerves.
- B. skeleton.
- C. appendages.
- D. ligaments.

7. Which of the following is classified as a short bone?

- A. carpal
- B. phalanx
- C. sternum
- D. humerus

8. The vertebrae are classified as which type of bone?

- A. long
- B. flat
- C. short
- D. irregular

9. The femur is classified as what type of bone?

10. The diaphysis is what part of a long bone?

- A. the end
- B. a projection
- C. the shaft
- D. a hole

AXIAL SKELETON

Goals

Upon completion of this module, you should be able to:

1. Identify the components of the axial skeleton.
2. Identify and describe the structure and functions of the axial skeleton.

The axial skeleton is the framework of the trunk of the body: the head, neck, chest, and upper abdomen. This part of the skeletal system serves mainly a protective function, since it encloses most of the vital organs. It also houses the organs of sight, smell, taste, and hearing, and is responsible for the flexibility of movement that allows these organs the fullest range of exposure to the environment.

THE SKULL

At the top of the axial skeleton is the skull, which is made up of the bones of the head. With one exception, the 29 bones of the skull articulate in (or are connected by) immovable joints. The joint of the lower jaw is the only one that moves; it allows for the movements necessary for speaking and chewing. In the skull, the immovable joints provide strength and rigidity for the protection of the fragile sensory organs (eyes, ears, mouth, and nose), as well as for the brain.

The skull is divided into two areas. In the front portion are 14 facial bones which lie beneath the flesh of the face. These bones form the inner structures of the mouth and nose. They also define the shape of the face by forming the cheekbones, the arch of the nose, the chin, and the jaw. The forehead is formed by part of the larger portion of the skull, the cranium. The eight bones of the cranium, or cranial bones, form the top, sides, and back of the head.

Two unique sets of bones are located within the skull, although they are not classified as either cranial or facial bones. First are the ossicles, three tiny bones located in each middle ear cavity. They contribute to hearing by transmitting and amplifying vibrations, and are named according to their shapes: malleus (hammer), incus (anvil), and stapes (stirrup). Second is the hyoid bone, located at the base of the tongue. This is the only bone in the body which is not connected to any other bone. Small and shaped like a "U", the hyoid provides an attachment for various muscles of the tongue and pharynx.

VERTEBRAL COLUMN

At the base of the skull is the vertebral column (backbone or spine) which, in an adult, consists of 24 closely-joined bones called vertebrae. These vertebrae are divided into three main divisions: the first seven are the cervical (neck) vertebrae; the thoracic (chest) are the next 12; and the lumbar (back) are the next five. The vertebral column ends with the sacrum, a single bone consisting of five fused vertebrae, and the coccyx ("tailbone"), which is fused from three to five bones.

Cushions of cartilage, called discs, sit between the vertebrae and contribute to the flexibility of the vertebral column. This flexibility provides the sensory organs with maximum exposure to the environment. For example, the head can rotate, tip, incline, and swivel to give the eyes the widest possible view of the surroundings.

The stacking of the vertebrae and the slight natural curve of the spinal column contribute to the strength of the structure, which enables it to support the skull, thorax, and abdomen. Each individual vertebra helps to protect the soft spinal cord, which runs through holes in the centers of the vertebrae; and the vertebral column as a whole protects the thoracic and abdominal organs from the rear.

THORACIC SKELETON

Another part of the axial system is the thoracic (chest) skeleton, consisting of the thoracic vertebrae, the ribs, the costal cartilage, and the sternum (breastbone). The thoracic skeleton supports the chest and the shoulder girdle (which anchors the upper extremities) and provides a base of attachment for many of the muscles that move the arms. Also, the thoracic skeleton plays an important role in the mechanics of breathing.

Twelve pairs of ribs articulate with the vertebral column in the back and curve around toward the sternum in the front. Only the first seven pairs of ribs attach (by costal cartilage) to the sternum; these are called the "true ribs." The next three pairs of ribs are "false ribs," as they do not join directly to the sternum but are joined by costal cartilage to each other and to the seventh ribs. Last are two pairs of "floating ribs" which do not attach anywhere except to the vertebral column.

In the front center of the chest, extending from just below the neck down the front of the ribcage, is the sternum or breastbone. It is flat and narrow; its shield-like shape helps it protect the heart and middle respiratory tract. The sternum serves as the central point of attachment for the ribs and the clavicles (collarbones). This gives stability to both the thoracic skeleton and the shoulder girdle. It is also filled with red bone marrow and is an important site of red blood cell production.

Optional Activities

- Using a skeleton or model skeleton, examine the movements of the spine, especially the first two vertebrae which support the head.
- Using a skull or model skull, examine and identify the bones of the head.

BONES OF THE AXIAL SKELETON

<u>Location</u>	<u>Bone</u>	<u>Number of Bones</u>
skull	frontal	1
	parietal	2
	occipital	1
	temporal	2
	sphenoid	1
	ethmoid	1
	nasal	2
	zygomatic (malar)	2
	maxilla	2
	mandible	1
	lacrimal	2
	vomere	1
base of tongue	palatine	2
	inferior concha	2
middle ear	hyoid	1
	malleus	2
	incus	2
spinal column	stapes	2
	vertebrae	26
thorax	ribs	24
	sternum	1

AXIAL SKELETON

Post-Test

1. Which of the following is a part of the axial skeleton?

- A. phalanges
- B. skull
- C. tibia
- D. humerus

2. The only bone in the body which does not articulate with another bone is the

3. Name the five divisions of the vertebral column.

4. The tiny bones of the middle ear are called the:

- A. hyoid.
- B. ossicles.
- C. vertebrae.
- D. clavicles.

5. What are the two major divisions of the skull?

6. One of the major functions of the vertebral column is to:

- A. protect the spinal cord.
- B. articulate with the arms.
- C. amplify vibrations.
- D. support the lungs.

7. What are the 12 pairs of bones that protect the chest cavity?

8. What is the primary function of the skull?

- A. movement
- B. thought
- C. support
- D. protection

9. Which of the following is an important site of red blood cell production?

- A. hyoid
- B. costal cartilage
- C. sternum
- D. stapes

APPENDICULAR SKELETON

Goals

Upon completion of this module, you should be able to:

1. Identify the components of the appendicular skeleton.
2. Identify and describe the structure and functions of the appendicular skeleton.

Providing the body with structures for movement is the appendicular skeleton, which is made up of the bones of the appendages (arms and legs) and the rings of bone to which they are attached: the shoulder girdle and the pelvic girdle.

PECTORAL GIRDLE

The pectoral (shoulder) girdle serves as the bony foundation for the attachment of the arms to the body. It rides over the thorax (chest), anchored only by two bone-to-bone articulations and the muscles of the thorax. This loose attachment does not provide for great stability or strength, but it does give flexibility of movement and a great range of motion to the upper extremities. Anterior (front) components of the shoulder girdle are the two clavicles (collarbones), small long bones that curve slightly from the shoulder to the top edge of the sternum. The clavicles hold the shoulder joints out to the sides of the body. The sternum is the only bony connection between the axial skeleton and the shoulder girdle. The tip of each clavicle joins a scapula or shoulder blade, which forms the socket where the upper arm attaches. The scapulae do not articulate at all with the ribcage. The scapulae are broad flat bones, triangular in shape, pointing downward over the true ribs about two inches from the spinal column. They slide over the posterior (back) of the thorax, buried and cushioned in large masses of muscle.

UPPER EXTREMITIES

Each arm is composed of 30 bones. The humerus, the upper arm bone, is the bone that joins the scapula at the shoulder. In the forearm are two bones, the radius and the ulna. The ulna is on the little-finger side of the forearm, and connects with the humerus to form the elbow. On the thumb side is the radius, which rotates with the ulna to turn the palm of the hand up and down. Eight small bones called carpals form the wrist. They are arranged in two rows, and their placement allows for a wide variety of movements. Five metacarpals form the hand. These bones can be felt along the back of the hand and thumb where they join the bones of the fingers or phalanges. Each finger is made up of three phalanges (except the thumb, which has two) that articulate at the knuckles.

LOWER EXTREMITIES

The lower extremities attach to the pelvis or pelvic girdle, a heavy set of bones that forms the lower wall of the abdomen. In the pelvis are three areas of bone called the ilium, the ischium, and the pubis. First is the ilium, which forms the wing-like structures that are commonly termed the "hipbones." It connects to the flat sacrum in back, in immovable joints that add to the sturdiness of the pelvis; to the sides, the ilium forms part of the socket of the hip. Second is the ischium, which curves under to form two arch-like projections that bear the weight of the body when sitting. The ischium meets the ilium to form the second part of the hip socket. Third, the remaining part of the socket is formed by the pubis, the front portion of the pelvis.

This bony socket, formed by the connection of the ilium, ischium, and pubis, is the point of articulation with the leg. It is comparatively deep, and the bones composing it are thick and heavy; this adds to the stability of the leg-pelvis joint, which bears the weight of the body at the same time that it allows for freedom of movement.

Connected to the pelvis is the femur of the upper leg, the longest bone in the body. Like other long bones (and especially like the humerus), the femur has a long shaft broadening out at both ends. One end of the femur forms a heavy ball, which fits very closely into the socket of the pelvis; the other end widens to form the knee joint.

The patella or kneecap is a short bone which rides over and protects the knee joint. It articulates with the femur but is fairly loose; like the scapula, the patella is buried in muscle, which gives it the freedom of movement necessary to glide over the knee joint regardless of the position of the joint.

The knee is also formed by the tibia, or shinbone. Along with the fibula, the tibia forms the lower leg, and both bones join to form the ankle.

There they articulate with the talus, one of the seven short bones of the foot called tarsals. The tarsals correspond to the carpals of the wrist. The rest of the tarsal bones help distribute the weight of the body throughout the foot; the tarsals form the heel, which bears some of the weight, and the arches of the foot, which distribute weight forward to the metatarsals. These are similar to the metacarpals of the hand in that they provide the framework of the foot; this is, however, a weight-bearing instead of a manipulative framework. The metatarsals are therefore heavier, especially the first metatarsal (joining with the great toe), which bears much of the body's forward weight. The close articulation of tarsals and metatarsals helps distribute the weight of the body as equally as possible to all parts of the feet. Similar to the phalanges of the hand (except that they are shorter and broader) are the phalanges of the foot, which form the toes.

The upper and lower extremities in general are very similar in terms of numbers and arrangements (and even shapes) of bones; however, the actual structures of these appendages differ according to their functions. The bones of the arms are relatively loosely attached to the body and otherwise structured for the greatest possible freedom of movement. This serves the arm's manipulative function. The bones of the leg articulate closely with the heavy pelvis, and are themselves quite heavy; they enjoy a wide range of motion but not so varied as that of the arm. This suits the weight-bearing and locomotive functions of the legs.

Optional Activity

- Identify the bones of the appendages on a skeleton or model skeleton.

BONES OF THE APPENDICULAR SKELETON

Upper Extremities

<u>Location</u>	<u>Bone</u>	<u>Number of Bones</u>
shoulder girdle	{ clavicle scapula	2 2
upper arm	{ humerus	2
forearm	{ radius ulna	2 2
carpals	{ lunate triangular (triquetrum) hamate capitate pisiform scaphoid (navicular) trapezium trapezoid	2 2 2 2 2 2 2 2
hand	{ metacarpals	10
fingers/thumbs	{ phalanges	28

BONES OF THE APPENDICULAR SKELETON

Lower Extremities

<u>Location</u>	<u>Bone</u>	<u>Number of Bones</u>
hip	{ pelvic bone	2
upper leg	{ femur	2
kneecap	{ patella	2
lower leg	{ tibia fibula	2 2
tarsals	{ talus calcaneus cuboid navicular cuneiform I cuneiform II cuneiform III	2 2 2 2 2 2 2
foot	{ metatarsals	10
toes	{ phalanges	28

APPENDICULAR SKELETON

Post-Test

1. The appendicular skeleton includes which of the following?

- A. vertebrae
- B. femur
- C. ribs
- D. cranium

2. The shoulder girdle is also called the

3. The bone of the upper arm is the:

- A. humerus.
- B. sternum.
- C. femur.
- D. tibia.

4. The lower extremities attach to the:

- A. sternum.
- B. vertebral column.
- C. scapula.
- D. pelvis.

5. The eight small bones of the wrist are called:

- A. ossicles.
- B. carpals.
- C. vertebrae.
- D. tarsals.

6. The kneecap is also called the

7. The foot is designed primarily to:

- A. move upward toward the knee.
- B. protect vital organs.
- C. articulate with the pelvis.
- D. bear the weight of the body.

8. The structures of the appendicular skeleton allow the body to:

- A. breathe.
- B. see.
- C. move.
- D. hear.

9. The primary function of the patella is to:

- A. protect the knee.
- B. initiate movement.
- C. support muscles.
- D. produce blood cells.

10. Which of the following articulates with the femur?

- A. scapula.
- B. vertebra.
- C. pelvic girdle.
- D. clavicle.

INTRODUCTION TO THE MUSCULAR SYSTEM

Goals

Upon completion of this module, you should be able to:

1. Identify the major components and functions of the muscular system.
2. Classify different types of muscle.

Without muscles, the respiratory system could not take in air, the digestive system could not process food, and the circulatory system could not pump blood. Without muscle, the skeletal system would be like the poles in a tent. However, the body is packed with muscle--almost one-half of total body weight is made up of muscle.

FUNCTIONS OF MUSCLE

Muscle tissue is a special type of tissue made up of layers of very long, thin cells. These cells have the ability to contract, or become shorter, causing the entire tissue to become shorter. If the muscle is attached to bones, the contraction causes the bones to move; if the muscle surrounds an organ, the contraction may move the contents of the organ. Movement is the primary function of muscle, whether it is movement of the body (as in walking or dancing) or movement of materials within the body (for instance, food through the digestive system or blood through the circulatory system).

Contraction of muscles requires energy. Not all of this energy is used to produce movement, however; about three-fourths of the muscular energy goes to producing heat--a very important function of muscle. How muscular action contributes to heat production is probably apparent to anyone who has exercised heavily on a warm day, or to anyone who has stamped feet or paced around to keep warm while waiting out in the cold. Even shivering is an attempt by the body to produce more heat by raising the level of muscular activity throughout the body. Muscular activity is the body's major mechanism for heat production.

In terms of structure, the skeletal system would contribute very little to the shape and support of the body if it were not for muscle. To return to the tent pole comparison, the poles will not support the tent if something (usually rope) is not holding them in the necessary positions of support. The same is true for the bones in the body. Muscles exert the necessary pull to keep the bones in good alignment, in the proper positions of support. The alignment of the body is called posture. Maintaining posture is another important function of muscle.

TYPES OF MUSCLE

Muscular functions are performed by three types of muscle: smooth muscle, cardiac muscle, and skeletal muscle. Smooth muscle is the simplest type of muscle tissue. It is made up of elongated cells arranged in sheets, which form the walls of many of the internal organs or viscera. (For this reason, smooth muscle is often called visceral muscle.) Smooth muscle is found in the hollow organs of the digestive system (esophagus, stomach, intestine) as well as in the walls of blood vessels, the bladder, the uterus, in glands, and in the skin.

Smooth muscle contraction is involuntary. That is, it is not consciously controlled; the complexity of the functions performed by smooth muscle would occupy the mind completely if the actions of the muscle had to be controlled consciously. Smooth muscle causes the movement of materials within the smooth-muscle organs. Thus it is responsible for the movement of food through the digestive system, elimination of waste from the body, and so on.

Cardiac (heart) muscle is also involuntary muscle, although it has a very different function. Composed of elongated muscle cells or fibers which branch apart and rejoin throughout the tissue, cardiac muscle (also called myocardium) is the tissue responsible for the beating action of the heart. When the muscle contracts, the heart itself contracts, causing a heartbeat. Circulation of blood would not be possible without this type of muscle.

Unlike cardiac and smooth muscle, skeletal muscle is voluntary; that is, its action can be controlled consciously. This is the muscle attached to, and responsible for, the movement of the skeletal system. Skeletal muscle is made up of long, cylindrical cells lined up in strands or fibers. These fibers, when viewed through a microscope, are cross-banded with light and dark stripes, or striations. (For this reason, skeletal muscle is also called striated muscle.) The strands of muscle tissue are arranged in bundles that form the skeletal muscles.

MUSCLE ACTION

The ends of skeletal muscles are attached to bones; the middle and major portion of the muscle, where the greatest part of the contraction takes place, is called the body. This bulky body tapers off at either end to the tough, thin part of the muscle that attaches to bone. Most muscles cross a joint and are attached to different bones on each side of the joint. The muscle exerts different actions on the bones to which it is attached; one bone will remain stationary while the muscle pulls against it, using it as a support, in order to move the other bone. In this process, the area where the muscle attaches to the unmoving bone is called the origin of the muscle and the area on the bone that moves is called the insertion of the muscle. For instance, the biceps, the muscle which moves the forearm, has its origin in the bones of the shoulder, crosses the elbow joint, and inserts in a bone of the forearm. When the body of this muscle contracts, the shortened muscle pulls against the upper arm in order to move the forearm, causing the arm to bend at the elbow.

Most muscles work in groups--several muscles work together to produce movement. Usually, however, only one muscle in a group is primarily responsible for causing the movement; the other muscles only contribute to the movement, or help to stabilize the bones. The muscle most responsible for a specific movement is called the prime mover. The prime mover is different for different movements: one muscle might be the prime mover in bending the arm, but another would be the prime mover in straightening it.

However, in order for the arm to straighten, the muscle that contracts to bend it (biceps) must stop contracting, or relax, so that the muscle which contracts to move it back (triceps) can do its job. This fact illustrates the agonist-antagonist relationship of muscles: most actions of skeletal muscles (for instance, bending a limb) have opposing actions that reverse them (for instance, straightening the limb). Nearly every muscle has an opposing muscle that contracts to cause the opposite movement. The prime mover is the agonist; the muscle that causes the opposite movement is the antagonist. The prime mover of one action becomes the antagonist of the opposite action; the antagonist must relax when the agonist, or prime mover, contracts. (See Figure 3 on the next page.)

Skeletal muscle is the meat of the body. It is located throughout the body, covering the bones and the organs, giving the body form. Cardiac muscle powers the circulatory system, and smooth muscle surrounds the tubes of the body. Combined, the muscles are responsible for all of the movements of the body.

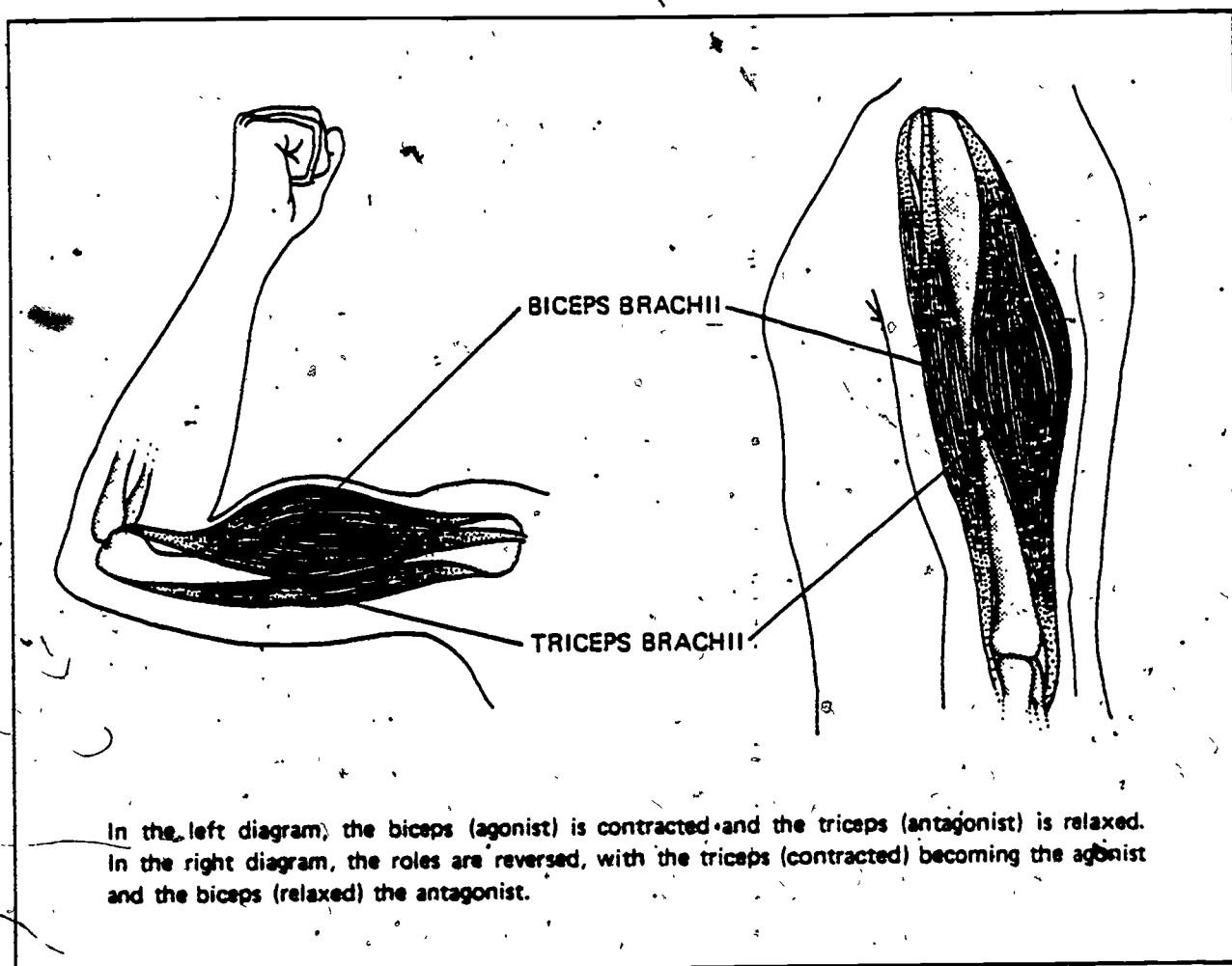


Figure 3. Agonist-Antagonist Muscle Action

Optional Activities

- Find muscle masses on yourself. Clench fists, point toes, raise limbs, and bend joints. Feel the areas where the muscles are contracted.
- Try to find agonist-antagonist muscle groups. Perform an action, a single movement, and then figure and perform the opposing action. Can you isolate the groups of muscle by feeling them?

INTRODUCTION TO THE MUSCULAR SYSTEM

Post-Test

1. Muscle cells have the ability to:
 - A. produce hormones.
 - B. ingest other cells.
 - C. produce bone cells.
 - D. contract.

2. One of the major functions of the muscular system is to:
 - A. transport nutrients.
 - B. produce heat.
 - C. protect the brain.
 - D. support the intestine.

3. The muscle most responsible for a particular action is called the:
 - A. antagonist.
 - B. prime mover.
 - C. stabilizer.
 - D. producer.

4. The areas where the two ends of a muscle attach are the:
 - A. agonist and antagonist.
 - B. flexor and extensor.
 - C. origin and insertion.
 - D. tendon and ligament.

5. The major portion of a muscle, where most of the contraction occurs, is called the.

_____.

6. Heart muscle is also called

_____.

7. Visceral muscle is also known as

_____.

8. Which of the following types of muscle is usually consciously controlled?

- A. skeletal
- B. smooth
- C. visceral
- D. cardiac

MAJOR MUSCLES OF THE BODY

Goals

Upon completion of this module, you should be able to:

1. Identify the major muscles and muscle groups of the body.
2. Identify and describe the actions of the major muscles of the body.

Most of the movements of the body produced by the muscles are either intended for locomotion (walking, running, climbing), or manipulation (lifting, twisting, carrying). Other movements serve neither function, but are responsible for important activities nonetheless--aiding in the mechanics of respiration, or helping to communicate. Muscles are structured in groups that act on sets of bones and joints; they are named by their action, location, origin or insertion, shape, or by any combination of these characteristics.

FACIAL MUSCLES

Facial muscles are among the few muscles in the body that attach to skin as well as to bone. They are responsible for the expressions of the face; the deeper muscles are necessary to speech and chewing. Some of the most important of the facial muscles are mentioned here. For example, the orbicularis oculi is the muscle that surrounds the eye and serves to close it. The zygomaticus pulls up on the corners of the mouth when it contracts, causing a smile. To make an unhappy expression, the triangularis does the opposite, pulling down the corners of the mouth. In the forehead is the corrugator, so named because it "corrugates" the forehead with frown lines. Contractions of the temporalis and masseter muscles close the mouth with a great clenching force. The lateral pterygoid, an internal muscle, pulls the jaw down to open the mouth. The tongue is also a muscle, contracting into different shapes to create the different sounds that contribute to speech.

MUSCLES OF THE EXTREMITIES

Most of the other muscles of the body are not attached to the skin as the facial muscles are; many of the muscles of the extremities attach to the trunk of the body in order to obtain the anchorage necessary to exert an effective pull on the appendicular bones. Even those muscles of the shoulder girdle that do not directly attach to the arm affect its actions. An example of this kind of muscle is the trapezius of the back, which connects to the base of the skull and the vertebral column down to the middle of the back; it moves the scapula, lifting and lowering it, and pulling the shoulders back. This is the muscle that moves your shoulders when you shrug. Also on the back is the latissimus dorsi, a broad, fan-like muscle which pulls the arm back. In the front, the pectoralis major originates on the clavicle and sternum, covering the chest to the seventh rib, and inserts on the upper arm; it raises and rotates the arm. The deltoid covers the shoulder and inserts on the humerus to raise the arm straight out like a wing.

On the arm itself, the best-known muscle is the biceps brachii, which originates at the shoulder joint and inserts on the forearm. This muscle brings the wrist to the shoulder by bending the elbow; it accounts for most of the muscle bulk of the upper arm. Its antagonist is the triceps brachii, which runs from the shoulder joint to the elbow along the back of the arm; it straightens the arm. In the forearm, the pronators and supinator rotate the arm in both directions. The many muscles in the wrist, hand, fingers, and thumb make possible the movements of these areas.

A large number of muscles of the lower extremities (legs) originate on the pelvic girdle. Among them is the quadriceps femoris group, some of the largest and strongest muscles in the body. The prime mover of the quadriceps group is the rectus femoris. The muscles of this group attach to the front part of the pelvis and insert on the femur and the bones of the lower leg. They draw the thigh up toward the belly, or straighten the leg out at the knee, and are very important in actions such as walking, running, or bicycling. In the back is the gluteus maximus, or muscle of the buttocks, which pulls the leg backwards and is also important to locomotion, especially climbing. Also in back is the hamstring group, made up of muscles which originate on the pelvis and insert on the bones of the lower leg. When the hamstrings contract, they pull the thigh back, or bend the knee and bring the heel up to the buttocks. In the inner thigh are the adductors, which draw the legs together.

In the back of the lower leg, the midcalf muscle mass is called the gastrocnemius. It originates at the femur and inserts on the heel bone; when it contracts, it pulls the heel up to force the toes down, as when standing on tiptoe. The gastrocnemius is very important to many activities ranging from walking to ballet dancing. An antagonist muscle to the gastrocnemius muscle

is the tibialis anterior, which runs down the length of the tibia or shinbone. The tibialis anterior originates near the knee and inserts on the toes; it contracts to pull the toes up toward the knee. There are also many muscles in the ankle, foot, and toes that contribute to lower leg and foot movements.

MUSCLES OF THE TRUNK

Muscles of the trunk control the position of the spine and are important to body posture. The erector spinae of the back are muscles that attach to the base of the skull and the pelvis; when contracted, they hold the back straight and upright. The antagonist muscle is the rectus abdominus, which originates at the pelvis and inserts on the ribs. Running down the middle of the belly, this muscle contracts to pull the head down toward the knees, as in doing a sit-up. The transverse abdominal muscle, a deep muscle, contracts to flatten the abdomen and is useful for any abdominal pushing, such as the movement that occurs in a woman's body when she is giving birth. In the chest, the internal muscles include the intercostal muscles of the ribcage, which lift and lower the ribs in breathing. The diaphragm is the major internal muscle of breathing. It has no antagonist group; its relaxation produces the movement opposite to that produced by its contraction.

MUSCLE CONTRACTION

In all of these major muscles, the function of contraction depends on the structure of the muscle tissue. Basically, the long strands or fibers of muscle tissue are composed of overlapping bands of cells. When stimulated by electrical impulses, the overlapping bands of muscle are drawn together and slide over one another, which shortens each individual muscle fiber. A shortening of all the fibers at once causes a shortening (or contraction) of the entire muscle. Depending on the orientation of the fibers, the contraction is along the length of the muscle (as in skeletal muscle), or in a ring around the organ walls (as in smooth-muscle organs). Different types of muscles thus accomplish their different functions by contracting to produce movements. Some of these muscles contract quickly and strongly to produce movements such as running. Others contract slowly and steadily, such as the muscles which maintain the body's posture.

Figure 4, on the next page, shows a frontal view of the major muscles of the body.

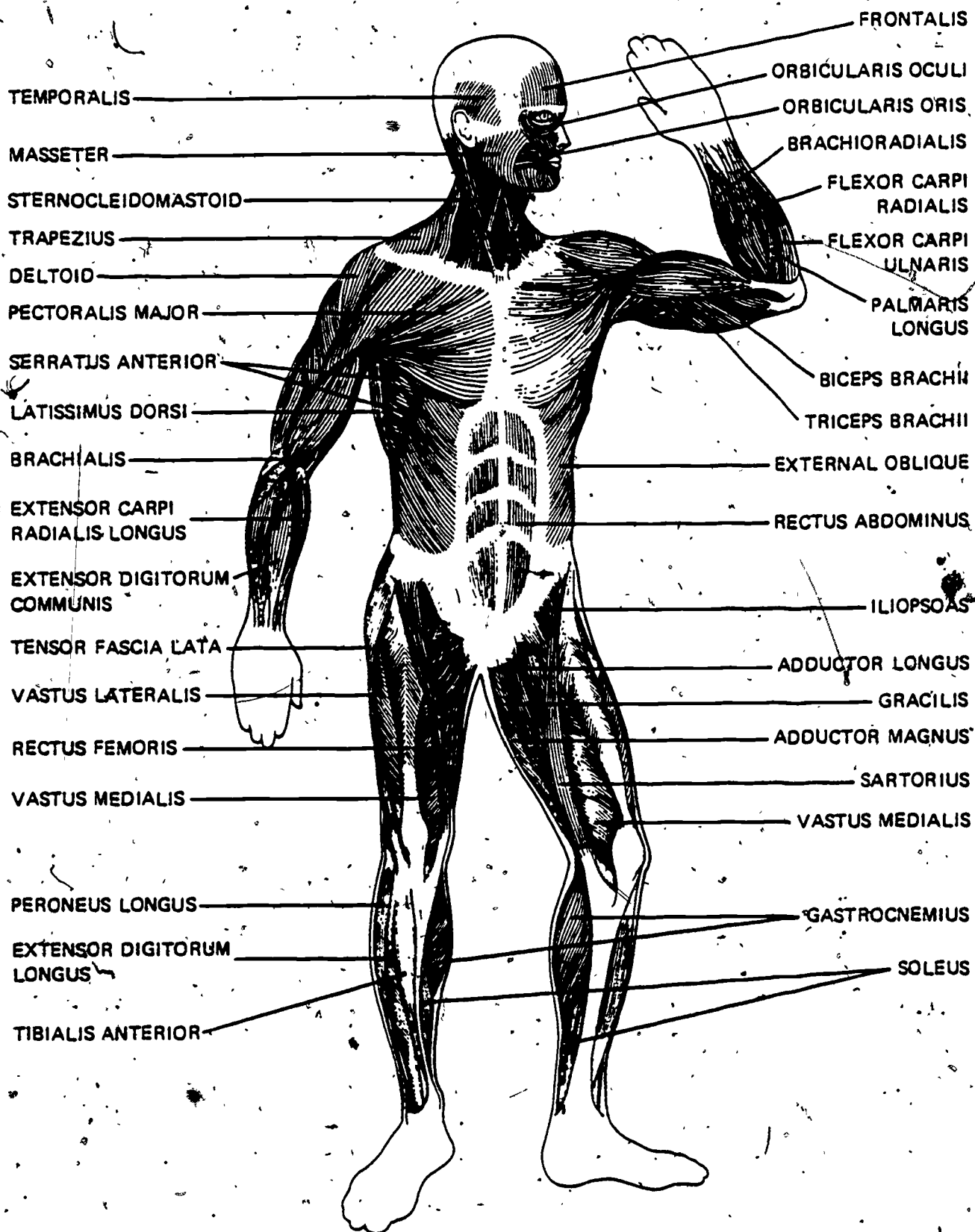


Figure 4. The Muscular System

Optional Activities

- Clench your jaw tightly, feeling different areas of your face as you do so. Can you identify the muscles that are producing the tension?
- On diagrams of the skeleton, draw the major muscles of the body.

MAJOR MUSCLES OF THE BODY

Post-Test

1. Which of the following is a muscle of the face?
 - A. tibialis anterior
 - B. pectoralis
 - C. obicularis oculi
 - D. trapezius

2. Which group of muscles is located on the front of the thigh?

3. The hamstring muscles are located:
 - A. in the chest.
 - B. on the back of the thigh.
 - C. in the lower back.
 - D. above and behind the jaw.

4. The muscles which raise the arms up from the side are the:
 - A. deltoids.
 - B. intercostals.
 - C. latissimus dorsi.
 - D. gluteals.

5. Which of the following is a prime mover in the action of doing a sit-up?

- A. intercostal
- B. diaphragm
- C. tibialis anterior
- D. rectus abdominus

6. The prime mover in straightening the lower leg is the:

- A. gastrocnemius.
- B. rectus femoris.
- C. trapezius.
- D. pectoralis,

7. Which of the following muscles move the ribcage?

- A. adductors
- B. biceps
- C. intercostals
- D. hamstrings

SUPPORTING STRUCTURES OF THE MUSCULOSKELETAL SYSTEM

Goals

Upon completion of this module, you should be able to:

1. Identify the supporting structures of the musculoskeletal system.
2. Describe the functions of the supporting structures of the musculoskeletal system.

In order for the muscular system and the skeletal system to function together smoothly, there must be several supporting structures to link the two systems. For instance, there are tough connective materials to attach muscle to bone, and even tougher connective material to attach bone to bone in the hard-working joints. The joints themselves, which are structured for specific functions, are crucial to the functioning of the musculoskeletal system.

TENDONS

Muscle-to-bone connections are made by tendons. Tendons are very strong, thick strands of fibrous (and therefore tough) connective tissue that connect muscles to bone. They can be very long, if necessary, to extend the effective reach of a muscle to a length that the muscle alone might not be able to achieve. This is important for bones that are fairly far apart (as in muscles of the thigh, for example, which originate on the upper edge of the pelvis and insert below the knee). Because they are much thinner than muscle tissue, tendons can attach in places where bulky muscle tissue would not fit. Finally, tendons, being tough, can withstand far more of the wear and tear caused by joint action than can the softer flesh of muscle.

LIGAMENTS

Ligaments surround or cross joints to connect bone to bone. In many articulations, thick layers of ligaments are wrapped around the bones, and thus help to form the joint structure; they also pass from bone to bone along the lengths of parallel limb bones, as in the forearm and lower leg. Made of very tough fibrous connective tissue, ligaments give stability and support to the joints and the skeletal system as a whole.

ARTICULATIONS

Joints, or articulations, are classified into three types according to structure; their structures relate to the functions they serve within the musculoskeletal system. Articulations are classified as non-movable, partly movable, or freely movable, depending on the range of motion they allow between the connecting bones.

Non-movable articulations are also called fibrous joints because the bones are tightly bound by fibrous sheets of tissue which permit no bone motion. An example of a non-movable joint is the connection of the tibia and the fibula above the ankle. Sometimes, as in the skull sutures, the joint is almost completely bone-to-bone, with very little tissue needed because the bones fit together so closely. Non-movable joints serve a protective function (as in the skull) or a strengthening and supportive function (as in the articulation between the pelvis and the sacrum).

Partly movable joints are also called cartilaginous joints because a cushion of cartilage connects the bones. Because cartilage is not very flexible, little movement is allowed in each individual cartilaginous joint. However, many partly movable joints in a series, each with a slight degree of motion, can permit a large range of motion. This explains the great flexibility of the spinal column, which articulates in cartilaginous joints. Examples of cartilaginous joints where very little movement is permitted include the sternum-rib articulations and the connection of the two pubis bones of the pelvis. Movement in these joints is not desirable because they serve mainly protective functions.

Movements associated with locomotion and manipulation are permitted by the freely movable articulations--the third category of joints. Freely movable articulations are also called synovial joints because of a membrane, the synovial membrane, which lines the joint area and secretes a special lubricating fluid

(synovial fluid) to help reduce friction as the moving bones slide over one another. Ligaments around the joint form the capsule that contains this fluid, and pads of cartilage coat each articulating surface for improved smoothness of movement. The cartilage pads also absorb the shock associated with the function of many of these bones (for instance, landing on your feet after you jump causes a shock to the knee joints).

Most of the freely movable joints are in the skeletal areas of the body that are involved in active movement--that is, the appendicular skeleton. There are several kinds of freely movable joints, each permitting a different type of motion. A hinge joint allows the type of motion involved in bending and straightening the elbow, the fingers, or the knee. A pivot joint allows for the rotation seen between the ulna and the radius of the forearm. A saddle joint allows the relatively free motion of the thumb. Ball-and-socket joints, such as those found in the hip and shoulder, permit the great freedom of movement allowed by those joints.

Exactly how muscles and bones work together and produce movement, and what kinds of movement they can produce, is the subject of the next module.

Optional Activities

- On a skeleton or model skeleton, examine the different types of joints and their movements.
- Find out about the structure of the knee joints and why so many athletes have problems with it.
- The next time you eat chicken at home, examine the tendons, ligaments, and joints of the chicken. Are they similar to those found in the human body?
- Examine x-rays of various types of joints. Can you guess the function of the joint from the structure? What movement does it permit?
- Discuss what would happen to the joints, and to the musculoskeletal system as a whole, if there were no ligaments.

SUPPORTING STRUCTURES OF THE MUSCULOSKELETAL SYSTEM

Post-Test

1. The most important structures in the connection of bone to bone are called:

- A. tendons.
- B. ligaments.
- C. synovial capsules.
- D. articular cartilage.

2. The sutures of the skull are examples of what type of joint?

3. Cartilaginous joints are:

- A. freely movable.
- B. non-movable.
- C. partly movable.
- D. capable of only one movement.

4. The variety of movements required for locomotion and manipulation are provided mainly by what type of joint?

MOVEMENTS

Goals

Upon completion of this module, you should be able to:

1. Identify and describe different human movements.

Movements, like muscle groups, generally occur in pairs. For most movements that take a part of the body in one direction, there is another movement that takes it in the opposite direction. Not surprisingly, most of the opposing movements are produced by agonist-antagonist muscle groups.

There are four major types of movement possible in the musculoskeletal system, as well as several other types of movement. When these different movements are combined, they allow for the amazing range and variety of motions that characterize the actions of the musculoskeletal system.

FLEXION-EXTENSION

Two movements necessary to most actions of the body are flexion and extension. Flexion involves bending a joint to bring areas closer together, as when the elbow is bent to bring the forearm to the shoulder. In a better definition, flexion is the movement that makes the angle of a joint smaller. The opposite motion is extension, which straightens joints to straighten or stretch the body or the extremities. At the elbow, flexion is accomplished by the biceps brachii. When this muscle contracts, it pulls on the forearm bones to bend the elbow and raise the wrist toward the shoulder. Its antagonist muscle, the triceps brachii, is the extensor of the arm; when it contracts, it shortens over the back of the arm and elbow to pull the forearm back into a straight position. (Remember that for any one muscle group to accomplish its task, while it contracts its antagonist muscle group must relax. With a few exceptions, at least two muscle groups are involved in every movement.)

In the leg, the hamstring muscles in back contract to bend the knee and flex the leg; this action brings the heel toward the buttocks. The leg is straightened out at the knee by the quadriceps femoris muscles, which run over the knee and which, when contracted, pull the lower leg to a straight position. Flexion and extension are the two movements allowed by the hinge structure of the elbow and knee joints.

The vertebral column has less freedom of motion, but also flexes and extends like any other bone-joint combination. In flexion of the vertebral column, the body bends forward (as when performing sit-ups); this movement is accomplished by strong contraction of the rectus abdominus muscle of the belly. This muscle attaches to the bottom edges of the ribs and pelvis and, when contracted, pulls these areas together; this makes the spinal column bend and curve forward. The vertebral column is straightened out, or extended, by the long muscles of posture, which attach to the skull and pelvis. When these muscles contract, they pull the back of the head toward the buttocks, straightening and lifting the spinal column.

ABDUCTION-ADDUCTION

Abduction and adduction are two other paired movements. Abduction is the movement of a body part away from the midline of the body; adduction is the movement of a part toward the midline of the body. Again, these movements are accomplished by agonist-antagonist muscle groups. In abduction of the arm, the prime mover is the deltoid muscle of the shoulder. This muscle attaches to the clavicle and the upper humerus; when it contracts, it shortens over the shoulder joint, pulling the arm directly up over the side. Adduction of the arm is accomplished by the latissimus dorsi, which attaches across the back to the spinal column and humerus, and the pectoralis of the chest. They contract to pull the arm in toward the side of the body. The action of "flapping wings" is actually a rapid abduction and adduction of the arms.

Abduction of the leg, or lifting it out to the side, is done by the deep gluteal muscles and a muscle that attaches to the outside of the pelvis and the outside surface of the femur. Adduction is accomplished by the adductor muscles on the inside of the thigh, which attach to the pubis bone and to the upper femur. These muscles do not bend the knee when they contract because the knee joint is not structured to bend sideways.

ROTATION-CIRCUMDUCTION

Rotation and circumduction, two other kinds of movements, are both basically circular motions. . Rotation is an actual, basic movement; circumduction is a combination of basic movements (flexion, abduction, extension, and adduction). Rotation (e.g., pointing the knee or elbow outward or inward) is the rotation of a body part. The humerus, femur, neck, spine, and scapula are capable of rotation. Tracing an imaginary circle with the finger (arm extended) is an example of circumduction.

SPECIAL MOVEMENTS

Several other special movements are made possible by muscular and skeletal interaction. Supination and pronation are two forms of rotation of the forearm made possible by the pivot joint which allows the radius to rotate around the ulna. Supination is the act of turning the palm from facing the floor to facing the ceiling when the arm is extended. Pronation is the opposite movement, turning the palm towards the floor. These movements contribute greatly to the manipulative abilities of the arms and hands.


Muscles of the lower leg and foot contract to turn the foot inward (inversion) and the antagonist muscles act to pull it outward (eversion). Two other movements of the foot are dorsiflexion and plantar-flexion. Dorsiflexion is a form of flexion, or bending of the foot at the ankle. This movement pulls the foot up so that the toes point toward the knees. Plantar-flexion is a form of extension, or straightening out of the foot at the ankle (the foot, however, is normally at right angles to the leg, so that plantar-flexion is not the foot's customary state of rest but a definite movement). In plantar-flexion, muscles at the back of the leg pull the heel up, which forces the toes down. Obviously, these two movements are very important in walking and in other forms of locomotion.

Muscles, bones, and joints must act together to produce these movements. The combinations of all these individual movements of the musculoskeletal system make possible the incredible variety of motion of which the human body is capable. Each movement and combination of movements has its own special functions--functions made possible by the structures of the musculoskeletal system working together.

Optional Activities

- Take a simple series of motions such as walking across the room and sitting down, and break it into its component movements. What muscle groups are being used? Joints? Bones?
- Use a model skeleton to study the movements of different parts of the body. For example, note why abductors-adductors do not bend the knee, how the radius rotates around the ulna, and how the head moves in different directions.
- Try to complete the word maze on the following page. It uses some of the terms that you learned in this unit.

WORD MAZE



Find the following terms in this maze by circling the words. They may appear frontwards or backwards, vertically, horizontally, or diagonally.

agonist

flexion

supination

carpal

incus

synovial joint

coccyx

marrow

tendon

cranium

patella

vertebra

epiphysis

scapula

MOVEMENTS

Post-Test

1. Bringing the palm of the hand from the hip to the shoulder is an example of which of the following movements?
 - A. extension
 - B. circumduction
 - C. eversion
 - D. flexion

2. Going from a squatting position to a standing position requires which of the following movements of the lower leg?
 - A. adduction
 - B. extension
 - C. flexion
 - D. rotation

3. Which of the following are special movements of the forearm?
 - A. inversion - eversion
 - B. dorsiflexion - plantar-flexion
 - C. supination - pronation
 - D. rotation - circumduction

4. Pointing the knee outward requires what basic movement of the upper leg?

5. Which of the following movements describes dorsiflexion?

- A. pointing the toes inward
- B. bringing the palm to the shoulder
- C. pulling the toes toward the knee
- D. pointing the palm upward

GLOSSARY

abduction: lateral movement away from the midline of the body.

adduction: lateral movement toward the midline of the body.

agonist: a muscle primarily responsible for a movement; a prime mover.

antagonist: a muscle with a movement opposite to that of an agonist.

anterior: pertaining to the front.

appendicular skeleton: the bones of the pelvis, shoulder, and extremities.

articulation: a connection between bones; a joint.

axial skeleton: the bones of the skull, vertebral column, and ribcage.

ball-and-socket joint: the shoulder and hip joints.

body (of a muscle): the main portion of a muscle; the area where most of the contraction takes place.

cardiac muscle: the muscle of the heart; myocardium.

carpals: the eight short bones of the wrist.

cervical vertebrae: the first seven vertebrae.

circumduction: the movement of a body part in a circular motion.

clavicle: the collarbone; a part of the shoulder girdle.

coccyx: the tailbone; the last portion of the vertebral column.

contraction: the shortening of muscle fibers.

costal cartilage: the cartilage that attaches the ribs to the sternum.

cranium: the portion of the skull that encloses the brain; consists of eight bones.

diaphysis: the shaft of a long bone.

epiphysis: one of the two ends of a long bone.

eversion: the outward movement of the foot.

extension: a movement which straightens a joint; the opposite of flexion.

flat bone: a flat sheet-like type of bone, as found in the skull.

flexion: a movement which closes a joint; the opposite of extension.

gluteal: muscles of the buttocks.

hamstrings: the muscle group of the back of the thigh which flexes the lower leg.

hinge joint: a joint with two-way motion, such as the elbow and knee.

hyoid bone: a small bone at the base of the tongue.

incus: a small anvil-shaped bone of the middle ear.

insertion: one of the areas where a muscle attaches.

intercostals: muscles of the ribcage.

inversion: an inward movement of the foot.

irregular bone: bones with unique structures.

ligaments: connective tissues which support and attach structures, especially bones.

long bone: the most common type of bone, found in the arms and legs.

lumbar vertebrae: the vertebrae of the lower back.

malleus: a small hammer-shaped bone of the middle ear.

marrow: a substance found inside bone; red or yellow.

muscle: body tissues which contract to produce movements.

origin: one of the areas where a muscle attaches.

ossicles: the small bones of the middle ear; the incus, malleus, and stapes.

patella: the kneecap.

pectoral girdle: the shoulder girdle, formed by the clavicle, scapula, and humerus.

pelvic girdle: the bones which form the hip joint.

phalanges: the bones which form the fingers and toes.

pivot joint: a joint which allows rotation, such as between the radius and ulna.

plantar-flexion: the movement which points the toes and foot downward.

posterior: pertaining to the back or rear.

prime mover: the muscle primarily responsible for a given movement; agonist.

pronation: the movement of the forearm which turns the palm upward.

quadriceps: the muscle group of the front of the thigh which extends the lower leg.

rotation: a movement causing a body part to rotate.

sacrum: five fused vertebrae which form a part of the pelvis.

scapula: the shoulder blade.

skeletal muscle: muscles which produce movements of the skeleton; striated muscle.

skull: the bones of the head; comprises the facial bones and the cranium.

smooth muscle: involuntary muscle; visceral muscle.

stapes: a small stirrup-shaped bone of the middle ear.

striated muscle: skeletal muscle.

supination: the movement of the forearm which turns the palm downward.

sutures: the immovable joints of the skull.

synovial fluid: the lubricating fluid produced by synovial membranes.

synovial joint: a freely movable joint.

synovial membrane: the membrane which surrounds a synovial joint.

tarsals: short bones of the foot.

tendon: a strip of strong connective tissue that connects muscle to bone.

thoracic vertebrae: the 12 vertebrae of the thorax.

vertebral column: the spine or backbone.

visceral muscle: muscle of the internal organs; smooth muscle.

ANSWERS TO THE PRETEST

Question

Correct Response

1.

D

2.

B

3.

sternum

4.

C

5.

muscle

6.

D

7.

D

8.

tendon



9.

D

10

adduction

/HEALTH OCCUPATIONS EDUCATION MODULE



INSTRUCTOR'S GUIDE
THE MUSCULOSKELETAL SYSTEM

Instructional Materials in Anatomy and Physiology
for Pennsylvania Health Occupations Programs

INSTRUCTOR'S GUIDE:
THE MUSCULOSKELETAL SYSTEM

Prepared for:

Research Coordinating Unit for Vocational Education
Pennsylvania Department of Education
Box 911
Harrisburg, Pennsylvania 17126

Prepared by:

National Evaluation Systems, Inc.
30 Gatehouse Road
Amherst, Massachusetts 01002

June, 1979

INTRODUCTION

These instructional modular units have been developed for the Pennsylvania Department of Education for use in vocational education programs. They were designed on the assumption that a basic understanding of human anatomy and physiology is essential to any person preparing to enter a health care occupation such as practical nursing, nursing assistant, medical assistant, emergency medical technician, or dental assistant. Each of these modular units will cover the most important aspects of one of the major systems of the human body. In the first four units the following systems will be covered: circulatory system, respiratory system, musculoskeletal system, and digestive system.

This Instructor's Guide is designed to provide suggestions to you on how to use a modular unit most effectively in your instruction. These recommendations, however, do not represent the only way to use these units; you may be able to devise more beneficial uses for the materials.

THE MODULAR UNITS

Each modular unit is made up of several components: a pretest, four to seven instructional modules with corresponding post-tests, optional activities for the students, and a glossary of terms used in the unit. Each of these components has a specific purpose and is organized in a specific way, as will be explained in the following sections.

Pretest

After reading the preface, which is simply an introduction to these instructional units, a student working through a modular unit should first take the pretest. As its name implies, this test is designed to be taken by the student before beginning work on the materials contained in the unit. Its purpose is twofold: (1) to stimulate interest in the modular unit by giving the student a preview of the topics covered, and (2) to provide a means of self-diagnosis so the student may identify, based on performance on the pretest, those areas of the

modular unit which may require special attention and extra effort on the part of the student. After selecting an answer to each of the pretest questions, the student should turn to the back of the modular unit and check the correct answers. If the student answers incorrectly on a number of questions dealing with a particular subject, then the student should pay closer attention to the module on that subject.

Instructional Modules

This modular unit is composed of seven separate but closely related modules, including: Introduction to the Skeletal System, Axial Skeleton, Appendicular Skeleton, Introduction to the Muscular System, Major Muscles of the Body, and Movements. After taking the pretest and checking the answers, the student should read through and study each of the instructional modules. For the student's benefit, each module begins with a statement of the goals, or objectives, that a student should have mastered upon completion of that particular module. The level of achievement of these goals is measured by the student's performance on the corresponding post-test. The language level and content of each module is aimed toward the student seeking an introduction to the components, structures, and functions and the basic terminology required for an understanding of the musculoskeletal system.

Optional Activities

Following many modules are optional activities intended to provide the student with an opportunity to pursue the content of the module at a more in-depth level. Many of these activities may require teacher participation, at least in obtaining and preparing additional materials for the student to utilize.

In addition to the optional activities available to the students, you may choose to provide further information to the students by teaching a brief unit on the common disorders of the musculoskeletal system. Discussion of these disorders has not been included in the texts because a basic knowledge of the proper structure and function of the human body in a healthy individual seems more appropriate for the purposes of an introductory program. If you do choose to discuss common disorders, the most effective approach may be one in which you use disorders to illustrate what can go wrong in the body, as a means of clarifying the students' understanding of how the body works when functioning properly.

You may also wish to provide students with the names of books or articles as suggested readings to further their understanding of a particular area.

Glossary

After the last of the modules in the unit is a glossary. This is not intended to be a comprehensive glossary to be used by the student as a dictionary. Rather, it includes the basic terms used in the unit which are necessary to an understanding of the system covered. Those words which appear in the modules and have been defined in the text are not always defined in the glossary. Some of these particular terms have been used in the module because they are essential but difficult terms needed to explain the content taught in the unit. The student should use the glossary to review the vocabulary essential to the unit before taking the post-tests.

Post-Tests

The post-tests are the final assessment of a student's understanding of the material presented in each module. They consist of multiple-choice and open-ended questions designed to measure a student's mastery of the goals (objectives) stated at the beginning of each module. Each of the questions has been written to measure an aspect of the skills and/or knowledge that a student may be expected to acquire as a result of working through a particular module. When a student has finished studying a module, has pursued any chosen optional activities, and has reviewed the vocabulary in the glossary, the student should take the post-test that follows the module.

SCORING THE POST-TESTS

As previously mentioned, the purpose of the post-tests is to measure whether or not a student has mastered the objectives (goals) stated at the beginning of each module. Due to the differing lengths of the post-tests, the variety of ways in which teachers may choose to utilize these modules, and discrepancies among students' previous exposure to the subject matter, it is not practical to set a standard cut-off score on each of the tests that would indicate mastery of the objectives. Rather, teachers are asked to use their professional judgment in individual cases to determine if a student's performance on a post-test indicates that he or she has mastered the objectives stated for that module. In making this determination, you should consider at least all of the following factors:

- (1) How long is each post-test?
- (2) How much information is included in each module and how complex is the information, relative to other modules?
- (3) Has the student been exposed to the kind of curricular material before? That is, has the student been taught the basics of this system of the body before?
- (4) Should the entire class be required to achieve a certain score in order to pass, or should each student be considered individually? (This depends on how and with whom you use this module as instructional material.)
- (5) Should the student be graded pass/fail on each post-test--i.e., on mastery of each module--or on the unit as a whole?

To facilitate the scoring of post-tests, each student will record his or her answers to all the post-tests on one separate sheet of paper. You should mark each answer correct or incorrect, then give the student a "pass" or "fail" on each module, or on the unit as a whole.

Because of the subject matter, responses to open-ended questions may vary slightly from those listed below, but these responses may also be acceptable. Again, in these cases instructors are asked to use their professional judgment to determine if a response is correct.

Use the following list of answers to questions on the post-tests to grade your students' papers.

ANSWERS TO THE MUSCULOSKELETAL SYSTEM POST-TESTS

Module/Question

Correct Response

Introduction to the Skeletal System:

- 1
- 2
- 3
- 4
- 5
- 6
- 7
- 8
- 9
- 10

- 206-
- axial skeleton,
appendicular skeleton
- C
A
muscle
B
A
D
long (bone)
C

Axial Skeleton:

- 1
- 2
- 3
- 4
- 5
- 6
- 7
- 8
- 9

- B
hyoid
- cervical, thoracic, lumbar,
sacral, coccygeal
- B
facial, cranial
A
ribs
D
C

Module/Question

Correct Response

Appendicular Skeleton:

- 1
- 2
- 3
- 4
- 5
- 6
- 7
- 8
- 9
- 10

- B
pectoral girdle
A
D
B.
patella
D
C
A
C

Introduction to the Muscular System:

- 1
- 2
- 3
- 4
- 5
- 6
- 7
- 8

- D
B
B
C
body
myocardium
smooth (involuntary) muscle
A

Major Muscles of the Body:

- 1
- 2
- 3
- 4
- 5
- 6
- 7

- C
quadriceps
B
A
D
B
C

Module/Question

Correct Response

Supporting Structures of
the Musculoskeletal System:

- 1
- 2
- 3
- 4

B
non-movable, fibrous
C
synovial, freely movable

Movements:

- 1
- 2
- 3
- 4
- 5

D
B
C
rotation
C